

Effects of melatonin on histopathological changes after experimental ovarian torsion-detorsion in cat

Fatemeh Mostajeran¹ M.D., Maryam Naderi¹ M.D., Shahriar Adibi² D.V.M.

1 Department of Obstetric and Gynecology, Isfahan University of Medical Sciences, Isfahan, Iran.

2 Torabienejad Dental Research Center, Isfahan University.

Received: 11 May 2007; accepted: 27 December 2007

Abstract

Background: During the detorsion of a torsioned ovary, oxidant agents are released and melatonin as an antioxidant can reduce ischemia. We studied the histopathological changes after using melatonin on experimental torsioned ovary in cat.

Objective: The aim of this experimental study was to investigate the effects of Melatonin on histopathological changes in torsion – detorsion injury in cat ovary.

Materials and Methods: An adnexal torsion – detorsion model was created by using 20 adult cats randomly divided equally in to 2 groups of Saline and Melatonin. Ischemia was induced by iatrogenic 360° clockwise torsion of the cat adnex for 3 hr. Reperfusion was achieved for 3 hr. Melatonin or saline were injected intra peritoneally (10mg/kg) 30 min before ovarian detorsion in both groups. After 3 hr of ovarian detorsion, ovarian tissue was removed and fixed in 10% formalin solution, embedded in paraffin and evaluated for ischemic indices.

Results: Histological examination showed a significant improvement in ovarian morphology in the melatonin treated cats. Edema and vasoconstriction in saline group were more severe than Melatonin group (p-value = 0.009). Hemorrhage and leukocyte infiltration were also more obvious in saline group (p-value 0.0018)

Conclusion: Our results demonstrated that Melatonin administration reduced ovarian histopathological damage due to oxidative injury associated with torsion.

Key words: Melatonin, Saline, Ischemia, Reperfusion, Cat.

Introduction

Ovarian torsion is a serious gynecologic problem and is most common in premenarchal girls and women of childbearing age (1-3). Because most of these women desire future fertility, the removal of an ovary could later adversely effect their reproductive life. On the other hand, when future fertility desired, rapid diagnosis is important and conservative management includes detorsion of the Involved segment (3,5). During the detorsion process an

excess amount of molecular oxygen is supplied to the tissues and abundant amount of ROS (reactive oxygen species) are produced. Accumulation of activated neutrophils and release of Ros such as $O_2^{\cdot-}$, $O^{\cdot}H$, H_2O_2 which interact with proteins, lipids and nucleic acids resulting in loss of cell membrane integrity and structural or functional changes in proteins (6-10). Melatonin is a biologically relevant indole compound and a free radical scavenger antioxidant which protect cells against the damage induced by several oxidative agents (11-14).

The protective effects of Melatonin on ovarian ischemia-reperfusion has not yet been investigated until Turkoz et al in Malataya (2004) demonstrated that Melatonin administration reduced the morphological changes by inducing Ischemia/Reperfusion(I/R). In particular,Polymorphonuclear Neutrophilic (PMN) infiltration, edema,

Correspondence Author:

Dr. Fatemeh Mostajeran, Department of Obstetric and Gynecology, Isfahan University of Medical Sciences, Isfahan, Iran.

Email: mostajeran@med.mui.ac.ir

hemorrhage and vascular dilatation were much lower but hadn't been totally prevented (15). To determine whether treatment with Melatonin modifies ischemic indices, we examined its effects on an *in vivo* model of adnexial Ischemia/Reperfusion injury in cats. The aim of the present study was to investigate the effects of Melatonin on histopathological change in I/R injury in cat ovaries.

Materials and methods

To determine whether ischemia followed by subsequent reperfusion induces ovarian damage and the effects of Melatonin on the injured ovaries, we created a model of adnexial I/R using cats. The permission for the animal tests and experiments was given by the center of animal researches of professor Torabynegad Institution of Isfahan University. All surgical procedures were performed while the cats were under general anesthesia. In total twenty cats with almost similar weights were subjected to right unilateral 360° clockwise adnexial torsion by a ring forceps which induced ischemia by occlusion of the tuboovarian vessels for 3 hr (15-17).

Melatonin (10mg/kg) that is a white lipophil powder was dissolved in 1% ethanol (total volume =10 cc) just before use and injected intra peritoneally 30 min before reperfusion in the Melatonin group while saline was administered (10cc) in the saline group. Reperfusion was achieved by releasing the occlusion and restoring the circulation for 3 hr. After 3 hr, cats in both groups were reanesthetized, laparotomy was performed and right ovaries were surgically removed. The ovaries were preserved in formalin for histopathological examination.

Histopathological examination

At the end of each experiment, the ovaries were removed and fixed in 10% neutral buffered formalin solution and then were embedded in paraffin as usual. Serial sections were cut using the microtome at a thickness of 4 μ m and were stained with hematoxylin and eosin. The histologic sections were examined for the presence of interstitial edema, vascular congestion, hemorrhage and PMN infiltration, using a microscope. The slides were coded and semiquantitative analysis of the sections was performed without knowledge of the treatment protocol.

The changes seen were graded as follows (16):
Grade I: Mild edema / Mild vascular congestion/No hemorrhage /No PMN.
Grade II: Moderate edema / Moderate vascular congestion / No hemorrhage /No PMN.
Grade III: Severe edema/Severe vascular Congestion /Minimal hemorrhage / Minimal PMN.
Grade IV: Severe edema / Severe vascular congestion / Severe hemorrhage / Severe PMN.

Statistical analysis

The Statistical package for social sciences (SPSS) version 10 was used for statistical analysis. Individual group parameters were assessed with Manwhitney test. The spearman's test determined the correlation between ischemic indices.

Results

Macroscopically, torsioned ovaries had a cherry-red color. Microscopic examination of ovaries in both groups showed: interstitial edema, vascular congestion, hemorrhage and acute infiltration by PMNs.

Table I. The distribution of histological grades of the ovaries in 2 groups of cats.

	Group		Total	p-value
	Melatonin	Saline		
Grade 1	count (%)	3 (30%)	3(15%)	0.018
Grade 2	count (%)	3(30%)	4(20%)	0.018
Grade 3	count (%)	2(20%)	6(30%)	0.015
Grade 4	count (%)	2(20%)	7(35%)	0.015

(There was no grade 0 or normal)

The Manwhitney test demonstrated edema and vascular congestion in saline group were more severe than Melatonin group (p-value=0.009), also hemorrhage and leukocyte infiltration were more obvious in saline group (p-value=0.018). The histological changes, graded as described in the methods, are summarized in Table I.

The histological grades of the ovaries in melatonin. Group were lower than those of the saline group (p-value=0.015). Further more, there was a correlation between edema and vascular congestion (r =1, p-value =0.001), hemorrhage and PMN infiltration (r=1, p-value=0.001) and the other ischemia indices, for example vascular

congestion and hemorrhage ($r = 0.857$, $p\text{-value} < 0.001$).

Discussion

Ovarian injury resulting from torsion and detorsion resembles the phenomenon of Ischemia – Reperfusion injuries in other organs (1-3). It has been demonstrated that oxygen free radical generation is a critical mechanism causing injury in post ischemic cells and tissues, therefore oxygen, despite its vital properties, can be the most toxic elements known to human (6,7,18,19). Detorsion of the ovary, a conservative management that save it for future fertility, is one of the most important factors in future injury (1,3) Lipid peroxidation by active oxygen radicals can alter both membrane structure and function thus reperfusion injury may increase vascular permeability. Neutrophil infiltration might be regarded as another source of free radicals in the ischemic tissue, because they stimulate inflammatory mediators such as Tumor Necrosis Factor (TNF) and Interleukin-1(IL_1) which are involved in the pathogenesis of I/R injury. Edema and increased permeability occurred in vivo after ischemia reperfusion, due to disruption of endothelial cell junction integrity (20, 21). In the present study, Melatonin significantly prevented hemorrhage and greatly reduced the number of PMN and degree of vascular congestion and edema. These effects of Melatonin may occur not only because of its anti oxidant and ROS scavenger properties, but also its stimulatory effect on endogenous anti oxidant enzyme such as: catalase and SOD (super oxide dismutase) which bind to cell membrane receptors and decrease Ca and cAMP concentrations. Thus it is superior to other scavengers (22-26).

The results of the histopathological parameters in our study indicate that administration of Melatonin has beneficial effects in the prevention of reperfusion injury of ovary. Hara et al (1996) demonstrated that melatonin given in advance of severe exercise prevented the reduction in muscle GSH (an antioxidant enzyme in normal tissues) (27).

Another study reported that melatonin prevents the paraquat induced reduction in GSH in both lung and liver (28). Although melatonin scavenging actions have been demonstrated in a number of tissues (29-33), only Turkoz et al demonstrated

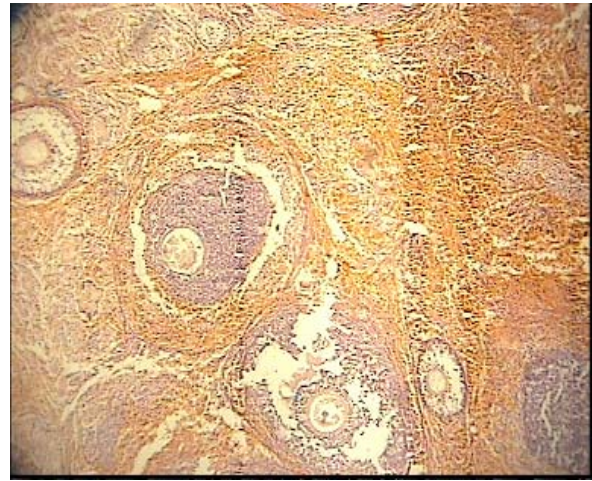


Figure 1: Intra paranchymal hemorrhage.

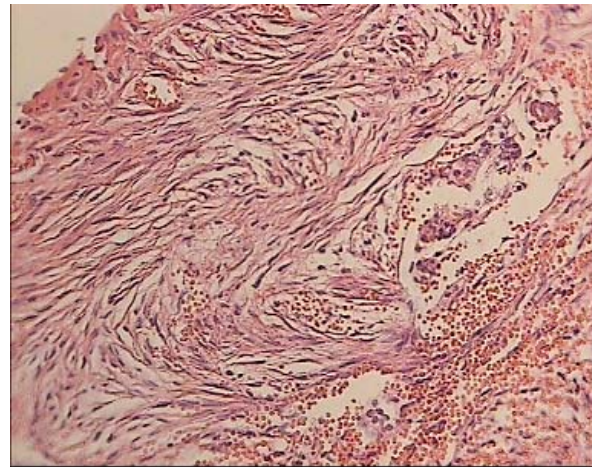


Figure 2: Severe edema.

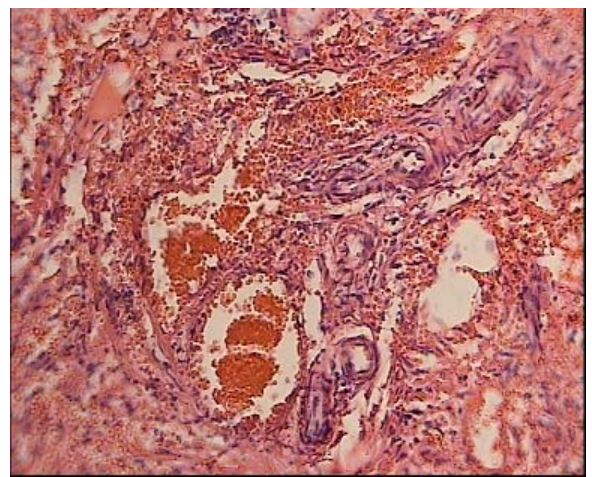


Figure 3: Congestion of blood vessels Leukocyte infiltration hasn't been shown because of minimal size of WBCs. Semiquantitative analysis was done according to reference (16).

the effects of melatonin on reducing ischemic indices such as xanthine oxidase (p-value <0.001), MDA (Malondialdehyde) (p-value <0.001), acute PMN infiltration, edema and Vascular dilatation in ovaries. In this study, Melatonin administration reduced the morphological changes by induced I/R; in particular, PMN infiltration, edema and vascular dilatation were much lower but had not been totally prevented by i.p Melatonin administration (15). In addition melatonin has an ameliorating effect on oxidative stress-induced renal tubular damage in diabetic nephropathy via its antioxidant properties (34). High dose of melatonin (50mg/kg), physiologically, biochemically and morphologically can be useful to normalize contractility injured by oxidative stress in intestinal ischemia/reperfusion (35).

Conclusion

We demonstrated that Melatonin reduced tissue damage induced by I/R in cat ovaries. This means that administration of Melatonin could be helpful in protection of ovaries from torsion – detorsion induced damage in humans.

References

- Chen M, Chen CD, Yang YS. Torsion of the previously normal uterine adnexa. Evaluation of the correlation between the pathological changes and the clinical characteristics. *Acta obstet Gynecol scand* 2001; 85:58-61.
- Haskins T, Shull B. Adnexal torsion: a mind – twisting diagnosis. *South Med J* 1986; 79: 576- 577.
- Meyer JS, Harman CM, Harty MP, Markowitz RI, Hubba AM, Bellah RD. Ovarian torsion: Clinical and imaging presentation in children. *J Pediatr Surg* 1995; 30:1433 – 1436.
- Taskin O, Birincioglu M, Aydin A, Buhur A, Burak F, Yilmaz I, et al. The effects of twisted ischemic adnexa managed by detorsion on Ovarian viability and histology: an ischemia–reperfusion rodent model. *Hum Reprod* 1998; 13: 2823-2827.
- Kaakaji Y, Nghiem HV, Nodell C, Winter TC. Sonography of obstetric and Gynecologic emergencies: part II, gynecologic emergencies. *AM J Roentgend* 2000; 174:651-656.
- Bird JE, Milhoan K, Wilson CB, Young SG, Mundy CA. Ischemic acute renal failure and antioxidant therapy in the rat: the relation between glomerular and tubular dysfunction. *J Din Invest* 1988; 81:1630–1638.
- Baker GL, Corry RJ, Autor AP. Oxygen free radical induced damage in kidneys subjected to warm ischemia and reperfusion: protection effect of superoxide dismutase. *Ann Surg* 1985; 202:628–641.
- Gilham B, Papa Chri Stodoulou Dk, Thomas Jh. *Will's Biochemical Basis of Medicine 3rd Ed.* Butterworth – Heinemann, London 1997: 343-354.
- Breen AP, Murphy JA. Reactions of oxyl radicals with DNA. *Free Radic Biol Med* 1995 ; 18: 1033-1077.
- Ames BN. Endogenous dna damage as related to cancer and aging. *Mutat Res* 1989 ; 214: 41-46
- Tan Dx, Chen Ld, Poeggeller B. Melatonin: a potent endogenous hydroxyl radical scavenger. *Endocr J* 1993; 1:57-60.
- Allegra M, Reiter RJ, Tan DX. The chemistry of melatonin's interaction with reactive species, *J Pineal Res* 2003; 34:1.
- Reiter RJ. Pineal Melatonin: Cell biology of its synthesis and its physiological interactions. *Endocr Rev* 1991; 12: 151-156.
- Marshall KA, Reiter RJ, Poeggeler B, Aruoma OI, Halliwell B. Evaluation of the antioxidant activity of melatonin in vitro. *Free Radic Biol Med* 1996; 21:307-315.
- Turkoz Y, Celik O, Hascalik S, Cigremis Y, Hascalik M, Mizrak B, et al. Melatonin reduces torsion – detorsion injury in rat ovary: Biochemical And Histopathologic Evaluation. *J .Pineal Res* 2004; 37: 137–141.
- Celik O, Turkoz Y, Hascalik S, Hascalik M, Cigremis Y, Mizrak B, et al. The protective effect of caffeic acid phenethyl ester on ischemia-reperfusion injury in rat ovary: *European Journal of Obstetrics & Gynecology and Reproductive Biology* 2004; 117: 183-188.
- Hascalik S, Celik O, Turkoz Y, Hascalik M, Cigremis Y, Mizrak B, et al. Resveratrol, a red wine constituent polyphenol, protects from ischemia-reperfusion damage of the ovaries. *Gynecol Obstet Invest* 2004; 57: 218-223.
- Melchiorri D, Reiter RJ, Sewerynek E, Hara M, Chen I, Nistico G. Paraquat toxicity and oxidative damage reduction by melatonin. *Biochem Biochem Pharmacol* 1996; 51: 1095-1099.
- MC Cord JM. Oxygen – derived free radicals in post ischemic tissue injury. *N Engl J Med* 1985; 312:159 – 163.
- Koltuksuz U, Ozen S, Vz E, Aydin M, Karaman A, Gultek A, et al. Caffeic acid phenethyl ester prevents intestinal reperfusion injury in rats. *J Pediatr Surg* 1999; 34:1458–1462.
- Suzuki S, Toledo – Pereyra LH, Rodriguez F, Lopez F. Role of kupffer cells in neutrophil activation and infiltration following total hepatic ischemia and reperfusion. *Circ Shock* 1994; 42:204-209.
- Reiter RJ, Tan DX, Manchester LC, Qi W. Biochemical reactivity of melatonin with reactive oxygen and nitrogen species. *Cell Biochem Biophys* 2001; 34:237-256.
- Tan Dx, Reiter RJ, Manchester LC. Chemical and physical properties and potential mechanisms: melatonin as a broad spectrum anti oxidant and free radical scavenger. *Curr Top Med Chem* 2002; 2:181-197.
- Reiter RJ, Guerrero JM, Garcia JJ, Acuna-Castroviejo D. Reactive oxygen intermediates, molecular damage, and aging relation to melatonin. *Ann NY Acad Sci* 1998; 854:410-424.
- Okatani Y. Melatonin increases activities of glutathione peroxidase and super oxide dismutase in fetal rat brain. *J Pineal Res* 2000; 28:89-96.
- Rodriguez C, Mayo JC, Sains RM, Antolin I, Herrera F, Martin V, et al. Regulation of anti oxidant enzymes: a significant role for melatonin. *J Pineal Res* 2004; 36: 1-9
- Hara M, Abe M, Suzuki T, Rieter RJ. Tissue changes in glutathione metabolism and lipid peroxidation induced by swimming are partially prevented by melatonin. *Pharmacol Toxicol* 1996; 78:308-312.
- Durmus O, Aricioglu A, Guven T, Oguz M, Yel M, Turkozkan N. The effects of allopurinol on the liver ultrastructure, reduced glutathione and lipid peroxide levels during liver ischemia in guinea pigs. *Gen Pharmacol* 1994; 25:781-786.

29. Bertuglia S, Marchiafava PI, Colantuoni A. Melatonin prevents ischemia reperfusion injury in hamster cheek. *Pouch Micro Circulation Cardiovasc Res* 1996; 31:947-952.
30. Sewerynek E, Reiter RJ, Melchiorri D, Ortiz GG, Lewinski A. Oxidative damage in the liver induced by ischemia-reperfusion: Protective by melatonin. *Hepato - Gastroenterology* 1996; 43:898-905.
31. Celik H, Ayar A, Tug N, Simsek M, Ozercan I, Cikim G, et al . Effects of melatonin on noncardiogenic pulmonary edema secondary to adnexial ischemia- reperfusion in guinea pig. *Neuroendocrinol Lett* 2002; 23:115-118.
32. Torri K, Uneyama H, Nishino H, Kondoh T. Melatonin suppresses cerebral edema caused by middle cerebral artery occlusion/reperfusion in rats assessed by magnetic resonance imaging. *J Pineal Res* 2004; 36: 18-24.
33. Lahiri OK, Ghosh C. Interactions between melatonin, reactive oxygen species, and nitric oxide. *Ann Ny Acad Sci* 1999; 893: 325-330.
34. Oktem F, Ozguner F, Yilmaz Hr, Uz E. Melatonin reduces urinary excretion of n-acetyl-beta-d-glucosaminidase, albumin and renal oxidative markers in diabetic rats. *Clin Exp Pharmacol Physiol* 2006; 33:95-101.
35. Ozacmak VH, Sayan H, Arslan SO, Altaner S, Aktas RG. Protective effect of melatonin on contractile activity and oxidative injury induced by ischemia and reperfusion of rat ileum. *Life Sci* 2005; 76:1575-1588.

