

·Complementary Medicine·

Effects of Roselle and Ginger on cisplatin-induced reproductive toxicity in rats

Amr Amin, AlaaEldin A. Hamza

Department of Biology, United Arab Emirates University, Al-Ain 17551, United Arab Emirates

Abstract

Aim: To evaluate the protective effects of *Hibiscus sabdariffa* (Roselle) and *Zingiber officinale* (Ginger) against cisplatin-induced reproductive toxicity in rats and to study the mechanisms underlying these effects. **Methods:** Ethanol extracts of *H. sabdariffa* or *Z. officinale* [1 g/(kg·day)] were given p.o. to male albino rats for 26 days, which began 21 days before a single cisplatin i.p. injection (10 mg/kg body weight). **Results:** Extracts of *H. sabdariffa* and *Z. officinale* reduced the extent of cisplatin-induced sperm abnormality and enhanced sperm motility. Both extracts restored the control level of malondialdehyde (MDA) (lipid peroxidation marker) in the cisplatin-treated testis. The cisplatin injection induced decline in the levels of superoxide dismutase (SOD), reduced glutathione (GSH) and catalase (CAT) were significantly reversed to control levels in groups where cisplatin was preceded by the administration of either *H. sabdariffa* or *Z. officinale*. **Conclusion:** Both *H. sabdariffa* and *Z. officinale* treatment increased the activities of testicular antioxidant enzymes and restored sperm motility of cisplatin-treated rats. The protective effects of tested plants are, therefore, suggested to be mediated by their potent antioxidant activities. (*Asian J Androl* 2006 Sep; 8: 607–612)

Keywords: cisplatin; testicular toxicity; *Hibiscus sabdariffa*; *Zingiber officinale*; herb; sperm motility; reproductive toxicity

1 Introduction

Because of the relative spermiotoxicity of cisplatin (cis-diamminedichloroplatinum [II]), almost all patients under chemotherapy show temporary or permanent azoospermia. The damage to both spermatogenesis and testicular endocrine function can be temporary or permanent based on the applied dose of cisplatin [1]. Within days of cisplatin injection, animals undergo severe tes-

ticular damage, which is characterized by spermatogenic damage, germ cell apoptosis, Leydig cell dysfunction and testicular steroidogenic disorder [2, 3].

Oxidative stress mediates cisplatin-induced nephrotoxicity [4]. The administration of antioxidants such as vitamin C reverses different cisplatin-associated side effects [4]. Many natural products of plant origin protect against drug-induced toxicity [4, 5]. However, to date, virtually no medicinal plant has been described to relieve the cisplatin-induced reproductive side effects accompanied by chemotherapy applied to cancer patients.

Roselle (*Hibiscus sabdariffa* L., family: Malvaceae), an annual shrub, is commonly used to make jellies, jams and beverages. In folk medicine, *H. sabdariffa* has been commonly used for its anti-hypertension properties [6].

Correspondence to: Dr Amr. Amin, Department of Biology, United Arab Emirates University, Al-Ain 17555, United Arab Emirates.
Tel: +971-3-7134-389, Fax: +971-3-7671-291
E-mail: a.amin@uaeu.ac.ae
Accepted 2006-01-09 Received 2006-02-27

The anthocyanin pigments that confer its color make it a valuable food product. Many biological activities of anthocyanin, such as antioxidative [7], hypocholesterolemic and hepatoprotective activities [8], have been investigated.

Ginger rhizome (*Zingiber officinale* R., family: Zingiberaceae), is used worldwide as a spice. Both antioxidative [9] and androgenic activity [10] of *Z. officinale* were reported in animal models. All major active ingredients of *Z. officinale*, such as Zingerone, Gingerdiol, Zingibrene, gingerols and shogaols, have antioxidant activity [11].

This investigation was set to evaluate the protective effects of *H. sabdariffa* and *Z. officinale* against cisplatin-induced testicular toxicity in male rats and to study the mechanisms underlying these effects.

2 Materials and methods

2.1 Chemicals, plants and extraction procedure

Cisplatin was purchased from Bristol-Myers Squibb Company (New Jersey, USA). Thiobarbituric acid, reduced glutathione, 5,5'-dithiobis (2-nitrobenzoic acid), Folin's reagent, epinephrine, superoxide dismutase, H₂O₂ and bovine albumin were obtained from Sigma Chemical (St. Louis, MO, USA). All other chemicals were obtained from local commercial suppliers. Dried flowers of *H. sabdariffa* and roots of *Z. officinale* were purchased from a local herbal store. Plant specimens were authenticated at the herbarium of the United Arab Emirates University. Plant specimens were then grounded into powder, which was subjected to microwave-assisted extraction [12].

2.2 Animals

Adult male Wistar strain albino rats (150–200 g) were obtained from the Animal House, United Arab Emirates University. They were maintained on standard pellet diet and tap water *ad libitum* and were kept in polycarbonate cages with wood chip bedding under a 12 h light/dark cycle and room temperature of 22–24°C. Rats were acclimatized to the environment for 2 weeks prior to experimental use. This study was approved by the Animal Ethics Committee, United Arab Emirates University.

2.3 Treatment

Animals were divided into four groups of five rats each. Extracts of *H. sabdariffa* or *Z. officinale* was given p.o. (1 g/kg body weight) each day for 26 consecutive days using an oral tube. Control and cisplatin

groups were gavaged distilled water instead. After 21 days of extracts or distilled water administration, cisplatin (dissolved in a vehicle of normal saline) was injected i.p. to *Hibiscus*, *Zingiber* or cisplatin group at a single dose of 10 mg/kg body weight. Animals in the corresponding control group were administered with vehicle alone. Five days after cisplatin injection, rats were killed using an anesthetic diethyl ether. Blood, testes and epididymid of each animal were collected. Testes and epididymid were weighed and the relative organ weight was calculated (relative organ weight = organ weight/body weight × 100). Epididymal sperm count, motility and abnormality were assessed immediately thereafter. The animals were weighed daily throughout the study.

2.4 Epididymal sperm motility, count and abnormality

Epididymal sperm were collected by cutting the one epididymis into small pieces in 5 mL of physiological saline at 32°C. A sperm viability test was done using the method described by World Health Organization (WHO) [13]. Epididymal sperm count and motility were evaluated and the methods used have been detailed elsewhere [14]. Epididymal weights also vary because of individual variation of weights and ages among tested rats. Therefore, sperm numbers were calculated relative to epididymal weights (sperm per gram) [15].

2.5 Biochemistry and histology

Testes were separated and homogenized separately in ice-cold KCl (150 mmol/L). Supernatants were collected and assays of lipid peroxidation, superoxide dismutase (SOD), catalase (CAT) and reduced glutathione (GSH) were done. Protein was estimated by the Lowry's method as modified by Peterson [16]. The methods have been standardized in our laboratory and have been detailed elsewhere [4].

For the histological examinations, pieces of testis were fixed in 10% neutral phosphate-buffered formalin and hydrated tissue sections, 5 µm in thickness, were stained with Hematoxylin and Eosin. The sections were examined under a Leica DMRB/E light microscope.

2.6 Statistical analysis

Data were expressed as mean ± SE. Statistical significance between the various groups was determined using unpaired *t*-test and analysis of variance [17].

3 Results

3.1 Effect on organ weight of male rats

The weights of testes and epididymid, expressed as relative to body weight, in rats after cisplatin administration were found to be significantly decreased, compared with the control group (Table 1). No significant changes in the weights of testes and epididymid were found in rats treated with *H. sabdariffa* or *Z. officinale* before and after cisplatin treatment. The administration of cisplatin alone or along with tested herbs did not alter the body weight of the animals (data not shown).

3.2 Effect on epididymal sperm indices

After cisplatin was administered, the epididymal sperm count and motility decreased significantly ($P < 0.01$),

whereas sperm abnormality was increased ($P < 0.01$). Administration of either *H. sabdariffa* or *Z. officinale* attenuated the cisplatin-induced decrease of sperm count and motility and protected against sperm abnormality changes (Table 1).

3.3 Biochemical parameters

Significant decline ($P < 0.01$) in testicular content of reduced GSH (Figure 1A) and of the activity of CAT and SOD (Figure 2A, B) was shown in the cisplatin-treated group 5 days post-treatment. A significant increase ($P < 0.01$) of MDA was recorded after cisplatin treatment (Figure 1B). These markers of oxidative stress did not differ significantly from control levels when *H.*

Table 1. Effects of *Hibiscus sabdariffa* and *Zingiber officinale* extracts on testicular and epididymal relative weights and on epididymal sperm count, motility and abnormality in cisplatin-treated rats. Data were expressed as mean \pm SE, $n = 5$; ^b $P < 0.05$, ^c $P < 0.01$, compared with the control group.

Parameters	Control	Cisplatin	<i>Hibiscus sabdariffa</i>	<i>Zingiber officinale</i>
Relative weights of testes (g/100 g)	1.17 \pm 0.03	1.00 \pm 0.05 ^b	1.08 \pm 0.05	1.10 \pm 0.08
Relative weights of epididymid (g/100 g)	0.45 \pm 0.02	0.33 \pm 0.04 ^b	0.46 \pm 0.03	0.40 \pm 0.03
Epididymal sperm count (million/g of epididymis)	295.36 \pm 22.92	78.72 \pm 18.06 ^c	301.70 \pm 33.46	205.70 \pm 17.17 ^b
Sperm motility (%)	79.00 \pm 3.32	22.00 \pm 4.46 ^c	71.00 \pm 2.63	79.00 \pm 3.32
Sperm abnormality (%)	2.20 \pm 0.37	29.00 \pm 5.68 ^c	2.00 \pm 0.45	2.20 \pm 0.37

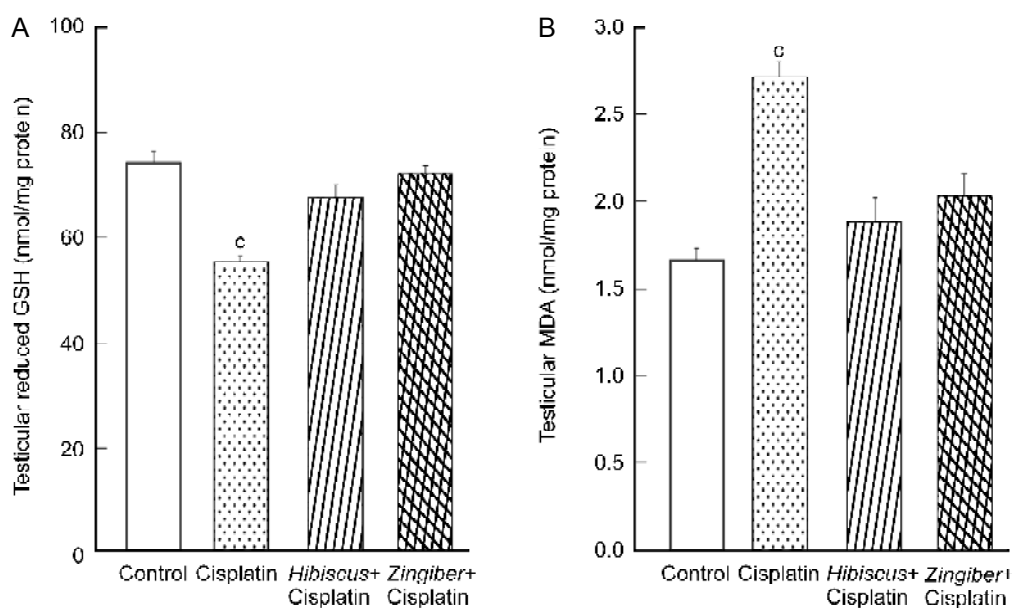


Figure 1. Effects of *Hibiscus sabdariffa* and *Zingiber officinale* on testicular (A) reduced glutathione (GSH) contents and (B) malondialdehyde (MDA) levels in cisplatin-treated rats. Data were expressed as mean \pm SE, $n = 5$; ^c $P < 0.01$, compared with the control group.

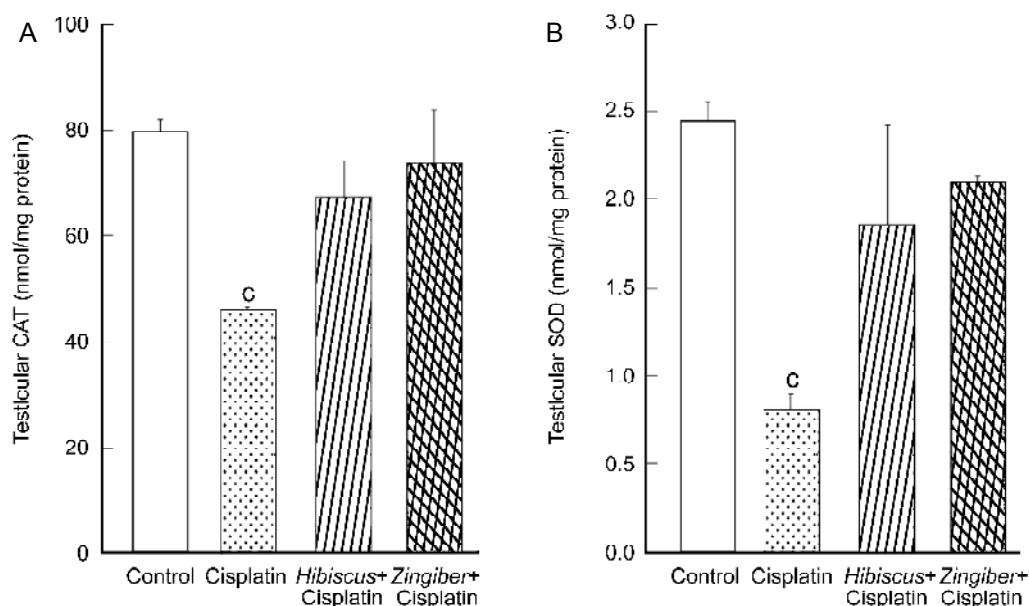


Figure 2. Effects of *Hibiscus sabdariffa* and *Zingiber officinale* on testicular (A) catalase (CAT) and (B) superoxide dismutase (SOD) activities (nmol/mg protein) in cisplatin-treated rats. Data were expressed as mean \pm SE, $n = 5$; $^*P < 0.01$, compared with the control group.

sabdariffa or *Z. officinale* was administered before cisplatin treatment.

3.4 Histologic evaluation

Cisplatin treatment caused severe degeneration in some seminiferous tubules (Figures 3 and 4). The tubules were also shrunken and greatly depleted of germ cells. The number of Leydig cells was clearly reduced in the cisplatin-treated rats. Debris from the degeneration of cellular components was seen in the lumen. Congestion of blood vessels was also observed between tubules. Animals pretreated with *H. sabdariffa* or *Z. officinale* showed normal testicular morphology and spermatogenesis with slight degeneration of spermatids and spermatozoa in some tubules (Figure 4C, D).

4 Discussion

The cisplatin-induced testicular damage in animals is commonly associated with spermatogenic damage, germ cell apoptosis, Leydig cell dysfunction and testicular steroidogenic disorder [2, 3]. Administration of testosterone has protective effects on Leydig cells [18] and spermatogenesis [19] in rats.

The present investigation shows a significant weight reduction of testes and epididymid as well as a decrease

in the quality of epididymal sperm (sperm count, motility and morphology) after treatment with cisplatin. Cisplatin-induced testicular damage was also confirmed by histopathological lesions. In the present study, cisplatin-treated animals showed an elevation in testicular MDA level vs. the control animals. Testicular activities of reduced GSH, CAT and SOD were lower in the cisplatin-treated animals relative to those in the control animals. The concurrent decrease of antioxidants in cisplatin-induced tissues might potentially explain the upregulation of MDA production [20]. A correlation between MDA and cisplatin-induced complications has also been reported [4]. It has been demonstrated that cisplatin toxicity in the kidney is mediated by the depletion of antioxidants and the elevation of lipid peroxidation [21]. It has been suggested that cisplatin generates free radicals by interacting with DNA [22]. Cisplatin has enhances the production of reactive oxygen species in kidneys [23], which interferes with antioxidant defense system and results in tissue injury. Therefore, overproduction of free radicals and, hence, oxidative stress might account, at least in part, for testicular injury associated with cisplatin treatment [24].

Recently, much attention has been focused on the protective effects of antioxidants and naturally-occurring substances against cisplatin-induced nephrotoxicity [5, 10]. However, little is known about herbal plants as

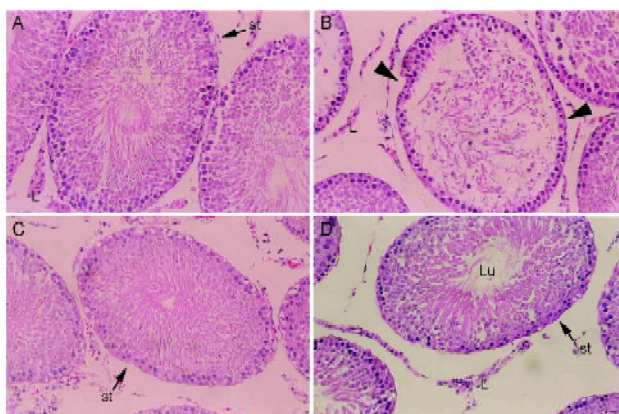


Figure 3. Photomicrograph of the seminiferous tubules (st) of control (A) shows the normal arrangement of germ cells at different stages of spermatogenesis. Testis of cisplatin-treated rats (B) shows extensive degeneration in some tubules (arrowheads) and depletion of germ cells and Leydig cells (L). Rats in groups pretreated with *Hibiscus sabdariffa* (C) or *Zingiber officinale* (D) before cisplatin treatment exhibit relatively normal tubules with the usual arrangement of cells. However, *Z. officinale* pretreated group shows moderate degeneration in some tubules and decrease in the number of sperm in the lumen (LU) (Hematoxylin and Eosin, $\times 200$).

protective agents against cisplatin-induced testicular toxicity. Administration of *H. sabdariffa* extract before cisplatin treatment clearly restored the testicular damage and quality of sperm caused by cisplatin, in addition to retaining the control values of oxidative stress markers. Accumulating evidence suggests that the protective effects of *H. sabdariffa* against oxidative damage could be attributed to its antioxidative properties [8, 24]. The antioxidant activity of *H. sabdariffa* could be attributed to its phenolic contents; namely, anthocyanins [7, 8]. The prevention of cisplatin-induced oxidative stress damage in rats with *H. sabdariffa* supports the hypothesis that the mechanism of testicular damage could be attributed, at least in part, to the overproduction of free radicals.

Administration of *Z. officinale* before cisplatin treatment also attenuates testicular damage induced by cisplatin treatment, as shown by the normal sperm count and morphology and by the histopathological recovery compared to the cisplatin-treated group. The protective effect of *Z. officinale* is reflected by the normalization of antioxidant activities and the concurrent decrease of malondialdehyde in testes. The major active phenolic ingredients isolated from *Z. officinale* (Zingerone, Gingerdiol, Zingibrene, gingerols and shogaols) have an-

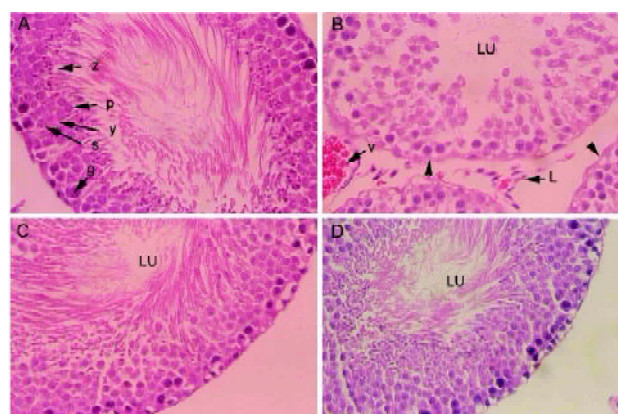


Figure 4. Photomicrograph of the seminiferous tubules of control (A) shows the normal arrangement of germ cells at different stages of spermatogenesis. The tubule contains spermatogonia (g), Sertoli cell (s), spermatocytes (y), spermatids (p) and spermatozoa (z) in the lumen (LU). Testis of cisplatin-treated rats (B) shows extensive degeneration in some tubules (arrowheads) and depletion of germ cells. There are few Leydig cells (L) and congestion of blood vessel (v) between the tubules. Rats in groups pretreated with *Hibiscus sabdariffa* (C) or *Zingiber officinale* (D) before cisplatin treatment shows normal testicular morphology and spermatogenesis with slight degenerations in spermatids and spermatozoa (Hematoxylin and Eosin, $\times 400$).

tioxidant activity [9, 11]. The protective effect of *Z. officinale* against cisplatin toxicity could also be mediated by its androgenic activities. Kamtchoung *et al.* [10] reported that *Z. officinale* extracts have a potent androgenic activity in male rats. This activity is reflected by the increase of both testis weight and serum testosterone levels.

In conclusion, the present study shows that *H. sabdariffa* and *Z. officinale* have significant protective effects against cisplatin-induced testicular damage and oxidative stress in rats. Further investigations are underway to elucidate the molecular mechanism of protection mediated by Roselle and ginger.

Acknowledgment

We are grateful to Mr Sayel Daud (Twam Hospital) and to Ms Enas Idris for their valuable assistance. We also thank Professor Michael Buratovich (Spring Arbor University, Michigan, USA) for proofreading the manuscript. Authors are also indebted to Mr Hamdi Kandil for his professional help revising all the graphs.

References

- 1 Colpi GM, Contalbi GF, Nerva F, Sagone P, Piediferro G. Testicular function following chemo-radiotherapy. *Eur J Obstet Gynecol Reprod Biol* 2004; 113(Suppl): S2–6.
- 2 Malarvizhi D, Mathur PP. Effects of cisplatin on testicular functions in rats. *Indian J Exp Biol* 1996; 34: 995–8.
- 3 Cherry SM, Hunt PA, Hassold TJ. Cisplatin disrupts mammalian spermatogenesis, but does not affect recombination or chromosome segregation. *Mutat Res* 2004; 564: 115–28.
- 4 Antunes LM, Darin JD, Bianchi Nde L. Effects of the antioxidants curcumin or selenium on cisplatin-induced nephrotoxicity and lipid peroxidation in rats. *Pharmacol Res* 2001; 43: 145–50.
- 5 Shirwaikar A, Issac D, Malini S. Effect of *Aerva lanata* on cisplatin and gentamicin models of acute renal failure. *J Ethnopharmacol* 2004; 90: 81–6.
- 6 Herrera-Arellano A, Flores-Romero S, Chavez-Soto MA, Tortoriello J. Effectiveness and tolerability of a standardized extract from *Hibiscus sabdariffa* in patients with mild to moderate hypertension: a controlled and randomized clinical trial. *Phytomedicine* 2004; 11: 375–82.
- 7 Tsai PJ, Huang HP. Effect of polymerization on the antioxidant capacity of anthocyanins in *Rosella*. *Food Res Inter* 2004; 37: 313–8.
- 8 Wang CJ, Wang JM, Lin WL, Chu CY, Chou FP, Tseng TH. Protective effect of *Hibiscus* anthocyanins against tert-butyl hydroperoxide-induced hepatic toxicity in rats. *Food Chem Toxicol* 2000; 38: 411–6.
- 9 Sekiwa Y, Kubota K, Kobayashi A. Isolation of novel glucosides related to gingerdiol from ginger and their antioxidative activities. *J Agric Food Chem* 2000; 48: 373–7.
- 10 Kamtchouing P, Mbongue Fandio GY, Dimo T, Jatsa HB. Evaluation of androgenic activity of *Zingiber officinale* and *pentadiplandra brazzeana* in male rats. *Asian J Androl* 2002; 4: 299–301.
- 11 Zancan KC, Marques MO, Petenate AJ, Meireles MA. Extraction of ginger (*Zingiber officinale* Roscoe) oleoresin with CO₂ and co-solvents: a study of the antioxidant action of the extracts. *J Supercrit Flu* 2002; 24: 57–76.
- 12 Alfaro MJ, Belanger JM, Padilla FC, Jocelyn Pare JR. Influence of solvent, matrix dielectric properties, and applied power on the liquid-phase microwave-assisted processes (MAP) extraction of ginger (*Zingiber officinale*). *Food Reser Inter* 2003; 36: 499–504.
- 13 World Health Organization. WHO Laboratory Manual for the Examination of Human Semen and Sperm-cervical Mucus Interaction. 4th ed. Cambridge: Cambridge University Press; 1999.
- 14 Latchoumycandane C, Chitra KC, Mathur PP. The effect of methoxychlor on the epididymal antioxidant system of adult rats. *Reprod Toxicol* 2002; 16: 161–72.
- 15 Peirce EJ, Breed WG. A comparative study of sperm production in two species of Australian arid zone rodents (*Pseudomys australis*, *Notomys alexis*) with marked differences in testis size. *Reproduction* 2001; 121: 239–47.
- 16 Peterson GL. A simplification of the protein assay method of Lowry et al. which is more generally applicable. *Anal Biochem* 1977; 83: 346–56.
- 17 Snedecor GW, Cochran WG. *Statistical Method*, 7th ed. Iowa: Iowa State University Press; 1980.
- 18 Malarvizhi D, Mathur PP. Protective effects of testosterone propionate on cisplatin-induced Leydig cell dysfunction in rats. *Biomed Lett (UK)* 1996; 53: 173–6.
- 19 Malarvizhi D, Manimaran RR, Aruldas MM, Mathur PP. Quantitative maintenance of spermatogenesis in cisplatin-treated rats by exogenous administration of testosterone propionate. *J Endocrinol Reprod* 1998; 1: 67–72.
- 20 Kaur P, Bansal MP. Influence of selenium induced oxidative stress on spermatogenesis and lactate dehydrogenase-X in mice testis. *Asian J Androl* 2004; 6: 227–32.
- 21 Devi Priya S, Shyamala Devi CS. Protective effect of Quercetin in cisplatin-induced cell injury in the rat kidney. *Ind J Pharmacol* 1999; 31: 422–6.
- 22 Masuda H, Tanaka T, Takahama U. Cisplatin generates superoxide anion by interaction with DNA in a cell-free system. *Biochem Biophys Res Commun* 1994; 203: 1175–80.
- 23 Matsushima H, Yonemura K, Ohishi K, Hishida A. The role of oxygen free radicals in cisplatin-induced acute renal failure in rats. *J Lab Clin Med* 1998; 131: 518–26.
- 24 D'cruz SC, Mathur PP. Effect of piperine on the epididymis of adult male rats. *Asian J Androl* 2005; 7: 363–8.

Edited by Prof. J. Anton Grootegoed