

EFFERENT CONNECTIONS OF THE BASOLATERAL AMYGDALOID PART TO THE ARCHI-, PALEO-, AND NEOCORTEX IN DOGS

Anna KOSMAL

Department of Neurophysiology, Nencki Institute of Experimental Biology
Warsaw, Poland

Abstract. Small electrolytic lesions were placed in the basal and lateral amygdaloid nuclei of the dog and the distribution of degenerating fibers was studied with Nauta and Fink-Heimer modifications of the impregnation methods. Degenerating axons were followed into the hippocampal region and entorhinal cortex as well as insular and temporal cortices. The present results suggest that: (i) The hippocampal region receives projections from the basal parvocellular and basal magnocellular nuclei; (ii) the entorhinal cortex from the lateral and basal parvocellular nuclei; (iii) the insular cortex, cortex of the anterior ectosylvian and sylvian gyri, and to a smaller degree the claustrum, from the lateral and basal magnocellular nuclei; (iv) the temporal cortex of the posterior suprasylvian gyrus from all nuclei of the basolateral part of the amygdala. It is concluded that the basolateral part of the amygdala in the dog has a complex and highly developed connections with the archi-, paleo- and neocortex.

INTRODUCTION

The efferent connections of the amygdala through the stria terminalis and ventral pathway have been described in various mammalian species (1, 2, 4, 6, 9, 16, 18, 19, 23-25). In contrast there are few reports on the projection from the amygdaloid complex to cortical structures. In the monkey, Nauta (18, 19) demonstrated a system of amygdalofugal fibers reaching temporal, insular and orbital regions. Valverde (24, 25) described fibers leading from the amygdala to the ventral part of the posterior sylvian gyrus in the cat. Using the autoradiographic method Krettek and

Price (15) recently demonstrated an amygdaloid projection to the peri- and entorhinal cortex and to the ventral subiculum. Miodoński (17), describing the myeloarchitecture of the dog's amygdala, referred to amygdalo-hippocampal fibers. However, there has not been any experimental evidence showing a direct amygdaloid projection to cortical regions in the dog.

The classification of the amygdaloid nuclei in the dog's brain, as in the other species, is based on cytoarchitectonics (7, 8, 10, 12) and the distribution of AChE activity (Kosmal and Nitecka, in preparation). Two main parts of the amygdaloid complex can be distinguished. The phylogenetically older, corticomедial part is situated mainly in the antero-medial region of the amygdala and contains the cortical, medial and central nuclei as well as the nucleus of the lateral olfactory tract. The phylogenetically younger, basolateral part occupies the central and posterolateral regions of the amygdala. The basolateral part contains several nuclei: basal parvocellular, basal magnocellular and lateral. It is separated from the claustrum by the external capsule. The basolateral nuclei contain a much greater variety of neurons including numerous large cells.

Using silver impregnation methods for degenerating axons, the present study deals with cortical projections from different basolateral nuclei of the amygdala in the dog. The control lesions were placed in the corticomедial part of the amygdala and in the periamygdaloid cortex. It has been previously shown that the corticomедial part of the amygdala has no cortical projection (13). Other tel- and diencephalic areas affected by the selective amygdalar lesions will be described in a separate paper (Kosmal, in preparation).

MATERIALS AND METHODS

Twenty nine adult, mongrel dogs, weighing about 10–12 kg, were used. Unilateral lesions were placed in the basolateral part of the amygdaloid complex in 19 subjects. The lesions were performed in a stereotaxic apparatus by passing a cathodal current (1 mA for 45–60 s) through a tungsten electrode (0.3 mm in diameter) inserted vertically. The following control operations were performed: in three dogs, an electrode was inserted at the same coordinates, but the current was not applied; in two dogs the piriform cortex underlying the amygdala was ablated, and in five animals lesions were placed in the corticomедial part of the amygdala.

Six to ten days after surgery, the animals were anesthetized with sodium pentobarbital and intracardially perfused with saline followed by 10%

neutral formalin. The brains were removed and stored in 10% formalin for 1 to 3 mo. Blocks of the brains were then placed in a 30% solution of sucrose with formalin until they sank. Serial frozen sections 30 μ m thick were cut in the frontal plane.

Every 10th section was stained according to the Klüver-Barrera (11) method for verification of the site and extent of the lesions. The remaining sections were impregnated according to suppressive silver methods of Nauta (20-22) and Fink-Heimer (3) for degenerating axons.

RESULTS

Localization of the lesions

Two types of lesions in the basolateral part of the amygdala were produced: (i) large lesions involving more than one nucleus (in 9 dogs); (ii) small lesions restricted to all or part of one nucleus (in 10 dogs). The first type of lesion allowed for the tracing of degenerating axons, their distribution, their direction of leaving the amygdaloid complex and their terminal regions. The second type of lesions, on the other hand, made possible a more precise localization of the area of origin as well as determining the contribution of different degrees of damage to bypassing fibers caused by large lesions.

The first type of lesion was present in dogs BL1-BL5, where both the basal magnocellular and basal parvocellular nuclei were damaged to a different degree. In dogs BL16-BL19 parts of the lateral and basal magnocellular nuclei (BL16, BL17) as well as the lateral, magnocellular and parvocellular basal nuclei (BL18, BL19) were damaged.

The second type of lesion included cases in which the basal parvocellular, basal magnocellular and lateral nuclei were separately damaged. Lesions in the basal parvocellular nucleus were represented in three dogs (BL5-BL7). In dogs BL5 and BL6 the medial part of the nucleus was destroyed, while the lateral part was involved in dog BL7 (Fig. 1, BL6,

LIST OF ABBREVIATIONS

Bm	basal magnocellular nucleus
Bp	basal parvocellular nucleus
C	claustrum
Ce	external capsule
Ci	intermediate part of the central nucleus
Cl	lateral part of the central nucleus
Cm	medial part of the central nucleus
Co	cortical nucleus
Cp	piriform (periamygdaloid) cortex

CE	entorhinal cortex
FA	amygdaloid fissure
gEa	gyrus ectosylvius anterior
gS	gyrus sylvius
gSp	gyrus suprasylvius posterior
H	hippocampus
iC	insular cortex
L	lateral nucleus
M	medial nucleus
N	nucleus of the lateral olfactory tract
Srh	rhinal sulcus

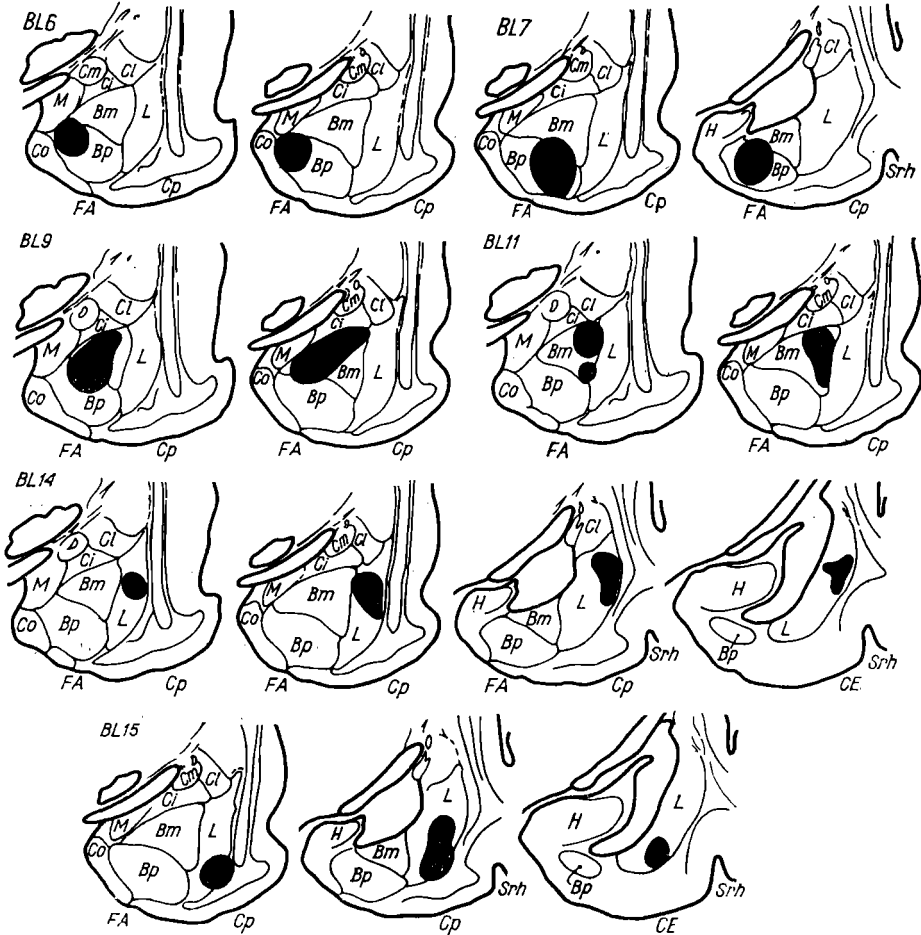


Fig. 1. Localization of the lesions (black) in the basolateral part of the amygdala in different dogs is presented on serial schematic diagrams in the frontal planes (amount of diagrams depend on extent of the lesions). BL6, in medial part of the basal parvocellular (Bp) nucleus; BL7, in lateral part of the Bp; BL9, in mediodorsal part of the basal magnocellular (Bm) nucleus; BL11, in lateral part of the Bm nucleus; BL14, in central part of the lateral (L) nucleus; BL15, in ventral part of the lateral nucleus.

BL7). In four dogs (BL9–BL12) the basal magnocellular nucleus was damaged. In dog BL9, a large lesion involved the mediodorsal part of this nucleus with a slight encroachment on the dorsal region of the basal parvocellular nucleus (Fig. 1, BL9). The lesion of dog BL10 involved only the medial part of this nucleus. In dogs BL11 and BL12 small lesions were confined to the lateral parts of the basal magnocellular nucleus (Fig. 1, BL11). Lesions in the lateral nucleus were placed in three dogs: BL13, BL14 and BL15. In dog BL14 the central part of the lateral nucleus was damaged in the whole rostrocaudal extent of the amygdala (Fig. 1, BL14). The lesion reached, but did not damage the external capsule. A narrow strip of large cells in the most lateral part of the lateral nucleus was extensively damaged. In dogs BL13 and BL15 the ventral parts of the lateral nucleus were destroyed (Fig. 1, BL15). There was slight additional damage to the external capsule at the ventral limit of the lesion.

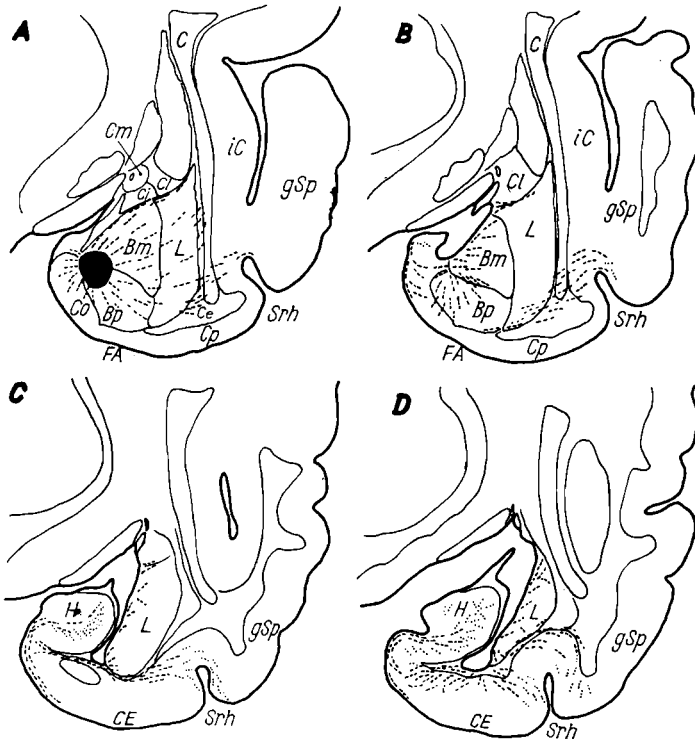


Fig. 2. Distribution of degenerating axons (dashes) following the lesion of the basal parvocellular nucleus (Bp), at different levels of the frontal sections from anterior (A) to posterior (D). Dog BL7. Preterminal degeneration (dots) was observed in hippocampal region (H), ventral tip of the gyrus suprasylvius posterior—perirhinal cortex (gSp) and in deep layers of the entorhinal cortex (CE).

Distribution of degenerating axons in the hippocampal region

Most of the degenerating fibers to the hippocampal region were traced following lesions involving the basal parvocellular nucleus, but some of them were also seen following damage to the basal magnocellular nucleus (Fig. 1, BL6, 7; BL9, 11). When the lesion involved the basal parvocellular nucleus, thin degenerating axons were seen to approach the hippocampal region via two routes: (i) some axons exited immediately above the most caudal region of the basal parvocellular nucleus, traversed the presubiculum and subiculum and terminated diffusely in the CA1 and CA2 fields of the ventral part of the hippocampus (Fig. 2), (ii) the second path ran perpendicularly through the basal parvocellular nucleus to the superficial layer of the periamygdaloid cortex where they turned medially and, as tangential fibers, continued course into the hippocampus (Fig. 5A). Both groups of axons disappeared in

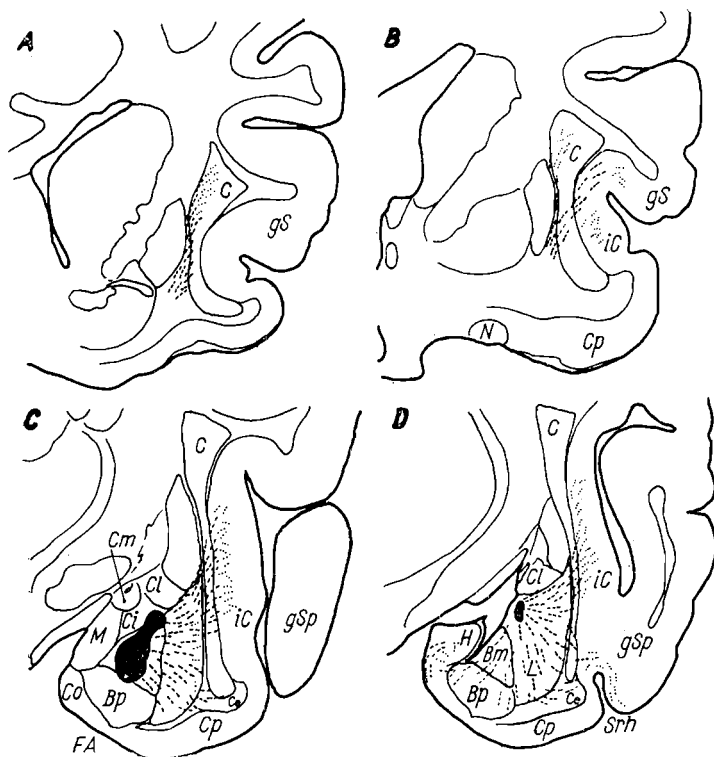


Fig. 3. Distribution of degenerating axons (dashes) following the lesion of the basal magnocellular nucleus (Bm), at the different level of the frontal sections, from anterior (A) to posterior (D). Dog BL9. Preterminal degeneration (dots) was in deep layers of the insular cortex (ic), dorsal part of the claustrum (C), and perirhinal cortex (gSp).

the same area of the hippocampus (Fig. 5B, Fig. 2 and 3). The second path contained more axons from the lateral part of the basal parvocellular nucleus than from the medial part. The projection from the basal magnocellular nucleus to the hippocampus was very weak and only a few axons from this nucleus took a course above the basal parvocellular nucleus. These axons partly disappeared in the subiculum bordering the basal parvocellular nucleus (BL9), and partly reached the hippocampus and terminated diffusely among cells of the CA1 and CA2 hippocampal fields which, as mentioned, are also the recipients of axons from the basal parvocellular nucleus (Fig. 3).

Distribution of degenerating axons in the entorhinal cortex

Degenerating axons were seen in the entorhinal cortex only after lesions confined to the lateral and basal parvocellular nuclei. Two components could be distinguished in this projection. The first component contained a moderate number of degenerating axons observed after lesions in the lateral nucleus (Fig. 1, BL14, BL15). These axons were traced from the ventral limits of the lesions, entering the ventral part of the external capsule where they ran as a group of parallel fibers (Fig. 4 C-F), and finally disappearing in the deep layers of the lateral part of the entorhinal cortex (ee CE in Fig. 4 EF). The second component of this projection was only observed following lesions in the ventral part of the lateral nucleus (Fig. 1, BL15). Only few degenerating axons running tangentially to the surface in the outer cell layers were observed in the medial region of the entorhinal cortex (Fig. 5E). These axons gradually disappeared in the medial region of the entorhinal cortex but they did not reach the parasubiculum.

Distribution of degenerating axons in the neocortex and claustrum

This system of the amygdaloid projection was composed of scattered thin axons observed after lesions in the lateral nucleus and to a smaller extent after lesions of the basal magnocellular and basal parvocellular nuclei. The axons were distributed to various regions of the cortex, forming a diffuse and widespread projection system. Although the degenerating axons did not form distinct separate bundles they could be roughly divided into three groups.

The first group of axons was traced to the neocortex of the posterior ectosylvian gyrus and sylvian gyrus, as well as to the claustrum. At the beginning of their course these axons were part of the ventral amygdalofugal pathway, directed rostrally. At the level of the substantia innominata they formed the most lateral portion of this pathway. From the sublenticular region of the substantia innominata the degenerating axons

of this group turned in the dorsolateral direction. They pierced the external capsule and penetrated the central and dorsal region of the claustrum. The degenerating axons in the dorsal claustrum were extremely thin and

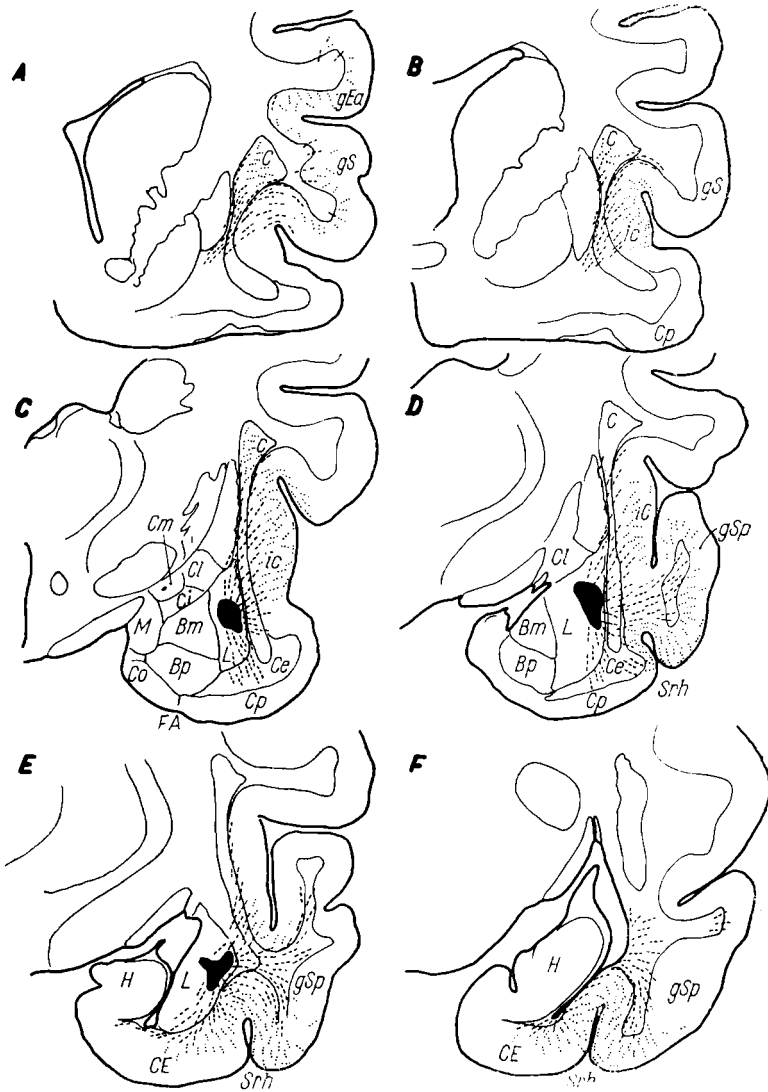


Fig. 4. Distribution of degenerating axons (dashes) following the lesion of the lateral nucleus (L), at the different level of the frontal sections from anterior (A) to posterior (F). Preterminal degeneration (dots) was in the dorsal part of the claustrum (c), neocortex of gyrus ectosylvius anterior (gEa) and gyrus sylvius (gS), insular cortex (ic), gyrus suprasylvius posterior—temporal cortex (gSp), lateral part of the entorhinal cortex (CE). Dog BL14.

seemed to terminate there although the typical pattern of preterminal ramification was not seen. These axons were observed after lesions in the basal magnocellular and lateral nuclei (Fig. 3*AB* and 4*A-C*). The contribution from the lateral nucleus was heavier than that from the basal nucleus. No degeneration was seen in the claustrum after lesions in the basal parvocellular nucleus. The axons coursing towards the central part of the claustrum pierced it and reached the cortex of the posterior ectosylvian gyrus and sylvian gyrus (Fig. 3*B* and 4*A*). They too were also most numerous after lesions of the lateral nucleus.

The second group of degenerating axons was traced to the insular cortex. These axons were observed after lesions of the lateral and basal magnocellular nuclei. From the lateral limits of the lesions degenerating axons took a direct lateral exit, traversed the external capsule, the central part of the claustrum and approached the insular cortex (iC Fig. 3*B-D* and 4*B-D*). There was a significant difference in the contribution of axons from the basal magnocellular and lateral nuclei. Following lesions of the basal magnocellular nucleus the degenerating axons were not in the basal nuclei. Following lesions in the basal nuclei, only lesions which included the most lateral, narrow, strip of the larger cells in the lateral nucleus caused axon degeneration leading to a large region of insular cortex, forming rich preterminal arborization in all its layers (Fig. 5*D*).

The third group of degenerating axons was traced to the temporal cortex of the posterior suprasylvian gyrus. These axons were seen after lesions in each of the basolateral nuclei although the contribution the lateral nucleus was more substantial than that from the basal nuclei. Following lesions in the basal nuclei, only a small group of scattered axons traveled laterally through the lateral nucleus and pierced the ventral part of the external capsule, composing a characteristic pattern of this projection. Preterminal degeneration was confined mainly to the perirhinal cortex, occupying the ventral tip of the posterior suprasylvian gyrus just above the dorsal wall of the rhinal sulcus (Fig. 5*C* and *Srh*, Fig. 2*A-D* and Fig. 3*D*). After lesions in the lateral nucleus, a great number of degenerating axons were found coursing laterally to the posterior suprasylvian gyrus. In case BL14, where the most lateral cell layer of the lateral nucleus was damaged, this group of axons showed massive preterminal degeneration in the anteroventral part of the posterior suprasylvian gyrus (Fig. 4*D-F*). The amount of degenerating axons seen in the posterior suprasylvian gyrus was greater and extended further posteriorly, after lesions of the lateral nucleus than after lesions of the basal nuclei. Moreover, it seemed that

the severity of degeneration in the suprasylvian gyrus, like that in the insular cortex, was related to the extent of damage of the narrow strip of large cells forming the lateral border of the lateral nucleus.

DISCUSSION

The present results demonstrated the existence of corticopetal fibers from the basolateral part of the amygdala in the dog. On the basis of the distribution pattern and a general direction of the corticopetal fibers from the particular amygdaloid nuclei three main fiber components can be distinguished: (i) dorsolateral, from the basal magnocellular and the lateral nuclei to the neocortex and claustrum; (ii) intermediate, from all basolateral nuclei to the perirhinal cortex; (iii) ventromedial, from the basal parvocellular nucleus and a ventral portion of the lateral nucleus to the entorhinal cortex, and from the parvocellular and magnocellular basal nuclei to the hippocampal region (see Fig. 6).

The above statements are more detailed than the previous reports on the amygdalocortical projections in the monkey (19) and cat (24, 25) which failed to distinguish a relative contribution from the particular nuclei to the projection systems just mentioned. However, these publications were based on large lesions which could by no means be compared with the minute destructions of individual nuclei or subunits of nuclei which were employed here. Such selective lesions gave substantiation to the conclusion that the great majority of the fibers to neocortical areas took their origin in the lateral nucleus and terminated in all layers of the insular and temporal cortices. In contrast, the neocortical projections from the basal magnocellular nucleus could only be traced to the deep layers of the insular cortex. The basal parvocellular nucleus has no discernible neocortical projection. The present material does not provide evidence for the amygdaloid projection to the orbitofrontal cortex, which was previously described by Nauta in the monkey (19). It is possible, however, that such projection in the dogs brain takes an indirect route via the dorsomedial nucleus, which receives fibers from the basolateral part of the amygdala (13).

Projections from the amygdala to the perirhinal and entorhinal cortices as well as to the hippocampal region have recently been demonstrated by Krettek and Price (15) in rats and cats. The present results in dogs indicate a projection to the perirhinal cortex which originates in all basolateral nuclei even if the majority of fibers arise in the basal parvocellular nucleus. A contribution of the lateral nucleus to this projection is difficult to estimate mainly because of its spatial overlap with the projection to the temporal cortex of the posterior suprasylvian gyrus.

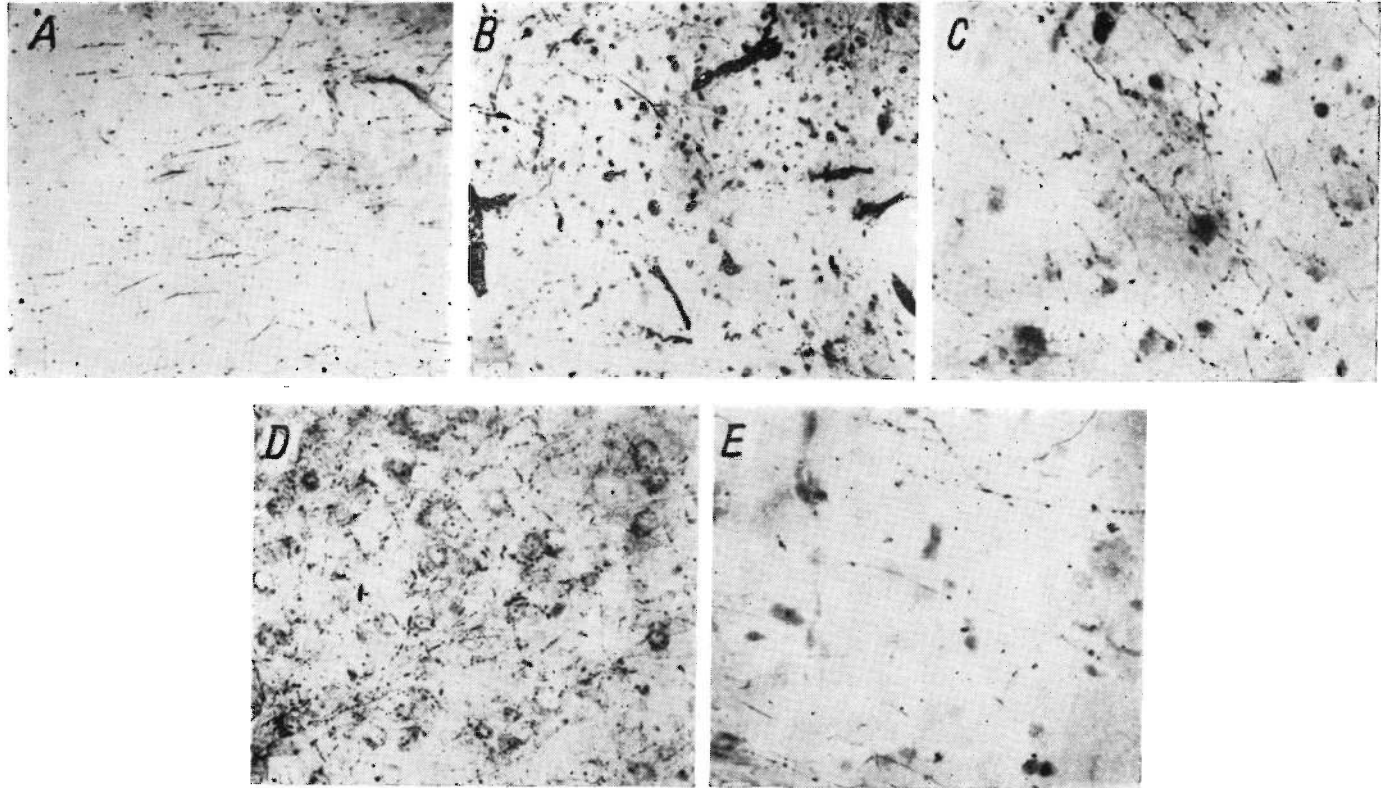


Fig. 5. Photomicrographs of degenerating axons following lesions of the amygdaloid nuclei. Impregnations according to modifications of Nauta method. *A*: Degenerating axons traversing the subiculum, dog BL6. *B*: Preterminal degeneration in the ventral part of hippocampal region, dog BL6. *C*: Degenerating axons in the perirhinal cortex, dog BL14. *D*: Preterminal degeneration in the insular cortex, dog BL14. *E*: Degenerating axons in the medial part of the entorhinal cortex, dog BL15.

The entorhinal projection from the amygdala appears primarily to arise in the lateral nucleus but also to some extent in the basal parvocellular nucleus. The present analysis of the distribution pattern suggests that a part of this projection may join fibers bypassing the entorhinal cortex in their course to the subiculum and the hippocampus (see below), thus constituting the indirect amygdalar innervation of the hippocampal region as suggested by Gloor (5) and Valverde (25).

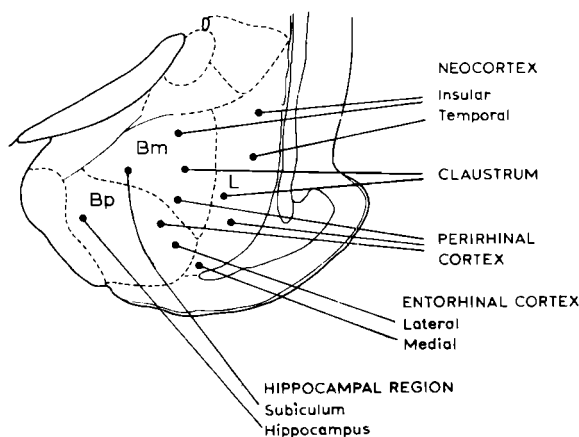


Fig. 6. A summary of corticopetal projections from the basolateral nuclei of the amygdala in the dog.

The potentially most important result of the present study is the demonstration of a direct amygdalo-hippocampal projection. A majority of the fibers in this projection was observed after selective lesions placed in the basal parvocellular nucleus. Furthermore, there is a small contribution to this projection from the basal magnocellular nucleus, but the latter fibers terminate to the greatest extent in the subiculum. It should be noted, however, that even small lesions in the amygdala may affect fibers from more rostral areas traversing the basal parvocellular or magnocellular nuclei on their way to the hippocampal region. Since such projection remain to be described, the present results warrant the suggestion of the amygdalar origin of the hippocampal innervation. On the other hand, it must be emphasized that an exact site of the termination of the amygdalar projection in the areas and fields of the hippocampal region could not be exactly determined in the present material with the methods which were employed and the survival times which were chosen. On the basis of the myeloarchitectonic observations Miodoński (17) has previously described amygdalo-hippocampal fibers in the dog's brain. The present results confirm his findings and provide the evidence that these fibers arise in the basal nuclei of the amygdala. Recently, Van Hoe-

sen et al. (26-28) have described cortico-cortical projections in the monkey. They have shown that the temporal and perirhinal cortices project to the entorhinal cortex, which in turn projects to the hippocampus via the perforant pathway. It was the opinion of these authors that such a serial projection system between neighboring cortical areas might provide an anatomical basis for a complex and sequential input to the hippocampus. The existence of the corticopetal fibers from the basolateral nuclei of the amygdala to the temporal, perirhinal, entorhinal and hippocampal cortices suggest that amygdala is closely related to the above mentioned cortical projection systems to the hippocampus.

I thank Professor O. Narkiewicz for helpful criticism during the course of this study, Dr. B. Srebro, Professor W. Harkmark and Dr. R. G. E. Oberg for valuable comments on the manuscript. I thank also T. Cymbalak for technical assistance. This investigation was supported by Project 09.4.1 of the Polish Academy of Sciences.

REFERENCES

1. BAN, T. and OMUKAI, F. 1959. Experimental studies on the fiber connections of amygdaloid nuclei in the rabbit. *J. Comp. Neurol.* 113: 245-268.
2. BÜRGI, S. and BUCHER, V. M. 1963. Stria terminalis and related structures. *Progr. Brain Res.* 3: 163-167.
3. FINK, R. P. and HEIMER, L. 1967. Two methods for selective silver impregnation of degenerating axons and their synaptic endings in the central nervous system. *Brain Res.* 4: 369-374.
4. FOX, C. A. 1943. The stria terminalis, longitudinal association bundle and precommisural fornix fibers in the cat. *J. Comp. Neurol.* 79: 277-295.
5. GLOOR, P. 1955. Electrophysiological studies on the connections of the amygdaloid nucleus in the cat. The neuronal organization of the amygdaloid projection system. *Electroenceph. Clin. Neurophysiol.* 7: 223-242.
6. HALL, E. 1963. Efferent connections of the basal and lateral nuclei of the amygdala in the cat. *Amer. J. Anat.* 113: 139-145.
7. HUMPHREY, T. 1936. The telencephalon of the bat. I. The noncortical nuclear masses and certain pertinent fiber connections. *J. Comp. Neurol.* 65: 603-711.
8. HUMPHREY, T. 1972. The development of the human amygdaloid complex. *In* E. Eleftheriou (ed.), *The neurobiology of the amygdala*. Plenum Press, New York, p. 21-80.
9. ISHIKAWA, L., KAWAMURA, S. and TANAKA, O. 1969. An experimental study on the efferent connections of the amygdaloid complex in the cat. *Acta Med. Okayama* 23: 519-539.
10. JOHNSTON, J. B. 1923. Further contributions to the study of evolution of the forebrain. *J. Comp. Neurol.* 35: 337-481.
11. KLÜVER, H. and BARRERA, E. 1953. A method for combined staining of cells and fibers in the nervous system. *J. Neuropath. Exp. Neurol.* 12: 400.

12. KOIKEGAMI, H. 1963. Amygdala and other related limbic structures. Experimental studies on the anatomy and function. *Acta Med. Biol.* 10: 161-277.
13. KOSMAL, A. 1973. Efferent projection of the amygdaloid complex in the dog (in Polish). Ph.D. Thesis. Nencki Inst. Exp. Biol. Warsaw.
14. KRETTEK, J. E. and PRICE, J. L. 1974. Projections from the amygdala to the perirhinal and entorhinal cortices and subiculum. *Brain Res.* 71: 150-154.
15. LEONARD, C. N. and SCOTT, J. W. 1971. Origin and distribution of amygdalofugal pathways in the rat. *J. Comp. Neurol.* 141: 313-329.
16. MIODOŃSKI, R. 1965. Myeloarchitectonics of the amygdaloid complex of the dog. *Acta Biol. Exp.* 25: 263-287.
17. NAUTA, W. J. H. 1961. Fibre degeneration following lesions of the amygdaloid complex in the monkey. *J. Anat. (Lond.)* 95: 515-530.
18. NAUTA, W. J. H. 1962. Neural associations of the amygdaloid complex in the monkey. *Brain* 85: 505-520.
19. NAUTA, W. J. H. 1967. Silver impregnation of degenerating axons. In W. F. Windle (ed.), *New research techniques of neuroanatomy*. Charles C Thomas, Springfield, p. 17-26.
20. NAUTA, W. J. H. and GYGAX, P. A. 1951. Silver impregnation of degenerating axon terminals in the central nervous system: 1) technic, 2) chemical notes. *Stain Technol.* 26: 5-11.
21. NAUTA, W. J. H. and GYGAX, P. A. 1954. Silver impregnation of degenerating axons in the central nervous system: a modified technic. *Stain Technol.* 29: 91-93.
22. De OLMOS, J. S. 1972. The amygdaloid projection field in the rat as studied with cupric-silver method. In B. E. Elefteriou (ed.), *The neurobiology of the amygdala*. Plenum Press, New York, p. 145-205.
23. VALVERDE, F. 1963. Amygdaloid projection field within the rhinencephalon and related structures. *Progr. Brain Res.* 3: 20-30.
24. VALVERDE, F. 1965. *Studies on the piriform lobe*. Harvard Univ. Press, Cambridge. 131 p.
25. VAN HOESEN, G. W., PANDYA, D. N. and BUTTERS, N. 1972. Cortical afferents to the entorhinal cortex of the rhesus monkey. *Science* 175: 1471-1473.
26. VAN HOESEN, G. W. and PANDYA, D. N. 1975. Some connections of the entorhinal (area 28) and perirhinal (area 35) cortices of the rhesus monkey. I. Temporal lobe afferents. *Brain Res.* 95: 1-24.
27. VAN HOESEN, G. W. and PANDYA, D. N. 1975. Some connections of the entorhinal (area 28) and perirhinal (area 35) cortices of the rhesus monkey. III. Efferent connections. *Brain Res.* 95: 39-59.

Accepted 15 December 1975

Anna KOSMAL, Department of Neurophysiology, Nencki Institute of Experimental Biology, Pasteura 3, 02-093 Warsaw, Poland.