

Electrochemotherapy with Cisplatin: Clinical Experience in Malignant Melanoma Patients¹

Gregor Serša,² Borut Štabuc, Maja Čemažar, Damijan Miklavčič, and Zvonimir Rudolf

Institute of Oncology [G. S., B. S., M. Č., Z. R.], and Faculty of Electrical Engineering, University of Ljubljana [D. M.], SI-1000 Ljubljana, Slovenia

ABSTRACT

Electrochemotherapy consists of chemotherapy followed by local application of electric pulses to the tumor to increase drug delivery into the cells. The aim of this Phase II clinical study was to evaluate the antitumor effectiveness of electrochemotherapy using intratumoral cisplatin administration on cutaneous tumor nodules in malignant melanoma patients. In 10 patients, 133 tumor nodules of different sizes were treated: (a) 82 tumor nodules were treated with electrochemotherapy; (b) 27 tumor nodules were treated with cisplatin; (c) 2 tumor nodules were treated with electric pulses; and (d) 22 tumor nodules were untreated. Four weeks after therapy, 78% objective responses were obtained in the electrochemotherapy group, and 38% objective responses were obtained in the cisplatin group. Exposure of tumor nodules to electric pulses without cisplatin treatment had no effect on tumor growth. Electrochemotherapy was well tolerated by all patients, and a good cosmetic effect was obtained, with only minimal scarring and a slight depigmentation of the skin. At 124 weeks of follow-up, a 77% control rate of the tumor nodules treated by electrochemotherapy was observed, compared to 19% for those that were treated with cisplatin only ($P < 0.0001$). Our results clearly demonstrate that electrochemotherapy with cisplatin is a highly effective approach for treatment of cutaneous malignant melanoma nodules. The advantages of this therapy include its simplicity, the short duration of treatment sessions, low cisplatin doses, and insignificant side effects, as well as the fact that it can be done on an outpatient basis.

INTRODUCTION

High doses of drugs, which often cause systemic toxicity, are usually needed for effective chemotherapy. In addition, the lack of selectivity of chemotherapeutic agents for tumor cells

has raised the call for the development of new drug delivery systems (1). A local increase in plasma membrane permeability, *i.e.*, exposure of the tumor nodule to electric pulses (electroporation), results in increased uptake of chemotherapeutics into the tumor cells. Therefore, lower doses of these drugs are needed to achieve a good antitumor effect, thus making this therapy less toxic (2, 3).

Enhanced delivery of chemotherapeutic drugs to tumor cells by electroporation is termed electrochemotherapy (2). Electrochemotherapy has been shown to be successful for drugs such as bleomycin and cisplatin, which normally exhibit impeded transport through the plasma membrane. The increased antitumor effectiveness of bleomycin and cisplatin combined with electric pulses has already been demonstrated in experimental and clinical studies (4–11). In clinical studies, electrochemotherapy with bleomycin given *i.v.* or intratumorally was performed on cutaneous and *s.c.* tumor nodules of head and neck carcinomas, malignant melanomas, basal cell carcinomas, adenocarcinomas, and Kaposi's sarcomas (10, 12–18). Objective responses were obtained for the majority of the electrochemotherapy-treated nodules, whereas nodules that were exposed only to electric pulses or treated only with bleomycin did not respond.

The first clinical study of electrochemotherapy with intratumoral application of cisplatin was performed on patients with malignant melanomas, squamous cell carcinomas, and basal cell carcinomas (11). In that study, only two patients with malignant melanomas were included. Electrochemotherapy with cisplatin was effective in the treatment of cutaneous tumor nodules, and its antitumor effectiveness was comparable to that of electrochemotherapy with bleomycin.

Cutaneous metastases of malignant melanomas arising after chemoimmunotherapy in patients without concomitant dissemination to other organs raise the problem of optimal treatment approach, especially in patients who have already undergone extensive surgical treatment. In the present Phase II clinical study, the antitumor effectiveness of electrochemotherapy with cisplatin was compared to that of intratumoral injection of cisplatin alone. Ten malignant melanoma patients who had been treated previously with surgery or chemoimmunotherapy and had a total of 133 cutaneous tumor nodules were included in this study.

PATIENTS AND METHODS

Patient Eligibility. From October 1995 to November 1997, 10 patients with histologically confirmed malignant melanomas were eligible to be included in this Phase II clinical trial (Table 1). All of them had recurrent or PD³ with measurable cutaneous nodules and had received prior treatment or refused

Received 10/29/98; revised 6/24/99; accepted 9/14/99.

The costs of publication of this article were defrayed in part by the payment of page charges. This article must therefore be hereby marked *advertisement* in accordance with 18 U.S.C. Section 1734 solely to indicate this fact.

¹ Supported by the Ministry of Science and Technology of the Republic of Slovenia.

² To whom requests for reprints should be addressed, at Institute of Oncology Ljubljana, Zaloška 2, SI-1000 Ljubljana, Slovenia. Phone/Fax: 386-61-133-74-10; E-mail: gserša@onko-i.si.

³ The abbreviations used are: PD, progressive disease; CR, complete response; PR, partial response; NC, no change.

Table 1 Patient characteristics

Patient no.	Age/sex	Previous treatment	Visceral metastases	No. of cutaneous tumors
1	49/F	Surgery, immunochemotherapy ^a	+ (liver)	17
2	51/M	Surgery, immunochemotherapy	+ (liver, lung)	3
3	59/M	Surgery, immunochemotherapy	–	28
4	38/F	Surgery, immunochemotherapy	+ (lung)	2
5	68/F	Surgery, immunochemotherapy	–	3
6	54/F	Surgery	–	2
7	63/F	Surgery, IFN ^b	–	30
8	71/F	Surgery, IFN	–	3
9	58/F	Surgery, IFN	–	1
10	62/F	Surgery, immunochemotherapy	+ (lung)	44

^a Day 1, vinblastine (4 mg/m², i.v.), comustine (60 mg/m², p.o.); day 2–5, cisplatin (20 mg/m², i.v.); day 3–7, recombinant IFN- α 2b (6.10⁶ U, s.c.).

^b Day 1, 3, and 5, recombinant IFN (3.10⁶ U, s.c.).

other standard treatment, *i.e.*, radiotherapy, surgery, or chemo-immunotherapy. Other eligibility criteria were as follows: (a) Eastern Cooperative Oncology Group performance status of 0–1; (b) normal renal function; (c) normal blood tests and biochemistry; and (d) life expectancy of more than 3 months. A treatment-free interval of at least 3 weeks was required after previously applied therapy, except for surgery. During the trial, all patients were excluded from conventional chemotherapy protocols as well as from any other kind of treatment. National ethics committee approval and written informed consent from each patient were obtained before beginning the study.

Study Design and Treatment Plan. The aim of this study was to evaluate the antitumor effectiveness of intratumoral administration of cisplatin followed by delivery of electric pulses to tumor nodules (electrochemotherapy group). This was compared with intratumoral administration of cisplatin only (cisplatin group), the delivery of electric pulses only (electric pulses group), and the growth of untreated tumor nodules (untreated controls). A total of 82 nodules were included in the electrochemotherapy group, 27 nodules were included in the cisplatin group, 2 nodules were included in the electric pulses group, and 22 nodules served as untreated controls.

Cisplatin (*cis*-diamminedichloroplatinum II; Platinol; Bristol-Myers Squibb, Vienna, Austria) was dissolved in 0.9% NaCl solution at a concentration of 2 mg/ml and administered intratumorally at doses ranging from 0.25–2 mg, depending on the size of the tumor nodule (approximately 1 mg/100 mm³). Tumor nodules larger than 200 mm³ were treated with 2 mg of cisplatin, regardless of the volume. The interval between cisplatin administration and the application of electric pulses was 1–2 min. Square wave electric pulses of 100 μ s, 910 V amplitude (amplitude to electrode distance ratio, 1300 V/cm), and frequency of 1 Hz were delivered through two parallel stainless steel electrodes with rounded tips and inner distance between them 7 mm (thickness, 1 mm; width, 7 mm; length, 14 mm) with an electropulsator Jouan GHT 1287 (Jouan, Saint Herblaine, France). Electrical parameters were controlled using an HM 205–3 oscilloscope (Hameg Instruments, Frankfurt am Main Germany). Each run of electric pulses was delivered in two trains of four pulses, with a 1-s interval, in two perpendicular directions. Good contact between the electrodes and the skin was assured by means of a conductive gel. Nodules larger than

7 mm in diameter were treated with several runs of electric pulses administered in adjacent positions to assure adequate coverage of the whole tumor area (2–25 runs in 47 nodules). Electrochemotherapy was performed on an outpatient basis; when repeated treatment sessions were needed, there was a 4-week interval between them.

Treatment Evaluation. After each treatment session, patients were kept in a recovery room for 2 h. Before they were released, hemodynamic and cardiological parameters were examined. At 4-week intervals, patients were examined on an outpatient basis by the team of the same experts that performed the therapy to evaluate treatment response and possible side effects. Tumor nodules were measured with a caliper and photographed. The volume of tumor nodules was calculated by the formula $V = a \times b \times c \times \pi/6$, where *a*, *b*, and *c* represent the diameters of the tumor nodule. Response to treatment was scored after 4 weeks, according to the WHO guidelines (19), as follows: (a) CR, absence of any trace of the tumor; (b) PR, a more than 50% reduction in tumor volume; (c) NC, a less than 50% reduction of tumor volume and no tumor enlargement more than 25%; and (d) PD, tumor volume enlarged more than 25%. The duration of CR was calculated as the interval between the date when the CR was first recorded and the date of tumor progression (19). Observation time was calculated as the interval between the date of the first treatment and the end of follow-up on August, 21 1998.

Statistical Analysis. Statistical calculations were performed using a personal computer and a Biomedical statistical software package (BMDP). The differences in the distribution of patients according to the objective responses were tested using contingency table analysis and Fisher's exact test. Local tumor control was estimated as a function of time by the Kaplan-Meier product limit method, and the difference between the curves was analyzed by means of the log-rank test. Data from patients who were alive or dead without recurrence were used as censored data. Statistical significance was tested at the 5% level.

RESULTS

Of the 10 patients included in this study, 6 patients had recurrent metastases in the skin that were refractory to chemo-immunotherapy, and 4 patients had visceral metastases. At the

Table 2 Summary of tumor response 4 weeks after treatment

Treatment	No. of nodules	PD	NC	PR	CR
		No. (%)	No. (%)	No. (%)	No. (%)
Control	22	14 (64)	8 (36)		
Electric pulses	2	1 (50)	1 (50)		
Cisplatin	27	9 (33)	8 (30)	5 (19)	5 (19)
Electrochemotherapy	82	6 (7)	12 (15)	8 (10)	56 (68)

end of follow-up, six patients were without evidence of local recurrence of the disease, whereas the remaining four patients with visceral metastases had died due to cerebral metastases (one patient) and/or visceral spread (three patients).

Treatment Response. In the electrochemotherapy-treated group, the median volume of the nodules was 61 mm³ (range, 2–39270 mm³). Four weeks after therapy, objective responses were observed in 64 of 82 (78%) nodules, CRs were observed in 56 of 82 (68%) nodules, and PRs were observed in 8 of 82 (10%) nodules. PD was observed in 6 of 82 (7%) nodules, and NC was observed in 12 of 82 (15%) nodules (Table 2). In 10 of these nodules, a CR was obtained later on, at 8 weeks after beginning therapy. In the cisplatin-treated group, the median volume of tumor nodules was 67 mm³ (range, 6–2094 mm³) and did not differ significantly ($P > 0.05$) from those in the electrochemotherapy group. Objective responses were obtained in 10 of 27 (38%) nodules, CR was obtained in 5 of 27 (19%) nodules, and PR was obtained in 5 of 27 (19%) nodules. Most of the nodules were resistant to therapy: PD was observed in 9 of 27 (33%) nodules, and NC was observed in 8 of 27 (30%) nodules.

Median follow-up of the patients was 35 weeks (range, 5–124 weeks). At 124 weeks, local tumor control rates were 77% for the electrochemotherapy group and 19% for the cisplatin group ($P < 0.0001$; Fig. 1). Median duration of the local tumor control of electrochemotherapy-treated nodules was 36 weeks (range, 4–124 weeks), and median duration of the local tumor control of cisplatin-treated nodules 4 weeks (range, 4–119 weeks).

Electric pulses as a single treatment were applied to two tumor nodules with volumes of 65 and 188 mm³. After therapy, one of the nodules continued to grow, and the response of the other one was determined to be partial. Untreated nodules served as controls; the median volume of these nodules was 23 mm³ (range, 0.5–524 mm³). Most of these nodules [14 of 22 nodules (64%)] continued to grow. However, in 8 of 22 (36%) nodules, NC was observed after 4 weeks of observation. All untreated controls were later included in the electrochemotherapy-treated group.

Treatment Tolerance. No significant deviations of hemodynamic or cardiologic parameters from normal values were noticed after the treatment procedures. The intratumoral route of cisplatin injection was tolerable, although it was associated with some pain, which dissipated after several minutes. No local or systemic toxicity resulted after cisplatin administration. Application of electric pulses induced instantaneous contractions of the muscles located beneath the site of the treatment that disappeared immediately afterward. No exulceration was

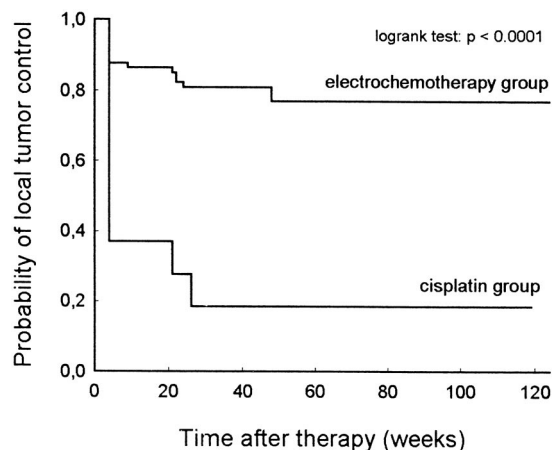


Fig. 1 Local tumor control curves for the electrochemotherapy group (82 nodules) and the cisplatin group (27 nodules). Local tumor control was estimated using the Kaplan-Meier product limit method, and the difference between the curves was analyzed by means of a log-rank test.

observed in nodules treated with cisplatin or electrochemotherapy. Erythema and a slight edema were observed in patients treated with electrochemotherapy at the site of the treated areas and remained for 2 weeks. Thereafter, a superficial scab was formed on these nodules, which fell off in approximately 4 weeks. A good cosmetic effect was obtained, with minimal scarring and a slight depigmentation of the skin.

DISCUSSION

Results of the present Phase II clinical study on cutaneous tumor nodules of malignant melanoma demonstrate that electrochemotherapy with cisplatin is an effective treatment with insignificant side effects. The objective response rate, its median duration, and local tumor control rate at the end of follow-up of electrochemotherapy-treated nodules were significantly higher compared to nodules treated with cisplatin alone.

Compared to electrochemotherapy with bleomycin, electrochemotherapy with cisplatin is equally effective. In a study on four different tumor types (*i.e.*, basal cell carcinoma, malignant melanoma, Kaposi's sarcoma, and squamous cell carcinoma), Heller *et al.* (18) demonstrated that electrochemotherapy with bleomycin results in 99.3% objective responses. When only malignant melanoma cases were considered, CRs were seen in 89.3% of treated nodules within 12 weeks (18), which is comparable to the results of this study with a CR of 68% observed at 4 weeks and a 77% control rate at 124 weeks of

follow-up. These results support our previous study on electrochemotherapy with cisplatin in which two of four patients had malignant melanoma (11). In all 14 of the tumor nodules treated using electrochemotherapy with cisplatin, a CR was recorded, with a median duration of local tumor control of 28 weeks.

In patients without visceral, cerebral, and/or bone metastases, especially in heavily pretreated patients, the problem of cutaneous tumor nodules is quite specific. Standard treatments for such patients are comprised of surgery, immunotherapy, chemotherapy, and radiotherapy. Cisplatin, especially in combination with other chemotherapeutics, is one of the most effective treatments for malignant melanoma. Our first electrochemotherapy treatment was performed on cutaneous tumor nodules in patients who were on ongoing, systemic, cisplatin-containing chemotherapy. In tumor nodules that were additionally treated with electric pulses, a better response rate was obtained. Based on our experience gained in this clinical study as well as in some of our preclinical studies demonstrating that intratumoral cisplatin injection is more effective than i.v. injection, we decided to perform the present Phase II clinical study using intratumoral cisplatin administration (7, 8, 11).

The data of the present study clearly show that percutaneous application of electric pulses to the tumor potentiates the effectiveness of cisplatin. Intratumoral cisplatin administration has the advantage over i.v. administration because it is an exclusively local treatment and has some antitumor effect on its own. Because only low cisplatin doses were needed to produce a pronounced antitumor effect, the treatment is safe, has insignificant side effects, and can be performed on an outpatient basis. Furthermore, after electrochemotherapy, tumor areas may exist that could not be adequately exposed to electric pulses; therefore, in those areas, reduction of tumor burden is expected to be due to cisplatin cytotoxicity. In addition, if, after the first electrochemotherapy session, the tumor nodule is not completely eradicated, the remaining tumor mass can be retreated in the following electrochemotherapy sessions.

In some tumors treated by electrochemotherapy, CR was not recorded after 4 weeks, but was recorded later on. This observation is in accordance with our preclinical studies, in which we demonstrated that tumors treated by electrochemotherapy with cisplatin regressed slowly compared to tumors treated by electrochemotherapy with bleomycin (2, 4, 7–9). The possible underlying mechanism for this observation is apoptosis, which is the predominant manner of cell death after cisplatin therapy. Therefore, for additional studies, an 8-week interval is recommended for the evaluation of patients.

Although resistance of tumor cells to cisplatin represents a specific problem, we did not observe the development of resistance in up to four sessions. This topic was addressed in our previous study, which demonstrated that electroporation of cisplatin-resistant cells *in vitro* potentiates the cell killing induced by cisplatin (20). Also, in our previous clinical study, we did not observe the development of resistance in squamous cell carcinomas: the patient was treated in six consecutive sessions; and a good antitumor effect was observed each time (11).

Recently, we have provided data that the application of electric pulses induces a reduction in tumor blood flow in addition to increasing the delivery of cisplatin into the tumor cells by electroporation (7, 9, 21, 22). This reduction of tumor

blood flow, which lasts for several hours, as demonstrated in experimental tumors, may have additional implications on the antitumor effectiveness of cisplatin. Therefore, entrapment of the drug in the tumors caused by a reduction of tumor blood flow prolongs the exposure of tumor cells to cisplatin and enhances its effectiveness (7, 9).

In conclusion, this Phase II clinical study demonstrates the high effectiveness of electrochemotherapy with cisplatin on malignant melanoma nodules. The advantages of this therapy are its simplicity, the short duration of treatment sessions, low cisplatin doses, insignificant side effects, and, due to all of the above, the fact that it can be performed on outpatient basis. Therefore, this must be considered the treatment of choice not only for patients in whom the cutaneous disease is in progression, but also in less advanced clinical cases. Optimization of electric field distribution in the tumors by numerical modeling and testing of new types and configuration of electrodes (23–25) will lead to advances in this therapy, which will, in turn, enable the treatment of tumors located deeper in the body.

REFERENCES

- Langer, R. New methods of drug delivery. *Science* (Washington DC), 249: 1527–1533, 1990.
- Mir, L. M., Orłowski, S., Belehradek, J., Jr., Teissie, J., Rols, M. P., Serša, G., Miklavčič, D., Gilbert, R., and Heller, R. Biomedical applications of electric pulses with special emphasis on antitumor electrochemotherapy. *Bioelectrochem. Bioenerg.*, 38: 203–207, 1995.
- Rols, M. P., and Teissie, J. Electroporomeabilization of mammalian cells. Quantitative analysis of the phenomenon. *Biophys. J.*, 58: 1089–1098, 1990.
- Serša, G., Čemažar, M., and Miklavčič, D. Antitumor effectiveness of electrochemotherapy with *cis*-diamminedichloroplatinum(II) in mice. *Cancer Res.*, 55: 3450–3455, 1995.
- Mir, L. M., Orłowski, S., Belehradek, J., Jr., and Paoletti, C. Electrochemotherapy potentiation of antitumor effect of bleomycin by local electric pulses. *Eur. J. Cancer*, 27: 68–72, 1991.
- Heller, R., Jaroszeski, M., Leo-Messina, J., Perrot, R., Van Voorhis, N., Reintgen, D., and Gilbert, R. Treatment of B16 mouse melanoma with the combination of electroporomeabilization and chemotherapy. *Bioelectrochem. Bioenerg.*, 36: 83–87, 1995.
- Čemažar, M., Milačič, R., Miklavčič, D., Dolžan, V., and Serša, G. Intratumoral cisplatin administration in electrochemotherapy: antitumor effectiveness, sequence dependence and platinum content. *Anti-Cancer Drugs*, 9: 525–530, 1998.
- Čemažar, M., Miklavčič, D., Vodovnik, L., Jarm, T., Rudolf, Z., Štabuc, B., Čufer, T., and Serša, G. Improved therapeutic effect of electrochemotherapy with cisplatin by intratumoral drug administration and changing of electrode orientation for electroporomeabilization on EAT tumors in mice. *Radiol. Oncol.*, 29: 121–127, 1995.
- Čemažar, M., Miklavčič, D., Ščančar, J., Dolžan, V., Golouh, R., and Serša, G. Increased platinum accumulation in SA-1 tumor cells after *in vivo* electrochemotherapy with cisplatin. *Br. J. Cancer*, 79: 1386–1391, 1999.
- Mir, L. M., Glass, L. F., Serša, G., Teissie, J., Dörmge, C., Miklavčič, D., Jaroszeski, M. J., Orłowski, S., Reintgen, D. S., Rudolf, Z., Belehradek, M., Gilbert, R., Rols, M. P., Belehradek, J., Jr., Bachaud, J. M., DeConti, R., Štabuc, B., Čemažar, M., Coninx, P., and Heller, R. Effective treatment of cutaneous and subcutaneous malignant tumors by electrochemotherapy. *Br. J. Cancer*, 77: 2336–2342, 1998.
- Serša, G., Štabuc, B., Čemažar, M., Jančar, B., Miklavčič, D., and Rudolf, Z. Electrochemotherapy with cisplatin: potentiation of local cisplatin antitumor effectiveness by application of electric pulses in cancer patients. *Eur. J. Cancer*, 34: 1213–1218, 1998.

12. Rudolf, Z., Štabuc, B., Čemažar, M., Miklavčič, D., Vodovnik, L., and Serša, G. Electrochemotherapy with bleomycin: the first clinical experience in malignant melanoma patients. *Radiol. Oncol.*, *29*: 229–235, 1995.
13. Domenge, C., Orlowski, S., Luboinski, B., De Baere, T., Belehradek, J., Jr., and Mir, L. M. Antitumor electrochemotherapy. New advances in the clinical protocol. *Cancer (Phila.)*, *77*: 956–963, 1996.
14. Heller, R., Jaroszeski, M., Glass, F., Messina, J. L., Rapaport, D. P., Fenske, N. A., Gilbert, R., Mir, L. M., and Reintgen, D. S. Phase I/II trial for the treatment of cutaneous and subcutaneous tumors using electrochemotherapy. *Cancer (Phila.)*, *77*: 964–971, 1996.
15. Reintgen, D. S., Jaroszeski, M. J., and Heller, R. Electrochemotherapy, a novel approach to cancer. *Skin Cancer Foundation*, *14*: 17–19, 83, 1996.
16. Glass, L. F., Jaroszeski, M., Gilbert, R., Reintgen, D. S., and Heller, R. Intralesional bleomycin-mediated electrochemotherapy in 20 patients with basal cell carcinoma. *J. Am. Acad. Dermatol.*, *37*: 596–599, 1997.
17. Panje, W. R., Hier, M. P., Garman, G. R., Harrel, E., Goldman, A., and Bloch, I. Electroporation therapy of head and neck cancer. *Ann. Otol. Rhinol. Laryngol.*, *107*: 779–785, 1998.
18. Heller, R., Jaroszeski, M. J., Reintgen, D. S., Puleo, C. A., DeConti, R. C., Gilbert, R. A., and Glass, L. F. Treatment of cutaneous and subcutaneous tumors with electrochemotherapy using intralesional bleomycin. *Cancer (Phila.)*, *83*: 148–157, 1998.
19. WHO Handbook for Reporting Results of Cancer Treatment, Vol. 48, pp. 22–27. Geneva: WHO Offset Publications, 1979.
20. Čemažar, M., Serša, G., and Miklavčič, D. Electrochemotherapy with cisplatin in treatment of tumor cells resistant to cisplatin. *Anticancer Res.*, *18*: 4463–4466, 1 1998.
21. Serša, G., Beravs, K., Čemažar, M., Miklavčič, D., and Demšar, F. Contrast enhanced MRI assessment of tumor blood volume after application of electric pulses. *Electro- Magnetobiol.*, *17*: 297–304, 1998.
22. Serša, G., Čemažar, M., Parkins, C. S., and Chaplin, D. J. Tumour blood flow changes induced by application of electric pulses. *Eur. J. Cancer*, *35*: 672–677, 1999.
23. Miklavčič, D., Beravs, K., Šemrov, D., Čemažar, M., Demšar, F., and Serša, G. The importance of electric field distribution for effective *in vivo* electroporation of tissues. *Biophys. J.*, *74*: 2152–2158, 1998.
24. Gilbert, R., Jaroszeski, M., and Heller, R. Novel electrode designs for electrochemotherapy. *Biochim. Biophys. Acta*, *1334*: 9–14, 1997.
25. Mir, L. M., Devauchelle, P., Quintin-Colonna, F., Delisle, F., Doliger, S., Fradelizi, D., Belehradek, J., Jr., and Orlowski, S. First clinical trial of cat soft-tissue sarcomas treatment by electrochemotherapy. *Br. J. Cancer*, *76*: 1617–1622, 1997.