

Emphysematous Gastritis Associated with Invasive Gastric Mucormycosis: A Case Report

Emphysematous gastritis is a rare form of phlegmonous gastritis, characterized by air in the wall of the stomach due to invasion by gas-forming microorganisms. The most commonly involved microorganisms are streptococci, *Escherichia coli*, *Pseudomonas aeruginosa*, *Clostridium perfringens* and *Staphylococcus aureus*. Gastrointestinal mucormycosis is another rare condition, which is most frequently occurs in the stomach. Because emphysematous gastritis associated with invasive gastric mucormycosis is an extremely rare clinical condition and both are life-threatening diseases, early precise diagnosis and early treatment should be done to avoid mortality. Herein we present an extremely rare case of emphysematous gastritis associated with invasive gastric mucormycosis. A 43-yr-old man, suffering from alcoholism and diabetes, has experienced diffuse abdominal pain for 4 days. Abdominal computed tomography scan demonstrated gas within the stomach wall. A histologic examination of the total gastrectomy specimen showed several gas-filled bubbles in the wall, along with numerous fungal hyphae throughout the necrotic stomach wall. He died of multiorgan failure secondary to disseminated mucormycosis, despite the intensive medical therapy.

Key Words : Gastritis; Stomach; Mucormycosis

Ji Han Jung, Hyun Joo Choi,
Jinyoung Yoo, Seok Jin Kang,
Kyo Young Lee

Department of Pathology, College of Medicine, The
Catholic University of Korea, Seoul, Korea

Received : 13 June 2006
Accepted : 6 July 2006

Address for correspondence

Jinyoung Yoo, M.D.
Department of Pathology, The Catholic University of
Korea, College of Medicine, St. Vincent's Hospital, 93
Ji-dong, Paldal-gu, Suwon 442-723, Korea
Tel : +82.31-249-7593, Fax : +82.31-244-6786
E-mail : jinyyoo@vincent.cuk.ac.kr

INTRODUCTION

Emphysematous gastritis, which was first described by Fraenkel in 1889 (1), is a rare disease characterized by the presence of air within the wall of the stomach and diffuse gastric wall inflammation by gas-forming bacteria, which may be also life-threatening due to systemic toxicity. Predisposing factors include the ingestion of corrosives, alcohol abuse, recent abdominal surgery, diabetes, and immunocompromised conditions (1-3). Since 1889, only 51 cases have been reported worldwide (1-8).

Mucormycosis is a rare fungal infection that usually involves the nasopharynx (9). Among the several forms, gastrointestinal mucormycosis is very rare, and the manifestations range from colonization of peptic ulcers to infiltrative disease with vascular invasion and dissemination (9). Commonly associated conditions include diabetes mellitus, lymphoma, leukemia, renal disease, septicemia, malnutrition, and long-term treatment with steroids and antibiotics (10). Among the reported cases of emphysematous gastritis, fungal organisms such as *Candida* species have been isolated rarely (4, 11-15). However, emphysematous gastritis associated with mucormycotic infection is extremely rare, and only one case has been reported in the English literature (15).

Here we report a case of emphysematous gastritis, diagnosed by computed tomography (CT) and confirmed by

histopathologic findings associated with invasive gastric mucormycosis that showed angioinvasion, necrosis, ultimately disseminated to the colon and liver, and was fatal despite medical and surgical treatment. To our knowledge, this is the first report of a patient with emphysematous gastritis associated with invasive gastric mucormycosis in Korea.

CASE REPORT

A 43-yr old man was admitted to the emergency room because of diffuse abdominal pain, indigestion, and poor oral intake for 4 days. He had had a 1-yr history of hypertension, diabetes mellitus without strict control, and chronic pancreatitis with stone. He had undergone endoscopic retrograde cholangiopancreatography to remove a pancreaticolith 8 months previously. There was also a history of excessive ingestion of alcohol and heavy smoking for 20 yr, but there was no history of peptic ulcer disease. His family history was not contributory. Upon admission, he looked acutely ill, but his mental status was alert. His blood pressure was 160/100 mmHg, with a body temperature of 36.2°C, pulse rate of 98/min, and respiration rate of 26/min. His breathing sound was decreased in both lung fields. Abdominal examination revealed decreased bowel sounds and severe tenderness in the epigastrium, with rigidity and rebound tenderness. How-

ever, there was no evidence of hepatosplenomegaly or mass-like lesion. Hematological and biochemical examinations on admission showed hemoglobin 13.9 g/dL (normal: 13-18), white blood cell $11.77 \times 10^9/L$ (3.6-11), platelet $210 \times 10^9/L$ (150-450), blood sugar 816 mg/dL (70-110), aspartate aminotransferase 148 IU/L (5-38), alanine aminotransferase 76 IU/L (4-43), lactate dehydrogenase 1,320 IU/L (180-460), amylase 6 U/L (45-108), blood urea nitrogen 37.7 mg/dL (8-23), and creatinine 1.6 mg/dL (0.5-1.2), and blood acetone-positive. Urinalysis showed sugar (++++)

and acetone (+). Blood and urine cultures were negative. Chest radiography revealed collapse and consolidation in the basal part of the left lower lobe, suggesting pneumonia. Abdominal CT scan revealed gastric wall thickening with a collection of dirty air bubbles and a small amount of pneumoperitoneum (Fig. 1). A diagnosis of emphysematous gastritis with combined perforation was made. Antibiotic therapy with sulferazone and metronidazole was initiated. Subsequently, he underwent emergency surgery. Operation findings showed nearly total necrosis of stomach wall with dark

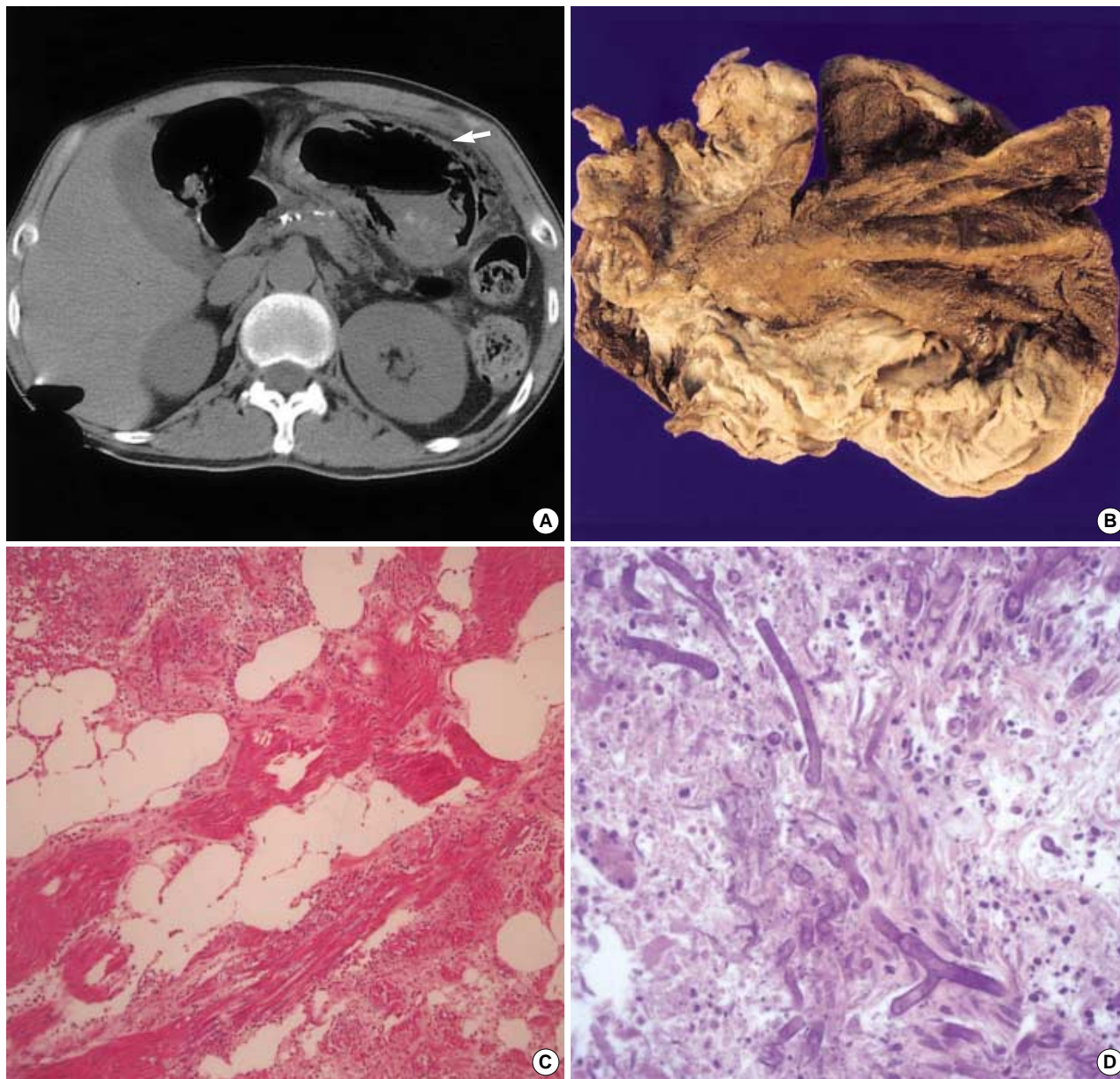


Fig. 1. (A) Computed tomography of the abdomen shows gastric wall thickening with a collection of dirty air bubbles (arrow), suggesting emphysematous gastritis. (B) The gross surgical specimen from the gastrectomy shows nearly total necrosis of the stomach. (C) Histologic findings of the gastrectomy specimen show some air spaces in the muscle layer of the stomach, consistent with emphysematous gastritis (H&E $\times 200$). (D) There are numerous broad-based, nonseptate, right angular branched fungal hyphae, morphologically consistent with mucormycosis (H&E $\times 400$).

green colored pus collection around the stomach. A total gastrectomy was performed.

Grossly, the stomach had a large area of necrosis with black discoloration of the mucosa (Fig. 1). Microscopic examination revealed extensive, full-thickness necrosis. The remaining viable stomach wall showed large numbers of neutrophils in the edematous submucosa and muscle layer. There were several gas-filled bubbles in the submucosa and muscle layer associated with numerous scattered or colonies of gram-negative bacilli, consistent with emphysematous gastritis (Fig. 1). At the same time, there were numerous broad-based, non-septate, right angular branched fungal hyphae, morphologically consistent with mucormycosis, detected on hematoxyline and eosin stain as well as silver stains throughout both necrotic and viable stomach wall (Fig. 1). Widespread invasion to blood vessels was found. Culture of pus in the peritoneum revealed *Klebsiella pneumoniae*, *Staphylococcus aureus*, and *Pseudomonas aeruginosa*. There was no evidence of involvement of the sinuses or lungs. Amphotericin B infusion was added after operation.

On the fifth hospital day, there was pus discharge from the wound site. However, the patient remained to have non-toxic appearance with stable vital signs.

On the seventh hospital day, he complained of diarrhea and vague abdominal discomfort. Over the following 2 days, the pus discharge aggravated. Clinically, wound dehiscence was suspected. Follow-up CT revealed an approximately 14.0 × 12.0 × 12.0 cm-sized, irregularly shaped air-containing fluid collection at the gastrectomy site, suggesting air-forming postoperative abscess and anastomotic site leakage. Reoperation was performed, and the operative findings showed multiple perforations with necrosis in the transverse colon, necrotic change in the liver, hematoma with fluid collection in the peritoneal cavity, and leakage in the anastomotic site. Roux-en-Y esophagojejunostomy with cecocolostomy and segmental resection of the large intestine were performed. The submitted pathological specimen consisted of segments of colon, small intestine, and a portion of liver. The gross examination of the segment of colon showed multiple perforations, dirty serosa, and necrotic mucosa with greenish black exudates. The portion of liver was totally necrotic. Microscopic examination of the colon and small intestine showed ischemic necrosis of mucosa with acute and chronic inflammation, and foreign body reaction. Mucormycotic fungal hyphae scattered in the muscle layer and serosa were noted. Microscopic examination of the liver also showed totally necrotic parenchyma with many angioinvasive mucormycotic fungal hyphae. After reoperation, the patient deteriorated rapidly. He developed dyspnea and remained in a sedated state. Auscultation of the lungs revealed decreased breathing sounds with rale on both lung fields, and saturation of arterial blood gas analysis was decreased. He underwent intubation and ventilation. On the 21st-hospital day, the patient expired. Autopsy was not performed.

DISCUSSION

Gas within the stomach wall is an alarming finding. Clinically this condition is divided into gastric emphysema and emphysematous gastritis (3, 5, 12). These two conditions should be differentiated because they are characterized by different clinical symptoms, possible etiology, radiologic findings, treatment, and prognosis (3, 5, 12). In gastric emphysema, air enters the stomach wall from the lumen, from the peritoneal surface, or from its connections with the esophagus and duodenum, resulting from barotraumas in the absence of bacterial infection (12). Radiologically, in contrast to emphysematous gastritis, a more linear distribution of gas in the gastric wall is characteristic of gastric emphysema (3). The symptom of acute abdomen as seen in patients with emphysematous gastritis is usually absent in patients with gastric emphysema (5). In general, gastric emphysema is asymptomatic; its course is usually benign and resolves spontaneously without treatment (3, 5, 12).

On the other hand, emphysematous gastritis, the gas formed in situ by gas-forming bacteria invading the gastric wall, results in a necrotizing inflammation of the gastric wall. In 1889, Fraenkel first reported a young man who died after several attacks of severe abdominal pain, blood vomitus, and diarrhea (1). At autopsy, rod-like organisms and multiple gas vesicles were found in the stomach wall. Originally, the stomach wall is well protected from bacterial infection by the close connection between cells, acidic pH, and good blood supply (3, 12). The predisposing factors, leading to the breakdown of these defenses, are ingestion of corrosives, alcohol abuse, diabetes, recent abdominal surgery, gastroenteritis, immunocompromised conditions, and treatment with non-steroidal anti-inflammatory drugs (1-3). In the present case, the patient had a history of alcohol abuse, which might have altered the unstirred mucous layer, and diabetes due to chronic pancreatitis, which might have led to a systemic predisposition to infection. Patients with emphysematous gastritis typically develop acute abdominal pain, as was the case in our patient, usually developing 1 week after initiation, accompanied by diarrhea, nausea, vomiting, and occasionally hematemesis and melena (1, 4, 12). Physical examination of the abdomen reveals epigastric tenderness, distension, and decreased bowel sounds (4, 12). Radiologically it has a characteristic appearance. Abdominal computed tomography, the best imaging modality to establish the diagnosis, reveals gastric wall thickening and intramural gas (1, 3, 12). In contrast to gastric emphysema, the gas in the wall is in the form of irregular mottled bubbles or spots, especially around the fundus and the greater curvature, and remains in place despite the position of the body or absorption through the gastric tube (3, 4, 12). Organisms that have been cultured from stomach aspirates, blood, and peritoneal fluid include streptococci, *E. coli*, *P. aeruginosa*, *Clostridium perfringens*, and *S. aureus* (1, 4). Among the previously reported cases, those associated with fungal infection

were rare (4, 11-15). Of these, most cases were *Candida* species (4, 11, 12, 15). Pathologically, the gas forming organisms in emphysematous gastritis have been shown to infiltrate the stomach wall diffusely and there are edematous stomach wall-containing gas bubbles (1, 6). The therapeutic approach for emphysematous gastritis included initial stabilization of the septic condition through vigorous fluid resuscitation and early empirical parenteral antibiotic therapy with a broad range of antibiotics covering Gram-negative and anaerobic bacteria (2, 3, 12, 14). Specific therapy should be modified according to the results of the gastric fluid culture and sensitivity testing of the isolated organism (12). The role of surgery in the acute phase is not well defined. However, indication for emergency surgery include deterioration despite optimal medical management, involvement of a large portion of or the entire stomach, presence of gastric infarction, or perforation (3, 4). Despite meticulous treatment, the prognosis for emphysematous gastritis patients is poor. The mortality rate of emphysematous gastritis is about 60%, and the morbidity near 21% (2).

Mucormycosis is a rare, opportunistic fungal infection that occurs almost exclusively in immunocompromised hosts such as patients with diabetes, leukemia, lymphoma, renal disease, septicemia, burns, malnutrition, and following long-term treatment with steroids and antibiotics (10). Clinical manifestations of mucormycosis can be categorized as rhinocerebral, pulmonary, disseminated, gastrointestinal, and cutaneous (9). Among these, rhinocerebral and pulmonary disease are the most common forms, and gastrointestinal involvement is very rare, accounting for only 7% of all cases (16). One of the most commonly associated conditions is diabetes mellitus (10). Other associated conditions are immunosuppressed conditions such as renal failure, hematological malignancies, cirrhosis, and solid organ transplantation (16). It is believed that infection of the alimentary tract is acquired through direct ingestion of and invasion by fungal spores. The gastrointestinal organ most frequently involved is the stomach, followed by the colon, small intestine, and esophagus (16). Widespread dissemination from a primary gastrointestinal site may occur (9). The fungus may colonize with or without invasion of surrounding tissue. When they invade, the lesion extends and marked surrounding induration develops, with a shaggy, velvety discolored surface or large plaque-like areas of green and blackened eschar (16). They also invade blood vessels and thus tend to cause extensive thrombosis, necrosis, and, ultimately, dissemination (10). Clinically, the lesion mimic ulcer or carcinoma. Diagnosis depends on the demonstration of tissue invasion by biopsy. Stool and gastric cultures are of value (9).

Association with emphysematous gastritis is an extremely rare, and only one such case has been reported (15). Mucormycosis is not gas-forming, therefore this infection is not a direct cause of emphysematous gastritis. Gastric wall necrosis caused by bacterial infection may be predisposed to the invasion by

mucormycosis. Alternatively, it is possible that invasive mucormycosis with subsequent gastric wall necrosis led to secondary bacterial invasion and intramural gas production (15). Successful management of mucormycosis includes aggressive metabolic support, amphotericin B, and surgical debridement of all necrotic involved tissue (15, 16). As in emphysematous gastritis, the prognosis of gastrointestinal mucormycosis is poor. Forty-two cases of gastric mucormycosis have been described in the literature thus far, with a mortality above 98% (15).

We report an extremely rare case of emphysematous gastritis associated with invasive gastric mucormycosis in a 43-yr-old man. Heavy alcohol abuse and diabetes mellitus were the predisposing factors. Clinicoradiological findings were typical and pathologic findings were consistent with emphysematous gastritis. CT is the diagnostic procedure of choice of emphysematous gastritis and helps in differentiating with gastric emphysema. Clinically, however, gastric mucormycosis associated with emphysematous gastritis is an unexpected finding. Moreover, the gastric mucormycosis showed angioinvasion, necrosis, and ultimately, disseminate to colon and liver. In the case of mucormycosis, biopsy of involved areas is often necessary to demonstrate the fungus histopathologically. As in previously reported cases, this patient also had a fatal outcome despite antibiotic and antifungal therapy and surgery. Increased awareness of these disease entities may facilitate early diagnosis, prompt medical therapy, and appropriate surgical intervention, and ultimately improve survival rates.

REFERENCES

1. Shipman PJ, Drury P. *Emphysematous gastritis: case report and literature review. Australas Radiol* 2001; 45: 64-6.
2. Gutierrez O, Cantalapiedra A, Tabuyo MI, Del Villar R, Penarrubia MJ, Sales R, Garcia-Frade LJ. *Emphysematous gastritis and severe aplastic anemia. Hematol J* 2003; 4: 82-4.
3. Ocepek A, Skok P, Virag M, Kamenik B, Horvat M. *Emphysematous gastritis-case report and review of the literature. Z Gastroenterol* 2004; 42: 735-8.
4. Yalamanchili M, Cady W. *Emphysematous gastritis in a hemodialysis patient. South Med J* 2003; 96: 84-8.
5. van Mook WN, van der Geest S, Goessens ML, Schoon EJ, Ramsay G. *Gas within the wall of the stomach due to emphysematous gastritis: case report and review. Eur J Gastroenterol Hepatol* 2002; 14: 1155-60.
6. Eisenhut M, Hughes D, Ashworth M. *Fatal emphysematous gastritis in a 2-year-old child with chronic renal failure. Pediatr Dev Pathol* 2004; 7: 414-6.
7. Cheong JY, Lee DH, Park WI, Park JH, Kim HW, Heo J, Kim GH, Kang DH, Song GA, Cho M, Yang US. *Emphysematous gastritis developed in a patient with Klatskin's tumor. Korean J Gastrointest Endosc* 2004; 28: 34-8.

8. Yoh KG, Lee DK, Baek SG, Lee SW, Bae SW, Kwon SO. *A case of emphysematous gastritis caused by acetic acid. Korean J Gastroenterol* 1993; 25: 1322-5.
9. Lehrer RI, Howard DH, Sypherd PS, Edwards JE, Segal GP, Winston DJ. *Mucormycosis. Ann Intern Med* 1980; 93: 93-108.
10. Dannheimer IP, Fouche W, Nel C. *Gastric mucormycosis in a diabetic patient. S Afr Med J* 1974; 48: 838-9.
11. Williamson MR, Shah HR, Harper RR, Angtuaco TL. *CT of emphysematous gastritis. Comput Med Imaging Graph* 1989; 13: 175-7.
12. Moosvi AR, Saravolatz LD, Wong DH, Simms SM. *Emphysematous gastritis: case report and review. Rev Infect Dis* 1990; 12: 848-58.
13. Van Allan RJ, Krebs TL, Henzie GM, Fermelia DE, Fichman MP. *Emphysematous gastritis in an immunocompromised host. Clin Imaging* 1995; 19: 129-30.
14. Bashour CA, Popovich MJ, Irefin SA, Esfandiari S, Ratliff NB, Hoffman WD, Averbook AW. *Emphysematous gastritis. Surgery* 1998; 123: 716-8.
15. Cherney CL, Chutuape A, Fikrig MK. *Fatal invasive gastric mucormycosis occurring with emphysematous gastritis: case report and literature review. Am J Gastroenterol* 1999; 94: 252-6.
16. Singh N, Gayowski T, Singh J, Yu VL. *Invasive gastrointestinal zygomycosis in a liver transplant recipient: case report and review of zygomycosis in solid-organ transplant. Clin Infect Dis* 1995; 20: 617-20.