

Editorial

'Aqualisation' of neuraxis: Wondrous neuraqua CSF 1

Manu Kothari, Atul Goel

1

View and Review

Organization of neurology services in India: Unmet needs and the way forward

Mandaville Gourie-Devi

4

Original Articles

Endoscopic management of brain abscesses

Yad Ram Yadav, Mallika Sinha, Neha, Vijay Parihar

13

Pattern of cerebellar perfusion on single photon emission computed tomography in subcortical hematoma: A clinical and computed tomography correlation

Jayantee Kalita, Usha K. Misra, Prasen Ranjan, P. K. Pradhan

17

Imaging features in Hirayama disease

Hemant A. Sonwalkar, Rakesh S. Shah, Firosh K. Khan, Arun K. Gupta, Narendra K. Bodhey, Surjith Vottath, Sukalyan Purkayastha

22

Delayed habituation in Behcet's disease

Sefa Gulturk, Melih Akyol, Hulusi Kececi, Sedat Ozelik, Ziyet Cinar, Ayse Demirkazik

27

Erythrocyte indicators of oxidative changes in patients with graded traumatic head injury

Chandrika D. Nayak, Dinesh M. Nayak, Annaswamy Raja, Anjali Rao

31

Repeat gamma knife radiosurgery for recurrent or refractory trigeminal neuralgia

Liang Wang, Zhen-wei Zhao, Huai-zhou Qin, Wen-tao Li, Hua Zhang, Jian-hai Zong, Jian-Ping Deng, Guo-dong Gao

36

Taste dysfunction in vestibular schwannomas

Rabi Narayan Sahu, Sanjay Behari, Vimal K. Agarwal, Pramod J. Giri, Vijendra K. Jain

42

Surgical management of traumatic intracranial pseudoaneurysms: A report of 12 cases

Xiang Wang, Jin-Xiu Chen, Chao You, Min He

47

Expression of truncated dystrophin cDNAs mediated by a lentiviral vector

Sun Shunchang, Chen Haitao, Chen Weidong, He Jingbo, Peng Yunsheng

52

Gamma knife radiosurgery for glomus jugulare tumors: Therapeutic advantages of minimalism in the skull base

Manish S. Sharma, A. Gupta, S. S. Kale, D. Agrawal, A. K. Mahapatra and B. S. Sharma

57

Case Reports

Subarachnoid hemosiderin deposition after subarachnoid hemorrhage on T2*-weighted MRI correlates with the location of disturbed cerebrospinal fluid flow on computed tomography cisternography <i>Yoshifumi Horita, Toshio Imaizumi, Yuji Hashimoto, Jun Niwa</i>	62
Anesthesia management of awake craniotomy performed under asleep-awake-asleep technique using laryngeal mask airway: Report of two cases <i>Gadhinglajkar Shrinivas Vitthal, Rupa Sreedhar, Mathew Abraham</i>	65
High cervical C3-4 'disc' compression associated with basilar invagination <i>Atul Goel</i>	68
Short-lasting unilateral neuralgiform headache with conjunctival injection and tearing: Response to antiepileptic dual therapy <i>Ravi Gupta, Manjeet S. Bhatia</i>	71
Correlation of autism with temporal tubers in tuberous sclerosis complex <i>Kavitha Kothur, Munni Ray, Prahbjot Malhi</i>	74
Non-traumatic carotid dissection and stroke associated with anti-phospholipid antibody syndrome: Report of a case and review of the literature <i>Benzi M. Kluger, Richard L. Hughes, C. Alan Anderson, Kathryn L. Hassell</i>	77
Osteoma of anterior cranial fossa complicated by intracranial mucocele with emphasis on its radiological diagnosis <i>Jinhu Ye, Hui Sun, Xin Li, Jianping Dai</i>	79
Vasospasm after transsphenoidal pituitary surgery: A case report and review of the literature <i>Manish Kumar Kasliwal, Ravinder Srivastava, Sumit Sinha, Shashank S. Kale, Bhawani S. Sharma</i>	81
Chondromyxoid fibroma of the seventh cervical vertebra <i>Ashish Jonathan, Vedantam Rajshekhar, Geeta Chacko</i>	84
Acute progressive midbrain hemorrhage after topical ocular cyclopentolate administration <i>Tarkan Calisaneller, Ozgur Ozdemir, Erkin Sonmez, Nur Altinars</i>	88

Letters to Editor

Digital subtraction angiography laboratory with inbuilt CT (DynaCT): Application during intracranial aneurysm embolization	90
Concomitant tuberculous and pyogenic cerebellar abscess in a patient with pulmonary tuberculosis	91
Drug compliance after stroke and myocardial infarction: Is complementary medicine an issue?	93

Multiple intracranial developmental venous anomalies associated with complex orbitofacial vascular malformation	93
Nitrofurantoin-induced peripheral neuropathy:A lesson to be re-learnt	94
Posterior longitudinal ligament cyst as a rare cause of lumbosacral radiculopathy with positive straight leg raising test	96
Aqueductal stenosis caused by an atypical course of a deep collector vein draining bilateral cerebellar developmental venous anomalies	97
Recovery of increased signal intensity of the cervical cord on magnetic resonance imaging after surgery for spontaneous spinal epidural hematoma causing hemiparesis	98
Simultaneous thalamic and cerebellar hypertensive hemorrhages	100

Neuroimages

MRI and MRA in spontaneous intracranial arterial dissection <i>S. Raghavendra, Sanjeev V. Thomas, Krishnamoorthy Thamburaj, Bejoy Thomas</i>	102
Shunt catheter migration into pulmonary arteries <i>Miikka Korja, Matti K. Karvonen, Arto Haapanen, Reijo J. Marttila</i>	103
Susceptibility weighted imaging in holohemispheric venous angioma with cerebral hemiatrophy <i>Sivaraman Somasundaram, Chandrasekharan Kesavadas, Bejoy Thomas</i>	104

Forthcoming Events	105
--------------------------	-----

Instructions to Authors	106
-------------------------------	-----

Referees List - 2007	000???
----------------------------	--------

The copies of the journal to members of the association are sent by ordinary post. The editorial board, association or publisher will not be responsible for non-receipt of copies. If any of the members wish to receive the copies by registered post or courier, kindly contact the journal's / publisher's office. If a copy returns due to incomplete, incorrect or changed address of a member on two consecutive occasions, the names of such members will be deleted from the mailing list of the journal. Providing complete, correct and up-to-date address is the responsibility of the members. Copies are sent to subscribers and members directly from the publisher's address; it is illegal to acquire copies from any other source. If a copy is received for personal use as a member of the association/society, one cannot resale or give-away the copy for commercial or library use.

Endoscopic management of brain abscesses

Yad Ram Yadav, Mallika Sinha, Neha, Vijay Parihar

Neurosurgery Unit, NSCB Government Medical College, Apex Hospital and Research Centre, Jabalpur, Madhya Pradesh, India

Background: Treatment of brain abscess is still a subject of controversy. Simple therapeutic approaches like twist drill/burr hole aspiration with or without insertion of a drain are also quite effective. There are reports of encouraging results following endoscopic treatment. We are reporting our results of endoscopic approach on 24 patients. **Materials and Methods:** This is a prospective study on 24 patients of brain abscesses treated between January 2004 and January 2007. All the cases except those with small abscesses (less than 1.0 cm in diameter) and multiloculated abscesses were included. Gabb 6-degree rigid endoscope was used. Repeat CT scan was done in all cases within 7 and 30 days after surgery. Ten patients (42%) had small residual abscess on 7th post-operative day's CT scan, while 30th post-operative day's CT scan did not show any significant lesion in all the cases. **Results:** There were 23 patients of chronic otitis media and one of congenital cyanotic heart disease. Glasgow coma score (GCS) was 3 in one patient, 13 in two cases, 14-15 in 21 cases. There were 14 cerebellar, 8 temporal and 1 frontal and thalamic abscess each. All the patients recovered completely except one who died (GCS 3). There was no procedure-related complication. Hospital stay ranged from 7 to 12 days with an average of 8.2 days. Follow-up ranged between 6 and 42 months. **Conclusion:** Endoscopic aspiration of brain abscess appears to be a safe and effective alternative method of treatment. There is direct visualization of abscess cavity, completeness of aspiration can be assessed, and perioperative bleeding can be controlled.

Key words: Brain abscess, endoscopic treatment, minimally invasive technique

Treatment of brain abscess is still a subject of controversy. Craniotomy with primary extirpation and resection of the abscess membrane,^[1-5] burr hole craniotomy and aspiration of pus with or without insertion of a drain,^[1,6] stereotactic aspiration,^[1,7,8] ultrasound-guided aspiration,^[9] medical management,^[1] endoscopic aspiration^[10,11] and stereotactic endoscopic aspiration^[12,13] are different therapeutic approaches. However, simple therapeutic approaches like twist drill/burr hole aspiration with or without insertion of

a drain are also quite effective. Endoscopic method has advantage of allowing direct visualization of abscess cavity. Completeness of aspiration can also be assessed.^[10,11] Perioperative bleeding can be controlled, which may not be possible in stereotactic or any other guided aspirations. We are reporting our results of 24 cases of endoscopic aspiration.

Materials and Methods

All the patients of brain abscesses referred to us were included, except small abscesses of less than 1.0 cm and multiloculated abscesses. This is a prospective study of 24 patients of brain abscesses treated between January 2004 and January 2007. Local Ethics Committee clearance was taken. Detailed history and thorough examination was done in all the cases. All the procedures were carried out in general anesthesia. Burr hole was made in all the cases; dura was opened in cruciate manner; arachnoid was also cut and brain cannula was inserted to confirm the presence of abscess; only about 5 ml of pus was aspirated. The sheath was introduced to puncture the abscess cavity. Gabb 6-degree rigid endoscope was used in all cases. In all the cases, the abscess content was aspirated, while the abscess membrane was left *in situ*. Pus was aspirated using infant feeding tube from working channel using gentle suction. Outflow channel was blocked intermittently, allowing the cavity to be filled up and then all the content was aspirated gently. This procedure was repeated many times till return became clear. The content of the cavity was also removed using normal saline irrigation and the fluid was allowed to come out through the outflow channel. The vision was poor initially but improved later on. Pus specimen was sent for culture sensitivity. A complete irrigation under view was performed. Preoperative CT scan was done in all patients [Figures 1 and 2]. Repeat CT scans were done in all cases within 7 and 30 days after surgery [Figures 3 and 4]. Ten cases had small residual abscess on 7th post-operative day's CT scan. CT scan done on 30th post-operative day did not show any significant lesion in all

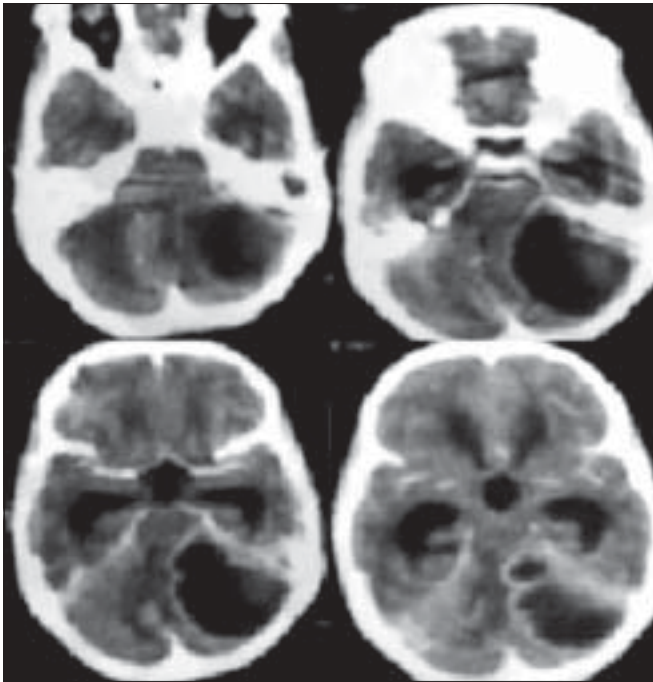


Figure 1: Pre-operative CT scan showing left cerebellar abscess with hydrocephalus

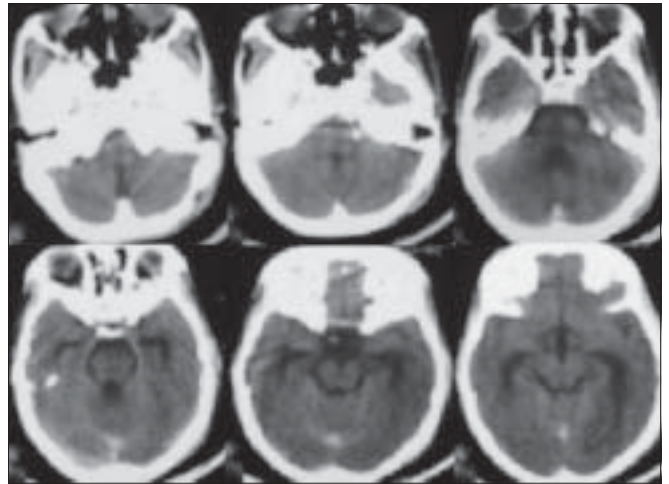


Figure 3: Post-operative CT scan showing complete aspiration of left cerebellar abscess

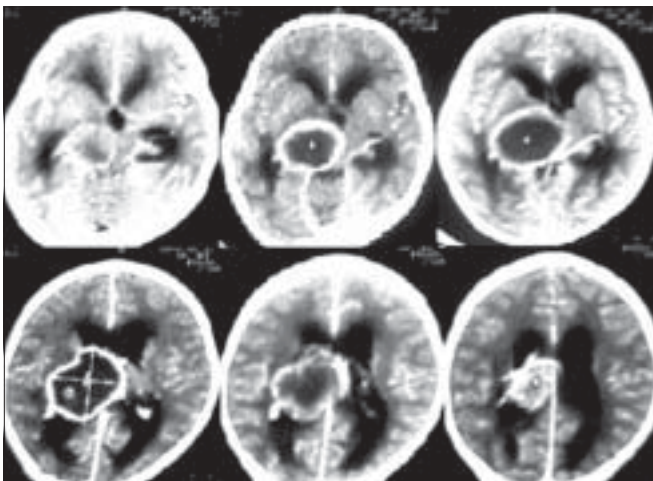


Figure 2: Pre-operative CT scan showing right thalamic abscess with hydrocephalus

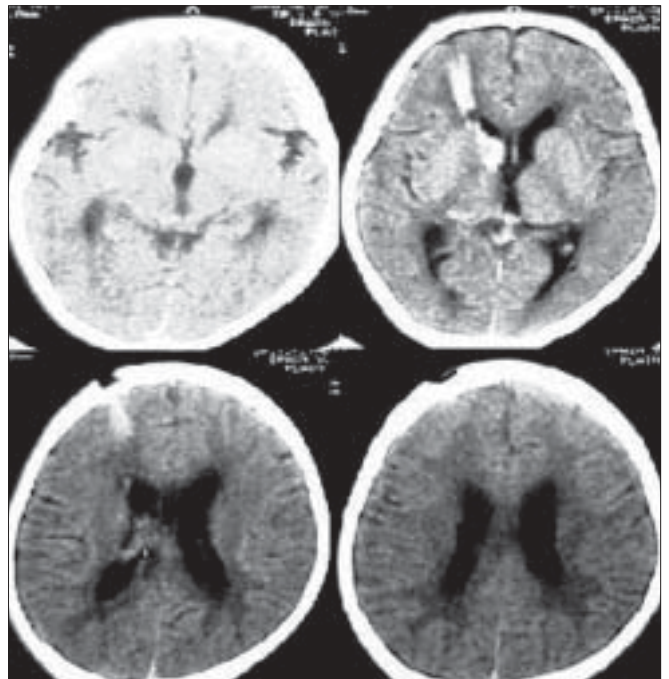


Figure 4: Post-operative CT scan showing complete aspiration of right thalamic abscess

the cases. Injection cefotaxim (100-150 mg/kg in three divided doses), injection vancomycin (1 gm 8 hourly in adults or 20 mg/kg in children) and metrogyl (500 mg 8 hourly in adults or 7.5 mgs/kg 8 hourly in children) were started pending sensitivity reports. According to culture and sensitivity, antibiotics were started later on. Intravenous antibiotics were given for 3 weeks, and oral antibiotics were continued for another 4 weeks. Dexamethasone (4 mg 6 hourly in adults) was used in all cases. All our patients had significant perilesional edema or obstructive hydrocephalus. Steroids were tapered as rapidly as possible and were given for 10-15 days.

Results

This is a prospective study of 24 patients of brain abscesses treated between January 2004 and January 2007. There were 16 male and 8 female patients. Their ages ranged between 6 and 58 years. There were 23 patients of chronic otitis media and one of congenital cyanotic heart disease. At the time of admission to the Neurosurgery Unit, GCS was 3 in one patient, 13 in two cases and 14-15 in 21 cases. All the patients underwent endoscopic surgery. There were 14 cerebellar, 8 temporal and one frontal and thalamic abscess each. Operating time ranged from 30 to 60 min (average 42 min). All

the patients recovered completely except one who died (GCS 3). There was no recurrence in any case. There was no complication related to procedure. Microorganisms were demonstrated in 11 (45%) patients; streptococcal was most frequent (62%); mixed infection occurred in 29% of abscesses. Stay in Neurosurgery Unit ranged from 7 to 12 days. Mastoid surgery was done as a separate procedure after endoscopic surgery during the hospital stay. The follow-up period ranged between 6 and 42 months.

Discussion

The results of endoscopic treatment of brain abscesses in our series were found to be safe and effective. Other authors too have advocated the use of endoscopy in brain abscesses. Fritsch *et al.*^[10] have suggested that the neuro-endoscopic treatment of brain abscesses has additional advantages as compared to stereotactic aspiration. It allows more complete drainage and lavage. Gajdhar and Yadav^[11] have concluded that the endoscopic aspiration of thalamic abscess appears to be a safe and effective method of treatment. They have also stressed that the direct visualization of abscess cavity is possible and the completeness of evacuation can be assessed. Bleeding during surgery can be controlled by endoscopic technique.^[11] Multiloculated abscesses can be better treated by endoscopic technique if the facility of neuro-navigation is available. This facility was not available in our operation theatre. Moreover, we did not manage multiloculated abscesses by endoscopic method. Although endoscopic approach has advantages over conventional techniques, including better visualization, completeness of aspiration, treatment of multiloculated abscess and control of bleeding, there is no controlled study available for comparison of results.

Sharma *et al.*^[1] have reviewed the concerned literature and found that the lavage with endoscopic stereotactic evacuation may cut down indications of excision of brain abscesses in future. They expected that a trend of adequate drainage of brain abscess via minimally invasive surgery is emerging. Hellwig *et al.*^[12] emphasized that endoscopic stereotactic technique, as a minimally invasive neurosurgical method, can be used for the treatment of brain abscess. Hellwig *et al.*^[13] concluded that the results of endoscopic stereotaxy in brain abscess were encouraging as compared to the conventional microsurgical techniques and pure stereotactic techniques.

The results of treatment in our series were related to the condition of patients before surgery; all our patients in GCS 13-15 survived with good results while a patient in GCS 3 died. Similar results were also seen in other endoscopic series of Fritsch and Manwaring^[10] and of Hellwig *et al.*^[12]. Ortega-Martinez *et al.*^[6] have observed 6.7% overall mortality in three treatment

groups-non-surgical, catheter drainage-aspiration and surgical excision. Mortality was higher in patients with low levels of consciousness and age over 70 years. Ciurea *et al.*^[9] have observed 11.86% mortality in repeated puncture and aspiration group.

There was no recurrence in any case in our series. Low recurrence in our series could be due to complete aspiration of abscess cavity under vision. Ciurea *et al.*^[9] have observed 18.64% recurrence in their series (repeated puncture and aspiration group). Ozkaya *et al.*^[4] have observed recurrence in 7.6% cases after the combined approach (mastoidectomy and abscess removal through the same sitting) as compared to 75% patients with recurrence after separate procedures (mastoidectomy followed by the cranial procedure within 7 days). Boviatsis *et al.*^[7] have observed recurrence in 8.33% cases after CT-guided stereotactic aspiration. Kutlay *et al.*^[14] have observed 0% recurrence rate in 13 patients treated with stereotactic aspiration and antibiotic treatment combined with hyperbaric oxygen therapy. Kurschel *et al.*^[15] also did not have any recurrence after a mean follow-up of 21 months (range from 7 to 72 months) with hyperbaric oxygen therapy in five children with brain abscess. Atiq *et al.*^[16] have recorded 66% complications like hemi-paresis, seizure, hydrocephalus and mental retardation. High complication in this series was due to late diagnosis and high percentage of cyanotic congenital heart disease (37%). They have also observed 3.3% bleeding (1/30) in children with brain abscesses. Kaplan *et al.*^[17] have observed that bleeding in brain abscess can occur due to inflammation or damage of the fragile neovasculature of the abscess wall. Hypoxia caused by Fallot's tetralogy or other congenital heart diseases facilitates the damage of these vessels. These damaged blood vessels bleed due to lack of any supportive tissues. Post-operative bleeding can occur in blind aspirations or stereotactic aspirations.^[11] There was no bleeding in our series.

Sharma *et al.*^[1] have stressed that stereotactic aspiration of all the loculi of multiloculated abscess can be done in single or staged aspiration. Nakajima *et al.*^[8] have suggested stereotactic aspiration for brainstem abscess. Boviatsis *et al.*^[7] have emphasized that CT-guided stereotactic aspiration of brain abscess helps achieve all treatment goals as it drains the content of the abscess, reduces mass effect and confirms diagnosis. CT-guided stereotactic aspiration is minimally invasive, carries minimal morbidity and mortality, and can be performed on compromised patients under local anesthesia. Ciurea *et al.*^[9] have reviewed the current concepts of management of brain abscesses, with particular emphasis on the use of real-time CT or ultrasound-guided operative techniques and found that these modalities are very useful in the management on brain abscess.

Simple techniques like twist drill/burr hole aspiration with or without insertion of a drain are also quite effective. Ortega-Martinez *et al.*^[6] have suggested that burr hole drainage-aspiration should be used as the first mode of treatment due to its advantage of shorter admission time together with its high efficacy and low morbidity.

Excision is required in large superficial abscesses resistant to multiple aspirations, post-traumatic abscess with a foreign body or fistula and multiloculated abscess of nocardia or actinomycotic etiology.^[1] Nowoslawska *et al.*^[2] have suggested craniotomy in children above 3 years of age with mature abscesses of the central nervous system. Bhand^[5] suggested that appropriate antibiotic therapy and complete removal of abscess along with excision of capsule could reduce mortality and neurological deficits from brain abscess.

Confirmation of diagnosis and monitoring of treatment response with magnetic resonance spectroscopy may allow greater number of patients to be managed with medical treatment in future.^[1] Reddy *et al.*^[18] have suggested that diffusion-weighted imaging has high sensitivity and specificity for the differentiation of brain abscess from other non-abscess intracranial cystic lesions.

We used infant feeding tube for aspiration. Husain *et al.*^[19] used angiographic catheter for aspiration of intraventricular and juxtaventricular cysts or solid lesions for aspiration, lesion removal and biopsy. Infant feeding tube is simple, cheap, effective and easily available, but its softness may cause it to bend and cause some difficulty while negotiating through the working channel. Angiographic catheter is stiffer, has wide internal diameter because of a thin wall and can be twisted as desired before introduction into the working channel. Therefore, it seems to be better than infant feeding tube.

Strength and limitation

This is the largest series on endoscopic management of brain abscesses. One limitation of endoscopic technique is that the vision is poor to start with. It is difficult in multiloculated abscesses, but stereotactic, ultrasound or other image-guided surgery can overcome this difficulty. We could not report multiloculated cases because of non-availability of navigation methods in our operation theatre.

Summary

Although conventional burr hole aspiration or twist drill aspiration and lavage are very effective in the

management of brain abscesses, endoscopic aspiration appears to be a safe and effective alternative method of treatment. Its advantages include direct visualization of abscess cavity, completeness of aspiration can be assessed, and perioperative bleeding can be controlled. It is also better in multiloculated abscesses.

References

1. Sharma BS, Gupta SK, Khosla VK. Current concepts in the management of pyogenic brain abscess. *Neurol India* 2000;48:105-11.
2. Nowoslawska E, Polis L, Mikolajczyk W, Krawczyk J, Zakrzewski K. The treatment of cerebral abscesses in children—the clinical experiences of neurosurgical clinic of PMMH in Lodz. *Neurol Neurochir Pol* 2001;35:12-8.
3. Sarma S, Sekhar LN Brain-stem abscess successfully treated by microsurgical drainage: A case report. *Neurol Res* 2001;23:855-61.
4. Ozkaya S, Bezircioglu H, Sucu HK, Ozdemir I. Combined approach for otogenic brain abscess. *Neurol Med Chir (Tokyo)* 2005;45:82-6.
5. Bhand AA. Brain abscess—diagnosis and management. *J Coll Physicians Surg Pak* 2004;14:407-10
6. Ortega-Martinez M, Cabezedo JM, Fernandez-Portales I, Gomez-Perals L, Rodriguez-Sanchez JA, Garcia-Yague L, *et al.* Pyogenic brain abscesses: Experience with 60 consecutive cases. *Neurocirugia (Astur)* 2006;17:23-33.
7. Boviatsis EJ, Kouyialis AT, Stranjalis G, Korfiatis S, Sakas DE. CT-guided stereotactic aspiration of brain abscesses. *Neurosurg Rev* 2003;26:206-9.
8. Nakajima H, Iwai Y, Yamanaka K, Kishi H. Successful treatment of brain-stem abscess with stereotactic aspiration. *Surg Neurol* 1999;52:445-8.
9. Ciurea AV, Stoica F, Vasilescu G, Nuteanu L. Neurosurgical management of brain abscesses in children. *Childs Nerv Syst* 1999;15:309-17.
10. Fritsch M, Manwaring KH. Endoscopic treatment of brain abscess in children. *Minim Invasive Neurosurg* 1997;40:103-6.
11. Gajdhar M, Yadav YR. A case of thalamic abscess treated by endoscopic surgery. *Neurol India* 2005;53:345-6.
12. Hellwig D, Bauer BL, Dauch WA. Endoscopic stereotactic treatment of brain abscesses. *Acta Neurochir Suppl* 1994;61:102-5.
13. Hellwig D, Benes L, Bertalanffy H, Bauer BL. Endoscopic stereotaxy: An eight year's experience. *Stereotact Funct Neurosurg* 1997;68:90-7.
14. Kutlay M, Colak A, Yildiz S, Demircan N, Akin ON. Stereotactic aspiration and antibiotic treatment combined with hyperbaric oxygen therapy in the management of bacterial brain abscesses. *Neurosurgery* 2005;57:1140-6.
15. Kurschel S, Mohia A, Weigl V, Eder HG. Hyperbaric oxygen therapy for the treatment of brain abscess in children. *Childs Nerv Syst* 2006;22:38-42.
16. Atiq M, Ahmed US, Allana SS, Chishti KN. Brain abscess in children. *Indian J Pediatr* 2006;73:401-4.
17. Kaplan M, Topsakal C, Cihangiroglu M. Hemorrhage into the brain abscess cavity with Fallot's tetralogy. *Pediatr Neurosurg* 2006;42:65-6.
18. Reddy JS, Mishra AM, Behari S, Husain M, Gupta V, Rastogi M, *et al.* The role of diffusion-weighted imaging in the differential diagnosis of intracranial cystic mass lesions: A report of 147 lesions. *Surg Neurol* 2006;66:246-50.
19. Husain M, Jha DK, Rastogi M. Angiographic catheter: Unique tool for neuroendoscopic surgery. *Surg Neurol* 2005;64:546-9

Accepted on 17-01-2008

Source of Support: Nil, Conflict of Interest: None declared.