

Endoscopic submucosal dissection: European Society of Gastrointestinal Endoscopy (ESGE) Guideline



Authors

Pedro Pimentel-Nunes¹, Mário Dinis-Ribeiro¹, Thierry Ponchon², Alessandro Repici³, Michael Vieth⁴, Antonella De Ceglie⁵, Arnaldo Amato⁶, Frieder Berr⁷, Pradeep Bhandari⁸, Andrzej Bialek⁹, Massimo Conio¹⁰, Jelle Haringsma¹¹, Cord Langner¹², Søren Meisner¹³, Helmut Messmann¹⁴, Mario Morino¹⁵, Horst Neuhaus¹⁶, Hubert Piessevaux¹⁷, Massimo Rugge¹⁸, Brian P. Saunders¹⁹, Michel Robaszewicz²⁰, Stefan Seewald²¹, Sergey Kashin²², Jean-Marc Dumonceau²³, Cesare Hassan²⁴, Pierre H. Deprez¹⁷

Institutions

Institutions listed at end of article

Bibliography

DOI <http://dx.doi.org/10.1055/s-0034-1392882>
Endoscopy 2015; 47: 829–854
© Georg Thieme Verlag KG
Stuttgart · New York
ISSN 0013-726X

Corresponding author

Dr. Pedro Pimentel-Nunes
Serviço de Gastrenterologia
Instituto Português de
Oncologia Francisco Gentil
Rua Dr Antonio Bernardino de
Almeida
4200-072 Porto
Portugal
Fax: +351-22-5513646
pedronunesml@msn.com

This Guideline is an official statement of the European Society of Gastrointestinal Endoscopy (ESGE). The Grading of Recommendations Assessment, Development, and Evaluation (GRADE) system [1,2] was adopted to define the strength of recommendations and the quality of evidence.

Main recommendations

1 ESGE recommends endoscopic en bloc resection for superficial esophageal squamous cell cancers (SCCs), excluding those with obvious submucosal involvement (strong recommendation, moderate quality evidence). Endoscopic mucosal resection (EMR) may be considered in such lesions when they are smaller than 10 mm if en bloc resection can be assured. However, ESGE recommends endoscopic submucosal dissection (ESD) as the first option, mainly to provide an en bloc resection with accurate pathology staging and to avoid missing important histological features (strong recommendation, moderate quality evidence).

2 ESGE recommends endoscopic resection with a curative intent for visible lesions in Barrett's esophagus (strong recommendation, moderate quality evidence). ESD has not been shown to be superior to EMR for excision of mucosal cancer, and for that reason EMR should be preferred. ESD may be considered in selected cases, such as lesions larger than 15 mm, poorly lifting tumors, and lesions at risk for submucosal invasion (strong recommendation, moderate quality evidence).

3 ESGE recommends endoscopic resection for the treatment of gastric superficial neoplastic lesions that possess a very low risk of lymph node metastasis (strong recommendation, high quality evidence). EMR is an acceptable option for lesions smaller than 10–15 mm with a very low probability of advanced histology (Paris 0-IIa). However, ESGE recommends ESD as treatment of choice for most gastric superficial neoplastic lesions (strong recommendation, moderate quality evidence).

4 ESGE states that the majority of colonic and rectal superficial lesions can be effectively removed in a curative way by standard polypectomy and/or by EMR (strong recommendation, moderate quality evidence). ESD can be considered for removal of colonic and rectal lesions with high suspicion of limited submucosal invasion that is based on two main criteria of depressed morphology and irregular or nongranular surface pattern, particularly if the lesions are larger than 20 mm; or ESD can be considered for colorectal lesions that otherwise cannot be optimally and radically removed by snare-based techniques (strong recommendation, moderate quality evidence).

Abbreviations

AJCC/UICC	American Joint Committee on Cancer/Union for International Cancer Control	EUS	endoscopic ultrasonography
APC	argon plasma coagulation	HGD	high grade dysplasia
CI	confidence interval	HGIN	high grade intraepithelial neoplasia
CT	computed tomography	LST	laterally spreading tumor
EMR	endoscopic mucosal resection	MRI	magnetic resonance imaging
EMRc	endoscopic mucosal resection with cap	NBI	narrow band imaging
ESD	endoscopic submucosal dissection	OR	odds ratio
		PET	positron emission tomography
		RFA	radiofrequency ablation
		SCC	squamous cell cancer
		WHO	World Health Organization

Introduction

▼ The widespread use of gastrointestinal endoscopy has increased the detection of early neoplastic lesions of the gastrointestinal tract, commonly known as gastrointestinal superficial lesions. Although these lesions are precancerous in most cases, invasion can be definitively excluded only after an adequate endoscopic resection. Endoscopic biopsies do not appear to be suitable for appropriate estimation of the malignant potential of the lesions, as shown by the substantial rate of histological upstaging in the passage from biopsies to adequately resected specimens. Endoscopic resection has also been shown to be an adequate treatment for patients with early gastrointestinal cancers with no or limited submucosal involvement and no additional risk factors. However, certainty on the endoscopic and histological completeness of such resection is needed, in order to spare these patients from pointless surgical treatment.

Most superficial gastrointestinal neoplasia may be treated by means of endoscopic mucosal resection (EMR). EMR is unsuitable for en bloc resection of lesions larger than 20 mm or of nonlifting lesions, as it does not permit adequate histological examination of early cancers. To overcome these limitations, endoscopic submucosal dissection (ESD) has been developed. ESD enables the operator to achieve an en bloc resection regardless of tumor size. However, ESD is technically demanding and associated with a higher risk of adverse events. ESD is nowadays extensively used in Eastern countries for the treatment of upper gastrointestinal superficial neoplasia, where it has been shown to be an extremely effective and safe procedure. Despite the different prevalence of gastrointestinal diseases, ESD is progressively gaining more attention in Western countries; this is also because of the technological innovations in this field.

The aim of this evidence-based and consensus-based Guideline, commissioned by the European Society of Gastrointestinal Endoscopy (ESGE), is to provide caregivers with a comprehensive review of the clinical indications for ESD for the treatment of gastrointestinal superficial lesions, as well as guidance on post-ESD management and on technical details. Details on pathology and the definitions applied (**Appendix 2**) and recommendations on training (**Appendix 3**) are also provided.

Methods

▼ The ESGE commissioned this Guideline and appointed a guideline leader (M.D.R.) who invited the listed authors to participate in the project development. The key questions were prepared by the coordinating team (P.D., M.D.R., M.V., T.P., A.R.) and then approved by the other members. The coordinating team formed task force subgroups, each with its own leader, and divided the key topics (esophagus, stomach, duodenum, and colorectum) among these task forces (see **Appendix 1**).

Each task force performed a systematic literature search to prepare evidence-based and well-balanced statements on their assigned key questions. The coordinating team independently performed systematic literature searches, including at least the Medline database, and at a minimum the following key words: ESD and neoplasia. All articles studying the use of ESD in esophageal, gastric, or colorectal epithelial tumors were selected by title or abstract. All selected articles were graded by the level of evidence and strength of recommendation according to the GRADE system [1,2].

Each task force proposed statements on their assigned key questions which were discussed and voted on during the plenary meeting held in March 2014 in Munich. The literature searches were updated through December 2014. In February 2015, a draft prepared by the coordinating team was sent to all group members. The manuscript was also reviewed by two members of the ESGE Governing Board and sent for further comments to the National Societies and Individual Members. After agreement on a final version, the manuscript was submitted to the journal *Endoscopy* for publication. All authors agreed on the final revised manuscript.

This Guideline was issued in 2015 and will be considered for review and update in 2020 or sooner if new and relevant evidence becomes available. Any updates to the Guideline in the interim will be noted on the ESGE website: <http://www.esge.com/esge-guidelines.html>.

Recommendations and statements



ESOPHAGUS

Efficacy in the esophagus

Squamous cell cancer

ESGE recommends endoscopic en bloc resection for superficial esophageal squamous cell cancers (SCCs), excluding those with obvious submucosal involvement (strong recommendation, moderate quality evidence). Endoscopic mucosal resection (EMR) may be considered in such lesions when they are smaller than 10 mm if en bloc resection can be assured. However, ESGE recommends endoscopic submucosal dissection (ESD) as the first option, mainly to provide an en bloc resection with accurate pathology staging and to avoid missing important histological features (strong recommendation, moderate quality evidence).

Endoscopic resection (EMR or ESD) is indicated for esophageal cancer with no or minimal risk of lymph node invasion. The incidence of lymph node invasion of esophageal cancer relates closely to the depth of invasion, tumor histology and differentiation, and lymphatic or vascular invasion. Features influencing deeper invasion include the endoscopic pattern, size of the lesion, and histological features, such as deep invasion limit, differentiation grade (G1–2, vs. G3) and lymphovascular invasion. These features can only be accurately assessed with an en bloc resection. Endoscopic resection is the standard treatment for superficial esophageal SCC classified as m1 (intraepithelial) or m2 (invading the lamina propria), with an almost null risk for lymph node metastasis [3,4]. The risk increases to 8%–18% for lesions invading the muscularis mucosae (m3), 11%–53% for lesions invading the submucosal layer to 200 µm or less (sm1) and 30%–54% for deeper lesions (sm2) [5–7]. Paris type 0–I and 0–III lesions have often submucosal infiltration and are not an ideal indication for endoscopic treatment, whereas types 0–IIa, 0–IIb, and 0–IIc are often intramucosal. According to the Japan Esophageal Society guidelines for treatment of esophageal cancer, the absolute indication for endoscopic resection is defined as flat lesions (Paris 0–II), with m1–m2 invasion, and circumferential extent of ≤2/3, while the relative indication is defined as m3–sm1 esophageal cancer and where endoscopic resection would leave a mucosal defect of circumferential extent ≥3/4 [4].

With ESD, these criteria tend to expand, accepting endoscopic treatment of lesions larger than 3 cm, and occupying the entire circumference of the esophagus, provided that all are restricted to the mucosa. The 15 series reporting ESD for superficial SCC [8–22] showed rates of en bloc resection of 83%–100%, com-

plete resection rates of 78%–100% and local recurrence rates of 0–2.6% (Table 1).

The risk of lymph node metastasis of m3 or sm1 lesions without lymphovascular invasion has indeed been reported to be as low as 4.7% [5,46]. Moreover, several studies have shown higher morbidity with surgery than endoscopic resection [47–49]. Therefore, for patients with co-morbid diseases or unwilling to undergo esophagectomy, ESD should be considered as an appropriate alternative for m3 or sm1 well-differentiated cancers without lymphatic or vessel infiltration and with free margins, particularly in older patients and/or significant comorbidities [3,50,51].

The size of the lesion is the main criterion for choosing between EMR and ESD excision. En bloc R0 resection is mandatory for SCC removal to provide a better disease-free survival in a cancer with a high risk of lymph node metastasis. The risk of lymph node metastasis can only be assessed on a single entire pathological specimen; otherwise important histological features may be missed. EMR may not provide en bloc resection (and R0 excision) in large lesions, with recurrence rates ranging from 9% to 23% following piecemeal excision [15,51–54]. Ishihara et al. [37] considered cap-assisted EMR (EMRc) to be a good alternative for small lesions, because they reported no difference concerning local recurrence, R0 resection, and en bloc resection for lesions <15 mm, while results were significantly better for ESD for lesions between 15 and 20 mm. However, in a meta-analysis Cao et al. showed that even for lesions <10 mm local recurrence was lower with ESD [55]. Based on these studies we consider that ESD should be the preferred technique and that EMRc could be an acceptable option for lesions smaller than 10 mm.

Barrett's esophagus

ESGE recommends endoscopic resection with a curative intent for visible lesions in Barrett's esophagus (strong recommendation, moderate quality evidence).

ESD has not been shown to be superior to EMR for excision of mucosal cancer, and for that reason EMR should be preferred. ESD may be considered in selected cases, such as lesions larger than 15 mm, poorly lifting tumors, and lesions at risk for submucosal invasion (strong recommendation, moderate quality evidence).

Available data on ESD in Barrett esophagus neoplasia are scarce [23,24,27,28,32,38]. In Western countries, the safety and high success rates of EMR are offset by technical difficulties and the risk of ESD to the esophagus [56, 57]. In Asian countries, Barrett's esophagus is an uncommon condition, and adenocarcinoma is still rare [58]. For these reasons, EMR is the gold standard in current clinical practice for endoscopic excision in Barrett's esophagus neoplasia. The main limitation of EMR is that it usually entails piecemeal resection, thus hampering histopathological assessment and curative resection as defined by "oncology standards," namely with en bloc resection and free margins [59].

Patients with Barrett's esophagus and the presence of high grade dysplasia (HGD) or intramucosal cancer without visible lesions (flat HGD/intramucosal cancer) are managed with an endoscopic ablative technique. Among ablative techniques, radiofrequency ablation (RFA) has high efficacy and a good safety and side-effect profile. In patients with dysplastic Barrett's esophagus associated with visible lesions, endoscopic resection is considered to be the therapy of choice. Tumors confined to the mucosa (T1a) have been shown to have significantly better 5-year recurrence-free and overall survival rates (100% and 91%, respectively) than those showing involvement of the submucosa (60% and 58%)

[60]. Endoscopic therapy for Barrett's neoplasia has been developed on the evidence that HGD and T1a carcinoma are associated with a low rate of lymph node metastasis: endoscopic and surgical series indicate a 0%–10% risk in T1a cancer, while submucosal invasion carries a higher risk (up to 46%) [60–68].

A recent systematic review reported no evidence of nodal metastasis in patients with a lesion finally staged as HGD [69]. EMR is usually used to resect all visible abnormalities. Focal EMR is combined with eradication of residual Barrett's esophagus by RFA because it reduces the risk of metachronous neoplasia [70]. This combined approach has become widely accepted by Western endoscopists as an ideal endoscopic treatment for early Barrett's adenocarcinoma.

Studies have shown that EMR of visible lumps shown to have HGD by biopsy leads to upgrading to cancer in 25%–40% of cases [70–72]. Paris type I lesions may be more likely to harbor unsuspected cancer, as may Paris type IIa+c lesions. In a surgical series of esophagectomies done for presumed HGD, the prevalence of coexisting cancer in patients was 45% (14/31) [73]. Cancer was found in the resected specimens from 7 of 9 patients (78%) with a visible lesion and 7 of 22 patients (32%) without a visible lesion ($P=0.019$). Lesions at high risk of harboring cancers should therefore be removed en bloc to achieve accurate histological staging. This helps in deciding the role of additional therapy if indicated, as in patients with cancers classified as sm2 cancers and higher. For ESD in Barrett's esophagus, outcomes of five measures of effectiveness and three measures related to safety were considered (Table 1). Although the data came from observational studies (mostly retrospective) and may have been affected by a high risk of bias, all the studies reported a high rate of en bloc resection (81%–100%), with a low rate of complications, most of which were managed endoscopically. The mean operation time ranged from 70 to 107 min. Complete resection (R0) rates were somewhat lower than for SCC and ranged from 38% to 97%. Recent European studies confirm that similar results may be obtained in Western countries [24,28,38]. However, resection of large lesions, involving more than 3/4 of the circumference may cause the onset of esophageal strictures. For Barrett's adenocarcinomas, according to reports that analyzed the rate of lymph node involvement relative to the depth of tumor infiltration, endoscopic resection might be extended to lesions with invasion into the submucosa (≤ 500 μ m, sm1), for low risk tumors (well or moderately differentiated tumor [G1–2], without lymphatic or vascular invasion [L0 and V0], and size <3 cm) because they harbor a low risk of lymph node metastasis (1.4%) [25,26,55,62,74]. However few data are available, the reported number of adenocarcinomas being only 237 (67 Barrett's esophagus, 16 esophageal, and 154 esophagogastric junction [EGJ]).

In a systematic review comparing EMR versus ESD resection, no significant differences were noticed for complications, patients with subsequent surgery, positive margins, positive lymph nodes, local recurrence, or metachronous cancer [75]. In instances where piecemeal tumor resection was predicted, local recurrence rates were significantly lower with ESD compared with EMR [76]. Based on this study, ESD should be considered in selected cases, such as for lesions larger than 15 mm, poorly lifting tumors, and lesions at risk for submucosal invasion. Indeed, an en bloc resection might provide improved histological evaluation, such as evidence of deeper invasion ($> pT1m2$) or G3 differentiation. Since ESD has not been shown to be superior to EMR for excision of mucosal cancer, multicenter, randomized, controlled trials are needed to define the role of ESD compared with EMR.

Table 1 Outcomes of ESD for esophageal superficial lesions.

Tumor type (Number of studies) First author, year	Lesions included, n	En bloc resection rate Lesions, n/N Overall % (Range, %) Studies, n/N*	Complete R0 resection rate Lesions, n/N Overall % (Range, %) Studies, n/N	Curative resection rate Lesions, n/N Overall % (Range, %) Studies, n/N	Local recurrence rate Lesions, n/N Overall % (Range, %) Studies, n/N	Mortality, ESD-related	Procedure-related bleeding rate Lesions, n/N Overall % (Range, %) Studies, n/N	Procedure-related perforation rate Lesions, n/N Overall % (Range, %) Studies, n/N	Mean operation time Range, min Studies, n/N
<i>Squamous cell carcinoma</i> (15 studies)									
Kanzaki 2013 [8]	970	963/970	719/868	528/698	3/850	0 %	40/970	37/970	24–160
Toyonaga 2013 [9]		99 %	82.8 %	75.6 %	0.3 %		4.1 %	3.8 %	9/15
Kawahara 2013 [10]		(83.3 %–100 %)	(78 %–100 %)	(69 %–100 %)	(0 %–2.6 %)		(0 %–22.8 %)	(0 %–4 %)	
Fujinami 2014 [11]		15/15	14/15	10/15	14/15		15/15	15/15	
Yamashina 2012 [12]									
Yamashita 2011 [13]									
Mokizuki 2011 [14]									
Takahashi 2010 [15]									
Repici 2010 [16]									
Chaves 2010 [17]									
Teoh 2010 [18]									
Nonaka 2010 [19]									
Ono 2009 [20]									
Fujishiro 2006 [21]									
Oyama 2005 [22]									
<i>Adenocarcinoma arising in Barrett esophagus or esophagogastric junction</i> (6 studies)									
Hoteya 2013 [23]	346	336/346	265/336	246/336	0 %	0 %	4/346	8/346	(70–145)
Neuhaus 2012 [24]		97.1 %	78.8 %	73.2 %	6/6	6/6	1.1 %	2.3 %	5/6
Hirasawa 2010 [25]		(81 %–100 %)	(38.5 %–97 %)	(64.5 %–86 %)			(0 %–2.7 %)	(0 %–4 %)	
Yoshinaga 2008 [26]		5/6	6/6	6/6			6/6	6/6	
Kakushima 2006 [27]									
Chevaux 2015 [28]									
<i>Squamous cell carcinoma (superficial) + adenocarcinoma</i> (10 studies)									
	678								

Table 1 (Continuation)

Tumor type (Number of studies) First author, year	Lesions included, n	En bloc resection rate Lesions, n/N Overall % (Range, %) Studies, n/N*	Complete R0 resection rate Lesions, n/N Overall % (Range, %) Studies, n/N	Curative resection rate Lesions, n/N Overall % (Range, %) Studies, n/N	Local recurrence rate Lesions, n/N Overall % (Range, %) Studies, n/N	Mortality, ESD-related	Procedure-related bleeding rate Lesions, n/N Overall % (Range, %) Studies, n/N	Procedure-related perforation rate Lesions, n/N Overall % (Range, %) Studies, n/N	Mean operation time Range, min Studies, n/N
Higuchi 2013 [29]		637/678	589/678	560/678	4/359	0 %	7/678	3/678	(67 – 142)
Arantes 2013 [30]		93.9 %	86.8 %	82.6 %	1.1 %		1 %	0.4 %	8/10
Isomoto 2013 [31]		(81.2 % – 100 %)	(50 % – 100 %)	(50 % – 97 %)	(0 % – 8 %)		(0 % – 3.2 %)	(0 % – 4 %)	
Sato 2013 [32]		10/10	10/10	10/10	8/10		10/10	10/10	
Chaves 2013 [33]									
Lee 2012 [34]									
Kikuchi 2012 [35]									
Ishii 2010 [36]									
Ishihara 2008 [37]									
Probst 2015 [38]									
Tumor not specified (4 studies)	44								
Linghu 2013 [39]		41/44	38/44	29/35	0 %	0 %	5/44		77 – 150
Farhat 2011 [40]		93.1 %	86.3 %	82.8 %	3/4		11.3 %		2/4
Coda 2010 [41]		(88.9 % – 100 %)	(77.8 % – 100 %)	(77 % – 100 %)			(0 % – 18.5 %)		
Motohashi 2009 [42]		4/4	4/4	3/4			(1 case of bleeding + perforation)		
Submucosal tumor (3 studies)	185						4/4		
Li 2012 [43]		173/185	163/173	175/185	0 %	0 %	0 %	9/185	45 – 73
Gong 2012 [44]		93.5 %	94.2 %	94.5 %	3/3		3/3	4.8 %	3/3
Shi 2011 [45]		(83.3 % – 94.4 %)	(94.4 % – 100 %)	(94.4 % – 100 %)				(0 % – 10.7 %)	
		3/3	2/3	3/3				3/3	
Total (38 studies)	2223	2150/2223	1774/2099	1538/1932	7/1560	0 %	53/2045	59/2179	24 – 160
		96.7 %	84.5 %	79.6 %	0.4 %		2.5 %	2.7 %	
Excluding submucosal tumors	2046	1965/2038	1611/1926	1363/1747	7/1375		53/1860	50/1994	27/38
		96.4 %	83.6 %	78 %	0.5 %		2.8 %	2.5 %	
		(81 % – 100 %)	(38.5 % – 100 %)	(0 % – 100 %)	(0 % – 8 %)		(0 % – 22.8 %)	(0 % – 10.7 %)	
		37/38	36/38	32/38	35/38		38/38	38/38	

*n/N, number of studies reporting outcome/number of studies considering each type of tumor

Safety of ESD for SCC and Barrett esophagus-associated adenocarcinoma

The complication rate of ESD is thought to be higher than that of EMR because of technical issues and because of the relatively long procedure times which are potential concerns in elderly patients who often have co-morbidities. The outcomes of three measures related to safety, as described in 37 out of 38 studies included in the analysis, are summarized in **Table 1**. No mortality was observed during and after ESD procedures. Bleeding was observed in a range of 0–22.8% of procedures and perforation in 0–10.7%. A systematic review reported that bleeding was managed conservatively in 95% of cases and required intervention in <10% of cases [75]. Most bleeding is observed during the procedure or within the first 24 hours [77]. Small perforations recognized during the procedure can be successfully sealed with endoscopic clips [21, 37]. Large perforations require urgent salvage surgery. No significant differences in procedural complications were observed between EMR versus ESD patients, except for the significantly higher prevalence of esophageal stenosis, probably related to the extent of the tumor removed and not to the technique itself ($P < 0.001$) [21, 28, 37, 75].

Ono et al. analyzed predictors of postoperative stricture following 11 ESD procedures for superficial SCC [78]. In multivariate analysis, a circumferential extent involving over 75% of the whole lumen, along with greater invasion depth ($> pT1m2$), was significantly associated with stricture occurrence. Tumor size ($> 59\%$ of the circumference) was also thought to potentially be involved [79]. These strictures usually can be successfully treated by endoscopic dilation, but steroids injected locally or with oral administration may decrease the need for dilation [80–82].

In comparison with esophagectomy, it appears that endoscopic resection is safer than surgery. However, there are only a few studies comparing endoscopic resection with surgery, all of them retrospective. They confirm that surgery is associated with higher rates of periprocedural mortality and morbidity, although endoscopic resection is related to higher recurrence. Moreover, long-term mortality was not different and most recurrences in the endoscopy group could be managed by another endoscopic treatment. Taking all this into account, in selected lesions and when feasible, it appears that endoscopic resection has comparable results to surgery with a better safety profile and so it should also be considered as a first-line treatment [61, 83, 84].

Evaluation before endoscopic resection: esophagus

In the treatment of esophageal superficial neoplasms, ESGE recommends performance of lesion assessment by an experienced endoscopist, using at least a high resolution endoscope and one of the advanced endoscopic imaging modalities (narrow-band imaging [NBI]) and/or chromoendoscopy (strong recommendation, moderate quality evidence).

Routine performance of endoscopic ultrasonography (EUS), computed tomography (CT), or positron emission tomography-CT (PET-CT) is not recommended prior to endoscopic resection (strong recommendation, moderate quality evidence).

ESGE suggests that EUS should be considered in esophageal superficial carcinomas with suspicious features for submucosal invasion or lymph node metastasis (weak recommendation, low quality evidence).

Expert high resolution endoscopy should be carried out in all patients with detected HGD or superficial cancer, in order to confirm visible abnormalities suitable for endoscopic resection and to detect other possible lesions and to delineate precise margins, since the size of the lesion and signs of submucosal invasion will determine whether the indication is for EMR or for ESD. Although early esophageal neoplasia generally presents as subtle flat le-

sions that may be difficult to detect, most procedures performed with high resolution endoscopes do reveal these abnormalities to the experienced eye [72, 85].

The morphology of all visible lesions should be described using the Paris classification since this gives an indication of the likelihood of invasive cancer [86]. In Barrett's mucosa, endoscopic reporting should be performed using a minimum dataset including a record of the length using the Prague criteria (circumferential extent [C], maximum extent [M] of endoscopically visible columnar-lined esophagus in centimeters, and any separate islands above the main columnar-lined segment noted).

Chromoendoscopy with dyes such as Lugol (for SCC) or acetic acid (for Barrett's esophagus) may be of significant help to detect and delineate lesions, but outcome is dependent on the experience and expertise of the individual endoscopist. Concerning acetic acid, the largest studies showed sensitivity of 96% for the diagnosis of high grade intraepithelial neoplasia (HGIN) or cancer [87–89]. Lugol chromoendoscopy has been the gold standard for detecting esophageal SCC but should also be used to define the lateral margins of superficial tumors and to detect synchronous esophageal lesions [90].

With recent technological advances "virtual chromoendoscopy" has become available, which allows chromoendoscopy without the use of dyes. This is based on light filters (NBI, Olympus) or digital processing after image acquisition (i-Scan, Pentax; and Fujinon Intelligent Chromoendoscopy [FICE], Fujinon). The most extensively studied "virtual chromoendoscopy" technique for the esophagus is NBI, which highlights the mucosal pattern and the superficial vasculature. NBI was shown to be useful in detecting esophageal neoplasia in high risk patients [91] and was even shown to have comparable sensitivity and superior specificity when compared with Lugol chromoendoscopy [92]. In Barrett's esophagus, a meta-analysis of 8 studies has found that NBI has sensitivity and specificity of 96% and 94%, respectively, for the diagnosis of HGIN [93]. However, the interobserver agreement for the interpretation of the NBI images is only moderate [94]. All these imaging techniques can therefore aid definition and detailed mapping of the edges of visible lesions in order to guide complete endoscopic resection [94, 95].

Dysplasia should always be confirmed by direct sampling of any visible lesions before endoscopic resection. There is no recent consensus on the optimal number of biopsy specimens necessary for the diagnosis before resection. In the past, at least 4 biopsies were recommended in suspected malignant lesions [96]. There is a now a trend towards fewer biopsies to avoid increase in submucosal fibrosis that may complicate the submucosal dissection. Visible lesions should always be considered malignant until proven otherwise, even if the biopsy specimen reveals no malignancy. Furthermore, high rates (20%–40%) of discordance between endoscopic biopsy and postoperative specimen have been reported [97]. En bloc endoscopic resection should always be considered to be the confirmative diagnosis.

Recent systematic reviews and meta-analyses on the diagnostic accuracy of EUS staging showed the following pooled values for EUS in T1a staging: sensitivity, 0.85 (95%CI 0.82–0.88); specificity, 0.87 (95%CI 0.84–0.90); positive likelihood ratio, 6.62 (95%CI 3.61–12.12); and negative likelihood ratio, 0.20 (95%CI 0.14–0.30). For T1b staging, the results were: sensitivity, 0.86 (95%CI 0.82–0.89); specificity, 0.86 (95%CI 0.83–0.89); positive likelihood ratio, 5.13 (95%CI 3.36–7.82); and negative likelihood ratio, 0.17 (95%CI 0.09–0.30) [98]. The area under the curve was at least 0.93 for both mucosal and submucosal lesions. For regional

lymph node metastases the pooled sensitivity and specificity have been reported as 0.76 and 0.72, respectively [99]. Although EUS has a better diagnostic performance compared with CT scanning and PET-CT, the question of regional lymph node detection has yet to be satisfactorily addressed.

Initial evidence that endoscopic resectability (discrimination between T1 and T2 lesions) could be predicted by EUS has been tempered by most of the recent series, which have indicated that 15%–25% of cases are understaged compared with EMR staging, while about 4%–12% are overstaged [100, 101]. High frequency probe-EUS has been found to be no better than high resolution endoscopy in local staging of early cancer (mucosal vs. submucosal invasion), but conventional EUS has a role in assessment of nodal staging and is certainly superior to CT scan in both T and N staging. However, it has limited accuracy in the detection of submucosal invasion in early esophageal cancer [102, 103].

The cumulative data are not enough to recommend routine use of EUS prior to EMR/ESD for HGD or superficial cancer [85, 104–107]. EUS should be considered in staging of high risk lesions as the risk of invasive cancer remains high. A negative EUS finding is not very helpful but a positive EUS finding can change management. However, when sm or T2 invasive cancer is suspected then complete staging should be performed with EUS, CT, and/or PET-CT. EUS remains superior to CT scan in locoregional staging of early lesions.

Management according to technical and histological outcomes: esophagus

In squamous cell cancer, ESGE recommends that:

- An en bloc R0 resection of a superficial lesion with histology no more advanced than m2 SCC, with no lymphovascular invasion, is considered curative (strong recommendation, moderate quality evidence).
- An en bloc R0 resection of a well-differentiated m3/sm1 tumor ($\leq 200 \mu\text{m}$) without lymphovascular invasion has a low risk of lymph node metastases and is curative in the majority of cases. The risk of further therapy should be balanced against the risk of lymph node metastasis, in a multidisciplinary discussion (strong recommendation, moderate quality evidence).
- In the case of sm2 or more advanced tumor ($> 200 \mu\text{m}$), poorly differentiated tumor, lymphovascular invasion, or positive vertical margins, further treatment is recommended (chemoradiotherapy and/or surgery) depending on patient status (strong recommendation, moderate quality evidence).
- If the horizontal margin is positive and no other high risk criteria are met, endoscopic surveillance/re-treatment is an option (strong recommendation, low quality evidence).

For Barrett's esophagus-associated adenocarcinoma, ESGE recommends that:

- In Barrett's esophagus, endoscopic en bloc R0 resection of a superficial lesion with mucosal adenocarcinoma is considered curative (strong recommendation, moderate quality evidence).
- Endoscopic en bloc R0 resection of a sm1 lesion ($\leq 500 \mu\text{m}$) with a low risk profile (well or moderately differentiated, no lymphovascular invasion) is potentially curative and in a multidisciplinary discussion the risk of surgery should be balanced against the risk of lymph node metastasis (strong recommendation, moderate quality evidence).
- Surgery is recommended when lymphovascular invasion, poorly differentiated tumor, deeper infiltration than sm1 ($> 500 \mu\text{m}$), or positive vertical margins are diagnosed (strong recommendation, moderate quality evidence).
- If the horizontal margin is positive or there is piecemeal resection with no other high risk criteria, endoscopic surveillance/re-treatment is recommended rather than surgery (strong recommendation, moderate quality evidence).
- In patients with early neoplasia in Barrett esophagus, further treatments are necessary (EMR, RFA) after the curative resection, in order to ablate or

resect the residual metaplastic epithelium where foci of synchronous intraepithelial neoplasia could be overlooked, and metachronous lesions could arise (strong recommendation, moderate quality evidence).

To our knowledge there are only few studies evaluating the risk of lymph node metastasis in superficial esophageal cancers. They are all retrospective and observational. For a given stage the risk of lymph node metastasis appears to be higher in SCC than in adenocarcinoma. In SCC, lesions that are m1 (intraepithelial) or m2 invading the lamina propria have an almost null risk for lymph node metastasis [3, 4]. The risk increases to 8%–18% for lesions invading the muscularis mucosae (m3), to 11%–53% for lesions invading the submucosal layer to $200 \mu\text{m}$ or less (sm1), and to 30%–54% for deeper lesions (sm2) [5–7]. Even though m3 and sm1 tumors have a significant risk of lymph node metastasis, when the data are analyzed most of these cases are associated with lymphovascular invasion or poorly differentiated tumor. Moriya et al. showed that well-differentiated m3/sm1 tumors without lymphovascular invasion in immunostaining had no risk of lymph node metastasis [108]. Based on this study and on the fact that esophagectomy has a mortality rate that often exceeds 2% and has significant morbidity, an en bloc R0 resection of a m3/sm1 tumor could be considered as an appropriate therapy, particularly in patients who are older and/or have significant comorbidities [3, 50, 51]. In the case of more advanced tumor, positive lymphovascular invasion, or positive vertical margins, further treatment for SCC carcinoma (chemoradiotherapy and/or surgery) is recommended, depending on the patient's clinical status.

Only a few studies report data on outcomes when horizontal margins are positive. However, a low rate of recurrence despite the presence of compromised horizontal margins has been reported (62 R1 and 47 Rx resections in 707 patients [15%], from 15 studies), and most of the time these recurrences could be managed by further endoscopic treatments [10, 11, 16, 18, 24–27, 29, 33, 35, 37, 109]. So, positive horizontal margins per se should prompt close endoscopic surveillance rather than further treatments. In SCC the risk of a new metachronous lesion in the esophagus is high and so endoscopic follow-up is recommended. The risk of lymph node metastasis in Barrett's esophagus adenocarcinoma appears to be lower than in SCC. However, the data come from only a few studies, that are retrospective, and that include a limited number of patients. For Barrett's adenocarcinomas, according to reports that analyzed the rate of lymph node involvement relative to the depth of tumor infiltration, endoscopic resection appears to be curative for intramucosal carcinomas that are well or moderately differentiated (G1–2) and without lymphatic or vascular invasion (L0 and V0) [25, 26, 55, 62, 74]. Manner et al. suggest that these criteria might be extended to lesions with invasion into the submucosa ($\leq 500 \mu\text{m}$, sm1), namely to low risk tumors (well or moderately differentiated (G1–2), without lymphatic or vascular invasion (L0 and V0), and of size $< 3 \text{ cm}$), because such lesions harbor a low risk of lymph node metastasis (1.4%) [74]. However, only few patients were included in that study, and so this risk should be balanced against the risk of surgery for a particular patient.

In 30 studies (6 did not report depth of invasion), the proportion of lesions having a probability of lymph node metastasis (m3–sm2 with/without lymphovascular invasion), was 193/1860 (10.3%); 14 studies report additional treatment by surgery and/or chemoradiotherapy in m3–sm2 lesions or when lymphovascular invasion was present.

In patients unfit for surgery or in patients who refused surgery, a strict follow-up was advised, but the rate of locoregional and metastatic disease, in this subgroup of patients, was modest [18–21, 25, 26, 37].

In all patients, the entire Barrett's segment must be eradicated after resection of any visible lesion, regardless of negative resection margin findings, in order to ablate or resect the residual metaplastic epithelium where foci of synchronous intraepithelial neoplasia could be overlooked and metachronous lesions could arise [23, 24].

Surveillance after curative endoscopic resection: esophagus

Squamous cell cancer: after a curative resection for esophageal squamous cell cancer, ESGE recommends intensive regular follow-up (endoscopy at 3–6 months and then annually), including high resolution endoscopy, virtual or dye chromoendoscopy, and biopsies of suspicious areas (strong recommendation, low quality evidence).

Since local recurrence is exceptional after en bloc curative resection, follow-up should aim at early detection of metachronous lesions in order to apply further endoscopic therapy (strong recommendation, moderate quality evidence).

ESGE does not suggest the use of EUS or CT in the follow-up after a curative resection (weak recommendation, low quality evidence).

Barrett esophagus-associated adenocarcinoma: ESGE recommends regular endoscopic follow-up after excision/ablation of Barrett esophagus-associated HGD or mucosal cancer, but more research is needed to determine the appropriate short and long intervals (strong recommendation, low quality evidence).

The risk of lymph node invasion in well-differentiated submucosal sm1 ($\leq 500 \mu\text{m}$) Barrett esophagus cancer appears to be lower than the surgical risk, justifying a close endoscopic follow-up as advised for HGD or mucosal cancer (strong recommendation, moderate quality evidence).

Although ESD provides high en bloc (90%–100%) and acceptable complete resection (38%–97%) of Barrett esophagus adenocarcinoma [23–25], it should be associated with eradication of the remaining Barrett segment by additional endoscopic therapy consisting of endoscopic resection, argon plasma coagulation (APC), and/or RFA, or other ablative techniques, regardless of presence or absence of residual dysplasia. The goal of endoscopic mucosal resection and ablation is to eliminate the subsequent risk of cancer. But Barrett esophagus can recur after ablative and excisional therapies. When remaining Barrett's mucosa has been left untreated, case series have reported recurrence of neoplasia, with rates varying from 11% to 30% (mean follow-up 3 years) [110–113]. Evidence for the most appropriate follow-up is lacking, so research should establish how patients should be monitored after ablative and excisional therapies. This research should include randomized controlled trials (with a follow-up of at least 5 years) to evaluate the effectiveness and optimal timing of different follow-up approaches, such as universal surveillance, with endoscopy if symptoms recur. The durability of the eradication therapy, the frequency and importance of buried metaplasia, and the long-term efficacy of ablation therapy for cancer prevention remain unsettled issues.

Post-therapy surveillance should follow the Barrett's management guidelines: endoscopic follow-up is recommended after endoscopic therapy of Barrett's neoplasia with biopsy samples taken from the esophagogastric junction (EGJ) and within the extent of the previous Barrett's esophagus [95, 114]. In all cases, follow-up is mandatory not only to detect recurrence but also to allow further therapy to be applied as required. Empirically, in patients treated for HGD or mucosal cancer, endoscopic follow-up is

recommended 3-monthly for 1 year and yearly thereafter. This approach is followed by most experts in a recent practice survey [115].

In the case of en bloc and complete resection (R0), the risk of local recurrence was found to be null in the 6 studies reporting on Barrett esophagus adenocarcinoma or EGJ adenocarcinoma (Table 1). The risk of lymph node metastasis in mucosal cancer is very low ($< 2\%$) justifying the attitude that follow-up may be limited to endoscopic surveillance. In submucosal lesions (sm1, limited to $\leq 500 \mu\text{m}$), the risk for lymph node metastasis seems lower than the risk associated with surgery, but the former risk may increase in the case of G3 differentiation and when lymphatic invasion is observed, justifying adjuvant or surgical therapy [74].

STOMACH Efficacy in the stomach

ESGE recommends endoscopic resection for the treatment of gastric superficial neoplastic lesions that possess a very low risk of lymph node metastasis (strong recommendation, high quality evidence).

EMR is an acceptable option for lesions smaller than 10–15 mm with a very low probability of advanced histology (Paris 0-IIa). However, ESGE recommends ESD as treatment of choice for most gastric superficial neoplastic lesions (strong recommendation, moderate quality evidence).

Several studies and meta-analyses show that ESD should be considered in the treatment of gastric superficial neoplastic lesions (low or high grade noninvasive neoplasia, adenocarcinoma with no evidence of deep submucosal invasion) since it allows high rates of en bloc R0 curative resection with a good safety profile when compared with alternative therapies [116–119]. For these reasons ESD is now contemplated as a first-line treatment for early gastric cancer in Japanese guidelines for gastric cancer [120]. The lesions that should be considered for endoscopic resection because of very low risk of lymph node metastasis are the following [120–122]:

- ▶ Noninvasive neoplasia (dysplasia) independently of size
- ▶ Intramucosal differentiated-type adenocarcinoma, without ulceration (size $\leq 2 \text{ cm}$ absolute indication, $> 2 \text{ cm}$ expanded indication)
- ▶ Intramucosal differentiated-type adenocarcinoma, with ulcer, size $\leq 3 \text{ cm}$ (expanded indication)
- ▶ Intramucosal undifferentiated-type adenocarcinoma, size $\leq 2 \text{ cm}$ (expanded indication)
- ▶ Differentiated-type adenocarcinoma with superficial submucosal invasion (sm1, $\leq 500 \mu\text{m}$), and size $\leq 3 \text{ cm}$ (expanded indication)

Even though the Japanese guidelines consider only lesions $\leq 2 \text{ cm}$ in size as representing an absolute indication for ESD, several recent studies have shown that clinical outcomes after ESD were similar for absolute and expanded indication lesions [121, 123, 124]. For this reason it is the ESGE panel's opinion that ESD should be considered in any lesion with very low possibility of lymph node metastasis, whether it meets either the absolute or expanded indication criteria, even though surveillance may be different (see below).

EMR was the first endoscopic treatment that was a real alternative to surgery for the treatment of early gastric cancer. In early series, EMR cured cancer in more than 85% of cases, a value that approached gastrectomy outcomes at the time [125, 126]. In selected cases long-term follow-up of this technique showed 99% disease-specific survival both at 5 and 10 years [127]. However, EMR is clearly associated with high rates of local recurrence (al-

most 30% in some studies), that must be treated either by another endoscopic treatment or by surgery [125–128]. ESD has emerged as a technique that could allow higher en bloc resection rates for larger lesions, consequently with lower levels of recurrence [129,130].

In fact several retrospective studies, whose data were grouped in three meta-analyses (Table 2) [118,119,131] have compared EMR with ESD for the treatment of early gastric cancer. ESD obtained higher en bloc resection rates (92% vs. 52%; odds ratio [OR] 9.69, 95%CI 7.74–12.13) and histologically complete resection rates (82% vs. 42%; OR 5.66, 95%CI 2.92–10.96), and lower recurrence frequency (1% vs. 6%; OR 0.10, 95%CI 0.06–0.18). Importantly, these benefits were maintained even in smaller lesions (less than 10mm). These better outcomes were, nevertheless, associated with longer procedure times (more 59.4 min; 95%CI 16.8–102) and higher risk of perforation (4% vs. 1%; OR 4.67, 95%CI 2.77–7.87). Most perforations were managed conservatively in these studies, with no death attributed to perforation. No differences in important bleeding rates were seen (9% in both groups). Authors concluded that ESD is better than EMR for the treatment of gastric neoplastic lesions, although with a slightly higher risk of perforation. An Eastern series comparing long-term outcomes of EMR vs. ESD confirmed higher rates of recurrence in the EMR group, even though there was no difference in survival [132]. A recent long-term Western series showed similar results, with ESD obtaining a higher R0 resection rate (91% vs. 54%, $P<0.001$) and a lower recurrence rate (4% vs. 15%, $P=0.02$) but no differences in survival [133]. However, it should be noticed that these studies have a selection bias, with bigger and more advanced lesions being preferentially selected for ESD. Nevertheless, given the fact that long-term survival does not appear to be compromised by the technique used, it is the ESGE panel's opinion that EMR is an acceptable option for lesions smaller than 10–15 mm with a very low probability of advanced histology (Paris 0–IIa).

Safety: stomach

There is no formal study comparing different approaches to management of adverse events associated with ESD. In most ESD series bleeding and perforations are the most common complications and most of the time they are managed conservatively without surgery [116–118,123,134–136]. All of these ESD series prompt the following considerations:

Bleeding during ESD is generally categorized as immediate (during the procedure) or delayed (after the procedure). Some immediate bleeding occurs in almost all ESDs. As a general rule, if large vessels are observed they should be coagulated before proceeding with the dissection. If a major bleed occurs, prompt hemostasis must be performed before proceeding, in order to prevent there being more than one bleeding spot. Bleeding can initially be controlled with the knife in coagulation mode and if this fails then a coagulation forceps should be used. The use of hemoclips during the procedure should be avoided in the dissection area since this may compromise further dissection. If a bleed is not controlled by the coagulation forceps then dissection around the bleeding point should be done before placing a hemoclip, in order to fully expose the bleeding point and to enable further and complete dissection of the lesion. Delayed bleeding occurs in almost 10% of the procedures. Visible vessels should be routinely coagulated after dissection since this has been shown to significantly reduce the risk of delayed bleeding [137]. If delayed bleeding does occur, this should be handled using the standard

Table 2 Outcomes of endoscopic submucosal dissection (ESD) for gastric superficial lesions (meta-analysis data).

Meta-analysis First author, year (number of studies)	Lesions included, n	En bloc resection rate Lesions, n/N (%)	Complete R0 resection rate Lesions, n/N (%)	Curative resection rate Lesions, n/N (%)	Local recurrence rate Lesions, n/N (%)	Mortality, ESD-related	Procedure-related bleeding Lesions, n/N (%)	Procedure-related perforation Lesions, n/N (%)	Mean operation time, range from studies, min
Park 2011 [119] (12 studies)	1734	1055/1150 (92%)	1287/1401 (92%)	774/973 (80%)	13/1592 ($<1\%$)	0	116/1642 (7%)	80/1762 (5%)	33–84
Lian 2012 [118] (9 studies)	1495	1328/1437 (92%)	1227/1495 (82%)*		11/1438 ($<1\%$)	0	82/876 (9%)	62/1438 (4%)	34–116
Facciorusso 2014 [131] (10 studies)	1916	1328/1437 (92%)	1227/1495 (82%)*		12/1859 ($<1\%$)	0	62/1438 (4%)	62/1438 (4%)	34–116

* Considered by author to be histologically complete resection (did not differentiate between complete R0 and curative resection)

methods of endoscopic hemostasis (ideally with hemoclips) and rarely by surgery.

Perforations occur rather uncommonly during gastric ESD, at an approximate rate of 1%–4%. In a study analyzing perforations during gastric ESD only one patient underwent surgery, because of simultaneous severe bleeding and perforation, while all the others were managed conservatively with or without endoscopic clipping [138]. When visible perforation occurs, clear visualization must first be obtained (eventually with further dissection) while minimizing air/CO₂ insufflation. Then a complete closure of the perforation must be achieved with application of hemoclips or any other closure device. Complete dissection and removal of the entire lesion should be attempted. If necessary exsufflation of peritoneal air/CO₂ should be done in order to reduce post-ESD complications and pain. There is no consensus regarding the use of a nasogastric tube with some experts defending this while others do not. In the case of delayed perforation, endoscopic or surgical closure should be discussed, with case by case management according to clinician experience and the specific situation. Broad-spectrum antibiotics should be given.

Concerning other possible complications of ESD (stenosis, pneumonia, mucosal lacerations, other), they should be handled case by case according to clinician experience and the specific situation.

Data comparing endoscopic resection techniques with surgery are limited. Only four retrospective studies compare these therapies – three for EMR and only one for ESD. Two initial studies with small numbers of patients and highly selected endoscopic cases did not find any differences in survival [139,140]. However, it was noticeable that even for small lesions, the rates of incomplete resection and recurrence were higher in the EMR group. On the other hand it was also clear that surgery was associated with higher post-procedure morbidity particularly in elderly patients [140]. In a more recent study that included more participants, EMR was comparable to surgery not only for survival but also for recurrence [141]. Although the EMR group had a higher risk of metachronous lesions, all patients were successfully re-treated with no effect on survival. Interestingly, the complication rate was similar between the groups (~7%), although there was no procedure-related death in the EMR group compared with 2 deaths in the surgery group. Analysis of the complications in this study shows that in the EMR group the majority were related to bleeding (all easily controlled endoscopically) in contrast to some serious complications (wound dehiscence, cholecystitis, urethral injury, etc.) in the surgery group. Moreover, the EMR group had a significantly shorter hospital stay (8 vs. 15 days) and lower cost of care, leading the authors to conclude that EMR has advantages over surgery for the treatment of early gastric cancer. In spite of these advantages, almost 30% of patients in the EMR group were not included in the analysis because the criteria for complete resection were not met, suggesting that EMR may not be feasible for the treatment of some early gastric cancers that can be treated by surgery.

The above consideration can favor ESD. Indeed, in the only cohort where ESD was compared with surgery, gastrectomy patients had longer operative time (265 vs. 90 min), longer hospital stay (10 vs. 3 days) and higher complication rates (33% vs. 5%), with similar oncologic outcomes and survival, leading the authors to conclude that ESD should be the first-line treatment for early gastric cancer [142]. However, it should be emphasized that in this series only a few patients underwent laparoscopic gastrectomy, a procedure that appears to have a better safety profile than

open gastrectomy [143,144]. So, further studies should compare ESD with laparoscopic surgery. Moreover, it is common knowledge that even in selected cases with complete resection by ESD, some patients will still need surgery with removal of ganglia because of noncurative resection (e.g. undifferentiated cancer, submucosal deep invasion, vascular invasion, etc). Nevertheless, even in these cases surgery remains an option with surgery results not compromised by previous ESD [145,146].

In conclusion, with the fallback that some patients will still need surgery after ESD, it appears that in selected cases ESD obtains similar oncologic outcomes with a better safety profile when compared with surgery.

Evaluation before endoscopic resection: stomach

ESGE recommends a high quality endoscopy, ideally with contrast or digital chromoendoscopy, by an experienced endoscopist in order to establish the feasibility of gastric endoscopic resection (strong recommendation, moderate quality evidence).

US, CT, or other procedures are not routinely recommended for the assessment of gastric superficial lesions prior to endoscopic resection (strong recommendation, moderate quality evidence).

Abdominal CT is part of the staging process for gastric cancer. However, superficial neoplastic lesions have a very low risk of distance metastasis and, so, it is unlikely that CT findings will rule out ESD in a lesion where endoscopic treatment seems feasible. Indeed, studies show that endoscopy findings alone have a high accuracy for predicting the depth of invasion and consequently tumor stage [147,148]. Findings associated with mucosal disease only (ESD, therefore, being feasible) included protrusion or depression of a smooth surface, slight marginal elevation, and smooth tapering of converging folds. On the other hand, findings suggestive of submucosal disease (ESD, therefore, probably not feasible) included an irregular surface, marked marginal elevation, and clubbing, abrupt cutting, or fusion of converging folds. Endoscopy with magnification and with contrast or digital chromoendoscopy may improve diagnosis and staging and might help in delineating tumor margins, factors that may be important in assessing feasibility and achieving an R0 resection [149–152]. For these reasons, ESGE recommends that when possible these techniques should be used to establish feasibility and to plan ESD. The role of EUS in establishing the feasibility of endoscopic resection is somewhat controversial. Although EUS is considered to be the most reliable method for local staging, its global accuracy particularly for gastric superficial lesions is rather low [153,154]. Moreover, a comparative study of EUS versus endoscopic evaluation for predicting endoscopic resectability clearly favored endoscopy since EUS findings would indicate gastrectomy for many lesions that did not need surgery [148]. For this reason, in many Eastern countries performance of EUS prior to ESD is not considered for a lesion amenable to endoscopic resection [117,135]. Nevertheless, in most Western countries EUS is generally recommended before treatment [155]. However, in one Western ESD series that systematically used EUS before endoscopic resection the feasibility of ESD was comparable and even slightly inferior to that in another Western ESD series where EUS was not performed (93% vs. 97%) [133,156]. Thus, ESGE suggests that a strategy of precise endoscopic evaluation of these lesions is sufficient for predicting resectability, with EUS reserved only for selected cases. CT is generally not necessary since the risk of metastatic disease is very low in a lesion where endoscopic resection is considered to be feasible [122,157,158].

Management according to technical and histological outcomes: stomach

ESGE recommends that:

- An en bloc R0 resection of dysplastic lesions or intestinal-type intramucosal adenocarcinoma, without ulceration or lymphovascular invasion should be considered curative (strong recommendation, moderate quality evidence).
- En bloc R0 resection of ulcerated intestinal-type intramucosal adenocarcinoma ≤ 30 mm or of submucosal adenocarcinoma ≤ 30 mm confined to the upper 500 μm of the submucosa (sm1) and without lymphovascular invasion has a very low risk of lymph node metastasis and is curative in most instances (strong recommendation, moderate quality evidence).
- En bloc R0 resection of nonulcerated intramucosal poorly differentiated tumor of size ≤ 20 mm is curative in most cases and surveillance is an option. However, in poorly differentiated/diffuse-type carcinomas gastrectomy should always be considered with the decision made on an individual basis (taking into account patient age and preference, and co-morbidities) in a multidisciplinary approach (strong recommendation, moderate quality evidence).
- Surgery is recommended when lymphovascular invasion, deeper infiltration than sm1 ($>500 \mu\text{m}$), positive vertical margins, ulcerated features in tumors >30 mm or with submucosal invasion are diagnosed (strong recommendation, moderate quality evidence).
- If there is a positive horizontal margin or resection is piecemeal, but there is no submucosal invasion and no other high risk criteria are met, endoscopic surveillance/re-treatment is recommended rather than surgery (strong recommendation, moderate quality evidence).

The traditional indications for curative endoscopic resection of gastric lesions were based on the limitations of EMR, namely, the impossibility of en bloc R0 resection of large tumors, and included differentiated adenocarcinomas less than 20 mm in size with no ulceration or lymphovascular invasion [120]. The risk of lymph node metastasis in these tumors appears null and so an en bloc R0 resection of these tumors should be considered curative [120]. However, after the introduction of the ESD technique, that allowed large en bloc resections, several authors noted that these criteria were too strict and led to unnecessary surgery [159]. In fact, although the risk of lymph node metastasis in intramucosal adenocarcinoma is described to be around 3%–4%, in one of the largest series involving 584 early gastric cancers, only undifferentiated or ulcerated intramucosal tumors presented lymph node metastases [157]. Indeed, Gotoda et al. in the largest series of early gastric cancers, involving 5265 patients who underwent gastrectomy, did not find any lymph node metastases in the 929 intramucosal intestinal-type adenocarcinomas without ulceration, regardless of lesion size [122]. Considering their results and other series, they estimated that the risk of lymph node metastasis was equal for nonulcerated well-differentiated intramucosal lesions whether less or more than 30 mm (95%CI of 0–0.3% vs. 0–0.4%) [117, 122, 160]. So, it appears that given the almost null risk of lymph node metastasis in nonulcerated well-differentiated intramucosal adenocarcinomas without lymphovascular invasion, an en bloc R0 resection of these lesions, independently of size, will be curative.

If the lesion is ulcerated but smaller than 30 mm, the risk also appears to be negligible. Indeed Gotoda et al. did not find any lymph node metastasis in this subgroup and estimated a risk of 0–0.3%, contrasting with the 3.4% risk of ulcerated tumors larger than 30 mm [122]. However, other groups found that ulceration was an independent risk factor for lymph node metastasis and so it is not absolutely clear that ulcerated tumors smaller than 30 mm have the low risk estimated by Gotoda et al. [157, 161].

Considering submucosal invasion, it is clear that tumors with submucosal invasion have an increased risk of lymph node metastasis, approaching 20%–30% in some series, particularly in larger lesions with deep infiltration and lymphovascular invasion [122, 157, 161]. Nevertheless, Gotoda et al. found that in the sub-

group of well-differentiated tumors smaller than 30 mm, with submucosal infiltration of less than 500 μm and without lymphovascular invasion, the risk was also negligible (95%CI 0–2.5%) [117, 122, 160].

Again, another controversial issue is whether any kind of diffuse/undifferentiated carcinoma can be cured by endoscopic therapy. Most series show that even intramucosal diffuse carcinomas may have a significant risk of lymph node metastasis approaching 5% [122, 157, 161]. However, Gotoda et al. found that intramucosal poorly differentiated/diffuse tumors, that were nonulcerated, smaller than 20 mm, and with no lymphovascular invasion can be cured by endoscopy since the risk of lymph node metastasis is very low (95%CI 0–2.6%) [122]. A recent report including 310 patients with poorly differentiated carcinoma with these characteristics confirmed these results, since the authors did not find any lymph node metastasis in those patients and they estimated a lower risk of metastasis in this subgroup (95%CI 0–0.96%) [162]. However, this is a matter of some controversy since the biology of these tumors is different, they are more frequent in younger patients, and the upper limit of the 95%CI (1% to 2.6%) may not be acceptable for a young and fit patient. Moreover, although long-term follow-up of ESD series for early gastric cancer did not show differences in survival when comparing the classic with the expanded criteria, it was true that curative resection rates were lower and recurrence with need for surgery was significantly higher in the expanded criteria group [163, 164]. And so, ESGE suggests that after an en bloc R0 resection of lesions meeting the expanded criteria (particularly ulcerated, minimally submucosally invasive, or undifferentiated/diffuse carcinomas), the option of gastrectomy should be discussed with the patient and a decision made on an individual basis taking into account patient preference, co-morbidities, and information from other procedures (for example CT in the case of suspicious lymph nodes).

Another controversial issue concerns what to do when the resection was piecemeal or showed positive borders – was the resection curative or not? This question remains a challenge and there is no definitive standard for management of these patients. Indeed, it appears that even in the worse scenarios with piecemeal resection and/or clearly positive margins the risk of recurrence is still only about 10%–30%, meaning that even in these cases, about 70%–90% of the patients will be cured [165, 166]. Moreover, it appears that for most of these incomplete resections the disease is amenable to further endoscopic treatment, without the need for surgery [165, 167–169]. Several series suggest that in intramucosal cancers, the implications of a positive lateral margin are clearly distinct from those of a positive vertical margin. In one series of patients with incomplete resection after EMR, 93% of the intramucosal cancers with positive lateral margins could be managed endoscopically (surveillance or further treatment) with only 7% being submitted to surgery [128]. But even in the latter group all recurrences were dysplasia/intramucosal cancer and no lymph node had metastasis (and so the recurrences, potentially, could also have been managed endoscopically). This was in clear contrast to patients with positive vertical margins (40% having residual cancer and 10% lymph node metastasis) and with minimal submucosal invasion and piecemeal resection (7% residual cancer but 14% lymph node metastasis) [128]. These findings were confirmed in other series, leading the authors to conclude that patients with lesions with positive lateral margins, in the absence of positive vertical margins, or submucosal or lymphovascular invasion, can be managed with further

endoscopic surveillance or therapy, without the need of surgery [128, 165, 167–170]. Moreover, Japanese guidelines for gastric cancer also consider that in this subgroup of patients with incomplete resection, nonsurgical options may be proposed to these patients given the very low risk of lymph node metastasis [120].

Surveillance after curative endoscopic resection: stomach

ESGE recommends scheduled endoscopic surveillance after a curative ESD (strong recommendation, moderate quality evidence).
ESGE suggests an endoscopy after 3–6 months and then annually (strong recommendation, low quality evidence).
If the curative ESD was performed according to expanded indications (ulcerated, submucosal, or undifferentiated tumors) a staging abdominal CT can be considered (weak recommendation, low quality evidence).
After piecemeal resection or presence of positive lateral margins without meeting criteria for surgery, an endoscopy with biopsies is recommended at 3 and 9–12 months and then annually (strong recommendation, low quality evidence).

Long-term follow-up of patients after successful ESD for early gastric cancer has shown that these patients are at high risk, of around 10% to 20%, for developing synchronous or metachronous multiple gastric neoplastic lesions [133, 163, 164, 171]. A multicenter retrospective cohort study has shown that scheduled endoscopic surveillance should be recommended since it allows early identification of these lesions, making curative endoscopic treatment possible for almost all lesions [160]. In accordance with these results, Japanese guidelines also recommend annual or biannual endoscopy in all patients as well as a CT abdominal scan in the subgroup of patients treated under extended indications [120].

Although it seems clear that follow-up endoscopy is beneficial for these patients, no study has analyzed which surveillance schedule is optimal. Based on a histopathological study that analyzed biopsy samples from several time points after endoscopic resection, it appears that endoscopy sooner than 3 months after resection is of limited value since it can be difficult to differentiate between regenerative changes and recurrence [172]. For these reasons we recommend that the first endoscopy after ESD should be performed 3–6 months after ESD and then annually, similarly to the schedule in most series. If the resection was incomplete but there were no clear indications for surgery (see preceding section), we recommend a first endoscopy at 3 months followed by another endoscopy in the first year, since some studies show that most of the recurrences after incomplete resection are identified in the first year [133, 165, 167, 169, 170]. Although for resections performed under the expanded criteria it is not clear whether CT results influence further management, given the very low but existent risk of metastasis, a staging abdominal CT can be considered, as recommended by other authors and guidelines [120, 171]. In this context the value of biopsy sampling in the absence of clear endoscopic recurrence is not established. Nevertheless, given the higher risk of recurrence after piecemeal resection and/or positive margin findings, we believe that in this context biopsies should be performed [172]. In the other scenarios, whether or not to perform biopsies should be decided on an individual basis.

DUODENUM AND SMALL BOWEL

ESGE does not recommend routine use of ESD for duodenal or small-bowel lesions, because of its high risk of perforation (strong recommendation, moderate quality evidence).
Standard polypectomy and EMR or piecemeal EMR are acceptable treatments for duodenal and small-bowel superficial lesions, and have a good safety profile (strong recommendation, moderate quality evidence).
Given the lack of scientific evidence, management after endoscopic resection should be individualized, with the presence of carcinoma in the specimen, particularly with submucosal invasion, being a consideration for surgery (strong recommendation, low quality evidence).

Only a few clinical series concerning the resection of nonampullary duodenal tumors are described in the literature. Most of them involve snare-based techniques (EMR) and the superficial lesions described are mostly adenomas. Short-term outcomes are good with successful resection rates of greater than 90% [173–176]. Even though the rate of piecemeal resection is high (more than 30%), local recurrence is not very frequent and most recurrences can be managed with a further endoscopic treatment [173–176]. These techniques are considered safe with perforation rates of apparently less than 5% and rates of 10%–15% for significant bleeding; this is mostly delayed bleeding, that can be managed with endoscopic therapies. Long-term outcomes are rarely described nevertheless it appears that after a successful endoscopic resection surgery is rarely needed and no death because of cancer progression has been described [173]. However, it should be noted that most superficial duodenal lesions included in these series are adenomas with few cases of intramucosal or submucosal adenocarcinomas, and the risk of lymph node metastasis in these carcinomas is not well described in the literature. For these reasons, and taking into account that duodenal surgery generally implies a Whipple procedure with significant associated morbidity and mortality, ESGE suggests that duodenal adenomas should be resected by endoscopy when feasible. The presence of carcinoma should raise the possibility of surgery; however, if final histology is no more advanced than well-differentiated intramucosal adenocarcinoma without lymphovascular invasion, the risk of lymph node metastasis would then appear to be low and surveillance could be an option, particularly in patients with significant co-morbidities.

Some series have also described ESD for the treatment of superficial duodenal lesions [173]. Although this provided acceptable rates for en bloc resection (>70%–80%), the perforation rate was more than 30%, and some of these were delayed perforations requiring surgery [173, 177, 178]. Moreover, in a comparative study with EMR even though ESD presented higher rates for complete resection there were no differences in long-term outcomes and survival [173]. For these reasons ESGE does not recommend routine use of ESD for treatment of duodenal superficial lesions.

COLON

Efficacy in the colon

ESGE states that the majority of colonic and rectal superficial lesions can be effectively removed in a curative way by standard polypectomy and/or by EMR (strong recommendation, moderate quality evidence).
ESD can be considered for removal of colonic and rectal lesions with high suspicion of limited submucosal invasion that is based on two main criteria of depressed morphology and irregular or nongranular surface pattern, particularly if the lesions are larger than 20 mm; or ESD can be considered for colorectal lesions that otherwise cannot be optimally and radically removed by snare-based techniques (strong recommendation, moderate quality evidence).

Table 3 Outcomes of endoscopic submucosal dissection (ESD) for colorectal superficial lesions.

Study First author, year	Lesions included, n	Location (colon or rectum)	En bloc resection rate, n/N (%)	Complete R0 resec- tion rate R0 n/N (%)	Local recur- rence rate, n/N (%)	Mortality, ESD- related	Procedure- related bleeding, n/N (%)	Procedure- related perfora- tion, n/N (%)	Mean operation time, min
Repici 2012 [190] (systematic review)	2841	Both	2727/2841 (96)	2500/2841 (88%)	1/1397 ($<0.1\%$)	0	47/2841 (2%)	135/2841 (4%)	
Hisabe 2012 [192]	200	Both	172/200 (86%)	–	–	–	2/200 (1%)	14/200 (7%)	109
Takeuchi 2012 [193]	185	Both	172/185 (93%)	140/185 (76%)	6/185 (3%)	–	4/185 (2%)	3/185 ($<2\%$)	–
Lee 2013 [194]	1000	Both	973/1000 (97%)	911/1000 (91%)	3/722 ($<1\%$)	–	4/1000 ($<1\%$)	53/1000 (5%)	–
Repici 2013 [195]	40	Rectum	36/40 (90%)	32/40 (80%)	1/40 (2%)	–	2/40 (5%)	1/40 (2%)	86
Rahmi 2014 [196]	45	Rectum	29/45 (64%)	24/45 (53%)	3/45 (7%)	–	6/45 (13%)	8/45 (18%)	110

EMR is highly effective for treatment of colorectal lesions smaller than 20 mm in diameter [179] but is ineffective for en bloc resection in the majority of lesions larger than 20 mm. Piecemeal EMR for larger lesions reduces the quality and reliability of histopathologic findings, in particular the accurate assessment of lateral and vertical resection margins and may also lead to high local recurrence rates [55]. With increasing promotion and uptake of colorectal cancer screening programs internationally, it is likely that greater numbers of advanced, but not yet malignant, sessile/flat colorectal polyps will be detected [180]. Nonetheless, piecemeal EMR is still considered to be the treatment of choice for the majority of these large colorectal lesions, with recent data showing excellent early and long-term outcomes [181–183]. Indeed, EMR appears to be successful in almost 95% of these lesions, even though some patients may require multiple sessions.

When the likelihood of malignancy is high, as determined by morphologic factors such as Paris classification 0–IIa+c or 0–III, nongranular surface, and advanced surface pattern, particularly in lesions larger than 20 mm, resection should be performed en bloc using ESD in order to allow accurate pathology staging and a high chance of curative resection [184].

In the rectum, the indications for ESD may be extended for all large (>20 mm) nongranular (NG) or granular lesions, or mixed laterally spreading tumors (LSTs) (>20 – 30 mm) because of their significant risk of harboring early cancer, the complexity of the standard surgical alternative, and the relative safety compared with colonic ESD [185, 186]. ESD can also be considered for rectal lesions that have previously been subjected to several attempts at endoscopic resection and that are not suitable for further standard endoscopic treatment, even though fibrosis may significantly increase the risk of perforation [187, 188]. However, for lesions located in the rectum, video-assisted transanal surgical approaches also present good results similar to those of ESD and should be discussed as an alternative to endoscopic therapy depending on local expertise [189].

The so called “hybrid techniques” (partial/circumferential ESD followed by EMR) could be an option in certain situations; however, the evidence is still too scarce to establish clear recommendations for these techniques.

A systematic review published in 2012 has shown ESD to be an effective technique for achieving resection of large colorectal le-

sions. The paper reported a per-lesion summary estimate for endoscopically complete resection of 96% (95%CI 91%–98%) and a per-lesion summary estimate for R0 resection rate of 88% (95%CI 82%–92%), although the inter-study heterogeneity was 91%, mostly due to inclusion of carcinoid versus noncarcinoid series and Asian versus European series [190]. Data from Japanese series have also shown long-term effectiveness of this technique reporting, during a median follow-up of 38.7 months (range 12.8–104.2), 3- and 5-year overall/disease-specific survivals of 97.1%/100% and 95.3%/100%, respectively [191]. **Table 3** [190, 192–196] summarizes the outcomes for colon and rectum ESD. In general, most superficial colonic lesions are benign and can be removed safely and efficaciously by standard polypectomy and EMR. ESGE recognizes that ESD is better than EMR for en bloc R0 resection of colonic superficial lesions larger than 20 mm; however, this benefit may be clinically significant in only a small number of lesions. Moreover, colonic ESD is technically difficult and, particularly in Western countries, few endoscopists have sufficient experience to achieve the results described in the literature. Furthermore, in lesions that are more suitable for ESD rather than EMR (IIa+c, IIc, III, non-lifting lesions, or nongranular LST [LST-NG] >20 mm), surgery is currently the gold standard of treatment with no study showing that ESD has better outcomes than surgery. The only exception might be in the rectum where the complexity of the traditional surgical approach with a higher risk of poor functional outcomes and the risk of abdominoperineal amputation might prompt ESD instead of surgery. However, even in these cases a surgical transanal approach is an option. It is ESGE's opinion that before ESD acquires an established role in the resection of colorectal superficial lesions, futures studies should compare ESD versus surgical approaches in the resection of lesions with suspicion of submucosal malignancy.

Safety: colon

The Colorectal Endoscopic Resection Standardization Implementation Working Group in Japan reported the details and results of a nationwide questionnaire survey on the situation of colorectal ESD in Japan [197]. They analyzed colorectal ESD performed from January 2000 to September 2008. The survey reported an overall incidence of perforation of 4.8%. Reported rates from other series

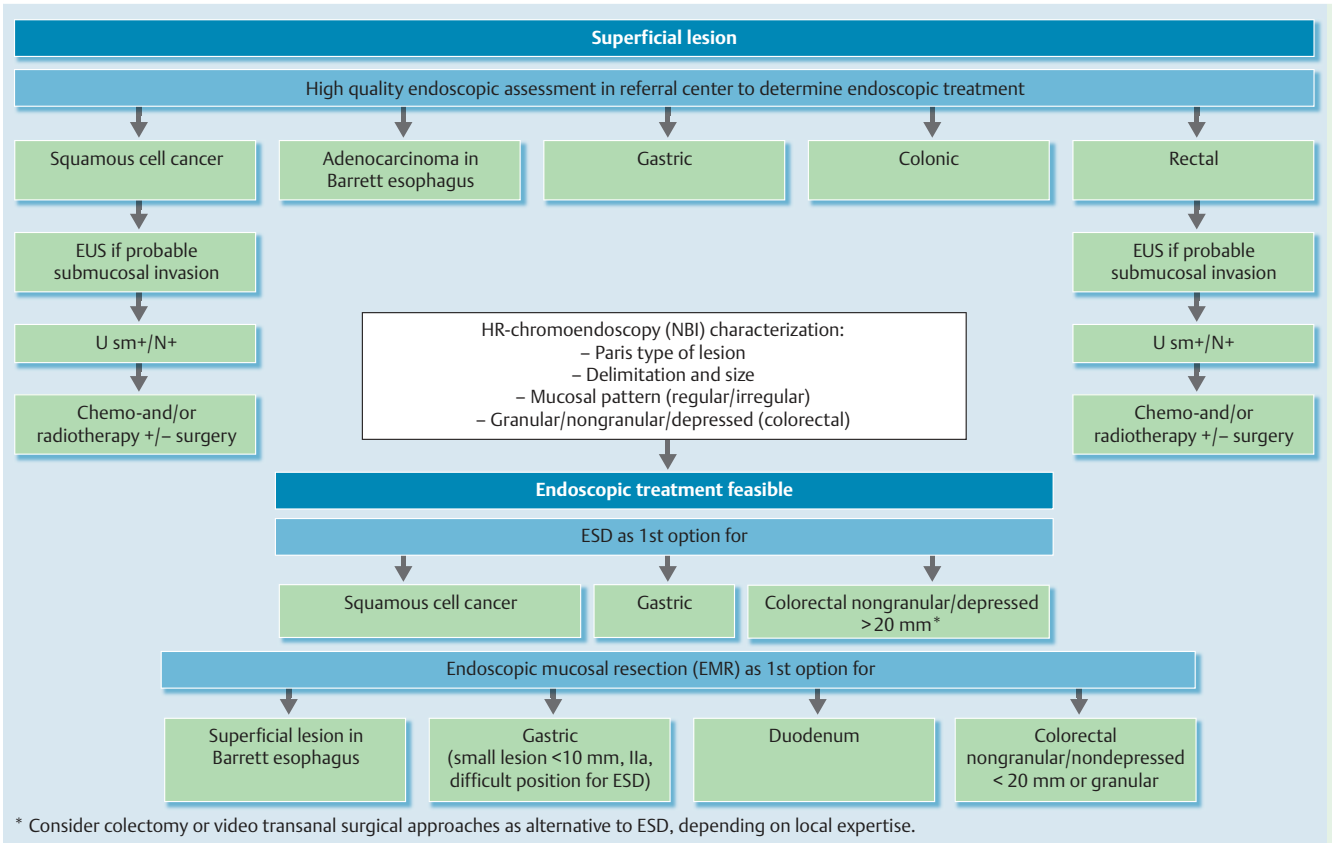


Fig. 1 Endoscopic submucosal dissection (ESD) for superficial lesions: a decision-making algorithm. EUS, endoscopic ultrasound; U sm+/N+, ultrasound suggestive of submucosal invasion or positive lymph nodes.

	VM0			VM1
En bloc HM0	R0			R1
	No submucosal invasion	< Cutoff*, L0 & V0, Well moderately differentiated	> Cutoff*, or L1 or V1, or Poorly differentiated	
	Low-risk resection (endoscopic follow-up is enough)		High risk resection (i. e. surgery +/- adjuvant treatment recommended)	High risk resection (i. e. surgery +/- adjuvant treatment recommended)
En bloc HM1c En bloc HM1d Piecemeal	RX			R1
	Local-risk resection (endoscopic follow-up and putative therapy may be possible)		High risk resection (i. e. surgery +/- adjuvant treatment recommended)	High risk resection (i. e. surgery +/- adjuvant treatment recommended)

Notation: VM, vertical margin; HM, horizontal margin; R, resection; L, lymphatic invasion; V, vascular invasion; c, carcinoma; d, dysplasia

Fig. 2 Pathological criteria for determining whether to consider the resection as low risk, local risk (risk of local recurrence), or high risk (to be adjusted according to organ and size if required). * Cutoff will differ: SCC ≤ 200 μm, Barrett's or gastric adenocarcinoma ≤ 500 μm and colorectal adenocarcinoma ≤ 1000 μm

range from 4% to 10%, higher compared with that of EMR (0.3–0.5%). A systematic review published in 2012 showed an adequate safety profile for colorectal ESD [190]. The risk of post-ESD complication-related surgery (1%) was reported to be negligible compared with the high efficacy of this procedure. Compared with EMR, ESD has been associated with higher risk of both bleeding and perforation. However, the safety profile of the procedure may still be considered adequate, as almost all ESD complications can be managed endoscopically. In that paper, a cumulative risk of 6%

for bleeding and perforation was reduced to a 1% risk for complication-related surgery because of the efficacy of endoscopic treatment of ESD-related complications. Furthermore, nearly half of the lesions treated by ESD were located in the rectum, where, because of the extraperitoneal location of two-thirds of the rectum, most perforations are usually treated conservatively, minimizing the clinical impact of the complication. Delayed bleeding has been reported in up to 13.9% of patients [198]. If delayed bleeding occurs, it can be treated with standard endoscopic techniques, preferably using clips in order to avoid

further thermal injury to the muscular layer. Of note is that the rates of adverse events associated with ESD appear to be higher in centers with low experience. In the largest prospective multicenter study of ESD for colorectal lesions, the number of perforations was 12% in the center with fewer than 50 ESDs performed compared with 4%–5% at the other centers with greater experience [199].

Evaluation before endoscopic resection: colon

ESGE recommends the use of high definition endoscopy and chromoendoscopy (contrast or digital), in order to establish the feasibility of endoscopic resection and to verify indications for en bloc resection with ESD (strong recommendation, moderate quality evidence).

Staging with either EUS and/or MRI can be considered for rectal lesions with endoscopic features suspicious for submucosal invasion (weak recommendation, low quality evidence).

The Paris classification [86] and the typing of LST lesions as proposed by Kudo et al. [200] should be applied to the description of the lesion since the risk of submucosal invasion varies according to the macroscopic features of the lesion. Chromoendoscopy is a validated technique for analysis of the morphologic architecture of colonic mucosal crypt orifices (surface pattern). In detail, determination of the V pit pattern can predict the depth of invasion of submucosal cancers. Kato et al. [201] and Bianco et al. [202] have shown the accuracy of chromoendoscopy for diagnosing pit pattern V to be 85% and 79%, respectively. In a study of 4215 lesions, Matsuda et al. [203] have reported the sensitivity of the pit pattern for determining the depth of invasion of polypoid, flat, and depressed lesions to be 75.8%, 85.7%, and 98.6%, respectively, confirming magnifying chromoendoscopy as a highly effective method for predicting depth of invasion by colorectal neoplasms. Hayashi et al. also showed that NBI patterns can be used to predict submucosal invasion in colonic lesions [204, 205]. These considerations are important since they may favor ESD or surgery rather than EMR.

According to a recent European prospective randomized study, EUS and MRI have similar accuracy in T and N staging for rectal cancer [206]. The presence of stenosis and polypoid morphology is inversely associated with accuracy for either EUS or MRI. Use of one of these methods is recommended for staging of rectal cancer, but not for colon cancer. However, regarding superficial lesions the roles of neither EUS nor MRI have been established.

The use of high frequency EUS has been shown to be useful in determining invasion depth of colorectal lesions. Hurlstone et al. compared high frequency EUS versus magnifying chromoendoscopy and found that high frequency EUS was superior to chromoendoscopy in determining the depth of invasion, showing an accuracy of 93% versus 59% ($P < 0.0001$) [207]. More recently a systematic review and meta-analysis by Gall et al. [208] has confirmed high frequency EUS, by means of miniprobe, as an highly effective procedure for assigning clinical stage in colon cancer and identifying patients who may be suitable for nonsurgical treatment. However, for superficial lesions only (distinguishing T1a from T1b) this accuracy might be lower. Urban et al. have shown that high frequency EUS only has a positive clinical impact in lesions with high risk features [209]. Moreover, this technique is not available in most centers and has the risk of directing to surgery some patients who could have been treated by endoscopic resection. Endoscopic resection will always be the best staging tool and for this reason, if the endoscopist feels the lesion is endoscopically resectable, probably there is no need for EUS. In

rectal lesions with endoscopic features suspicious for submucosal invasion EUS or MRI could be considered, since the finding of suspicious lymph nodes could be an indication for neoadjuvant treatment.

Management according to technical and histological outcomes: colon

ESGE recommends that:

- An en bloc R0 resection of a superficial lesion with histology no more advanced than well-differentiated adenocarcinoma (G1/G2), sm1 (≤ 1 mm submucosal invasion) with no lymphovascular invasion is considered curative (strong recommendation, moderate quality evidence).
- Surgery is recommended when lymphovascular invasion, deeper infiltration than sm1, positive/nonevaluable vertical margins, or poorly differentiated tumor with submucosal invasion is diagnosed (strong recommendation, moderate quality evidence).
- If the horizontal margin is positive, but no other high risk criteria are met, endoscopic surveillance/re-treatment could be considered instead of surgery (strong recommendation, moderate quality evidence).

Technical success is considered to be removal of the target lesion in a single piece (en bloc) with macroscopic evidence of complete lesion removal. Resection is considered complete (defined as R0) when the tumor is removed en bloc with tumor-free lateral and vertical margins. Resection is considered incomplete when tumors are removed piecemeal, or when lateral or vertical margins are positive for tumor invasion (defined as R1), or when the margins are not evaluable because of artificial burn effects or because of insufficient reconstruction of the piecemeal fragments (defined as RX).

In the colon, intramucosal carcinomas have no potential for lymph node metastasis and so en bloc R0 resection of intramucosal carcinoma of any size should be considered to be a curative resection. By the same principle, positive margins in these cases are not an indication for surgery and should prompt endoscopic surveillance or further endoscopic treatment.

In the case of a malignant lesion (invasion into the submucosa) several features should be taken into account. The first is the morphology of the polyp. In a pedunculated polyp, the Haggitt classification should be applied [210, 211]. In this case, the depth of invasion in millimeters is not important, and the criteria for surgery are only Haggitt level 4 (invasion into the submucosa of the colonic wall and not the stalk) or positive vertical margins [210, 211]. For a sessile/flat lesion, depth of invasion is an important factor since the risk of lymph node metastasis appears significant only in lesions with > 1 mm submucosal invasion [212]. Presence of lymphovascular invasion or poor differentiation of the tumor are associated with increased risk of lymph node metastasis, independently of the depth or morphology of the tumor, and are an indication for surgery [212].

Resection margins are another controversial aspect. Lateral margins alone have not been extensively studied. However, positive lateral margins are probably only a risk factor for local recurrence. Most of the time recurrence at an adenoma-positive margin will be adenoma and not cancer which can be treated at follow-up endoscopy. So it is the ESGE panel's opinion that, in the absence of other risk factors, a positive or nonevaluable lateral margin should prompt endoscopic reassessment instead of surgery. Piecemeal resection or positive lateral margin for carcinoma probably is another scenario and in these cases surgery must be considered on an individual basis. Future studies should evaluate these aspects. A positive vertical margin has different significance and it is an indication for surgery [212]. Nonetheless, controversy exists regarding what should be considered a positive

vertical margin. Some consider the margin to be clear if there is no tumor at the edge of the resection specimen, but others require a tumor-free specimen margin of more than 2 mm. Butte et al. showed that none of the patients with a tumor-free margin > 1 mm had residual invasive disease [213]. However, in patients with indeterminate margins or less than 1 mm free margins the rate of recurrence was 15%–20% [213]. This might be related to tumor budding, another recently proposed prognostic factor [214,215]. Tumor budding is defined by the presence of clusters of isolated tumor cells ahead of the invasive front. Hence the margin may be free of tumor while other tumor cell clusters may remain in the bowel wall. Taking these considerations into account, the ESGE panel suggests that if the endoscopist feels the resection was complete, and in the absence of tumor budding, when there is no tumor at the edge of the specimen the resection may be considered to be R0. On the other hand if there is any kind of tumor budding, at least 1 mm of tumor-free margin should be required for resection to be considered complete while margins with less than 1 mm tumor-free are considered to be nonevaluable. Future studies should evaluate these issues in order to establish conclusive recommendations.

Finally, in the cases of invasive carcinoma with massive submucosal invasion (> 1000 µm below the muscularis mucosae), undifferentiated adenocarcinoma, positive or nonevaluable vertical margins, and/or lymphovascular infiltration by cancer cells, additional surgical intervention with removal of regional lymph nodes should be recommended [212,215].

Surveillance after curative endoscopic resection: colon

ESGE recommends endoscopic surveillance 3–6 months after the index treatment. If this shows no recurrence, a follow-up total colonoscopy should be done 1 year after that surveillance (strong recommendation, moderate quality evidence). After piecemeal resection or with presence of positive lateral margins without indication for surgery, colonoscopy with biopsies at 3 months is recommended (low quality evidence).

All the retrospective studies evaluating the issue of outcomes have shown that ESD is associated with lower local recurrence rates, ranging from 0% to 3%, as compared with EMR, whose local recurrence rates vary from 0% to 9.1% for en bloc resections, and from 10% to 23.5% following piecemeal procedures [55, 190].

Despite this, there is no clear evidence to inform decisions on optimal post-ESD surveillance. Hence, most authors recommend follow-up endoscopy 3 to 6 months after resection in order to verify complete removal based on both endoscopic and pathological assessments. If technical success is confirmed, total colonoscopy at 1 year after this reassessment is suggested, to check for local recurrence or secondary primary tumors before returning to standard surveillance intervals.

• **Fig. 1** provides an algorithm for decision-making and • **Fig. 2** synthesizes recommendations based on pathological evaluation of the resection specimen.

ESGE guidelines represent a consensus of best practice based on the available evidence at the time of preparation. They may not apply in all situations and should be interpreted in the light of specific clinical situations and resource availability. Further controlled clinical studies may be needed to clarify aspects of these statements, and revision may be necessary as new data appear. Clinical consideration may justify a course of action at variance to these recommendations. ESGE guidelines are intended to be an educational device to provide information that may assist endoscopists in providing care to patients. They are not rules and should not be construed as establishing a legal standard of care or as encouraging, advocating, requiring, or discouraging any particular treatment.

Appendix 1 Endoscopic submucosal dissection (ESD): ESGE Guideline. Key questions for each of the Guideline task forces



Task forces and key questions
Task force 1: Esophagus
1 What are the clinical indications (if any) for ESD in the esophagus?
a Squamous cancer
b HGD/early adenocarcinoma
c Other (GIST, etc)
2 What is the available evidence on the efficacy/safety of ESD for each of these indications?
3 How does such efficacy/safety compare with that of competing techniques or surgery for each of these indications?
4 What pre-ESD staging is needed (EUS, CT, chromoendoscopy, etc.)?
5 What is the management for ESD complications?
6 What is the post-ESD management according to technical and histological outcomes?
7 What is the post-ESD surveillance according to technical and histological outcomes?
8 How far can this evidence be extended to Western endoscopy?
9 What future research is needed for each indication?
Task force 2: Stomach
1 What are the clinical indications (if any) for ESD in the stomach?
a HGD/early adenocarcinoma
b Other (GIST, NET, etc.)
2 What is the available evidence on the efficacy/safety of ESD for each of these indications?
3 How does such efficacy/safety compare with that of competing techniques or surgery for each of these indications?
4 What pre-ESD staging is needed (EUS, CT, chromoendoscopy, etc.)?
5 How to manage the pathological sample?
6 What should be indicated in the pathological report?
7 What is the management of ESD complications?
8 What is the post-ESD management according to technical and histological outcomes?
9 What is the post-ESD surveillance according to technical and histological outcomes?
10 How far can this evidence be extended to Western endoscopy?
11 What future research is needed for each indication?
Task force 3: Colorectum
1 What are the clinical indications (if any) for ESD in the colon and in the rectum?
a LST
b NET
c Polypoid lesions with suspicious findings
d Scar from previous polypectomy
e Others
2 What is the available evidence on the efficacy/safety of ESD for each of these indications?
3 How does such efficacy/safety compare with that of competing techniques or surgery for each of these indications (including EMR/TEM)?
4 What pre-ESD staging is needed (EUS, CT, chromoendoscopy, etc.)?
5 What is the management of ESD complications?
6 What is the post-ESD management according to technical and histological outcomes?
7 What is the post-ESD surveillance according to technical and histological outcomes?
8 How far can this evidence be extended to Western endoscopy?
9 What future research is needed for each indication?

Task forces and key questions

Task force 4: Training

- 1 What is the training required for ESD?
- 2 What might be possible quality indicators?

Task force 5: Pathology

- 1 How to manage the post-ESD pathological sample?
- 2 What should be indicated in the ESD pathological report?

Appendix 2 Pathology and definitions



These recommendations are valid for the entire gastrointestinal tract.

Note. The terms “dysplasia” and “intraepithelial neoplasia” can be used synonymously. In this report however the term “dysplasia” is used.

How to manage the post-endoscopic resection pathological sample?

Tissue derived from endoscopic resections should be pinned on cork or thick paper to avoid shrinkage artifacts. Needles should not stretch the specimen but pin it down very loosely. If the gastroenterologist feels that accurate orientation is necessary, latex colors can be applied to mark the edges to allow orientation of the specimen. Alternatively, colored needles can be used. Needle placement through a suspected lesion or too close to the edges of the specimen should be avoided, as this may hamper proper examination of lesions as well as of resection lines. Circular en bloc resections can be placed over a syringe before fixation for best results.

The specimen should then be placed overnight in 4% neutral buffered formalin. The specimens should completely be covered by formalin. It is important that vials are the correct size and contain enough formalin.

What should be included in the endoscopic resection pathological report?

The histopathological diagnosis of an endoscopic resection specimen is the basis for the clinical decision on whether the endoscopic resection has been curative or whether the patient needs to undergo surgical resection. Thus, the report on the specimen needs to include all the relevant information needed to make that decision. This information varies throughout the gastrointestinal tract, because of location, type of epithelium, different staging modalities, and tumor aggressiveness. For all neoplasms, however, the following risk factors have to be reported: lymphatic vessel permeation, blood vessel permeation, budding (mandatory due to different staging systems and lacking worldwide acceptance, often graded 0–3), perineural invasion, resection margin involvement (HM = horizontal margin, VM = vertical margin), as well as typing and grading of neoplasia according to the WHO classification. Perineural invasion is, however, mainly identified in deeply invasive carcinomas and its presence should not be expected in early cancers. Information on the distance towards the basal margin (in micrometers) should be included in every report.

Notably, the WHO classification refers to mucosal carcinomas only in the upper gastrointestinal tract and the anal canal. In the colorectum, only tumors that have penetrated through the mus-

cularis mucosae are considered malignant (invasive). A diagnosis of carcinoma in situ should only be made for lesions originating from squamous epithelium. In contrast to the American Joint Committee on Cancer/Union for International Cancer Control (AJCC/UICC) TNM system, the term “carcinoma in situ” therefore should be avoided for lesions originating from columnar epithelium, as the criteria for diagnosis have not been fully established and differentiation from high grade dysplasia is infeasible.

Esophagus

In the esophagus two different types of epithelium may give rise to two different forms of neoplasia: squamous cell neoplasia and neoplasia of columnar epithelium (Barrett's).

Squamous cell neoplasia appears to be more aggressive than Barrett's neoplasia. Furthermore, squamous cell neoplasia tends to show “lateral spread” along the basal cell layer. About two thirds of cases show this type of lateral cancer spread, extending 2 mm or more with overlying completely normal squamous epithelium. Endoscopic detection of lateral cancer spread is extremely difficult. Its clinical relevance is still unknown but the finding should be reported.

The report of squamous cell neoplasia should include grading of neoplasia, e.g. low grade dysplasia, high grade dysplasia, carcinoma in situ, invasive squamous cell carcinoma. Information on keratinization is optional. In the case of verrucous carcinoma this should be stated explicitly since verrucous carcinomas do not metastasize in general. In invasive carcinomas information on the depth of infiltration is mandatory. Depth should be classified according to the Japanese guidelines on esophageal cancer, and subdivided into m1 (=carcinoma in situ), m2 (=microinvasive carcinoma into the tunica propria), and m3 (=invasion into muscularis mucosae). Depth of submucosal invasion should be classified as invasion into the upper third (sm1), middle third (sm2), or lower third (sm3). A correct estimation of thirds of submucosal invasion can only be made on surgical specimens and cannot be made on endoscopic resections. Alternatively, the maximum depth of submucosal invasion (in micrometers [microns, μm]) can be measured. In this setting, sm1 invasion is restricted to cancer invasion at equal to or less than 200 micrometers ($\leq 200 \mu\text{m}$).

Barrett's neoplasia is also subdivided into low grade dysplasia, high grade dysplasia, and carcinoma. Because of the double muscularis mucosae, two different classification systems are available to substage depth of infiltration following the anatomical structures (those of Westerterp et al. [216] and of Vieth et al. [217]). However, this discrepancy appears to be largely irrelevant, as the clinical impact of tumor substaging is limited in mucosal carcinomas. Hence, substaging of mucosal cancers cannot be regarded as mandatory, while invasion depth of submucosal tumors should be subdivided into thirds as described above (sm1 – sm3). When the maximum depth of submucosal invasion is measured (in micrometers), the limit for sm1 in Barrett's carcinoma is to be seen at equal to or less than 500 micrometers ($\leq 500 \mu\text{m}$) measured from the bottom fibre of the muscularis mucosae downwards. Probably early and focal submucosal invasion represents a prognosis comparable to that of mucosal carcinoma [74].

Stomach

Neoplasms of the stomach are subdivided into low grade dysplasia, high grade dysplasia, and carcinoma. Carcinoma is subdivided into mucosal carcinoma (m-type) and submucosal carcinoma

(sm1 – sm3). The limit for sm1 is given as equal to or less than 500 micrometers ($\leq 500 \mu\text{m}$). The report should type the carcinomas according to the WHO classification and according to the Laurén classification (intestinal type, diffuse type, and mixed type). Information on pathological findings in the adjacent non-neoplastic gastric mucosa (e.g. gastritis status) should be provided.

Duodenum/small bowel

For the small bowel there are no clear recommendations in the literature that are distinct from those for the stomach, probably because of the small number of primary small-bowel carcinomas. Therefore, probably, the same rules as those for grading and evaluating depth of infiltration in the stomach apply. That means there is the possibility of mucosal carcinoma of the small bowel (m-type) and the upper third of the submucosa is defined as equal to or less than 500 micrometers ($\leq 500 \mu\text{m}$). Special attention should be paid at the papilla since adenomas here can show an invasive component in the depth of the pancreatic duct. Special attention should be also paid for papillary lesions on the basis that a main-duct type of intraductal papillary mucinous neoplasia (IPMN) of the pancreas can sometimes protrude into the lumen of the small bowel.

Large bowel

Neoplasms of the colorectum are subdivided into low grade dysplasia, high grade dysplasia, and carcinoma. As already pointed out above, carcinomas at this site have penetrated through the muscularis mucosae and they are subdivided into sm1 – sm3, accordingly. In sessile lesions, depth of infiltration should additionally be measured (in micrometers from the muscularis mucosae), and the limit for sm1 has to be defined as equal to or less than 1000 micrometers ($\leq 1000 \mu\text{m}$). In pedunculated lesions, the stalk always represents the upper third of the submucosal layer. For prognostic stratification of depth of submucosal invasion in pedunculated lesions, the Haggitt levels should be mentioned in the pathology report.

Despite the lack of standardization in its evaluation, tumor cell budding appears to be a promising marker for tumor aggressiveness, particularly in colorectal cancers, and should be included in the report. Special tumor types, such as medullary or micropapillary carcinoma, have been identified and should be reported. Immunohistochemistry may be helpful in differential diagnosis and may also be applied to identify patients with Lynch syndrome (hereditary nonpolyposis colorectal cancer [HNPCC]) [218]. All carcinomas must be classified according to the AJCC/UICC TNM system.

ESGE recommendations for mandatory data to be shown in the conclusion of endoscopic/pathology reports

Before ESD

- ▶ Exact location [organ, distance, position]
- ▶ Paris classification
- ▶ Ulceration (Y/N)
- ▶ Size [mm]
- ▶ Inclusion of images is mandatory, preferably within the endoscopic report

Examples:

Esophagus, 25 cm from incisors, IIc, ulc –, 15 mm

Stomach, distal lesser curvature, IIc + a, ulc –, 30 mm

Colon, rectum, granular LST, 30 mm

ESD

- ▶ Exact location
- ▶ Paris classification
- ▶ Ulceration (Y/N)
- ▶ Size [mm]
- ▶ En bloc versus piecemeal
- ▶ Inclusion of images is mandatory, preferably within the endoscopic report

Examples:

Esophagus, 25 cm from incisors, IIc, ulc –, 15 mm

Stomach, distal lesser curvature, IIc+a, ulc –, 30 mm, en bloc

Colon, rectum, granular LST, 30 mm, piecemeal

Pathology

- ▶ Maximal histology observed *and* differentiation if applicable [well/moderate versus poorly]
- ▶ Size [mm] [we recommend to include HGD in the complete measurement; and this size will determine the attitude]
- ▶ Horizontal margin [negative if no neoplasia is present in at least 1 mm, HM0; positive for carcinoma, HM1c, or dysplasia, HM1d]
- ▶ Vertical margin [negative, VM0 (preferably > 1 mm) or positive, VM1; only applicable for carcinoma]
- ▶ Maximum depth of invasion sm [taken from the lowest fiber of the muscularis mucosae; in Barrett's be aware of duplicated muscularis mucosae]
- ▶ Lymphatic and/or venous infiltration [L0, L1; V0, V1]
- ▶ Complete resection or not [R0, RX, R1]
 - ▶ R0 (complete), if en bloc, and horizontal and vertical margins negative (HM0 & VM0)
 - ▶ RX (non-assessable), if en bloc or piecemeal, and horizontal margin positive (HM1) and vertical margin negative (VM0)
 - ▶ R1, if vertical margin positive (VM1)

Examples:

Well-differentiated carcinoma, 30 mm, HM0, VM0, R0

Well-differentiated carcinoma, 20 mm, HM1d, VM0, sm 450 µm, L0, V0, Rx

Poorly differentiated carcinoma, 15 mm, HM0, VM0, R0

Tumor budding

Tumor budding or tumor cell dissociation is poorly reproducible and there can be no clear recommendation can be given at present on this feature. In experienced hands a prognostic relevance has been reported.

Multidisciplinary recommendation

ESGE recommends that patients are seen in multidisciplinary teams, with the following recommendations based on endoscopic and pathology reports.

Low risk resection (i.e., low risk for local or distant recurrence; no further immediate therapy is required) is defined as:

- ▶ R0, and no poor prognosis features < cutoff invasion, and L0 and V0

High risk resection (i.e., high risk for distant recurrence; further measures are required; case-by-case follow-up): is defined as:

- ▶ R0 or RX but at least one poor prognosis feature; or R1

Local risk resection (i.e., with risk for local recurrence) is defined as:

- ▶ RX and no poor prognosis features for distant metastasis

See **Fig. 2**.

Appendix 3 Training in endoscopic submucosal dissection

Endoscopic submucosal dissection (ESD) has been developed as a less invasive alternative to surgery. It is a complex time-consuming procedure associated with a high complication rate, and requires systematic training under the supervision of an expert endoscopist. Inexperience in ESD might not only be associated with higher risk for procedure-related complications, but also with the risk of incomplete resection [219]. For these reasons ESD has been restricted to tertiary referral centers, although a multicenter retrospective questionnaire study showed that outcomes of ESD for early gastric neoplasms at low volume centers were as good as those at high volume centers [33,220].

Farhat et al. reported that with increased endoscopist experience the duration of ESD diminished significantly for the same relative size of lesions. A statistically significant difference in the complication rate was noted for centers with the highest number of ESDs [40]. ESD has gained widespread use in Asia, but not yet in the West, where the main obstacles remain the very flat learning curve and the lack of training resources. In Japan, endoscopic resection is widely performed and training in ESD follows the traditional mentor/apprentice approach over a period of few years. In the West there are not enough sufficient experts and high case volumes to support this approach [221,222].

Therefore, doing ESD under direct expert supervision is not feasible and the very few cases of early gastric cancer do not provide sufficient opportunities for trainees to begin their experience with ESD in easier locations, such as the gastric antrum [223]. Japanese experts recommend performing ESD on gastric lesions first, as these are technically easier to remove. The curative en bloc resection rate was shown to be significantly higher for the lower part of the stomach compared with the middle and upper parts (upper vs. middle vs. lower, 74% vs. 77% vs. 91%; $P < 0.05$), as well as for smaller lesions (> 20 mm vs. 20 mm or less, 59% vs. 89%; $P < 0.0001$). Moreover, the procedure times and perforation rates were shown to be significantly lower in the lower part of the stomach compared with the middle and the upper parts [223].

Once expertise is reached in these locations, endoscopists in training may move to the proximal stomach and finally to the colon and esophagus [42]. Esophageal ESD is considered technically more challenging than gastric or rectal ESD (because the esophageal wall is thinner, luminal space is limited, it is usually not possible to work in retroflexed view, and heartbeat or respiratory movement sometimes impairs the stability needed for submucosal dissection), and it should be attempted only after experience in gastric ESD [30].

In Japan, several reports have analyzed the learning curve for ESD in the stomach. A level of expertise ranging from 30 to 40 performances of gastric ESD has been considered proficient, and the procedural outcomes of ESD done by preceptees who have experience in over 80 cases are similar to those of expert endoscopists [224–226]. Some studies suggest performing at least 20–40 ESDs in the lower part of the stomach before starting ESD in the proximal stomach, esophagus, and colon. The learning curve for colonic ESD requires performance of at least 40 procedures to acquire the necessary skill to avoid complications and of 80 procedures to remove large colorectal tumors [220]. ESGE supports the necessity and benefit of ESD training using animal models before performance in human patients [47].

More recently, Kato et al. suggest the use of an ex vivo porcine model to lead to a significant improvement in safety and efficiency in performing the ESD technique, this model being cheaper than live pigs. The learning curve in an ex vivo porcine model requires 30 ESD gastric resections [227].

Nevertheless, it is advisable to gain experience in the live pig, with conditions that are similar to those in humans, before moving on to actual patients [228].

An ESD training algorithm for Western endoscopists has been proposed [41], that should include:

- ▶ ESD training offered to endoscopists already skilled in therapeutic endoscopy, particularly EMR
- ▶ Knowledge about technique, instrumentation, and electrosurgical equipment, acquired by self-study and later reinforced by visiting centers with high volumes of ESD
- ▶ Practice on animal models (explanted animal organs and live animal models)
- ▶ Observing experts performing ESD, for a relatively short period (4–5 weeks) in tertiary referral centers
- ▶ Attendance at ESD workshops providing hands-on exposure and expert guidance
- ▶ Commencing performance of ESD in humans on carefully selected lesions. Since early gastric cancer is rare in the West, smaller (20–30 mm) rectal laterally spreading tumors can serve as entry point to human ESD

Coda et al. [41] report that at least 30 procedures should be carefully observed for each location; at least 10 ESDs should be performed on animal models before starting with patients (stomach only), and experts should supervise at least 3 initial procedures. Colonic ESD should be performed in the lower rectum first; ESD in the right colon should be attempted only after adequate experience has been gained. Initial experience should be gained at specialized centers. Caution is mandatory, and tight cooperation with a surgical team is advisable.

ESD is a complex procedure that requires considerable endoscopic skills and has relatively high potential for serious adverse events. Moreover ESD for colorectal lesions is even more technically demanding than gastric ESD, thus requiring a higher degree of expertise. The decision-making process for the colon is more difficult than for gastric lesions and must consider more diagnostic items and different therapeutic alternatives. Therefore, dedicated physician training appears to be essential to achieve positive outcomes. In Asian countries, where lesions suitable for ESD are more prevalent mainly in the stomach, there are many medical institutions (i.e., in Japan) providing training in a traditional stepwise approach. This approach has not always been applicable in Western countries, where there has been a lack of widespread official training programs, so that resection rates have not been as high as those from Japanese studies, although a clear learning curve has been shown. Nevertheless, the recent efforts made by Western institutions to organize specific training programs and to produce guidelines permit an expectation that differences with the Eastern world should disappear.

How far can this evidence be extended to Western endoscopic practice?

- ▶ ESD has disseminated slowly in Western countries because it is technically demanding.
- ▶ ESD should be initially restricted to a limited number of institutions and it is essential that endoscopists who wish to perform ESD should complete an adequate training program, fol-

lowing the recommendations issued by Eastern and Western experts.

- ▶ Western ESD series present similar results to Eastern ones, with the exception of colorectal ESD where the rates of complete resection are lower and complication rates are higher. For these reasons, colonic ESD should only be attempted by endoscopists with expertise in stomach and esophageal ESD and after significant training in animals.
- ▶ ESGE supports the full extension of the current guidelines to Western endoscopic practice. ESGE would not expect significant differences from the Eastern world in terms of indications and outcomes of gastrointestinal ESD provided that specific training programs and dedicated guidelines are strictly adhered to in Western countries.
- ▶ After proper training and in referral centers ESD can be considered as a first-line treatment for gastrointestinal superficial neoplastic lesions in Western countries also.
- ▶ Centers performing ESD should keep records on all referred patients, and for those who finally undergo ESD, records should be kept on rates of en bloc and R0 resections, on adverse events rates, and on follow-up.

Even though in Eastern countries EMR and ESD are considered the standard and first-line therapies for several superficial gastrointestinal neoplastic lesions, presenting similar efficacy and survival with a potentially better safety profile when compared with surgery [120,229], according to Western guidelines, treatment of these lesions, even for initial stages such as high grade intraepithelial neoplasia, generally involves surgery [155]. The problem is that ESD is a technically difficult procedure requiring a high level of endoscopic training and skills and so, in Western countries with a relatively low incidence of early gastric cancer, considered the ideal lesion for beginning ESD, opportunities for proper training are scarce [57,117,230–232].

For these reasons only a few Western ESD series from a small number of centers have been described in the literature. Globally, evaluating according to organ, in these Western referral centers ESD for esophageal and gastric lesions appears to have results similar to those of Eastern series.

For the esophagus, only a few series with few cases are described in the literature. Long-term outcomes are rarely described. Nevertheless, all the authors have concluded that esophageal ESD is feasible, and rates of complete resection and complications were not significantly different from Eastern series [16,24,28,33,38,40].

For the stomach the scenario is similar. Again, only a few Western series from a small number of centers have been described in the literature [41,133,156,233–236]. Long-term outcomes after endoscopic resection of gastric neoplasias are rarely described [133,156,236]. In the Western series with the longest follow-up, that described long-term outcomes following endoscopic resection of gastric superficial lesions [133], rates of en bloc and R0 resection were comparable to those in Eastern meta-analyses of ESD (en bloc rate of 94% vs. 92% in Eastern series, and R0 rate of 91% vs. 82%) [118,119]. Recurrence rates were also comparable (4% vs. 1% in Eastern series) [118,119,133]. The rates of long-term curative resection in this series, of 86% after one procedure and 91% after two procedures, are also remarkable results. Regarding safety, once more the results were comparable to Eastern series, with similar rates of bleeding (8% vs 9%) and of perforation (1% vs. 4%). In fact, the perforation rate of 1% in the ESD group, without need of surgery, was remarkable and better than most Eastern ESD series [118,119,133].

However, colorectal ESD in Western series described in the literature presents lower rates of complete resection and higher complication rates. Indeed, a multi-institutional report in France showed that ESD (several organs considered) was associated with lower rates of complete resection (73%) and higher rates of perforation (18%) [40]. Probst et al. also achieved lower rates of complete resection (69%) but with similar complications, even though only rectosigmoid lesions were included [237]. A small series in Sweden also achieved lower rates of complete resection (69%) with a 7% perforation rate [238]. A recent series in France, involving 49 patients and only rectal lesions, achieved even worse results with only a 53% complete resection rate and an immediate perforation rate of 18% [196]. Others have achieved results similar to those of Eastern series, suggesting that with proper training and in referral centers it is possible to obtain good results in Western countries also [239–242]. It should be noted that even in Eastern centers the complication rate for colorectal ESD is higher in centers with low experience: in the largest prospective multicenter study of ESD for colorectal lesions, the number of perforations was 12% in the center with fewer than 50 ESDs compared with 4%–5% on the other centers with greater experience [199].

Taking all these points together, it appears that in referral centers and after proper training, as recommended by ESGE [42], ESD is highly efficacious for the treatment of gastrointestinal superficial neoplasias in Western countries also.

Competing interests: None

Institutions

- ¹ Department of Gastroenterology, Instituto Portugues de Oncologia, Porto, Portugal
- ² Department of Digestive Diseases, Hôpital Edouard Herriot, Lyon, France
- ³ Department of Gastroenterology, Istituto Clinico Humanitas, Milan, Italy
- ⁴ Institute for Pathology, Klinikum Bayreuth, Bayreuth, Germany
- ⁵ Department of Gastroenterology, National Cancer Institute, Bari, Italy
- ⁶ Gastroenterology Unit, Ospedale Valduce, Como, Italy
- ⁷ University Clinic of Internal Medicine I, Salzburg, Austria
- ⁸ Department of Gastroenterology, Queen Alexandra Hospital, Portsmouth, UK
- ⁹ Pomeranian Medical University, Szczecin, Poland
- ¹⁰ Department Gastroenterology and Endoscopy, Ospedale di Sanremo, Sanremo, Italy
- ¹¹ Erasmus Medical Center, Rotterdam, The Netherlands
- ¹² Institute of Pathology, Medizinische Universität Graz, Graz, Austria
- ¹³ Bispebjerg Hospital, Copenhagen, Denmark
- ¹⁴ Department of Internal Medicine III, Klinikum Augsburg, Augsburg, Germany
- ¹⁵ Department of Surgery, University Hospital of Turin, Turin, Italy
- ¹⁶ Department of Internal Medicine, Evangelisches Krankenhaus Düsseldorf, Düsseldorf, Germany
- ¹⁷ Cliniques universitaires St-Luc, Université catholique de Louvain, Brussels, Belgium
- ¹⁸ Department of Pathology, Università di Padova, Padova, Italy
- ¹⁹ Wolfson Unit for Endoscopy, St. Mark's Hospital & Imperial College, London, UK
- ²⁰ Service d'hépatogastroentérologie, Hôpital de la Cavale-Blanche, Brest, France
- ²¹ GastroZentrum, Klinik Hirslanden, Zurich, Switzerland
- ²² Endoscopy Department, Yaroslavl Regional Cancer Hospital, Yaroslavl, Russia
- ²³ Gedyt Endoscopy Center, Buenos Aires, Argentina
- ²⁴ Department of Gastroenterology, Nuovo Regina Margherita Hospital, Rome, Italy

References

- 1 Atkins D, Best D, Eccles M et al. GRADE Working Group. Grading quality of evidence and strength of recommendations. *BMJ* 2004; 328: 1490
- 2 Dumonceau JM, Hassan C, Riphaus A et al. European Society of Gastrointestinal Endoscopy (ESGE) Guideline Development Policy. *Endoscopy* 2012; 44: 626–629 Epub 2012 Feb 27 DOI 10.1055/s-0031-1291747
- 3 Higuchi K, Koizumi W, Tanabe S et al. Current management of esophageal squamous-cell carcinoma in Japan and other countries. *Gastrointest Cancer Res* 2009; 3: 153–161
- 4 [Anonymous]. Japanese Classification of Esophageal Cancer, 10th edition: part I. Esophagus. 2009; 6: 1–25
- 5 Tajima Y, Nakanishi Y, Tachimori Y et al. Significance of involvement by squamous cell carcinoma of the ducts of esophageal submucosal glands. Analysis of 201 surgically resected superficial squamous cell carcinomas. *Cancer* 2000; 89: 248–254
- 6 Natsugoe S, Baba M, Yoshinaka H et al. Mucosal squamous cell carcinoma of the esophagus: a clinicopathologic study of 30 cases. *Oncology* 1998; 55: 235–241
- 7 Bollschweiler E, Baldus SE, Schroder W et al. High rate of lymph-node metastasis in submucosal esophageal squamous-cell carcinomas and adenocarcinomas. *Endoscopy* 2006; 38: 149–156
- 8 Kanzaki H, Ishihara R, Ohta T et al. Randomized study of two endo-knives for endoscopic submucosal dissection of esophageal cancer. *Am J Gastroenterol* 2013; 108: 1293–1298
- 9 Toyonaga T, Man-i M, East JE et al. 1,635 Endoscopic submucosal dissection cases in the esophagus, stomach, and colorectum: complication rates and long-term outcomes. *Surg Endosc* 2013; 27: 1000–1008
- 10 Kawahara Y, Hori K, Takenaka R et al. Endoscopic submucosal dissection of esophageal cancer using the Mucosectom2 device: a feasibility study. *Endoscopy* 2013; 45: 869–875
- 11 Fujinami H, Hosokawa A, Ogawa K et al. Endoscopic submucosal dissection for superficial esophageal neoplasms using the stag beetle knife. *Dis Esophagus* 2014; 27: 50–54
- 12 Yamashina T, Ishihara R, Uedo N et al. Safety and curative ability of endoscopic submucosal dissection for superficial esophageal cancers at least 50 mm in diameter. *Dig Endosc* 2012; 24: 220–225
- 13 Yamashita T, Zeniya A, Ishii H et al. Endoscopic mucosal resection using a cap-fitted panendoscope and endoscopic submucosal dissection as optimal endoscopic procedures for superficial esophageal carcinoma. *Surg Endosc* 2011; 25: 2541–2546
- 14 Mochizuki Y, Saito Y, Tsujikawa T et al. Combination of endoscopic submucosal dissection and chemoradiation therapy for superficial esophageal squamous cell carcinoma with submucosal invasion. *Exp Ther Med* 2011; 2: 1065–1068
- 15 Takahashi H, Arimura Y, Masao H et al. Endoscopic submucosal dissection is superior to conventional endoscopic resection as a curative treatment for early squamous cell carcinoma of the esophagus (with video). *Gastrointest Endosc* 2010; 72: 255–264 (264.e 251–252)
- 16 Repici A, Hassan C, Carlino A et al. Endoscopic submucosal dissection in patients with early esophageal squamous cell carcinoma: results from a prospective Western series. *Gastrointest Endosc* 2010; 71: 715–721
- 17 Chaves DM, Maluf Filho F, de Moura EG et al. Endoscopic submucosal dissection for the treatment of early esophageal and gastric cancer – initial experience of a western center. *Clinics (Sao Paulo)* 2010; 65: 377–382
- 18 Teoh AY, Chiu PW, Yu Ngo DK et al. Outcomes of endoscopic submucosal dissection versus endoscopic mucosal resection in management of superficial squamous esophageal neoplasms outside Japan. *J Clin Gastroenterol* 2010; 44: e190–e194
- 19 Nonaka K, Arai S, Ishikawa K et al. Short term results of endoscopic submucosal dissection in superficial esophageal squamous cell neoplasms. *World J Gastrointest Endosc* 2010; 2: 69–74
- 20 Ono S, Fujishiro M, Niimi K et al. Long-term outcomes of endoscopic submucosal dissection for superficial esophageal squamous cell neoplasms. *Gastrointest Endosc* 2009; 70: 860–866
- 21 Fujishiro M, Yahagi N, Kakushima N et al. Endoscopic submucosal dissection of esophageal squamous cell neoplasms. *Clin Gastroenterol Hepatol* 2006; 4: 688–694
- 22 Oyama T, Tomori A, Hotta K et al. Endoscopic submucosal dissection of early esophageal cancer. *Clin Gastroenterol Hepatol* 2005; 3: 67–70
- 23 Hoteya S, Matsui A, Iizuka T et al. Comparison of the clinicopathological characteristics and results of endoscopic submucosal dissection for esophagogastric junction and non-junctional cancers. *Digestion* 2013; 87: 29–33
- 24 Neuhaus H, Terheggen G, Rutz EM et al. Endoscopic submucosal dissection plus radiofrequency ablation of neoplastic Barrett's esophagus. *Endoscopy* 2012; 44: 1105–1113
- 25 Hirasawa K, Kokawa A, Oka H et al. Superficial adenocarcinoma of the esophagogastric junction: long-term results of endoscopic submucosal dissection. *Gastrointest Endosc* 2010; 72: 960–966

- 26 Yoshinaga S, Gotoda T, Kusano C et al. Clinical impact of endoscopic submucosal dissection for superficial adenocarcinoma located at the esophagogastric junction. *Gastrointest Endosc* 2008; 67: 202–209
- 27 Kakushima N, Yahagi N, Fujishiro M et al. Efficacy and safety of endoscopic submucosal dissection for tumors of the esophagogastric junction. *Endoscopy* 2006; 38: 170–174
- 28 Chevaux JB, Piessevaux H, Jouret-Mourin A et al. Clinical outcome in patients treated with endoscopic submucosal dissection for superficial Barrett's neoplasia. *Endoscopy* 2015; 47: 103–112
- 29 Higuchi K, Tanabe S, Azuma M et al. A phase II study of endoscopic submucosal dissection for superficial esophageal neoplasms (KDOG 0901). *Gastrointest Endosc* 2013; 78: 704–710
- 30 Arantes V, Albuquerque W, Freitas Dias CA et al. Standardized endoscopic submucosal tunnel dissection for management of early esophageal tumors (with video). *Gastrointest Endosc* 2013; 78: 946–952
- 31 Isomoto H, Yamaguchi N, Minami H et al. Management of complications associated with endoscopic submucosal dissection/endoscopic mucosal resection for esophageal cancer. *Dig Endosc* 2013; 25: 29–38
- 32 Sato H, Inoue H, Kobayashi Y et al. Control of severe strictures after circumferential endoscopic submucosal dissection for esophageal carcinoma: oral steroid therapy with balloon dilation or balloon dilation alone. *Gastrointest Endosc* 2013; 78: 250–257
- 33 Chaves DM, Moura EG, Milhomem D et al. Initial experience of endoscopic submucosal dissection in Brazil to treat early gastric and esophageal cancer: a multi-institutional analysis. *Arq Gastroenterol* 2013; 50: 148–152
- 34 Lee CT, Chang CY, Tai CM et al. Endoscopic submucosal dissection for early esophageal neoplasia: a single center experience in South Taiwan. *J Formos Med Assoc* 2012; 111: 132–139
- 35 Kikuchi OMH, Matsueda K, Yamamoto H. Endoscopic submucosal dissection for treatment of patients aged 75 years and over with esophageal cancer. *ISRN Gastroenterol* 2012; DOI 10.5402/2012/671324
- 36 Ishii N, Uchida S, Itoh T et al. Endoscopic submucosal dissection with a combination of small-caliber-tip transparent hood and flex knife for superficial esophageal neoplasia. Is it safe for elderly patients? *Surg Endosc* 2010; 24: 2110–2119
- 37 Ishihara R, Iishi H, Takeuchi Y et al. Local recurrence of large squamous-cell carcinoma of the esophagus after endoscopic resection. *Gastrointest Endosc* 2008; 67: 799–804
- 38 Probst A, Aust D, Markl B et al. Early esophageal cancer in Europe: endoscopic treatment by endoscopic submucosal dissection. *Endoscopy* 2015; 47: 113–121
- 39 Linghu E, Feng X, Wang X et al. Endoscopic submucosal tunnel dissection for large esophageal neoplastic lesions. *Endoscopy* 2013; 45: 60–62
- 40 Farhat S, Chaussade S, Ponchon T et al. Endoscopic submucosal dissection in a European setting. A multi-institutional report of a technique in development. *Endoscopy* 2011; 43: 664–670
- 41 Coda S, Trentino P, Antonellis F et al. A Western single-center experience with endoscopic submucosal dissection for early gastrointestinal cancers. *Gastric Cancer* 2010; 13: 258–263
- 42 Motohashi O, Nishimura K, Nakayama N et al. Endoscopic submucosal dissection (two-point fixed ESD) for early esophageal cancer. *Dig Endosc* 2009; 21: 176–179
- 43 Li QL, Yao LQ, Zhou PH et al. Submucosal tumors of the esophagogastric junction originating from the muscularis propria layer: a large study of endoscopic submucosal dissection (with video). *Gastrointest Endosc* 2012; 75: 1153–1158
- 44 Gong W, Xiong Y, Zhi F et al. Preliminary experience of endoscopic submucosal tunnel dissection for upper gastrointestinal submucosal tumors. *Endoscopy* 2012; 44: 231–235
- 45 Shi Q, Zhong YS, Yao LQ et al. Endoscopic submucosal dissection for treatment of esophageal submucosal tumors originating from the muscularis propria layer. *Gastrointest Endosc* 2011; 74: 1194–1200
- 46 Katada C, Muto M, Momma K et al. Clinical outcome after endoscopic mucosal resection for esophageal squamous cell carcinoma invading the muscularis mucosae – a multicenter retrospective cohort study. *Endoscopy* 2007; 39: 779–783
- 47 Makuuchi H. Endoscopic mucosal resection for mucosal cancer in the esophagus. *Gastrointest Endosc Clin N Am* 2001; 11: 445–458
- 48 McCulloch P, Ward J, Tekkis PP. Mortality and morbidity in gastro-esophageal cancer surgery: initial results of ASCOT multicentre prospective cohort study. *BMJ* 2003; 327: 1192–1197
- 49 Karl RC, Schreiber R, Boulware D et al. Factors affecting morbidity, mortality, and survival in patients undergoing Ivor Lewis esophagogastrectomy. *Ann Surg* 2000; 231: 635–643
- 50 Shitara K, Muro K. Chemoradiotherapy for treatment of esophageal cancer in Japan: current status and perspectives. *Gastrointest Cancer Res* 2009; 3: 66–72
- 51 Shimizu Y, Kato M, Yamamoto J et al. EMR combined with chemoradiotherapy: a novel treatment for superficial esophageal squamous-cell carcinoma. *Gastrointest Endosc* 2004; 59: 199–204
- 52 Ciocirlan M, Lapalus MG, Hervieu V et al. Endoscopic mucosal resection for squamous premalignant and early malignant lesions of the esophagus. *Endoscopy* 2007; 39: 24–29
- 53 Kodama M, Kakegawa T. Treatment of superficial cancer of the esophagus: a summary of responses to a questionnaire on superficial cancer of the esophagus in Japan. *Surgery* 1998; 123: 432–439
- 54 Katada C, Muto M, Manabe T et al. Local recurrence of squamous-cell carcinoma of the esophagus after EMR. *Gastrointest Endosc* 2005; 61: 219–225
- 55 Cao Y, Liao C, Tan A et al. Meta-analysis of endoscopic submucosal dissection versus endoscopic mucosal resection for tumors of the gastrointestinal tract. *Endoscopy* 2009; 41: 751–757
- 56 Alvarez Herrero L, Pouw RE, van Vilsteren FG et al. Safety and efficacy of multiband mucosectomy in 1060 resections in Barrett's esophagus. *Endoscopy* 2011; 43: 177–183
- 57 Deprez PH, Bergman JJ, Meisner S et al. Current practice with endoscopic submucosal dissection in Europe: position statement from a panel of experts. *Endoscopy* 2010; 42: 853–858
- 58 Goda K, Singh R, Oda I et al. Current status of endoscopic diagnosis and treatment of superficial Barrett's adenocarcinoma in Asia-Pacific region. *Dig Endosc* 2013; 25: 146–150
- 59 Komanduri S, Deprez PH, Atasoy A et al. Barrett's esophagus: treatments of adenocarcinomas I. *Ann N Y Acad Sci* 2011; 1232: 248–264
- 60 Liu L, Hofstetter WL, Rashid A et al. Significance of the depth of tumor invasion and lymph node metastasis in superficially invasive (T1) esophageal adenocarcinoma. *Am J Surg Pathol* 2005; 29: 1079–1085
- 61 Prasad GA, Wu TT, Wigle DA et al. Endoscopic and surgical treatment of mucosal (T1a) esophageal adenocarcinoma in Barrett's esophagus. *Gastroenterology* 2009; 137: 815–823
- 62 Alvarez Herrero L, Pouw RE, van Vilsteren FG et al. Risk of lymph node metastasis associated with deeper invasion by early adenocarcinoma of the esophagus and cardia: study based on endoscopic resection specimens. *Endoscopy* 2010; 42: 1030–1036
- 63 Buskens CJ, Westerterp M, Lagarde SM et al. Prediction of appropriateness of local endoscopic treatment for high-grade dysplasia and early adenocarcinoma by EUS and histopathologic features. *Gastrointest Endosc* 2004; 60: 703–710
- 64 Sepesi B, Watson TJ, Zhou D et al. Are endoscopic therapies appropriate for superficial submucosal esophageal adenocarcinoma? An analysis of esophagectomy specimens. *J Am Coll Surg* 2010; 210: 418–427
- 65 Stein HJ, Feith M, Bruecher BL et al. Early esophageal cancer: pattern of lymphatic spread and prognostic factors for long-term survival after surgical resection. *Ann Surg* 2005; 242: 566–573 (discussion 573–565)
- 66 Westerterp M, Koppert LB, Buskens CJ et al. Outcome of surgical treatment for early adenocarcinoma of the esophagus or gastro-esophageal junction. *Virchows Arch* 2005; 446: 497–504
- 67 Abraham SC, Krasinskas AM, Correa AM et al. Duplication of the muscularis mucosae in Barrett esophagus: an underrecognized feature and its implication for staging of adenocarcinoma. *Am J Surg Pathol* 2007; 31: 1719–1725
- 68 Barbour AP, Jones M, Brown I et al. Risk stratification for early esophageal adenocarcinoma: analysis of lymphatic spread and prognostic factors. *Ann Surg Oncol* 2010; 17: 2494–2502
- 69 Dunbar KB, Specbler SJ. The risk of lymph-node metastases in patients with high-grade dysplasia or intramucosal carcinoma in Barrett's esophagus: a systematic review. *Am J Gastroenterol* quiz 863 2012; 107: 850–862
- 70 Pech O, May A, Manner H et al. Long-term efficacy and safety of endoscopic resection for patients with mucosal adenocarcinoma of the esophagus. *Gastroenterology* 2014; 146: 652–660 (e651)
- 71 Peters FP, Brakenhoff KP, Curvers WL et al. Histologic evaluation of resection specimens obtained at 293 endoscopic resections in Barrett's esophagus. *Gastrointest Endosc* 2008; 67: 604–609

- 72 Pech O, Gossner L, Manner H et al. Prospective evaluation of the macroscopic types and location of early Barrett's neoplasia in 380 lesions. *Endoscopy* 2007; 39: 588–593
- 73 Tharavej C, Hagen JA, Peters JH et al. Predictive factors of coexisting cancer in Barrett's high-grade dysplasia. *Surg Endosc* 2006; 20: 439–443
- 74 Manner H, May A, Pech O et al. Early Barrett's carcinoma with "low-risk" submucosal invasion: long-term results of endoscopic resection with a curative intent. *Am J Gastroenterol* 2008; 103: 2589–2597
- 75 Sgourakis G, Gockel I, Lang H. Endoscopic and surgical resection of T1a/T1b esophageal neoplasms: a systematic review. *World J Gastroenterol* 2013; 19: 1424–1437
- 76 Pech O, Behrens A, May A et al. Long-term results and risk factor analysis for recurrence after curative endoscopic therapy in 349 patients with high-grade intraepithelial neoplasia and mucosal adenocarcinoma in Barrett's oesophagus. *Gut* 2008; 57: 1200–1206
- 77 Larghi A, Waxman I. State of the art on endoscopic mucosal resection and endoscopic submucosal dissection. *Gastrointest Endosc Clin N Am* 2007; 17: 441–469
- 78 Ono S, Fujishiro M, Niimi K et al. Predictors of postoperative stricture after esophageal endoscopic submucosal dissection for superficial squamous cell neoplasms. *Endoscopy* 2009; 41: 661–665
- 79 Mizuta H, Nishimori I, Kuratani Y et al. Predictive factors for esophageal stenosis after endoscopic submucosal dissection for superficial esophageal cancer. *Dis Esophagus* 2009; 22: 626–631
- 80 Yamaguchi N, Isomoto H, Nakayama T et al. Usefulness of oral prednisolone in the treatment of esophageal stricture after endoscopic submucosal dissection for superficial esophageal squamous cell carcinoma. *Gastrointest Endosc* 2011; 73: 1115–1121
- 81 Hashimoto S, Kobayashi M, Takeuchi M et al. The efficacy of endoscopic triamcinolone injection for the prevention of esophageal stricture after endoscopic submucosal dissection. *Gastrointest Endosc* 2011; 74: 1389–1393
- 82 Deprez PH. Esophageal strictures after extensive endoscopic resection: hope for a better outcome? *Gastrointest Endosc* 2013; 78: 258–259
- 83 Pech O, Bollschweiler E, Manner H et al. Comparison between endoscopic and surgical resection of mucosal esophageal adenocarcinoma in Barrett's esophagus at two high-volume centers. *Ann Surg* 2011; 254: 67–72
- 84 Das A, Singh V, Fleischer DE et al. A comparison of endoscopic treatment and surgery in early esophageal cancer: an analysis of surveillance epidemiology and end results data. *Am J Gastroenterol* 2008; 103: 1340–1345
- 85 Thomas T, Gilbert D, Kaye PV et al. High-resolution endoscopy and endoscopic ultrasound for evaluation of early neoplasia in Barrett's esophagus. *Surg Endosc* 2010; 24: 1110–1116
- 86 Anonymus. Update on the Paris classification of superficial neoplastic lesions in the digestive tract. *Endoscopy* 2005; 37: 570–578
- 87 Pohl J, May A, Rabenstein T et al. Comparison of computed virtual chromoendoscopy and conventional chromoendoscopy with acetic acid for detection of neoplasia in Barrett's esophagus. *Endoscopy* 2007; 39: 594–598
- 88 Longcroft-Wheaton G, Duku M, Mead R et al. Acetic acid spray is an effective tool for the endoscopic detection of neoplasia in patients with Barrett's esophagus. *Clin Gastroenterol Hepatol* 2010; 8: 843–847
- 89 Fortun PJ, Anagnostopoulos GK, Kaye P et al. Acetic acid-enhanced magnification endoscopy in the diagnosis of specialized intestinal metaplasia, dysplasia and early cancer in Barrett's oesophagus. *Aliment Pharmacol Ther* 2006; 23: 735–742
- 90 Inoue H, Rey JF, Lightdale C. Lugol chromoendoscopy for esophageal squamous cell cancer. *Endoscopy* 2001; 33: 75–79
- 91 Lee CT, Chang CY, Lee YC et al. Narrow-band imaging with magnifying endoscopy for the screening of esophageal cancer in patients with primary head and neck cancers. *Endoscopy* 2010; 42: 613–619
- 92 Takenaka R, Kawahara Y, Okada H et al. Narrow-band imaging provides reliable screening for esophageal malignancy in patients with head and neck cancers. *Am J Gastroenterol* 2009; 104: 2942–2948
- 93 Mannath J, Subramanian V, Hawkey CJ et al. Narrow band imaging for characterization of high grade dysplasia and specialized intestinal metaplasia in Barrett's esophagus: a meta-analysis. *Endoscopy* 2010; 42: 351–359
- 94 Curvers WL, Bohmer CJ, Mallant-Hent RC et al. Mucosal morphology in Barrett's esophagus: interobserver agreement and role of narrow band imaging. *Endoscopy* 2008; 40: 799–805
- 95 Fitzgerald RC, di Pietro M, Ragunath K et al. British Society of Gastroenterology guidelines on the diagnosis and management of Barrett's oesophagus. *Gut* 2014; 63: 7–42
- 96 Lal N, Bhasin DK, Malik AK et al. Optimal number of biopsy specimens in the diagnosis of carcinoma of the oesophagus. *Gut* 1992; 33: 724–726
- 97 Lee IS, Park YS, Lee JH et al. Pathologic discordance of differentiation between endoscopic biopsy and postoperative specimen in mucosal gastric adenocarcinomas. *Ann Surg Oncol* 2013; 20: 4231–4237
- 98 Thosani N, Singh H, Kapadia A et al. Diagnostic accuracy of EUS in differentiating mucosal versus submucosal invasion of superficial esophageal cancers: a systematic review and meta-analysis. *Gastrointest Endosc* 2012; 75: 242–253
- 99 Sgourakis G, Gockel I, Lyros O et al. Detection of lymph node metastases in esophageal cancer. *Expert Rev Anticancer Ther* 2011; 11: 601–612
- 100 May A, Gunter E, Roth F et al. Accuracy of staging in early oesophageal cancer using high resolution endoscopy and high resolution endosonography: a comparative, prospective, and blinded trial. *Gut* 2004; 53: 634–640
- 101 Larghi A, Lightdale CJ, Memeo L et al. EUS followed by EMR for staging of high-grade dysplasia and early cancer in Barrett's esophagus. *Gastrointest Endosc* 2005; 62: 16–23
- 102 Pech O, Gunter E, Dusemund F et al. Value of high-frequency miniprobe and conventional radial endoscopic ultrasound in the staging of early Barrett's carcinoma. *Endoscopy* 2010; 42: 98–103
- 103 Pech O, May A, Gunter E et al. The impact of endoscopic ultrasound and computed tomography on the TNM staging of early cancer in Barrett's esophagus. *Am J Gastroenterol* 2006; 101: 2223–2229
- 104 Pech O, Gunter E, Dusemund F et al. Accuracy of endoscopic ultrasound in preoperative staging of esophageal cancer: results from a referral center for early esophageal cancer. *Endoscopy* 2010; 42: 456–461
- 105 Rampado S, Bocus P, Battaglia G et al. Endoscopic ultrasound: accuracy in staging superficial carcinomas of the esophagus. *Ann Thorac Surg* 2008; 85: 251–256
- 106 Young PE, Gentry AB, Acosta RD et al. Endoscopic ultrasound does not accurately stage early adenocarcinoma or high-grade dysplasia of the esophagus. *Clin Gastroenterol Hepatol* 2010; 8: 1037–1041
- 107 Pouw RE, Heldoorn N, Alvarez Herrero L et al. Do we still need EUS in the workup of patients with early esophageal neoplasia? A retrospective analysis of 131 cases. *Gastrointest Endosc* 2011; 73: 662–668
- 108 Moriya H, Ohbu M, Kobayashi N et al. Lymphatic tumor emboli detected by D2–40 immunostaining can more accurately predict lymph-node metastasis. *World J Surg* 2011; 35: 2031–2037
- 109 Ishii N, Horiki N, Itoh T et al. Endoscopic submucosal dissection with a combination of small-caliber-tip transparent hood and flex knife is a safe and effective treatment for superficial esophageal neoplasias. *Surg Endosc* 2010; 24: 335–342
- 110 Larghi A, Lightdale CJ, Ross AS et al. Long-term follow-up of complete Barrett's eradication endoscopic mucosal resection (CBE-EMR) for the treatment of high grade dysplasia and intramucosal carcinoma. *Endoscopy* 2007; 39: 1086–1091
- 111 Peters FP, Kara MA, Rosmolen WD et al. Endoscopic treatment of high-grade dysplasia and early stage cancer in Barrett's esophagus. *Gastrointest Endosc* 2005; 61: 506–514
- 112 Fleischer DE, Overholt BF, Sharma VK et al. Endoscopic radiofrequency ablation for Barrett's esophagus: 5-year outcomes from a prospective multicenter trial. *Endoscopy* 2010; 42: 781–789
- 113 Ell C, May A, Pech O et al. Curative endoscopic resection of early esophageal adenocarcinomas (Barrett's cancer). *Gastrointest Endosc* 2007; 65: 3–10
- 114 Bennett C, Vakili N, Bergman J et al. Consensus statements for management of Barrett's dysplasia and early-stage esophageal adenocarcinoma, based on a Delphi process. *Gastroenterology* 2012; 143: 336–346
- 115 Bedi AO, Kwon RS, Rubenstein JH et al. A survey of expert follow-up practices after successful endoscopic eradication therapy for Barrett's esophagus with high-grade dysplasia and intramucosal adenocarcinoma. *Gastrointest Endosc* 2013; 78: 696–701
- 116 Chung IK, Lee JH, Lee SH et al. Therapeutic outcomes in 1000 cases of endoscopic submucosal dissection for early gastric neoplasms: Korean ESD Study Group multicenter study. *Gastrointest Endosc* 2009; 69: 1228–1235

- 117 Gotoda T, Jung HY. Endoscopic resection (endoscopic mucosal resection/ endoscopic submucosal dissection) for early gastric cancer. *Dig Endosc* 2013; 25: 55–63
- 118 Lian J, Chen S, Zhang Y et al. A meta-analysis of endoscopic submucosal dissection and EMR for early gastric cancer. *Gastrointest Endosc* 2012; 76: 763–770
- 119 Park YM, Cho E, Kang HY et al. The effectiveness and safety of endoscopic submucosal dissection compared with endoscopic mucosal resection for early gastric cancer: a systematic review and metaanalysis. *Surg Endosc* 2011; 25: 2666–2677
- 120 Japanese Gastric Cancer Association. Japanese gastric cancer treatment guidelines 2010 (ver. 3). *Gastric Cancer* 2011; 14: 113–123
- 121 Gotoda T, Iwasaki M, Kusano C et al. Endoscopic resection of early gastric cancer treated by guideline and expanded National Cancer Centre criteria. *Br J Surg* 2010; 97: 868–871
- 122 Gotoda T, Yanagisawa A, Sasako M et al. Incidence of lymph node metastasis from early gastric cancer: estimation with a large number of cases at two large centers. *Gastric Cancer* 2000; 3: 219–225
- 123 Ahn JY, Jung HY, Choi KD et al. Endoscopic and oncologic outcomes after endoscopic resection for early gastric cancer: 1370 cases of absolute and extended indications. *Gastrointest Endosc* 2011; 74: 485–493
- 124 Park CH, Shin S, Park JC et al. Long-term outcome of early gastric cancer after endoscopic submucosal dissection: expanded indication is comparable to absolute indication. *Dig Liver Dis* 2013; 45: 651–656
- 125 Takekoshi T, Baba Y, Ota H et al. Endoscopic resection of early gastric carcinoma: results of a retrospective analysis of 308 cases. *Endoscopy* 1994; 26: 352–358
- 126 Hiki Y, Shimao H, Mieno H et al. Modified treatment of early gastric cancer: evaluation of endoscopic treatment of early gastric cancers with respect to treatment indication groups. *World J Surg* 1995; 19: 517–522
- 127 Uedo N, Iishi H, Tatsuta M et al. Longterm outcomes after endoscopic mucosal resection for early gastric cancer. *Gastric Cancer* 2006; 9: 88–92
- 128 Nagano H, Ohyama S, Fukunaga T et al. Indications for gastrectomy after incomplete EMR for early gastric cancer. *Gastric Cancer* 2005; 8: 149–154
- 129 Gotoda T. A large endoscopic resection by endoscopic submucosal dissection procedure for early gastric cancer. *Clin Gastroenterol Hepatol* 2005; 3: 71–73
- 130 Takeuchi Y, Uedo N, Iishi H et al. Endoscopic submucosal dissection with insulated-tip knife for large mucosal early gastric cancer: a feasibility study (with videos). *Gastrointest Endosc* 2007; 66: 186–193
- 131 Facciorusso A, Antonino M, Di Maso M et al. Endoscopic submucosal dissection vs endoscopic mucosal resection for early gastric cancer: A meta-analysis. *World J Gastrointest Endosc* 2014; 6: 555–563
- 132 Tanabe S, Ishido K, Higuchi K et al. Long-term outcomes of endoscopic submucosal dissection for early gastric cancer: a retrospective comparison with conventional endoscopic resection in a single center. *Gastric Cancer* 2014; 17: 130–136
- 133 Pimentel-Nunes P, Mourao F, Veloso N et al. Long-term follow-up after endoscopic resection of gastric superficial neoplastic lesions in Portugal. *Endoscopy* 2014; 46: 933–940
- 134 Abe N, Gotoda T, Hirasawa T et al. Multicenter study of the long-term outcomes of endoscopic submucosal dissection for early gastric cancer in patients 80 years of age or older. *Gastric Cancer* 2012; 15: 70–75
- 135 Gotoda T, Yamamoto H, Soetikno RM. Endoscopic submucosal dissection of early gastric cancer. *J Gastroenterol* 2006; 41: 929–942
- 136 Lee DW, Jeon SW. Management of complications during gastric endoscopic submucosal dissection. *Diagn Ther Endosc* 2012; 2012: 624835
- 137 Takizawa K, Oda I, Gotoda T et al. Routine coagulation of visible vessels may prevent delayed bleeding after endoscopic submucosal dissection—an analysis of risk factors. *Endoscopy* 2008; 40: 179–183
- 138 Jeon SW, Jung MK, Kim SK et al. Clinical outcomes for perforations during endoscopic submucosal dissection in patients with gastric lesions. *Surg Endosc* 2010; 24: 911–916
- 139 Kim HS, Lee DK, Baik SK et al. Endoscopic mucosal resection with a ligation device for early gastric cancer and precancerous lesions: comparison of its therapeutic efficacy with surgical resection. *Yonsei Med J* 2000; 41: 577–583
- 140 Etoh T, Katai H, Fukagawa T et al. Treatment of early gastric cancer in the elderly patient: results of EMR and gastrectomy at a national referral center in Japan. *Gastrointest Endosc* 2005; 62: 868–871
- 141 Choi KS, Jung HY, Choi KD et al. EMR versus gastrectomy for intramucosal gastric cancer: comparison of long-term outcomes. *Gastrointest Endosc* 2011; 73: 942–948
- 142 Chiu PW, Teoh AY, To KF et al. Endoscopic submucosal dissection (ESD) compared with gastrectomy for treatment of early gastric neoplasia: a retrospective cohort study. *Surg Endosc* 2012; 26: 3584–3591
- 143 Zeng YK, Yang ZL, Peng JS et al. Laparoscopy-assisted versus open distal gastrectomy for early gastric cancer: evidence from randomized and nonrandomized clinical trials. *Ann Surg* 2012; 256: 39–52
- 144 Zhang CD, Chen SC, Feng ZF et al. Laparoscopic versus open gastrectomy for early gastric cancer in Asia: a meta-analysis. *Surg Laparosc Endosc Percutan Tech* 2013; 23: 365–377
- 145 Jung H, Bae JM, Choi MG et al. Surgical outcome after incomplete endoscopic submucosal dissection of gastric cancer. *Br J Surg* 2011; 98: 73–78
- 146 Kwon HY, Hyung WJ, Lee JH et al. Outcomes of laparoscopic gastrectomy after endoscopic treatment for gastric cancer: a comparison with open gastrectomy. *J Gastric Cancer* 2013; 13: 51–57
- 147 Choi J, Kim SG, Im JP et al. Endoscopic prediction of tumor invasion depth in early gastric cancer. *Gastrointest Endosc* 2011; 73: 917–927
- 148 Choi J, Kim SG, Im JP et al. Comparison of endoscopic ultrasonography and conventional endoscopy for prediction of depth of tumor invasion in early gastric cancer. *Endoscopy* 2010; 42: 705–713
- 149 Ezoe Y, Muto M, Uedo N et al. Magnifying narrowband imaging is more accurate than conventional white-light imaging in diagnosis of gastric mucosal cancer. *Gastroenterology* 2011; 141: 2017–2025 e2013
- 150 Nagahama T, Yao K, Maki S et al. Usefulness of magnifying endoscopy with narrow-band imaging for determining the horizontal extent of early gastric cancer when there is an unclear margin by chromoendoscopy (with video). *Gastrointest Endosc* 2011; 74: 1259–1267
- 151 Repici BE, Kim GH, Park do Yet al. Acetic acid-indigo carmine chromoendoscopy for delineating early gastric cancers: its usefulness according to histological type. *BMC Gastroenterol* 2010; 10: 97
- 152 Taghavi SA, Membari ME, Eshraghian A et al. Comparison of chromoendoscopy and conventional endoscopy in the detection of premalignant gastric lesions. *Can J Gastroenterol* 2009; 23: 105–108
- 153 Cardoso R, Coburn N, Seevaratnam R et al. A systematic review and meta-analysis of the utility of EUS for preoperative staging for gastric cancer. *Gastric Cancer* 2012; 15: 19–26
- 154 Mocellin S, Marchet A, Nitti D. EUS for the staging of gastric cancer: a meta-analysis. *Gastrointest Endosc* 2011; 73: 1122–1134
- 155 Ajani JA, Bentrem DJ, Besh S et al. Gastric cancer, version 2.2013: featured updates to the NCCN Guidelines. *J Natl Compr Canc Netw* 2013; 11: 531–546
- 156 Probst A, Pommer B, Golger D et al. Endoscopic submucosal dissection in gastric neoplasia – experience from a European center. *Endoscopy* 2010; 42: 1037–1044
- 157 Folli S, Morgagni P, Roviello F et al. Risk factors for lymph node metastases and their prognostic significance in early gastric cancer (EGC) for the Italian Research Group for Gastric Cancer (IRGGC). *Jpn J Clin Oncol* 2001; 31: 495–499
- 158 Son SY, Park JY, Ryu KW et al. The risk factors for lymph node metastasis in early gastric cancer patients who underwent endoscopic resection: is the minimal lymph node dissection applicable? A retrospective study. *Surg Endosc* 2013; 27: 3247–3253
- 159 Soetikno R, Kaltenbach T, Yeh R et al. Endoscopic mucosal resection for early cancers of the upper gastrointestinal tract. *J Clin Oncol* 2005; 23: 4490–4498
- 160 Ohgami M, Otani Y, Kumai K et al. [Laparoscopic surgery for early gastric cancer]. *Nihon Geka Gakkai Zasshi* 1996; 97: 279–285
- 161 Yamao T, Shirao K, Ono H et al. Risk factors for lymph node metastasis from intramucosal gastric carcinoma. *Cancer* 1996; 77: 602–606
- 162 Hirasawa T, Gotoda T, Miyata S et al. Incidence of lymph node metastasis and the feasibility of endoscopic resection for undifferentiated-type early gastric cancer. *Gastric Cancer* 2009; 12: 148–152
- 163 Choi MK, Kim GH, Park DY et al. Long-term outcomes of endoscopic submucosal dissection for early gastric cancer: a single-center experience. *Surg Endosc* 2013; 27: 4250–4258
- 164 Kosaka T, Endo M, Toya Y et al. Long-term outcomes of endoscopic submucosal dissection for early gastric cancer: A single-center retrospective study. *Dig Endosc* 2013; DOI 10.1111/den.12099

- 165 Horiki N, Omata F, Uemura M et al. Risk for local recurrence of early gastric cancer treated with piecemeal endoscopic mucosal resection during a 10-year follow-up period. *Surg Endosc* 2012; 26: 72–78
- 166 Sekiguchi M, Suzuki H, Oda I et al. Risk of recurrent gastric cancer after endoscopic resection with a positive lateral margin. *Endoscopy* 2014; DOI 10.1055/s-0034-1364938
- 167 Ahn JY, Jung HY, Choi JY et al. Natural course of noncurative endoscopic resection of differentiated early gastric cancer. *Endoscopy* 2012; 44: 1114–1120
- 168 Yokoi C, Gotoda T, Hamanaka H et al. Endoscopic submucosal dissection allows curative resection of locally recurrent early gastric cancer after prior endoscopic mucosal resection. *Gastrointest Endosc* 2006; 64: 212–218
- 169 Oda I, Gotoda T, Sasako M et al. Treatment strategy after non-curative endoscopic resection of early gastric cancer. *Br J Surg* 2008; 95: 1495–1500
- 170 Yoon H, Kim SG, Choi J et al. Risk factors of residual or recurrent tumor in patients with a tumor-positive resection margin after endoscopic resection of early gastric cancer. *Surg Endosc* 2013; 27: 1561–1568
- 171 Kato M, Nishida T, Yamamoto K et al. Scheduled endoscopic surveillance controls secondary cancer after curative endoscopic resection for early gastric cancer: a multicentre retrospective cohort study by Osaka University ESD study group. *Gut* 2013; 62: 1425–1432
- 172 Mitsuhashi T, Lauwers GY, Ban S et al. Post-gastric endoscopic mucosal resection surveillance biopsies: evaluation of mucosal changes and recognition of potential mimics of residual adenocarcinoma. *Am J Surg Pathol* 2006; 30: 650–656
- 173 Nonaka S, Oda I, Tada K et al. Clinical outcome of endoscopic resection for nonampullary duodenal tumors. *Endoscopy* 2015; 47: 129–135
- 174 Abbass R, Rigaux J, Al-Kawas FH. Nonampullary duodenal polyps: characteristics and endoscopic management. *Gastrointest Endosc* 2010; 71: 754–759
- 175 Alexander S, Bourke MJ, Williams SJ et al. EMR of large, sessile, sporadic nonampullary duodenal adenomas: technical aspects and long-term outcome (with videos). *Gastrointest Endosc* 2009; 69: 66–73
- 176 Conio M, De Ceglie A, Filiberti R et al. Cap-assisted EMR of large, sporadic, nonampullary duodenal polyps. *Gastrointest Endosc* 2012; 76: 1160–1169
- 177 Matsumoto S, Miyatani H, Yoshida Y. Endoscopic submucosal dissection for duodenal tumors: a single-center experience. *Endoscopy* 2013; 45: 136–137
- 178 Jung JH, Choi KD, Ahn JY et al. Endoscopic submucosal dissection for sessile, nonampullary duodenal adenomas. *Endoscopy* 2013; 45: 133–135
- 179 Repici A, Pellicano R, Strangio G et al. Endoscopic mucosal resection for early colorectal neoplasia: pathologic basis, procedures, and outcomes. *Dis Colon Rectum* 2009; 52: 1502–1515
- 180 Zorzi M, Senore C, Da Re F et al. Quality of colonoscopy in an organised colorectal cancer screening programme with immunochemical faecal occult blood test: the EQUiPE study (Evaluating Quality Indicators of the Performance of Endoscopy). *Gut* 2014; DOI 10.1136/gutjnl-2014-307954
- 181 Moss A, Bourke MJ, Williams SJ et al. Endoscopic mucosal resection outcomes and prediction of submucosal cancer from advanced colonic mucosal neoplasia. *Gastroenterology* 2011; 140: 1909–1918
- 182 Hassan C, Repici A, Sharma P et al. Efficacy and safety of endoscopic resection of large colorectal polyps: a systematic review and meta-analysis. *Gut* 2015; DOI 10.1136/gutjnl-2014-308481
- 183 Moss A, Williams SJ, Hourigan LF et al. Long-term adenoma recurrence following wide-field endoscopic mucosal resection (WF-EMR) for advanced colonic mucosal neoplasia is infrequent: results and risk factors in 1000 cases from the Australian Colonic EMR (ACE) study. *Gut* 2015; 64: 57–65
- 184 Bosch SL, Teerenstra S, de Wilt JH et al. Predicting lymph node metastasis in pT1 colorectal cancer: a systematic review of risk factors providing rationale for therapy decisions. *Endoscopy* 2013; 45: 827–834
- 185 Horiuchi Y, Chino A, Matsuo Y et al. Diagnosis of laterally spreading tumors (LST) in the rectum and selection of treatment: characteristics of each of the subclassifications of LST in the rectum. *Dig Endosc* 2013; 25: 608–614
- 186 Uraoka T, Saito Y, Matsuda T et al. Endoscopic indications for endoscopic mucosal resection of laterally spreading tumors in the colorectum. *Gut* 2006; 55: 1592–1597
- 187 Saito Y, Yamada M, So E et al. Colorectal endoscopic submucosal dissection: Technical advantages compared to endoscopic mucosal resection and minimally invasive surgery. *Dig Endosc* 2014; 26: 52–61
- 188 Kim ES, Cho KB, Park KS et al. Factors predictive of perforation during endoscopic submucosal dissection for the treatment of colorectal tumors. *Endoscopy* 2011; 43: 573–578
- 189 Arezzo A, Passera R, Saito Y et al. Systematic review and meta-analysis of endoscopic submucosal dissection versus transanal endoscopic microsurgery for large noninvasive rectal lesions. *Surg Endosc* 2014; 28: 427–438
- 190 Repici A, Hassan C, De Paula Pessoa D et al. Efficacy and safety of endoscopic submucosal dissection for colorectal neoplasia: a systematic review. *Endoscopy* 2012; 44: 137–150
- 191 Niimi K, Fujishiro M, Kodashima S et al. Long-term outcomes of endoscopic submucosal dissection for colorectal epithelial neoplasms. *Endoscopy* 2010; 42: 723–729
- 192 Hisabe T, Nagahama T, Hirai F et al. Clinical outcomes of 200 colorectal endoscopic submucosal dissections. *Dig Endosc* 2012; 24: 105–109
- 193 Takeuchi Y, Ohta T, Matsui F et al. Indication, strategy and outcomes of endoscopic submucosal dissection for colorectal neoplasm. *Dig Endosc* 2012; 24: 100–104
- 194 Lee EJ, Lee JB, Lee SH et al. Endoscopic submucosal dissection for colorectal tumors – 1,000 colorectal ESD cases: one specialized institute's experiences. *Surg Endosc* 2013; 27: 31–39
- 195 Repici A, Hassan C, Pagano N et al. High efficacy of endoscopic submucosal dissection for rectal laterally spreading tumors larger than 3 cm. *Gastrointest Endosc* 2013; 77: 96–101 DOI 10.1016/j.gie.2012.08.03
- 196 Rahmi G, Hotayt B, Chaussade S et al. Endoscopic submucosal dissection for superficial rectal tumors: prospective evaluation in France. *Endoscopy* 2014; 46: 670–676
- 197 Oka S, Tanaka S, Kanao H et al. Current status in the occurrence of postoperative bleeding, perforation and residual/local recurrence during colonoscopic treatment in Japan. *Dig Endosc* 2010; 22: 376–380
- 198 Terasaki M, Tanaka S, Shigita K et al. Risk factors for delayed bleeding after endoscopic submucosal dissection for colorectal neoplasms. *Int J Colorectal Dis* 2014; 29: 877–882
- 199 Saito Y, Uraoka T, Yamaguchi Y et al. A prospective, multicenter study of 1111 colorectal endoscopic submucosal dissections (with video). *Gastrointest Endosc* 2010; 72: 1217–1225
- 200 Kudo S, Tamura S, Nakajima T et al. Diagnosis of colorectal tumorous lesions by magnifying endoscopy. *Gastrointest Endosc* 1996; 44: 8–14
- 201 Kato S, Fujii T, Koba I et al. Assessment of colorectal lesions using magnifying colonoscopy and mucosal dye spraying: can significant lesions be distinguished? *Endoscopy* 2001; 33: 306–310
- 202 Bianco MA, Rotondano G, Marmo R et al. Predictive value of magnification chromoendoscopy for diagnosing invasive neoplasia in nonpolypoid colorectal lesions and stratifying patients for endoscopic resection or surgery. *Endoscopy* 2006; 38: 470–476
- 203 Matsuda T, Fujii T, Saito Y et al. Efficacy of the invasive/non-invasive pattern by magnifying chromoendoscopy to estimate the depth of invasion of early colorectal neoplasms. *Am J Gastroenterol* 2008; 103: 2700–2706
- 204 Hayashi N, Tanaka S, Hewett DG et al. Endoscopic prediction of deep submucosal invasive carcinoma: validation of the narrow-band imaging international colorectal endoscopic (NICE) classification. *Gastrointest Endosc* 2013; 78: 625–632
- 205 Hayashi N, Tanaka S, Kanao H et al. Relationship between narrow-band imaging magnifying observation and pit pattern diagnosis in colorectal tumors. *Digestion* 2013; 87: 53–58
- 206 Fernandez-Esparrach G, Ayuso-Colella JR, Sendino O et al. EUS and magnetic resonance imaging in the staging of rectal cancer: a prospective and comparative study. *Gastrointest Endosc* 2011; 74: 347–354
- 207 Hurlstone DP, Brown S, Cross SS et al. High magnification chromoscopic colonoscopy or high frequency 20 MHz mini probe endoscopic ultrasound staging for early colorectal neoplasia: a comparative prospective analysis. *Gut* 2005; 54: 1585–1589
- 208 Gall TM, Markar SR, Jackson D et al. Mini-probe ultrasonography for the staging of colon cancer: a systematic review and meta-analysis. *Colorectal Dis* 2014; 16: 1–8

- 209 Urban O, Kliment M, Fojtik P et al. High-frequency ultrasound probe sonography staging for colorectal neoplasia with superficial morphology: its utility and impact on patient management. *Surg Endosc* 2011; 25: 3393–3399
- 210 Haggitt RC, Glotzbach RE, Soffer EE et al. Prognostic factors in colorectal carcinomas arising in adenomas: implications for lesions removed by endoscopic polypectomy. *Gastroenterology* 1985; 89: 328–336
- 211 Nivatvongs S, Rojanasakul A, Reiman HM et al. The risk of lymph node metastasis in colorectal polyps with invasive adenocarcinoma. *Dis Colon Rectum* 1991; 34: 323–328
- 212 Beaton C, Twine CP, Williams GL et al. Systematic review and meta-analysis of histopathological factors influencing the risk of lymph node metastasis in early colorectal cancer. *Colorect Dis* 2013; 15: 788–797
- 213 Butte JM, Tang P, Gonen M et al. Rate of residual disease after complete endoscopic resection of malignant colonic polyp. *Dis Colon Rectum* 2012; 55: 122–127
- 214 Tominaga K, Nakanishi Y, Nimura S et al. Predictive histopathologic factors for lymph node metastasis in patients with nonpedunculated submucosal invasive colorectal carcinoma. *Dis Colon Rectum* 2005; 48: 92–100
- 215 Choi DH, Sohn DK, Chang HJ et al. Indications for subsequent surgery after endoscopic resection of submucosally invasive colorectal carcinomas: a prospective cohort study. *Dis Colon Rectum* 2009; 52: 438–445
- 216 Westerterp M, Koppert LB, Buskens CJ et al. Outcome of surgical treatment for early adenocarcinoma of the esophagus or gastro-esophageal junction. *Virchows Arch* 2005; 446: 497–504 (Epub 2005 Apr 19)
- 217 Vieth M, Schubert B, Lang-Schwarz K et al. Frequency of Barrett's neoplasia after initial negative endoscopy with biopsy: a long-term histopathological follow-up study. *Endoscopy* 2006; 38: 1201–1205
- 218 Pox C, Aretz S, Bischoff SC et al. Leitlinienprogramm Onkologie der AWMF; Deutschen Krebsgesellschaft e.V.; Deutschen Krebshilfe e.V. [S3-guideline colorectal cancer version 1.0]. *Z Gastroenterol* 2013; 51: 753–854 DOI 10.1055/s-0033-1350264
- 219 Coman RM, Gotoda T, Draganov PV. Training in endoscopic submucosal dissection. *World J Gastrointest Endosc* 2013; 5: 369–378
- 220 Hotta K, Oyama T, Akamatsu T et al. A comparison of outcomes of endoscopic submucosal dissection (ESD) For early gastric neoplasms between high-volume and low-volume centers: multi-center retrospective questionnaire study conducted by the Nagano ESD Study Group. *Intern Med* 2010; 49: 253–259
- 221 Draganov PV, Gotoda T, Chavalitdhamrong D et al. Techniques of endoscopic submucosal dissection: application for the Western endoscopist? *Gastrointest Endosc* 2013; 78: 677–688
- 222 Draganov PV, Coman RM, Gotoda T. Training for complex endoscopic procedures: how to incorporate endoscopic submucosal dissection skills in the West? *Expert Rev Gastroenterol Hepatol* 2014; 8: 119–121
- 223 Imagawa A, Okada H, Kawahara Y et al. Endoscopic submucosal dissection for early gastric cancer: results and degrees of technical difficulty as well as success. *Endoscopy* 2006; 38: 987–990
- 224 Gotoda T, Friedland S, Hamanaka H et al. A learning curve for advanced endoscopic resection. *Gastrointest Endosc* 2005; 62: 866–867
- 225 Kakushima N, Fujishiro M, Kodashima S et al. A learning curve for endoscopic submucosal dissection of gastric epithelial neoplasms. *Endoscopy* 2006; 38: 991–995
- 226 Oda I, Odagaki T, Suzuki H et al. Learning curve for endoscopic submucosal dissection of early gastric cancer based on trainee experience. *Dig Endosc* 2012; 24: 129–132
- 227 Kato M, Gromski M, Jung Y et al. The learning curve for endoscopic submucosal dissection in an established experimental setting. *Surg Endosc* 2013; 27: 154–161
- 228 Herreros de Tejada A. ESD training: A challenging path to excellence. *World J Gastrointest Endosc* 2014; 6: 112–120
- 229 Jung HY. Endoscopic resection for early gastric cancer: current status in Korea. *Dig Endosc* 2012; 24: 159–165
- 230 Rosch T, Sarbia M, Schumacher B et al. Attempted endoscopic en bloc resection of mucosal and submucosal tumors using insulated-tip knives: a pilot series. *Endoscopy* 2004; 36: 788–801
- 231 Kakushima N, Hirasawa K, Morita Y et al. Terminology for training of endoscopic submucosal dissection. *Dig Endosc* 2012; 24: 133–135
- 232 Ribeiro-Mourao F, Pimentel-Nunes P, Dinis-Ribeiro M. Endoscopic submucosal dissection for gastric lesions: results of an European inquiry. *Endoscopy* 2010; 42: 814–819
- 233 Dinis-Ribeiro M, Pimentel-Nunes P, Afonso M et al. A European case series of endoscopic submucosal dissection for gastric superficial lesions. *Gastrointest Endosc* 2009; 69: 350–355
- 234 Catalano F, Trecca A, Rodella L et al. The modern treatment of early gastric cancer: our experience in an Italian cohort. *Surg Endosc* 2009; 23: 1581–1586
- 235 Repici A, Zullo A, Hassan C et al. Endoscopic submucosal dissection of early gastric neoplastic lesions: a western series. *Eur J Gastroenterol Hepatol* 2013; 25: 1261–1264 DOI 10.1097/MEG.0-b013e328364b492
- 236 Schumacher B, Charton JP, Nordmann T et al. Endoscopic submucosal dissection of early gastric neoplasia with a water jet-assisted knife: a Western, single-center experience. *Gastrointest Endosc* 2012; 75: 1166–1174
- 237 Probst A, Golger D, Anthuber M et al. Endoscopic submucosal dissection in large sessile lesions of the rectosigmoid: learning curve in a European center. *Endoscopy* 2012; 44: 660–667
- 238 Thorlacius H, Uedo N, Toth E. Implementation of endoscopic submucosal dissection for early colorectal neoplasms in Sweden. *Gastroenterol Res Pract* 2013; 2013: 758202
- 239 Spychalski M, Dziki A. Safe and efficient colorectal endoscopic submucosal dissection in European settings: Is successful implementation of the procedure possible? *Dig Endosc* 2015; 27: 368–373 DOI 10.1111/den.12353
- 240 Spychalski M, Zelga P, Dziki A. Key factors in achieving successful endoscopic dissection of rectal tumors: early results of 33 consecutive rectal endoscopic submucosal dissections in Polish academic center. *Surg Laparosc Endosc Percutan Tech* 2015; 25: 173–177 DOI 10.1097/SLE.0000000000000111
- 241 Lang GD, Konda VJ, Siddiqui UD et al. A single-center experience of endoscopic submucosal dissection performed in a Western setting. *Dig Dis Sci* 2015; 60: 531–536
- 242 Bialek A, Pertkiewicz J, Karpinska K et al. Treatment of large colorectal neoplasms by endoscopic submucosal dissection: a European single-center study. *Eur J Gastroenterol Hepatol* 2014; 26: 607–615