

ENETS Consensus Guidelines for High-Grade Gastroenteropancreatic Neuroendocrine Tumors and Neuroendocrine Carcinomas

R. Garcia-Carbonero^a H. Sorbye^b E. Baudin^c E. Raymond^d B. Wiedenmann^e
B. Niederle^f E. Sedlackova^g C. Toumpanakis^h M. Anlaufⁱ J.B. Cwikla^j
M. Caplin^k D. O'Toole^l A. Perren^m
all other Vienna Consensus Conference participants

^aMedical Oncology Department, Hospital Universitario Doce de Octubre, Madrid, Spain; ^bDepartment of Oncology, Haukeland University Hospital, Bergen, Norway; ^cInstitut Gustave Roussy, Villejuif, and ^dOncologie Médicale, Hôpitaux Universitaires Paris Nord Val de Seine, Paris, France; ^eDepartment of Hepatology and Gastroenterology, Campus Virchow Klinikum, Charité Universitätsmedizin Berlin, Berlin, Germany; ^fDepartment of Surgery, Medical University of Vienna, Vienna, Austria; ^gDepartment of Oncology, First Faculty of Medicine and General Teaching Hospital, Prague, Czech Republic; ^hNeuroendocrine Tumour Unit, Royal Free Hospital, London, UK; ⁱInstitut für Pathologie und Zytologie, St. Vincenz Krankenhaus, Limburg, Germany; ^jDepartment of Radiology, Faculty of Medical Sciences, University of Warmia and Mazury, Olsztyn, Poland; ^kNeuroendocrine Tumour Unit, Royal Free Hospital, London, UK; ^lNET Centre, St. Vincent's University and Department of Clinical Medicine, St. James Hospital and Trinity College, Dublin, Ireland; ^mInstitute of Pathology, University of Bern, Bern, Switzerland

Introduction

Neuroendocrine carcinomas (NEC) are rare in the gastrointestinal (GI) tract, whereas they are frequent in the form of small cell carcinoma (SCLC) in the lung. Therefore, most of the suggested guidelines arise from analogy to SCLC. As for other extrapulmonary primary tumor locations, published data on NEC of the GI tract are scarce. This guideline encompasses all WHO grade 3 (G3) gastroenteropancreatic (GEP) neoplasms; however, in the future, G3 neuroendocrine neoplasms (NEN) will probably be separated according to differentiation, as explained below, and potentially according to organ of origin, such as for well-differentiated neuroendocrine tumors (NET) G1/G2.

According to the WHO classification of 2010, NEC are defined as poorly differentiated NEN with Ki-67 >20% and hence G3. Increasing evidence suggests that G3 NEN

are not a homogenous entity and can be further subclassified into biologically relevant subgroups. A separation based on the proliferative index (Ki-67 >55%) was shown to have clinical implications regarding response to chemotherapy and prognosis: NEC with Ki-67 >55% responded better to platinum-based chemotherapy and, nevertheless, had a 4 months' shorter median survival than G3 NEN in the lower proliferative range (20–55%) [1]. More recent publications show that morphological differentiation and Ki-67 are able to separate prognostic groups among G3 cases, and therefore a separation of well-differentiated G3 NET from poorly differentiated G3 NEC is emerging [2–4]. The exact criteria need to be defined both on the morphological and on the molecular level. The spectrum of mutations of well-differentiated

For an alphabetical list of all other Vienna Consensus Conference participants, see Appendix.

pancreatic NET is different from that of pancreatic NEC [5], suggesting different ways of tumorigenesis. However, to date there are no solid data that adequately address the implications of these observations in terms of treatment effect of the different available regimens.

Epidemiology

The GEP tract is the most common site of extrapulmonary NEC, accounting for 35–55% of all NEC originating from the lung. Only about 5% of all GI NEN have Ki-67 >20% [6, 7]. This frequency might differ by organ, with about 7% in the pancreas [7] and up to 40% in the colon [8]. GEP NEC are therefore very rare neoplasms representing <1% of all GI malignancies. Up to 85% have metastases at the time of diagnosis (65% distant) [1, 6]. Metastases are most frequently found in the liver (70%) followed by the lung (15%), bone (15%) and brain (4%) [1]. No gender difference has been identified. The mean age at diagnosis is 60 years [1].

Clinicopathological Features

As the great majority of these tumors are not associated with a hormonal syndrome (<5%), and more than two thirds of all patients present with advanced disease, clinical presentation is dominated by tumor-derived site-specific symptoms and the constitutional syndrome characteristics of advanced cancer (anorexia, weight loss and fatigue). Depending upon tumor location, a wide variety of symptoms may occur. The neuroendocrine nature of these tumors is generally not suspected from the clinical presentation, although as in SCLC paraneoplastic syndromes may occur in some patients (i.e., Cushing or Inappropriate ADH Secretion Syndromes). A detailed anamnesis and physical examination are fundamental to appropriately guide diagnostic procedures.

According to the WHO 2010 classification, NEC are poorly differentiated highly aggressive neoplasms, sometimes with organoid features, marked nuclear atypia and multifocal necrosis [9]. A diffuse expression of neuroendocrine markers (diffuse for synaptophysin, focal for chromogranin A, and the latter may be absent) separates the entity pathologically from poorly differentiated carcinoma.

The grading introduced by ENETS in 2006 [10] of NEC is by definition G3, either based on a proliferation index >20% or >20 mitoses in 10/HPF. This proposition

has been adopted by the WHO classification and was shown repeatedly to be clinically applicable in predicting a very aggressive subset of NEN [7].

Prognosis and Survival

Survival is poor in NEC, ranging from 38 months for patients with localized disease to 5 months in the metastatic setting according to the SEER population registry data, which involved 2,546 patients diagnosed with GI NEC from 1973 to 2012 in the USA [11]. Median survival in the metastatic setting may be as short as 1 month for patients receiving only best supportive care, up to 12–19 months for those treated with best available therapy [1, 12]. Only 5% of all patients are long-time survivors [7]. Progression-free survival after cisplatin-based chemotherapy and overall survival differs according to the location of the primary tumor, with poorer reported outcomes in esophageal, colonic and rectal NEC compared to gastric and pancreatic ones in some large European series [1]. In contrast, survival of pancreatic NEC was poorer in Japanese patients [13]. A poor performance status, high proliferation rate, elevated baseline lactate dehydrogenase (LDH) and thrombocytosis are other factors that have also been associated with a worse prognosis.

Diagnostic Procedures

Biochemical Tests

Plasma chromogranin A may be elevated in up to two thirds of patients with advanced NEC [1], although the levels are generally lower than those observed in well-differentiated tumors [14, 15]. In contrast, the levels of other tumor markers such as neuron-specific enolase (NSE) are higher in poorly differentiated tumors than in NET, and they are significantly associated with survival. However, the role of circulating tumor markers to predict and monitor outcome has not been properly assessed in extrapulmonary NEC. Screening for other hormonal markers is not justified unless clinically indicated.

Endoscopic and Imaging Procedures

Endoscopic examination of the primary tumor site is recommended, which is also useful to obtain a biopsy for histological diagnosis. If this is not feasible, endoscopic ultrasound-guided or percutaneous procedures can be useful. Once the histological diagnosis of a G3 NEC has been confirmed, complete staging using whole-body CT

scan or MRI should be performed to assess the extent of disease and to design the most appropriate therapeutic strategy. A lung primary should be reasonably excluded (negative imaging studies of the lung). FDG-PET may be useful if radical surgery is being pursued or if clarification of equivocal findings on conventional imaging may change the therapeutic approach. Radiolabeled somatostatin analogue scans are not routinely recommended, as poorly differentiated tumors generally do not express somatostatin receptors. However, data from large series indicate positive SRI findings in a substantial proportion of patients with certain primary tumors (up to 45% of pancreatic NEC), particularly those with proliferative indexes in the low range of G3, and may differ by histological subtype (45% of small cell vs. 32% of large cell NEC) [1]. In the absence of neurological symptoms, brain CT or MRI are not recommended, as the incidence of brain metastasis in extrapulmonary NEC is rather low (<5%) [1]. Bone scans are neither indicated if there is no clinical or biochemical suspicion of bone metastasis. In the presence of elevated LDH, peripheral blood leukoerythroblastosis or thrombocytopenia, a bone marrow biopsy may be considered.

Minimal Consensus Statement

Clinical signs and symptoms should guide the appropriate diagnostic procedures (summarized in fig. 1). Chromogranin A and NSE testing is not mandatory, although they may be useful if elevated at diagnosis. A proper assessment of their utility in extrapulmonary NEC is, however, pending. Other hormone tests are not routinely recommended.

A minimal diagnostic workup should include site-specific endoscopic assessment with tumor biopsy, and whole-body CT scan (and/or MRI) for tumor staging. In patients with metastatic disease, an ultrasound-guided percutaneous biopsy may be performed if feasible. Somatostatin receptor scintigraphy is not routinely indicated but may be considered in tumors with proliferative indexes in the low range of G3 (Ki-67 <55%). Bone scans or brain imaging (CT or MRI) should not be performed in the absence of site-specific symptoms. FDG-PET may be considered in patients in whom radical surgery is being pursued or if clarification of equivocal findings on conventional imaging may change the therapeutic approach. FDG-PET may be useful in resectable cases for whole body assessment.

Histopathology and Genetics of Poorly Differentiated NEC

Histopathologically, NEC show a neuroendocrine phenotype by immunohistochemistry, in large cell NEC a positivity for synaptophysin is mandatory, chromo-

granin A staining is variable and may be weak or absent. Rarely, both markers may be negative in small cell NEC (<5% [1]). Other neuroendocrine markers such as NSE or CD56 are less specific and must be used with caution. Ki-67 is by definition >20% [10] and in half of the cases, it is >55% [1]. Punctate or geographic necrosis is frequent. Reporting of the immunohistochemical results above as well as the proliferative index by mitosis is essential. Somatostatin receptor 2A (Sstr 2a) immunohistochemistry is optional [16, 17]. Over 90% of G3 NEC do not produce hormones [17].

In the setting of a carcinoma of unknown primary, the expression of transcription factors such as Ttf1, Cdx-1 or Isl1 cannot be used to help localize the site of the primary tumor [18].

Care must be taken to differentiate NEC from poorly differentiated adenocarcinoma, especially in certain organs such as the pancreas, where a differential diagnosis with acinic cell carcinoma may be particularly challenging [19]. NEC are separated into large cell and small cell types; however, no clear clinicopathological differences between the two types have been shown for the pancreas [19].

Pancreatic NEC show a genetic profile different from NET with frequent mutations in p53 and RB [5] and a much higher mutation rate (in review), similar to pulmonary small cell carcinoma. Furthermore, up to 40% of all NEC present a minor component of adenocarcinoma (colon [20], stomach [21]) or squamous cell carcinoma (esophagus, anus). If the non-endocrine component exceeds 30%, the neoplasm is classified as mixed adenoneuroendocrine carcinoma. Differentiation together with proliferation and mutation spectrum will be important in discriminating G3 NET from G3 NEC in the future [2–4].

Minimal Consensus Statement

A routine pathological report should include morphology (large cell vs. small cell and differentiation), staining for chromogranin A and synaptophysin and Ki-67 estimate or/and mitotic count.

Treatment

Evidence to support treatment recommendations for GEP G3 NEC is scarce and derives from limited retrospective series and very few small non-controlled clinical trials. Most investigators, therefore, treat this entity in analogy to the much more common SCLC due to

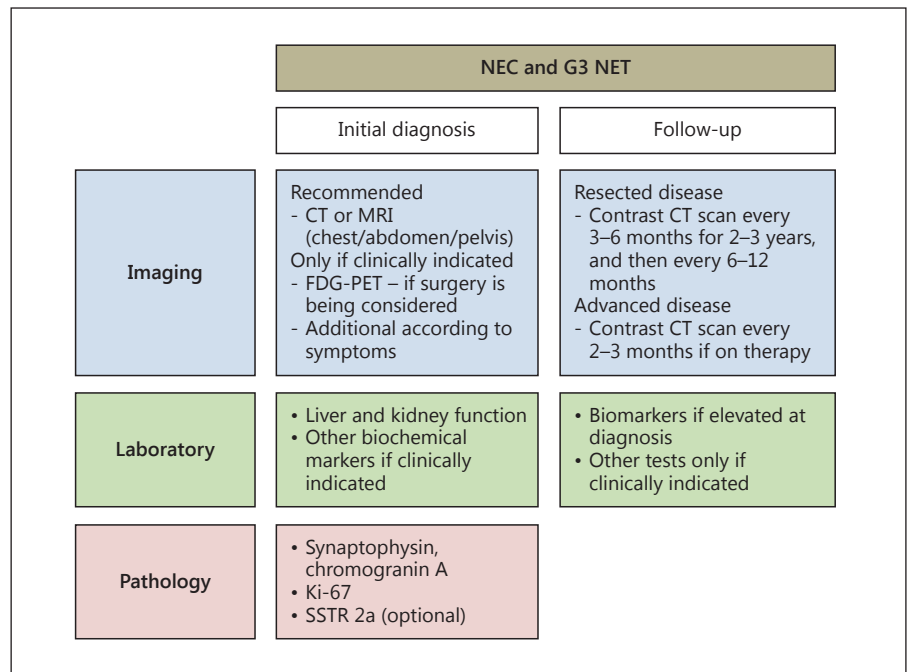


Fig. 1. Diagnostic algorithm for NEC and G3 NET.

their histological and clinical resemblance. Bearing these caveats in mind, guidance is hereby provided (fig. 2). Nevertheless, generating prospective and preferably controlled data is greatly needed and encouraged in this setting.

Surgery

Curative surgery is usually attempted in localized disease, although retrospective series indicate that it is rarely curative as a sole therapeutic modality [22]. Given the high relapse rate observed following radical surgery, most clinicians would advocate platinum-based adjuvant therapy in this setting. Data reported by Casas et al. of a large series of esophageal small cell carcinomas support this approach [23]. In this study, survival was 20 months for patients who received systemic chemotherapy in addition to local treatment versus only 5 months for those who were treated with local therapy only, and the type of treatment was found to be an independent prognostic factor in multivariate analysis. Some authors propose neoadjuvant chemotherapy followed by definitive surgery, although data to support this approach are scarce [24]. In patients with important comorbidities or where the tumor's anatomical site makes surgical resection not advisable due to high morbidity (i.e., esophagus), a definitive course of radiotherapy and chemotherapy is a reasonable treatment strategy.

In the context of advanced metastatic disease, debulking or cytoreductive surgery and surgical resection of metastasis are not recommended. Other ablative strategies of liver metastasis (i.e., radiofrequency ablation, TACE) are also discouraged.

Medical Therapy

Chemotherapy is an essential part of the multimodality approach for localized NEC and the mainstay of care in advanced disease. Survival of patients with metastatic NEC treated with chemotherapy varies widely (from 7 to 19 months) but shows a substantial improvement over that reported for patients that receive only best supportive care (1 month). No randomized studies, however, have properly addressed the magnitude of this effect so far. Swift referral for consideration of palliative chemotherapy is recommended as performance status deterioration may occur rapidly and preclude further therapy. Based on their established role in metastatic SCLC, cisplatin and etoposide (EP) have been one of the most widely used regimens in GEP NEC (table 1) [1, 13, 25–29], with response rates in the largest most recent series of ~30% and median survival of around one year. In one of the largest series published to date, Sørbye et al. [1] observed that Ki-67 was significantly associated with response to chemotherapy. Indeed, patients with Ki-67 values >55% had a greater response rate (42 vs. 15%) al-

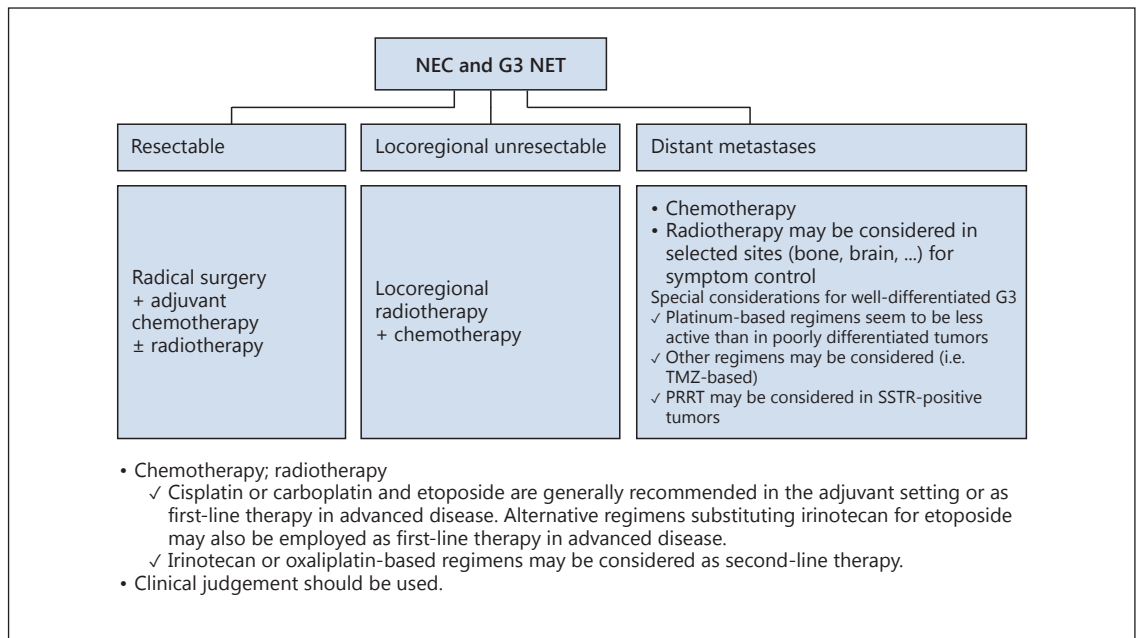


Fig. 2. Therapeutic algorithm for NEC and G3 NET.

though poorer survival (10 vs. 14 months) than patients with Ki-67 values <55%. Other negative prognostic factors in this study were a poor performance status, primary colorectal tumors and elevated platelets or LDH levels, which were all associated with decreased survival.

Alternative regimens substituting carboplatin for cisplatin, or irinotecan for EP, have been validated in SCLC and seem at least equivalent in terms of efficacy in limited series of GEP NEC (table 1) [13, 30–35], with different toxicity profiles. In the context of advanced stage SCLC, a randomized study conducted in Japan demonstrated that the combination of irinotecan and cisplatin (IP) was associated with improved overall survival as compared to the standard cisplatin and EP combination [36]. Two subsequent randomized Western trials, however, failed to confirm this superiority. Both regimens produced comparable efficacy, with less hematological and greater GI toxicity with the IP combination (particularly diarrhea and vomiting) [37, 38]. Consistent with these findings, large retrospective data of systemic chemotherapy for advanced GEP NEC from 23 Japanese institutions documented that the IP regimen was associated with greater response rates (50 vs. 28%) and survival (13 vs. 7 months) than the EP regimen, and this difference was more remarkable in hepatobiliarypancreatic NEC. Prognostic factors in this study included primary

tumor site (those with hepatobiliarypancreatic primaries having the worst prognosis) and elevated baseline LDH levels, whereas treatment schedule was not an independent predictive factor for survival. Three-drug regimens such as cisplatin, EP and paclitaxel do not seem to substantially improve efficacy and are significantly more toxic [39].

Evidence for salvage therapy in patients progressing on first-line platinum-based regimens is very limited (table 1) [1, 13, 40–45]. Overall, response rates are lower (18% in the NORDIC NEC study), although small series have documented response rates of 23–40% with oxaliplatin-based (XELOX, FOLFOX) or irinotecan-based (FOLFIRI, IP) regimens. Welin et al. reported a 33% response rate with temozolomide, alone or in combination with capecitabine and bevacizumab, in a cohort of 25 patients with poorly differentiated NEC (17 of GEP origin) [44]. A Ki-67 index <60% was predictive for response to treatment and survival. In contrast, no responses were observed in another series of 28 NEC cases treated with temozolomide monotherapy [45]. Retreatment with platinum/EP may also be considered in patients that achieve good durable responses upfront and progress after a treatment break of at least 3 months, provided no cumulative toxicity (i.e., neurotoxicity, ototoxicity) precludes further treatment with platinum

Table 1. Series of patients with advanced G3 NEC of the GI tract treated with chemotherapy

First author	Patients, n	Primary site	Chemotherapy regimen	RR, %	Survival, months
<i>First-line therapy</i>					
Moertel [25]	18	GEP (14), lung (1), UKP (3)	Cisplatin/EP	67	19
Mitry [26]	41	GEP (20), lung (10), H&N (4), UKP (7)	Cisplatin/EP	42	15
Deutschbein [28]	18	G3 NEC (primary NR)	Cisplatin/EP +/- paclitaxel	17	NR
Iwasa [27]	21	Hepatobiliary and pancreas	Cisplatin/EP	14	6
Patta [29]	8	Colorectal	Cisplatin/EP	63	10
Sørbye [1]	252	GEP (69%), UKP (31%)			
	129		Cisplatin/EP	31	12
	67		Carboplatin/EP	30	11
Hainsworth [39]	78	GEP (15), lung (7), skin (4), other (4), UKP (48)	Paclitaxel/carboplatin/EP	53	15
Ramella [30]	27	GEP (18), H&N (1), GU (1), UKP (7)	Platinum/irinotecan	46	12
Okita [31]	12	Gastric	IP	75	23
Nakano [32]	35	GEP (9), H&N (18), GU/GYN (5), UKP (12)	IP	64	NR
Okuma [33]	12	Esophagus	IP	50	13
Lu [34]	16	GEP	IP	57	11
Kulke [35]	4	GEP/UKP	IP	25	NR
Yamaguchi [13]	258	GEP NEC/MANEC			
	160		IP	50	13
	46		Cisplatin/EP	28	7
<i>Second- or third-line therapy</i>					
Hentic [40]	19	GEP	FOLFIRI	31	18
Welin [44]	25	GEP (17), UKP (5), lung (3)	Temozolomide +/- capecitabine +/- bevacizumab	33	22
Olsen [45]	28	GEP (18), UKP (6), lung (1), GU (3)	Temozolomide	0	4
Bajetta [41]	13	GEP (58%)	XELOX	23	NR
Ferrarotto [42]	9	GEP (75%)	XELOX	29	NR
Hadoux [43]	20	G3 NEC (primary NR)	FOLFOX	29	10
Yamaguchi [13]	25	GEP NEC/MANEC	Amrubicin	4	8
	23	GEP NEC/MANEC	Platinum/EP	17	5
	21	GEP NEC/MANEC	Irinotecan	5	6
	11	GEP NEC/MANEC	S-1	27	12
	5	GEP NEC/MANEC	IP	40	9
Sørbye [1]	100	GEP, UKP	Various (Taxane-22; Tmz-35)	18	19

GU = Genitourinary; GYN = gynecological; H&N = head and neck; MANEC = mixed adenoneuroendocrine carcinoma; NR = not reported; RR = response rate; UKP = unknown primary.

agents. Other agents tested include amrubicin, S-1 or taxanes (table 1).

Other Treatment Options (Radiotherapy, PRRT)

In contrast to recommendations for patients with limited-stage SCLC, prophylactic cranial irradiation is not indicated in patients with successfully treated localized GEP NEC, as the incidence of brain metastasis in patients with extrapulmonary NEC is rather low. Palliative radiotherapy may be considered for localized bone

metastasis to control pain or to prevent skeletal complications.

Although a subgroup of NEC expresses somatostatin receptors, there are no data to support the use of somatostatin analogs in this context. Some case reports have communicated long-lasting responses to peptide receptor radionucleotide therapy (PRRT) in NEC with high expression of somatostatin receptors, but this therapeutic strategy is generally not successful in the majority of G3 tumors [46].

Minimal Consensus Statement on Treatment

For patients with localized disease, a combination of platinum-based chemotherapy with local treatment consisting of surgery, radiotherapy or both probably offers the greatest likelihood of long-term survival. Debulking or surgical resection of metastasis is not recommended. Systemic chemotherapy is indicated in advanced inoperable disease, provided the patient has adequate organ function and performance status, otherwise the patient should be rapidly referred for consideration of palliative chemotherapy. The combination of cisplatin and EP, or alternative regimens substituting carboplatin for cisplatin or irinotecan for EP, are recommended as first-line therapy. Since response rates of these regimens are lower in patients with a Ki-67 value in the lower range of G3 (20–55%), other treatment options may be explored in these patients (especially for NEC of GI origin). While second-line regimens have not been evaluated rigorously, options include temozolomide-, irinotecan- or oxaliplatin-based schedules as main alternatives. There are no data to support the use of somatostatin analogs or PRRT in patients with GEP NEC expressing somatostatin receptors. Prophylactic cranial irradiation is not indicated in patients with limited-stage disease in complete remission.

Follow-Up

Follow-up recommendations are based on expert opinion as there is no solid evidence to support the type and frequency of performance of specific procedures. Patients with localized G3 NEC who have undergone complete resection are recommended to be followed every 3–6 months during the first 2–3 years following surgery, and then every 6–12 months up to 5 years. Conventional imaging (CT scan or MRI) should be performed during these follow-up visits, but testing for general tumor markers (i.e., chromogranin A or NSE) is only indicated if elevated at diagnosis. Somatostatin receptor imaging procedures are generally not warranted in this setting, particularly if negative at diagnosis. FDG-PET may be indicated if equivocal findings are encountered on conventional imaging and/or if salvage surgery is being considered.

Follow-up of patients with advanced disease should be customized depending upon tumor kinetics (the Ki-67 proliferative index and the actual growth rate documented by serial CT scans), treatment strategy, side effects of therapy and general health condition. Clinical assessment visits should be scheduled frequently, as these patients generally present fast tumor kinetics, are highly symptomatic and/or receive toxic agents. Clinical judgement is advised to establish the appropriate assessment interval. Conventional imaging procedures are recommended to be performed every 2–3 months while on active therapy.

Minimal Consensus Statement

In patients with localized R0/R1 resected G3 NEC, conventional imaging (CT and/or MRI) and assessment of circulating tumor markers (if elevated at baseline) are recommended to be performed every 3 months during the first 2–3 years after surgical resection, and every 6–12 months up to 5 years following surgery. In patients with advanced disease G3 NEC, frequent clinical assessment visits should be performed, and conventional imaging is recommended every 2–3 months while on active therapy.

Please also refer to consensus guideline updates for other GEP NET [47–52, this issue].

Appendix

All Other Vienna Consensus Conference Participants

Bartsch, D.K. (Department of Surgery, Philipps University, Marburg, Germany); Capdevila, J. (Institute of Oncology, Vall d'Hebron University Hospital, Barcelona, Spain); Costa, F. (Centro de Oncologia, Hospital Sírio Libanês, São Paulo, Brazil); De Herder, W.W. (Department of Internal Medicine, Division of Endocrinology, Erasmus Medical Center, Rotterdam, The Netherlands); Delle Fave, G. (Department of Digestive and Liver Disease, Ospedale Sant'Andrea, Rome, Italy); Eriksson, B. (Department of Endocrine Oncology, University Hospital, Uppsala, Sweden); Falconi, M. (Department of Surgery, San Raffaele Hospital, Università Vita e Salute, Milan, Italy); Ferolla, P. (NET Center, Umbria Regional Cancer Network, Università degli Studi di Perugia, Perugia, Italy); Ferone, D. (Department of Endocrine and Metabolic Sciences, University of Genoa, Genoa, Italy); Gross, D. (Department of Endocrinology and Metabolism, Hadassah University Hospital, Mevasseret Tsion, Israel); Ito, T. (Pancreatic Diseases Branch, Kyushu University Hospital, Fukuoka, Japan); Jensen, R.T. (Digestive Diseases Branch, NIH, Bethesda, Md., USA); Kaltsas, G. (Department of Pathophysiology, Division of Endocrinology, National University of Athens, Athens, Greece); Kelestimir, F. (Department of Endocrinology, Erciyes University Medical School, Kayseri, Turkey); Kianmanesh, R. (Department of Surgery, CHU Robert Debré, Reims, France); Klöppel, G. (Institute of Pathology, Technische Universität München, Munich, Germany); Knigge, U. (Neuroendocrine Tumor Center of Excellence, Rigshospitalet, Copenhagen University Hospital, Copenhagen, Denmark); Kos-Kudla, B. (Department of Endocrinology, Medical University of Silesia, Katowice, Poland); Krenning, E. (Department of Internal Medicine, Division of Nuclear Medicine, Erasmus Medical Center, Rotterdam, The Netherlands); Kwekkeboom, D. (Department of Internal Medicine, Division of Nuclear Medicine, Erasmus Medical Center, Rotterdam, The Netherlands); Öberg, K. (Department of Medical Sciences, Endocrine Oncology Unit, University Hospital, Uppsala, Sweden); O'Connor, J. (Department of Clinical Oncology, Institute Alexander Fleming, Buenos Aires, Argentina); Pape, U.-F. (Department of Hepatology and Gastroenterology, Campus Virchow Klinikum, Charité Universitätsmedizin Berlin, Berlin, Germany); Pascher, A. (Department of Visceral and Transplant Surgery, Campus VirchowKlinikum, Charité Universitätsmedizin Berlin, Berlin, Germany); Pavel, M. (Department of Hepatology and Gastroenterology, Campus Virchow Klinikum,

Charité Universitätsmedizin Berlin, Berlin, Germany); Ramage, J.K. (Gastroenterology Department, Hampshire Hospitals NHS Trust, Hampshire, UK); Reed, N. (Beatson Oncology Centre, Gartnavel General Hospital, Glasgow, UK); Rindi, G. (Institute of Anatomic Pathology, Policlinico A. Gemelli, Università Cattolica del Sacro Cuore, Rome, Italy); Ruzsniowski, P. (Department of Gastroenterology, Beaujon Hospital, Clichy, France); Sundin, A. (De-

partment of Radiology, Section for Molecular Imaging, University Hospital, Uppsala, Sweden); Taal, B. (Netherlands Cancer Centre, Lijnden, The Netherlands); Weber, W. (Department of Radiology, Memorial Sloan Kettering Cancer Center, New York, N.Y., USA); Zheng-Pei, Z. (Department of Endocrinology, Peking Union Medical College Hospital, Beijing, China).

References

- 1 Sorbye H, et al: Predictive and prognostic factors for treatment and survival in 305 patients with advanced gastrointestinal neuroendocrine carcinoma (WHO G3): the NORDIC NEC study. *Ann Oncol* 2013;24:152–160.
- 2 Tang LH, et al: Well differentiated neuroendocrine tumors with a morphologically apparent high grade component: a pathway distinct from poorly differentiated neuroendocrine carcinomas. *Clin Cancer Res* 2016;22:1011–1017.
- 3 Basturk O, et al: The high-grade (WHO G3) pancreatic neuroendocrine tumor category is morphologically and biologically heterogeneous and includes both well differentiated and poorly differentiated neoplasms. *Am J Surg Pathol* 2015;39:683–690.
- 4 Heetfeld M, et al: Characteristics and treatment of patients with G3 gastroenteropancreatic neuroendocrine neoplasms. *Endocr Relat Cancer* 2015;22:657–664.
- 5 Yachida S, et al: Small cell and large cell neuroendocrine carcinomas of the pancreas are genetically similar and distinct from well-differentiated pancreatic neuroendocrine tumors. *Am J Surg Pathol* 2012;36:173–184.
- 6 Garcia-Carbonero R, et al: Incidence, patterns of care and prognostic factors for outcome of gastroenteropancreatic neuroendocrine tumors (GEP-NETs): results from the National Cancer Registry of Spain (RGETNE). *Ann Oncol* 2010;21:1794–1803.
- 7 Rindi G, et al: TNM staging of neoplasms of the endocrine pancreas: results from a large international cohort study. *J Natl Cancer Inst* 2012;104:764–777.
- 8 Niederle MB, et al: Gastroenteropancreatic neuroendocrine tumours: the current incidence and staging based on the WHO and European Neuroendocrine Tumour Society classification: an analysis based on prospectively collected parameters. *Endocr Relat Cancer* 2010;17:909–918.
- 9 Bosman FT, et al. (eds): WHO Classification of Tumors of the Digestive System, ed 4. Lyon, WHO, 2010.
- 10 Rindi G, et al: TNM staging of foregut (neuro) endocrine tumors: a consensus proposal including a grading system. *Virchows Arch* 2006;449:395–401.
- 11 Sorbye H, et al: Gastroenteropancreatic high-grade neuroendocrine carcinoma. *Cancer* 2014;120:2814–2823.
- 12 Strosberg J, et al: Correlation between grade and prognosis in metastatic gastroenteropancreatic neuroendocrine tumors. *Hum Pathol* 2009;40:1262–1268.
- 13 Yamaguchi T, et al: Multicenter retrospective analysis of systemic chemotherapy for advanced neuroendocrine carcinoma of the digestive system. *Cancer Sci* 2014;105:1176–1181.
- 14 Korse CM, et al: Choice of tumour markers in patients with neuroendocrine tumours is dependent on the histological grade. A marker study of Chromogranin A, Neuron specific enolase, Progastrin-releasing peptide and cytokeratin fragments. *Eur J Cancer* 2012;48:662–671.
- 15 Baudin E, et al: Neuron-specific enolase and chromogranin A as markers of neuroendocrine tumours. *Br J Cancer* 1998;78:1102.
- 16 Korner M, et al: Somatostatin receptor subtype 2A immunohistochemistry using a new monoclonal antibody selects tumors suitable for in vivo somatostatin receptor targeting. *Am J Surg Pathol* 2012;36:242–252.
- 17 Rindi G, et al: Gastric carcinoids and neuroendocrine carcinomas: pathogenesis, pathology, and behavior. *World J Surg* 1996;20:168–172.
- 18 Agaimy A, et al: ISL1 expression is not restricted to pancreatic well-differentiated neuroendocrine neoplasms, but is also commonly found in well and poorly differentiated neuroendocrine neoplasms of extrapancreatic origin. *Mod Pathol* 2013;26:995–1003.
- 19 Basturk O, et al: Poorly differentiated neuroendocrine carcinomas of the pancreas: a clinicopathologic analysis of 44 cases. *Am J Surg Pathol* 2014;38:437–447.
- 20 Li Y, et al: Colorectal glandular-neuroendocrine mixed tumor: pathologic spectrum and clinical implications. *Am J Surg Pathol* 2011;35:413–425.
- 21 Namikawa T, et al: Primary gastric small cell carcinoma: report of a case and review of the literature. *Med Mol Morphol* 2005;38:256–261.
- 22 Brenner B, et al: Small cell carcinomas of the gastrointestinal tract: clinicopathological features and treatment approach. *Semin Oncol* 2007;34:43–50.
- 23 Casas F, et al: Primary small cell carcinoma of the esophagus. *Cancer* 1997;80:1366–1372.
- 24 Sorbye H, Westre B, Horn A: Curative surgery after neoadjuvant chemotherapy in metastatic poorly differentiated neuroendocrine carcinoma. *Eur J Surg Oncol* 2007;33:1209–1210.
- 25 Moertel CG, et al: Treatment of neuroendocrine carcinomas with combined etoposide and cisplatin. Evidence of major therapeutic activity in the anaplastic variants of these neoplasms. *Cancer* 1991;68:227–232.
- 26 Mitry E, et al: Treatment of poorly differentiated neuroendocrine tumours with etoposide and cisplatin. *Br J Cancer* 1999;81:1351.
- 27 Iwasa S, et al: Cisplatin and etoposide as first-line chemotherapy for poorly differentiated neuroendocrine carcinoma of the hepatobiliary tract and pancreas. *Jpn J Clin Oncol* 2010;40:313–318.
- 28 Deutschbein T, et al: Chemotherapy in patients with progressive, undifferentiated neuroendocrine tumors: a single-center experience. *Horm Metab Res* 2011;43:838–843.
- 29 Patta A, Fakih M: First-line cisplatin plus etoposide in high-grade metastatic neuroendocrine tumors of colon and rectum (MCRC NET): review of 8 cases. *Anticancer Res* 2011;31:975–978.
- 30 Ramella Munhoz R, et al: Combination of irinotecan and a platinum agent for poorly differentiated neuroendocrine carcinomas. *Rare Tumors* 2013;5:e39.
- 31 Okita NT, et al: Neuroendocrine tumors of the stomach: chemotherapy with cisplatin plus irinotecan is effective for gastric poorly-differentiated neuroendocrine carcinoma. *Gastric Cancer* 2011;14:161–165.
- 32 Nakano K, et al: Feasibility and efficacy of combined cisplatin and irinotecan chemotherapy for poorly differentiated neuroendocrine carcinomas. *Jpn J Clin Oncol* 2012;42:697–703.
- 33 Okuma HS, et al: Irinotecan plus cisplatin in patients with extensive-disease poorly differentiated neuroendocrine carcinoma of the esophagus. *Anticancer Res* 2014;34:5037–5041.
- 34 Lu Z, et al: Feasibility and efficacy of combined cisplatin plus irinotecan chemotherapy for gastroenteropancreatic neuroendocrine carcinomas. *Med Oncol* 2013;30:1–5.
- 35 Kulke MH, et al: A phase II trial of irinotecan and cisplatin in patients with metastatic neuroendocrine tumors. *Dig Dis Sci* 2006;51:1033–1038.

- 36 Noda K, et al: Irinotecan plus cisplatin compared with etoposide plus cisplatin for extensive small-cell lung cancer. *N Engl J Med* 2002;346:85–91.
- 37 Hanna N, et al: Randomized phase III trial comparing irinotecan/cisplatin with etoposide/cisplatin in patients with previously untreated extensive-stage disease small-cell lung cancer. *J Clin Oncol* 2006;24:2038–2043.
- 38 Lara PN, et al: Phase III trial of irinotecan/cisplatin compared with etoposide/cisplatin in extensive-stage small-cell lung cancer: clinical and pharmacogenomic results from SWOG S0124. *J Clin Oncol* 2009;27:2530–2535.
- 39 Hainsworth JD, et al: Phase II trial of paclitaxel, carboplatin, and etoposide in advanced poorly differentiated neuroendocrine carcinoma: a Minnie Pearl Cancer Research Network Study. *J Clin Oncol* 2006;24:3548–3554.
- 40 Hentic O, et al: FOLFIRI regimen: an effective second-line chemotherapy after failure of etoposide-platinum combination in patients with neuroendocrine carcinomas grade 3. *Endocr Relat Cancer* 2012;19:751–757.
- 41 Bajetta E, et al: Are capecitabine and oxaliplatin (XELOX) suitable treatments for progressing low-grade and high-grade neuroendocrine tumours? *Canc Chemother Pharmacol* 2007;59:637–642.
- 42 Ferrarotto R, et al: Combination of capecitabine and oxaliplatin is an effective treatment option for advanced neuroendocrine tumors. *Rare Tumors* 2013;5:e35.
- 43 Hadoux J, et al: Post-first-line FOLFOX chemotherapy for grade 3 neuroendocrine carcinoma. *Endocr Relat Cancer* 2015;22:289–298.
- 44 Welin S, et al: Clinical effect of temozolomide-based chemotherapy in poorly differentiated endocrine carcinoma after progression on first-line chemotherapy. *Cancer* 2011;117:4617–4622.
- 45 Olsen IH, et al: Temozolomide as second or third line treatment of patients with neuroendocrine carcinomas. *ScientificWorldJournal* 2012;2012:170496.
- 46 Ezziddin S, et al: Impact of the Ki-67 proliferation index on response to peptide receptor radionuclide therapy. *Eur J Nucl Med Mol Imaging* 2011;38:459–466.
- 47 Delle Fave G, O'Toole D, Sundin A, Taal B, Ferolla P, Ramage JK, Ferone D, Ito T, Weber W, Zheng-Pei Z, De Herder WW, Pascher A, Ruzniewski P; all other Vienna Consensus Conference participants: ENETS consensus guidelines update for gastroduodenal neuroendocrine neoplasms. *Neuroendocrinology* 2016;103:119–124.
- 48 Niederle B, Pape UF, Costa F, Gross D, Kelestimur F, Knigge U, Öberg K, Pavel M, Perren A, Toumpanakis C, O'Connor J, O'Toole D, Krenning E, Reed N, Kianmanesh R; all other Vienna Consensus Conference participants: ENETS consensus guidelines update for neuroendocrine neoplasm of the jejunum and ileum. *Neuroendocrinology* 2016;103:125–138.
- 49 Ramage JK, De Herder WW, Delle Fave G, Ferolla P, Ferone D, Ito T, Ruzniewski P, Sundin A, Weber W, Zheng-Pei Z, Taal B, Pascher A; all other Vienna Consensus Conference participants: ENETS consensus guidelines update for colorectal neuroendocrine neoplasms. *Neuroendocrinology* 2016;103:139–143.
- 50 Pape UF, Niederle B, Costa F, Gross D, Kelestimur F, Kianmanesh R, Knigge U, Öberg K, Pavel M, Perren A, Toumpanakis C, O'Connor J, Krenning E, Reed N, O'Toole D; all other Vienna Consensus Conference participants: ENETS consensus guidelines for neuroendocrine neoplasms of the appendix (excluding goblet cell carcinomas). *Neuroendocrinology* 2016;103:144–152.
- 51 Falconi M, Eriksson B, Kaltsas G, Bartsch DK, Capdevila J, Caplin M, Kos-Kudla B, Kwekkeboom D, Rindi G, Klöppel G, Reed N, Kianmanesh R, Jensen RT; all other Vienna Consensus Conference participants: ENETS consensus guidelines update for the management of patients with functional pancreatic neuroendocrine tumors and non-functional pancreatic neuroendocrine tumors. *Neuroendocrinology* 2016;103:153–171.
- 52 Pavel M, O'Toole D, Costa F, Capdevila J, Gross D, Kianmanesh R, Krenning E, Knigge U, Salazar R, Pape UF, Öberg K; all other Vienna Consensus Conference participants: ENETS consensus guidelines update for the management of distant metastatic disease of intestinal, pancreatic, bronchial neuroendocrine neoplasms (NEN) and NEN of unknown primary site. *Neuroendocrinology* 2016;103:172–185.