

# ENETS Consensus Guidelines for the Management of Patients with Neuroendocrine Neoplasms from the Jejunum and the Appendix Including Goblet Cell Carcinomas

Ulrich-Frank Pape<sup>a</sup> Aurel Perren<sup>b</sup> Bruno Niederle<sup>c</sup> David Gross<sup>d</sup>  
Thomas Gress<sup>e</sup> Frederico Costa<sup>f</sup> Rudolf Arnold<sup>e</sup> Timm Denecke<sup>g</sup>  
Ursula Plöckinger<sup>a</sup> Ramon Salazar<sup>h</sup> Ashley Grossman<sup>i</sup>  
and all other Barcelona Consensus Conference participants<sup>1</sup>

<sup>a</sup>Division of Hepatology and Gastroenterology, Department of Internal Medicine, Campus Virchow-Klinikum, Charité-Universitätsmedizin Berlin, Berlin, Germany; <sup>b</sup>Department of Pathology, Universitätsspital, Zürich, Switzerland; <sup>c</sup>Division of General Surgery, Department of Surgery, Medical University of Vienna, Vienna, Austria; <sup>d</sup>Department of Endocrinology and Metabolism, Hadassah University Hospital, Jerusalem, Israel; <sup>e</sup>Department of Internal Medicine, Philipps University, Marburg, Germany; <sup>f</sup>Hopital Sirio Libanes, Centro de Oncologia, São Paulo, Brazil; <sup>g</sup>Department of Radiology, Campus Virchow-Klinikum, Charité, University Medicine Berlin, Berlin, Germany; <sup>h</sup>Department of Oncology, Institut Català d'Oncologia (IDIBELL), Barcelona, Spain; <sup>i</sup>Oxford Centre for Diabetes, Endocrinology and Metabolism, Churchill Hospital, University of Oxford, Oxford, UK

## Introduction

Neuroendocrine neoplasms (NEN) originating from the small bowel comprise, after pancreatic NEN, probably the largest subgroup of NEN within the gastroenteropancreatic system, and reflect the typical distribution pattern of the endocrine cells of the diffuse endocrine system within the digestive system. Previous ENETS guidelines have discussed NEN of the jejunum and of the appendix including goblet cell carcinoids/carcinomas (GCC) in two separate papers [1, 2]. This update summarises these entities together in one chapter, while excluding the consideration of metastatic disease in a separate chapter [3]. The chapter on metastatic NEN by Pavel et al. also includes guidelines for medical and other treatment options of the carcinoid syndrome since this occurs almost exclusively only when the tumour is metastatic. Carcinoid heart syndrome (Hedinger's syndrome),

however, is covered in this chapter, since early recognition and treatment is important for this complication of carcinoid syndrome.

Since highly proliferative carcinomas with a neuroendocrine phenotype but poor histological differentiation grade are extremely rare in the jejunum, management of such cases remains highly individual and can currently not be considered standardised according to organ-oriented guidelines. For the management of such cases, the reader is referred to previous guidelines [4].

This chapter, therefore, deals with non-metastatic NEN originating from the small bowel and the appendix as originally described as 'carcinoid' tumours by Oberndorfer [5] in 1907. For greater ease of use, jejunum-ileal NEN (part 1), appendiceal NEN (part 2) and GCC (part 3) are discussed in separate sections.

<sup>1</sup> See list at the end of the paper.

Since this chapter is an updated version of previously published guidelines, the minimal consensus parts have only been modified where agreed upon by the majority of consensus meeting participants. The comments in the text have been, however, almost completely rewritten, thereby focussing on new literature where applicable to avoid redundancy with the previous guidelines. However, overlaps and close resemblances may occur in some sections [1, 2].

## Jejuno-Ileal Neuroendocrine Neoplasms

### *Epidemiology and Prognosis*

NEN originating in the small intestine are an overall relatively rare entity with a reported incidence between 0.32/100,000 in England [6], 0.33/100,000 in Japan [7], 0.67/100,000 in the USA [8], 0.81/100,000 in Norway [9] and 1.12/100,000 in Sweden [10] according to the most recent literature. Malignant NEN have been reported with an incidence of 0.29/100,000 [11]; in this study malignant NEN made up approximately half of all NEN, while others have shown lower numbers of 20–35% [8, 9, 12]. The mean age at initial diagnosis is in the late 50s in several cohorts, with the majority of cases occurring in the seventh decade [7, 13–15]. The incidence of small intestinal NEN has not shown a gender preference in most [6, 13, 15] but a slight male preponderance in other series [8, 14, 16]. While the incidence of small intestinal NEN may be lower in persons of Asian descent [7, 8] it seems to be higher in African-Americans in the SEER database [8]. Small intestinal NEN constitute up to one third or even half of all small bowel neoplasms [11, 14]. The ‘true’ incidence of small intestinal NEN in post-mortem studies is much higher (1.22/100), and suggests that these NEN may be much more abundant at early or very early stages but do not manifest themselves clinically and are not diagnosed during life [17].

Prognosis of jejuno-ileal NEN depends on both staging and grading, which is reflected in the WHO classification of 2010 [18]. This has been shown also in a recent study in which the Ki67 grading system as well as TNM staging for jejuno-ileal NEN has been validated; Jann et al. [19] reported 5-year tumour-specific survival rates for jejuno-ileal NEN from an oncological cohort of 100% for stage I and II, 97.1% for stage III and 84.8% for stage IV jejuno-ileal NEN. Grading-dependent 5-year tumour-specific survival rates are 93.8% for G1, 83.0% for G2 and 50.0% for the very rare G3-jejuno-ileal NEN [19]. The SEER analysis for jejuno-ileal NEN performed by Boudreaux et al. [20] revealed 5-year overall survival rates (YSR) of ap-

proximately 72% for locoregional spread and approximately 55% for NEN with distant metastases. In the Spanish NET registry, 5-YSR for the whole cohort of ‘enteric carcinoid tumours’ was 77.6% [13] while it was only 61% in The Netherlands Cancer Registry (NCR) approximately 10 years earlier [21]. The SEER data do not suggest a significant survival difference between different ethnicities [8]. Prognosis for small intestinal NEN is thus considerably better than for other small intestinal neoplasms such as lymphomas, adenocarcinomas, and sarcomas [14]. In the older patient group of more than 60 years at initial diagnosis, the outcome figures may be worse as was suggested by analysis of the population-based Florida Cancer Data System (FCDS) [22], but this may not be exclusively related to NEN but rather other secondary neoplasms or other age-related causes of death [16].

Although recent data [19, 23] suggest better overall or tumour-specific outcome figures, the datasets are not completely comparable as they are analysed at different tumour stages. However, as has been suggested by Yao et al. [8], the overall outcome has probably improved over the last 25 years which may be related to better diagnosis, effective treatment options and multimodal sequential or simultaneous treatments. This aspect, however, has not been specifically shown by every study [16], and will also undoubtedly be very hard to prove.

### *Minimal Consensus Statement on Epidemiology and Prognosis*

The clinical incidence of small intestinal endocrine neoplasms is considerably lower than the incidence at autopsy (~1/100). Clinical incidence is probably higher than stated earlier in the literature. Figures from the SEER and other registries indicate a significant rise of the reported annual incidence of 0.67–0.81/100,000/year for jejuno-ileal NEN. The incidence rate may be considerably lower in Asia with 0.20/100,000/year as suggested by Japanese data. Jejuno-ileal NEN represent 30% to even 50% of all small bowel neoplasms. The incidence rates have increased in more recent years. The average age at diagnosis for patients with small intestinal carcinoids is between 60 and 65 years. According to the literature, there is a slight male preponderance and there are some ethnic differences. African-Americans have a slightly higher incidence rate than Caucasians for developing jejuno-ileal NEN. The former terminology of midgut and hindgut origin is inaccurate and hence these tumours are classified as jejuno-ileal, appendiceal, caecal, colonic or rectal NEN. A potential risk factor associated with increased risk of development of NEN of the small bowel is a family history of first-degree relatives with cancer suggesting a genetic component independent of MEN-1, which is not associated with jejuno-ileal or appendiceal NEN. Familial clustering of jejuno-ileal NEN is described but probably very rare.

Survival rates strongly depend on histopathological WHO classification and TNM stage: 5-YSR for all stages reach between 50 and 60%; however, in NEN with only locally limited disease (5-YSR: 80–100%) or only regional lymph node involvement (5-YSR: 70–80%; stages I–IIIa), the survival is significantly better than in tumour stages with metastatic disease (5-YSR: 35–80%). Series presenting analyses from more recent data collections observe even more favourable outcome results. Ki67 grading is an important prognostic stratifier and is therefore mandatory in pathological reporting.

### *Clinical Presentation*

Jeuno-ileal NEN are frequently detected while searching for a primary tumour in asymptomatic but metastatic patients, or incidentally, for example on screening colonoscopy. The most frequent clinical symptom in a number of uni- or multicentric series as well as from population-based data sources is non-specific abdominal pain [10, 12, 24–27] which may be due to various reasons: dysmotility of the small bowel wall, small bowel obstruction, intermittent mesenteric ischaemia caused by mesenteric root fibrosis, but also functional causes such as secretory diarrhoea and bacterial overgrowth. Other non-specific symptoms such as weight loss, fatigue and (rarely) fever of unknown origin may also occur. Tumour mass-related symptoms due to bowel obstruction with nausea and vomiting, jaundice in case of metastatic cholestasis and even gastrointestinal bleeding, may also occur, but in a lower proportion of patients [10, 12, 24–27]. The desmoplastic reaction leading to visceral fibrosis may culminate in small bowel ischaemia or hydronephrosis from some degree of retroperitoneal fibrosis, although these are rare problems.

Tumour-specific, hormone hypersecretion-related symptoms from the carcinoid syndrome comprise secretory diarrhoea (60–80%), flushing (60–85%) and intermittent bronchial wheezing (which is frequently not clinically apparent; approx. less than 10%) and most importantly right heart fibrosis with carcinoid heart disease (CHD or Hedinger's syndrome; in up to 20%) [12, 16, 25, 26]. These manifestations are always associated with metastatic disease and by far most often with liver metastasis which allows bypassing of hepatic clearance of serotonin from the portal circulation [25, 26, 28]. There is no evidence that the carcinoid syndrome per se and independently from metastatic disease has an influence on prognosis [19] except for clinically manifest right heart failure of CHD (see below).

Carcinoid crisis is a severe and potentially fatal exacerbation of hormonal symptoms often provoked by anaesthesia or invasive procedures, such as surgery [29].

The clinical picture includes flushing, hypo- or hypertension, diarrhoea, severe bronchospasm and cardiac arrhythmias.

### *Minimal Consensus Statement on Clinical Presentation*

Abdominal pain is the most frequent initial symptom in patients presenting with NEN from the small bowel, possibly previously misinterpreted as a manifestation of irritable bowel syndrome. The consensus is that the rate of functionality and the presence of the carcinoid syndrome in this patient group is about 20–30% in patients with metastases, i.e. higher than previously stated. Small bowel ischaemia can be another cause of both diarrhoea and pain besides hormone-hypersecretion-related diarrhoea. In the literature, flushing is reported to be a more frequent symptom (in 90% of patients with the carcinoid syndrome) than diarrhoea (80%), but according to clinical experience the rate is roughly the same. It is emphasised that the carcinoid syndrome is usually seen in patients with liver metastases (in at least 95% of patients), but excess tachykinin or serotonin production from retroperitoneal metastases or ovarian tumours/metastases can bypass the liver and enter the systemic circulation and cause the typical carcinoid syndrome (in up to 5% of patients).

### *Imaging*

Cross-sectional imaging by either computed tomography (CT) applying modern protocols (3-phase, contrast-enhanced, multislice-detector CT) or magnetic resonance imaging (MRI; also with the use of contrast media) is the cornerstone of indirect imaging of the abdomen for initial staging as well as preoperative diagnosis [30–32]. By this approach the primary tumour may sometimes but not necessarily always be imaged, but lymph node and/or distant metastases can regularly be either detected or ruled out. In the case of an unknown primary tumour, thoracic scanning (preferably with CT) may also be necessary to either detect or rule out a bronchial primary NEN. CT or MR enteroclysis may provide additional benefit for primary tumour detection in the small intestine with very good sensitivities and specificities in institutions where either of them is available [33, 34]. Transabdominal ultrasonography may be used for screening of hepatic metastases with good results [35], but is strongly investigator-dependent; in individual cases transabdominal ultrasonography of the small bowel with high frequency probes (10 or 12 MHz) may also detect a small intestinal primary tumour and/or mesenteric lymph node metastases. However, for long-term follow-up purposes and reliable comparability, CT or MRI provide a better, investigator-independent basis.

Direct visualisation may be possible with regular colonoscopy if the tumour is prolapsed through the ileocaecal

valve into the colon, or if intubation of the ileum via the ileocecal valve is performed during the investigation. For investigation of more proximal parts of the ileum or of the jejunum, the newer modalities of enteroscopy including video-capsule endoscopy [36–38] or double-balloon enteroscopy [39] may be effective, although their role in routine staging still has to be established and they are not widely available. There are no data on potential procedural risks of these methods in NEN which should always be weighed against the benefits of tumour localisation and/or even histological confirmation by luminal biopsy. At least, in the case of impending small bowel occlusion, video-capsule endoscopy is absolutely contraindicated.

Somatostatin receptor imaging (SRI) of jejuno-ileal NEN depends on the overexpression of somatostatin receptors in NEN, particularly of subtype 2 which is the receptor to which the currently used ligands for these modalities bind with the highest affinity. Linked to the ligand are either radionuclides that can be detected by somatostatin receptor scintigraphy (SRS; e.g. indium-111) or by positron emission tomography (PET; e.g. gallium-68) scanning [40–52]. For jejuno-ileal NEN metabolic PET scanning using 18-fluorodeoxyglucose (FDG) cannot be recommended since it has a low sensitivity for well to moderately differentiated NEN which comprise by far the majority of jejuno-ileal NEN. Other newer tracers such as 11-carbon-5-hydroxytryptophane (HTP) or 18-fluoro-dihydroxyphenylalanine (DOPA) have shown promising results but are even less available and reported results await publication of successful reproducibility [53, 54]. SRI has sensitivities of >90% for jejuno-ileal NEN and >95% for liver metastases from these, and is therefore an important tool for initial staging as well as for follow-up studies. Gallium-68-PET, preferably with simultaneous CT (using contrast media), may be even more sensitive and change management in an additional 20–30% of cases. Particularly for the detection of small tumours within the jejunum-ileum, as well as for preoperative exclusion of distant metastases not detected by other direct or indirect imaging modalities, PET scanning may be useful but prospective data dedicated to this particular issue have not yet been published.

For clinically suspected and not otherwise (CT or MRI) detected bone metastases, which are the fourth most frequent metastatic localisation (with lymph nodes, liver and the lungs in descending frequency being the other more frequent localisations of metastases) [12, 15], SRI may also be the more sensitive nuclear medicine method; however, conventional bone scintigraphy using technetium-99m-DPD scintigraphy may also be useful [55].

A rational stepwise approach of diagnostic modalities, as suggested in figure 1, is recommended to make the optimal use of available methods and limited resources, with the least invasive methodology for the patient and the most effective outcome for patient management.

#### *Minimal Consensus Statement on Imaging*

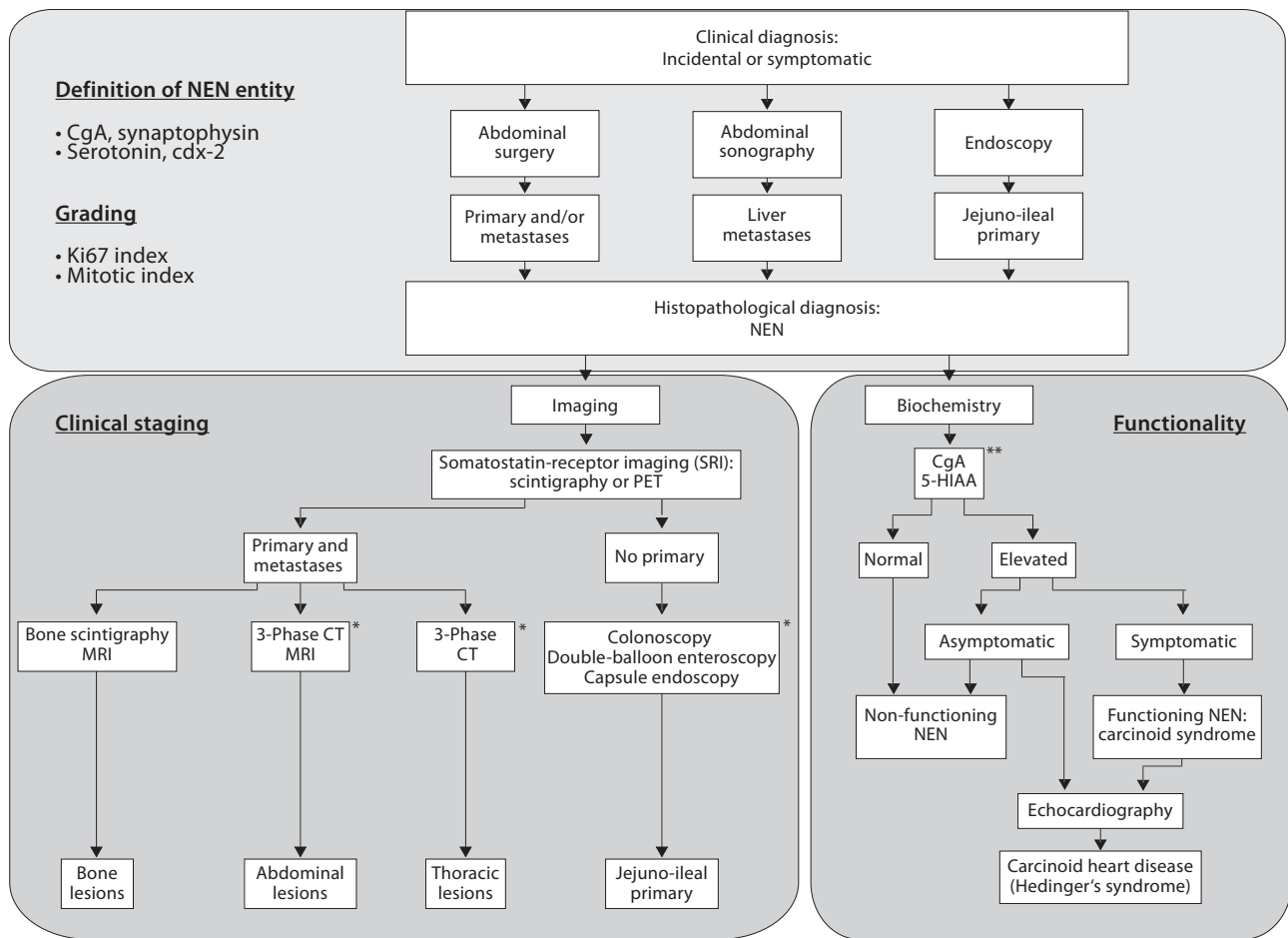
In the search for a primary tumour, cross-sectional imaging with CT and/or MRI should be followed by SRS, ideally in combination with SPECT/CT; <sup>68</sup>Ga-DOTATOC-PET in combination with native or preferably 3-phase contrast-enhanced CT may be a more sensitive alternative but is not widely available as yet. In general, fusion imaging with CT is always preferable. Further newer PET imaging techniques may be useful but require the presence of a cyclotron and are unlikely to become generally available; FDG-PET does not have an important role for the almost always well or moderately differentiated NEN from the jejunum-ileum. Transabdominal ultrasound can be applied and is frequently useful to guide more expensive techniques, but is investigator-dependent and less reliable for follow-up comparisons.

If the search for a primary tumour is indicated in surgical candidates for bowel resection, either CT-/MR-water enteroclysis or endoscopic techniques such as video-capsule endoscopy or double-balloon enteroscopy may be applied according to local expertise, but potential risks need to be weighed against benefits such as precise preoperative localisation particularly of multicentric NEN. Endoscopic ultrasonography, on the other hand, has no place in this setting. Colonoscopy should be performed because it may detect primary tumours in the distal ileum and is necessary to rule out synchronous neoplastic disease (particularly colorectal cancer).

For cardiac diagnostics to investigate for carcinoid heart disease, please see the section below.

#### *Laboratory Tests*

Specific laboratory testing for NEN-associated serum markers is strongly recommended for chromogranin A (CgA), which is a sensitive marker for NEN of all origins including jejuno-ileal NEN [56–58]. CgA has also more recently been shown to predict prognostically significantly differing groups with higher levels of CgA indicating a worse prognosis, probably related to increased tumour cell mass [59, 60]. For longitudinal follow-up purposes it is important to note that absolute CgA values may differ significantly between different assays [61–63], and therefore it is recommended to perform repeated measurements in the same laboratory or at least with the same assay whenever possible. Furthermore, the differential diagnosis of elevated CgA values such as proton-pump inhibitor use, chronic atrophic gastritis, chronic renal failure, liver cirrhosis or congestive heart failure, as well as other CgA-secreting neoplasms (e.g. hepatocellular carcinoma, med-



**Fig. 1.** Rational stepwise approach of diagnostic modalities. \* If not performed previously; \*\* Cga being non-specific for carcinoid-syndrome and urinary 5-HIAA being a biochemically determinable metabolite of serotonin, a specific mediator of carcinoid syndrome.

ullary thyroid carcinoma) needs to be considered when CgA values are interpreted [64–66]. CgA may signal NEN recurrence after successful curative resection early in patients with a small tumour burden [58, 67].

Endocrine tumours of the jejunum-ileum produce serotonin and elevated 24 h urinary 5-hydroxyindoleacetic acid (5-HIAA) levels as a product of the metabolism of serotonin [68, 69]. 5-HIAA has a sensitivity of up to 100% and a specificity of 85–90% for detecting a carcinoid syndrome, and a sensitivity of 70–75% and a specificity of close to 100% for predicting a primary tumour in the jejunum-ileum [56, 57]. 5-HIAA should be collected with strict dietary restrictions to avoid false positive levels [70]. Serum serotonin determinations are less sensitive and specific, and are therefore not recommended; serotonin measurements in platelets, where serotonin is stored depending on its availability in the systemic circulation,

may be even more sensitive, but are not widely available and therefore currently impractical [68].

#### *Minimal Consensus Statement on Laboratory Tests*

The minimally required biochemical tests include plasma CgA and urinary 5-HIAA. These tests should be performed at first visit and then for follow-up or on suspicion of NEN recurrence or progression. Newer markers, either biochemical or based on circulating NEN cells, require further validation. Neuron-specific enolase has no role for the diagnosis of these almost always well to moderately differentiated NEN (NET-G1/2).

#### *Pathology and Genetics*

Pathological diagnosis is mandatory in all cases and usually obtained on ultrasonography-guided liver biopsy or surgical or endoscopic biopsy. Pathological diagnosis of jejunal-ileal tumours is achieved using haematoxylin and

**Table 1.** TNM classification of jejuno-ileal NEN according to ENETS/UICC [73, 74] TNM classification

<i>T – primary tumour</i>			
x	primary tumour cannot be assessed		
0	no evidence of primary tumour		
1	tumour invades mucosa or submucosa and size ≤1 cm		
2	tumour invades muscularis propria or size >1 cm		
3	tumour invades subserosa		
4	tumour invades peritoneum/other organs		
	for any T add (m) for multiple tumours		
<i>N – regional lymph node metastasis</i>			
x	regional lymph nodes cannot be assessed		
0	no regional lymph node metastasis		
1	regional lymph node metastasis		
<i>M – distant metastasis</i>			
X	distant metastasis cannot be assessed		
0	no distant metastases		
1	distant metastasis		
Stage:			
stage 0:	Tis	N0	M0 (stage 0: ENETS only)
stage I:	T1	N0	M0
stage IIa:	T2	N0	M0
stage IIb:	T3	N0	M0
stage IIIa:	T4	N0	M0
stage IIIb:	any T	N1	M0
stage IV:	any T	any N	M1

**Table 2.** Grading of jejuno-ileal NEN according to ENETS/UICC [72–74]

Grade	Ki67 index	Mitotic index (mitoses/10 HPF)
G1	≤2%	<2
G2	3–20%	2–20
G3	>20%	>20

eosin staining, and immunohistochemical staining with CgA and synaptophysin [71–74]. As opposed to serum levels of CgA, weaker CgA staining on immunohistochemistry may indicate a poorer prognosis [12, 75]. Determination of mitotic index and calculation of Ki67 index by immunohistochemistry is mandatory and prognostically relevant in jejuno-ileal NEN [19, 74]. The tumours should be classified according to the WHO system [72] (table 1) including TNM staging [73, 74] and Ki67 grading [72–74] (table 2). Immunohistochemical staining for somatostatin receptor subtype 2 (SSR-2) has been suggested by several studies [76–78] to correlate with, or at least be indicative of a therapeutic response to somatostatin analogue (SSA)

treatment. However, currently it can only be considered optional since methodological variations and current data do not show a completely conclusive pattern. Thus, SSA treatment may be initiated although SSR-2 staining may be weak or even absent on immunohistochemistry. In the setting of liver metastases from a NEN of unknown primary tumour localisation, nuclear immunohistochemical positivity for cdx-2 and/or serotonin with negativity for TTF-1 and ISL-1 is indicative of intestinal, especially jejuno-ileal origin [79]. Other markers such as E-cadherin, p53, p27, VEGF and others have not been established as yet for routine diagnostics, although they may play a role in the future [80–82].

A familial or genetic predisposition for jejuno-ileal NEN has not been undoubtedly proven, however, recent reports show some familial associations which strongly suggest that a genetic predisposition may exist in rare instances [83–85]. Other changes such as allelic loss of chromosome 18q have been reported to indicate adverse prognosis, but currently have no role outside of scientific studies [86, 87].

#### *Minimal Consensus Statement on Pathology and Genetics*

##### *Pathology*

Histology is always necessary to establish the diagnosis of a NEN. Cytology may be helpful, particularly in a metastatic setting. The minimal ancillary tests to support the histological diagnosis include immunohistochemistry for CgA, synaptophysin, and optionally serotonin. The mitotic count in 10 HPF (2 mm<sup>2</sup>) evaluated in areas of highest mitotic density, the Ki67 index (MIB1 antibody; % of 2,000 cells in areas of highest nuclear labelling) and TNM staging according to UICC and ENETS, should be reported. Immunohistochemistry for cdx-2, p53 and somatostatin receptor subtype-2 (sst2) is optional. The histopathology report should allow for a correct classification according to the current WHO criteria. In the future, it should also provide information for a correct TNM classification and grading (tables 1, 2).

##### *Genetics*

Although a familiar clustering of midgut neuroendocrine tumours appears to rarely exist, the genetic background has not been elucidated and there is no indication to perform germline or somatic DNA testing and genetic counselling in the absence of other tumours or a family history.

#### *Curative Surgery*

##### *Resection of Localised Disease in Jejuno-Ileal NEN*

All patients with jejuno-ileal NEN should be considered potential candidates for curative surgery [81–86]

and should be evaluated in an interdisciplinary setting including an experienced visceral surgeon [12, 23, 26, 27, 88–95]. Curative resection of the primary tumour and locoregional lymph node metastases improves outcome in these patients resulting in excellent 5- and 10-YSR of 100% in stage I and II patients and still favourable outcomes of 5-YSR of >95% and 10-YSR of >80% in stage III jejuno-ileal NEN [19]. Any resective procedure should follow the principles of oncological surgery in the small intestinal tract [88–95], but may sometimes require a concomitant right hemicolectomy if the tumour is located in the terminal ileum. Curative resection also involves clearance of lymph node metastases by dissection around the mesentery, aiming to preserve the vascular supply. To limit the extent of small intestinal resection, lymphatic mapping has been suggested to be helpful but it is not a standardised procedure and therefore not generally recommended [96]. A minimally invasive approach can be considered provided oncological surgical standards can be achieved; however, patients with large mesenteric infiltration and multiple tumours are probably not candidates for laparoscopic resection. Furthermore, there are currently no published data to support or counter this thesis, and therefore the potential benefits of minimally invasive surgery should be weighed against the risk of incomplete (i.e. non-curative) tumour resection. Postoperatively malabsorptive and/or chologenic diarrhoea due to resection of more or less extensive parts of the distal small intestine, and particularly the terminal ileum, may be observed, and require either medical or nutritional therapy. However, postoperative mortality should be lower than 2% and significant morbidity lower than 20% [25, 95].

#### *Concomitant Cholecystectomy*

Since cholelithiasis appears to be increased in NEN patients, particularly in those undergoing SSA treatment, cholecystectomy has been recommended even for non-symptomatic patients in the past [97]. However, prospective proof of this concept has never been produced, and there is an ongoing debate as to whether routine cholecystectomy is required or not [98, 99] because the increased incidence of cholelithiasis does not consistently lead to increased clinical problems. It may therefore be individually decided by the operating surgeon depending on technical and clinical aspects (e.g. already present cholelithiasis, previous episodes of cholecystitis or cholangitis, or presumed cholecystolithiasis-associated right upper abdominal pain, planned transarterial (chemo-) embolization or selective internal radiotherapy SIRT, and the intraoperative risk of cholecystectomy in an emergency situation).

### *Minimal Consensus Statement on Curative Surgery*

Curative surgery is always recommended whenever feasible. Surgery of the primary should be performed as segmental resection with wide lymphadenectomy. In case of lymph node involvement around the superior mesenteric artery, high lymph node dissection is recommended. In cases with severe desmoplastic reaction around the artery, radical tumour resection may not be possible.

Cholecystectomy may be performed during the initial session to prevent or treat cholelithiasis, which may in the case of later SSA treatment cause cholecystitis, choledocholithiasis and/or cholangitis; the benefit of cholecystectomy has, however, never been prospectively proven. In emergency situations, cholecystectomy may therefore not be enforced.

Tumour multicentricity, which may occur in 20% of all cases, demonstrated by SRS, cross-sectional imaging, intraoperative palpation and/or endoscopy, does not change the indication for surgery. A minimally invasive approach may be considered provided oncological surgical standards can realistically be achieved; patients with large mesenteric infiltration and multiple tumours are not candidates for laparoscopy.

The outcome of surgery may be worse in cases of distant metastases other than the liver, as in cases with the so-called frozen mesenteric root and peritoneal carcinomatosis. Careful pre- and perioperative symptomatic control of any carcinoid syndrome can be achieved by medical treatment (s.c. or i.v. SSAs).

After curative surgery, there is no indication for specific medical treatment and there is no proven role for neoadjuvant or adjuvant medical treatment in NEN of the jejuno-ileum.

### *Palliative Surgery*

#### *Palliative Resection of the Primary Tumour in Metastatic Disease*

In cases of distant metastases the decision of whether to resect the primary tumour or not will be influenced by three considerations: Firstly, if a curative approach including curative resection of distant metastases (mostly liver metastases) [3] can still be reasonably achieved, then a primary tumour resection should be performed following oncological standards as outlined above [100]. Secondly, in symptomatic patients with symptoms due to small intestinal obstruction or (impeding) occlusion, resection of the cause of obstruction (either primary tumour and/or mesenterial lymph node metastases) is obviously mandatory to prevent clinical deterioration or death, but this is in fact a palliative procedure. Thirdly, if a curative approach seems no longer achievable, primary tumour resection may still improve overall outcome and can therefore be considered [25, 101], although this has not been shown to be reproducible in all series [23]. However, these data are all influenced by their retrospective nature and a potential 'surgical' bias favouring resectable

and thus less morbid patients. Thus, in the third setting comorbidities should carefully be considered, probably best in an interdisciplinary setting to avoid unnecessary risks to the patient.

The aspects of debulking surgery are discussed in the previous guidelines by Steinmüller et al. [102] and in the metastasis section of the current guidelines update [3].

#### *Minimal Consensus Statement on Palliative Surgery*

Palliative surgery for patients with endocrine tumours of the jeuno-ileum has the objective to make liver metastases the only persisting problem or to improve prognosis.

Resection of the small intestinal primary tumour should be attempted because overall outcome is better in patients after primary tumour resection although a direct causal relationship has not been proven to date; an interdisciplinary discussion is recommended for such a decision. Resection should also be considered in symptomatic patients and in patients in whom imaging (bowel dilatation, mesenteric fibrosis) suggests that obstruction will probably occur.

Patients suitable for palliative debulking procedures are those presumed to benefit from tumour reduction performed in accordance with given guidelines. Palliative surgery should mainly be done for symptomatic reasons or to facilitate other therapeutic modalities, i.e. medical or radionuclide treatment. The type of surgery should be individualised and no general approach can be given. If liver metastases require a minor resection, this can be done at the same procedure as the primary, otherwise it should be done at a second operation.

In the palliative setting, medical therapy is frequently required pre-, peri-, and postoperatively. For further recommendations, please refer to the metastasis paper [3].

#### *Carcinoid Heart Disease (Hedinger's Syndrome)*

Carcinoid heart disease (CHD) can be detected in 25% up to 50% of patients with carcinoid syndrome [12, 25, 103–109]. It indicates a poor prognosis and is associated with clinical signs of right heart failure, echocardiographic signs of right ventricular dilatation or tricuspid valve regurgitation, and with the duration of CHD; prognosis has improved over the last 20 years with 5-YSR from below 30% in the 1980s to now approximately 55%. The most important reason for this improvement is successful cardiac surgery with valve replacement [106, 108–110]. CHD is characterised by plaque-like, fibrous endocardial thickening that principally involves the right side of the heart, causing retraction and fixation of the leaflets of the tricuspid and pulmonary valves as well as diminished right ventricular function [111, 112]. These changes are thought to be elicited by excess serotonin release and co-secretion of other fibrogenic factors such as tachykinins, connective tissue growth factor, transforming growth factor- $\beta$  and/or substance P [103, 110, 112].

Transthoracic echocardiography is the most important diagnostic modality [105–107], although cardiac MRI [113] and other newer techniques such as tissue Doppler imaging [114] may play a role in the future. CHD is echocardiographically characterised by plaque-like, fibrous endocardial thickening that principally involves the right side of the heart, causing retraction and fixation of the tricuspid leaflets and pulmonary valves as well as diminished right ventricular function [110, 115]. Natriuretic peptides such as brain natriuretic peptide and its precursors have also been shown to be quite sensitive indicators of early CHD and may be monitored regularly for early detection of CHD, when available [116]. Screening for CHD should be performed on a regular basis (fig. 1), particularly prior to planned surgical procedures. If it develops, right heart failure rather than metastatic disease may be the cause of death. Medical therapy for heart failure should be introduced when necessary and cardiac surgery with valve replacement (bioprosthesis) should be considered for patients in whom control of hormonal symptoms and tumour growth has been achieved. Cardiac surgery should be performed before major liver surgery or liver embolisation, while on the other hand early liver metastasis resection may slow progression of CHD particularly in its earlier stages [117].

More recently, the coincidence of a patent foramen ovale (PFO) has been described together with CHD [118, 119], and may increase the chance of left-sided heart lesions; its closure has also improved functional outcome in CHD patients. A patent foramen ovale should therefore be ruled out in clinically progressing CHD and prior to cardiac surgery.

#### *Minimal Consensus Statement on Carcinoid Heart Disease*

For patients with the carcinoid syndrome and CHD, transthoracic echocardiography should be performed annually; cardiac MRI may be helpful but its usefulness has not been proven as yet. For timing of cardiac surgery with replacement of the tricuspid (and pulmonary) valves, brain natriuretic peptide measurements may be helpful, since they reflect the volume load on the right heart. At cardiac imaging a patent foramen ovale should be ruled out; if present its closure should be considered although only sparse data exist for this approach. Decisions towards cardiologic intervention or cardiac surgery should be made on an individual basis in collaboration with an experienced cardiologist and cardiac surgeon.

#### *Follow-Up*

A precise follow-up strategy is described in the ENETS standards of care [120]. Briefly, for patients having under-



gone surgery with a curative intent, the schedule for follow-up should be every 6–12 months, with the exception of grade 3 tumours, which should be followed every 3 months. Patients who were not curatively treated should be followed at 6-month intervals for NET-G1 and 3-month intervals for NET-G2 and the very rare NEC-G3. Minimal examination includes measurement of CgA and 5-HIAA and triphasic CT. SRI should be performed in suspected recurrences before any therapeutic decisions are made, or even after curative resection with unknown NEN prior to surgery to rule out distant metastases. The follow-up should be lifelong, considering that after 25 years only approximately 20% of patients are free of disease [12, 121].

#### *Minimal Consensus Statement on Follow-Up*

For guidelines regarding follow-up strategies we recommend to follow the ENETS standards of care [120].

### **Appendiceal Neuroendocrine Neoplasms**

#### *Epidemiology and Prognosis*

NEN of the appendix have been reported with an incidence rate of approximately 0.15/100,000/year in the SEER database [8] as well as in other population-based databases from Europe [6, 9, 21, 122], and probably comprise one of the largest subgroups of gastroenteropancreatic NEN depending on the series [6, 11, 14, 24]. A slight female preponderance has been repeatedly described, and they may also be more frequent in the Caucasian subpopulation than in the African-American and Asian subpopulations in the SEER [8, 9] as well as in a Japanese series [7], which suggests a lower incidence in the Asian populations. The incidence has increased throughout the last decades to up to 0.4–0.6/100,000/year in the UK [6], which parallels the phenomenon of the generally increased incidence rate of all NEN. In single or multicentre-based studies, appendiceal NEN may be under-represented because the majority of them may not be referred to secondary or tertiary centres. Similarly, registries such as the SEER in the USA [8, 123], the Norwegian Registry of Cancer [9] or the UK National Health Services Central Registry [124], which register only malignant tumours, will probably also underestimate the true incidence of appendiceal NEN. The incidence in appendicectomies performed for any reason is approximately 3 to 9/1,000 [125–129] and thus they comprise a regularly observed problem in routine medical care. Appendiceal NEN comprise

the largest subgroup of appendiceal neoplasms with approximately 80% of all appendiceal neoplasms (including both benign and malignant neoplasms). The mean age at diagnosis has been reported between 38 and 51 years and is thus considerably earlier than for other gastroenteropancreatic NEN [6, 13–15].

The prognosis of the majority of appendiceal NEN is excellent in the series that report outcome on limited tumour stages with 5-YSR of 100% or close to this [13, 21, 130, 131]. However, the whole cohort including all tumour stages does not show such a favourable prognosis, with 5-YSR ranging between 70 and 85% [13, 21, 130–132]. This is still better than for all jejuno-ileal NEN, although advanced stages with distant metastases have been reported with a much poorer prognosis and a 5-YSR of as low as 12–28% [8, 21]. However, it is not clear to what extent more ‘malignant’ histologies such as GCC or mixed adenoneuroendocrine carcinomas (MANEC) with a poorer prognosis per se may have been included in these series. In addition, variations in reported survival rates in all NEN have been reported for Europe and may also influence these figures for appendiceal NEN [133].

#### *Minimal Consensus Statement on Epidemiology and Prognosis*

Appendiceal NEN are reported in the literature with an incidence of 0.15/100,000/year. They are diagnosed slightly more often in female than in male patients at an average age of 40–50 years. Appendiceal NEN are, however, much more frequently diagnosed incidentally during appendicectomy with a rate of approximately 3–5/1,000 appendicectomies. There seems to be no overall difference between Caucasians and African-Americans, however, in Japan they appear to be rarer. In contrast, malignant tumours seem to occur more often in Caucasians compared to other races.

While at a limited stage, survival is extremely good (local disease: 5-YSR 95–100%, regional disease: 85–100%), the few cases with distant metastasis present with relatively poor survival (5-YSR: ~25%).

From the available data it is concluded that an appendiceal NEN with a size  $\leq 1$  cm, with invasion up to the subserosa or mesoappendiceal invasion up to 3 mm, and clear surgical margins, poses no further risk of recurrence after appendicectomy. Most tumours (70%) are located at the tip of the appendix. However, tumours at the base of the appendix, tumours  $> 2$  cm, deep mesoappendiceal invasion or margin invasion, confer a relevant risk of recurrence and further surgical procedures are warranted although no data have proven a survival benefit by more aggressive surgery.

#### *Clinical Presentation*

Most appendiceal NEN are incidental findings in post-appendicectomy specimen and therefore no charac-

teristic tumour-specific symptomatology is established. However, symptoms that lead to appendectomy such as right lower abdominal pain are thus indirectly associated with appendiceal NEN, although due to their most frequent localisation at the tip of the appendix (approx. 70%) these NEN are very probably not causative of acute appendicitis [27, 129, 134–137]. In the rare cases of distant metastases these may cause symptoms related to the localisation of the metastasis (see metastasis chapter [3]). The carcinoid syndrome is only very rarely described in metastatic patients [126, 129, 135] and thus should rather raise suspicion of a small intestinal primary tumour in the metastatic patient.

#### *Minimal Consensus Statement on Clinical Presentation*

NEN of the appendix are rarely symptomatic in the large majority of cases due to the incidental nature of their diagnosis. However, tumours with extensive local disease or distant metastases may appear symptomatic with abdominal pain, a tumour mass effect or signs of bowel obstruction. An association with the carcinoid syndrome is extremely rare and indicates metastatic disease.

#### *Diagnostic Procedures*

Since most appendiceal NEN are incidentally diagnosed by postoperative histology, diagnostic procedures relate mostly to postoperative staging, follow-up and to the rare cases with suspected or evidenced distant metastasis.

#### *Imaging*

There are no specific diagnostic studies focusing on appendiceal NEN only, and therefore the considerations which apply to small intestinal NEN (see above) are considered also valid for appendiceal NEN.

Cross-sectional imaging using CT or MRI with modern protocols should be used to rule out locoregional or distant metastasis [138]. NEN limited to the appendix may be detected by transabdominal ultrasonography which in spite of its investigator-dependent limitations is the least invasive procedure; it has, however, not been validated prospectively. Endoscopy is rarely helpful unless the tumour is locally advanced and infiltrates the caecum which is a very rare situation, and therefore routine colonoscopy for tumour detection is not recommended. In the context of the potentially increased incidence of secondary neoplasms, general recommendations regarding colorectal cancer screening should be followed. SRI using either indium-111-SRS (including SPECT) or PET scan-

ning using gallium-68-labelled SSAs in combination with CT may be considered in cases when curative resection is not completely assured or when distant metastasis is suspected.

#### *Laboratory Tests*

CgA can be used as a tumour marker in appendiceal NEN as it is used in small intestinal NEN (see above), and it is particularly useful to differentiate NEN from GCC; it has been described to be increased in appendiceal NEN [139, 140] although its role for regular follow-up has not been thoroughly studied. It is thus probably indicated in metastatic disease as a follow-up parameter. In the very rare patient with carcinoid syndrome, urinary 5-HIAA is useful (see above). To avoid falsely elevated 5-HIAA levels, proper proceedings with 24-hour urine collection and food and/or medical restrictions during the collecting period should be adhered to [70].

#### *Minimal Consensus Statement on Diagnostic Procedures*

For the majority of well-differentiated appendiceal NEN diagnosed incidentally, with a maximum diameter <1 cm and R0 resection, no postoperative diagnostic procedure is required. For well-differentiated tumours of 1 to <2 cm and R0 resection there are no clear data, but a single CT or MRI of the abdomen to rule out lymph node or distant involvement is justified. In cases with deep mesoappendiceal infiltration or angioinvasion and tumours >2 cm, CT or MRI of the abdomen and SRS, ideally in combination with SPECT/CT or somatostatin receptor PET in combination with native or preferably 3-phase contrast-enhanced CT, may be performed to detect or rule out potentially distant tumour spread.

CgA may be used as a surrogate parameter but has not been particularly validated for diagnosis and follow-up of appendiceal NEN.

#### *Pathology and Genetics*

Histopathological characterisation of appendiceal NEN includes immunohistochemical proof of the neuroendocrine tumour entity by immunohistochemical staining for synaptophysin and CgA, as well as for Ki67 to determine the proliferative capacity of the tumour [72–74]. The Ki67 index also determines the tumour grading according to the current WHO classification (see table 4) [72, 74].

#### *Stratification According to Size, Localisation and Extent of Invasion*

Size of the appendiceal NEN, localisation within the appendix and the extent of invasion into the mesoappen-

dix are essential criteria for the therapeutic and follow-up stratification of appendiceal NEN which are usually well differentiated (G1/2).

The key issue is the correct T classification of the frequently incidentally detected appendiceal NEN because only tumours <1 cm (T1a according to UICC/AJCC and T1 according to ENETS; table 3) can be considered cured by simple appendicectomy, even in children [141, 142]. Although children are not an explicit part of these guidelines, they provide the longest follow-up data and thus confirm the approach of simple appendicectomy in appendiceal NEN <1 cm in size. Overall survival is 100% in this subgroup of appendiceal NEN in the published series.

However, appendiceal NEN >2 cm, although rare (less than 10%), carry a risk of metastases which has been reported between 25 and 40% [122, 128, 134] and therefore a radical oncological resection and long-term follow-up are necessary for this stage (T2 according to UICC/AJCC and T3 according to ENETS; table 3). Some series have, however, not detected any metastases in this subgroup [143], while others have recently reported occurrence of metastases [144].

The intermediate size group of appendiceal NEN >1 cm but <2 cm (T1b according to UICC/AJCC and T2 according to ENETS; table 3) is the group with a less clear situation. Although metastases also seem to only very rarely occur in this subgroup, which comprises 5–25% of all appendiceal NEN, their occurrence has been described in up to 10% in some series although the largest by Moertel et al. [134] did not report any metastases in this subgroup. It is therefore not clear whether these NEN necessarily require a more aggressive surgical approach than just appendicectomy, or whether this would be overtreatment. A careful discussion with the patient and a careful consideration of his or her lifetime expectations should therefore also be part of the decision-making as long as definitive scientific clarity is not available.

An additional criterion to assist in decision-making is the localisation of the NEN within the appendix. Most appendiceal NEN are located at the tip of the organ (60–75%) while some are located at the mid-appendix (5–20%) and the smallest fraction (less than 10%) at the base of the appendix. Although no clear correlation with outcome exists, incomplete resection after appendicectomy and thus metastases probably occur more frequently (although still infrequently) when the NEN is located at the base of the appendix; therefore, this may be an (as yet unproven) argument for a more aggressive surgical strategy in appendiceal NEN between 1 and 2 cm in size.

**Table 3.** Comparison of TNM classification of appendiceal NEN according to ENETS [74] versus UICC/AJCC [73] (TNM classification)

ENETS	UICC/AJCC		
<i>T – primary tumour</i>			
x	primary tumour cannot be assessed		
0	no evidence of primary tumour		
1	tumour ≤1 cm invading submucosa and muscularis propria		
1a	tumour ≤1 cm in greatest dimension		
1b	tumour >1 cm but ≤2 cm in greatest dimension		
2	tumour ≤2 cm invading submucosa, muscularis propria and/or minimally (up to 3 mm) invading subserosa/mesoappendix	tumour >2 cm but ≤4 cm or with extension to the caecum	
3	tumour >2 cm and/or extensive (>3 mm) invasion of subserosa/mesoappendix	tumour >4 cm or with extension to the ileum	
4	tumour invades peritoneum/other organs	tumour perforates peritoneum or invades other adjacent organs or structures, e.g. abdominal wall and skeletal muscle	
<i>N – regional lymph node metastasis</i>			
x	regional lymph nodes cannot be assessed		
0	no regional lymph node metastasis		
1	regional lymph node metastasis		
<i>M – distant metastasis</i>			
X	distant metastasis cannot be assessed		
0	no distant metastases		
1	distant metastasis		
ENETS stage:			
stage 0:	Tis	N0	M0
stage I:	T1	N0	M0
stage IIa:	T2	N0	M0
stage IIb:	T3	N0	M0
stage IIIa:	T4	N0	M0
stage IIIb:	any T	N1	M0
stage IV:	any T	any N	M1
UICC/AJCC stage:			
stage I:	T1	N0	M0
stage II:	T2-3	N0	M0
stage III:	T4	N0	M0
	any T	N1	M0
stage IV:	any T	any N	M1

**Table 4.** Grading of appendiceal NEN according to ENETS/UICC [72–74]

Grade	Ki67 index	Mitotic index (mitoses/10 HPF)
G1	≤2%	<2
G2	3–20%	2–20
G3	>20%	>20

Another important criterion is invasion of the mesoappendix and the extent of invasion into the mesoappendix (T2 vs. T3 stage according to ENETS, not considered by UICC/AJCC, see table 3) although it is frequently underreported in the pathology reports. Invasion of the NEN into the mesoappendix can relatively frequently be observed in up to 20% of adults and up to 40% in children; on more detailed pathological analysis the incidence may even be higher [145–147]. While infiltration of the appendiceal serosa does not per se seem to be associated with poorer outcome, invasion into the mesoappendix shows a higher rate of lymphatic invasion than in cases without. The depth of invasion beyond 3 mm has been suggested to reflect the aggressiveness of the disease and therefore the TNM classification by ENETS uses this criterion to distinguish T2 from T3 tumours even in case of tumours <2 cm; this means that even smaller tumours with deep mesoappendiceal invasion beyond 3 mm carry a higher risk of metastasis [74]. A more aggressive surgical approach beyond appendicectomy and an appropriate follow-up strategy may therefore be required in these patients, although prospective long-term data are not available at the moment.

#### *Minimal Consensus Statement on Pathology and Genetics*

Histology is always necessary to establish the diagnosis. Cytology may be helpful, particularly in the rare metastatic setting. The minimal ancillary tests to support the histological diagnosis include immunohistochemistry for CgA and synaptophysin. Either the mitotic count per 10 HPF (2 mm<sup>2</sup>, at least 40 fields at 40× magnification), evaluated in areas of highest mitotic density, or the Ki67 index (MIB1 antibody; % of 2,000 cells in areas of highest nuclear labelling), should be reported (table 4). The histopathology report should allow for a correct classification according to the current WHO criteria. ENETS-TNM staging differs for T stages from AJCC/UICC/WHO-TNM staging for appendiceal tumours. It is strongly recommended to use the ENETS-TNM classification in addition to the AJCC/UICC/WHO system and to indicate this in the pathology report (table 3).

No genetic association has been reported thus far and therefore there is currently no need for any genetic testing.

#### *Surgical Therapy*

Two surgical procedures can be applied to treat appendiceal NEN: simple appendicectomy and oncological right-sided hemicolectomy.

As outlined above, appendiceal NEN are frequently diagnosed incidentally on the occasion of appendicectomy for suspected or manifest acute appendicitis. The NEN may either be already detected during this procedure or afterwards by the pathologist on histological evaluation. Similarly to the staging criteria mentioned above, the surgical strategy should be tailored to the individual situation:

For T1 (ENETS) or T1a (UICC/AJCC) NEN (i.e. <1 cm), generally simple appendicectomy is curative and sufficient. The only exception could be the extremely rare situation when the NEN is located at the base of the appendix and incompletely resected or when a mesoappendiceal invasion >3 mm may be detected in these very small NEN. Under these circumstances, completion of the resection seems advisable, although a worsened prognosis has not been proven and a higher complication rate than with simple appendicectomy has to be discussed with the patient.

For NEN >2 cm with a T3 stage (ENETS) or higher and T2 (UICC/AJCC) or higher respectively, a right-sided hemicolectomy is advised due to the clearly increased risk of lymph node metastasis and long-term tumour recurrence and/or distant metastasis. The right-sided hemicolectomy should be performed either as the initial surgical intervention should the problem be overt at that time, or during a second intervention.

In the case of a T2 (ENETS) or a T1b (UICC/AJCC) NEN with a size between 1 and 2 cm, lymph node or distant metastases seems unlikely but possible, particularly on a longitudinal perspective for these in the majority of cases relatively young patients. Thus, definitive curative treatment seems much more likely with right-sided hemicolectomy but at an increased perioperative risk when compared to simple appendicectomy. Therefore, the additional criteria of localisation of the NEN at the base of the appendix (particularly with R1 resection) or a mesoappendiceal invasion >3 mm should be taken into consideration. In any of these cases, right-sided hemicolectomy seems advisable, but long-term prospective data are currently not available.

Additional criteria such as a Ki67 index of 3% or higher (NET-G2) or angioinvasion have been suggested to aid with decision-making, but even less evidence for these criteria has been published.

### *Minimal Consensus Statement on Surgical Therapy*

It is generally felt that a well-differentiated appendiceal NET <2 cm is cured by appendectomy independent of the location of the tumour. Thus, right hemicolectomy is justified only in those rare tumours 1–2 cm but with positive or unclear margins or with deep mesoappendiceal invasion (ENETS T2), higher proliferation rate (G2) and/or angioinvasion. Tumours with a diameter >2 cm should be treated by right hemicolectomy.

#### *Follow-Up*

In cases of curative resection of appendiceal NEN <1 cm by simple appendectomy, no specific follow-up strategy has been recommended.

For cases with right-sided hemicolectomy due to a size >1 cm but without proof of lymph node involvement or any other residual disease in the resected specimen, again a specific follow-up strategy does not seem to be necessary.

For cases with involvement of the lymph nodes or any cases with resected distant metastases, however, long-term follow-up because of the proven invasiveness of the tumour is advised.

Finally, the patient with an appendiceal NEN with a size between 1 and 2 cm who has not received right-sided hemicolectomy for whatever reason (comorbidity, no consent, hesitancy, etc.) but with risk factors (i.e. localisation at the base of the appendix, mesoappendiceal invasion >3 mm, presumably NET-G2 or angioinvasion), regular follow-up due to the presumed risk of lymph node metastases seems advisable but unproven. It should be considered that neither determination of surrogate parameters (i.e. CgA or 5-HIAA) nor indirect non-invasive imaging have been studied for their sensitivity for detection of metastasis or local tumour recurrence in this specific setting. Cumulative exposure to irradiation with repetitive scanning may be an argument to use MRI rather than CT scanning in the younger and particularly the fertile patient (female or male). The role of colonoscopy or transabdominal ultrasound imaging has not been established in this setting, and it is therefore not automatically recommended. However, it seems rational to apply transabdominal ultrasound to extend intervals between MRI or CT examinations.

Although unproven, lifelong awareness of the potential of these slowly growing tumours to recur should be kept in mind in appendiceal NEN >2 cm or >1 cm with risk factors.

### *Minimal Consensus Statement on Follow-Up*

For guidelines regarding follow-up strategies, we recommend to follow the ENETS standards of care [120]. For well-differen-

tiated tumours, diagnosed incidentally, with a maximum diameter <1 cm and R0 resection, no follow-up is required when considered cured. For well-differentiated tumours of 1–2 cm and R0 resection, there are no sufficient data for a clear-cut decision. Most participants of the consensus conference suggested that no follow-up is required. However, in cases with deep mesoappendiceal infiltration or angioinvasion, imaging as outlined above may be performed to rule out any residual disease. All other patients with either larger tumours, metastases or additional risk factors (R1 resection, tumour size >2 cm), should be followed initially after 6 and 12 months postoperatively and then annually, although this approach has not been validated.

## **Goblet Cell Carcinoids/Carcinomas**

### *Introductory Commentary*

Although presenting themselves with more or less pronounced neuroendocrine features, GCC should be considered a rare subtype of mixed adeno-neuroendocrine carcinomas (MANEC) which comprise a clinically and therapeutically differing entity from other midgut NEN. Due to their rarity, data on GCC are scarce and the guidelines below represent mostly expert opinions based on the available literature. ENETS decided to continue to comment on this entity because due to the at least partially neuroendocrine phenotype experts treating NEN are also frequently consulted for GCC. However, GCC are not NEN in a strict sense, which is also demonstrated by the issues discussed below. Because the medical treatment of metastatic GCC is not discussed in the metastatic NEN chapter by Pavel et al. [3], the minimal consensus statement regarding this issue is also included in this section.

### *Epidemiology and Prognosis*

Appendiceal GCC occur with an incidence of approximately 0.01–0.05/100,000/year and thus are very rare epithelial neoplasms [130, 132] with malignant behaviour. GCC represent one subtype within the spectrum of epithelial neoplasms from the appendix which cover colonic type adenocarcinomas, mucinous adenocarcinomas, signet ring cell (adeno)carcinomas, GCC and appendiceal NEN [130–132, 148]. Exact figures on incidences and percentage of GCC among appendiceal neoplasms vary depending on the data source and particularly whether benign appendiceal neoplasms are also considered [149]. However, GCC are malignant neoplasms and therefore probably well documented in the SEER database [130, 132] which currently provides the most detailed information on GCC.

The mean age at initial diagnosis of GCC is 52 years in the SEER database and thus approximately 10 years high-

er than that for appendiceal NEN, but roughly 10 years lower than that for jejunio-ileal NEN. A gender preference has not been described for GCC in population-based databases [130–132, 148] while individual case series, which are probably biased, have shown inconclusive data [150–152]. An ethnic preference for Caucasians is clearly described, with more than 80% of GCC reported in this subgroup in the SEER [130, 132]. However, a recent series reported the characteristics of appendiceal GCC from China [150]; in this series, interestingly an association of GCC with schistosomiasis was discussed, the only potential risk factor for GCC identified to date.

Outcome data are again influenced by varying classifications of appendiceal adenocarcinomas with more or less pronounced goblet cell and/or neuroendocrine features. The overall 5-YSR for GCC ranges between 40 and 75% [130, 131, 148] and is stage-dependent, while, for comparison, the 5-YSR is between 0 and 15% in signet ring cell carcinoma and colonic type adenocarcinoma both of the appendix. While stage distribution is similar to appendiceal NEN at initial diagnosis in the SEER (which includes only ‘malignant’ neoplasms), the outcome is worse even for localised disease (5-YSR 86 vs. 100% in appendiceal NEN) and more pronounced so in regionally metastasised stages (5-YSR 74 vs. 83% in appendiceal NEN) and with distant metastasis (5-YSR 18 vs. 30% in appendiceal NEN). This illustrates that in early stages GCC have a similar outcome to appendiceal NEN, while in advanced stages their outcome figures more closely resemble those of colonic-type adenocarcinoma [130, 131, 148].

#### *Minimal Consensus Statement on Epidemiology and Prognosis*

GCC are rare appendiceal tumours, which must be differentiated from appendiceal NEN, and are considered as MANEC, biologically a subtype of adenocarcinoma. In approximately two thirds they are incidental findings on appendicectomy or ileocaecal resection. They occur during the fifth decade, more often in the Caucasian population than any other group, with an equal distribution between the sexes.

In limited stages survival is better (locoregional disease: 50–80%) than in cases with distant metastasis (5-YSR: <20%).

#### *Clinical Presentation*

The clinical picture patients present with is usually quite non-specific and most frequently includes symptoms of acute appendicitis in approximately 50–60% with or without concurrent peritonitis in an additional 10–20% [137, 151]. The appendicitic cause of the preoperative complaints is usually confirmed in most patients postop-

eratively by histology [153]. In addition, symptoms of small bowel obstruction (up to 20%), or right lower quadrant abdominal pain, may be detected. Diarrhoea has also been described, but approximately one third of the patients may actually be asymptomatic and the GCC an incidental finding on surgery performed for other reasons such as cholecystectomy or gynaecological surgery [134, 137, 151]. GCC may in rare instances also present as Krukenberg tumour(s) in the ovaries [154, 155].

#### *Minimal Consensus Statement on Clinical Presentation*

Most GCC, when located in the mid-third of the appendix, may cause appendicitis. At diagnosis, approximately 10% of these tumours are already widespread with distant metastases to the liver, the ovaries and the peritoneum.

#### *Diagnostic Procedures*

Similarly to appendiceal NEN, most GCC are incidentally diagnosed postoperatively [148] and thus diagnostic procedures mostly concern postoperative rather than preoperative staging and follow-up, and to the rare cases with suspected or evidenced distant metastasis [153, 156].

#### *Imaging*

There are – again similar to appendiceal NEN – no specific diagnostic studies focusing on GCC and therefore the considerations which apply to appendiceal NEN (see above) are also valid for GCC.

Thus, cross-sectional imaging using CT or MRI with modern protocols should be used to rule out locoregional or distant metastasis [138]. GCC limited to the appendix may be detected by transabdominal ultrasonography in spite of its investigator-dependent limitations, but it has not been validated prospectively. Endoscopy is sometimes helpful when the GCC is locally advanced and infiltrates the caecum and is obviously only indicated prior to surgery, which is a rare situation [151]. In the context of potentially increased incidences of secondary neoplasms, general recommendations regarding colorectal cancer screening should be followed [153]. SRI using either scintigraphy (SRS; including SPECT scanning) or PET scanning in combination with CT may be considered in cases when curative resection is not completely assured or when distant metastasis is suspected. However, the sensitivity of SRI decreases with less neuroendocrine differentiation and therefore less somatostatin receptor expression, and cross-sectional imaging is more sensitive and therefore more useful in these cases [157, 158].

### Laboratory Tests

In contrast to appendiceal NEN, serum CgA has no value for the detection and monitoring of GCC [151]. Conversely, carcinoembryonic antigen (CEA), CA-19-9 and CA-125 have been shown to be elevated in GCC in up to 80% of patients, and therefore are of greater value for follow-up of GCC although none of these has been prospectively validated for this indication [151].

### Minimal Consensus Statement on Diagnostic Procedures

Investigations after the initial diagnostic surgical intervention will involve a similar work-up as for high risk (>2 cm) appendiceal endocrine tumours. Because GCC bear a higher risk of distant metastases, a chest CT is added to the work-up strategy, in addition to a CT of abdomen and pelvis or alternatively MRI of the abdomen and pelvis together with SRI; in cases of negative SRI, FDG-PET may be useful but is not validated for GCC. Lifelong screening for synchronous or metachronous malignancies is recommended. In contrast to appendiceal NEN, CgA determination is not recommended. CEA, CA-19-9 and CA-125 are suggested as tumour markers.

### Pathology and Genetics

Since GCC display neuroendocrine as well as adenocarcinomatous features, their histopathological classification is not simple and has been a matter of debate [159, 160].

The histological hallmark of GCC is focal presence of mucin-containing goblet-shaped epithelial cells which may cluster in the lamina propria of submucosa of the appendix, leaving the appendiceal mucosa itself intact [148, 150, 156, 161, 162]. The tumours are usually ill defined and extend both longitudinally and circumferentially within the appendix as well as into the mesoappendix and beyond. Interestingly, a conventional histomorphologic variant of lipid-rich well-differentiated appendiceal NEN is a morphologic differential diagnosis to GCC which should be managed like appendiceal NEN but may histologically be confused with GCC [163] because of their clear cell appearance. GCC, however, stain positive on periodic acid-Schiff (PAS) staining of mucin (with or without alcian blue, PAS-AB), and thus can be differentiated from appendiceal NEN. Another topic of discussion is the conventional histological differential diagnosis between goblet and signet ring cells, the latter being associated with a more unfavourable prognosis [148, 160, 164]. For the clinician this probably means that in cases of doubt a second pathological opinion from a referral centre is advisable. TNM classification should be performed

**Table 5.** TNM classification of GCC according to UICC/AJCC (identical to TNM classification of appendiceal NEN by UICC/AJCC) [73] (TNM classification)

<i>T – primary tumour</i>			
x	primary tumour cannot be assessed		
0	no evidence of primary tumour		
1	tumour ≤2 cm in greatest dimension		
a	tumour ≤1 cm in greatest dimension		
b	tumour >1 cm but ≤2 cm in greatest dimension		
2	tumour >2 cm but ≤4 cm or with extension to the caecum		
3	tumour >4 cm or with extension to the ileum		
4	tumour perforates peritoneum or invades other adjacent organs or structures, e.g. abdominal wall and skeletal muscle		
<i>N – regional lymph node metastasis</i>			
x	regional lymph nodes cannot be assessed		
0	no regional lymph node metastasis		
1	regional lymph node metastasis		
<i>M – distant metastasis</i>			
X	distant metastasis cannot be assessed		
0	no distant metastases		
1	distant metastasis		
Stage:			
stage I:	T1	N0	M0
stage II:	T2-3	N0	M0
stage III:	T4	N0	M0
	any T	N1	M0
stage IV:	any T	any N	M1

according to UICC/AJCC in analogy to appendiceal NEN (table 5) [73].

Immunohistochemical staining of GCC shows some characteristics that clearly identify the majority of GCC. Besides more or less pronounced expression of the neuroendocrine markers CgA and synaptophysin, the expression of CEA provides the hallmark marker that differentiates between appendiceal NEN and GCC [150, 161, 165]. Cytokeratin staining for CK20 [161, 166] or CK19 [162] may assist in differential diagnosis between appendiceal NEN or adenocarcinomas respectively. The presence of mucin vacuoles and decreased number of secretory granules in comparison to NEN has also been ultrastructurally confirmed by electron microscopy [165]. However, in very rare cases, truly mixed tumours with features of both NEN and GCC may also exist [167].

Ki67 increases with decreasing differentiation of appendiceal neoplasms, however a clear correlation with clinical outcome as in NEN has been suggested by small series but not unequivocally [148, 160–162, 165]; it is however recommended as a routine indicator of prognosis

since it seems to be generally and significantly higher in the appendiceal adenocarcinomas than in GCC and NEN. Grading of the adeno-component similar to grading of jejuno-ileal and appendiceal NEN (tables 2, 4) might be of prognostic relevance [148] but awaits validation.

Other interesting immunohistochemical markers or combinations of such have been studied such as staining for glucagon in combination with serotonin [161], CK19 and CD99 [162], p21,  $\beta$ -catenin and E-cadherin [150], but cannot currently be recommended for routine application.

There are only very few genetic studies on appendiceal GCC which have suggested that, similar to jejuno-ileal NEN, allelic loss of chromosomes 11q, 16q and 18q may play a role in the pathogenesis of GCC [87]. However, there is neither a familial association nor a clinically relevant role for genetic testing.

#### *Minimal Consensus Statement on Pathology and Genetics*

A complete pathological report requires ancillary immunohistochemical tests such as CgA, synaptophysin, CEA, CK20 and PAS-AB to differentiate other tumour entities; other IHC markers for tumour cell subtyping or malignant behaviour are not validated in GCC. Mitotic index or Ki67 should be assessed following the consensus recommendations (see tables 2, 4), but their correlation with prognosis is not established in GCC. The WHO system does not include GCC in the category of NEN. TNM for GCC is as for adenocarcinomas of the appendix (see table 5). These tumours should be treated as adenocarcinomas depending on stage. However, patients with these tumours are referred to NEN centres.

No genetic association has been reported thus far and therefore there is currently no evidence for any genetic testing.

#### *Surgical Therapy*

Right hemicolectomy, usually to be performed after initial appendectomy, is the standard surgical intervention for the majority of GCC, since metastatic risk is high and prognosis poor if metastasis occurs [130, 151–153, 156, 168]. Right hemicolectomy is recommended to take place within 3 months of the appendectomy, in which case the same surgical strategy applies as for colorectal tumours. Some authors have shown that GCC <1 cm, localised tumours, without serosal, mesoappendiceal or caecal invasion, and with low proliferative index, can be better served with appendectomy alone [136, 152, 153], because in these low-risk tumours metastases rarely develop. However, these are very rare situations. Morbidity of right hemicolectomy is not negligible, and can be as high as 40% in the elderly. In female patients with GCC of the appendix, regardless of age, bilat-

eral salpingo-oophorectomy has been suggested [156] but its advantage remains unproven. Cytoreductive surgery with adjuvant intraperitoneal chemotherapy may offer prolonged survival in cases with advanced peritoneal dissemination [156, 169, 170] but has not been studied prospectively. Surgical treatment of liver metastases might follow the standard procedures recommended in the guidelines for intestinal neuroendocrine carcinomas, but experience is scarce, since this clinical setting seems to be extremely rare. Thus, there are no data to address the question as to whether goblet cell liver metastases should be treated similar to liver metastases from colorectal cancer.

#### *Minimal Consensus Statement on Surgical Therapy*

Hemicolectomy is considered the standard surgical treatment of GCC. Treatment of liver metastases, particularly medical treatment, should follow the corresponding recommendations for adenocarcinomas (i.e. colonic carcinoma).

#### *Palliative Therapy of Metastatic GCC*

In cases of non-resectable locoregional disease or distant metastasis, a cytotoxic anti-proliferative treatment is indicated and has been shown to be effective in at least 50% of reported patients with stable disease for a minimum of 8 months and up to more than 12 months [87, 151, 152, 156, 169]. However, the substances used are quite variable but most include a 5-fluorouracil-based combination regimen (e.g. FOLFOX).

Other treatment strategies, such as ablative treatment of liver metastasis, have not been systematically studied, but may be considered in individual cases. PRRT has also not systematically been studied, depends on somatostatin receptor expression and is less effective in patients with higher Ki67 index [171]; therefore it is still highly investigational and cannot be generally recommended.

#### *Minimal Consensus Statement on Medical Therapy*

In spite of the scarcity of data, based on clinical experience and anecdotal reports, it is recommended that patients with advanced GCC are treated with 5-fluorouracil-based chemotherapeutic regimens as for colorectal adenocarcinoma.

#### *Follow-Up*

Because GCC is a more malignant entity and has a high tendency to recur, a comparable strategy to colorectal carcinoma is recommended. In case of metastatic disease, ongoing 3-month-interval staging is recommended to detect disease progression and submit to therapy [153, 156].



Another aspect is that even in curatively resected and long-term recurrence-free patients, secondary neoplasms such as colorectal cancer have been described with increased incidence as compared to the average population, and therefore lifelong surveillance should be performed although the precise strategy has not been defined [137, 153].

#### *Minimal Consensus Statement on Follow-Up*

The scheduled follow-up for patients after curative surgical treatment should include clinical, biochemical and imaging every 3–6 months, then yearly, mimicking the guidelines for colorectal adenocarcinoma. Due to the malignant potential the duration of the follow-up should be unlimited, but this has not been formally studied. Gastrointestinal follow-up is recommended because of the high coincidence (up to 48%) of gastrointestinal neoplasms in these patients.

#### **Medical Therapy in Advanced Disease – General**

Treatment of advanced disease is updated in a separate and comprehensive chapter [3]. Here is a brief summary regarding anti-proliferative treatment. In a prospective randomised placebo-controlled trial of octreotide LAR in midgut NET (PROMID trial) the anti-proliferative efficacy of octreotide LAR has been confirmed [172]. Median time to tumour progression was 14.3 months with octreotide LAR and 6.0 months with placebo. Based on the results of this trial, the use of SSAs, especially octreotide LAR, is recommended for anti-proliferative purposes in functioning and non-functioning midgut tumours.

Two prospective randomised trials in metastatic gastroenteropancreatic NETs have shown that SSAs, interferon or the combination of both, have comparable anti-proliferative effects when used after prior disease progression [172, 173].

PRRT is considered in both functioning and non-functioning NET and irrespective of the primary tumour site. Based upon small phase II trials and retrospective data, partial remission rates range between 0 and 33% [174, 175].

Given the limited treatment options for anti-proliferative therapy in NET of midgut and other non-pancreatic sites, everolimus, if available, may be a treatment option in functioning and non-functioning NETs [176].

#### *Minimal Consensus Statement on Medical Therapy in Advanced Disease*

SSAs are recommended first-line therapy in non-functioning midgut NET if G1 and slowly progressive, and may be consid-

ered in therapy naive patients with metastatic disease without a prior observation period of spontaneous tumour growth behaviour as studied in the PROMID trial.

The early combination use of SSA and interferons for anti-proliferative purposes is not recommended.

Chemotherapy might be an option exclusively in advanced intestinal NET after failure to several previous treatment lines.

The use of PRRT cannot be recommended as first-line therapy, but after failure of medical therapy. The presence of a strong expression of sstr2 as visualised by SRI is a prerequisite for the use of PRRT. The minimum requirements for PRRT are reported in a separate consensus guideline [177].

Everolimus should be considered only in progressive disease after failure of SSAs; potential other options include locoregional therapies, interferon- $\alpha$  and PRRT.

#### **Complete List of Participants**

##### *List of Participants of the Consensus Conference on the 2011 Consensus Guidelines for the Management of Patients with Digestive Neuroendocrine Tumors: An Update*

Martin Anlauf, Germany (Martin.Anlauf@gmx.de)  
Rudolf Arnold, Germany (arnoldr@staff.uni-marburg.de)  
Detlef Bartsch, Germany (bartsch@med.uni-marburg.de)  
Eric Baudin, France (baudin@igr.fr)  
Richard Baum, Germany (info@rpbaum.de)  
Maria Luisa Brandi, Italy (m.brandi@dmi.unifi.it)  
Guillaume Cadiot, France (gcadiot@chu-reims.fr)  
Frederico Costa, Brazil (frederico.costa@hsl.org.br)  
Martyn Caplin, UK (m.caplin@medsch.ucl.ac.uk)  
Anne Couvelard, France (anne.couvelard@bjn.aphp.fr)  
Wouter de Herder, The Netherlands (w.w.deherder@erasmusmc.nl)  
Gianfranco Delle Fave, Italy (gianfranco.dellefave@uniroma1.it)  
Timm Denecke, Germany (timm.denecke@charite.de)  
Barbro Eriksson, Sweden (barbro.eriksson@medsci.uu.se)  
Massimo Falconi, Italy (massimo.falconi@univr.it)  
Thomas Gress, Germany (gress@med.uni-marburg.de)  
David Gross, Israel (gross@vms.huji.ac.il)  
Ashley Grossman, UK (a.b.grossman@qmul.ac.uk)  
Robert Jensen, USA (robertj@bdg10.niddk.nih.gov)  
Gregory Kaltsas, Greece (gkaltsas@endo.gr)  
Fahrettin Kelestimur, Turkey (fktimur@erciyes.edu.tr)  
Reza Kianmanesh, France (reza.kianmanesh@lmr.ap-hop-paris.fr)  
Günter Klöppel, Germany (guenter.kloepfel@alumni.uni-kiel.de)  
Klaus-Jochen Klose, Germany (klose@med.uni-marburg.de)  
Ulrich Knigge, Denmark (knigge@mfi.ku.dk)  
Paul Komminoth, Switzerland (paul.komminoth@triemli.stzh.ch)  
Beata Kos-Kudla, Poland (beatakos@ka.onet.pl)  
Eric Krenning, The Netherlands (e.p.krenning@erasmusmc.nl)  
Dik Kwekkeboom, The Netherlands (d.j.kwekkeboom@erasmusmc.nl)  
Jose Manuel Lopes, Portugal (jmlopes@ipatimup.pt)  
Bruno Niederle, Austria (bruno.niederle@meduniwien.ac.at)  
Ola Nilsson, Sweden (ola.nilsson@llcr.med.gu.se)  
Kjell Öberg, Sweden (kjell.oberg@medsci.uu.se)  
Juan O'Connor, Argentina (juanconnor@hotmail.com)  
Dermot O'Toole, Ireland (dermot.otoole@tcd.ie)  
Ulrich-Frank Pape, Germany (ulrich-frank.pape@charite.de)

Mauro Papotti, Italy (mauro.papotti@unito.it)  
 Andreas Pascher, Germany (andreas.pascher@charite.de)  
 Marianne Pavel, Germany (marianne.pavel@charite.de)  
 Aurel Perren, Switzerland (aurel.perren@pathology.unibe.ch)  
 Ursula Plöckinger, Germany (ursula.ploeckinger@charite.de)  
 Guido Rindi, Italy (guido.rindi@rm.unicatt.it)  
 Philippe Ruzsniowski, France  
 (philippe.ruzsniowski@bjn.aphp.fr)  
 Ramon Salazar, Spain (ramonsalazar@iconcologia.net)  
 Hironobu Sasano, Japan (hsasano@patholo2.med.tohoku.ac.jp)  
 Alain Sauvanet, France (alain.sauvanet@bjn.aphp.fr)

Jean-Yves Scoazec, France (jean-yves.scoazec@chu-lyon.fr)  
 Thomas Steinmüller, Germany  
 (t.steinmueller@drk-kliniken-westend.de)  
 Anders Sundin, Sweden (anders.sundin@radiol.uu.se)  
 Babs Taal, The Netherlands (b.taal@nki.nl)  
 Paola Tomassetti, Italy (paola.tomassetti@unibo.it)  
 Eric Van Cutsem, Belgium (eric.vancutsem@uzleuven.be)  
 Marie-Pierre Vullierme, France  
 (marie-pierre.vullierme@bjn.aphp.fr)  
 Bertram Wiedenmann, Germany  
 (bertram.wiedenmann@charite.de)

## References

- Eriksson B, Klöppel G, Krenning E, et al: Consensus guidelines for the management of patients with digestive neuroendocrine tumours: well-differentiated jejunal-ileal tumour/carcinoma. *Neuroendocrinology* 2008;87:8–19.
- Plöckinger U, Couvelard A, Falconi M, et al: Consensus guidelines for the management of patients with digestive neuroendocrine tumours: well-differentiated tumour/carcinoma of the appendix and goblet cell carcinoma. *Neuroendocrinology* 2008;87:20–30.
- Pavel M, Baudin E, Couvelard A, Krenning E, Öberg K, Steinmüller T, et al: ENETS consensus guidelines for the management of patients with liver and other distant metastases from neuroendocrine tumors of foregut, midgut, hindgut, and unknown primary. *Neuroendocrinology* 2012;95:157–176.
- Ahlman H, Nilsson O, McNicol AM, et al: Poorly-differentiated endocrine carcinomas of midgut and hindgut origin. *Neuroendocrinology*. 2008;87:40–46.
- Oberndorfer S: Karzinoide Tumoren des Dünndarms. *Frankf Z Pathol* 1907;1:426–423.
- Ellis L, Shale MJ, Coeman MP: Carcinoid tumors of the gastrointestinal tract: trends in incidence in England since 1971. *Am J Gastroenterol* 2010;105:2563–2569.
- Ito T, Sasano H, Tanaka M, et al: Epidemiological study of gastroenteropancreatic neuroendocrine tumors in Japan. *J Gastroenterol* 2010;45:234–243.
- Yao JC, Hassan M, Phan A, et al: One hundred years after ‘carcinoid’: epidemiology of and prognostic factors for neuroendocrine tumors in 35,825 cases in the United States. *J Clin Oncol* 2008;26:3063–3072.
- Hauso O, Gustafsson BI, Kidd M, et al: Neuroendocrine tumor epidemiology: contrasting Norway and North America. *Cancer* 2008;113:2655–2664.
- Landerholm K, Falkmer S, Järhult J: Epidemiology of small bowel carcinoids in a defined population. *World J Surg* 2010;34:1500–1505.
- Niederle MB, Hackl M, Kaserer K, et al: Gastroenteropancreatic neuroendocrine tumours: the current incidence and staging based on the WHO and European Neuroendocrine Tumour Society classification: an analysis based on prospectively collected parameters. *Endocr Relat Cancer* 2010;17:909–918.
- Pape UF, Berndt U, Müller-Nordhorn J, et al: Prognostic factors of long-term outcome in gastroenteropancreatic neuroendocrine tumours. *Endocr Relat Cancer* 2008;15:1083–1097.
- García-Carbonero R, Capdevila J, Crespo-Herrero G, et al: Incidence, patterns of care and prognostic factors for outcome of gastroenteropancreatic neuroendocrine tumors (GEP-NETs): results from the National Cancer Registry of Spain (RGETNE). *Ann Oncol* 2010;21:1794–1803.
- Lepage C, Bouvier AM, Manfredi S, et al: Incidence and management of primary malignant small bowel cancers: a well-defined French population study. *Am J Gastroenterol* 2006;101:2826–2832.
- Ploekinger U, Kloepfel G, Wiedenmann B, et al: The German NET registry: an audit on the diagnosis and therapy of neuroendocrine tumours. *Neuroendocrinology* 2009;90:349–363.
- Bergestuen DS, Aabakken L, Holm K, et al: Small intestinal neuroendocrine tumors: prognostic factors and survival. *Scand J Gastroenterol* 2009;44:1084–1091.
- Berge T, Linell F: Carcinoid tumours. Frequency in a defined population during a 12-year period. *Acta Pathol Microbiol Scand* 1976;84:322–330.
- Klimstra DS, Arnold R, Capella C, et al: Bosman FT, Carneiro F, Hruban RH, Theise ND (eds): WHO Classification of Tumours of the Digestive System. Lyon, IARC, 2010.
- Jann H, Roll S, Couvelard A, et al: Neuroendocrine tumors of midgut and hindgut origin: tumor-node-metastasis classification determines clinical outcome. *Cancer* 2011;117:3332–3341.
- Boudreaux JP, Klimstra DS, Hassan MM, et al: The NANETS consensus guideline for the diagnosis and management of neuroendocrine tumors: well-differentiated neuroendocrine tumors of the jejunum, ileum, appendix, and cecum. *Pancreas* 2010;39:753–766.
- Quaedvlieg PF, Visser O, Lamers CB, Jansen-Heijen ML, Taal BG: Epidemiology and survival in patients with carcinoid disease in the Netherlands. An epidemiological study with 2,391 patients. *Ann Oncol* 2001;12:1295–1300.
- Perez EA, Koniari LG, Snell SE, et al: 7,201 carcinoids: increasing incidence overall and disproportionate mortality in the elderly. *World J Surg* 2007;1022–1030.
- Strosberg J, Gardner N, Kvols L: Survival and prognostic factor analysis of 146 metastatic neuroendocrine tumors of the mid-gut. *Neuroendocrinology* 2009;89:471–476.
- Helland SK, Prosch AM, Viste A: Carcinoid tumours in the gastrointestinal tract – a population-based study from western Norway. *Scand J Surg* 2006;95:158–161.
- Ahmed A, Turner G, King B, et al: Midgut neuroendocrine tumours with liver metastases: results of the UKINETS study. *Endocr Relat Cancer* 2009;16:885–894.
- Pape UF, Böhmig M, Berndt U, et al: Survival and clinical outcome of patients with neuroendocrine tumors of the gastroenteropancreatic tract in a German referral center. *Ann NY Acad Sci* 2004;1014:222–233.
- Niederle MB, Niederle B: Diagnosis and treatment of gastroenteropancreatic neuroendocrine tumors: current data on a prospectively collected, retrospectively analyzed clinical multicenter investigation. *Oncologist* 2011;16:602–613.
- Druce MR, Bharwani N, Akker SA, et al: Intra-abdominal fibrosis in a recent cohort of patients with neuroendocrine (‘carcinoid’) tumours of the small bowel. *QJM* 2010;103:177–185.
- Castillo JG, Filsoufi F, Adams DH, et al: Management of patients undergoing multi-valvular surgery for carcinoid heart disease: the role of the anaesthetist. *Br J Anaesth* 2008;101:618–626.
- Ricke J, Klose KJ, Mignon M, et al: Standardisation of imaging in neuroendocrine tumours: results of a European delphi process. *Eur J Radiol* 2001;37:8–17.

- 31 Kaltsas G, Rockall A, Papadogias D, et al: Recent advances in radiological and radionuclide imaging and therapy of neuroendocrine tumours. *Eur J Endocrinol* 2004;151:15–27.
- 32 Bader TR, Semelka RC, Chiu VC, et al: MRI of carcinoid tumors: spectrum of appearances in the gastrointestinal tract and liver. *J Magn Reson Imaging* 2001;14:261–269.
- 33 Masselli G, Poletini E, Casciani E, et al: Small-bowel neoplasms: prospective evaluation of MR enteroclysis. *Radiology* 2009;251:743–750.
- 34 Kamaoui I, De-Luca V, Ficarelli S, et al: Value of CT enteroclysis in suspected small-bowel carcinoid tumors. *AJR Am J Roentgenol* 2010;194:629–633.
- 35 Doerffel Y, Wermke W: Neuroendocrine tumors: characterization with contrast-enhanced ultrasonography. *Ultraschall Med* 2008;29:506–514.
- 36 Van Tuyl SAC, van Noorden JT, Timmer J, et al: Detection of small-bowel neuroendocrine tumors by video-capsule endoscopy. *Gastrointest Endosc* 2006;64:66–72.
- 37 Johanssen S, Boivin M, Lochs H, et al: The yield of wireless capsule endoscopy in the detection of neuroendocrine tumors in comparison with CT enteroclysis. *Gastrointest Endosc* 2006;63:660–665.
- 38 Bailey AA, Debinski HS, Appleyard MN, et al: Diagnosis and outcome of small bowel tumors found by capsule endoscopy: a three-center Australian experience. *Am J Gastroenterol* 2006;101:2237–2243.
- 39 Belluti M, Fry LC, Schmitt J, et al: Detection of neuroendocrine tumours of the small bowel by double balloon enteroscopy. *Dig Dis Sci* 2009;54:1050–1058.
- 40 Ezziddin S, Logviniski T, Yong-Hing C, et al: Factors predicting tracer uptake in somatostatin receptor and MIBG scintigraphy of metastatic gastroenteropancreatic neuroendocrine tumors. *J Nucl Med* 2006;47:223–233.
- 41 Orlefors H, Sundin A, Garske U, et al: Whole-body <sup>11</sup>C-5-hydroxytryptophan positron emission tomography as a universal imaging technique for neuroendocrine tumors: comparison with somatostatin receptor scintigraphy and computed tomography. *J Clin Endocrinol Metab* 2005;90:3392–3400.
- 42 Gabriel M, Decristofori C, Kendler D, et al: <sup>68</sup>Ga-DOTA-Tyr<sup>3</sup>-octreotide PET in neuroendocrine tumors: comparison with somatostatin receptor scintigraphy and CT. *J Nucl Med* 2007;48:508–518.
- 43 Buchmann I, Henze M, Engelbrecht S, et al: Comparison of <sup>68</sup>Ga-DOTATOC PET and <sup>111</sup>In-DTPAOC (Octreoscan) SPECT in patients with neuroendocrine tumours. *Eur J Nucl Med Mol Imaging* 2007;1617–1626.
- 44 Ruf J, Steffen I, Mehl S, et al: Influence of attenuation correction by integrated low-dose CT on somatostatin receptor SPECT. *Nucl Med Commun* 2007;28:782–788.
- 45 Ambrosini V, Tomassetti P, Castellucci P, et al: Comparison between <sup>68</sup>Ga-DOTA-NOC and <sup>18</sup>F-DOPA PET for the detection of gastro-entero-pancreatic and lung neuroendocrine tumours. *Eur J Nucl Med Mol Imaging* 2008;35:1431–1438.
- 46 Koopmans KP, Neels OC, Kema IP, et al: Improved staging of patients with carcinoid and islet cell tumours with <sup>18</sup>F-dihydroxyphenyl-alanine and <sup>11</sup>C-5-hydroxytryptophan positron emission tomography. *J Clin Oncol* 2008;26:1489–1495.
- 47 Haug A, Auernhammer CJ, Wängler B, et al: Intraindividual comparison of <sup>68</sup>Ga-DOTA-TATE and <sup>18</sup>F-DOPA PET in patients with well-differentiated metastatic neuroendocrine tumours. *Eur J Nucl Med Mol Imaging* 2009;36:765–770.
- 48 Montravers F, Kerrou K, Nataf V, et al: Impact of fluorodihydroxyphenylalanine-<sup>18</sup>F positron emission tomography on management of adult patients with documented or occult digestive endocrine tumors. *J Clin Endocrinol Metab* 2009;94:1295–1301.
- 49 Ruf J, Heuck F, Schiefer J, et al: Impact of multiphase <sup>68</sup>Ga-DOTATOC-PET/CT on therapy management in patients with neuroendocrine tumours. *Neuroendocrinology* 2010;91:101–109.
- 50 Prasad V, Baum RP: Biodistribution of the <sup>68</sup>Ga-labeled somatostatin analogue DOTA-NOC in patients with neuroendocrine tumors: characterization of uptake in normal organs and tumor lesions. *Q J Nucl Med Mol Imaging* 2010;54:61–67.
- 51 Prasad V, Ambrosini V, Hommann M, et al: Detection of unknown primary neuroendocrine tumours (CUP-NET) using <sup>68</sup>Ga-DOTA-NOC receptor PET/CT. *Eur J Nucl Med Mol Imaging* 2010;37:67–77.
- 52 Ruf J, Schiefer J, Furth C, et al: <sup>68</sup>Ga-DOTA-TOC PET/CT of neuroendocrine tumors: spotlight on the CT phases of a triple-phase protocol. *J Nucl Med* 2011;52:697–704.
- 53 Koopmans KP, de Vries EGE, Kema IP, et al: Staging of carcinoid tumours with <sup>18</sup>F-DOPA PET: a prospective, diagnostic accuracy study. *Lancet Oncol* 2006;7:728–734.
- 54 Orlefors H, Sundin A, Garske U, et al: Whole-body <sup>11</sup>C-5-hydroxytryptophan positron emission tomography as a universal imaging technique for neuroendocrine tumors: comparison with somatostatin receptor scintigraphy and computed tomography. *J Clin Endocrinol Metab* 2005;90:3392–3400.
- 55 Meijer WG, van der Veer E, Jager PL, et al: Bone metastases in carcinoid tumors: clinical features, imaging characteristics, and markers of bone metabolism. *J Nucl Med* 2003;44:184–191.
- 56 Ardill JE, Eriksson B: The importance of the measurement of circulating markers in patients with neuroendocrine tumours of the pancreas and gut. *Endocr Relat Cancer* 2003;10:459–462.
- 57 Feldman JM, O'Dorisio TM: Role of neuropeptides and serotonin in the diagnosis of carcinoid tumors. *Am J Med* 1986;81:41–48.
- 58 Eriksson B, Oberg K: Peptide hormones as tumor markers in neuroendocrine gastrointestinal tumors. *Acta Oncol* 1991;30:477–483.
- 59 Arnold R, Wilke A, Rinke A, et al: Plasma chromogranin A as marker for survival in patients with metastatic endocrine gastroenteropancreatic tumors. *Clin Gastroenterol Hepatol* 2008;6:820–827.
- 60 Korse CM, Bonfrer JMG, Aaronson NK, et al: Chromogranin A as an alternative to 5-hydroxyindoleacetic acid in the evaluation of symptoms during treatment of patients with neuroendocrine tumours. *Neuroendocrinology* 2009;89:296–301.
- 61 Zatelli MC, Torta M, Leon A, et al: Chromogranin A as a marker of neuroendocrine neoplasia: an Italian multicenter study. *Endocr Relat Cancer* 2007;14:473–482.
- 62 Stridsberg M, Eriksson B, Oberg K, et al: A comparison between three commercial kits for chromogranin A measurements. *J Endocrinol* 2003;177:337–341.
- 63 Peracchi M, Gebbia C, Basilisco G, et al: Plasma chromogranin A in patients with autoimmune chronic atrophic gastritis, enterochromaffin-like cell lesions and gastric carcinoids. *Eur J Endocrinol* 2005;152:443–448.
- 64 Spadaro A, Ajello A, Morace C, et al: Serum chromogranin-A in hepatocellular carcinoma: diagnostic utility and limits. *World J Gastroenterol* 2005;11:1987–1990.
- 65 Giusti M, Sidoti M, Augeri C, et al: Effect of short-term treatment with low dosages of the proton-pump inhibitor omeprazole on serum chromogranin A levels in man. *Eur J Endocrinol* 2004;150:299–303.
- 66 Massironi S, Fraquelli M, Paggi S, et al: Chromogranin A levels in chronic liver disease and hepatocellular carcinoma. *Dig Liver Dis.* 2009;41:31–35.
- 67 Welin S, Stridsberg M, Cunningham J, et al: Elevated plasma chromogranin A is the first indication of recurrence in radically operated midgut carcinoid tumours. *Neuroendocrinology* 2009;89:302–307.
- 68 Meijer WG, Kema IP, Volmer M, et al: Discriminating capacity of indole markers in the diagnosis of carcinoid tumors. *Clin Chem* 2000;46:1588–1596.
- 69 Kema IP, Meijer WG, Meiborg G, et al: Profiling of tryptophan-related plasma indoles in patients with carcinoid tumors by automated, on-line, solid-phase extraction and HPLC with fluorescence detection. *Clin Chem* 2001;47:1811–1820.
- 70 O'Toole D, Grossman A, Gross D, et al: ENETS consensus guidelines for the standards of care in neuroendocrine tumors: biochemical markers. *Neuroendocrinology* 2009;90:194–202.
- 71 Hamilton SR AL: Tumours of the Digestive System. Pathology and Genetics. WHO Classification of Tumours. Lyon, ARC Press, 2000.

- 72 Klimstra DS, Arnold R, Capella C, et al: Bosman FT, Carneiro F, Hruban RH, Theise ND (eds): WHO Classification of Tumours of the Digestive System. Lyon, IARC, 2010.
- 73 Sobin LH, Gospodarowicz MK, Wittekind C (eds): TNM Classification of Malignant Tumours. Chichester, Wiley & Blackwell, 2009.
- 74 Rindi G, Klöppel G, Couvelard A, et al: TNM staging of midgut and hindgut (neuro)endocrine tumors: a consensus proposal including a grading system. *Virchows Arch* 2007; 451:757–762.
- 75 Welin S, Sorbye H, Sebjornsen S, et al: Clinical effect of temozolomide-based chemotherapy in poorly differentiated endocrine carcinoma after progression on first-line chemotherapy. *Cancer* 2011 (E-pub ahead of print).
- 76 Volante M, Brizzi MP, Faggiano A, et al: Somatostatin receptor type 2A immunohistochemistry in neuroendocrine tumours: a proposal of scoring system correlated with somatostatin receptor scintigraphy. *Mod Pathol* 2007;20:1172–1182.
- 77 Srirajaskanthan R, Watkins J, Marelli L, et al: Expression of somatostatin and dopamine-2 receptors in neuroendocrine tumours and the potential role for new biotherapies. *Neuroendocrinology* 2009;89:308–314.
- 78 Miederer M, Seidl S, Buck A, et al: Correlation of immunohistopathological expression of somatostatin receptor-2 with standardised uptake values in <sup>68</sup>Ga-DOTATOC PET/CT. *Eur J Nucl Med Mol Imaging* 2009;36:48–52.
- 79 Schmitt AM, Riniker F, Anlauf M, et al: Islet-1 (Isl1) expression is a reliable marker for pancreatic endocrine tumors and their metastases. *Am J Surg Pathol* 2008;32:420–425.
- 80 Grabowski P, Schrader J, Wagner J, et al: Loss of nuclear p27 expression and its prognostic role in relation to cyclin E and p53 mutation in gastroenteropancreatic neuroendocrine tumors. *Clin Cancer Res* 2008;14:7378–7384.
- 81 Besig S, Volland P, Baur DM, et al: Vascular endothelial growth factors, angiogenesis, and survival in human ileal enterochromaffin cell carcinoids. *Neuroendocrinology* 2009;90:402–415.
- 82 Volland P, Besig S, Rad R, et al: Correlation of matrix metalloproteinases and tissue inhibitors of matrix metalloproteinase expression in ileal carcinoids, lymph nodes and liver metastasis with prognosis and survival. *Neuroendocrinology* 2009;89:66–78.
- 83 Hemminki K, Li X: Familial carcinoid tumors and subsequent cancers: a nationwide epidemiologic study from Sweden. *Int J Cancer* 2001;94:444–448.
- 84 Hassan MM, Phan A, Li D, et al: Family history of cancer and associated risk of developing neuroendocrine tumors: a case-control study. *Cancer Epidemiol Biomarkers Prev* 2008;17:959–965.
- 85 Järhult J, Landerholm K, Falkmer S, et al: First report on metastasizing small bowel carcinoids in first-degree relatives in three generations. *Neuroendocrinology* 2010;91:318–323.
- 86 Tönnies H, Toliat MR, Ramel C, et al: Analysis of sporadic neuroendocrine tumours of the enteropancreatic system by comparative genomic hybridisation *Gut* 2001;48:536–541.
- 87 Stancu M, Wu TT, Wallace C, et al: Genetic alterations in goblet cell carcinoids of the vermiform appendix and comparison with gastrointestinal carcinoid tumors. *Mod Pathol* 2003;16:1189–1198.
- 88 Akerstrom G, Makridis C, Johansson H: Abdominal surgery in patients with midgut carcinoid tumors. *Acta Oncol* 1991;30:547–553.
- 89 Rothmund M, Kisker O: Surgical treatment of carcinoid tumors of the small bowel, appendix, colon and rectum. *Digestion* 1994; 55(suppl 3):86–91.
- 90 Ahlman H, Wangberg B, Jansson S, et al: Interventional treatment of gastrointestinal neuroendocrine tumours. *Digestion* 2000;62(suppl 1):59–68.
- 91 Makridis C, Oberg K, Juhlin C, et al: Surgical treatment of mid-gut carcinoid tumors. *World J Surg* 1990;14:377–384.
- 92 Norton JA: Surgical management of carcinoid tumors: role of debulking and surgery for patients with advanced disease. *Digestion* 1994;55(suppl 3):98–103.
- 93 Goede AC, Winslet MC: Surgery for carcinoid tumors of the lower gastrointestinal tract. *Colorectal Dis* 2003;5:123–128.
- 94 Sutton R, Doran HE, Williams EMI, et al: Surgery for midgut carcinoid. *Endocr Relat Cancer* 2003;10:469–481.
- 95 Han SL, Cheng J, Zhou HZ, et al: Surgically treated primary malignant tumor of small bowel: a clinical analysis. *World J Gastroenterol* 2010;16:1527–1532.
- 96 Hellman P, Lundström T, Ohrvall, et al: Effect of surgery on the outcome of midgut carcinoid disease with lymph node and liver metastases. *World J Surg* 2002;26:991–997.
- 97 Eriksson J, Stalberg P, Nilsson A, et al: Surgery and radiofrequency ablation for treatment of liver metastases from midgut and foregut carcinoids and endocrine pancreatic tumors. *World J Surg* 2008;32:930–938.
- 98 Toumpanakis C, Garland J, Marelli L, et al: Long-term results of patients with malignant carcinoid syndrome receiving octreotide LAR. *Aliment Pharmacol Ther* 2009; 30:733–740.
- 99 Norlen O, Hessman O, Stalberg P, et al: Prophylactic cholecystectomy in midgut carcinoid patients. *World Surg* 2010;34:1361–1367.
- 100 Schindl M, Kaczirek K, Passler C, et al: Treatment of small intestinal neuroendocrine tumors: is an extended multimodal approach justified? *World J Surg* 2002;26:976–984.
- 101 Givi B, Pommier SEJ, Thompson AK, et al: Operative resection of primary carcinoid neoplasms in patients with liver metastases yields significantly better survival. *Surgery* 2006;140:891–898.
- 102 Steinmüller T, Kianmanesh R, Falconi M, et al: Consensus guidelines for the management of patients with liver metastases from digestive (neuro)endocrine tumours: foregut, midgut, hindgut, and unknown primary. *Neuroendocrinology* 2008;87:47–62.
- 103 Zuetenhorst JM, Bonfrer JM, Korse CM, et al: Carcinoid heart disease: the role of urinary 5-hydroxyindoleacetic acid excretion and plasma levels of atrial natriuretic peptide, transforming growth factor- $\beta$  and fibroblast growth factor. *Cancer* 2003;97:1609–1615.
- 104 Norheim I, Oberg K, Theodorsson-Norheim E, et al: Malignant carcinoid tumors. An analysis of 103 patients with regard to tumor localization, hormone production, and survival. *Ann Surg* 1987;206:115–125.
- 105 Møller JE, Connolly HM, Rubin J, et al: Factors associated with progression of carcinoid heart disease. *N Engl J Med* 2003;348:1005–1015.
- 106 Møller JE, Pellikka PA, Bernheim AM, et al: Prognosis of carcinoid heart disease: analysis of 200 cases over two decades. *Circulation* 2005 22;112:3320–3327.
- 107 Bhattacharyya S, Davar J, Dreyfus G, et al: Carcinoid heart disease. *Circulation* 2007; 116:2860–2865.
- 108 Mansencal N, Mitry E, Bachet JB, et al: Echocardiographic follow-up of treated patients with carcinoid syndrome. *Am J Cardiol* 2010;105:1588–1591.
- 109 Castillo JG, Filsoufi F, Rahmanian PB, et al: Early and late results of valvular surgery for carcinoid heart disease. *J Am Coll Cardiol* 2008;51:1507–1509.
- 110 Bhattacharyya S, Raja SG, Toumpanakis C, et al: Outcomes, risks and complications of cardiac surgery for carcinoid heart disease. *Eur J Cardiothorac Surg* 2011;40:168–172.
- 111 Jacobsen MB, Nitter-Hauge S, Bryde PE, Hanssen LE: Cardiac manifestations in mid-gut carcinoid disease. *Eur Heart J* 1995;16:263–268.
- 112 Druce M, Rockall A, Grossman AB: Fibrosis and carcinoid syndrome: from causation to future therapy. *Nat Rev Endocrinol* 2009; 5:276–283.
- 113 Sandmann H, Pakkal M, Steeds R: Cardiovascular magnetic resonance imaging in the assessment of carcinoid heart disease. *Clin Radiol* 2009;64:761–766.
- 114 Mansencal N, McKenna WJ, Mitry E, et al: Comparison of prognostic value of tissue Doppler imaging in carcinoid heart disease versus the value in patients with the carcinoid syndrome but without carcinoid heart disease. *Am J Cardiol* 2010;105:527–531.
- 115 Bhattacharyya S, Toumpanakis C, Chilkunda D, et al: Risk factors for the development and progression of carcinoid heart disease. *Am J Cardiol* 2011;107:1221–1226.

- 116 Zuetenhorst JM, Korse CM, Bonfrer JM, et al: Role of natriuretic peptides in the diagnosis and treatment of patients with carcinoid heart disease. *Br J Cancer* 2004;90:2073–2079.
- 117 Bernheim AM, Connolly HM, Rubin J, et al: Role of hepatic resection for patients with carcinoid heart disease. *Mayo Clin Proc* 2008;83:143–150.
- 118 Mansencal N, Mitry E, Forissier JF, et al: Assessment of patent foramen ovale in carcinoid heart disease. *Am Heart J* 2006;151:1129.e1–6.
- 119 Mansencal N, Mitry E, Pillière R, et al: Prevalence of patent foramen ovale and usefulness of percutaneous closure device in carcinoid heart disease. *Am J Cardiol* 2008;101:1035–1038.
- 120 Arnold R, Chen YJ, Costa F, et al: ENETS consensus guidelines for the standards of care in neuroendocrine tumours: follow-up and documentation. *Neuroendocrinology* 2009;90:227–233.
- 121 Moertel CG: Karnofsky memorial lecture. An odyssey in the land of small tumors. *J Clin Oncol* 1987;5:1502–1522.
- 122 In't Hof KH, van der Wal HC, Kazemier G, et al: Carcinoid tumour of the appendix: an analysis of 1,485 consecutive emergency appendectomies. *J Gastrointest Surg* 2008;12:1436–1438.
- 123 Modlin IM, Lye KD, Kidd M: A five-decade analysis of 13,715 carcinoid tumors. *Cancer* 2003;97:934–959.
- 124 Lepage C, Rachtel B, Coleman MP: Survival from malignant digestive endocrine tumors in England and Wales: a population-based study. *Gastroenterology* 2007;132:899–904.
- 125 Moertel CG, Dockerty MB, Judd ES: Carcinoid tumors of the vermiform appendix. *Cancer* 1968;21:270–278.
- 126 Goede AC, Caplin ME, Winslet MC: Carcinoid tumour of the appendix. *Br J Surg* 2003;90:1317–1322.
- 127 Iwuagwu OC, Jameel JK, Drew PJ, et al: Primary carcinoma of the appendix – Hull series. *Dig Surg* 2005;22:163–167.
- 128 Fornai R, Frascio M, Sticchi C, et al: Appendectomy or right hemicolectomy in the treatment of appendiceal carcinoid tumors? *Tumori* 2007;93:587–590.
- 129 Groth SS, Virnig BA, Al-Refaie WB, et al: Appendiceal carcinoid tumors: predictors of lymph node metastasis and the impact of right hemicolectomy on survival. *J Surg Oncol* 2011;103:39–45.
- 130 McGory ML, Maggard MA, Kang H, et al: Malignancies of the appendix: beyond case series reports. *Dis Colon Rectum* 2005;48:2264–2271.
- 131 Landry CS, Woodall C, Scoggins, et al: Analysis of 900 appendiceal carcinoid tumors for a proposed predictive staging system. *Arch Surg* 2008;143:664–670.
- 132 McCusker ME, Cote TR, Clegg LX, et al: Primary malignant neoplasms of the appendix: a population-based study from the surveillance, epidemiology and end-results program, 1973–1998. *Cancer* 2002;94:3307–3312.
- 133 Lepage C, Ciccolallo L, De Angelis R, et al: European disparities in malignant digestive endocrine tumours survival. *Int J Cancer* 2010;126:2928–2934.
- 134 Moertel CG, Weiland LH, Nagorney DM, et al: Carcinoid tumor of the appendix: treatment and prognosis. *N Engl J Med* 1987;317:1699–1701.
- 135 Stinner B, Rothmund M: Neuroendocrine tumours (carcinoids) of the appendix. *Best Pract Res Clin Gastroenterol* 2005;19:729–738.
- 136 Deans GT, Spence RA: Neoplastic lesions of the appendix. *Br J Surg* 1995;82:299–306.
- 137 O'Donnell ME, Carson J, Garstin WIH, et al: Surgical treatment of malignant carcinoid tumours of the appendix. *Int J Clin Pract* 2007;61:431–437.
- 138 Pickhardt PJ, Levy AD, Rohrmann CA, et al: Primary neoplasms of the appendix: radiologic spectrum of disease with pathologic correlation. *Radiographics* 2003;23:645–662.
- 139 Prommegger R, Ensinger C, Adlassnig C, et al: Catestatin – a novel neuropeptide in carcinoid tumors of the appendix. *Anticancer Res* 2004;24:311–316.
- 140 Modlin IM, Kidd M, Latich I, et al: Genetic differentiation of appendiceal tumor malignancy: a guide for the perplexed. *Ann Surg* 2006;244:52–60.
- 141 Prommegger R, Obrist P, Ensinger C, et al: Retrospective evaluation of carcinoid tumors of the appendix in children. *World J Surg* 2002;26:1489–1492.
- 142 Parkes SE, Muir KR, Sheyyab M, et al: Carcinoid tumours of the appendix in children 1957–1986: incidence, treatment and outcome. *Br J Surg* 1993;80:502–504.
- 143 Bamboat ZM, Berger DL: Is right hemicolectomy for 2.0-cm appendiceal carcinoids justified? *Arch Surg* 2006;141:349–352.
- 144 Alexandraki KI, Griniatsos J, Bramis KI, et al: Clinical value of right hemicolectomy for appendiceal carcinoids using pathologic criteria. *J Endocrinol Invest* 2011;34:255–259.
- 145 Dunn JP: Carcinoid tumours of the appendix: 21 cases, with a review of the literature. *NZ Med J* 1982;95:73–76.
- 146 Prommegger R, Obrist P, Ensinger C, et al: Secretoneurin in carcinoids of the appendix-immunohistochemical comparison with chromogranin A, B and secretogranin II. *Anticancer Res* 1998;18:3999–4002.
- 147 Rossi G, Valli R, Bertolini F, et al: Does mesoappendix infiltration predict a worse prognosis in incidental neuroendocrine tumors of the appendix? A clinicopathologic and immunohistochemical study of 15 cases. *Am J Clin Pathol* 2003;120:706–711.
- 148 Tang LH, Shia J, Soslow RA, et al: Pathologic classification and clinical behavior of the spectrum of goblet cell carcinoid tumors of the appendix. *Am J Surg Pathol* 2008;32:1429–1443.
- 149 Hemminki K, Li X: Incidence trends and risk factors of carcinoid tumors: a nationwide epidemiologic study from Sweden. *Cancer* 2001;92:2204–2210.
- 150 Jiang Y, Long H, Wang W, et al: Clinicopathological features and immunexpression profiles of goblet cell carcinoid and typical carcinoid of the appendix. *Pathol Oncol Res* 2011;17:127–132.
- 151 Toumpanakis C, Standish RA, Baishnab E, et al: Goblet cell carcinoid tumors (adenocarcinoid) of the appendix. *Dis Colon Rectum* 2006;50:315–322.
- 152 Pham TH, Wolff B, Abraham SC, et al: Surgical and chemotherapy treatment outcomes of goblet cell carcinoid: a tertiary cancer center experience. *Ann Surg Oncol* 2006;13:370–376.
- 153 Bucher P, Gervaz P, Ris F, et al: Surgical treatment of appendiceal adenocarcinoid (goblet cell carcinoid). *World J Surg* 2005;29:1436–1439.
- 154 Mandai M, Konishi I, Tsuruta Y, et al: Krukenberg tumor from an occult appendiceal adenocarcinoid: a case report and review of the literature. *Eur J Obstet Gynecol Reprod Biol* 2001;97:90–95.
- 155 Hristov AC, Young RH, Vang R, et al: Ovarian metastases of appendiceal tumors with goblet cell carcinoid-like and signet ring cell patterns: a report of 30 cases. *Am J Surg Pathol* 2007;31:1502–1511.
- 156 Pahlavan PS, Kanthan R: Goblet cell carcinoid of the appendix. *World J Surg Oncol* 2005;3:36.
- 157 Maggard MA, O'Connell JB, Ko CY: Updated population-based review of carcinoid tumors. *Ann Surg* 2004;240:117–122.
- 158 Dromain C, de Baere T, Lumbroso J, et al: Detection of liver metastases from endocrine tumors: a prospective comparison of somatostatin receptor scintigraphy, computed tomography, and magnetic resonance imaging. *J Clin Oncol* 2005;23:70–78.
- 159 Grimelius L: Methods in neuroendocrine histopathology – a methodological overview. *Ups J Med Sci* 2008;113:243–260.
- 160 Wang HL, Dhall D: Goblet or signet ring cells – that is the question. *Adv Anat Pathol* 2009;16:247–254.
- 161 Van Eeden S, Offerhaus GJA, Hart AAM, et al: Goblet cell carcinoid of the appendix: a specific type of carcinoma. *Histopathology* 2007;51:763–773.
- 162 Alsaad K, Serra S, Perren A, et al: CK19 and CD99 immunorepression profile in goblet cell (mucin-producing neuroendocrine tumors) and classical carcinoids of the vermiform appendix. *Int J Surg Pathol* 2007;15:252–257.
- 163 La Rosa S, Finzi G, Puppa G, et al: Lipid-rich variant of appendiceal well-differentiated endocrine tumor (carcinoid). *Am J Clin Pathol* 2010;133:809–814.

- 164 Chetty R: Goblet cell carcinoid tumours of the appendix: a unique neuroendocrine tumour. *Histopathology* 2008;52:770–771.
- 165 Kanthan R, Saxena A, Kanthan SC: Goblet cell carcinoids of the appendix: immunophenotype and ultrastructural study. *Arch Pathol Lab Med* 2001;125:386–390.
- 166 Alsaad KO, Serra S, Schmitt A, et al: Cytokeratins 7 and 20 immunoexpression profile in goblet cell and classical carcinoids of appendix. *Endocr Pathol* 2007;18:16–22.
- 167 Chetty R, Klimstra DS, Henson DE, et al: Combined classical carcinoid and goblet cell carcinoid tumor: a new morphologic variant of carcinoid tumor of the appendix. *Am J Surg Pathol* 2010;34:1163–1167.
- 168 Butler JA, Houshiar A, Lin F, et al: Goblet cell carcinoid of the appendix. *Am J Surg* 1994;168:685–687.
- 169 Garin L, Corbinais S, Boucher E, et al: Adenocarcinoid of the appendix vermiformis complete and persistent remission after chemotherapy (folfox) of a metastatic case. *Dig Dis Sci* 2002;47:2760–2762.
- 170 Mahteme H, Sugarbaker PH: Treatment of peritoneal carcinomatosis from adenocarcinoid of appendiceal origin. *Br J Surg* 2004;91:1168–1173.
- 171 Ezziddin S, Opitz M, Attassi M, et al: Impact of the Ki-67 proliferation index on response to peptide receptor radionuclide therapy. *Eur J Nucl Med Mol Imaging* 2011;38:459–466.
- 172 Arnold R, Rinke A, Klose KJ, Muller HH, Wied M, Zamzow K, et al: Octreotide versus octreotide plus interferon in endocrine gastroenteropancreatic tumors: a randomized trial. *Clin Gastroenterol Hepatol* 2005;3:761–771.
- 173 Faiss S, Pape UF, Bohmig M, et al: International Lanreotide and Interferon Alfa Study Group: prospective, randomized, multicenter trial on the antiproliferative effect of lanreotide, interferon alfa, and their combination for therapy of metastatic neuroendocrine gastroenteropancreatic tumors. *J Clin Oncol* 2003;21:2689–2696.
- 174 Kwekkeboom DJ, de Herder WW, van Eijck CH, et al: Peptide receptor radionuclide therapy in patients with gastroenteropancreatic neuroendocrine tumors. *Semin Nucl Med* 2010;40:78–88.
- 175 Kwekkeboom DJ, de Herder WW, Kam BL, et al: Treatment with the radiolabeled somatostatin analog [<sup>177</sup>Lu-DOTA<sup>0</sup>,Tyr<sup>3</sup>]octreotate: toxicity, efficacy, and survival. *J Clin Oncol* 2008;26:2124–2130.
- 176 Pavel M, Hainsworth JD, Baudin E, et al: Everolimus plus octreotide long-acting repeatable for the treatment of advanced neuroendocrine tumours associated with carcinoid syndrome (RADIANT-2): a randomised, placebo-controlled, phase 3 study. *Lancet* 2011;378:2005–2012.
- 177 Kwekkeboom DJ, Krenning EP, Lebtahi R, et al: ENETS consensus guidelines for the standards of care in neuroendocrine tumours: peptide receptor radionuclide therapy with radiolabeled somatostatin analogs. *Neuroendocrinology* 2009;90:220–226.