

Enterobacter Asburiae Pneumonia with Cavitation¹

공동을 형성한 Enterobacter Asburiae 폐렴의 증례¹

Seung Woo Cha, MD¹, Jeong Nam Heo, MD¹, Choong-Ki Park, MD¹, Yo Won Choi, MD²,
Seok Chol Jeon, MD²

¹Department of Radiology, Hanyang University College of Medicine, Guri Hospital, Guri, Korea

²Department of Radiology, Hanyang University College of Medicine, Seoul Hospital, Seoul, Korea

Enterobacter species have increasingly been identified as pathogens over the past several decades. These bacterial species have become more important because most are resistant to cephalothin and cefoxitin, and can produce extended-spectrum β -lactamase. *Enterobacter asburiae* (*E. asburiae*) is a gram-negative rod of the family Enterobacteriaceae, named in 1986. Since then, there has been only one clinical report of *E. asburiae* pneumonia. We report a case of *E. asburiae* pneumonia with cavitation and compare it with the previous case.

Index terms

Enterobacter Asburiae

Enterobacter

Cavitation

Pneumonia

Received September 16, 2012; Accepted December 10, 2012

Corresponding author: Jeong Nam Heo, MD

Department of Radiology, Hanyang University College of Medicine, Guri Hospital, 153 Gyeongchun-ro, Guri 471-701, Korea.

Tel. 82-31-560-2563 Fax. 82-31-560-2551

E-mail: radjena@hanyang.ac.kr

Copyrights © 2013 The Korean Society of Radiology

INTRODUCTION

Enterobacter species have increasingly been identified as pathogens over the past several decades (1). *Enterobacter asburiae* (*E. asburiae*) is a gram-negative rod of the family Enterobacteriaceae (2), classified as the Enteric group 17 by Farmer et al. (3). The species was named in 1986 (2), and since then, there has only been one clinical report of *E. asburiae* pneumonia (1). We report a case of *E. asburiae* pneumonia with cavitation and compared it with the previous case.

CASE REPORT

A 74-year-old man was admitted to our hospital and underwent radiofrequency ablation due to hepatocellular carcinoma. His chest radiograph was clear at that time (Fig. 1A).

Six months later, he was admitted to the emergency department with fever, chills and facial rash. His legal guardian said that he was in the habit of playing computer games and smok-

ing through the night. Chest radiography revealed a large cavity in the right upper lobe and extensive consolidation in the left lung (Fig. 1B).

Because our location is an area of endemic pulmonary tuberculosis, we started anti-tuberculous medication (Isoniazid 300 mg, Rifampin 450 mg, Ethambutol 600 mg, Pyrazinamide 1000 mg). The consolidation improved slightly after 3 weeks, but the patient's condition did not get better. In the meantime, *E. asburiae* was cultured from his sputum. This bacterium was resistant to several antibiotics: Amoxicillin, Ampicillin, Cefoxitin and Cephalothin. We therefore stopped anti-tuberculous medication and changed to IV antibiotics (Tazoperan 4.5 g). Subsequently, patient's condition improved and the consolidation in the left lower lobe disappeared (Fig. 1C). However, the cavitory lesion in the right upper lobe has persisted until now.

DISCUSSION

Enterobacter species have increasingly been identified as

pathogens over the past several decades (1). These bacteria have become more important because most of them are resistant to cephalothin and cefoxitin (4), and they can produce extended-spectrum β -lactamase (ESBL). In Korea, Choi et al. (5) reported that 12.8% of *Enterobacter* isolates produce ESBL.

There has been only one clinical report of *E. asburiae* pneumonia (1). This previous case and ours have in common the presence of cavitation on chest radiography. Of course, other gram-negative bacteria can cause cavitation, especially *Klebsiella*, *Proteus*, and *Pseudomonas* (6), but cavitation due to *Enterobacter* species appears to be less common than cases due to other gram-negative bacilli (7). The clinical and laboratory manifestations of *E. asburiae* pneumonia differ little from those of other gram-negative pneumonias, but the symptoms of *E. asburiae* pneumonia may be subtle or muted, especially in the elderly (7).

Although there is only one previous reported case of *E. asburiae* pneumonia, both it and our case involve cavitation. The subtlety of the symptoms of *E. asburiae* pneumonia may be the reason why patients only come to the hospital after a considerable progression of pneumonia, and the delay could be responsible for lung cavitation. Another possible cause of cavitation is the tendency of *E. asburiae* to grow rapidly. These characteristics tend to lead to abscess formation.

REFERENCES

1. Stewart JM, Quirk JR. Community-acquired pneumonia caused by *Enterobacter asburiae*. *Am J Med* 2001;111:82-83
2. Brenner DJ, McWhorter AC, Kai A, Steigerwalt AG, Farmer JJ 3rd. *Enterobacter asburiae* sp. nov., a new species found in clinical specimens, and reassignment of *Erwinia dissolvens* and *Erwinia nimipressuralis* to the genus *Enterobacter* as *Enterobacter dissolvens* comb. nov. and *Enterobacter nimipressuralis* comb. nov. *J Clin Microbiol* 1986;23:1114-1120
3. Farmer JJ 3rd, Davis BR, Hickman-Brenner FW, McWhorter A, Huntley-Carter GP, Asbury MA, et al. Biochemical identification of new species and biogroups of *Enterobacteriaceae* isolated from clinical specimens. *J Clin Microbiol* 1985;21:46-76
4. Ehrhardt AF, Sanders CC, Thomson KS, Watanakunakorn C, Trujillano-Martin I. Emergence of resistance to imipenem in *Enterobacter* isolates masquerading as *Klebsiella pneumoniae* during therapy with imipenem/cilastatin. *Clin Infect Dis* 1993;17:120-122
5. Choi SH, Lee JE, Park SJ, Kim MN, Choo EJ, Kwak YG, et al.

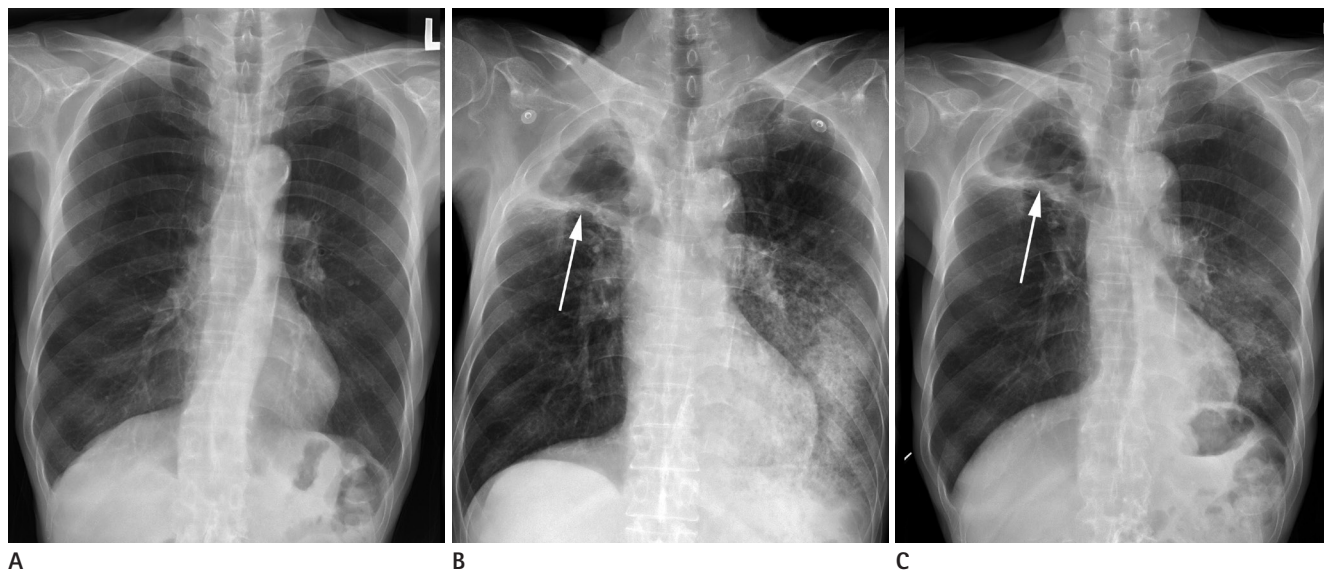


Fig. 1. *Enterobacter asburiae* pneumonia with cavitation in a 74-year-old man.

A. Chest radiograph after radiofrequency ablation for hepatocellular carcinoma is clear.

B. Radiograph obtained after 6 months for the evaluation of fever shows a large cavity in the right upper lobe (arrow) and extensive consolidation in the left lung.

C. After administration of IV antibiotics (Tazoperan 4.5 g), consolidation in the left lower lobe disappeared. The cavitary lesion in the right upper lobe (arrow) has persisted until now.

Prevalence, microbiology, and clinical characteristics of extended-spectrum beta-lactamase-producing *Enterobacter* spp., *Serratia marcescens*, *Citrobacter freundii*, and *Morganella morganii* in Korea. *Eur J Clin Microbiol Infect Dis* 2007;26:557-561

6. Hansell DM, Lynch DA, McAdams HP, Bankier AA. *Imaging*

of the diseases of the chest. Philadelphia: Elsevier Mosby; 2005

7. Sanders WE Jr, Sanders CC. *Enterobacter* spp.: pathogens poised to flourish at the turn of the century. *Clin Microbiol Rev* 1997;10:220-241

공동을 형성한 *Enterobacter Asburiae* 폐렴의 증례¹

차승우¹ · 허정남¹ · 박충기¹ · 최요원² · 전석철²

Enterobacter 종은 지난 수십 년간 동정되는 횟수가 증가해 오고 있다. 이 병원균은 대부분이 cephalothin과 cefoxitin에 저항성이 있고 extended-spectrum의 β -lactamase를 만들 수 있어서 그 중요성이 증가하고 있다. 그 중 *Enterobacter asburiae* (*E. asburiae*)는 Enterobacteriaceae 과에 속하는 그람음성간균으로 1986년에 명명되었다. 그 이후로, *E. asburiae* 폐렴은 한 개의 임상 증례 이외에 보고된 바가 없다. 우리는 공동을 형성한 *E. asburiae* 폐렴의 증례를 보고하고 이전의 임상 증례와 비교하고자 한다.

¹한양대학교 의과대학 구리병원 영상의학과, ²한양대학교 의과대학 서울병원 영상의학과