

## Case report

### Entirely thoracoscopic resection of a giant emphysematous bulla



**Agustín Buero<sup>1,8</sup>, Walter Sebastian Nardi<sup>1</sup>, Gustavo Alejandro Lyons<sup>1</sup>, Silvia Quadrelli<sup>1</sup>, Domingo Javier Chimondeguy<sup>1</sup>**

<sup>1</sup>British Hospital of Buenos Aires, Buenos Aires, Argentina

<sup>8</sup>Corresponding author: Agustín Buero, British Hospital of Buenos Aires, Buenos Aires, Argentina

Key words: giant bulla, bullectomy, VATS

Received: 01/04/2017 - Accepted: 22/07/2018 - Published: 06/08/2018

#### Abstract

A 38-year-old man with longilinear shape, smoker (38 packs/year) and no other relevant medical history was referred to our department due to the finding of left pulmonary hyperlucency on a chest x-ray. A computed tomography (CT) was performed and a giant emphysematous bulla with thin-walled partitions inside was shown that replaced almost the entire left upper lobe. The patient underwent an exploratory thoracoscopy. Intraoperatively a giant bulla was seen that initially impressed to replace the entire upper lobe. Despite the large size we decided to attempt thoracoscopic resection preserving the remaining healthy parenchyma. Bullectomy was done using linear endoscopic stapling devices. To our knowledge this is the only case with such a large bulla resected entirely by VATS.

**Pan African Medical Journal. 2018; 30:247 doi:10.11604/pamj.2018.30.247.12400**

This article is available online at: <http://www.panafrican-med-journal.com/content/article/30/247/full/>

© Agustín Buero et al. The Pan African Medical Journal - ISSN 1937-8688. This is an Open Access article distributed under the terms of the Creative Commons Attribution License (<http://creativecommons.org/licenses/by/2.0>), which permits unrestricted use, distribution, and reproduction in any medium, provided the original work is properly cited.

## Introduction

---

Giant bullous emphysema (GBE) was first described by Burke in 1937 [1] and involves the presence of emphysematous areas with complete destruction of lung tissue producing airspaces bigger than 1cm in diameter. The bulla area does not participate in bronchoalveolar oxygenation and can cause symptoms such as dyspnea, thoracic pain, infection, pneumothorax and even slow progression to malignancy. Roberts et al described radiographic criteria for this entity: giant bullae in one or both upper lobes occupying at least one third of the hemithorax and compressing the normal surrounding parenchyma [2]. Surgery is indicated in symptomatic patients and in asymptomatic patients who have a bulla that occupies more than one-third of the hemithorax or when in the clinical follow-up an increase in the size of the bulla is observed. We report herein the case of a patient with a giant bulla who underwent successful bullectomy.

## Patient and observation

---

A 38-year-old man with longilinear shape, smoker (38 packs/year) with no other relevant medical history was referred to our department due to the finding of left pulmonary hyperlucency on a chest x-ray done (Figure 1A) because of an upper airway disease. A computed tomography (CT) was performed and a giant emphysematous bulla with thin-walled partitions inside was shown, that replaced almost the entire left upper lobe (Figure 1B). Preoperative spirometry revealed a forced vital capacity (FVC) of 5.5lts (99%) and forced expiratory volume on the 1st second (FEV1) of 3.27lts (71%). Carbon monoxide diffusion was 6.84 (58%). The dosage of alpha-1 antitrypsin was within the reference values. The patient underwent an exploratory thoracoscopy to evaluate the extension of the bulla. Intraoperatively we saw a giant bulla that initially impressed to replace the entire upper lobe. Once all firm adhesions to parietal pleura were released and the bulla was opened for a better dissection, because of its large size, we saw that the upper lobe was partially affected persisting a healthy parenchyma area. Despite the large size we decided to attempt thoroscopic resection trying to preserve the remaining healthy parenchyma. Bullectomy was done using six linear endoscopic stapling devices of 60mm. Pulmonary insufflation after resection showed a good lung expansion of the remnant (Figure 2 A-G). Finally mechanical pleural abrasion was done. Pleural cavity was drained with two chest tubes connected to a water seal. Histopathology examination revealed a giant cavitated emphysematous bulla with walls 0.1cm thick. Patient presented lack of lung expansion on chest x-ray with persistent air loss through both drains. Continuous aspiration was placed. He remained with pleural drainage for 13 days (Figure 1C). A postoperative spirometry and CT showed an improvement of all the volumes and carbon monoxide diffusion (FVC 6.07lts -108%, FEV1 5.31lts -116%, DLCO 9.42 - 80%) and complete pulmonary expansion (Figure 1D).

## Discussion

---

GBE, sometimes referred to as Vanishing Lung Syndrome (VLS) as a clinical syndrome, was first described by Burke in 1937. It typically presents in young males cigarette smokers as in our patient and also can be associated with other conditions (alpha-1 antitrypsin deficiency or marijuana abuse). Development of multiple large lung bullae (termed GBE or VLS) is a rare and progressive disease with chest radiographs showing peripheral (paraseptal) bullae in contrast to the more uniformly distributed bullae of centrilobular emphysema

shown in smokers. High resolution computed tomography (HRCT) typically shows extensive paraseptal emphysema coalescing into giant bullae and is the best imaging to determine the extension of the disease. Surgery is indicated to treat complications related to GBE or in asymptomatic patients who have a bulla that occupies more than one-third of the hemithorax compressing healthy adjacent lung tissue and when in the clinical follow-up an increase in the size of the bulla is observed. Different thoroscopic techniques are reported in literature and almost all are nowadays abandoned [3-5]. The VATS bullectomy with endoscopic staple resection is considered a safe and feasible procedure when possible. We consider that total resection must be done since the higher risk in patients with GBE to develop bronchogenic carcinoma [6, 7]. The most common post-operative complication following bullectomy is persistent air leakage, which can prolong hospital stay [8, 9]. In spite of this, it did not prevent the compressed lung tissue from re-expanding. Some authors recommend the use of pericardial strips to prevent the air leakage in the case of lung volume reduction for severe emphysema [10]. Other authors suggest associating a pleurectomy in order to achieve a better pleurodesis and reduce air leaking.

## Conclusion

---

We presented the only case with a bulla of such size resected completely by videothoracoscopy. To obtain satisfactory results, both postoperative and operative care are essential. As we mentioned, the most frequent complication is persistent air leakage and the lack of pulmonary expansion in the postoperative period. The use of adequate mechanical sutures, some type of pleurodesis and mechanical and respiratory kinesiology are key points in this type of interventions. Despite there is not enough evidence published with similar cases resolved entirely by VATS, we consider that it's a safe and feasible procedure in experienced centers.

## Competing interests

---

The authors declare no competing interests.

## Authors' contributions

---

Agustin Buero drafted the manuscript and therefore made the major substantive contribution and was also assisting surgeon. Walter Sebastian Nardi helped to draft the manuscript, and was also assisting surgeon. Gustavo Alejandro Lyons was the operating surgeon, coordinated the draft of the manuscript and revised the manuscript critically. Silvia Quadrelli and Domingo Javier Chimondeguy revised the manuscript for intellectual content and helped to coordinate the draft of the manuscript and to revise the manuscript critically. All the authors have read and agreed to the final manuscript.

## Figures

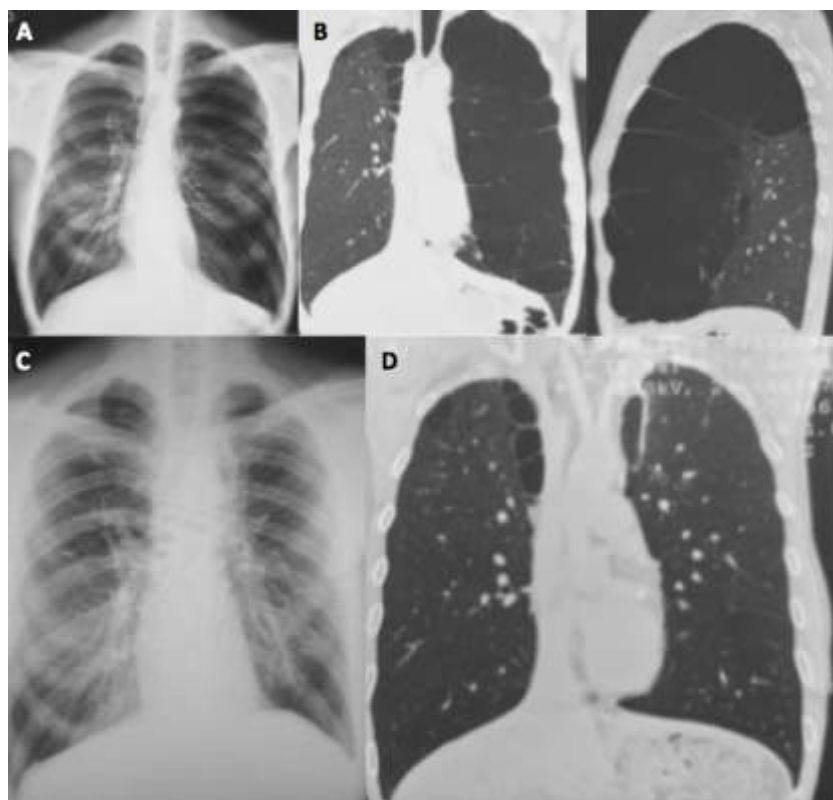
---

**Figure 1:** A) preoperative chest X-Ray. Left pulmonary hyperlucency; B) preoperative chest CT. Giant emphysematous bulla with thin-walled partitions inside replacing almost the entire upper lobe; C) postoperative chest X-Ray. Complete pulmonary expansion; D) postoperative chest CT

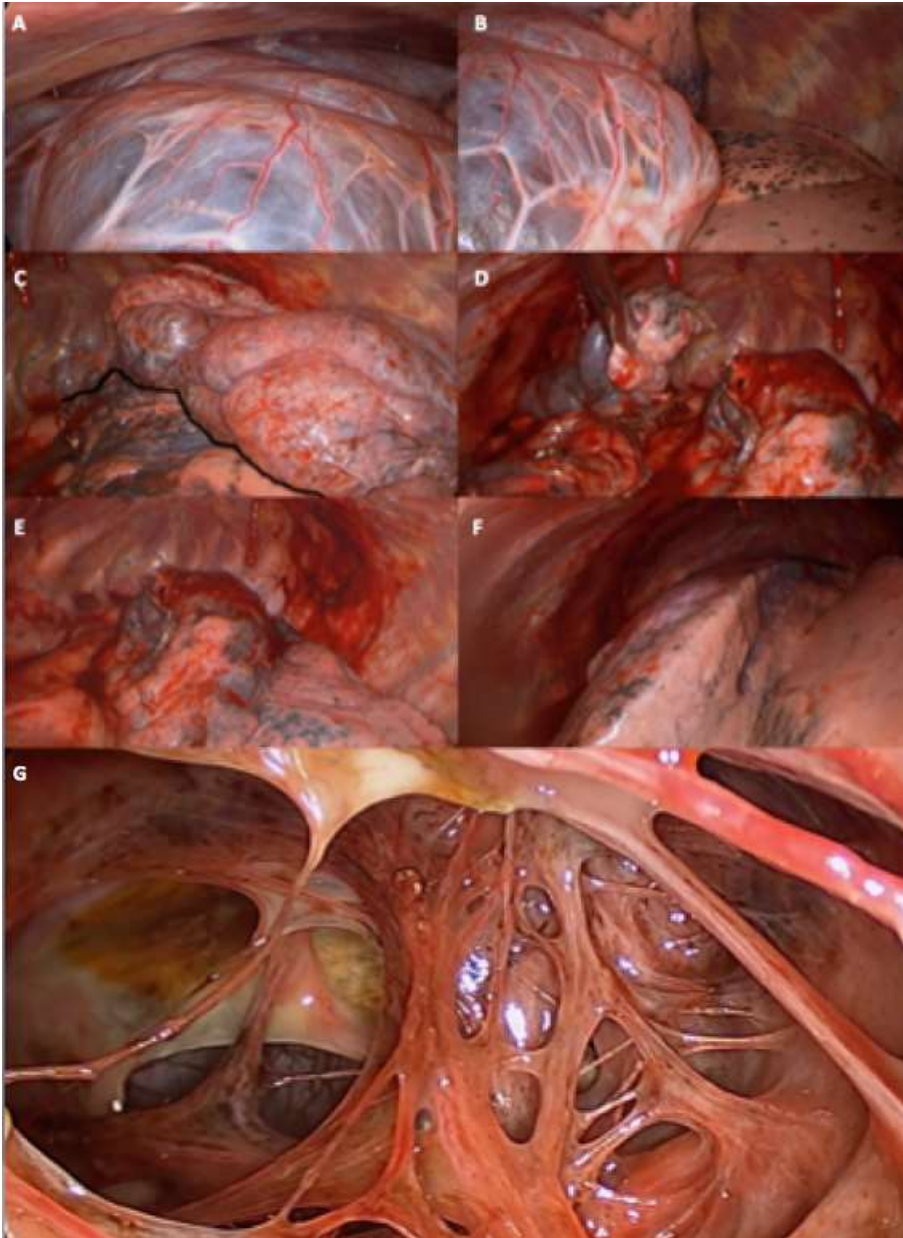
**Figure 2:** A) giant bulla occupying; B) upper lobe almost replaced by the giant bulla. Healthy lower lobe; C) upper lobe was partially affected persisting a healthy parenchyma area. Black line: implantation line of the bulla; (D, E) bullectomy performed with endoscopic stapling devices; F) lung expansion of the remnant; G) interior of the bulla

## References

1. Burke R. Vanishing lungs: a case report of bullous emphysema. *Radiology*. 1937; 28(3): 367-71. [PubMed](#) | [Google Scholar](#)
2. Roberts L, Putman CE, Chen JT et al. Vanishing lung syndrome: upper lobe bullous pneumopathy. *Rev Interam Radiol*. 1987; 12: 249-55.
3. Brenner M, Kayaleh RA, Milne EN, Dellabella L, Osann K, Tadir Y et al. Thoracoscopic laser-ablation of pulmonary bullae-radiographic selection and treatment response. *J thorac Cardiovasc Surg*. 1994; 107(3): 883-890. [PubMed](#)
4. Hillerdal G, Gustafsson G, Wegenius G, Englesson S, Hedenstrom H, Hedenstierna G. Large emphysematous bullae-successful treatment with thoracoscopic technique using fibrin glue in poor-risk patients. *Chest*. 1995; 107(5): 1450-1453. [PubMed](#) | [Google Scholar](#)
5. Nathanson LK, Shimi SM, Wood RAB, Cuschieri A. Videothoroscopic ligation of bulla and pleurectomy for spontaneous pneumothorax. *Ann Thorac Surg*. 1991; 52(2): 316-319. [PubMed](#) | [Google Scholar](#)
6. Venuta F, Rending EA, Pescarmona EO, DeGiacomo T, Vizza D, Flaishman I et al. Occult lung cancer in patients with bullous emphysema. *Thorax*. 1997; 52(3): 289-290. [PubMed](#) | [Google Scholar](#)
7. Golstein MJ, Snider GL, Liberson M, Poske RM. Bronchogenic carcinoma and giant bullous disease. *Am Rev Respir Dis*. 1968; 97(6P1): 1062. [PubMed](#) | [Google Scholar](#)
8. Schipper PH, Meyers BF, Battafarano RJ et al. Outcomes after resection of giant emphysematous bullae. *Ann Thorac Surg*. 2004; 78(3): 976-82. [PubMed](#) | [Google Scholar](#)
9. Gunnarsson SI, Johannesson KB, Gudjonsdottir M et al. Incidence and outcomes of surgical resection for giant pulmonary bullae-a population-based study. *Stand J Surg*. 2012; 101(3): 166-9. [PubMed](#) | [Google Scholar](#)
10. Cooper JD. Technique to reduce air leaks after resection of emphysematous lung. *Ann Thorac Surg*. 1994; 57(4): 1038-1039. [PubMed](#) | [Google Scholar](#)



**Figure 1:** A) preoperative chest X-Ray. Left pulmonary hyperlucency; B) preoperative chest CT. Giant emphysematous bulla with thin-walled partitions inside replacing almost the entire upper lobe; C) postoperative chest X-Ray. Complete pulmonary expansion; D) postoperative chest CT



**Figure 2:** A) giant bull occupying; B) upper lobe almost replaced by the giant bulla. Healthy lower lobe; C) upper lobe was partially affected persisting a healthy parenchyma area. Black line: implantation line of the bulla; (D, E) bullectomy performed with endoscopic stapling devices; F) lung expansion of the remnant; G) interior of the bulla