

Epidemiology and Clinical Manifestations of Mucormycosis

George Petrikos,¹ Anna Skiada,² Olivier Lortholary,⁴ Emmanuel Roilides,³ Thomas J. Walsh,⁵ and Dimitrios P. Kontoyiannis⁶

¹National and Kapodistrian University of Athens, Attikon Hospital, ²National and Kapodistrian University of Athens, Laikon Hospital, Athens, and ³Aristotle University School of Medicine, Hippokraton Hospital, Thessaloniki, Greece; ⁴Necker Hospital, Paris, France; ⁵Weill Cornell Medical Center of Cornell University, New York, New York; and ⁶University of Texas MD Anderson Cancer Center, Houston

Mucormycosis is an emerging angioinvasive infection caused by the ubiquitous filamentous fungi of the Mucorales order of the class Zygomycetes. Mucormycosis has emerged as the third most common invasive mycosis in order of importance after candidiasis and aspergillosis in patients with hematological and allogeneic stem cell transplantation. Mucormycosis also remains a threat in patients with diabetes mellitus in the Western world. Furthermore, this disease is increasingly recognized in recently developed countries, such as India, mainly in patients with uncontrolled diabetes or trauma. Epidemiological data on this type of mycosis are scant. Therefore, our ability to determine the burden of disease is limited. Based on anatomic localization, mucormycosis can be classified as one of 6 forms: (1) rhinocerebral, (2) pulmonary, (3) cutaneous, (4) gastrointestinal, (5) disseminated, and (6) uncommon presentations. The underlying conditions can influence clinical presentation and outcome. This review describes the emerging epidemiology and the clinical manifestations of mucormycosis.

During the past 2 decades, mucormycosis has emerged as an important fungal infection with high associated mortality rates. Zygomycoses are uncommon, frequently fatal diseases caused by fungi of the class Zygomycetes (consisting of the orders Mucorales and Entomophthorales) with distinct patterns of clinical infection. The majority of human cases are caused by Mucorales fungi; therefore, the terms *mucormycosis* and *zygomycosis* are used interchangeably (the term *phycomycosis* is also used) [1, 2]. The Mucorales species most often recovered from clinical specimens are those of the genera *Rhizopus* (the most common genus associated with mucormycosis), *Lichtheimia* (formerly known as *Absidia* and *Mycocladius*), and *Mucor*. Species of other

Zygomycetes genera, such as *Rhizomucor*, *Saksenaea*, *Cunninghamella*, and *Apophysomyces*, are less common [2–7]. Fungi of the order Entomophthorales are uncommon pathogens, with infections typically restricted to tropical areas, and produce chronic cutaneous and subcutaneous infections. In general, these infections occur in immunocompetent hosts and progress locally via direct extension into adjacent tissues but rarely are angioinvasive or become disseminated [2, 8–10]. In contrast, Mucorales species are vasotropic, causing tissue infarctions, and the mucormycosis spectrum ranges from cutaneous, rhinocerebral, and sinopulmonary to disseminated and frequently fatal infections, especially in immunocompromised hosts [11, 12]. The importance of Mucorales species has grown in recent years as the number of patients with predisposing factors for mucormycosis has increased dramatically.

EPIDEMIOLOGY

Most human infections result from inhalation of fungal sporangiospores that have been released in the air or direct inoculation of organisms into disrupted skin or

Correspondence: George Petrikos, PhD, Fourth Department of Internal Medicine, School of Medicine, National and Kapodistrian University of Athens, Attikon Hospital, RIMINI 1-Haidari, Athens 12464, Greece (petrikos@hol.gr).

Clinical Infectious Diseases 2012;54(S1):S23–34

© The Author 2012. Published by Oxford University Press on behalf of the Infectious Diseases Society of America. All rights reserved. For Permissions, please e-mail: journals.permissions@oup.com.

DOI: 10.1093/cid/cir866

Table 1. Underlying Conditions in Patients With Mucormycosis as Presented in Various Studies

Reference	Characteristics of Studies				Underlying Conditions, % of Cases							Trauma/No Underlying Disease
	Countries of Origin for Cases	Prospective Study ^a	Multicenter Study	Time Period	Cases, No.	HM	DM	SOM/SOT	DFO	HIV	AI/CO	
Roden et al ^b [27]	Global	NA	NA	1885–2004	929	21.0	36.0	7.0	6.0	2.0	1.0	19.0
Bitar et al ^c [26]	France	No	Yes	1997–2006	53	17.3	16.2	7.1	...	4.9	...	54.4
Pagano et al [34]	Italy	Yes	Yes	2004–2007	60	61.7	18.0	1.7	...	1.7	3.3	40.0
Saegeman et al [185]	Belgium	No	Yes	2000–2009	31	77.0	6.4	13.0	...	3.0	...	13.0
Rüping et al [33]	Global	Yes	Yes	2006–2009	41	63.4	17.1	9.8
Skjoda et al [28]	Europe	Yes	Yes	2005–2007	230 ^c	55.0	17.0	9.0	1.0	2.0	7.0	20.0
Chakrabarti et al [16]	India	Yes	No	2006–2007	178	1.1	73.6	0.6	19.1

Abbreviations: AI/CO, autoimmune diseases and/or corticosteroid therapy; DFO, deferoxamine therapy; DM, diabetes mellitus; HM, human immunodeficiency virus; HIV, hematological malignancies and/or hematopoietic stem cell transplantation; NA, not applicable; SOM/SOT, solid organ malignancy and/or solid organ transplantation.

^a Depicted studies are from registries collecting passive surveillance data; no study involved active surveillance of cases.

^b This was a review of reported cases in the literature.

^c In this study, 19 patients (8%) had >1 underlying disease, so the total is >100%.

mucosa [13]. The Mucorales are ubiquitous in nature, but their precise ecology remains to be determined; they are thermotolerant and are usually found in decaying organic matter. Cases with mucormycosis have been reported from all over the world. Seasonal variation in Mucorales infection is possible. In a study from Israel, 16 of 19 reported cases of rhino-orbitocerebral mucormycosis (ROCM) occurred in autumn [14]. In another study from Japan, a similar seasonal variation among hematology patients was noted, with 6 of 7 cases of pulmonary mucormycosis having developed from August to September [15].

Differences in the epidemiology of mucormycosis seem to exist between developed and developing countries. In developed countries, the disease remains uncommon and, at present, is mostly seen in patients with diabetes mellitus and hematological malignancies (HMs) undergoing chemotherapy and those who have received allogeneic stem cell transplants [1]. In contrast, in developing countries, especially in India, mucormycosis cases, although sporadic, occur mainly in patients with uncontrolled diabetes or trauma [2, 16].

There are several factors that limit our ability to accurately determine the exact incidence of mucormycosis. Autopsy rates, the “gold standard” approach, have been in continuous decline globally during the last decades. Nevertheless, mucormycosis remains an uncommon disease, even in high-risk patients, and represents 8.3%–13% of all fungal infections encountered at autopsy in such patients [17–19]. Postmortem prevalence evaluation shows that mucormycosis is 10–50-fold less frequent than candidiasis or aspergillosis with a frequency of 1–5 cases per 10 000 autopsies [17–21].

The challenges to establish a clinical diagnosis of mucormycosis add to the difficulty of obtaining a clear view of the epidemiology of this disease. Patients are often treated presumptively for mucormycosis, but cases may be missed due to lack of histological and microbiological proof [22]. The incorporation of modern, minimally invasive techniques for safer tissue sampling and the use of molecular techniques for the identification of the pathogen show promise for clarification of many ambiguous clinical scenarios in the near future [23]. Laboratory diagnosis is discussed in greater depth elsewhere in this supplement.

The literature contains few population-based studies [24–31]. These studies differ in capture periods, populations, and definition or case ascertainment procedures (Table 1 and Figure 1). Nearly 2 decades ago, in the era before highly active anti-retroviral therapy, an active population-based surveillance study in San Francisco, California, from 1992 to 1993 revealed that the annual incidence of mucormycosis was 1.7 cases per 1 million individuals (~500 cases per year) [24]. A more recent study in a more general population in Spain found a lower incidence (0.43 cases/1 million inhabitants, or 0.62/100 000 hospital admissions) [25]. The analysis of hospital records in France showed an increasing incidence from 0.7/million in 1997 to

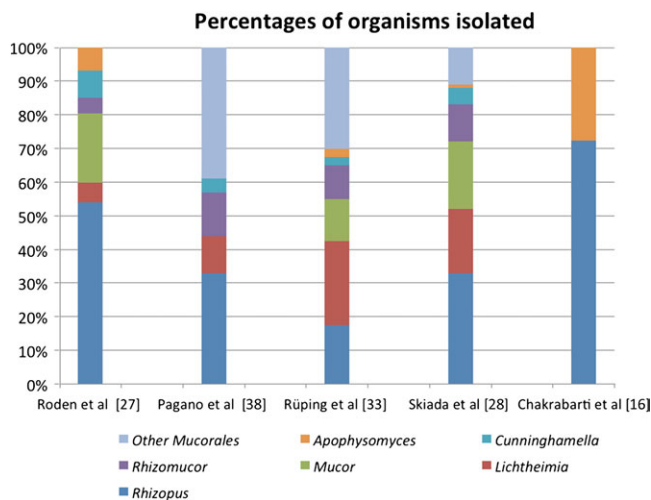


Figure 1. Most frequent agents of mucormycosis. Data from 5 studies [16, 27, 28, 33, 38].

1.2/million in 2006 ($P < .001$) [26]. In the largest review of mucormycosis cases in the English-language literature, Roden et al compiled 929 cases of mucormycosis from 1885 to 2004 and showed that an increasing proportion of immunocompromised patients with mucormycosis was reported in the 1980s and 1990s [27]. Patients with HMs or who underwent hematopoietic stem cell transplantation (HSCT) represented 22% of the cases (17% and 5%, respectively). In the largest registry of the European Confederation of Medical Mycology Working Group, 230 cases occurring between 2005 and 2007 were analyzed and found to occur in patients with hematological malignancies (44%), trauma (15%), HSCT (9%), and diabetes mellitus (9%) [28]. During the same period, an exhaustive analysis was performed at the country level in all hospitals of France and revealed a total of 101 cases of mucormycoses (60 proven/41 probable), mostly in men (58%) >50 years old (mean age, 50.7 ± 19.9 years). Fifty percent of the cases were in patients with hematological malignancies with or without stem cell transplantation, 23% in patients with diabetes, and 18% in patients with trauma. Notably, HIV infection does not inherently predispose to mucormycosis unless associated with illicit intravenous drug use, neutropenia, diabetes mellitus, or corticosteroids.

Predisposing Conditions

The most important conditions predisposing to mucormycosis, according to various studies, include malignant hematological disease with or without stem cell transplantation, prolonged and severe neutropenia, poorly controlled diabetes mellitus with or without diabetic ketoacidosis, iron overload, major trauma, prolonged use of corticosteroids, illicit intravenous drug use, neonatal prematurity and malnourishment [1, 3, 27]. Antifungal

agents with no activity against Zygomycetes, such as voriconazole and caspofungin, have also been implicated in breakthrough zygomycosis [27, 28]. Apart from these host-related risk factors, a number of cases have been—at least partially—attributed to the hospital environment. Nosocomial mucormycosis has been associated with exposure to heavy air fungal loads because of construction work, contaminated air filters, or a variety of healthcare-associated procedures and devices, such as contaminated wound dressings, transdermal nitrate patches, intravenous catheters, tongue depressors, and even allopurinol pills [30]. Iatrogenic mini-outbreaks also have occurred [31, 32]. An exhaustive literature review on the topic is included in the present supplement.

HM and Hematopoietic Stem Cell Transplantation

Among patients with HM, those with acute myelogenous leukemia (AML) are at the highest risk for mucormycosis, with incidences ranging from 1% to 8% [15, 33–39]. Mucormycosis is less common in other acute or chronic HMs [39]. In patients with either autologous or allogeneic stem cell transplantation, the frequency of mucormycosis is lower than that observed in patients with AML, ranging from 0.9% to 2.0%, with the highest incidence observed in patients with graft-versus-host disease [40–46]. Some studies have suggested a rising incidence of mucormycosis in HM units. At the University of Texas MD Anderson Cancer Center, the number of cases increased from 8/100 000 admissions in 1989–1993 to 17/100 000 admissions in 1994–1998. The overall incidence of mucormycosis among those with HMs at this center at autopsy was 1.9% for the period 1994–1998 versus only 0.7% during the period 1989–1998 [37]. A similar incidence of 2.1% at autopsy in patients with acute leukemia was reported in a study from Japan [15]. Further insight into the epidemiology of mucormycosis is anticipated with analysis of data from prospective networks, such as that from the Centers for Disease Control and Prevention TRANSNET (Parks and Kontoyiannis, submitted) and the Prospective Antifungal Therapy (PATH) Alliance. However, these networks focused only on transplant patients (TRANSNET) or immunosuppressed patients in general (PATH Alliance), in whom the incidence of mucormycosis may be higher [45]. Surveillance programs that reach beyond the setting of HSCT would further advance understanding of the epidemiology of this rare disease [45, 47].

Solid Organ Malignancies and Solid Organ Transplantation

Mucormycosis constitutes a small proportion of invasive fungal infections in solid organ transplant (SOT) recipients; however, the disease is also associated with a high mortality rate. The estimated incidence ranges from 0.4% to 16.0% depending on the SOT type [26, 27, 47–50]: the range is 0.2%–1.2% in renal transplant recipients, 0%–1.6% in liver transplant recipients, 0%–0.6% in heart transplant recipients, and 0%–1.5% in lung transplant recipients [51–63]. In a retrospective study and literature review, neutropenia was absent in SOT recipients, as

were acidosis with and without hyperglycemia and deferoxamine (DFO) use [50]. In contrast, all patients underwent chronic immunosuppression, typically with high doses of systemic corticosteroids. Furthermore, dissemination of mucormycosis to distant organs occurred often after rejection and its treatment. Dissemination occurred preferentially to skin and soft tissues but not the brain. In a prospective, matched, case-controlled study of mucormycosis in SOT recipients, renal failure, diabetes mellitus, and prior voriconazole and/or caspofungin use were associated with an increased risk of mucormycosis [52]. In contrast, tacrolimus use was associated with a decreased risk. Liver transplant recipients were more likely to have disseminated disease and had earlier development of mucormycosis after transplantation versus other SOT recipients (median, 0.8 vs 5.7 months).

Diabetes Mellitus and Ketoacidosis. Authors have reported diabetes mellitus as a predisposing factor for mucormycosis in 36%–88% of cases [27, 64–73]. Patients with uncontrolled hyperglycemia, particularly those with ketoacidosis, are the most susceptible [11, 69, 70]. Mucormycosis may be the first manifestation in some patients with undiagnosed diabetes mellitus [72], but it is rarely observed in those with metabolically controlled diabetes [71]. Type 1, type 2, and secondary diabetes mellitus are all reportedly risk factors for mucormycosis [73].

The epidemiology of mucormycosis in diabetic patients is evolving. Roden et al [27] showed that diabetic patients represented 36% of 929 reported cases, but there was a decreased incidence of mucormycosis in diabetics over time. This contrasts with the increased prevalence of diabetes worldwide [74]. Researchers have speculated that treatment with statins, used widely for metabolic syndromes in the West, has a role in this decreased incidence, because statins are active against some Zygomycetes [74, 75]. However, mucormycosis remains a formidable threat in diabetics. A recent nationwide retrospective study in France showed a 9% annual increase in mucormycosis incidence in diabetics [26]. In another retrospective study from 2 American teaching and tertiary care hospitals, 83% of patients with ROCM were diabetics; 41% of them had no known history of diabetes [76]. Data from a study in a tertiary care center in India were also alarming, as 74% of patients with mucormycosis had uncontrolled diabetes; in 43% of these cases, diabetes was diagnosed for the first time [16].

These findings underline the association between poor diabetes control and socioeconomic status. Unless complications occur, low-income individuals avoid seeking medical attention, because healthcare is largely unaffordable to them. Furthermore, almost 80% of type 2 diabetes mellitus deaths occur in low- and middle-income individuals [77]. Many of these mucormycosis cases could have been prevented with diabetes control programs.

Corticosteroid Use and Rheumatic Diseases. Chronic corticosteroid-based therapy is another primary risk factor that

enhances a patient's susceptibility to mucormycosis by causing defects in macrophages and neutrophils and/or steroid-induced diabetes [3]. In the few cases of mucormycosis in patients with systemic lupus erythematosus reported in the English-language literature [77–91], the infection apparently could present in any clinical form, but disseminated mucormycosis was common and the mortality rate was very high (88%) [78]. Additional predisposing factors for opportunistic mucormycosis include hypocomplementemia, nephrotic syndrome, uremia, leukopenia, and diabetes mellitus. Opportunistic mucormycosis occasionally occurs in patients with other autoimmune diseases. Importantly, in patients with Wegener granulomatosis, mucormycosis may mimic a relapse of the underlying disease and go undiagnosed [92].

Iron Overload and Chelation Therapy With DFO. Therapy with DFO, an iron chelator used to treat iron and/or aluminum overload in dialysis recipients, reportedly is a risk factor for angioinvasive mucormycosis [93, 94]. A report of an international registry of mycoses showed that 78% of dialysis recipients with mucormycosis received DFO [95]. Besides DFO, iron overload, either transfusional or caused by dyserythropoiesis, is a risk factor for mucormycosis [42, 96, 97]. The most common presentation of mucormycosis in patients receiving DFO seems to be the disseminated form (44%), and this presentation is associated with high mortality rates, reaching 80% [25, 95]. Fortunately, DFO is no longer used because of the introduction of novel iron chelators such as deferasirox (Exjade) and deferiprone, which do not predispose patients to mucormycosis.

Prolonged Use of Voriconazole. The introduction and widespread use of *Aspergillus*-active agents, especially voriconazole, mainly in patients with HMs and recipients of hematopoietic stem cell transplants at high risk for mucormycosis is linked with increased incidence of mucormycosis in several institutions worldwide [98–106]. Recent prospective randomized studies comparing prophylaxes using voriconazole with those using fluconazole or itraconazole in allogeneic transplant recipients did not confirm this finding, however [107, 108]. Both of these studies enrolled patients at low risk for invasive mold infections, including mucormycosis, so the controversy about the use of voriconazole remains. Yet, despite uncertainty about this risk, clinicians should be aware that mucormycosis can develop in high-risk patients receiving voriconazole, because double fungal infections are not uncommon.

HIV or AIDS

Mucormycosis in patients with human immunodeficiency virus (HIV) or AIDS is very rare. In a large retrospective study of 1630 autopsies of patients who died of AIDS from 1984 to 2002, Antinori et al [107] observed only 2 patients with mucormycosis. This relatively low frequency reflects the uncommon occurrence of mucormycosis in HIV-infected patients compared with other

immunocompromised populations. [27, 28] Most mucormycosis cases in HIV-infected patients are associated with intravenous drug use [109–112].

No Underlying Disease. A considerable proportion of patients with mucormycosis have no apparent immune deficiency [25]. These patients typically have primary cutaneous mucormycosis associated with trauma or burns. Authors have reported iatrogenic factors as causes of mucormycosis, including surgical trauma and use of contaminated bandages, adhesive dressings, wooden tongue depressors, and central venous catheters [32, 113].

Mucormycosis in Children. Mucormycosis in children is very rare. Zaoutis et al [114] reviewed all available English-language reports of pediatric mucormycosis cases before 2004. They found a total of 157 case patients (64% male), with a median age of 5 years. Twenty-eight (18%) patients had HMs, and 9 (6%) had undergone HSCT. Authors reported an additional 30 pediatric cases from 2004 to 2008 [115].

CLINICAL MANIFESTATIONS

The clinical hallmark of invasive mucormycosis is tissue necrosis resulting from angioinvasion and subsequent thrombosis. In most cases, the infection is rapidly progressive and results in death unless underlying risk factors (ie, metabolic acidosis) are corrected and aggressive treatment with antifungal agents and surgical excision is instituted. Based on its clinical presentation and anatomic site, invasive mucormycosis is classified as one of the following 6 major clinical forms: (1) rhinocerebral, (2) pulmonary, (3) cutaneous, (4) gastrointestinal, (5) disseminated, and (6) uncommon rare forms, such as endocarditis, osteomyelitis, peritonitis, and renal infection [116–118]. Any of the species of the Mucorales may cause infection at these sites.

The most common reported sites of invasive mucormycosis have been the sinuses (39%), lungs (24%), and skin (19%) [25]. Dissemination developed in 23% of these cases. The overall mortality rate for the disease is 44% in diabetics, 35% in patients with no underlying conditions, and 66% in patients with malignancies. The mortality rate varied with the site of infection and host: 96% of patients with disseminated infections, 85% with gastrointestinal infections, and 76% with pulmonary infections died. In children, mucormycosis manifested as cutaneous, gastrointestinal, rhinocerebral, and pulmonary infections in 27%, 21%, 18%, and 16% of cases, respectively, in one study [114]. The skin and gut are affected more frequently in children than in adults.

Pulmonary Mucormycosis

Pulmonary mucormycosis occurs most often in neutropenic patients with cancer undergoing induction chemotherapy and those who have undergone HSCT and have graft-versus-host

disease [119]. The overall mortality rate in patients with pulmonary mucormycosis is high (76%); it is even higher in severely immunosuppressed patients [25]. The clinical features of pulmonary mucormycosis are nonspecific and cannot be easily distinguished from those of pulmonary aspergillosis. Patients usually present with prolonged high-grade fever (>38°C) that is unresponsive to broad-spectrum antibiotics. Nonproductive cough is a common symptom, whereas hemoptysis, pleuritic chest pain, and dyspnea are less common. In rare circumstances, pulmonary mucormycosis can present as an endobronchial or tracheal lesion, especially in diabetics. Endobronchial mucormycosis can cause airway obstruction, resulting in lung collapse, and can lead to invasion of hilar blood vessels with subsequent massive hemoptysis [120–122]. Pulmonary mucormycosis may invade lung-adjacent organs, such as the mediastinum, pericardium, and chest wall [123].

The signs of pulmonary mucormycosis on chest images are also nonspecific and indistinguishable from those of pulmonary aspergillosis. The most frequent findings include infiltration, consolidation, nodules, cavitations, atelectasis, effusion, posterior tracheal band thickening, hilar or mediastinal lymphadenopathy, and even normal findings [124–126]. The air crescent sign may be observed and is similar to that seen with pulmonary aspergillosis [127, 128]. In a study of computed tomography (CT) scan features in 45 patients with HMs who had pulmonary mucormycosis or invasive pulmonary aspergillosis, Chamilos et al [129] found that the presence of multiple lung nodules (≥ 10) and pleural effusion on initial CT scans was an independent predictor of pulmonary mucormycosis. Researchers have observed that the CT finding of a reversed halo sign, a focal round area of ground-glass attenuation surrounded by a ring of consolidation, is more common in patients with mucormycosis than in those with other invasive pulmonary fungal infections [130].

Rhinocerebral Mucormycosis

Rhinocerebral mucormycosis (ROCM) is the most common form of mucormycosis in patients with diabetes mellitus [27, 28]. It may also occur in patients with underlying malignancies, recipients of hematopoietic stem cell or solid organ transplants, and individuals with other risk factors [39]. The infection develops after inhalation of fungal sporangiospores into the paranasal sinuses. The infection may then rapidly extend into adjacent tissues. Upon germination, the invading fungus may spread inferiorly to invade the palate, posteriorly to invade the sphenoid sinus, laterally into the cavernous sinus to involve the orbits, or cranially to invade the brain [131]. The fungus invades the cranium through either the orbital apex or cribriform plate of the ethmoid bone and ultimately kills the host. Occasionally, cerebral vascular invasion can lead to hematogenous dissemination of the infection with or without development of mycotic aneurysms [132]. The initial symptoms of ROCM are consistent with those of sinusitis and periorbital

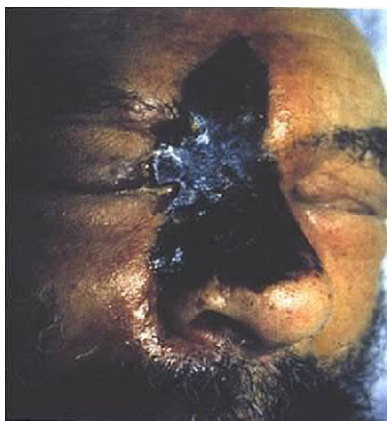

Figure 2. Necrotic facial eschar of a patient with rhinocerebral mucormycosis.

cellulitis and include eye and/or facial pain and facial numbness followed by blurry vision [3]. Signs and symptoms that suggest mucormycosis in susceptible individuals include multiple cranial nerve palsies, unilateral periorbital facial pain, orbital inflammation, eyelid edema, blepharoptosis, proptosis, acute ocular motility changes, internal or external ophthalmoplegia, headache, and acute vision loss.

A black necrotic eschar is the hallmark of mucormycosis (Figure 2). However, the absence of this finding should not exclude the possibility of mucormycosis. Fever is variable and may be absent in up to half of cases. The white blood cell count is typically elevated as long as the patient has functioning bone marrow.

Preoperative contrast-enhanced CT is useful in defining the extent of ROCM. Such CT scans show the edematous mucosa, fluid filling the ethmoid sinuses, and destruction of periorbital tissues and bone margins [133]. Although sinus CT is the preferred imaging modality for evaluating signs of invasion (Figure 3), bone destruction is often seen only late in the infection course after soft-tissue necrosis has occurred.

Magnetic resonance (MR) imaging is quite useful in identifying the intradural and intracranial extent of ROCM, cavernous sinus thrombosis, and thrombosis of cavernous portions of the internal carotid artery. Contrast-enhanced MR imaging can also demonstrate perineural spread of the infection. Although evidence of infection of orbital soft tissues may be seen on CT scans, MR imaging is more sensitive for this [114, 135]. Still, as with CT scans, patients with early ROCM may have normal MR images, and high-risk patients should always undergo surgical exploration with biopsy analysis of the suspected areas of infection. Nevertheless, imaging studies are nonspecific for ROCM, and diagnosing ROCM almost always requires histopathological evidence of fungal tissue invasion. Given the rapidly progressive nature of ROCM and marked increase in the mortality rate when the fungus penetrates the cranium, any diabetic patient with

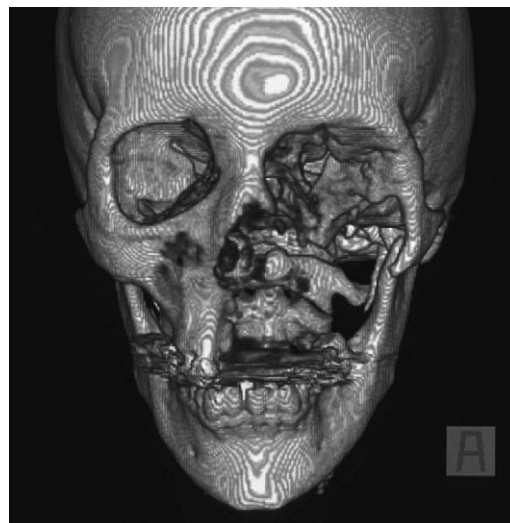

Figure 3. Three-dimensional computed tomographic scan of the facial skeleton of a patient with rhinocerebral mucormycosis showing extensive skeletal defects after orbitomaxillary resection.

a headache and visual changes is a candidate for prompt evaluation using imaging studies and nasal endoscopy to rule out mucormycosis.

Cutaneous Mucormycosis

Cutaneous mucormycosis results from direct inoculation of fungal spores in the skin, which may lead to disseminated disease. The reverse (dissemination from internal organs to the skin) is very rare [1, 27]. Roden et al [27] noted such reverse dissemination in only 6 cases (3%). Depending on the extent of the infection, cutaneous mucormycosis is classified as localized when it affects only the skin or subcutaneous tissue; deep extension when it invades muscle, tendons, or bone; and disseminated when it involves other noncontiguous organs [136].

The clinical manifestations of cutaneous mucormycosis vary. Its onset may be gradual, and it may progress slowly, or it may be fulminant, leading to gangrene and hematogenous dissemination [137–139]. The typical presentation of cutaneous mucormycosis is a necrotic eschar accompanied by surrounding erythema and induration. However, a nonspecific erythematous macule, although small and apparently insignificant, may be the cutaneous manifestation of disseminated disease in an immunosuppressed patient [138]. Authors have reported other, less common presentations of cutaneous mucormycosis, such as superficial lesions with only slightly elevated circinate and squamous borders resembling tinea corporis [136], targetoid plaques with outer erythematous rims and ecchymotic or blackened necrotic centers [139], and, in patients with open wounds, lesions with a cottonlike appearance resembling that of bread mold [140, 141]. When cutaneous mucormycosis presents with necrotic eschars,

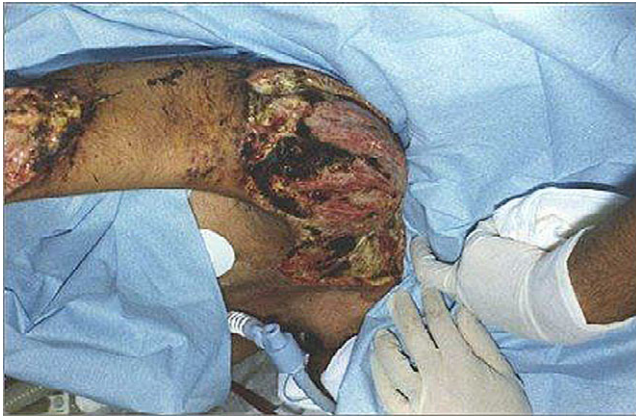

Figure 4. Cutaneous necrotizing mucormycosis of the right upper limb of a burn victim.

these lesions may mimic pyoderma gangrenosum, bacterial synergistic gangrene, or other infections produced by bacteria or fungi (Figure 4) [142].

Gastrointestinal Mucormycosis

Gastrointestinal mucormycosis is uncommon and seldom diagnosed in living patients. In such cases, diagnosis is delayed, and the mortality rate is as high as 85% [27]. Only 25% of gastrointestinal mucormycosis cases are diagnosed antemortem, and authors have reported the disease mainly in premature neonates, malnourished children, and individuals with HMs, diabetes mellitus, or a history of corticosteroid use [143–148]. Gastrointestinal mucormycosis is acquired by ingestion of pathogens in foods such as fermented milk and dried bread products [13]. Consumption of fermented porridges and alcoholic drinks derived from corn may promote gastric mucormycosis. Use of spore-contaminated herbal and homeopathic remedies is also linked with gastrointestinal mucormycosis [148, 149]. Finally, one group of authors reported on a series of cases of gastrointestinal mucormycosis presumably transmitted orally with sporangiospore contaminated tongue depressors used for oropharyngeal examinations in a hematology-oncology clinic [144].

Gastrointestinal mucormycosis can occur in any part of the alimentary system, but the stomach is most commonly affected, followed by the colon and ileum [147, 151, 152]. The infection usually presents with an appendiceal, cecal, or ileac mass or gastric perforation that may be associated with frequently massive upper gastrointestinal tract bleeding [145, 148, 151–156]. In premature neonates, gastrointestinal mucormycosis presents as necrotizing enterocolitis, whereas in neutropenic patients, it does so as a masslike appendiceal or ileal lesion [3, 157]. Neutropenic fever, typhilitis, and hematochezia also can occur in neutropenic patients. Diagnosis of gastrointestinal mucormycosis is usually

delayed, because its nonspecific presentation requires a high degree of suspicion, leading to early use of endoscopic biopsy analysis. Gastrointestinal mucormycosis can also involve the liver, spleen, and pancreas. The fungus can invade bowel walls and blood vessels, resulting in bowel perforation, peritonitis, sepsis, and massive gastrointestinal hemorrhage, which is the most common cause of death [153, 157].

Disseminated Mucormycosis

Mucormycosis in one organ can spread hematogenously to other organs [84, 158–162]. The organ most commonly associated with dissemination is the lung. Dissemination also occurs from the alimentary tract, burns, and extensive cutaneous lesions. Although the brain is a common site of spread, metastatic lesions may also be found in the liver, spleen, heart, and other organs [163]. Patients with iron overload (especially those receiving deferoxamine), profound immunosuppression (eg, recipients of allogeneic stem cell transplants having graft-versus-host disease treated with corticosteroids), or profound neutropenia and active leukemia are the classic groups at risk for disseminated mucormycosis [2, 11, 95, 163]. The symptoms and evolution of disseminated mucormycosis vary widely, reflecting the host as well as the location and degree of vascular invasion and tissue infarction in the affected organs. The variable presentation of disseminated mucormycosis requires a high index of suspicion to enable early diagnosis. Postmortem diagnosis of disseminated mucormycosis is quite common. A metastatic skin lesion is an important hallmark in early diagnosis. Without appropriate treatment, disseminated mucormycosis is always fatal [161].

Uncommon Forms of Mucormycosis

Other less common or unusual focal forms of mucormycosis include endocarditis, osteomyelitis, peritonitis, and pyelonephritis. Specifically, mucormycosis is a rare cause of prosthetic or native valve endocarditis [162–170]. Intravenous drug use is the typical risk factor [170–172]. Endocarditis occurs principally on or around prosthetic valves and can cause aortic thrombosis [167]. Osteomyelitis usually occurs after traumatic inoculation or surgical intervention (eg, tibial pin placement, anterior cruciate ligament repair) [171–173]. Authors have reported osteomyelitis of the tibia, cuboid, calcaneus, femur, humerus, scapula, metacarpals, phalanges, and sternum [174–177]. Hematogenous osteomyelitis is extremely rare [177]. Also rare is involvement of the peritoneal cavity by *Zygomycetes* in patients undergoing continuous ambulatory peritoneal dialysis [178, 179].

Peritonitis tends to be slowly progressive, although the attributable mortality rate in patients receiving delayed or inappropriate treatment has been as high as 60% [180, 181]. In all cases of catheter-related mucormycosis, prompt removal of the catheter and use of systemic antifungal therapy for several weeks

are essential. Although rare, renal mucormycosis should be suspected in any immunocompromised patient who presents with hematuria, flank pain, and unexplained anuric renal failure. Isolated renal mucormycosis has occurred in intravenous drug users as well as renal transplant recipients in developing countries with warm climates such as India, Egypt, Saudi Arabia, Kuwait, and Singapore [53, 118, 182]. Another rare manifestation of mucormycosis is brain involvement (typically in the basal ganglia) without rhino-orbital involvement in patients with leukemia and intravenous drug abusers [160]. Finally, isolated mucormycosis in the mastoid, oral mucosa, bone [173], the bladder, the trachea [183], the mediastinum [123, 184], or the ear is rare.

CONCLUSION

Mucormycosis is a rare but emerging fungal infection with a high mortality rate. Most of the existing epidemiological studies of mucormycosis are retrospective and limited. The literature contains few prospective, population-wide studies of it. Available studies typically took place at institutions with specific populations at risk for mucormycosis (patients with HM and recipients of transplants). The incidence of mucormycosis seems to be increasing in leukemic patients and stem cell transplant recipients chronically exposed to *Aspergillus*-active agents, although the generalizability of this observation is controversial. Despite the diabetes epidemic in developed countries, the incidence of mucormycosis in diabetics may be decreasing. In contrast, in developing countries, uncontrolled diabetes mellitus and trauma are the most common risk factors for mucormycosis. More representative data on specific groups of patients (eg, leukemic patients, transplant recipients, diabetics) are needed for better evaluation of the infection. Well-organized global registries are needed to estimate the burden of mucormycosis. The pleiotropic clinical manifestations and elusive presentation of mucormycosis often delay diagnosis, with resultant poor outcomes. A high index of suspicion for mucormycosis based on appropriate risk stratification and improved laboratory diagnosis are important for improving the natural history of this devastating infection.

Notes

Supplement sponsorship. This article was published as part of a supplement entitled “Advances Against Mucormycosis: A Tribute to the Memory and Courage of Hank Schueler,” sponsored by the Henry Schueler 41&9 Foundation.

Potential conflicts of interest. G. P. has received grant support from Gilead, Pfizer, Schering Plough, Aventis, and Merck Sharp & Dohme (MSD); has acted as a paid consultant to Janssen Cilag, Gilead, Astellas, and Schering Plough; and is a member of the speakers bureaus for Gilead, Schering Plough, and MSD. E.R. has received grant support from Pfizer, Gilead, Enzon, Schering, and Wyeth; has acted as a paid consultant to Schering,

Gilead, Astellas, and Pfizer; and is a member of the speakers bureaus for Gilead, Cephalon, Pfizer, Wyeth, Schering, Merck, Aventis, and Astellas. T. J. W. has received grant support from Novartis, Astellas and is a consultant for Trius, iCo, Sigma Tau, and Draius. D. P. K. has received research support and honoraria from Merck, Pfizer, Fujisawa Pharmaceutical, and Enzon Pharmaceuticals and serves on the advisory boards for Merck and Schering-Plough Research Institute. All other authors report no potential conflicts.

All authors have submitted the ICMJE Form for Disclosure of Potential Conflicts of Interest. Conflicts that the editors consider relevant to the content of the manuscript have been disclosed.

References

1. Spellberg B, Edwards J Jr, Ibrahim A. Novel perspectives on mucormycosis: pathophysiology, presentation, and management. *Clin Microbiol Rev* **2005**; 18:556–69.
2. Prabhu RM, Patel R. Mucormycosis and entomophthoromycosis: a review of the clinical manifestations, diagnosis and treatment. *Clin Microbiol Infect* **2004**; 10(Suppl 1):31–47.
3. Ribes JA, Vanover-Sams CL, Baker DJ. Zygomycetes in human disease. *Clin Microbiol Rev* **2000**; 13:236–301.
4. Lass-Flörl C. Zygomycosis: conventional laboratory diagnosis. *Clin Microbiol Infect* **2009**; 15(Suppl 5):60–5.
5. Kontoyiannis DP, Vartivarian S, Anaissie EJ, Samonis G, Bodey GP, Rinaldi M. Infections due to *Cunninghamella bertholletiae* in patients with cancer: report of three cases and review. *Clin Infect Dis* **1994**; 18:925–8.
6. Kwon-Chung KJ, Young RC, Orlando M. Pulmonary mucormycosis caused by *Cunninghamella elegans* in a patient with chronic myelogenous leukemia. *Am J Clin Pathol* **1975**; 64:544–8.
7. Ventura GJ, Kantarjian HM, Anaissie E, Hopfer RL, Fainstein V. Pneumonia with *Cunninghamella* species in patients with hematologic malignancies: a case report and review of the literature. *Cancer* **1986**; 58:1534–6.
8. Lyon GM, Smilack JD, Komatsu KK, et al. Gastrointestinal basidiobolomycosis in Arizona: clinical and epidemiological characteristics and review of the literature. *Clin Infect Dis* **2001**; 32:1448–55.
9. van den Berk GE, Noorduyt LA, van Ketel RJ, van Leeuwen J, Bemelman WA, Prins JM. A fatal pseudo-tumour: disseminated basidiobolomycosis. *BMC Infect Dis* **2006**; 6:140.
10. Fischer N, Ruef C, Ebnöther C, Bächli EB. Rhinofacial *Conidiobolus coronatus* infection presenting with nasal enlargement. *Infection* **2008**; 36:594–6.
11. Gonzalez CE, Rinaldi MG, Sugar AM. Mucormycosis. *Infect Dis Clin North Am* **2002**; 16:895–914, vi.
12. Rogers TR. Treatment of mucormycosis: current and new options. *J Antimicrob Chemother* **2008**; 61(Suppl 1):35–9.
13. Ibrahim A, Edwards JE Jr, Filler SG, eds. *Mucormycosis*. Philadelphia: Harcourt Brace, **2004**.
14. Talmi YP, Goldschmeid-Reouven A, Bakon M, et al. Rhino-orbital and rhino-orbitocerebral mucormycosis. *Otolaryngol Head Neck Surg* **2002**; 127:22–31.
15. Funada H, Matsuda T. Pulmonary mucormycosis in a hematology ward. *Intern Med* **1996**; 35:540–4.
16. Chakrabarti A, Das A, Mandal J, et al. The rising trend of invasive mucormycosis in patients with uncontrolled diabetes mellitus. *Med Mycol* **2006**; 44:335–42.
17. Kume H, Yamazaki T, Abe M, Tanuma H, Okudaira M, Okayasu I. Increase in aspergillosis and severe mycotic infection in patients with leukemia and MDS: comparison of the data from the Annual of the Pathological Autopsy Cases in Japan in 1989, 1993 and 1997. *Path Intern* **2003**; 53:744–50.
18. Chamilos G, Luna M, Lewis RE, et al. Invasive fungal infections in patients with hematologic malignancies in a tertiary care cancer center: an autopsy study over a 15-year period (1989–2003). *Haematologica* **2006**; 91:986–9.

19. Hotchi M, Okada M, Nasu T. Present state of fungal infections in autopsy cases in Japan. *Am J Clin Pathol* **1980**; 74:410–16.
20. Tietz HJ, Brehmer D, Janisch W, Martin H. Incidence of endomycoses in the autopsy material of the Berlin Charité Hospital. *Mycoses* **1998**; 41(Suppl 2):81–5.
21. Yamazaki T, Kume H, Murase S, Yamashita E, Arisawa M. Epidemiology of visceral mycoses: analysis of data in annual of the pathological autopsy cases in Japan. *J Clin Microbiol* **1999**; 37:1732–8.
22. De Pauw B, Walsh TJ, Donnelly JP, et al. Revised definitions of invasive fungal disease from the European Organization for Research and Treatment of Cancer/Invasive Fungal Infections Cooperative Group and the National Institute of Allergy and Infectious Diseases Mycoses Study Group (EORTC/MSG) Consensus Group. *Clin Infect Dis* **2008**; 46:1813–21.
23. Kasai M, Harrington SM, Francesconi A, et al. Detection of molecular biomarkers for *Rhizopus* spp., *Mucor* spp., and *Cunninghamella* spp. by quantitative PCR and melt curve analysis in plasma, bronchoalveolar lavage, and lung tissue in experimental pulmonary zygomycosis. *J Clin Microbiol* **2008**; 46:3690–702.
24. Rees JR, Pinner RW, Hajjeh RA, Brandt ME, Reingold AL. The epidemiological features of invasive mycotic infections in the San Francisco Bay area, 1992–1993: results of population-based laboratory active surveillance. *Clin Infect Dis* **1998**; 27:1138–47.
25. Torres-Narbona M, Guinea J, Martinez-Alarcon J, et al. Impact of mucormycosis on microbiology overload: a survey study in Spain. *J Clin Microbiol* **2007**; 45:2051–3.
26. Bitar D, Van Cauteren D, Lanternier F, et al. Increasing incidence of zygomycosis (mucormycosis), France, 1997–2006. *Emerg Infect Dis* **2009**; 15:1395–401.
27. Roden MM, Zaoutis TE, Buchanan WL, et al. Epidemiology and outcome of mucormycosis: a review of 929 reported cases. *Clin Infect Dis* **2005**; 41:634–53.
28. Skiada A, Pagano L, Groll A, et al. Zygomycosis in Europe: analysis of 230 cases accrued by the registry of the European Confederation of Medical Mycology (ECMM) Working Group on Zygomycosis between 2005 and 2007. *Clin Microbiol Infect* **2011**; 17:1859–67.
29. Perloth J, Choi B, Spellberg B. Nosocomial fungal infections: epidemiology. Diagnosis and treatment. *Med Mycol* **2007**; 45:321–46.
30. Petrikos GL, Skiada A, Sambatakou H, et al. Mucormycosis: ten year experience in a tertiary-care centre in Greece. *Eur J Clin Microbiol Infect Dis* **2003**; 22:753–6.
31. Antoniadou A. Outbreaks of mucormycosis in hospitals. *Clin Microbiol Infect* **2009**; 15(Suppl 5):55–9.
32. Cheng VC, Chan JF, Ngan AH, et al. Outbreak of intestinal infection due to *Rhizopus microsporus*. *J Clin Microbiol* **2009**; 47:2834–43.
33. Rüping MJ, Heinz W, Kindo AJ, et al. Forty-one recent cases of invasive mucormycosis from a global clinical registry. *J Antimicrob Chemother* **2009**; 430:1–7.
34. Pagano L, Valentini CG, Posteraro B, et al. Mucormycosis in Italy: a survey of FIMUA-ECMM (Federazione Italiana de Micopatologia Umana ed Animale and European Confederation of Medical Mycology). *J Chemother* **2009**; 21:322–9.
35. Pagano L, Ricci P, Tonso A, et al. Mucormycosis in patients with haematological malignancies: a retrospective clinical study of 37 cases. *Br J Haem* **1997**; 99:331–6.
36. Nosari A, Oreste P, Montillo M, et al. Mucormycosis in hematologic malignancies: an emerging fungal infection. *Haematologica* **2000**; 85:1068–71.
37. Kontoyiannis DP, Wessel VC, Bodey GP, Rolston KV. Mucormycosis in the 1990s in a tertiary-care cancer center. *Clin Infect Dis* **2000**; 30:851–6.
38. Pagano L, Caira M, Candoni A, et al. The epidemiology of fungal infections in patients with hematologic malignancies: the SEIFEM-2004 study. *Haematologica* **2006**; 91:1068–75.
39. Meyer RD, Rosen P, Armstrong D. Phycomycosis complicating leukemia and lymphoma. *Ann Intern Med* **1972**; 77:871–9.
40. Baddley JW, Stroud TP, Salzman D, Pappas PG. Invasive mold infections in allogeneic bone marrow transplant recipients. *Clin Infect Dis* **2001**; 32:1319–24.
41. Maertens J, Demuyneck H, Verbeken EK, et al. Mucormycosis in allogeneic bone marrow transplant recipients: report of five cases and review of the role of iron overload in the pathogenesis. *Bone Marrow Transplant* **1999**; 24:307–12.
42. Morrison VA, McGlave PB. Mucormycosis in the BMT population. *Bone Marrow Transplant* **1993**; 11:383–8.
43. Penalver FJ, Romero R, Fores R, Cabrera R, Briz M, Fernandez M. Mucormycosis and hemopoietic transplants. *Haematologica* **1998**; 83:950–1.
44. Marr KA, Carter RA, Crippa F, Wald A, Corey L. Epidemiology and outcome of mould infections in hematopoietic stem cell transplant recipients. *Clin Infect Dis* **2002**; 34:909–17.
45. Neofytos D, Horn D, Anaissie E, et al. Epidemiology and outcome of invasive fungal infection in adult hematopoietic stem cell transplant recipients: analysis of Multicenter Prospective Antifungal Therapy (PATH) Alliance registry. *Clin Infect Dis* **2009**; 48:265–73.
46. Garcia-Vidal C, Upton A, Kirby KA, Marr KA. Epidemiology of invasive mold infections in allogeneic stem cell transplant recipients: biological risk factors for infection according to time after transplantation. *Clin Infect Dis* **2008**; 47:1041–50.
47. Park BJ, Kontoyiannis DP, Pappas PG, et al. Comparison of mucormycosis and fusariosis to invasive aspergillosis (IA) among transplant recipients reporting to TRANSNET. In: Program and abstracts of the 44th Interscience Conference on Antimicrobial Agents and Chemotherapy (Washington, DC). Washington, DC: American Society for Microbiology, **2004**.
48. Almyroudis NG, Sutton DA, Linden P, Rinaldi MG, Fung J, Kusne S. Mucormycosis in solid organ transplant recipients in a tertiary transplant center and review of the literature. *Am J Transplant* **2006**; 6:2365–74.
49. Husain S, Alexander BD, Munoz P, et al. Opportunistic mycelial fungal infections in organ transplant recipients: emerging importance of non-*Aspergillus* mycelial fungi. *Clin Infect Dis* **2003**; 37:221–9.
50. Singh N, Aguado JM, Bonatti H, et al. Mucormycosis in solid organ transplant recipients: a prospective, matched case-control study to assess risks for disease and outcome. *J Infect Dis* **2009**; 200:1002–11.
51. Wajszczuk CP, Dummer JS, Ho M, Van Thiel TE, Iwatsuki S, Shaw B. Fungal infections in liver transplant recipients. *Transplantation* **1985**; 40:347–53.
52. Maurer J, Tullis E, Grossman RF, Vellend H, Winton TL, Patterson A. Infectious complications following isolated lung transplantation. *Chest* **1992**; 101:1056–9.
53. Chkhotua A, Yussim A, Tovar A, et al. Mucormycosis of the renal allograft: case report and review of the literature. *Transpl Int* **2001**; 14:438–41.
54. Jimenez C, Lumberras C, Aguado JM, et al. Successful treatment of Mucor infection after liver or pancreas-kidney transplantation. *Transplantation* **2002**; 73:476–80.
55. Castaldo P, Stratta RJ, Wood P, et al. Clinical spectrum of fungal infections after orthotopic liver transplantation. *Arch Surg* **1991**; 126:149–56.
56. Grossi P, Farina C, Fiocchi R, Gasperina DD. Prevalence and outcome of invasive fungal infections in 1,963 thoracic organ transplant recipients: a multicenter retrospective study. *Transplantation* **2000**; 70:112–16.
57. Ko WJ, Chien NC, Chou NK, Chu SH, Chang SC. Infection in heart transplant recipients: seven years' experience at the national Taiwan University hospital. *Transplant Proc* **2000**; 32:2392–5.
58. Schowengerdt KO, Naftel DC, Seib PM, et al. Infection after pediatric heart transplantation: results of a multiinstitutional study. *J Heart Lung Transplant* **1997**; 16:1207–16.

59. Ruffini E, Baldi S, Rapellino M, et al. Fungal infections in lung transplantation. Incidence, risk factors and prognostic significance. *Sarcoidosis Vasc Diffuse Lung Dis* **2001**; 18:181–90.
60. Bertocchi M, Thevenet F, Bastien O, et al. Fungal infections in lung transplant recipients. *Transplant Proc* **1995**; 27:1695.
61. Hofflin JM, Potasman I, Baldwin JC, Oyer PE, Stinson EB, Remington JS. Infectious complications in heart transplant recipients receiving cyclosporine and corticosteroids. *Ann Intern Med* **1987**; 106:209–16.
62. Miller LW, Naftel DC, Bourge RC, et al. Infection after heart transplantation: a multiinstitutional study. *Transplantation* **1994**; 13:381–93.
63. Nampooray MR, Khan ZU, Johnny KV, et al. Invasive fungal infections in renal transplant recipients. *J Infect* **1996**; 33:95–101.
64. Ludvigsson J. Why diabetes incidence increases—a unifying theory. *Ann N Y Acad Sci* **2006**; 1079:374–82.
65. Nithyanandam S, Jacob MS, Battu RR, Thomas RK, Correa MA, D'Souza O. Rhinoorbital-cerebral mucormycosis: a retrospective analysis of clinical features and treatment outcomes. *Indian J Ophthalmol* **2003**; 51:231–6.
66. Joshi N, Caputo GM, Weitekamp MR, Karchmer AW. Infections in patients with diabetes mellitus. *N Engl J Med* **1999**; 341:1906–12.
67. Chayakulkeeree M, Ghannoum MA, Perfect JR. Mucormycosis: the re-emerging fungal infection. *Eur J Clin Microbiol Infect Dis* **2006**; 25:215–29.
68. Sugar AM. Agents of mucormycosis and related species. In: Mandell GL, Bennett JE, Dolin R, eds. *Mandell, Douglas, and Bennett's principles and practice of infectious diseases*. Philadelphia: Elsevier Churchill Livingstone, **2005**:2973–84.
69. Greenberg RN, Scott LJ, Vaughn HH, Ribes JA. Zygomycosis (mucormycosis): emerging clinical importance and new treatments. *Curr Opin Infect Dis* **2004**; 17:517–25.
70. Helderman JH, Cooper HS, Mann J. Chronic phycomycosis in a controlled diabetic. *Ann Intern Med* **1974**; 80:419.
71. Bhansali A, Bhadada S, Sharma A, et al. Presentation and outcome of rhino-orbital-cerebral mucormycosis in patients with diabetes. *Postgrad Med J* **2004**; 80:670–4.
72. Kontoyiannis DP. Decrease in the number of reported cases of mucormycosis among patients with diabetes mellitus: a hypothesis. *Clin Infect Dis* **2007**; 44:1089–90.
73. Chamilos G, Lewis RE, Kontoyiannis DP. Lovastatin has significant activity against zygomycetes and interacts synergistically with voriconazole. *Antimicrob Agents Chemother* **2006**; 50:96–103.
74. Reed C, Bryant R, Ibrahim AS, et al. Combination polyene-caspofungin treatment of rhino-orbital-cerebral mucormycosis. *Clin Infect Dis* **2008**; 47:364–71.
75. World Health Organization. Diabetes. Available at: <http://www.who.int/mediacentre/factsheets/fs312/en/index.html>. Accessed 10 January 2011.
76. Mok CC, Que TL, Tsui EY, Lam WY. Mucormycosis in systemic lupus erythematosus. *Semin Arthritis Rheum* **2003**; 33:115–24.
77. Arce-Salinas CA, Pérez-Silva E. Mucormycosis complications in systemic lupus erythematosus. *Lupus* **2010**; 19:985–8.
78. Shenoi S, Emery HM. Successful treatment of invasive gastric mucormycosis in a child with systemic lupus erythematosus. *Lupus* **2010**; 19:646–9.
79. Peel T, Daffy J, Thursky K, Stanley P, Buising K. Posaconazole as first line treatment for disseminated mucormycosis. *Mycoses* **2008**; 51:542–5.
80. Yu J, Li RY. Primary renal mucormycosis due to *Rhizopus oryzae*. *Med Mycol* **2006**; 44:461–6.
81. Fujimoto A, Nagao K, Tanaka K, Yamagami J, Udagawa SI, Sugiura M. The first case of cutaneous mucormycosis caused by *Rhizopus azygosporus*. *Br J Dermatol* **2005**; 153:428–30.
82. Alsuwaida K. Primary cutaneous mucormycosis complicating the use of adhesive tape to secure the endotracheal tube. *Can J Anaesth* **2002**; 49:880–2.
83. Sungkanuparph S, Sathapatayavongs B, Kunachak S, Luxameechanporn T, Cheewaruangroj W. Treatment of invasive fungal sinusitis with liposomal amphotericin B: a report of four cases. *J Med Assoc Thai* **2001**; 84:593–601.
84. Liu MF, Chen FF, Hsiue TR, Liu CC. Disseminated mucormycosis simulating cerebrovascular disease and pulmonary alveolar haemorrhage in a patient with systemic lupus erythematosus. *Clin Rheumatol* **2000**; 19:311–14.
85. Hosseini M, Lee J. Gastrointestinal mucormycosis mimicking ischemic colitis in a patient with systemic lupus erythematosus. *Am J Gastroenterol* **1998**; 93:1360–2.
86. Dickinson M, Kalayanamit T, Yang CA, Pomper GJ, Franco-Webb C, Rodman D. Cutaneous zygomycosis (mucormycosis) complicating endotracheal intubation: diagnosis and successful treatment. *Chest* **1998**; 114:340–2.
87. Fingerote RJ, Seigel S, Atkinson MH, Lewkonian RM. Disseminated mucormycosis associated with systemic lupus erythematosus. *J Rheumatol* **1990**; 17:1692–4.
88. Bloxham CA, Carr S, Ryan DW, et al. Disseminated mucormycosis and systemic lupus erythematosus. *Intensive Care Med* **1990**; 16:201–7.
89. Wong KL, Tai YT, Loke SL, et al. Disseminated mucormycosis masquerading as cerebral lupus erythematosus. *Am J Clin Pathol* **1986**; 86:546–9.
90. Nogueira EL, Ind PW, Friedland JS, Salama AD. Mucormycosis may mimic disease relapse in Wegener's granulomatosis. *J Rheumatol* **2010**; 37:1364–5.
91. Artis WM, Fountain JA, Delcher HK, Jones HE. A mechanism of susceptibility to mucormycosis in diabetic ketoacidosis: transferrin and iron availability. *Diabetes* **1982**; 31:1109–14.
92. Daly AL, Velazquez LA, Bradley SF, Kauffman CA. Mucormycosis: association with deferoxamine therapy. *Am J Med* **1989**; 87:468–71.
93. Boelaert JR, Fenves AZ, Coburn JW. Deferoxamine therapy and mucormycosis in dialysis patients: report of an international registry. *Am J Kidney Dis* **1991**; 18:660–7.
94. Sugar AM. Mucormycosis. *Clin Infect Dis* **1992**; 14(Suppl 1):S126–9.
95. McNab AA, McKelvie P. Iron overload is a risk factor for mucormycosis. *Arch Ophthalmol* **1997**; 115:919–21.
96. Marty FM, Cosimi LA, Baden LR. Breakthrough mucormycosis after voriconazole treatment in recipients of hematopoietic stem-cell transplants. *N Engl J Med* **2004**; 350:950–2.
97. Vigouroux S, Morin O, Moreau P, et al. Mucormycosis after prolonged use of voriconazole in immunocompromised patients with hematologic disease: attention required. *Clin Infect Dis* **2005**; 40:e35–7.
98. Kontoyiannis DP, Lionakis MS, Lewis RE, et al. Zygomycoses in a tertiary-care cancer center in the era of *Aspergillus*-active antifungal therapy: a case-control observational study of 27 recent cases. *J Infect Dis* **2005**; 191:1350–60.
99. Siwek GT, Dodgson KJ, de Magalhaes-Silverman M, et al. Invasive mucormycosis in hematopoietic stem cell transplant recipients receiving voriconazole prophylaxis. *Clin Infect Dis* **2004**; 39:584–7.
100. Imhof A, Balajee SA, Fredricks DN, England JA, Marr KA. Breakthrough fungal infections in stem cell transplant recipients receiving voriconazole. *Clin Infect Dis* **2004**; 39:743–6.
101. Kobayashi K, Kami M, Murashige N, Kishi Y, Fujisaki G, Mitamura T. Breakthrough mucormycosis during voriconazole treatment for invasive aspergillosis. *Haematologica* **2004**; 89:e140.
102. Lionakis MS, Kontoyiannis DP. Sinus mucormycosis in a patient receiving voriconazole prophylaxis. *Br J Haematol* **2005**; 129:2.
103. Oren I. Breakthrough mucormycosis during empirical voriconazole therapy in febrile patients with neutropenia. *Clin Infect Dis* **2005**; 40:770–1.
104. Trifilio SM, Bennett CL, Yarnold PR, et al. Breakthrough mucormycosis after voriconazole administration among patients with hematologic malignancies who receive hematopoietic stem-cell

- transplants or intensive chemotherapy. Bone Marrow Transplant **2007**; 39:425–9.
105. Wingard JR, Carter SL, Walsh TJ, et al. Randomized, double-blind trial of fluconazole versus voriconazole for prevention of invasive fungal infection after allogeneic hematopoietic cell transplantation. Blood **2010**; 116:5111–18.
 106. Marks DI, Pagliuca A, Kibbler CC, et al. Voriconazole versus itraconazole for antifungal prophylaxis following allogeneic haematopoietic stem-cell transplantation. Br J Haem **2011**; 155:318–27.
 107. Antinori S, Nebuloni M, Magni C, et al. Trends in the postmortem diagnosis of opportunistic invasive fungal infections in patients with AIDS: a retrospective study of 1630 autopsies performed between 1984 and 2002. Am J Clin Pathol **2009**; 132:221–7.
 108. Moraru RA, Grossman ME. Palatal necrosis in an AIDS patient: a case of mucormycosis. Cutis **2000**; 66:15–18.
 109. Van den Saffele JK, Boelaert JR. Mucormycosis in HIV-positive patients: a review of the literature. Mycoses **1996**; 39:77–84.
 110. Nagy-Agren SE, Chu P, Smith GJ, Waskin HA, Altice FL. Mucormycosis and HIV infection: report of three cases and review. J Acquir Immune Defic Syndr Hum Retrovirol **1995**; 10:441–9.
 111. Sanchez MR, Ponge-Wilson I, Moy JA, Rosenthal S. Mucormycosis and HIV infection. J Am Acad Dermatol **1994**; 30:904–8.
 112. Blatt SP, Lucey DR, DeHoff D, Zellmer RB. Rhinocerebral mucormycosis in a patient with AIDS. J Infect Dis **1991**; 164:215–16.
 113. Skiada A, Petrikos G. Cutaneous mucormycosis. Clin Microbiol Infect **2009**; 15(Suppl 5):41–5.
 114. Zauotis TE, Roilides E, Chiu CC, et al. Mucormycosis in children: a systematic review and analysis of reported cases. Pediatr Infect Dis J **2007**; 26:723–7.
 115. Roilides E, Zauotis TE, Walsh TJ. Invasive zygomycosis in neonates and children. Clin Microbiol Infect **2009**; 15(Suppl 5):50–4.
 116. Goodman NL, Rinaldi MG. Agents of mucormycosis. In: Balows A, Hausler WJ, Herrmann KL, Isenberg HD, Shadomy HJ, eds. Manual of clinical microbiology. 5th ed. Washington, DC: ASM Press, **1991**: 674–92.
 117. Lopes JO, Pereira DV, Streher LA, Fenalte AA, Alves SH, Benevenga JP. Cutaneous mucormycosis caused by *Absidia corymbifera* in a leukemic patient. Mycopathologia **1995**; 130:89–92.
 118. Stas KJF, Louwagie GLH, Van Damme BJC, Coosemans W, Waer M, Vanrenterghem YFC. Isolated mucormycosis in a bought living unrelated kidney transplant. Transplant Int **1996**; 9:600–2.
 119. Tedder M, Spratt JA, Anstadt MP, Hegde SS, Tedder SD, Lowe JE. Pulmonary mucormycosis: results of medical and surgical therapy. Ann Thorac Surg **1994**; 57:1044–50.
 120. Gupta KL, Khullar DK, Behera D, Radotra BD, Sakhuja V. Pulmonary mucormycosis presenting as fatal massive haemoptysis in a renal transplant recipient. Nephrol Dial Transplant **1998**; 13:3258–60.
 121. Kitabayashi A, Hirokawa M, Yamaguchi A, Takatsu H, Miura AB. Invasive pulmonary mucormycosis with rupture of the thoracic aorta. Am J Hematol **1998**; 58:326–9.
 122. Passamonte PM, Dix JD. Nosocomial pulmonary mucormycosis with fatal massive hemoptysis. Am J Med Sci **1985**; 289:65–7.
 123. Connor BA, Anderson RJ, Smith JW. Mucor mediastinitis. Chest **1979**; 75:525–6.
 124. Hsu JW, Chiang CD. A case report of novel roentgenographic finding in pulmonary mucormycosis: thickening of the posterior tracheal band. Kaohsiung J Med Sci **1996**; 12:595–600.
 125. Rubin SA, Chaljub G, Winer-Muram HT, Flicker S. Pulmonary mucormycosis: a radiographic and clinical spectrum. J Thorac Imaging **1992**; 7:85–90.
 126. McAdams HP, Rosado de Christenson M, Strollo DC, Patz EF Jr. Pulmonary mucormycosis: radiologic findings in 32 cases. Am J Roentgenol **1997**; 168:1541–8.
 127. Dykhuizen RS, Kerr KN, Soutar RL. Air crescent sign and fatal haemoptysis in pulmonary mucormycosis. Scand J Infect Dis **1994**; 26:498–501.
 128. Funada H, Misawa T, Nakao S, Saga T, Hattori KI. The air crescent sign of invasive pulmonary mucormycosis in acute leukemia. Cancer **1984**; 53:2721–3.
 129. Chamilos G, Marom EM, Lewis RE, Lionakis MS, Kontoyiannis DP. Predictors of pulmonary mucormycosis versus invasive pulmonary aspergillosis in patients with cancer. Clin Infect Dis **2005**; 41:60–6.
 130. Wahba H, Truong MT, Lei X, Kontoyiannis DP, Marom EM. Reversed halo sign in invasive pulmonary fungal infections. Clin Infect Dis **2008**; 46:1733–7.
 131. Hosseini SM, Borghei P. Rhinocerebral mucormycosis: pathways of spread. Eur Arch Otorhinolaryngol **2005**; 262:932–8.
 132. Orguc S, Yuceturk AV, Demir MA, Goktan C. Rhinocerebral mucormycosis: perineural spread via the trigeminal nerve. J Clin Neurosci **2005**; 12:484–6.
 133. Franquet T, Gimenez A, Hidalgo A. Imaging of opportunistic fungal infections in immunocompromised patient. Eur J Radiol **2004**; 51:130–8.
 134. Terk MR, Underwood DJ, Zee CS, Colletti PM. MRI imaging in rhinocerebral and intracranial mucormycosis with CT and pathologic correlation. Magn Reson Imaging **1992**; 10:81–7.
 135. Garces P, Mueller D, Trevenen C. Rhinocerebral mucormycosis in a child with leukemia: CT and MRI findings. Pediatr Radiol **1994**; 24:50–1.
 136. Oliveira-Neto MP, Da Silva M, Monteiro PCF, et al. Cutaneous mucormycosis in a young, immunocompetent girl. Med Mycol **2006**; 44:567–70.
 137. Hampson FG, Ridgway EJ, Feeley K, Reilly JT. A fatal case of disseminated mucormycosis associated with the use of blood glucose self-monitoring equipment. J Infect **2005**; 51:e269–72.
 138. Hocker TL, Wada DA, Bridges A, El-Azhary R. Disseminated mucormycosis heralded by a subtle cutaneous finding. Dermatol Online J **2010**; 16:3.
 139. Rubin AI, Grossman ME. Bull's-eye cutaneous infarct of mucormycosis: a bedside diagnosis confirmed by touch preparation. J Am Acad Dermatol **2004**; 51:996–1001.
 140. Chawla R, Sehgal S, Ravindra Kumar S, Mishra B. A rare case of mucormycosis of median sternotomy wound caused by *Rhizopus arrhizus*. Indian J Med Mycol **2007**; 25:419–21.
 141. Kordy FN, Al-Mohsen IZ, Hashem F, et al. Successful treatment of a child with posttraumatic necrotizing fasciitis caused by *Apophysomyces elegans*: case report and review of the literature. Pediatr Infect Dis J **2004**; 23:877–9.
 142. Kerr OA, Bong C, Wallis C, Tidman MJ. Primary cutaneous mucormycosis masquerading as pyoderma gangrenosum. Br J Dermatol **2004**; 150:1212–34.
 143. Diven SC, Angel CA, Hawkins HK, Rowen JL, Shattuck KE. Intestinal mucormycosis due to *Absidia corymbifera* mimicking necrotizing enterocolitis in a preterm neonate. J Perinatol **2004**; 24:794–6.
 144. Mitchell SD, Gray J, Morgan ME, et al. Nosocomial infection with *Rhizopus microsporus* in preterm infants: association with wooden tongue depressors. Lancet **1996**; 348:441–3.
 145. Michalak DM, Cooney DR, Rhodes KH, Telander RL, Kleinberg F. Gastrointestinal mucormycoses in infants and children: a cause of gangrenous intestinal cellulitis and perforation. J Pediatr Surg **1980**; 15:320–4.
 146. Garg PK, Gupta N, Gautam V, Hadke NS. Gastric mucormycosis: unusual cause of gastric perforation in an immunocompetent patient. South Med J **2008**; 101:449–50.
 147. Bittencourt AL, Ayala MA, Ramos EA. A new form of abdominal mucormycosis different from mucormycosis: report of two cases and review of the literature. Am J Trop Med Hyg **1979**; 28:564–9.
 148. Oliver MR, Van Voorhis WC, Boeckh M, et al. Hepatic mucormycosis in a bone marrow transplant recipient who ingested naturopathic medicine. Clin Infect Dis **1996**; 22:521–4.
 149. Ismail MH, Hodkinson HJ, Setzen G, Sofianos C, Hale MJ. Gastric mucormycosis. Trop Gastroenterol **1990**; 11:103–5.

150. Lyon DT, Schubert TT, Mantia AG, Kaplan MH. Phycomycosis of the gastrointestinal tract. *Am J Gastroenterol* **1979**; 72:379–94.
151. Geramizadeh B, Modjalal M, Nabai S, et al. Gastrointestinal mucormycosis: a report of three cases. *Mycopathologia* **2007**; 164:35–8.
152. Echo A, Hovsepian RV, Shen GK. Localized cecal mucormycosis following renal transplantation. *Transplant Infect Dis* **2005**; 7:68–70.
153. Virk SS, Singh RP, Arora AS, Grewal JS, Puri H. Gastric mucormycosis—an unusual cause of massive upper gastrointestinal bleed. *Indian J Gastroenterol* **2004**; 23:146–7.
154. Azadeh B, McCarthy DO, Dalton A, Campbell F. Gastrointestinal mucormycosis: two case reports. *Histopathology* **2004**; 44:298–300.
155. Park YS, Lee JD, Kim TH, et al. Gastric mucormycosis. *Gastrointest Endosc* **2002**; 56:904–5.
156. Siu KL, Lee WH. A rare cause of intestinal perforation in an extreme low birth weight infant—gastrointestinal mucormycosis: a case report. *J Perinatol* **2004**; 24:319–21.
157. Cherney CL, Chutuape A, Fikrig MK. Fatal invasive gastric mucormycosis occurring with emphysematous gastritis: case report and literature review. *Am J Gastroenterol* **1999**; 94:252–6.
158. Tomita T, Ho H, Allen M, Diaz J. Mucormycosis involving lungs, heart and brain, superimposed on pulmonary edema. *Pathol Int* **2005**; 55:202–5.
159. Fujii T, Takata N, Katsutani S, Kimura A. Disseminated mucormycosis in an acquired immunodeficiency syndrome (AIDS) patient. *Intern Med* **2003**; 42:129–30.
160. Richardson MD, Warnock DW. Mucormycosis. In: Richardson MD, Warnock DW, eds. *Fungal infection diagnosis and management*. Oxford, United Kingdom: Blackwell, **2003**:230–40.
161. Ingram CW, Sennesh J, Cooper JN, Perfect JR. Disseminated mucormycosis: report of four cases and review. *Rev Infect Dis* **1989**; 11:741–54.
162. Virmani R, Connor DH, McAllister HA. Cardiac mucormycosis: a report of five patients and review of 14 previously reported cases. *Am J Clin Pathol* **1982**; 78:42–7.
163. Sanchez-Recalde A, Merino JL, Dominguez F, Mate I, Larrea JL, Sobrino JA. Successful treatment of prosthetic aortic valve mucormycosis. *Chest* **1999**; 116:1818–20.
164. Mishra B, Mandal A, Kumar N. Mycotic prosthetic-valve endocarditis. *J Hosp Infect* **1992**; 20:122–5.
165. Solano T, Atkins B, Tambosis E, Mann S, Gottlieb T. Disseminated mucormycosis due to *Saksenaia vasiformis* in an immunocompetent adult. *Clin Infect Dis* **2000**; 30:942–3.
166. Zhang R, Zhang JW, Szerlip HM. Endocarditis and hemorrhagic stroke caused by *Cunninghamella bertholletiae* infection after kidney transplantation. *Am J Kidney Dis* **2002**; 40:842–6.
167. Kalayjian RC, Herzig RH, Cohen AM, Hutton MC. Thrombosis of the aorta caused by mucormycosis. *South Med J* **1988**; 81:1180–2.
168. Mehta NN, Romanelli J, Sutton MG. Native aortic valve vegetative endocarditis with *Cunninghamella*. *Eur J Echocardiogr* **2004**; 5:156–8.
169. Gubarev N, Separovic J, Gasparovic V, Jelic I. Successful treatment of mucormycosis endocarditis complicated by pulmonary involvement. *Thorac Cardiovasc Surg* **2007**; 55:257–8.
170. Sanchez-Recalde A, Merino JL, Dominguez F, et al. Successful treatment of prosthetic aortic valve mucormycosis. *Chest* **1999**; 116:1818–20.
171. Burke WV, Zych GA. Fungal infection following replacement of the anterior cruciate ligament: a case report. *J Bone Joint Surg Am* **2002**; 84A:449–53.
172. Pierce PP, Wood MB, Roberts GD, Fitzgerald RH, Robertson C, Edson RS. *Saksenaia vasiformis* osteomyelitis. *J Clin Microbiol* **1987**; 25:933–5.
173. Holtom PD, Obuch AB, Ahlmann ER, Shepherd LE, Patzakis MJ. Mucormycosis of the tibia: a case report and review of the literature. *Clin Orthop* **2000**; 381:222–8.
174. Wanishawad C, Kimbrough RC, Chinratanalab S, Nugent K. Mucormycotic osteolytic rib lesion presenting as subacute pleural effusion. *Clin Infect Dis* **1996**; 22:715–16.
175. Meis JF, Kullberg BJ, Pruszczyński M, Veth RP. Severe osteomyelitis due to the zygomycetes *Apophysomyces elegans*. *J Clin Microbiol* **1994**; 32:3078–81.
176. Chaudhuri R, McKeown B, Harrington D, Hay RJ, Bingham JB, Spencer JD. Mucormycosis osteomyelitis causing avascular necrosis of the cuboid bone: MR imaging findings. *Am J Roentgenol* **1992**; 159:1035–7.
177. Echols RM, Selinger DS, Hallowell C, Goodwin JS, Duncan MH, Cushing AH. Rhizopus osteomyelitis. A case report and review. *Am J Med* **1979**; 66:141–5.
178. Nayak S, Satish R, Gokulnath, Savio J, Rajalakshmi T. Peritoneal mucormycosis in a patient on CAPD. *Perit Dial Int* **2007**; 27:216–17.
179. Ram R, Swarnalatha G, Prasad N, Dakshinamurthy KV. Exit site infection due to mucormycosis resulting in abdominal wall necrosis in a continuous ambulatory peritoneal dialysis patient. *Nephrol Dial Transplant* **2007**; 22:266–7.
180. Serna JH, Wanger A, Dosekun AK. Successful treatment of mucormycosis peritonitis with liposomal amphotericin B in a patient on long-term peritoneal dialysis. *Am J Kidney Dis* **2003**; 42:E14–17.
181. Fergie JE, Fitzwater DS, Einstein P, Leggiadro RJ. Mucor peritonitis associated with acute peritoneal dialysis. *Pediatr Infect Dis J* **1992**; 11:498–500.
182. Weng DE, Wilson WH, Little R, Walsh TJ. Successful medical management of isolated renal mucormycosis: case report and review. *Clin Infect Dis* **1998**; 26:601–5.
183. Schwartz JR, Nagle MG, Elkins RC, et al. Mucormycosis of the trachea: an unusual cause of acute upper airway obstruction. *Chest* **1982**; 81:653–4.
184. Marwaha RK, Banerjee AK, Thapa BR, et al. Mediastinal mucormycosis. *Postgrad Med J* **1985**; 61:733–5.
185. Saegeman V, Maertens J, Meersseman W, et al. Increasing incidence of mucormycosis in university hospital, Belgium. *Emerg Infect Dis* **2010**; 16:1456–8.