

Epidemiology, Etiology, Pathogenesis, and Diagnosis of Recurrent Bacterial Meningitis

Marc Tebruegge and Nigel Curtis*

Department of Paediatrics, The University of Melbourne, Parkville, Australia; Infectious Diseases Unit, Department of General Medicine, Royal Children's Hospital Melbourne, Parkville, Australia; and Murdoch Childrens Research Institute, Parkville, Australia

INTRODUCTION	519
DEFINITION OF RECURRENT BACTERIAL MENINGITIS	520
SEARCH STRATEGY AND RESULTS	520
EPIDEMIOLOGY OF RECURRENT BACTERIAL MENINGITIS	520
ETIOLOGY OF RECURRENT BACTERIAL MENINGITIS	521
PREDISPOSING CONDITIONS ASSOCIATED WITH RECURRENT BACTERIAL MENINGITIS	521
Congenital Anatomical Defects	521
Heterotopic brain tissue.....	521
Epidermoid cysts, dermoid cysts, and dermal sinus tracts	522
Neurenteric cysts.....	522
Mondini dysplasia and other congenital inner ear malformations	522
Neural tube defects.....	523
Asplenia.....	523
Acquired Anatomical Defects	523
Head injuries	523
Neoplasias	526
Congenital Immunodeficiencies	526
Complement deficiencies.....	526
X-linked agammaglobulinemia	526
IgG subclass deficiency	526
IRAK-4 deficiency	527
Acquired Immunodeficiencies	527
HIV infection	527
Chronic Parameningeal Infections	527
POTENTIAL INDICATORS OF UNDERLYING CONDITIONS	528
Age at Onset	528
Presentation in childhood.....	528
Presentation in adult life	528
Microbiological Aspects	529
<i>Streptococcus pneumoniae</i>	529
<i>Neisseria meningitidis</i>	529
<i>Haemophilus influenzae</i>	529
<i>Staphylococcus aureus</i>	530
Gram-negative enteric organisms.....	530
DIAGNOSTIC PATHWAYS	530
History	530
Examination	530
Investigations	531
Laboratory investigations	531
Radiological investigations	532
LIMITATIONS	532
ACKNOWLEDGMENTS	532
REFERENCES	533

INTRODUCTION

Bacterial meningitis is a severe, potentially life-threatening infection that is associated with high rates of morbidity and

significant disability in survivors. In recent years, despite improvements in antimicrobial therapy and intensive care support, overall mortality rates related to bacterial meningitis of around 20% to 25% have been reported by major centers (44, 195). Potential long-term neurological sequelae include cranial nerve palsies, hemiparesis, hydrocephalus, and seizures as well as visual and hearing impairment (1, 44), which can have a profound impact on the quality of life of the survivors.

Recurrent bacterial meningitis is a much less common phe-

* Corresponding author. Mailing address: Department of Paediatrics, Royal Children's Hospital Melbourne, Flemington Rd., Parkville, Victoria 3052, Australia. Phone: 61-3-9345 4545. Fax: 61-3-9345 6667. E-mail: nigel.curtis@rch.org.au.

nomenon but generally poses a considerable diagnostic challenge. The early diagnosis of any underlying pathology is crucial to prevent further episodes and improve the overall outcome for the affected individual.

The last comprehensive literature review on recurrent meningitis was published by Kline in 1989 (96). That author identified only 47 cases published in the preceding 10 years, which consisted of 34 cases of cerebrospinal fluid (CSF) fistulas, 10 patients with immunodeficiency, and 3 cases in whom no predisposing factor had been identified.

Advances in microbiology, immunology, and radiology since that review have led to a further understanding of the mechanisms underlying recurrent meningitis. In this review, we systematically and comprehensively summarize the literature on recurrent bacterial meningitis that has been published in the last two decades. We also suggest a structured approach to the investigation of patients with recurrent meningitis.

DEFINITION OF RECURRENT BACTERIAL MENINGITIS

There is considerable confusion and disagreement about the definition and terminology used in relation to the recurrence of bacterial meningitis. Most authors have defined "recurrent meningitis" as being two separate episodes of meningitis that are separated by a period of convalescence and full recovery. Therefore, true recurrence results from a reinfection with the same or a different bacterial organism. In contrast, recrudescence and relapse represent persistence of the "original" infection resulting from treatment failure.

For this review, in accordance with most other authors (1, 42, 44), we defined recurrent bacterial meningitis as two or more episodes of meningitis caused by a different bacterial organism or, alternatively, a second or further episode caused by the same organism with a greater-than-3-week interval after the completion of therapy for the initial episode. In addition, we included cases with two or more episodes of bacterial meningitis defined by abnormal CSF results if the episodes occurred a minimum of 3 weeks apart. These definitions were designed to exclude cases of relapsing meningitis and recrudescence meningitis.

All cases that were deemed to be iatrogenic in origin were excluded from the review. These cases included patients who had recurrent meningitis following neurosurgical operations (e.g., ventriculoperitoneal shunts or spinal surgery), otorhinolaryngological interventions (e.g., cochlear implants), or other forms of cranial or maxillofacial surgery resulting in a CSF leak. Cases secondary to the retention of intracerebral foreign bodies (such as missile- and blast-related injuries) and oncological patients undergoing intrathecal therapy were also excluded. Cases of meningitis caused by mycobacteria were also excluded, as these are a separate entity.

SEARCH STRATEGY AND RESULTS

Publications in English between January 1988 and December 2007 were searched for using multiple strategies. The Medline database, using the PubMed interface, was searched using the search terms "recurr*" and "meningitis" joined by the Boolean operator "AND" (no limits set), which produced

2,102 matches, 132 of which were relevant and included in the review. A PubMed MeSH database search using the search terms "recurrence" and "meningitis" produced 918 matches but did not identify any further relevant publications. The same search using the ISI Web of Science database identified 1,549 publications, including 4 relevant publications not previously identified (69, 73, 163, 169). In addition, all identified publications were searched for further relevant references, which identified another eight papers (63, 121, 129, 165, 189, 209, 215, 220). Only cases in which the likely underlying etiology was described were included. In some instances where insufficient data were presented in the manuscript to categorize cases adequately, the authors were contacted and asked to provide the missing details. Publications with substantial remaining uncertainties or insufficient details were not included (71, 89, 182, 200, 207, 213).

One case with recurrent episodes of bacterial meningitis caused by the same organism within a 3-week period was included, as the authors demonstrated that different strains had been involved (19).

EPIDEMIOLOGY OF RECURRENT BACTERIAL MENINGITIS

A large retrospective study by Durand et al. established that as many as 6% of patients presenting with community-acquired meningitis develop a subsequent recurrence (44). A similar proportion (5%) was reported by Adriani et al. in a more recent prospective, nationwide study of adults with community-acquired meningitis in The Netherlands (1). However, this proportion may be considerably lower in children. Drummond et al. reported that only 1.3% of children with meningitis admitted to a large tertiary unit over an 11-year period had experienced bacterial meningitis on at least one previous occasion (42).

Based on their data, Adriani et al. estimated the annual incidence of recurrent meningitis to be around 0.12 cases per 100,000 adults. Notably, in 26 of the 34 episodes of recurrent meningitis recorded in that study, predisposing factors could be identified, which included head injuries, history of CSF leakage, and immunocompromise.

Both Durand et al. and Adriani et al. made interesting observations about the severity of illness and mortality in patients with recurrent bacterial meningitis. Adriani's group noted that the mortality rate in their cohort of patients with recurrent meningitis was only 15%, while the mortality rate in a cohort with a single episode in the same country, thus having access to the same treatment and facilities, was more than double (34%) (216). An even more pronounced trend was observed by Durand et al., who reported that none of their patients with recurrent meningitis had died during the study period, compared with a case fatality rate of 25% for patients presenting with their first episode of bacterial meningitis. Adriani et al. hypothesized that this was partly related to the fact that patients who had experienced previous episodes of meningitis are likely to recognize the symptoms early and seek medical attention sooner, thereby improving their prognosis.

ETIOLOGY OF RECURRENT BACTERIAL MENINGITIS

Predisposing factors for recurrent bacterial meningitis can be broadly categorized into congenital and acquired conditions and further divided into anatomical abnormalities, immunodeficiencies, and chronic parameningeal infections.

A total of 363 cases of recurrent bacterial meningitis reported in 144 publications were identified in the systemic literature search of publications between 1998 and 2007. These cases are summarized in Tables 1 to 3. Of these cases, 214 (59%) were related to anatomical problems, 132 (36%) were related to immunodeficiencies, and 17 (5%) were related to parameningeal infections. The majority of publications reported only a single patient with recurrent bacterial meningitis (105 reports [73%]). Only 15 reports described five or more cases. There was a slight male predominance (1.2:1) in the 201 cases in which the gender was stated.

In the group of cases related to anatomical problems, the abnormality was located in the cranial or cervical region in 198 cases (93%), compared with only 16 cases (7%) with defects in lumbosacral location. By far, the largest group in this category were cases of traumatic head injury with secondary CSF fistula, accounting for almost one-half of all cases in this category (102 cases [47%]).

Individuals with complement deficiency dominated the category of immunodeficient patients (72 cases [55%]). Human immunodeficiency virus (HIV) infection was identified as being a predisposing factor in 43 (33%) cases, with all but 2 cases reported in a single study (135). The remaining 17 (13%) cases in this category consisted of individuals with agammaglobulinemia, immunoglobulin G (IgG) subclass deficiency, common variable immunodeficiency, interleukin-1 receptor-associated kinase 4 (IRAK-4) deficiency, and asplenia.

Of the patients with recurrent bacterial meningitis due to chronic parameningeal infections, the majority (11 cases [73%]) had a diagnosis of chronic otitis media and/or chronic mastoiditis. Only two cases were attributed to chronic sinusitis, and a further two cases were attributed to chronic osteomyelitis.

In three cases, there was a presumed association with distinct syndromes. Two patients were suffering from neurofibromatosis type I, a neurocutaneous syndrome (28, 65). One of these patients was found to have a meningocele; in the second case, the authors assumed that a neurofibroma had eroded the skull base. The third case was a patient with Maffucci's syndrome, a rare disorder associated with multiple haemangiomas and enchondromata (202). As part of the disease process, this patient had developed multiple bone and dural dehiscences of the skull base, resulting in CSF fistulas.

In 548 of the episodes of meningitis, the causative organism was reported by the authors. Many patients had additional, culture-negative episodes with CSF findings suggestive of bacterial meningitis. Microbiological results were not specified in several publications. *Streptococcus pneumoniae* was the most commonly isolated organism, responsible for 310 (56.6%) of the culture-confirmed episodes of meningitis. *Neisseria meningitidis* was identified as being the causative agent in 134 (24.5%) episodes; of these episodes, 123 (92%) occurred in complement-deficient patients. The remaining culture-positive episodes of meningitis comprised *Haemophilus influenzae* in 38

episodes (6.9%), *Escherichia coli* in 23 episodes (4.2%), *Staphylococcus aureus* in 13 episodes (2.4%), *Salmonella* spp. in 10 episodes (1.8%), *Proteus* spp. in 5 episodes (0.9%), enterococci in 3 episodes (0.5%), and *Klebsiella pneumoniae* in 2 episodes (0.4%). Streptococci were implicated in 10 episodes (1.8%) (group A streptococci in 2, group B streptococci in 3, group D streptococci in 2, and viridans streptococci [not further specified] in 3 episodes).

PREDISPOSING CONDITIONS ASSOCIATED WITH RECURRENT BACTERIAL MENINGITIS

Congenital Anatomical Defects

Bacterial meningitis is believed to result predominantly from blood-borne bacteria invading the cerebrospinal fluid space via the choroid plexus (35, 225). In addition, a variety of cranial and spinal anatomical defects can produce an abnormal communication with the CSF space, thereby facilitating the migration of pathogenic organisms into the intradural and subarachnoid spaces. In the cranial area, these pathological pathways of entry are located mainly at the anterior skull base—composed of frontal, ethmoid, and sphenoid bone—or the temporal bone. Congenital neural tube defects, also called spinal dysraphism, are most commonly located in the lumbosacral area but may occur elsewhere along the cervical or thoracic spine (191).

Heterotopic brain tissue. The extracranial location of brain tissues is a rare phenomenon. Unfortunately, the classification and terminology for heterotopic brain tissue used in the literature are confusing. One useful classification was proposed by Knox et al., who divided extracranial congenital malformations of the central nervous system into encephaloceles, gliomas, and heterotopias depending on the presence or absence of an anatomical connection to the brain (97). While encephaloceles retain an attachment to the brain, gliomas retain their connection in only 30% of the cases, and heterotopias represent isolated remnants of neural tissue without central attachment. Histologically, encephaloceles commonly contain neurons, glia, choroid plexus, and meninges; in contrast, gliomas consist predominantly of glial cells and fibrous tissue, rarely contain neurons, and never contain choroid plexus or ependyma (224).

Encephaloceles are usually congenital and have less commonly been described as being an acquired condition caused by rhinological operations or traumatic head injuries (20, 64, 196). These are rare, with an overall incidence of congenital encephaloceles in Western populations of approximately 1 per 11,500 live births (82).

Basal encephaloceles may protrude through the cribriform plate into the superior meatus (transethmoidal), through a defect in the posterior ethmoid and sphenoid sinuses (sphenothmoidal), or through a patent craniopharyngeal canal (transsphenoidal) into the nasal and pharyngeal spaces (224). Therefore, encephaloceles may present as feeding or respiratory difficulties in the neonatal age, as nasal obstruction in childhood, or as recurrent meningitis at any stage. Interestingly, spontaneous rinorrhoea in this group appears to be rare and occurs primarily after surgical interventions such as biopsy or "polypectomy" (224). There have been reports of intranasal encephaloceles that were initially misinterpreted as being nasal polyps or sinusitis upon clinical examination or radiological

imaging (98); the potentially deleterious consequences of such misdiagnoses resulting in inappropriate surgical approaches are obvious.

The literature search identified 19 cases of recurrent meningitis secondary to heterotopic brain tissue, consisting predominantly of individuals with meningocele or encephalocele. In seven (78%) of the nine cases in which the age was reported, the first presentation was in childhood (28, 75, 82, 127, 140, 196). The remaining two patients presented at 21 and 40 years of age (40, 74). In most cases, the gap between the initial presentation and the diagnosis was 3 years or less. The notable exception was a patient with a transthemoidal intranasal meningoencephalocele, who had his first episode of bacterial meningitis at 12 years of age but was diagnosed 40 years later, having suffered five further episodes of bacterial meningitis in the interim (75). The vast majority of meningitis episodes in this group were caused by *S. pneumoniae* (83%), followed by *S. aureus* (11%) and *N. meningitidis* (6%).

Epidermoid cysts, dermoid cysts, and dermal sinus tracts. Epidermoid and dermoid cysts are developmental tumors that originate from the inclusion of epidermal or dermal components within the neuroaxis during the embryonic stage and can consequently be located intracranially or intraspinally. While epidermoid cysts contain only keratinized epithelium, dermoid cysts also contain additional dermal elements including hair, connective tissue, and sebaceous glands. The vast majority of patients with epidermoid and dermoid cysts present with slowly progressing neurological symptoms in adulthood, such as headaches, seizures, and disequilibrium, rather than with meningitis (228). However, both tumors can cause recurrent, episodic aseptic meningitis by rupturing cyst contents into the subarachnoid space, which is thought to result in chemical irritation (103, 106, 188).

Bacterial meningitis in association with these tumors is most commonly related to a coexisting dermal sinus tract, which is due to the incomplete separation of the cutaneous ectoderm from the neural ectoderm during embryonic development. The tract may appear as only a tiny dimple in the midline of the spine or the posterior skull, and identification upon physical examination may be challenging, particularly when located in the occipital region, where the opening may be covered by hair (10, 103, 198). In a spinal location, dermal sinus tracts are frequently associated with visible cutaneous stigmata in the surrounding area, such as naevi, port wine stains, or a tuft of hair (10).

The spectrum of organisms causing bacterial meningitis in the group with occipital lesions consists predominantly of constituents of the skin flora, with *S. aureus* being the most commonly isolated organism (198, 206). In contrast, in infants and young children with dermal sinuses in the lumbosacral location, gram-negative organisms, particularly *E. coli*, and enterococci are the most common causative organisms of meningitis, most likely secondary to fecal contamination (10, 115).

The literature search identified 24 cases of recurrent bacterial meningitis associated with dermoid and epidermoid cysts (6, 10, 26, 80, 103, 115, 172, 198). Histologically, only one tumor was determined to be an epidermoid cyst (26); 17 cases were reported as being dermoid cysts. The location was intracranial in 5, cervical in 1, thoracic in 3, and lumbosacral in 15 cases. In all cases, an abnormal connection to the CSF space

was present in the form of a dermal sinus tract. The majority of patients in this group experienced their first episode of meningitis in the first few months of life. The exception is the case of a girl who presented with *Proteus mirabilis* meningitis at the age of 25 months (26). She was readmitted with another episode of meningitis due to the same organism 4 months later and was subsequently found to have an intracranial epidermoid cyst associated with a dermal sinus tract that terminated in the occipital region.

Neurenteric cysts. Neurenteric cysts are congenital malformations originating from endodermal tissue and are located mainly in the mediastinum (131, 199). Less commonly, they can occur in the spinal canal in an intradural or intramedullary location, when they are generally ventrally located to the spinal cord (111). Patients may therefore present with cardiac or respiratory compromise secondary to the intrathoracic mass effect or signs of cord compression (131). Less frequently, affected individuals present with episodic aseptic meningitis due to the leakage of cystic fluid, analogous to the phenomenon described in connection with epidermoid and dermoid cysts mentioned above, or bacterial meningitis (9, 131).

The literature search identified four cases of recurrent bacterial meningitis associated with this condition (2, 70, 115, 131). In three cases, the neurenteric cyst was located in the suboccipital region or cervicomedullary junction, and in one case, the lesion was found in the presacral area. The patient with a premedullary neurenteric cyst described by Lieb et al. experienced three further episodes of bacterial meningitis despite surgical removal of the cyst (115). After multiple diagnostic and surgical procedures, a coexisting small fistulous duct between the posterior cranial fossa and the left Eustachian tube was identified as being the cause. The difficulty of diagnosing these patients is also illustrated by the case of a 10-year-old girl, who experienced a total of 59 episodes of meningitis (32 culture-confirmed episodes) and had undergone eight surgical explorations before the diagnosis was eventually made (70). The most common causative organism in this group of patients was again *S. pneumoniae* (37%), closely followed by *H. influenzae* (34%) and *S. aureus* (23%).

Mondini dysplasia and other congenital inner ear malformations. Mondini dysplasia and other forms of congenital inner ear malformations accounted for a large proportion of cases of recurrent bacterial meningitis (55 of 363 cases). The predisposition to develop bacterial meningitis in these conditions results from a fistulous connection between the CSF spaces and the middle ear, which in turn is connected to the nasopharynx via the Eustachian tube. Organisms causing meningitis in this context are therefore frequently nasopharyngeal commensals.

Mondini dysplasia, one of the more common congenital inner ear dysplasias, is thought to result from a developmental arrest around the seventh week of the embryonic stage (158). The cochlea characteristically consists of 1½ turns instead of the normal 2½ turns in association with a deficient interscalar septum. The underlying CSF fistula in Mondini dysplasia occurs primarily through a deficient oval window or stapes footplate into the middle ear (154, 187). There can be uni- or bilateral involvement. Most affected individuals have profound sensorineural hearing loss, but hearing is preserved to some extent in some cases

(154). Mondini dysplasia usually occurs in isolation but has been described in association with Klippel-Feil syndrome, Pendred's syndrome, and Di-George syndrome.

In the absence of an alternative explanation, patients with recurrent meningitis, particularly children, should always be tested for a hearing impairment that might suggest an inner ear malformation. A number of pitfalls may delay the diagnosis of Mondini dysplasia. The malformation may be unilateral, and hearing problems, particularly in younger children, may go unnoticed. In addition, the hearing impairment might be misinterpreted as resulting from preceding episodes of meningitis (154). Also, there have been several reports where CSF leaks into the middle ear, producing a fluid level behind the tympanic membrane or bulging of the same in conjunction with hearing impairment, were initially misinterpreted as being benign serous otitis media (122, 208). As a result, some of these patients underwent myringotomy and insertion of a ventilation tube, which may have exacerbated the situation further by creating an additional portal of entry for bacteria (208). Thus, a persistently or intermittently bulging tympanic membrane in conjunction with recurrent meningitis should always raise suspicion. In this scenario, the distinction between CSF and serous exudate can easily be made via β_2 -transferrin analysis (see the section on examination).

A review by Ohlms et al. in 1990 summarized a total of 39 cases of Mondini dysplasia associated with meningitis (154). Strikingly, only three of these cases were diagnosed after the first episode of meningitis, while the remaining patients suffered between 2 and 20 episodes before the correct diagnosis was made. All episodes reported in that review were caused either by *S. pneumoniae* or, less frequently, by *H. influenzae*.

In the cases associated with inner ear malformations identified in the literature search (Table 1), in addition to these two organisms, there were also three cases in which *N. meningitidis* was identified as being the causative agent (31, 141, 164) and two cases caused by viridans streptococci (120, 133). One of these occurred in an infant who developed meningitis due to *Streptococcus sanguis* at 1 month of age, followed by pneumococcal meningitis at 4 months.

The likelihood of a patient with inner ear malformations acquiring meningitis appears to be surprisingly high. In a series of 20 patients with congenital inner ear malformations described by Phelps et al., one-quarter developed recurrent meningitis; in one case, the second episode was fatal (164).

The majority of cases of meningitis related to Mondini's dysplasia and other inner ear malformations occur under the age of 10 years, with only a few cases reported for adults (165, 177). In the unusual case of a 33-year-old patient who developed his first episode of meningitis at age 29, both a preceding fall as well as deep sea diving may have contributed to the development of a CSF leak via a circular defect in the stapes footplate (177).

Plain skull X-rays are rarely helpful in this setting, and high-resolution computer tomography (CT) scanning of the temporal bones is considered to be the method of choice to confirm the diagnosis by most authors (133, 164, 165, 171).

Neural tube defects. Lumbosacral neural tube defects such as meningoceles and meningomyeloceles are classical examples of congenital malformations with abnormal communication between the skin surface and the CSF spaces. Most are

diagnosed prenatally by ultrasound or at birth and treated by early neurosurgical interventions. This may partly explain why the literature search identified only one case of recurrent meningitis in this group reported in the last two decades. The decline in the prevalence of neural tube defects in industrialized countries in the last decade attributable to folic acid supplementation and food fortification may be an additional factor (39, 191, 192). Another explanation may be that the association between an open neural tube defect and meningitis is too well described to warrant further publications. However, in rare instances, the identification of the defect might still prove challenging. This is illustrated by the case of an infant with recurrent meningitis who had an occult anterior sacral meningocele identified only after a CT scan following three episodes of meningitis (59).

Asplenia. Asplenia is most commonly due to the surgical removal of the spleen following trauma or related to a variety of hematological conditions. Individuals with absent spleen are at an increased risk of overwhelming bacterial infections with encapsulated organisms, particularly *S. pneumoniae* and *H. influenzae* (37). Congenital asplenia occurs mainly in the context of Ivemark syndrome (also referred to as asplenia syndrome), which consists of congenital heart disease, complex thoracoabdominal heterotaxia, and asplenia (27). However, rare cases of isolated congenital asplenia have also been described and have been associated with recurrent pneumococcal meningitis on three reported occasions (62).

The literature search identified 11 cases of asplenia associated with recurrent bacterial meningitis. Five had congenital asplenia, and the remaining six had undergone splenectomy for various medical reasons. One patient in the latter group was also infected with HIV. There were a total of 21 culture-positive episodes of meningitis reported in this group. Strikingly, with the exception of one case due to *Streptococcus bovis*, all other episodes were due to *S. pneumoniae* (Table 2).

Acquired Anatomical Defects

Head injuries. Reports of patients with CSF fistulas as a result of head injury represented the largest group of cases (28%) of recurrent bacterial meningitis identified in the literature search.

Reports suggest that CSF leaks occur in approximately 2% of all head injuries and in about 5% to 12% of basal skull fractures (58, 114, 166). According to Brodie and Thompson, as well as Friedman et al., CSF fistulas are most commonly associated with frontal sinus fractures, followed by orbital and petrous bone fractures (21, 58). The majority of these posttraumatic CSF leaks resolve through spontaneous closure within the first 24 to 48 h (58). While most affected adult patients have clinical symptoms suggestive of a CSF leak, consisting primarily of rhinorrhea or otorrhea, a smaller proportion have clinically occult leaks (58). The diagnosis in children is more challenging, as CSF rhinorrhea is often not recognized unless externally apparent.

There have been numerous reports of CSF leaks with a delayed onset following the injury. In most cases, these fistulas become apparent within the first month (58), but delays up to several years have been reported, including a patient who developed rhinorrhea 34 years after sustaining a head injury (179).

Persistent CSF fluid fistulas after head injury can lead to

TABLE 1. Anatomical problems associated with recurrent bacterial meningitis^a

Condition	Total no. of cases	Median age at onset ^b (range)	Median age at diagnosis (range)	Organism(s) ^c isolated (no. of occasions ^d)	Reference(s)
Cranial and cervical anatomical defects					
Heterotopic brain tissue (congenital) (meningocele/meningoencephalocele)	19	7 yr (6 wk–40 yr)	13.5 yr (3 yr–65 yr)	<i>S. pneumoniae</i> (15), <i>S. aureus</i> (2), <i>N. meningitidis</i> (1)	16, 28, 40, 48, 60, 74, 75, 82, 127, 128, 140, 162, 183, 196, 224
Meningioma	1	49 yr	53 yr	<i>S. pneumoniae</i> (1)	91
Skull base defects (likely congenital)					
Ethmoid bone	3	3.5 yr (3 yr–4 yr)	6 yr (5 yr–12 yr)	<i>S. pneumoniae</i> (5)	24, 159, 183
Petrosal bone	5	2 yr (1.5 yr–4 yr)	6.5 yr (6 yr–29 yr)	<i>S. pneumoniae</i> (8), <i>H. influenzae</i> (2), <i>N. meningitidis</i> (1)	13, 19, 107, 138, 222
Sphenoid sinus	3	n.a.	47 yr (32 yr–63 yr)	<i>S. pneumoniae</i> (1) ^e	72, 183
Dermoid cyst/epidermoid cyst/dermal sinus tract	5	0.5 yr (2 wk–2 yr)	1 yr (3 mo–3 yr)	<i>E. coli</i> (4), <i>P. mirabilis</i> (3), <i>S. aureus</i> (3)	26, 80, 103, 110, 172, 198
Cranial lymphangiomatosis	1	19 mo	3.5 yr	<i>H. influenzae</i> (2), group A streptococcus (2), <i>S. pneumoniae</i> (1)	145
Neurenteric cyst	4	0.1 yr (1 wk–1 mo)	9 yr (4 yr–13 yr)	<i>S. pneumoniae</i> (13), <i>H. influenzae</i> (12), <i>S. aureus</i> (8), group B streptococcus (1), group D streptococcus (1)	2, 70, 115, 131
Inner ear abnormality (unspecified)	42	1.7 yr (1 mo–23 yr)	5 yr (4 mo–24 yr)	<i>S. pneumoniae</i> (36), <i>H. influenzae</i> (8), <i>N. meningitidis</i> (3), viridans streptococcus (1)	15, 31, 81, 87, 93, 116, 121, 122, 133, 137, 142, 160, 164, 165, 171, 178, ^g 203, 208, 209
Mondini dysplasia	13	4 yr (1 yr–8 yr)	5.9 yr (1.5 yr–9 yr)	<i>S. pneumoniae</i> (15), <i>N. meningitidis</i> (2), <i>H. influenzae</i> (1), viridans streptococcus (1)	3, ^h 76, 95, 120, 137, 141, 143, 154, 178, ^g 212, 215
Head injury/basal skull fractures ^f	102	9 yr (8 mo–36 yr)	16.5 yr (3 mo–56 yr)	<i>S. pneumoniae</i> (100), <i>H. influenzae</i> (7), <i>N. meningitidis</i> (4), group B streptococcus (1)	1, 4, 5, 8, 14, 22, 24, 36, 42, 46, 54, 58, 64, 66, 69, 78, 79, 90, 92, 94, 98, 100, 105, 118, 124, 139, 146, 156, 163, 167, 172, 201, 205, 217, 223, 227
Lumbosacral anatomical defects					
Meningocele	1	4 mo	1 yr	<i>K. pneumoniae</i> (1), <i>Proteus mirabilis</i> (1)	59
Dermal sinus/dermoid cyst	15	1 yr (2 mo–5 yr)	1.5 yr (1 yr–5 yr)	<i>E. coli</i> (14), enterococci (3), <i>S. pneumoniae</i> (1), <i>Klebsiella</i> (1)	6, 10, 115, 172

^a Patients with more than one risk factor were recorded in all the relevant categories. All patient included had at least two episodes of meningitis (clinical features and results suggestive of bacterial meningitis), but the causative organism was not identified in all episodes.

^b Age at onset is age at the first episode of meningitis. n.a., no data available.

^c Organisms determined by CSF culture, CSF antigen testing, or positive blood culture with CSF analysis suggestive of bacterial meningitis

^d Number of separate occasions at which an organism was isolated; i.e., one patient may have had several episodes caused by different organisms.

^e The actual number of *S. pneumoniae*-positive meningitis episodes is probably higher; the second article provided insufficient details.

^f The patient described by Hristea et al. with 28 episodes of pneumococcal meningitis was included as a single episode (79).

^g Additional data that were not included in the original publication were provided by the author; V. Rupa confirmed that the CSF findings are indicative of bacterial meningitis.

^h Additional data that were not included in the original publication were provided by the author. L. Al-Shamsan provided the number of meningitis episodes and age at onset.

TABLE 2. Immunodeficiencies associated with recurrent bacterial meningitis^a

Condition	Total no. of cases	Median age at onset ^b (range)	Median age at diagnosis (range)	Organism(s) ^c isolated (no. of occasions ^d)	Reference(s)
HIV infection ^e	43	n.a.	n.a.	<i>S. pneumoniae</i> (23), <i>Salmonella</i> spp. (10), Hib (2), <i>E. coli</i> (1)	1, 68, 135, ^f 136
Complement deficiencies					
C factor I	1	22 yr	n.a.	<i>N. meningitidis</i> (2)	67
C2	5	1 yr (1 mo–1.3 yr)	2 yr (1 yr–37 yr)	<i>S. pneumoniae</i> (7), <i>N. meningitidis</i> (2), group B streptococcus (1)	86, 193
C3	7	3 yr (1 mo–6 yr)	4 yr (3.5 yr–41 yr)	<i>S. pneumoniae</i> (29), <i>N. meningitidis</i> (3)	18, 36, 50, 52, 54, 180, 210
C3b inhibitor	1	4 mo	n.a.	<i>N. meningitidis</i> (4), <i>S. pneumoniae</i> (1)	124
C4	1	51 yr	n.a.	<i>S. pneumoniae</i> (2)	124
C4b	1	3 mo	17 yr	n.a.	83
C5	5	8.5 yr (3 yr–15 yr)	16 yr (7 yr–44 yr)	<i>N. meningitidis</i> (9)	29, 38, 124, 175, 180
C6	26	23 yr (2 yr–37 yr)	43 yr (25 yr–45 yr)	<i>N. meningitidis</i> (54)	33, 56, 148, 170, ^g 194
C7	5	10 yr (1 yr–18 yr)	20 yr (11 yr–20 yr)	<i>N. meningitidis</i> (13)	7, 124, 150, 168, 223
C8	19	15 yr (1 yr–28 yr)	21 yr	<i>N. meningitidis</i> (35)	168, 174
C9	1	23 yr	56 yr	<i>N. meningitidis</i> (1)	229
Agammaglobulinemia	2	1.8 yr (6 mo–3 yr)	2.8 yr (8 mo–5 yr)	<i>S. pneumoniae</i> (2)	49, 104
IgG subclass deficiency	3	2.5 yr (11 mo–16 yr)	4 yr (14 mo–18 yr)	<i>S. pneumoniae</i> (7)	56, 73, 153
Common variable immunodeficiency	1	7 yr	8 yr	<i>S. pneumoniae</i> (2)	157
IRAK-4 deficiency	1	n.a.	n.a.	<i>S. pneumoniae</i> (2)	129
Asplenia (iatrogenic and congenital) ^e	10	13 yr (3 mo–38 yr)	14 yr (6 mo–39 yr)	<i>S. pneumoniae</i> (21), <i>Streptococcus bovis</i> (1)	1, 42, 62, 63, 78, 102, 136, 167, 189, 201

^a Patients with more than one risk factor were recorded in all the relevant categories. All patients included had at least two episodes of meningitis (clinical features and results suggestive of bacterial meningitis), but the causative organism was not identified in all episodes. n.a., no data available.

^b Age at onset indicates the age at the first episode of meningitis.

^c Organisms were determined by CSF culture, CSF antigen testing, or positive blood culture with CSF analysis suggestive of bacterial meningitis.

^d Number of separate occasions at which an organism was isolated; i.e., one patient may have had several episodes caused by different organisms.

^e One patient was HIV positive and had a splenectomy before the onset of recurrent meningitis.

^f Incorporates additional data provided by author that were not included in the original publication; E. M. Molyneux provided more detailed data on the cohort described in the text.

^g Incorporates additional data provided by author that were not included in the original publication; the number of episodes of meningitis in some individuals was considerably greater than 2, but exact figures were unclear (P. C. Potter and A. Orren, personal communication).

posture-related headaches and pneumocephalus and render the individual vulnerable to invasion of the intradural space by organisms inhabiting the nasopharyngeal spaces. A retrospective analysis of 160 patients with CSF leak after closed head injury by Eljamel and Foy suggests that the risk of developing meningitis is greatest (9.1%) in the first week after the trauma (46). Following this period, those authors estimated the risk to be around 8% per month for the first 6 months and about 8% per year thereafter.

The literature search identified 102 patients with recurrent meningitis secondary to head injury. Most publications in this category were single case reports or very small case series. Only five publications described more than five cases (1, 46, 58, 124, 184). In many cases, there was a significant gap between the traumatic event and the first presentation with meningitis. In one unusual case, this interval was 31 years (205). Numerous reports highlighted patients who had suffered several episodes of meningitis before the correct diagnosis was made (79, 90, 92, 184, 223). At the extreme end of the spectrum was a patient

with a posttraumatic ethmoidal CSF fistula with 39 episodes of bacterial meningitis (including 28 episodes of pneumococcal meningitis) over a 20-year period despite immunization with a polyvalent pneumococcal vaccine and prophylaxis with penicillin (79).

S. pneumoniae was by far the most common causative agent in this group of patients, accounting for 89% of all culture-positive episodes, followed by *H. influenzae* (6%) and *N. meningitidis* (4%).

One interesting report described a 45-year-old woman with meningitis who had experienced intermittent watery discharge from the left nostril from the time she had sustained a severe head injury as a child. Group B streptococci were cultured from the CSF. Although those authors did not confirm the presence of a CSF leak, as the patient died despite adequate therapy, an underlying fistula appears to be likely. In this context, it should be mentioned that although group B streptococcal meningitis occurs predominantly in the neonatal period, it does infrequently affect adults (43, 181).

Neoplasias. Cranial tumors resulting in the erosion of the skull base only rarely appear to be associated with recurrent meningitis unless in association with complications related to neurosurgery or radiotherapy. The literature search identified a single case in this category, a 53-year-old woman diagnosed with a meningioma, who experienced two episodes of meningitis 4 years apart before the tumor was identified (91). However, the involvement of a CSF fistula in this case remains unclear, as there was no involvement of the middle ear and no evidence of temporal bone dehiscence intraoperatively.

Congenital Immunodeficiencies

Data from the above-mentioned prospective study on community-acquired recurrent meningitis by Adriani et al. suggested that only 9% of cases have an underlying immunodeficiency (1). However, that study included patients who had undergone neurosurgery, therefore skewing the data in favor of anatomical defects. Also, no predisposing condition was identified in 23% of the patients in that study. The particular immunological investigations undertaken were not detailed, but complement deficiencies were not routinely assessed. It is therefore possible that the proportion attributable to immunodeficiencies was considerably higher. Thus, all individuals with recurrent bacterial meningitis without an obvious history or clinical finding suggestive of an anatomical problem should undergo an immunological evaluation as outlined below.

Complement deficiencies. Deficiencies have been described for almost all known components and regulatory proteins of the complement system (53). Activation of the complement system can occur via three independent pathways, the classical, the alternative, and the mannan-binding lectin pathways, and results in the formation of the membrane attack complex consisting of the terminal complement components C5b, C6, C7, C8 and C9.

Complement deficiencies are generally associated with an increased risk of bacterial infections but have also been linked to autoimmune disorders, particularly systemic lupus erythematosus (204, 211). Complement plays a particularly important role in the defense against encapsulated bacteria including *N. meningitidis*, *Neisseria gonorrhoeae*, *S. pneumoniae*, and *H. influenzae* (53).

An outstanding review by Ross and Densen, encompassing 242 patients with complement deficiency, established that 25% of the patients reported in the literature at that point had acquired systemic infection with either *N. meningitidis* or *N. gonorrhoeae* (176). Interestingly, 39 of the 47 cases (83%) of invasive meningococcal disease (meningitis/sepsis) captured in that review were patients with terminal complement deficiency (C5 to C9), while only a small proportion were cases of C1 to C4 or complement factor I, H, or P deficiency.

Homozygous C2 deficiency is the most common form of complement deficiency and is estimated to occur with a frequency of about 1 in 10,000 individuals (176). The majority of C2-deficient individuals appear to be asymptomatic, while others develop collagen-vascular disease and experience increased susceptibility to infection (51, 176, 193). A literature review by Fasano et al. documented that *S. pneumoniae* (64%) and *H. influenzae* (20%) are the most com-

mon causative agents in invasive disease (meningitis/sepsis) in C2-deficient individuals, with *N. meningitidis* playing a relatively minor role (51).

We observed a very similar trend in the cases identified in the literature search (Table 2), consisting of 73 complement-deficient patients suffering from recurrent bacterial meningitis, with a total of 165 culture-proven episodes of meningitis. Of these, 57 (78%) patients (involving 114 episodes) had a deficiency of one of the terminal complement components (C5 to C9). In this group, every episode of culture-proven meningitis was caused by *N. meningitidis*. In contrast, in the remaining group of complement-deficient patients, comprising individuals with complement factor I, C2, C3, C3b, C4, and C4b deficiency, only 22% of the episodes were due to *N. meningitidis*, while the majority were caused by *S. pneumoniae* (76%).

Most individuals with terminal complement component deficiency (TCCD) captured in our review presented with their first episode of meningitis in late childhood or early adulthood (median age, 16 years) (Table 2), consistent with the findings of Platonov et al. (168). Despite the increased risk of systemic meningococcal infections, affected individuals generally develop milder disease, a phenomenon that is not fully understood. In the study reported by Platonov et al., none of the TCCD patients presenting with invasive meningococcal disease died, and only 39% had severe disease, in comparison with mortality rates of 8% and 61% of severe disease in a control group of individuals without complement deficiencies. Similar observations were reported by other authors (53, 175, 176).

X-linked agammaglobulinemia. X-linked agammaglobulinemia or Bruton's disease is a primary immunodeficiency caused by mutations in the Bruton tyrosine kinase gene, which is required for normal B-cell development and, consequently, the production of functional antibodies (61, 117).

A publication from the U.S. national X-linked agammaglobulinemia registry, which included 201 individuals, reported that as many as 25 patients (12%) experienced either encephalitis or meningitis (226). The leading causes of central nervous system infections in this group were enteroviruses (echovirus, coxsackievirus, and poliovirus), followed by *S. pneumoniae* and *Haemophilus influenzae* type b (Hib). However, in that report, there was no mention of cases of recurrent meningitis, suggesting that this is not a major feature of this condition. The literature search did, however, identify two reports of patients with X-linked agammaglobulinemia who experienced recurrent bacterial meningitis. The first case was a 5-year-old boy who had three recurrences of meningitis (no organism was specified) and was subsequently found to have very low immunoglobulin levels, low B-cell numbers, and atrophy of the lymphoid tissue (49), which was strongly suggestive of X-linked agammaglobulinemia, although no genetic confirmation was sought. The second case was an 8-month-old boy with two episodes of pneumococcal meningitis whose diagnosis was confirmed by genetic testing (104).

IgG subclass deficiency. IgG subclass-deficient individuals are at increased risk of invasive bacterial infections in general and infections with *S. pneumoniae* and *H. influenzae* in particular (57, 190). Affected individuals have been found to be especially prone to recurrent respiratory and sinopulmonary infections (57, 190).

Three reports identified in the literature search described

cases of recurrent meningitis, which were attributed to IgG subclass deficiency (56, 73, 153). In a case described by Harfi et al., of a 4-year-old boy with three episodes of proven pneumococcal meningitis, combined IgG2/IgG4 deficiency was the only predisposing factor that could be identified despite an exhaustive search (73). One other patient in this group was diagnosed with the same deficiency, while the remaining patient had IgG3 subclass deficiency. All culture-positive episodes of meningitis in these two patients had also been caused by *S. pneumoniae*.

IRAK-4 deficiency. Of particular interest in the category of immunodeficiencies was a patient with an IRAK-4 defect described by Medvedev et al., as that report demonstrates how much our understanding of immunology and molecular biology has evolved over the last few years, illuminating complex host-pathogen interactions (129). In brief, IRAK-4 is involved in the intracellular signal transduction pathway of Toll-like receptor 4, which is activated by ligating with lipopolysaccharide. Ultimately, this pathway leads to nuclear factor κ B (NF- κ B) translocation, which in turn results in increased levels of production of cytokines and the expression of costimulatory molecules (130).

The patient described in that report, by then a 21-year-old woman, had experienced 13 severe bacterial infections in the first 15 years of life, including two episodes of pneumococcal meningitis at 9 and 20 months of age, endophthalmitis with *N. meningitidis*, and several episodes of cellulitis due to *S. aureus*. In contrast to the severity and spectrum of bacterial diseases, it was of note that this patient did not experience significant problems with either viral or fungal infections.

Acquired Immunodeficiencies

HIV infection. Infection with HIV typically predisposes infected individuals to cryptococcal meningitis but also to mycobacterial and bacterial meningitis (84, 126, 134). Several studies have shown that both children as well as adults with HIV infection have a significantly increased risk of acquiring pneumococcal infections (17, 101, 149). Epidemiological data suggest that individuals with untreated HIV infection have a higher risk (>40-fold) of acquiring invasive pneumococcal disease than uninfected individuals (149). However, since the advent of highly active antiretroviral therapy, there has been a significant reduction in invasive pneumococcal disease in the HIV-positive population (77).

In an interesting study by Molyneux et al., which evaluated the effect of HIV infection on bacterial meningitis in a pediatric cohort in Malawi over a 3-year period, 64 episodes of recurrent meningitis were recorded (135). Strikingly, 68% of the recurrences of meningitis had occurred in HIV-positive children, representing only 34% of the study population. Based on their data, those authors estimated the risk of recurrence of meningitis in HIV-infected children compared to HIV-uninfected children to be around six times higher. In HIV-positive patients with culture-positive, recurrent meningitis, the most common causative agents in that study were *S. pneumoniae* ($n = 18$ [58%]) and *Salmonella* species ($n = 10$ [32%]) (E. Molyneux, personal communication). The proportion of meningitis cases caused by *S. pneumoniae* in HIV-infected children was significantly greater than that in the HIV-uninfected group.

Further support for the highly probable association between

recurrent pneumococcal meningitis and HIV infection comes from two other reports, each describing one HIV-infected individual with two and three episodes of culture-proven pneumococcal meningitis, respectively (1, 136). It should be noted however, that the patient described by the former group had previously also undergone splenectomy for refractory idiopathic thrombocytopenic purpura, which constitutes an additional risk factor for pneumococcal disease, as illustrated above.

Chronic Parameningeal Infections

Parameningeal infections, which primarily include sinusitis, otitis media, and mastoiditis, can result in central nervous system infections by continuous spread through bony layers and the periosteum of the skull and, to a lesser extent, via the hematogenous route.

The most common complication of paranasal sinusitis is orbital cellulitis, followed by intracranial infection (32, 221). A large study of 649 cases of acute or chronic sinusitis reported that 3.7% of the patients developed intracranial complications comprising frontal lobe abscess (46%), meningitis (29%), and subdural empyema (8%) (32). The most commonly implicated organisms included staphylococci, streptococci (group A streptococci and pneumococcus), *H. influenzae*, and anaerobic organisms.

Otitis media, in contrast, is far less commonly associated with intracranial complications. Kangsanarak et al., who conducted a retrospective analysis of 17,144 patients with acute or chronic suppurative otitis media, found that only 43 (0.24%) patients developed intracranial complications, consisting mainly of meningitis (51%) and brain abscess (42%) (88). In that study, the bacteria most commonly isolated from intracranial specimens were *Proteus mirabilis*, staphylococci, and *Pseudomonas aeruginosa*.

The literature search identified 15 cases in which the authors suggested that a chronic parameningeal focus had been the source of recurrent episodes of meningitis (11, 56, 78, 102, 124, 127, 161, 167, 169, 215). This group comprised 11 cases of chronic otitis media and/or mastoiditis, two cases of chronic sinusitis (sphenoidal and maxillary), and two cases of chronic osteomyelitis of the skull (Table 3). However, in the two cases of osteomyelitis, the causal relationship was somewhat doubtful. In a case described by Avasthi et al., there was clear evidence of simultaneous frontal sinusitis (11). The second case, a 38-year-old female patient, experienced two episodes each of bacterial meningitis and septicemia due to *S. pneumoniae* and subsequently underwent extensive immunological and radiological investigations (102). This revealed that the patient had congenital asplenia, a more likely predisposing factor for pneumococcal infection than the focus of mandibular osteitis identified in this case.

The most commonly isolated organisms in this group with parameningeal infections were *S. pneumoniae* (15 episodes) and *H. influenzae* (four episodes), while *Proteus vulgaris* was found in only one case. Additionally, there was the unusual case of a 43-year-old woman, described by Passeron et al., who developed four episodes of culture-confirmed *E. coli* meningitis secondary to sphenoidal sinusitis (161) (Fig. 1).

TABLE 3. Chronic infections and other conditions associated with recurrent bacterial meningitis^a

Condition	Total no. of cases	Median age at onset ^b (range)	Median age at diagnosis (range)	Organism(s) ^c isolated (no. of occasions ^d)	Reference(s)
Parameningeal infections					
Chronic sinusitis	2	42 yr	32 yr (21 yr–43 yr)	<i>E. coli</i> (4)	78, 161
Chronic otitis media/mastoiditis	11	19 yr (11 mo–46 yr)	29 yr (3 yr–47 yr)	<i>S. pneumoniae</i> (11), <i>H. influenzae</i> (4), <i>Proteus vulgaris</i> (1)	56, 78, 124, 127, 167, 169, 215
Chronic osteomyelitis	2	38 yr	27 yr (15 yr–39 yr)	<i>S. pneumoniae</i> (4)	11, 102
Maffuci's syndrome	1	2 yr	n.a.	<i>S. pneumoniae</i> (2)	202
Neurofibromatosis type 1	2	11 yr (4 yr–18 yr)	14 yr (8 yr–20 yr)	<i>S. pneumoniae</i> (1)	28, 65

^a Patients with more than one risk factor were recorded in all the relevant categories. All patients included had at least two episodes of meningitis (clinical features and results suggestive of bacterial meningitis), but the causative organism was not identified in all episodes. n.a., no data available.

^b Age at onset indicates age at the first episode of meningitis.

^c Organisms were identified by CSF culture, CSF antigen testing, or positive blood culture with CSF analysis suggestive of bacterial meningitis.

^d Number of separate occasions at which an organism was isolated; i.e., one patient may have had several episodes caused by different organisms.

POTENTIAL INDICATORS OF UNDERLYING CONDITIONS

Age at Onset

A number of underlying diseases are associated with a particular age distribution with regard to the first presentation, which may help reduce differential diagnoses and consequently aid in the planning of investigations.

There was no clear association with a particular age group in the group of patients with head injuries (age range at presentation, 8 months to 36 years), most likely due to the fact that head trauma may be sustained at any stage in life.

Presentation in childhood. Patients with lumbosacral lesions, including meningocele, meningomyelocele, and dermoid cysts with dermal sinus, almost universally presented in infancy (Table 1). As these abnormalities produce a direct connection between the spinal tract and the skin surface in the lower back region and as contact with fecal matter occurs on a regular basis in infants in diapers, they are predestined to infection with predominantly gram-negative organisms. In contrast, children with cranial, cervical, and thoracic dermal sinuses and/or dermoid cysts tended to present slightly later but generally still in early childhood.

All four patients with a neurenteric cyst presented with recurrent episodes of meningitis in childhood; one patient in this group developed meningitis with *S. aureus* at 7 days of age, an unusual pathogen in this age group, followed by three episodes of streptococcal meningitis over the first 16 months of his life (115).

The vast majority of individuals with Mondini dysplasia and

other forms of inner ear malformations with CSF leak experienced their first episode of meningitis in infancy or early childhood. The median age at the first episode of meningitis in this group was 3 years, with a range of 1 month to 23 years. None of the patients with Mondini dysplasia presented in adulthood. Only in three patients with inner ear malformations the initial episode of meningitis occurred in adulthood, compared with 39 cases (93%) in childhood (164, 165, 178).

In patients with cranial meningocele/meningoencephalocele, there was also a tendency to presentation in childhood (median age, 7 years), although this pattern was less clear, as almost half of the publications did not report the age at which the respective patient had experienced the first episode of meningitis. In the group of cases of congenital ethmoidal or petrosal skull base defects, all patients presented before the age of 5 years.

Patients with complement deficiencies almost universally experienced their first episode of meningitis during childhood or early adult life (Table 2). The notable exception was a patient with C4 deficiency, who developed the first episode of pneumococcal meningitis at the age of 51 years (124).

Presentation in adult life. The only conditions that were clearly associated with presentation in adulthood were from the category of chronic parameningeal infections (Table 3). None of the patients in the groups with chronic osteomyelitis and chronic sinusitis as an underlying diagnosis experienced their first episode of meningitis in childhood; only four patients

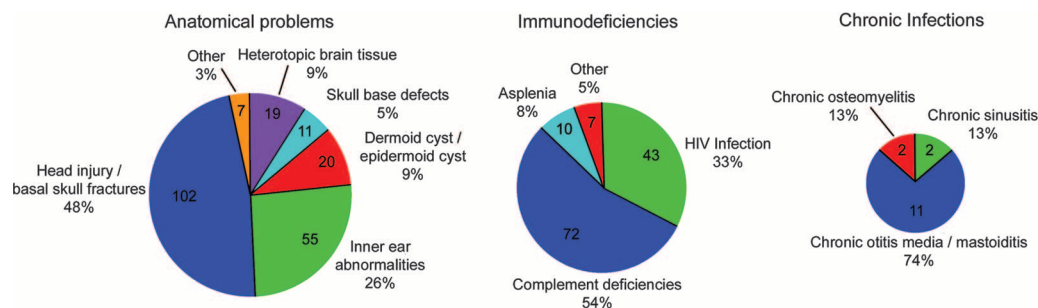


FIG. 1. Underlying conditions predisposing to recurrent bacterial meningitis in the cases identified in the literature search. The relative size of each pie chart is proportional to the frequency of each of the three major categories.

(36%) in the group with otitis media and/or mastoiditis as a predisposing condition experienced their initial episode of meningitis in childhood.

Microbiological Aspects

A variety of underlying conditions were found to be associated with a particular causative bacterial organism (Table 4). Thus, the repeated isolation of a particular bacterium can potentially point toward the underlying condition, which may consequently help in tailoring investigations more individually. This approach is less useful when the causative agent is *S. pneumoniae*.

***Streptococcus pneumoniae*.** Numerous conditions have been reported to be associated with an increased risk of pneumococcal disease, including hematologic disorders, immunodeficiencies, asplenia (congenital and iatrogenic), chronic renal failure, HIV infection, malnutrition, alcoholism, and head injuries (45, 112, 217). However, the vast majority of cases of invasive pneumococcal disease occur in seemingly healthy hosts. A large nationwide population-based study on invasive pneumococcal disease in children in Switzerland identified 393 cases over a 10-year period, 165 cases of which (42.0%) presented with meningitis (217). Interestingly, a predisposing condition was identified only in 28 cases (7.1%). A similar proportion (10%) was reported from a population-based study in the United States (112). In the former study, skull fractures were the most frequently recorded risk factor, accounting for 46% of the cases with predisposing factors. Ten children in that report experienced recurrent meningitis; an underlying pathology was identified only in two patients, namely, a history of basal skull fracture. Thus, a single episode of pneumococcal meningitis in a patient does not necessarily warrant further investigations unless there are other worrying features in the history or upon examination. In contrast, two or more episodes should certainly always prompt a full workup.

Our literature search revealed that in all conditions with abnormal CSF connection in a cranial location (head injury/basal skull fractures, congenital basal skull defects, meningoceles/meningoencephaloceles, and inner ear abnormalities), *S. pneumoniae* was the most frequently isolated organism, accounting for 179 (72%) of the 247 culture-positive episodes of meningitis in these groups. Among the category of immunodeficiencies, *S. pneumoniae* was the dominant causative organism in patients with agammaglobulinemia, IgG subclass deficiency, early complement deficiency (C2 to C4), asplenia, and HIV infection (Table 2).

***Neisseria meningitidis*.** Several abnormalities of the immune system have been found to predispose affected individuals to infections with *N. meningitidis*, including immunoglobulin deficiencies (25), IgG subclass deficiency (12), as well as most types of complement deficiencies (34, 47, 132, 147).

In one study assessing the prevalence of complement deficiencies in 125 individuals with previous meningococcal disease, the investigators found that a surprisingly high proportion (41%) of individuals in the subgroup with recurrent meningococcal infection had an underlying complement deficiency (147). A similar prevalence of 31% was reported in another study (132). However, there is evidence that the prevalence of complement deficiencies varies greatly among differ-

TABLE 4. Associations between causative bacterial organisms isolated in recurrent bacterial meningitis and underlying defects

Organism	Defects ^a
<i>S. pneumoniae</i>	Head injury/basal skull fracture Congenital basal skull defect Meningocele/meningoencephalocele Neurenteric cyst Inner ear dysplasia/Mondini dysplasia Asplenia XLA IgG subclass deficiency Early complement deficiency (C2–C4) HIV infection Chronic otitis media/mastoiditis
<i>N. meningitidis</i>	Head injury/basal skull fracture Congenital basal skull defect Meningocele/meningoencephalocele Inner ear dysplasia/Mondini dysplasia Complement deficiency (C2–C9)
<i>H. influenzae</i>	Head injury/basal skull fracture Congenital basal skull defect Neurenteric cyst Inner ear dysplasia/Mondini dysplasia Chronic otitis media/mastoiditis
<i>S. aureus</i>	Meningocele/meningoencephalocele Neurenteric cyst Dermoid/epidermoid cyst/dermal sinus
Gram-negative, enteric organisms (<i>E. coli</i> , <i>Klebsiella</i> spp., <i>Proteus</i> spp.)	Meningocele (lumbosacral) Dermoid/epidermoid cyst/dermal sinus Chronic parameningeal infections
<i>Salmonella</i> spp.	HIV infection

^a Boldface indicates conditions strongly associated with a particular organism(s).

ent populations, as demonstrated by a study of 47 unselected Danish patients with meningococcal disease, which failed to identify any individuals with this disorder (173).

The vast majority (92%) of episodes of recurrent meningitis captured in this review in which *N. meningitidis* was isolated occurred in patients with complement deficiency. Even more striking was the observation that all culture-positive episodes that had occurred in patients with TCCD (C5 to C9) were due to *N. meningitidis*. Although cases of meningococcal meningitis were also reported for a few patients with cranial CSF fistulas, this organism played only a relatively minor role in these groups (Tables 1 and 2).

***Haemophilus influenzae*.** As a result of the widespread introduction of Hib vaccines into vaccination programs in many industrialized countries, there has been a dramatic decline in invasive disease caused by *H. influenzae* over the last two decades (108, 123). *H. influenzae* was found to be the causative agent in a significant number (38 episodes) of culture-positive episodes of meningitis captured by our literature search, perhaps reflecting that our review extended beyond a period before the introduction of Hib vaccination programs.

Interestingly, *H. influenzae* was found in only two instances

in patients with immunodeficiency, both in HIV-infected patients. In contrast, *H. influenzae* was not infrequently isolated from patients with head injuries and basal skull fractures, congenital basal skull defects, and inner ear malformations (including Mondini dysplasia), accounting for 6%, 13%, and 13% of the total numbers of culture-positive episodes in these groups, respectively (Table 1). In the group of patients with neurenteric cysts, *H. influenzae* was the second most commonly isolated organism, responsible for 34% of the culture-positive episodes.

Staphylococcus aureus. *S. aureus* is a rare cause of bacterial meningitis. According to the U.S. Bacterial Meningitis Surveillance Study, less than 1% of cases of meningitis are caused by this bacterium (185). In a report of 40 patients with *S. aureus* meningitis, 80% had known predisposing CNS abnormalities, and all these patients had recently undergone neurosurgical procedures, most commonly involving ventriculoperitoneal shunts, a well-documented risk factor for staphylococcal meningitis (152, 186). In the remaining patients, prematurity was thought to be the main risk factor in three cases; one patient had a sacral meningocele in combination with an enteric cyst, while another two were attributable to dermal sinus tracts.

A similar pattern was reflected in the reports included in our review, bearing in mind that we excluded patients who experienced meningitis only after undergoing neurosurgery from the review. All episodes of recurrent meningitis associated with *S. aureus* occurred in connection with anatomical lesions, which included two cases of intranasal meningoencephaloceles (75, 196), cases with dermal sinus tracts (103, 115, 198), and a patient who was subsequently found to have a neurenteric cyst (70). Strikingly, *S. aureus* infection was not reported for any patient with immunodeficiency.

Gram-negative enteric organisms. Gram-negative enteric bacillary meningitis (GNEBM) is very unusual outside the newborn period unless it is acquired in a nosocomial setting. In a review of 2,708 cases of bacterial meningitis in a large pediatric unit over a 20-year period, only 98 (3.6%) were caused by an enteric organism (214). Only 27% of the cases occurred in patients older than 28 days of age. In a relatively large proportion (26%) of patients, an underlying condition was identified, comprising mainly surgical problems including neural tube defects and urinary tract anomalies.

We agree with other authors (218) that even a single episode of GNEBM, and undoubtedly recurrent episodes, should prompt a search for CSF fistulas and urinary tract malformations, which is supported not only by the findings of the above-cited study but also by several reports captured in this review. Recurrent GNEBM meningitis was reported predominantly for patients with lumbosacral lesions, including a patient with meningocele (*K. pneumoniae* and *P. mirabilis*) and patients with dermal sinuses (*E. coli* and *Klebsiella*). However, it should also be noted that *E. coli* was also the only causative organism identified in both cases of chronic sinusitis associated with recurrent meningitis, which should therefore be included in the list of differential diagnoses.

DIAGNOSTIC PATHWAYS

As an infrequently encountered condition, recurrent meningitis poses a considerable challenge to any clinician. In the

following section, we outline a diagnostic pathway to facilitate a structured approach to patients with recurrent bacterial meningitis. A suggested diagnostic algorithm is summarized as in Fig. 2.

In every case, a detailed history and examination should form the basis of a thorough assessment. If neither is suggestive of a particular underlying cause, first-line investigations should be initiated, which encompass tests that are accessible in most hospital settings, are minimally invasive, and do not expose the patient to any radiation risk. In contrast, many of the recommended second-line investigations may require referral to a more specialized center.

History

A history of head injury should not lead to the presumption that a basal skull fracture is necessarily the underlying cause. In a collection of 25 cases with recurrent bacterial meningitis reported by Lieb et al., a history of head injury was indeed recorded for the only two patients with skull fractures, but those authors noted that a similar history of traumatic events was obtained from patients in whom a congenital defect was ultimately found to be the cause (115). Regardless, it is essential to specifically ask about major traumatic events, including those that may have occurred several years prior to the first episode of meningitis and that the patient might not think are relevant. Equally, a history of otorrhea and rinorrhea should actively be sought, as a number of reports highlighted patients who were aware of a persistent nasal discharge for many years after the traumatic event but failed to attribute any significance to this (5, 69, 98).

Particularly in children, a history of potential hearing impairment or a delay in speech development should raise the suspicion of inner ear malformations. It is important not to assume that hearing impairment in children with recurrent meningitis is due simply to preceding episodes of meningitis, as illustrated above. A history of frequent or chronic middle ear infections and/or mastoiditis, potentially in association with previous mastoidectomy, may point toward a parameningeal focus as the source of recurrent meningitis.

Also, in children, a history of failure to thrive as well as unusual or frequent infections additionally affecting other systems, such as the skin or the respiratory tract, should raise the suspicion of an underlying immunodeficiency. In this context, it is particularly important to elicit a thorough family history, which may reveal other family members with recurrent or severe infections, as well as early deaths of family members due to infections.

Examination

A thorough physical examination is vitally important, as illustrated by several cases of patients with dermal sinus tracts, which had been missed on previous admissions, that were detected by examination alone (10, 103). Particular attention should be given to the examination of the head and spine, as this may reveal fistulous tracts or cutaneous stigmata suggestive of occult spinal defects. Additionally, anosmia and hyposmia should be screened for, as these have been reported to occur in up to 41% of cases with traumatic CSF fistula (109).

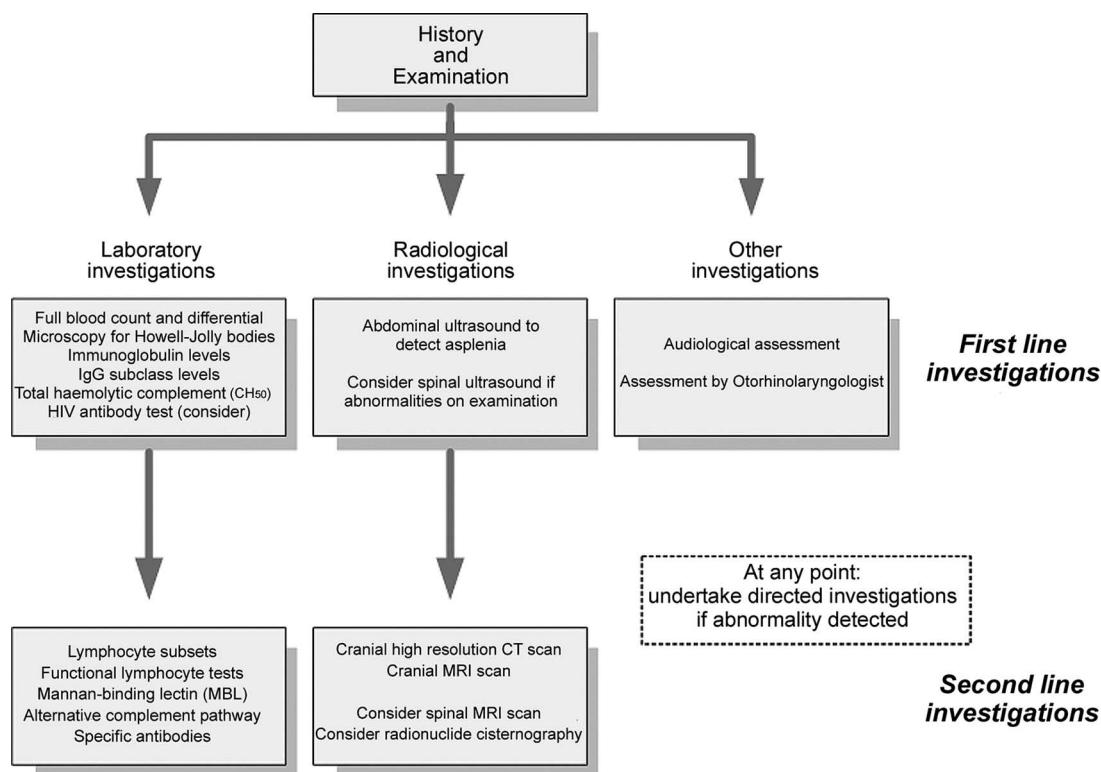


FIG. 2. Diagnostic algorithm for the investigation of recurrent bacterial meningitis.

In many types of immunodeficiency, the physical examination may be completely unremarkable, unless previous infections, such as skin abscesses, have left residual scarring. Lymphadenopathy, splenomegaly, parotid enlargement, and oropharyngeal candidiasis can be suggestive of HIV infection. The absence of palpable lymph nodes, particularly in sites corresponding to areas of active infection, and tonsillar hypotrophy may be an indication of XLA.

CSF rhinorrhea most commonly occurs unilaterally. Typically, there is clear nasal discharge, which frequently increases with a Valsalva maneuver and when the patient leans forward (98, 100).

CSF otorrhea may occur with inner ear malformations and temporal bone defects, which can be congenital, iatrogenic, or traumatic in origin or, less commonly, due to osteolytic erosion as a result of chronic ear infections. It is of note that these patients may simultaneously report rhinorrhea, as the CSF often drains from the middle ear via the Eustachian tube into the nasopharynx. As discussed above, a bulging tympanic membrane with a visible fluid level should not be dismissed simply as serous otitis media (or “glue ear”), as this may be the only sign of an otogenic CSF fistula.

Examination frequently provides a vital clue in identifying patients with temporal bone defects. In a report of 92 cases, CSF fluid flow could be demonstrated in 80 patients (87%) using provocative maneuvers (182).

Various methods to ascertain whether fluid draining from the nose or ear represents CSF or merely secretions have been proposed. Multireagent strip testing for glucose and protein has been found to be unreliable. Several authors described

cases of CSF leaks with false-negative results upon glucose testing, and the proportion of false-positive results has been reported to be between 45% and 75% (23, 151, 159).

Recently, testing for β_2 -transferrin has become more commonly used in the clinical setting (144, 197, 219). This test is reported to have high specificity, as this protein is found only in CSF, vitreous humor, and inner ear perilymph. Contamination of samples with mucus, blood, or saliva has little influence on the accuracy of the assay.

Patients with recurrent meningitis should also undergo a formal assessment by an otolaryngologist as well as an audiological assessment to detect subtle or previously unrecognized (particularly in young children) hearing deficits, which may be associated with inner ear malformations. A thorough examination of the nasal passages, ideally by means of fiberoptic endoscopy, may reveal the presence of heterotopic brain tissue or meningoceles or even, albeit indirectly, the site of a CSF leak, as outlined in a number of reports (14, 64, 75, 90).

Investigations

Laboratory investigations. As part of first-line investigations (Fig. 2), we recommend a full blood count in combination with a differential and microscopy to detect Howell-Jolly bodies (which may suggest asplenia) as well as lymphopenia or neutropenia. Abnormalities in immunoglobulin levels (IgA, IgM, IgG, and IgE) may point to a range of immunodeficiencies including selective IgA deficiency and common variable immunodeficiency. In

the latter, the defect may be in the T-cell or, more commonly, the B-cell population.

IgG subclass deficiency is confirmed by detecting persistently low IgG subclass levels, which may affect one or more IgG subtype antibodies (IgG1 to IgG4). Assessment of the total serum hemolytic complement (CH_{50}) will detect abnormalities of the classical complement pathway (C1 to C9) and should be followed with assays for individual complement components if found to be abnormal. Also, depending on the presence of potential risk factors and local epidemiology, an HIV antibody test should be considered at this stage in connection with appropriate pretest counseling.

Determining levels of specific antibodies against particular antigens, such as tetanus and diphtheria toxoid antibodies, provides a reflection of the ability of the humoral immune system to generate an appropriate response. Further, more detailed immunological investigations, including functional tests, will generally need to be undertaken in a more specialized setting after liaison with an experienced immunologist. Although a full description of these investigations is beyond the scope of this article, this may include lymphocyte subsets, T-cell proliferation responses to phytohemagglutinin, B-cell proliferation responses to pokeweed mitogen, neutrophil function tests, and assessment of the alternative complement (AH_{50}) and mannan-binding lectin pathways.

Radiological investigations. A number of radiological techniques can be used to identify CSF fistulas, including cranial CT scans, CT cisternography, radionuclide cisternography, and specially weighted cranial magnetic resonance imaging (MRI) scans. The need for sensitive imaging techniques in this setting was previously emphasized by Carrol et al., who reported the case of a 9-year-old boy with recurrent meningitis whose ethmoidal fracture was missed on an initial cranial CT scan (24). The importance of this is also highlighted in a cohort of children with recurrent meningitis and anatomical abnormalities in which radiological investigations had to be repeated for a number of individuals to pinpoint the underlying defect (115).

CT scans in general, and high-resolution CT (HRCT) scans in particular, produce the best definition of bony structures and are considered to be the method of choice for the investigation of basal skull defects by many authors (118, 128). An added advantage, in contrast to other techniques discussed below, is that HRCT is a noninvasive technique. The sensitivity of HRCT in detecting CSF fistulas was previously reported to be between 50% and 100% (41, 118). In addition, cranial HRCT scanning is considered by most authors to be the method of choice to investigate potential inner ear malformations (93, 95, 164, 165, 215).

CT cisternography requires the injection of a contrast medium via lumbar puncture, which is associated with a range of potential side effects such as headache, nausea, and temporary perceptual abnormalities (85). CT cisternography relies on the demonstration of contrast medium passing through the fistulous defect or the detection of its presence in the paranasal sinuses. The reported sensitivity ranges from 55% to 76%, although the performance was previously noted to decrease significantly in inactive or intermittent CSF leaks (30, 125).

MRI scans offer the best definition of brain parenchyma and soft tissue, which is particularly important in the context of encephaloceles (64). A sensitivity of 100% was reported for

MRI in the evaluation of CSF leaks in one study of 24 patients (85). In this report, the site of the CSF leak identified by MRI was later verified by surgery in all cases. The capabilities of flow-sensitive MRI, based on slow-flow magnetic resonance pulsing sequences or diffusion-weighted MRI, as an additional valuable diagnostic tool to identify CSF leaks has also been emphasized (113).

Radionuclide cisternography has proven to be helpful in a number of cases where CT and MRI scans failed to identify the CSF leak. One example is a patient with a petrosal bone abnormality who experienced three episodes of meningitis in whom radionuclide (Tc-99m-DTPA [diethylene triamine pentaacetate]) cisternography was the only investigation that revealed the CSF leak (222). However, there are two inherent drawbacks to radionuclide cisternography: firstly, the isotope has to be injected into the intrathecal space, and secondly, this technique is unable to pinpoint the exact anatomical location of the defect. Nevertheless, the placement of nasal or aural pledgets does provide some localizing ability. The advantage of this technique lies in the fact that it permits repeated examinations over more than 48 h, thus facilitating the detection of intermittent CSF leaks (55, 113).

In cases of CSF leaks originating from the spinal canal, ultrasound imaging and MRI have been proven to be the most useful investigations. In the hands of an experienced ultrasonographer, spina bifida and dermal sinuses can usually readily be detected on ultrasound (99, 119). Spinal MRI offers high levels of definition and can show the relationship between spinal lesions and adjacent anatomical structures, providing invaluable information for preoperative planning (99, 155).

In conclusion, there is no single imaging modality that will invariably identify an underlying CSF fistula in all instances. Therefore, depending on the suspected site or defect, appropriate investigations should be chosen in close liaison with an experienced radiologist.

LIMITATIONS

We reviewed only the English language literature and limited our search to the last 20 years. The literature consisted predominantly of single case reports or small case series and may therefore not reflect the true prevalence of each condition in patients with recurrent meningitis in general. Also, the overall picture may be skewed by the relatively high proportion of reports in neurosurgical and otolaryngological journals as well as a large number of reports on complement deficiency in the 1990s. A number of reports were excluded because they contained insufficient details to categorize the patients with reasonable certainty despite our efforts to obtain further details from the respective authors.

ACKNOWLEDGMENTS

We thank the following individuals for kindly providing additional data related to their original manuscripts: Elizabeth Molyneux, Rupa Vedantam, Leslie Michaels, Paul Potter, Ann Orren, and Layla Al Shamsan. We are also grateful to Anastasia Pantazidou for providing assistance with the literature search and helpful comments on the manuscript.

The work of M.T. was supported by an international research scholarship from the University of Melbourne and a fellowship award from the European Society of Pediatric Infectious Diseases.

We report no competing interests.

REFERENCES

1. **Adriani, K. S., D. van de Beek, M. C. Brouwer, L. Spanjaard, and J. de Gans.** 2007. Community-acquired recurrent bacterial meningitis in adults. *Clin. Infect. Dis.* **45**:e46–e51.
2. **Alrabeeah, A., D. A. Gillis, M. Giacomantonio, and H. Lau.** 1988. Neurenteric cysts—a spectrum. *J. Pediatr. Surg.* **23**:752–754.
3. **Al-Shamsan, L., N. Weir, V. Palkar, M. Al-Hatani, and B. Al-Esam.** 2006. A 7-year old boy with recurrent attacks of *Streptococcus pneumoniae* meningitis. *Ann. Saudi Med.* **26**:155, 163–1655.
4. **al Zamil, F.** 1999. Recurrent bacterial meningitis: report of two cases from Riyadh, Saudi Arabia. *Ann. Trop. Paediatr.* **19**:395–399.
5. **Amin, M. U., and A. Ghaffar.** 2006. Delayed appearance of posttraumatic cerebrospinal fluid fistula. *J. Coll. Physicians Surg. Pak.* **16**:378–380.
6. **Andiran, N., T. Coskun, E. Ozaydin, and G. Secmeer.** 1998. Recurrent meningitis associated with congenital paravertebral dermal sinus tract. *Turk. J. Pediatr.* **40**:121–125.
7. **Angibaud, G., G. Durand, A. Rascol, and M. Clanet.** 1992. Recurrent *Neisseria meningitidis* meningitis associated with homozygote complement C7 fraction deficiency. *Rev. Neurol.* **148**:237–238.
8. **Ansari, S., D. B. Carron, and M. J. Smith.** 1994. Recurrent late onset post-traumatic meningitis. *J. Pak. Med. Assoc.* **44**:193–194.
9. **Arai, Y., Y. Yamauchi, T. Tsuji, S. Fukasaku, R. Yokota, and T. Kudo.** 1992. Spinal neurenteric cyst. Report of two cases and review of forty-one cases reported in Japan. *Spine* **17**:1421–1424.
10. **Au, H.** 2006. Recurrent meningitis in a child due to an occult spinal lesion. *CMAJ* **175**:737.
11. **Avasthi, G., A. Parti, S. N. Gupta, and R. Goel.** 1991. Frontal bone osteomyelitis causing recurrent meningitis. *J. Assoc. Physicians India* **39**:409–410.
12. **Bass, J. L., R. Nuss, K. A. Mehta, P. Morganeli, and L. Bennett.** 1983. Recurrent meningococemia associated with IgG2-subclass deficiency. *N. Engl. J. Med.* **309**:430.
13. **Beaumont, G. D., and M. R. Sage.** 1990. Encephalocele involving the petrous bone. *Neuroradiology* **32**:533–534.
14. **Bektas, D., R. Caylan, O. Bahadir, and R. Caylan.** 2007. Occult anterior skull base defect without rhinorrhea as a cause of recurrent meningitis. *Surg. Neurol.* **68**:50–52.
15. **Ben-Shoshan, M., A. DeRowe, G. Grisaru-Soen, L. Ben-Sira, and E. Miller.** 2007. Recurrent meningitis and cerebrospinal fluid leak—two sides of the same vestibulocochlear defect: report of three cases. *Eur. J. Pediatr.* **166**:269–272.
16. **Bernstein, J. M., J. T. Roland, and M. S. Persky.** 1997. Sphenoid cranial base defects in siblings presenting with cerebrospinal fluid leak. *Skull Base Surg.* **7**:193–197.
17. **Bernstein, L. J., B. Z. Krieger, B. Novick, M. J. Sicklick, and A. Rubinstein.** 1985. Bacterial infection in the acquired immunodeficiency syndrome of children. *Pediatr. Infect. Dis.* **4**:472–475.
18. **Bhide, S. S.** 2006. Recurrent meningitis in a family with C3 deficiency. *Indian Pediatr.* **43**:269–270.
19. **Bingen, E., H. Cave, Y. Aujard, N. Lambert-Zechovsky, P. Desjardins, J. Elion, and E. Denamur.** 1993. Molecular analysis of multiply recurrent meningitis due to *Escherichia coli* K1 in an infant. *Clin. Infect. Dis.* **16**:82–85.
20. **Boseley, M. E., and T. A. Tami.** 2004. Endoscopic management of anterior skull base encephaloceles. *Ann. Otol. Rhinol. Laryngol.* **113**:30–33.
21. **Brodie, H. A., and T. C. Thompson.** 1997. Management of complications from 820 temporal bone fractures. *Am. J. Otol.* **18**:188–197.
22. **Byrne, J. V., J. A. Britten, and G. Kaar.** 1992. Chronic post-traumatic erosion of the skull base. *Neuroradiology* **34**:528–531.
23. **Calcaterra, T. C.** 1980. Extracranial surgical repair of cerebrospinal rhinorrhea. *Ann. Otol. Rhinol. Laryngol.* **89**:108–116.
24. **Carrol, E. D., A. H. Latif, S. A. Misbah, T. J. Flood, M. Abinun, J. E. Clark, R. E. Pugh, and A. J. Cant.** 2001. Lesson of the week. Recurrent bacterial meningitis: the need for sensitive imaging. *BMJ* **323**:501–503.
25. **Castagliuolo, P. P., R. Nisini, I. Quinti, A. Fattorossi, and R. D'Amelio.** 1986. Immunoglobulin deficiencies and meningococcal disease. *Ann. Allergy* **57**:68–70.
26. **Ceccarelli, M., M. Balestri, C. Fontani, L. Lupetti, and C. Ughi.** 1989. Recurrent meningitis: a case report. *Eur. J. Pediatr.* **148**:646–647.
27. **Cesko, I., J. Hajdu, T. Toth, T. Marton, C. Papp, and Z. Papp.** 1997. Ivemark syndrome with asplenia in siblings. *J. Pediatr.* **130**:822–824.
28. **Chapman, P. H., H. D. Curtin, and M. J. Cunningham.** 2000. An unusual pterygopalatine meningocele associated with neurofibromatosis type 1. Case report. *J. Neurosurg.* **93**:480–483.
29. **Chaudhuri, A. K., N. Banatvala, D. A. Caugant, R. J. Fallon, and K. Whaley.** 1994. Phenotypically similar clones of serogroup B *Neisseria meningitidis* causing recurrent meningitis in a patient with total C5 deficiency. *J. Infect.* **29**:236–238.
30. **Chow, J. M., D. Goodman, and M. F. Mafee.** 1989. Evaluation of CSF rhinorrhea by computerized tomography with metrizamide. *Otolaryngol. Head Neck Surg.* **100**:99–105.
31. **Claros, P., C. Guirado, A. Claros, A. Claros, Jr., A. Claveria, and P. Wienberg.** 1993. Association of spontaneous anterior fossa CSF rhinorrhea and congenital perilymphatic fistula in a patient with recurrent meningitis. *Int. J. Pediatr. Otorhinolaryngol.* **27**:65–71.
32. **Clayman, G. L., G. L. Adams, D. R. Paugh, and C. F. Koopmann, Jr.** 1991. Intracranial complications of paranasal sinusitis: a combined institutional review. *Laryngoscope* **101**:234–239.
33. **Cooper, J. F., and D. W. Gregory.** 1989. Recurrent meningitis in a black man. *South. Med. J.* **82**:235–237.
34. **D'Amelio, R., A. Agostoni, R. Biselli, M. Brai, G. Caruso, M. Cicardi, A. Corvetta, L. Fontana, G. Misiano, R. Perricone, et al.** 1992. Complement deficiency and antibody profile in survivors of meningococcal meningitis due to common serogroups in Italy. *Scand. J. Immunol.* **35**:589–595.
35. **Daum, R. S., D. W. Scheifele, V. P. Syriopoulou, D. Averill, and A. L. Smith.** 1978. Ventricular involvement in experimental *Hemophilus influenzae* meningitis. *J. Pediatr.* **93**:927–930.
36. **Davachi, F., H. Bregu, and G. Lito.** 2002. Recurrent *Streptococcus pneumoniae* meningitis. *J. Trop. Pediatr.* **48**:249–251.
37. **Davidson, R. N., and R. A. Wall.** 2001. Prevention and management of infections in patients without a spleen. *Clin. Microbiol. Infect.* **7**:657–660.
38. **Delgado-Cervino, E., G. Fontan, and M. Lopez-Trascasa.** 2005. C5 complement deficiency in a Spanish family. Molecular characterization of the double mutation responsible for the defect. *Mol. Immunol.* **42**:105–111.
39. **De Wals, P., F. Tairou, M. I. Van Allen, S. H. Uh, R. B. Lowry, B. Sibbald, J. A. Evans, M. C. Van den Hof, P. Zimmer, M. Crowley, B. Fernandez, N. S. Lee, and T. Niyonsenga.** 2007. Reduction in neural-tube defects after folic acid fortification in Canada. *N. Engl. J. Med.* **357**:135–142.
40. **Dhar, M. C., S. Chaudhuri, K. Basu, S. Pain, T. J. Sau, and K. Mitra.** 2001. Recurrent pyogenic meningitis in a case of transthemoid encephalocele. *J. Assoc. Physicians India* **49**:767–768.
41. **Dietrich, U., A. Feldges, K. Sievers, and W. Kocks.** 1993. Localization of frontobasal traumatic cerebrospinal fluid fistulas. Comparison of radiologic and surgical findings. *Zentralbl. Neurochir.* **54**:24–31. (In German.)
42. **Drummond, D. S., A. L. de Jong, C. Giannoni, M. Sulek, and E. M. Friedman.** 1999. Recurrent meningitis in the pediatric patient—the otolaryngologist's role. *Int. J. Pediatr. Otorhinolaryngol.* **48**:199–208.
43. **Dunne, D. W., and V. Quagliarello.** 1993. Group B streptococcal meningitis in adults. *Medicine (Baltimore)* **72**:1–10.
44. **Durand, M. L., S. B. Calderwood, D. J. Weber, S. I. Miller, F. S. Southwick, V. S. Caviness, Jr., and M. N. Swartz.** 1993. Acute bacterial meningitis in adults. A review of 493 episodes. *N. Engl. J. Med.* **328**:21–28.
45. **Einarsdottir, H. M., H. Erlendsdottir, K. G. Kristinsson, and M. Gottfredsson.** 2005. Nationwide study of recurrent invasive pneumococcal infections in a population with a low prevalence of human immunodeficiency virus infection. *Clin. Microbiol. Infect.* **11**:744–749.
46. **Eljamel, M. S., and P. M. Foy.** 1990. Acute traumatic CSF fistulae: the risk of intracranial infection. *Br. J. Neurosurg.* **4**:381–385.
47. **Ellison, R. T., III, P. F. Kohler, J. G. Curd, F. N. Judson, and L. B. Reller.** 1983. Prevalence of congenital or acquired complement deficiency in patients with sporadic meningococcal disease. *N. Engl. J. Med.* **308**:913–916.
48. **Erol, F. S., C. Topsakal, M. F. Ozveren, I. Akdemir, and B. Cobanoglu.** 2004. Meningocele with cervical dermoid sinus tract presenting with congenital mirror movement and recurrent meningitis. *Yonsei Med. J.* **45**:568–572.
49. **Ersoy, F., O. Sanal, I. Tezcan, and A. I. Berkel.** 1990. X-linked agammaglobulinemia: clinical and immunologic evaluation of six patients. *Turk. J. Pediatr.* **32**:241–247.
50. **Farhoudi, A., N. Bazargan, Z. Pourpak, and M. Mahmoudi.** 2003. Two related cases of primary complement deficiency. *Immunol. Investig.* **32**:313–321.
51. **Fasano, M. B., A. Hamosh, and J. A. Winkelstein.** 1990. Recurrent systemic bacterial infections in homozygous C2 deficiency. *Pediatr. Allergy Immunol.* **1**:46–49.
52. **Fernandez-Sola, J., R. Monforte, E. Ponz, F. Lozano, M. Plana, J. Montoliu, A. Torras, and M. Ingelmo.** 1990. Persistent low C3 levels associated with meningococcal meningitis and membranoproliferative glomerulonephritis. *Am. J. Nephrol.* **10**:426–430.
53. **Figuerola, J. E., and P. Densen.** 1991. Infectious diseases associated with complement deficiencies. *Clin. Microbiol. Rev.* **4**:359–395.
54. **Fijen, C. A., E. J. Kuijper, A. J. Hannema, A. G. Sjöholm, and J. P. van Putten.** 1989. Complement deficiencies in patients over ten years old with meningococcal disease due to uncommon serogroups. *Lancet* **ii**:585–588.
55. **Flynn, B. M., S. P. Butler, R. J. Quinn, A. F. McLaughlin, G. J. Bautovich, and J. G. Morris.** 1987. Radionuclide cisternography in the diagnosis and management of cerebrospinal fluid leaks: the test of choice. *Med. J. Aust.* **146**:82–84.
56. **Ford, H., and J. Wright.** 1996. Recurrent bacterial meningitis in adults: a case series. *J. Infect.* **33**:131–133.
57. **Freijd, A., V. A. Oxelius, and B. Rynnel-Dagoo.** 1985. A prospective study

- demonstrating an association between plasma IgG2 concentrations and susceptibility to otitis media in children. *Scand. J. Infect. Dis.* **17**:115–120.
58. **Friedman, J. A., M. J. Ebersold, and L. M. Quast.** 2000. Persistent post-traumatic cerebrospinal fluid leakage. *Neurosurg. Focus* **9**:e1.
 59. **Funayama, C. A., F. M. De Turcato, R. Moura-Ribeiro, G. M. Rocha, J. M. Pina Neto, and M. V. Moura-Ribeiro.** 1995. Recurrent meningitis in a case of congenital anterior sacral meningocele and agenesis of sacral and coccygeal vertebrae. *Arq. Neuropsiquiatr.* **53**:799–801.
 60. **Garg, P., V. Rathi, S. K. Bhargava, and A. Aggarwal.** 2005. CSF rhinorrhea and recurrent meningitis caused by transethmoidal meningoencephaloceles. *Indian Pediatr.* **42**:1033–1036.
 61. **Gaspar, H. B., T. Lester, R. J. Levinsky, and C. Kinnon.** 1998. Bruton's tyrosine kinase expression and activity in X-linked agammaglobulinemia (XLA): the use of protein analysis as a diagnostic indicator of XLA. *Clin. Exp. Immunol.* **111**:334–338.
 62. **Gilbert, B., C. Menetrey, V. Belin, P. Brosset, L. de Lumley, and A. Fisher.** 2002. Familial isolated congenital asplenia: a rare, frequently hereditary dominant condition, often detected too late as a cause of overwhelming pneumococcal sepsis. Report of a new case and review of 31 others. *Eur. J. Pediatr.* **161**:368–372.
 63. **Gill, D. G., and M. Kara.** 1991. Septicaemia and adrenal haemorrhage in congenital asplenia. *Arch. Dis. Child.* **66**:1366–1367.
 64. **Giunta, G., and I. Piazza.** 1991. Recurrent bacterial meningitis occurring five years after closed head injury and caused by an intranasal post-traumatic meningo-encephalocele. *Postgrad. Med. J.* **67**:377–379.
 65. **Goel, D., S. Jha, R. K. Gupta, and M. Hussain.** 2001. Recurrent pyogenic meningitis: an unusual presentation in a case of neurofibromatosis-1. *Pediatr. Neurosurg.* **34**:242–243.
 66. **Golding-Wood, D. G., H. O. Williams, and G. B. Brookes.** 1991. Tegmental dehiscence and brain herniation into the middle ear cleft. *J. Laryngol. Otol.* **105**:477–480.
 67. **Gonzalez-Rubio, C., A. Ferreira-Cerdan, I. M. Ponce, J. Arpa, G. Fontan, and M. Lopez-Trascasa.** 2001. Complement factor I deficiency associated with recurrent meningitis coinciding with menstruation. *Arch. Neurol.* **58**:1923–1928.
 68. **Gordon, S. B., M. Chabonda, A. L. Walsh, C. J. Whitty, M. A. Gordon, C. E. Machili, C. F. Gilks, M. J. Boeree, S. Kampondeni, R. C. Read, and M. E. Molyneux.** 2002. Pneumococcal disease in HIV-infected Malawian adults: acute mortality and long-term survival. *AIDS* **16**:1409–1417.
 69. **Graham, J. C., P. J. Moss, and M. W. McKendrick.** 1996. Group B streptococcal meningitis associated with cerebrospinal fluid rhinorrhoea. *J. Infect.* **32**:69–70.
 70. **Gumerlock, M. K., L. E. Spollen, M. J. Nelson, R. C. Bishop, and M. S. Cooperstock.** 1991. Cervical neurenteric fistula causing recurrent meningitis in Klippel-Feil sequence: case report and literature review. *Pediatr. Infect. Dis. J.* **10**:532–535.
 71. **Haga, Y., H. Cho, S. Shinoda, and T. Masuzawa.** 2003. Recurrent meningitis associated with complete Currarino triad in an adult—case report. *Neurol. Med. Chir. (Tokyo)* **43**:505–508.
 72. **Handa, R., A. K. Sood, R. K. Yadav, R. K. Dhamija, and S. Prakash.** 1994. Recurrent bacterial meningitis. *J. Assoc. Physicians India* **42**:165–166.
 73. **Harfi, H. A., M. Abdul-Jabbar, and E. Rabe.** 1989. Recurrent meningitis associated with congenital deafness and IgG subclass immunodeficiency: report of a case. *Ann. Saudi Med.* **9**:494–496.
 74. **Harsha, W. J., D. Varon, and P. B. Pritchard III.** 2002. Recurrent bacterial meningitis: the search for a cause. *J. S. C. Med. Assoc.* **98**:193–195.
 75. **Hasegawa, T., N. Sugeno, Y. Shiga, A. Takeda, H. Karibe, T. Tominaga, and Y. Itoyama.** 2005. Transethmoidal intranasal meningoencephalocele in an adult with recurrent meningitis. *J. Clin. Neurosci.* **12**:702–704.
 76. **Hayashi, N., M. Kino, U. Nobori, M. Yanagida, K. Ushiro, T. Kumazawa, and Y. Kobayashi.** 1989. Recurrent bacterial meningitis. Secondary to malformation of the inner ear. *Clin. Pediatr. (Philadelphia)* **28**:139–141.
 77. **Heffernan, R. T., N. L. Barrett, K. M. Gallagher, J. L. Hadler, L. H. Harrison, A. L. Reingold, K. Khoshnood, T. R. Holford, and A. Schuchat.** 2005. Declining incidence of invasive *Streptococcus pneumoniae* infections among persons with AIDS in an era of highly active antiretroviral therapy, 1995–2000. *J. Infect. Dis.* **191**:2038–2045.
 78. **Hosoglu, S., C. Ayaz, A. Ceviz, B. Cumen, M. F. Geyik, and O. F. Kokoglu.** 1997. Recurrent bacterial meningitis: a 6-year experience in adult patients. *J. Infect.* **35**:55–62.
 79. **Hristea, A., M. Chiotan, M. Tudose, and F. Mihalcu.** 1997. The combined value of chemoprophylaxis and pneumococcal vaccine in the prevention of recurrent pneumococcal meningitis. *J. Infect.* **34**:265–267.
 80. **Hsu, S. T., J. Yu-Yun Lee, S. C. Chao, M. Y. Hsieh, and C. C. Huang.** 1998. Congenital occipital dermal sinus with intracranial dermoid cyst complicated by recurrent *Escherichia coli* meningitis. *Br. J. Dermatol.* **139**:922–924.
 81. **Hultcrantz, M., H. Bergstedt, and L. Mendel.** 1996. Congenital malformation of the inner ear and recurrent meningitis. A case report. *J. Otorhinolaryngol. Relat. Spec.* **58**:333–337.
 82. **Izquierdo, J. M., and L. M. Gil-Carcedo.** 1988. Recurrent meningitis and transethmoidal intranasal meningoencephalocele. *Dev. Med. Child Neurol.* **30**:248–251.
 83. **Jaatinen, T., M. Lahti, O. Ruuskanen, R. Kinon, L. Truedsson, R. Lahesmaa, and M. L. Lokki.** 2003. Total C4B deficiency due to gene deletion and gene conversion in a patient with severe infections. *Clin. Diagn. Lab. Immunol.* **10**:195–201.
 84. **Jarvis, J. N., and T. S. Harrison.** 2007. HIV-associated cryptococcal meningitis. *AIDS* **21**:2119–2129.
 85. **Johnson, D. B., P. Brennan, J. Toland, and A. J. O'Dwyer.** 1996. Magnetic resonance imaging in the evaluation of cerebrospinal fluid fistulae. *Clin. Radiol.* **51**:837–841.
 86. **Jonsson, G., L. Truedsson, G. Sturfelt, V. A. Oxelius, J. H. Braconier, and A. G. Sjöholm.** 2005. Hereditary C2 deficiency in Sweden: frequent occurrence of invasive infection, atherosclerosis, and rheumatic disease. *Medicine (Baltimore)* **84**:23–34.
 87. **Kaddour, H. S.** 1993. Recurrent meningitis due to a congenital fistula of the stapedial footplate. *J. Laryngol. Otol.* **107**:931–932.
 88. **Kangsanarak, J., S. Fooanant, K. Ruckphaopunt, N. Navacharoen, and S. Teotrakul.** 1993. Extracranial and intracranial complications of suppurative otitis media. Report of 102 cases. *J. Laryngol. Otol.* **107**:999–1004.
 89. **Kavaliotis, J., A. Tsiaousi, D. Papavasiliou, and A. Kansouzidou.** 1994. Non-typhoid *Salmonella* meningitis. *Scand. J. Infect. Dis.* **26**:403–405.
 90. **Kawamura, S., H. Hadeishi, N. Sasaguchi, A. Suzuki, and N. Yasui.** 1997. Penetrating head injury caused by chopstick—case report. *Neurol. Med. Chir. (Tokyo)* **37**:332–335.
 91. **Kelleher, R. J., J. A. Murray, and P. D. Welsby.** 1989. Recurrent meningitis associated with meningioma of the mastoid cavity. *J. Laryngol. Otol.* **103**:99–100.
 92. **Kendirli, T., B. Unay, F. Tosun, B. Hacıhamdioglu, R. Akin, Y. Ozkaptan, and E. Gokcay.** 2006. Recurrent *Streptococcus pneumoniae* meningitis in a child with traumatic anterior cranial base defect. *Pediatr. Int.* **48**:91–93.
 93. **Kimitsuki, T., M. Inamitsu, S. Komune, and S. Komiyama.** 1999. Congenital malformation of the inner ear associated with recurrent meningitis. *Eur. Arch. Otorhinolaryngol.* **256**(Suppl. 1):S11–S14.
 94. **Kirkpatrick, B., D. S. Reeves, and A. P. MacGowan.** 1994. A review of the clinical presentation, laboratory features, antimicrobial therapy and outcome of 77 episodes of pneumococcal meningitis occurring in children and adults. *J. Infect.* **29**:171–182.
 95. **Kitazawa, K., M. Matsumoto, M. Senda, A. Honda, N. Morimoto, N. Kawashiro, and S. Imashuku.** 2004. Mondini dysplasia and recurrent bacterial meningitis in a girl with relapsing Langerhans cell histiocytosis. *Pediatr. Blood Cancer* **43**:85–87.
 96. **Kline, M. W.** 1989. Review of recurrent bacterial meningitis. *Pediatr. Infect. Dis. J.* **8**:630–634.
 97. **Knox, R., M. Pratt, A. J. Garvin, and B. White.** 1989. Heterotopic lingual brain in the newborn. *Arch. Otolaryngol. Head Neck Surg.* **115**:630–632.
 98. **Kohrmann, M., P. D. Schellinger, A. Wetter, and S. Hahnel.** 2007. Nasal meningoencephalocele, an unusual cause for recurrent meningitis. Case report and review of the literature. *J. Neurol.* **254**:259–260.
 99. **Korsvik, H. E., and M. S. Keller.** 1992. Sonography of occult dysraphism in neonates and infants with MR imaging correlation. *Radiographics* **12**:297–306; discussion, 307–308.
 100. **Koso-Thomas, A. K., and E. H. Harley.** 1995. Traumatic cerebrospinal fluid fistula presenting as recurrent meningitis. *Otolaryngol. Head Neck Surg.* **112**:469–472.
 101. **Kourtis, A. P., P. Bansil, S. F. Posner, C. Johnson, and D. J. Jamieson.** 2007. Trends in hospitalizations of HIV-infected children and adolescents in the United States: analysis of data from the 1994–2003 Nationwide Inpatient Sample. *Pediatrics* **120**:e236–243.
 102. **Kragsbjerg, P., and H. Rydman.** 2001. Recurrent pneumococcal bacteraemia and meningitis in an asplenic adult with possible unusual focus. *Scand. J. Infect. Dis.* **33**:706–708.
 103. **Kriss, T. C., V. M. Kriss, and B. C. Warf.** 1995. Recurrent meningitis: the search for the dermoid or epidermoid tumor. *Pediatr. Infect. Dis. J.* **14**:697–700.
 104. **Kumar, S., and B. Bennuri.** 1998. Index of suspicion. Case 2. Diagnosis: recurrent bacterial meningitis. *Pediatr. Rev.* **19**:137–139.
 105. **Kunze, W., L. Muller, M. Kilian, M. U. Schuhmann, L. Baumann, and W. Handrick.** 2007. Recurrent posttraumatic meningitis due to nontypable *Haemophilus influenzae*: case report and review of the literature. *Infection* **36**:74–77.
 106. **Kuroda, Y., M. Abe, F. Nagumo, R. Neshige, R. Kakigi, and K. Tabuchi.** 1991. Neuroepithelial cyst presenting as recurrent aseptic meningitis. *Neurology* **41**:1834–1835.
 107. **Lackmann, G. M., and U. Tollner.** 1993. Aneurysmal cyst of the petrosal bone. *Arch. Dis. Child.* **69**:241–242.
 108. **Ladhani, S., M. P. Slack, M. Heys, J. White, and M. E. Ramsay.** 17 October 2007, posting date. Fall in *Haemophilus influenzae* serotype b (Hib) disease following implementation of a booster campaign. *Arch. Dis. Child.* doi:10.1136/adc.2007.126888.
 109. **Laun, A.** 1982. Traumatic cerebrospinal fluid fistulas in the anterior and middle cranial fossae. *Acta Neurochir. (Wien)* **60**:215–222.

110. Layadi, F., N. Louhab, M. Lmejjati, K. Aniba, A. Ait Elqadi, and S. Ait Benali. 2006. Cerebellar dermoid cyst with occipital dermal sinus. Report of two pediatric cases. *Pediatr. Neurosurg.* **42**:387–390.
111. Levin, P., and S. P. Antin. 1964. Intraspinous neurenteric cyst in the cervical area. *Neurology* **14**:727–730.
112. Levine, O. S., M. Farley, L. H. Harrison, L. Lefkowitz, A. McGeer, and B. Schwartz. 1999. Risk factors for invasive pneumococcal disease in children: a population-based case-control study in North America. *Pediatrics* **103**:E28.
113. Levy, L. M., A. J. Gulya, S. W. Davis, D. LeBihan, S. S. Rajan, and D. Schellinger. 1995. Flow-sensitive magnetic resonance imaging in the evaluation of cerebrospinal fluid leaks. *Am. J. Otol.* **16**:591–596.
114. Lewin, W. 1954. Cerebrospinal fluid rhinorrhoea in closed head injuries. *Br. J. Surg.* **42**:1–18.
115. Lieb, G., J. Krauss, H. Collmann, L. Schrod, and N. Sorensen. 1996. Recurrent bacterial meningitis. *Eur. J. Pediatr.* **155**:26–30.
116. Lim, K. W., and H. K. Cheng. 1989. Bacterial meningitis—a four year survey in a paediatrics unit. *Ann. Acad. Med. Singapore* **18**:649–654.
117. Lindvall, J. M., K. E. Blomberg, J. Valiaho, L. Vargas, J. E. Heinson, A. Berglof, A. J. Mohamed, B. F. Nore, M. Vihinen, and C. I. Smith. 2005. Bruton's tyrosine kinase: cell biology, sequence conservation, mutation spectrum, siRNA modifications, and expression profiling. *Immunol. Rev.* **203**:200–215.
118. Lloyd, M. N., P. M. Kimber, and E. H. Burrows. 1994. Post-traumatic cerebrospinal fluid rhinorrhoea: modern high-definition computed tomography is all that is required for the effective demonstration of the site of leakage. *Clin. Radiol.* **49**:100–103.
119. Lowe, L. H., A. J. Johaneck, and C. W. Moore. 2007. Sonography of the neonatal spine: part 2, spinal disorders. *Am. J. Roentgenol.* **188**:739–744.
120. Lu, M. Y., P. I. Lee, C. Y. Lee, and C. J. Hsu. 1996. Mondini dysplasia with recurrent meningitis. *Zhonghua Min Guo Xiao Er Ke Yi Xue Hui Za Zhi* **37**:289–291.
121. Luntz, M., T. Balkany, A. V. Hodges, and F. F. Telischi. 1997. Cochlear implants in children with congenital inner ear malformations. *Arch. Otolaryngol. Head Neck Surg.* **123**:974–977.
122. MacRae, D. L., and R. R. Ruby. 1990. Recurrent meningitis secondary to perilymph fistula in young children. *J. Otolaryngol.* **19**:222–225.
123. Madore, D. V. 1996. Impact of immunization on Haemophilus influenzae type b disease. *Infect. Agents Dis.* **5**:8–20.
124. Maitra, S., and S. K. Ghosh. 1989. Recurrent pyogenic meningitis—a retrospective study. *Q. J. Med.* **73**:919–929.
125. Manefte, C., P. Cellier, D. Sobel, C. Prevost, and A. Bonafe. 1982. Cerebrospinal fluid rhinorrhea: evaluation with metrizamide cisternography. *Am. J. Roentgenol.* **138**:471–476.
126. Marra, C. M. 1999. Bacterial and fungal brain infections in AIDS. *Semin. Neurol.* **19**:177–184.
127. McGregor, D. H., R. Cherian, J. J. Kepes, and M. Kepes. 1994. Case reports: heterotopic brain tissue of middle ear associated with cholesteatoma. *Am. J. Med. Sci.* **308**:180–183.
128. Meco, C., and G. Oberascher. 2004. Comprehensive algorithm for skull base dural lesion and cerebrospinal fluid fistula diagnosis. *Laryngoscope* **114**:991–999.
129. Medvedev, A. E., A. Lentschat, D. B. Kuhns, J. C. Blanco, C. Salkowski, S. Zhang, M. Arditi, J. I. Gallin, and S. N. Vogel. 2003. Distinct mutations in IRAK-4 confer hyporesponsiveness to lipopolysaccharide and interleukin-1 in a patient with recurrent bacterial infections. *J. Exp. Med.* **198**:521–531.
130. Medzhitov, R., P. Preston-Hurlburt, E. Kopp, A. Stadlen, C. Chen, S. Ghosh, and C. A. Janeway, Jr. 1998. MyD88 is an adaptor protein in the hToll/IL-1 receptor family signaling pathways. *Mol. Cell* **2**:253–258.
131. Menezes, A. H., and T. C. Ryken. 1995. Craniocervical intradural neurenteric cysts. *Pediatr. Neurosurg.* **22**:88–95.
132. Merino, J., V. Rodriguez-Valverde, J. A. Lamelas, J. L. Riestra, and B. Casanueva. 1983. Prevalence of deficits of complement components in patients with recurrent meningococcal infections. *J. Infect. Dis.* **148**:331.
133. Michel, R. S., E. DeFlora, J. Jefferies, and L. G. Donowitz. 1992. Recurrent meningitis in a child with inner ear dysplasia. *Pediatr. Infect. Dis. J.* **11**:336–338.
134. Michelet, C., C. Arvieux, C. Francois, J. M. Besnier, J. P. Rogez, J. P. Breux, F. Souala, C. Allavena, F. Raffi, M. Garre, and F. Cartier. 1998. Opportunistic infections occurring during highly active antiretroviral treatment. *AIDS* **12**:1815–1822.
135. Molyneux, E. M., M. Tembo, K. Kayira, L. Bwanaisa, J. Mwenyechanya, A. Njobvu, H. Forsyth, S. Rogerson, A. L. Walsh, and M. E. Molyneux. 2003. The effect of HIV infection on paediatric bacterial meningitis in Blantyre, Malawi. *Arch. Dis. Child.* **88**:1112–1118.
136. Morand, P. C., V. Veuille, C. Poyart, E. Abachin, G. Quesne, B. Dupont, P. Berche, and J. P. Viard. 2003. Recurrent pneumococcal meningitis in a splenectomised HIV-infected patient. *Ann. Clin. Microbiol. Antimicrob.* **2**:9.
137. Mostafa, B. E., L. El Fiky, and A. Khafagy. 2005. Occult otologic fistulas as a cause of recurrent meningitis. *Rev. Laryngol. Otol. Rhinol. (Bordeaux)* **126**:25–28.
138. Motojima, T., K. Fujii, N. Ishiwada, J. Takanashi, O. Numata, Y. Uchino, I. Yamakami, and Y. Kohno. 2005. Recurrent meningitis associated with a petrous apex cephalocele. *J. Child Neurol.* **20**:168–170.
139. Mra, Z., J. A. McCormick, and C. P. Poje. 1997. Persistent cerebrospinal fluid otorrhea: a case of Munchausen's syndrome by proxy. *Int. J. Pediatr. Otorhinolaryngol.* **41**:59–63.
140. Mulcahy, M. M., S. O. McMenomey, J. M. Talbot, and J. B. Delashaw, Jr. 1997. Congenital encephalocele of the medial skull base. *Laryngoscope* **107**:910–914.
141. Muranjan, M. N., B. A. Bharucha, M. V. Kirtane, and C. T. Deshmukh. 1999. Mondini dysplasia of the inner ear with CSF leak—a rare cause of recurrent meningitis. *Indian Pediatr.* **36**:401–406.
142. Mylanus, E. A., L. J. Rotteveel, and R. L. Leeuw. 2004. Congenital malformation of the inner ear and pediatric cochlear implantation. *Otol. Neurotol.* **25**:308–317.
143. Nakhla, I. A., A. Mansour, Y. Sultan, and W. Frenck, Jr. 2002. Recurrent meningitis in a seven-year-old girl. *Pediatr. Infect. Dis. J.* **21**:1081, 1093–1094.
144. Nandapalan, V., I. D. Watson, and A. C. Swift. 1996. Beta-2-transferrin and cerebrospinal fluid rhinorrhoea. *Clin. Otolaryngol. Allied Sci.* **21**:259–264.
145. Nazarian, G. K., S. S. Gebarski, and J. K. Niparko. 1990. Cranial lymphangiomatosis causing CSF otorrhea and recurrent meningitis: CT features. *J. Comput. Assist. Tomogr.* **14**:121–123.
146. Ng, M., D. R. Maceri, M. M. Levy, and D. M. Crockett. 1998. Extracranial repair of pediatric traumatic cerebrospinal fluid rhinorrhea. *Arch. Otolaryngol. Head Neck Surg.* **124**:1125–1130.
147. Nielsen, H. E., C. Koch, P. Magnussen, and I. Lind. 1989. Complement deficiencies in selected groups of patients with meningococcal disease. *Scand. J. Infect. Dis.* **21**:389–396.
148. Nishizaka, H., T. Horiuchi, Z. B. Zhu, Y. Fukumori, K. Nagasawa, K. Hayashi, R. Krumdieck, C. G. Cobbs, M. Higuchi, S. Yasunaga, Y. Niho, and J. E. Volanakis. 1996. Molecular bases for inherited human complement component C6 deficiency in two unrelated individuals. *J. Immunol.* **156**:2309–2315.
149. Nuorti, J. P., J. C. Butler, L. Gelling, J. L. Kool, A. L. Reingold, and D. J. Vugia. 2000. Epidemiologic relation between HIV and invasive pneumococcal disease in San Francisco County, California. *Ann. Intern. Med.* **132**:182–190.
150. Nurnberger, W., H. Pietsch, R. Seger, T. Bufon, and V. Wahn. 1989. Familial deficiency of the seventh component of complement associated with recurrent meningococcal infections. *Eur. J. Pediatr.* **148**:758–760.
151. Oberascher, G. 1988. Cerebrospinal fluid otorrhea—new trends in diagnosis. *Am. J. Otol.* **9**:102–108.
152. Odio, C., G. H. McCracken, Jr., and J. D. Nelson. 1984. CSF shunt infections in pediatrics. A seven-year experience. *Am. J. Dis. Child* **138**:1103–1108.
153. Ohga, S., K. Okada, T. Asahi, K. Ueda, Y. Sakiyama, and S. Matsumoto. 1995. Recurrent pneumococcal meningitis in a patient with transient IgG subclass deficiency. *Acta Paediatr. Jpn.* **37**:196–200.
154. Ohlms, L. A., M. S. Edwards, E. O. Mason, M. Igarashi, B. R. Alford, and R. J. Smith. 1990. Recurrent meningitis and Mondini dysplasia. *Arch. Otolaryngol. Head Neck Surg.* **116**:608–612.
155. O'Neill, P., and J. P. Stack. 1990. Magnetic resonance imaging in the pre-operative assessment of closed spinal dysraphism in children. *Pediatr. Neurosurg.* **16**:240–246.
156. Ouma, J. R. 2002. Recurrent meningitis due to unrecognised skull fracture. *S. Afr. Med. J.* **92**:778–779.
157. Pahari, A., C. Pal, and H. Lyall. 2004. Recurrent meningitis in association with common variable immune deficiency. *Indian Pediatr.* **41**:1152–1154.
158. Paparella, M. M. 1980. Mondini's deafness. A review of histopathology. *Ann. Otol. Rhinol. Laryngol. Suppl.* **89**:1–10.
159. Pappas, D. G., Jr., P. E. Hammerschlag, and M. Hammerschlag. 1993. Cerebrospinal fluid rhinorrhea and recurrent meningitis. *Clin. Infect. Dis.* **17**:364–368.
160. Park, A. H., B. Kou, A. Hotaling, B. Azar-Kia, J. Leonetti, and B. Papsin. 2000. Clinical course of pediatric congenital inner ear malformations. *Laryngoscope* **110**:1715–1719.
161. Passeron, A., L. Capron, and G. Grateau. 2004. Recurrent Escherichia coli meningitis associated with aspergillar sphenoidal sinusitis. *Scand. J. Infect. Dis.* **36**:492–493.
162. Patel, R. B., J. A. Kwartler, R. M. Hodosh, and S. Baredes. 2000. Spontaneous cerebrospinal fluid leakage and middle ear encephalocele in seven patients. *Ear Nose Throat J.* **79**:372–373, 376–378.
163. Phanthumchinda, K., S. Shuangshoti, and S. Khaoroptham. 1989. Post-traumatic arachnoid cyst at the cranial base with unusual manifestations. *Surg. Neurol.* **32**:64–67.
164. Phelps, P. D., A. King, and L. Michaels. 1994. Cochlear dysplasia and meningitis. *Am. J. Otol.* **15**:551–557.
165. Phelps, P. D., D. Proops, S. Sellars, J. Evans, and L. Michaels. 1993. Congenital cerebrospinal fluid fistula through the inner ear and meningitis. *J. Laryngol. Otol.* **107**:492–495.

166. **Piek, J.** 2000. Surgical treatment of complex traumatic frontobasal lesions: personal experience in 74 patients. *Neurosurg. Focus* **9**:e2.
167. **Pikis, A., J. Kavaliotis, J. Tsikoulas, P. Andrianopoulos, D. Venzon, and S. Manios.** 1996. Long-term sequelae of pneumococcal meningitis in children. *Clin. Pediatr. (Philadelphia)* **35**:72-78.
168. **Platonov, A. E., V. B. Beloborodov, and I. V. Vershinina.** 1993. Meningococcal disease in patients with late complement component deficiency: studies in the U.S.S.R. *Medicine (Baltimore)* **72**:374-392.
169. **Polimili, G., N. Gyrousis, A. Galis, P. Karagianni, K. Babili, D. Triantafylidou, and S. Kastanakis.** 2004. Diagnostic approach to patient with recurrence of bacterial meningitis. *Int. J. Antimicrob. Agents* **24**:S172.
170. **Potter, P. C., C. E. Frasca, W. J. van der Sande, R. C. Cooper, Y. Patel, and A. Orren.** 1990. Prophylaxis against *Neisseria meningitidis* infections and antibody responses in patients with deficiency of the sixth component of complement. *J. Infect. Dis.* **161**:932-937.
171. **Quiney, R. E., D. B. Mitchell, B. Djazeri, and J. N. Evans.** 1989. Recurrent meningitis in children due to inner ear abnormalities. *J. Laryngol. Otol.* **103**:473-480.
172. **Rajeshwari, K., and A. Sharma.** 1995. Remediable recurrent meningitis. *Indian Pediatr.* **32**:491-496.
173. **Rasmussen, J. M., I. Brandslund, B. Teisner, H. Isager, S. E. Svehag, L. Maarup, L. Willumsen, J. O. Ronne-Rasmussen, H. Permin, P. L. Andersen, et al.** 1987. Screening for complement deficiencies in unselected patients with meningitis. *Clin. Exp. Immunol.* **68**:437-445.
174. **Rosa, D. D., A. C. Pasqualotto, M. de Quadros, and S. H. Prezzi.** 2004. Deficiency of the eighth component of complement associated with recurrent meningococcal meningitis—case report and literature review. *Braz. J. Infect. Dis.* **8**:328-330.
175. **Rosen, M. S., B. Lorber, and A. R. Myers.** 1988. Chronic meningococcal meningitis. An association with C5 deficiency. *Arch. Intern. Med.* **148**:1441-1442.
176. **Ross, S. C., and P. Densen.** 1984. Complement deficiency states and infection: epidemiology, pathogenesis and consequences of neisserial and other infections in an immune deficiency. *Medicine (Baltimore)* **63**:243-273.
177. **Rupa, V., A. Job, and V. Rajshekhar.** 2001. Adult onset spontaneous CSF otorrhea with oval window fistula and recurrent meningitis: MRI findings. *Otolaryngol. Head Neck Surg.* **124**:344-346.
178. **Rupa, V., V. Rajshekhar, and D. J. Weider.** 2000. Syndrome of recurrent meningitis due to congenital perilymph fistula with two different clinical presentations. *Int. J. Pediatr. Otorhinolaryngol.* **54**:173-177.
179. **Russell, T., and B. H. Cummins.** 1984. Cerebrospinal fluid rhinorrhea 34 years after trauma: a case report and review of the literature. *Neurosurgery* **15**:705-706.
180. **Sanal, O., M. Loos, F. Ersoy, G. Kanra, G. Secmeer, and I. Tezcan.** 1992. Complement component deficiencies and infection: C5, C8 and C3 deficiencies in three families. *Eur. J. Pediatr.* **151**:676-679.
181. **Sarmiento, R., F. M. Wilson, and R. Khatib.** 1993. Group B streptococcal meningitis in adults: case report and review of the literature. *Scand. J. Infect. Dis.* **25**:1-6.
182. **Savva, A., M. J. Taylor, and C. W. Beatty.** 2003. Management of cerebrospinal fluid leaks involving the temporal bone: report on 92 patients. *Laryngoscope* **113**:50-56.
183. **Schick, B., W. Draf, G. Kahle, R. Weber, and T. Wallenfang.** 1997. Occult malformations of the skull base. *Arch. Otolaryngol. Head Neck Surg.* **123**:77-80.
184. **Schick, B., R. Weber, G. Kahle, W. Draf, and G. M. Lackmann.** 1997. Late manifestations of traumatic lesions of the anterior skull base. *Skull Base Surg.* **7**:77-83.
185. **Schlech, W. F., III, J. I. Ward, J. D. Band, A. Hightower, D. W. Fraser, and C. V. Broome.** 1985. Bacterial meningitis in the United States, 1978 through 1981. The National Bacterial Meningitis Surveillance Study. *JAMA* **253**:1749-1754.
186. **Schoenbaum, S. C., P. Gardner, and J. Shillito.** 1975. Infections of cerebrospinal fluid shunts: epidemiology, clinical manifestations, and therapy. *J. Infect. Dis.* **131**:543-552.
187. **Schuknecht, H. F.** 1980. Mondini dysplasia; a clinical and pathological study. *Ann. Otol. Rhinol. Laryngol. Suppl.* **89**:1-23.
188. **Schwartz, J. F., and J. D. Balentine.** 1978. Recurrent meningitis due to an intracranial epidermoid. *Neurology* **28**:124-129.
189. **Selby, C. D., and P. J. Toghiani.** 1989. Meningitis after splenectomy. *J. R. Soc. Med.* **82**:206-209.
190. **Shackelford, P. G., S. H. Polmar, J. L. Mayus, W. L. Johnson, J. M. Corry, and M. H. Nahm.** 1986. Spectrum of IgG2 subclass deficiency in children with recurrent infections: prospective study. *J. Pediatr.* **108**:647-653.
191. **Shaw, G. M., N. G. Jensvold, C. R. Wasserman, and E. J. Lammer.** 1994. Epidemiologic characteristics of phenotypically distinct neural tube defects among 0.7 million California births, 1983-1987. *Teratology* **49**:143-149.
192. **Shaw, G. M., D. Schaffer, E. M. Velie, K. Morland, and J. A. Harris.** 1995. Periconceptual vitamin use, dietary folate, and the occurrence of neural tube defects. *Epidemiology* **6**:219-226.
193. **Sheikh, J., J. F. Bastian, and N. W. Wilson.** 1994. Recurrent bacterial meningitis in a 22-month-old boy. *Ann. Allergy* **73**:101-104.
194. **Shelanski, S., and B. Zweiman.** 1988. Recurrent meningitis. *Ann. Allergy* **60**:306-307, 343-345.
195. **Sigurdardottir, B., O. M. Bjornsson, K. E. Jonsdottir, H. Erlendsdottir, and S. Gudmundsson.** 1997. Acute bacterial meningitis in adults. A 20-year overview. *Arch. Intern. Med.* **157**:425-430.
196. **Silbert, P., M. McComish, T. Chakeva, and I. Surveyor.** 1992. Intranasal meningoencephalocele causing recurrent meningitis in a 25-year-old Caucasian man. *Med. J. Aust.* **156**:141-142.
197. **Skedros, D. G., S. P. Cass, B. E. Hirsch, and R. H. Kelly.** 1993. Beta-2 transferrin assay in clinical management of cerebral spinal fluid and perilymphatic fluid leaks. *J. Otolaryngol.* **22**:341-344.
198. **Slavin, K. A., and S. Kohl.** 2000. Eleven-month-old with recurrent bacterial and aseptic meningitis. *Pediatr. Infect. Dis. J.* **19**:175, 178-179.
199. **Smith, J. R.** 1960. Accessory enteric formations: a classification and nomenclature. *Arch. Dis. Child.* **35**:87-89.
200. **Spencer, S. E., I. A. D'Cruz, and M. F. Tenholder.** 1997. Recurrent meningitis and severe hypoxemia in a 77-year-old man. *Chest* **112**:1120-1123.
201. **Sponsel, C., and J. W. Park.** 1994. Recurrent pneumococcal meningitis. Search for occult skull fracture. *Postgrad. Med.* **95**:109-110, 197.
202. **Stenger, R. D., J. A. Assaf, M. R. Gaab, E. Werner, H. Wiersbitzky, S. Wiersbitzky, and P. Muller.** 1998. Maffucci's syndrome as cause of chronic liquorrhea. *Pediatr. Hematol. Oncol.* **15**:179-185.
203. **Stevenson, D. S., D. W. Proops, and P. D. Phelps.** 1993. Severe cochlear dysplasia causing recurrent meningitis: a surgical lesson. *J. Laryngol. Otol.* **107**:726-729.
204. **Sullivan, K. E.** 1998. Complement deficiency and autoimmunity. *Curr. Opin. Pediatr.* **10**:600-606.
205. **Talamonti, G., R. A. Fontana, P. P. Versari, F. Villa, G. A. D'Aliberti, P. Car, and M. Collice.** 1995. Delayed complications of ethmoid fractures: a "growing fracture" phenomenon. *Acta Neurochir. (Wien)* **137**:164-173.
206. **Tekkok, I. H., S. S. Baeesa, M. J. Higgins, and E. C. Ventureyra.** 1996. Abscedation of posterior fossa dermoid cysts. *Childs Nerv. Syst.* **12**:318-322.
207. **Tender, G. C., S. Kutz, D. Awasthi, and P. Rigby.** 2003. Vascularized temporalis muscle flap for the treatment of otorrhea. *Technical note. J. Neurosurg.* **98**:1128-1132.
208. **Teo, D. T., T. Y. Tan, S. P. Eng, and Y. M. Chan.** 2004. Spontaneous cerebrospinal fluid otorrhea via oval window: an obscure cause of recurrent meningitis. *J. Laryngol. Otol.* **118**:717-720.
209. **Tom, L. W., L. Bilaniuk, R. A. Roa, and W. P. Potsic.** 1992. Recurrent meningitis and a congenital perilymph fistula. *Ear Nose Throat J.* **71**:287-290.
210. **Totan, M.** 2002. Recurrent pneumococcal meningitis in homozygous C3 deficiency. *Indian J. Pediatr.* **69**:625-626.
211. **Truedsson, L., A. A. Bengtsson, and G. Sturfelt.** 2007. Complement deficiencies and systemic lupus erythematosus. *Autoimmunity* **40**:560-566.
212. **Tullu, M. S., S. S. Khanna, J. R. Kamat, and M. V. Kirtane.** 2004. Mondini dysplasia and pyogenic meningitis. *Indian J. Pediatr.* **71**:655-657.
213. **Tyagi, I., R. Syal, and A. Goyal.** 2005. Cerebrospinal fluid otorrhoea due to inner-ear malformations: clinical presentation and new perspectives in management. *J. Laryngol. Otol.* **119**:714-718.
214. **Unhanand, M., M. M. Mustafa, G. H. McCracken, Jr., and J. D. Nelson.** 1993. Gram-negative enteric bacillary meningitis: a twenty-one-year experience. *J. Pediatr.* **122**:15-21.
215. **Valmari, P., and A. Palva.** 1986. Recurrent meningitis due to pneumococci and non-typable *Haemophilus influenzae* in a child with a Mondini malformation. *Infection* **14**:36-37.
216. **van de Beek, D., J. de Gans, L. Spanjaard, M. Weisfelt, J. B. Reitsma, and M. Vermeulen.** 2004. Clinical features and prognostic factors in adults with bacterial meningitis. *N. Engl. J. Med.* **351**:1849-1859.
217. **Venet, I., K. Schopfer, K. Muhlemann, et al.** 1998. Paediatric, invasive pneumococcal disease in Switzerland, 1985-1994. *Int. J. Epidemiol.* **27**:1101-1104.
218. **Vieira, T., S. C. Eppes, and G. Magram.** 1996. Recurrent *E. coli* meningitis associated with an intracranial dermoid cyst. *Clin. Pediatr. (Philadelphia)* **35**:32-33.
219. **Warnecke, A., T. Averbeck, U. Wurster, M. Harmening, T. Lenarz, and T. Stover.** 2004. Diagnostic relevance of beta2-transferrin for the detection of cerebrospinal fluid fistulas. *Arch. Otolaryngol. Head Neck Surg.* **130**:1178-1184.
220. **Weber, B. P., W. Dillo, B. Dietrich, I. Maneke, B. Bertram, and T. Lenarz.** 1998. Pediatric cochlear implantation in cochlear malformations. *Am. J. Otol.* **19**:747-753.
221. **Weiss, A., D. Friendly, K. Eglin, M. Chang, and B. Gold.** 1983. Bacterial periorbital and orbital cellulitis in childhood. *Ophthalmology* **90**:195-203.
222. **Wen, H. Y., M. L. Chou, K. L. Lin, P. F. Kao, and J. F. Chen.** 2001. Recurrence of pneumococcal meningitis due to primary spontaneous cerebrospinal fluid fistulas. *Chang Gung Med. J.* **24**:724-728.
223. **Whitehouse, D. P., J. R. Bowen, and S. P. Sahi.** 1993. Recurrent bacterial meningitis and impaired host defences. *J. R. Army Med. Corps* **139**:14-16.
224. **Whittet, H. B., S. Barker, P. Anslow, and S. Leighton.** 1990. Heterotopic

- brain tissue: a rare cause of adult recurrent meningitis. *J. Laryngol. Otol.* **104**:328–330.
225. **Williams, A. E., and W. F. Blakemore.** 1990. Pathogenesis of meningitis caused by *Streptococcus suis* type 2. *J. Infect. Dis.* **162**:474–481.
226. **Winkelstein, J. A., M. C. Marino, H. M. Lederman, S. M. Jones, K. Sullivan, A. W. Burks, M. E. Conley, C. Cunningham-Rundles, and H. D. Ochs.** 2006. X-linked agammaglobulinemia: report on a United States registry of 201 patients. *Medicine (Baltimore)* **85**:193–202.
227. **Yano, K., T. Kuroda, Y. Tanabe, A. Takao, and N. Sakai.** 1997. Three-dimensional computed tomography imaging of a frontal skull base fracture. *Neurol. Med. Chir. (Tokyo)* **37**:838–840.
228. **Yasargil, M. G., C. D. Abernathy, and A. C. Sarioglu.** 1989. Microneurosurgical treatment of intracranial dermoid and epidermoid tumors. *Neurosurgery* **24**:561–567.
229. **Zoppi, M., M. Weiss, U. E. Nydegger, T. Hess, and P. J. Spath.** 1990. Recurrent meningitis in a patient with congenital deficiency of the C9 component of complement. First case of C9 deficiency in Europe. *Arch. Intern. Med.* **150**:2395–2399.

AUTHOR'S CORRECTION

Epidemiology, Etiology, Pathogenesis, and Diagnosis of Recurrent Bacterial Meningitis

Marc Tebruegge and Nigel Curtis

Department of Paediatrics, The University of Melbourne, Parkville, Australia; Infectious Diseases Unit, Department of General Medicine, Royal Children's Hospital Melbourne, Parkville, Australia; and Murdoch Children's Research Institute, Parkville, Australia

Volume 21, no. 3, p. 519–537, 2008. Page 530, column 1, lines 14–15: “In a report of 40 patients with *S. aureus* meningitis” should read “In a report of 40 patients with *S. aureus* meningitis (64a).”

Page 534: The following reference was inadvertently omitted.

64a. **Givner, L. B., and S. L. Kaplan.** 1993. Meningitis due to *Staphylococcus aureus* in children. *Clin. Infect. Dis.* **16**:766–771.