



Epidermal Th22 and Tc17 Cells Form a Localized Disease Memory in Clinically Healed Psoriasis

This information is current as of August 4, 2022.

Stanley Cheuk, Maria Wikén, Lennart Blomqvist, Susanne Nylén, Toomas Talme, Mona Ståhle and Liv Eidsmo

J Immunol 2014; 192:3111-3120; Prepublished online 7 March 2014;

doi: 10.4049/jimmunol.1302313

<http://www.jimmunol.org/content/192/7/3111>

Supplementary Material <http://www.jimmunol.org/content/suppl/2014/03/07/jimmunol.1302313.DCSupplemental>

References This article **cites 44 articles**, 8 of which you can access for free at: <http://www.jimmunol.org/content/192/7/3111.full#ref-list-1>

Why *The JI*? Submit online.

- **Rapid Reviews! 30 days*** from submission to initial decision
- **No Triage!** Every submission reviewed by practicing scientists
- **Fast Publication!** 4 weeks from acceptance to publication

**average*

Subscription Information about subscribing to *The Journal of Immunology* is online at: <http://jimmunol.org/subscription>

Permissions Submit copyright permission requests at: <http://www.aai.org/About/Publications/JI/copyright.html>

Author Choice Freely available online through *The Journal of Immunology* [Author Choice option](#)

Email Alerts Receive free email-alerts when new articles cite this article. Sign up at: <http://jimmunol.org/alerts>

Epidermal Th22 and Tc17 Cells Form a Localized Disease Memory in Clinically Healed Psoriasis

Stanley Cheuk,* Maria Wikén,* Lennart Blomqvist,[†] Susanne Nylén,[‡] Toomas Talme,* Mona Ståhle,* and Liv Eidsmo*

Psoriasis is a common and chronic inflammatory skin disease in which T cells play a key role. Effective treatment heals the skin without scarring, but typically psoriasis recurs in previously affected areas. A pathogenic memory within the skin has been proposed, but the nature of such site-specific disease memory is unknown. Tissue-resident memory T (T_{RM}) cells have been ascribed a role in immunity after resolved viral skin infections. Because of their localization in the epidermal compartment of the skin, T_{RM} may contribute to tissue pathology during psoriasis. In this study, we investigated whether resolved psoriasis lesions contain T_{RM} cells with the ability to maintain and potentially drive recurrent disease. Three common and effective therapies, narrowband-UVB treatment and long-term biologic treatment systemically inhibiting TNF- α or IL-12/23 signaling were studied. Epidermal T cells were highly activated in psoriasis and a high proportion of CD8 T cells expressed T_{RM} markers. In resolved psoriasis, a population of cutaneous lymphocyte-associated Ag, CCR6, CD103, and IL-23R expressing epidermal CD8 T cells was highly enriched. Epidermal CD8 T cells expressing the T_{RM} marker CD103 responded to ex vivo stimulation with IL-17A production and epidermal CD4 T cells responded with IL-22 production after as long as 6 y of TNF- α inhibition. Our data suggest that epidermal T_{RM} cells are retained in resolved psoriasis and that these cells are capable of producing cytokines with a critical role in psoriasis pathogenesis. We provide a potential mechanism for a site-specific T cell-driven disease memory in psoriasis. *The Journal of Immunology*, 2014, 192: 3111–3120.

Psoriasis is an immune-mediated disorder primarily affecting the skin. Plaque psoriasis is the most common disease manifestation in which T cell infiltration into epidermis is closely linked to disease development and maintenance of inflammation (1, 2). In particular, Th17 cells and local production of IL-17 and IL-22 within the skin drives localized patches of chronic inflammation (3, 4). The powerful therapeutic effect of IL-12/23 inhibition (5) and promising results from clinical trials inhibiting IL-17 signaling in plaque psoriasis strengthen the critical role of Th17 in maintaining the chronic inflammation (6–8). Although current treatments induce clinical remission, psoriasis preferentially recurs in previously inflamed sites upon withdrawal of treatment. This indicates that a site-specific disease memory is formed during active disease and that such disease memory is maintained within the

skin during remission. T cell-associated genes (*LCK* and *TRCB1*) and inflammatory genes (*IL17*, *IL22*, and *IFNG*) remain upregulated in clinically resolved lesions at least three months after initiation of systemic TNF- α inhibiting treatment (9) indicating that activated T cells are retained at sites of previous skin inflammation and that skin resident T cells may form the site-specific disease memory within the skin.

Human skin is inhabited by and constantly patrolled by a vast number of memory T cells (10). Tissue-resident memory T cells (T_{RM} cells) lodged in the skin have the potential to confer both tolerance and immunity depending on the local microenvironment (11) and CD8 T_{RM} can be tracked by the phenotypic markers CD49a and CD103 (12, 13). Circulating effector T cells infiltrate sites of skin inflammation and have the potential to convert into long-lived epidermal T_{RM} cells as the skin inflammation resolves (14, 15). In the context of viral skin infection, it has been shown that epidermal T_{RM} cells reside at sites of previous infection and confer local immunity. By analogy, it is plausible that T_{RM} cells form a pathologic site-specific disease memory in sites of recurrent psoriasis.

In this study, we performed a detailed analysis of gene expression and cytokine production in T cells within epidermis and dermis after successful narrowband-UVB (nb-UVB) treatment and during successful long-term anti-TNF α or anti-IL-12/23 treatment. We found profound differences in the T cell populations at sites of previous psoriasis inflammation as compared with healthy skin. Our data show that a subpopulation of T cells infiltrating the epidermis during active disease turn into T_{RM} cells and establish a site-specific disease memory in psoriasis.

Materials and Methods

Patient material

Healthy control skin samples were obtained from reconstructive skin surgery at AdVita Clinic (Stockholm, Sweden). Swedish patients diagnosed with moderate to severe psoriasis (Table I) were recruited from the Psoriasis Association Clinic (Sundbyberg, Sweden) and Department of Der-

*Department of Medicine Solna, Karolinska Institutet, 171 77 Stockholm, Sweden;

[†]Department of Medicine Huddinge, Karolinska Institutet, 141 86 Stockholm, Sweden; and [‡]Department of Microbiology and Tumour Cell Biology, Karolinska Institutet, 171 77 Stockholm, Sweden

Received for publication August 29, 2013. Accepted for publication January 27, 2014.

This work was supported by Swedish Research Council Grant Dnr 2009-2357, the Åke Wiberg Foundation, the Svenska Läkaresällskapet, the Harald and Greta Jeansson Foundation, and the Karolinska Institutet, Psoriasisfonden and Hudfonden. S.C. is a Croucher Foundation Scholar; L.E. is a Clinical Research Fellow funded by Swedish Research Council Grant Dnr 2009-2357. L.E. has received an investigator-initiated research grant from Pfizer, and M.S. has received grant support from Pfizer and Janssen-Cilag.

Address correspondence and reprint requests to Dr. Liv Eidsmo, Dermatology and Venereology Unit, Department of Medicine, Karolinska Institutet, 171 77 Stockholm, Sweden. E-mail address: liv.eidsmo@ki.se

The online version of this article contains supplemental material.

Abbreviations used in this article: CLA, cutaneous lymphocyte-associated Ag; nb-UVB, narrowband-UVB; T_{RM} , tissue-resident memory T.

This article is distributed under The American Association of Immunologists, Inc., [Reuse Terms and Conditions for Author Choice articles](#).

Copyright © 2014 by The American Association of Immunologists, Inc. 0022-1767/14/\$16.00

matology at Karolinska University Hospital (Stockholm, Sweden). The study was approved by the Stockholm Regional Committee of Ethics (approval numbers 2012/50-31/2 and 2006/02-258) and performed according to the Declaration of Helsinki Principles. Signed consent forms were collected from all sample donors. Photos taken at times of active disease, reliable anamnestic information, or postinflammatory hyperpigmentation were used to localize sites of resolved skin. Punch skin biopsies (4 mm diameter, one to four per individual) were obtained from the trunk or thighs from plaque psoriasis patients under local anesthesia. Nonlesional skin were collected >3 cm from psoriasis plaques. Skin biopsies from patients or healthy donors were immediately frozen for histology or collected in PBS and freshly prepared for flow cytometry, sorting, and RNA analysis.

Confocal microscopy

Cryopreserved skin biopsies were processed and stained as described previously (16). Primary Abs used for immunofluorescence are shown in Supplemental Table I. Images were acquired with a laser scanning confocal microscopy (LSM700) with Zen 2011 software (Zeiss) and analyzed with ImageJ (<http://imagej.nih.gov/ij/>).

Preparation of skin cell suspensions

Whole-skin biopsies were incubated in 5 U dispase (Life Technologies) overnight at 4°C and epidermis was separated from dermis. Epidermis was cut and incubated in trypsin (0.025%)/EDTA (0.01%) (Life Technologies) for 15 min, and single-cell suspension was prepared by pipetting. Dermis was incubated in collagenase III (3 mg/ml; Worthington) for 90 min with DNase (5 µg/ml) in 10% FBS RPMI 1640 medium and further processed by Medicon tissue disruptor (BD Biosciences) as described previously (17). For cytokine stimulation and CD103, CCR6 and IL-23R staining epidermis was treated with collagenase, and for IL-23R staining, the samples were incubated 18 h prior to staining.

Ex vivo stimulation

Cell suspensions were stimulated with PMA (50 ng/ml) and ionomycin (1 µg/ml) for 5 h in the presence of brefeldin A (BD Biosciences) in the last 4 h of stimulation following the manufacturer's protocols.

Flow cytometry and cell sorting

Cell suspensions were stained with Live/Dead Yellow Kit (Invitrogen) followed by conjugated Abs (Supplemental Table I) at 4°C. Intracellular cytokine staining was performed following the manufacturer's protocol (BD Cytofix/Cytoperm). The entire sample was acquired using CyAn ADP analyzer (Beckman Coulter) or LSR-II (BD Biosciences) and analyzed using Flowjo (Tree Star). The number of T cells were divided by surface area of skin sample and presented as "number of cells/mm²." Cell sorting into QIAzol Lysis Reagent (Qiagen) was performed at the FACS facility at Department of Microbiology, Tumor and Cell Biology in Karolinska Institutet using MoFlo XDP (Beckman Coulter) cell sorter.

RNA purification and quantitative RT-PCR

RNA was purified from cell-qiazol lysate using miRNeasy Mini Kit (Qiagen) and reverse transcribed by High Capacity cDNA Reverse Transcription Kits (Applied Biosystems), and quantitative RT-PCR was performed using TaqMan PreAmp Master Mix Kit (Applied Bioscience) and the TaqMan Gene Expression Master Mix (Applied Bioscience) following the manufacturers' protocols. Gene expression was normalized to the house-keeping gene β_2 -microglobulin (*B2M*). The following TaqMan Gene Expression Assays were used and were all ordered from Applied Biosystems: B2M-Hs00984230_m1, CD207-Hs00210451_m1, CD3E-Hs01062241_m1, CD4-Hs00181217_m1, CD68-Hs00154355_m1, CD8A-Hs00233520_m1, CTLA4-Hs03044418_m1, FOXP3-Hs01085834_m1, GZMA-Hs00989184_m1, GZMB-Hs01554355_m1, IFNG-Hs00989291_m1, IL10-Hs00961622_m1, IL17A-Hs00174383_m1, IL22-Hs01574154_m1, IL4-Hs00174122_m1, IL5-Hs00174200_m1, IL13-Hs00174379_m1, ITGAE-Hs01025372_m1, PRF1-Hs00169473_m1, RORC-Hs01076122_m1, and TBX21-Hs00203436_m1.

Statistical analysis

Statistics were calculated using the PRISM (GraphPad) software. Two-tailed Mann-Whitney *U* test and two-tailed Wilcoxon matched-pairs signed rank test were used for testing independent or paired data, respectively. For comparisons involving multiple groups, the Holm-Bonferroni method was used to correct for multiple testing. Annotation of significance level, after correction of multiple testing, if applicable, was depicted as **p* ≤ 0.05; ***p* ≤ 0.01; and ****p* ≤ 0.001. Medians were depicted by horizontal bars in scatter dot plots.

Results

Massive infiltration of epidermal CD8 T cells expressing *T_{RM}* markers occurs in active psoriasis

A small but distinct population of epidermal T cells interspersed with Langerhans cells was detected in epidermal sheets from healthy skin (Fig. 1A). The epidermal T cells are located just above the epidermal-dermal junction (Fig. 1B), whereas the vast majority of T cells in healthy skin are located in the dermis around vessels as shown in cross-sectional projections in Fig. 1B. In untreated (active) psoriasis, there is massive infiltration of T cells into both epidermis and dermis, and epidermal T cells relocate higher up into the epidermis as compared with their strict confinement on the basal membrane in healthy skin (Fig. 1B). To further characterize the epidermal and dermal T cell infiltrate, rapid processing of the skin was performed to avoid potential alterations of the T cell populations through prolonged ex vivo cultures. Epidermal and dermal single-cell suspensions were analyzed by flow cytometry within 30 h of sampling as shown in Fig. 1C and Supplemental Fig. 1. Compared with normal skin (Fig. 1D) or nonlesional psoriasis skin (data not shown), the epidermal T cell population was ~100-fold increased in active psoriasis with a dominance of CD8 T cells (Fig. 1E), whereas the dermal T cell population showed a more modest 10-fold increase with a dominance of CD4 T cells in both active psoriasis and healthy skin (Fig. 1D, 1E). In healthy skin, 20–30% of epidermal CD8 T cells coexpressed the integrins CD103 and CD49a, phenotypic markers for *T_{RM}* cells (Fig. 1F). In active psoriasis, approximately one-half of the epidermal CD8 T cells coexpressed these *T_{RM}* phenotypic markers (Fig. 1F). Taken the 100-fold increase in epidermal T cells in active psoriasis compared with healthy skin (Fig. 1D) and 50-fold compared with nonlesional skin (Supplemental Fig. 2A), this corresponds to an impressive expansion of *T_{RM}* in psoriasis lesions.

Activated T cells preferentially accumulate in epidermis in active psoriasis

The inflammatory cytokines IL-17, IFN- γ , and IL-22 are highly produced by both CD4 and CD8 T cells in active psoriasis lesions (2, 18), and histological assessment further demonstrates that other cell types such as neutrophils and mast cells also express IL-17 in active psoriasis (2). Thus, analysis of full skin biopsies will not reveal the different expression profiles of CD4 and CD8 T cells or discriminate between epidermal and dermal T cells. To analyze the activation profiles of CD4 and CD8 T cells in the different skin compartments, T cells were sorted from active psoriasis and healthy skin, and RNA expression analysis was performed by real-time PCR. The purity of the sorted populations was confirmed by their gene expression profile as shown in Supplemental Fig. 1. We found that epidermal T cells in psoriasis exhibit high expression of genes related to T cell activation and inflammation (Fig. 2). *IL17A*, *IL22*, and *IFNG* showed striking upregulation in both epidermal CD4 and CD8 T cells in lesional psoriasis but not in dermal T cells (Fig. 2A). The cytotoxicity effector molecules granzyme A and B were upregulated in epidermal and dermal CD8 T cells and in epidermal CD4 T cells, whereas perforin was upregulated only in epidermal CD8 T cells (Fig. 2B). The coinhibitory molecule CTLA-4, the regulatory T cells transcriptional factor Forkheadbox (Fox)-P3, and the regulatory cytokine IL-10 showed increased gene expression in epidermal CD4 and CD8 (*CTLA4*) or CD4 (*FOXP3* and *IL10*) T cells from active psoriasis as compared with healthy skin (Fig. 2C). *CTLA4* and *FOXP3* were upregulated in dermal CD4 T cells, and *CTLA4* was upregulated in dermal CD8 T cells. Taken together, these data show that epidermis in active psoriasis contained highly activated CD4 and CD8 T cells, whereas their dermal counterparts were less activated.

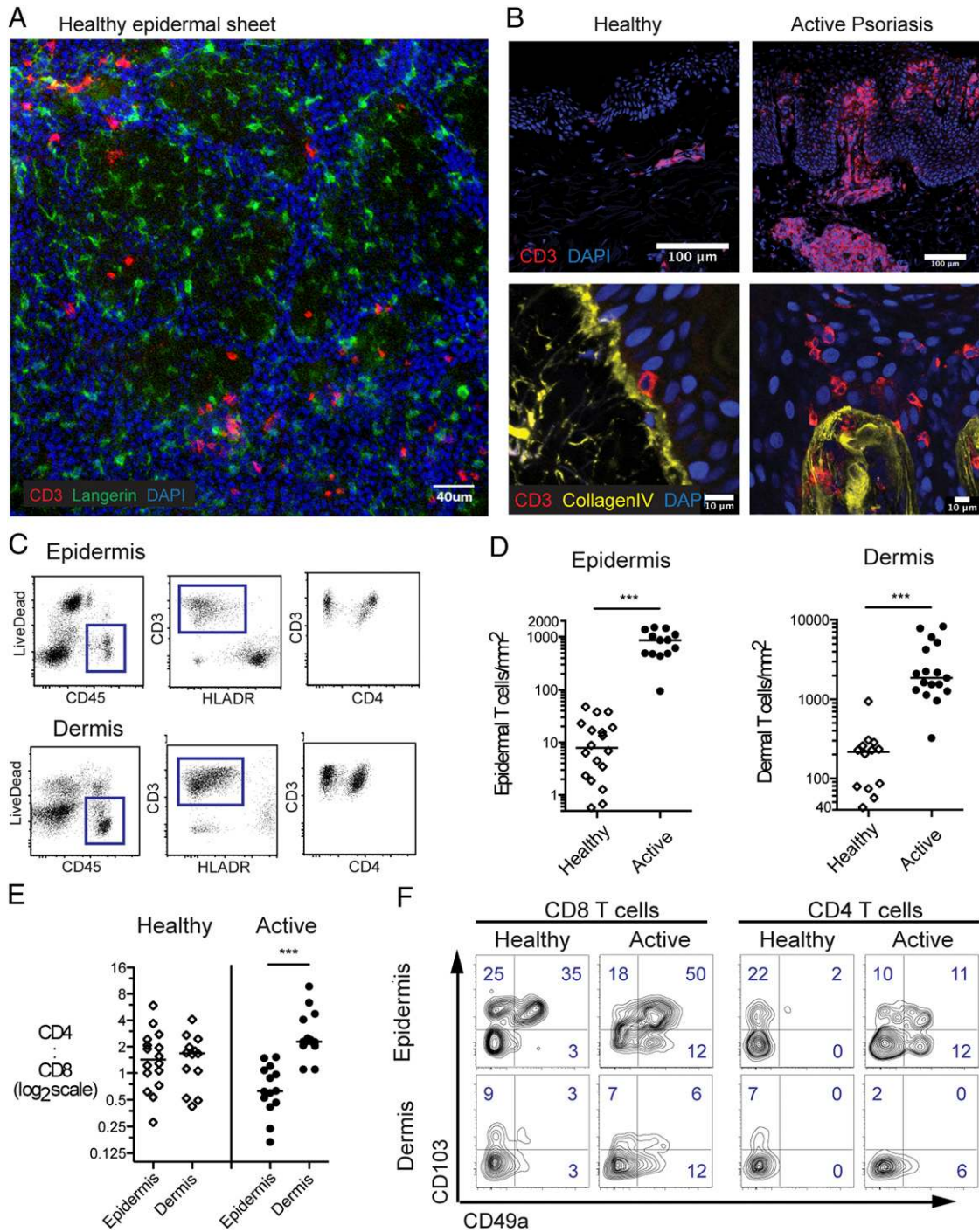


FIGURE 1. CD8 and CD4 T cells infiltrate both epidermis and dermis in psoriasis. **(A and B)** Confocal microscopy of healthy epidermal sheet **(A)** and cross-sectional projection of healthy and active psoriasis skin **(B)**. CD3 was pseudocolored in red, Collagen IV in yellow, Langerin in green and nuclei in blue. Representative pictures of three to six donors are shown. **(C)** Representative FACS plots of epidermal and dermal cell suspensions. **(D and E)** Number of T cells per mm² skin surface area **(D)** and CD4:CD8 ratio **(E)** of FACS analyzed samples, each dot corresponds to one individual. **(F)** CD103 and CD49a expression of T cells from healthy or active psoriasis skin, representative FACS contour plots gated on live, CD45⁺, and CD3⁺ T cells. Two-tailed Mann-Whitney *U* test used in **(D)**, two-tailed Wilcoxon matched-pairs signed rank test used in **(E)**. ****p* < 0.001.

CD49a expressing epidermal CD8 T cells are enriched in resolved psoriasis lesions

Highly activated and proinflammatory T cells were particularly enriched in epidermis in active psoriasis. We next examined how three disparate and commonly used therapies, nb-UVB and biologic therapy (ustekinumab and infliximab), affected the inflammatory profile of T cells in clinically healed psoriasis skin. nb-UVB treatment effectively clears psoriasis in responders after 20–30

treatments (19). Biologic treatment with systemic administration of Abs directed against TNF- α (infliximab) or IL-12/23 (ustekinumab) induces disease remission in responders, but continuous treatment is necessary to maintain the effect (5, 20). Regardless of treatment, flare-ups of psoriasis at sites of previous inflammation are common within a few months of withdrawal of treatment (5, 19, 20). To investigate whether pathogenic T_{RM} cells reside at sites of previous psoriasis lesions, biopsies were collected after

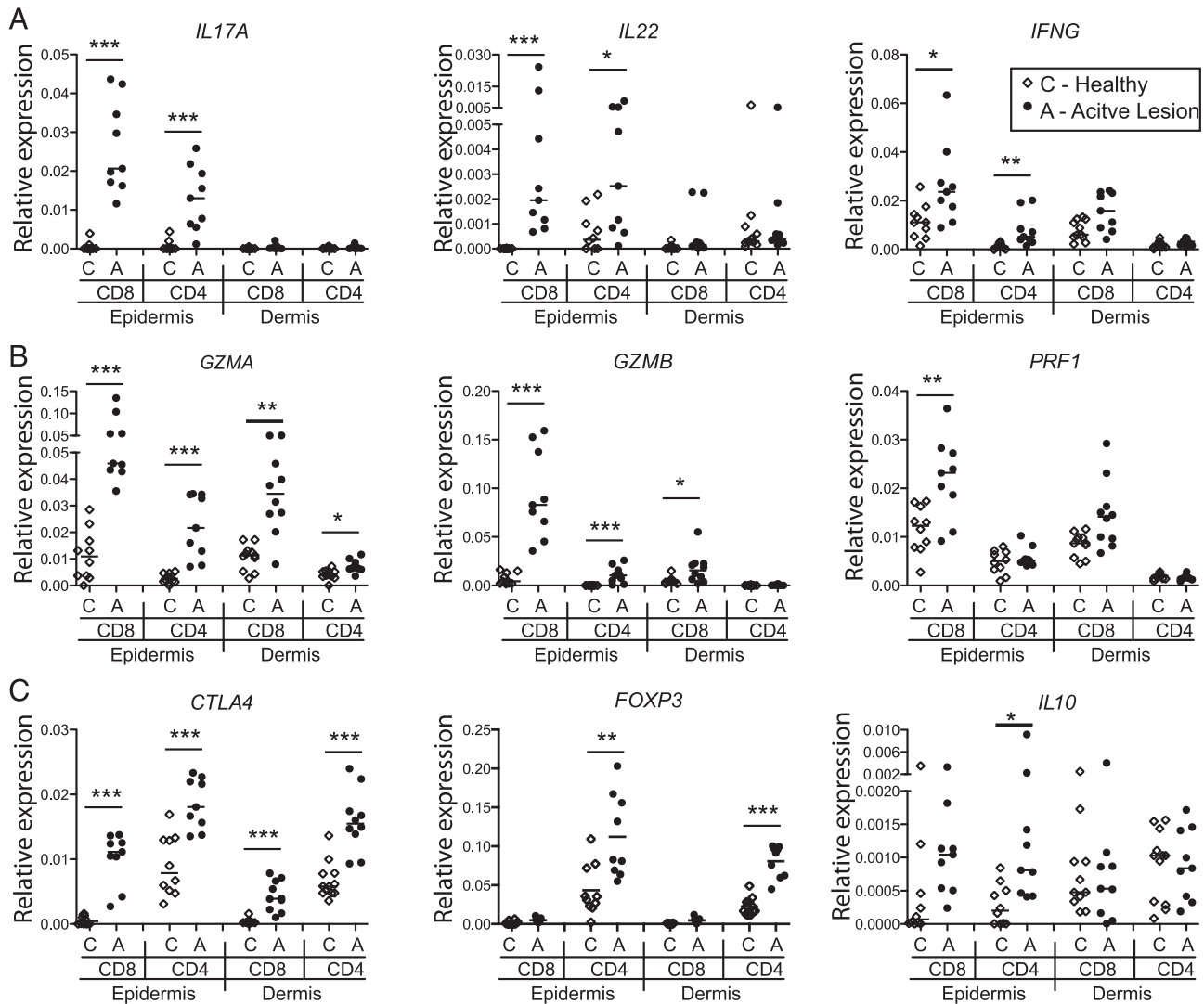


FIGURE 2. RNA expression profiles reveal highly activated epidermal T cells in lesional psoriasis. Relative gene expression of *IL17A*, *IL22*, *IFNG* (**A**), *GZMA*, *GZMB*, *PRF1* (**B**), *CTLA4*, *FOXP3*, and *IL10* (**C**) in epidermal and dermal CD8 or CD4 T cells from active psoriasis lesions (A, $n = 9$) and healthy skin (C, $n = 10$). Relative gene expression was calculated against the housekeeping gene β_2 -microglobulin (*B2M*) as $2^{-CT(\text{Target Gene})-CT(B2M)}$. Two-tailed Mann–Whitney U test corrected for multiple testing by using the Holm–Bonferroni method. * $p < 0.05$, ** $p < 0.01$, *** $p < 0.001$.

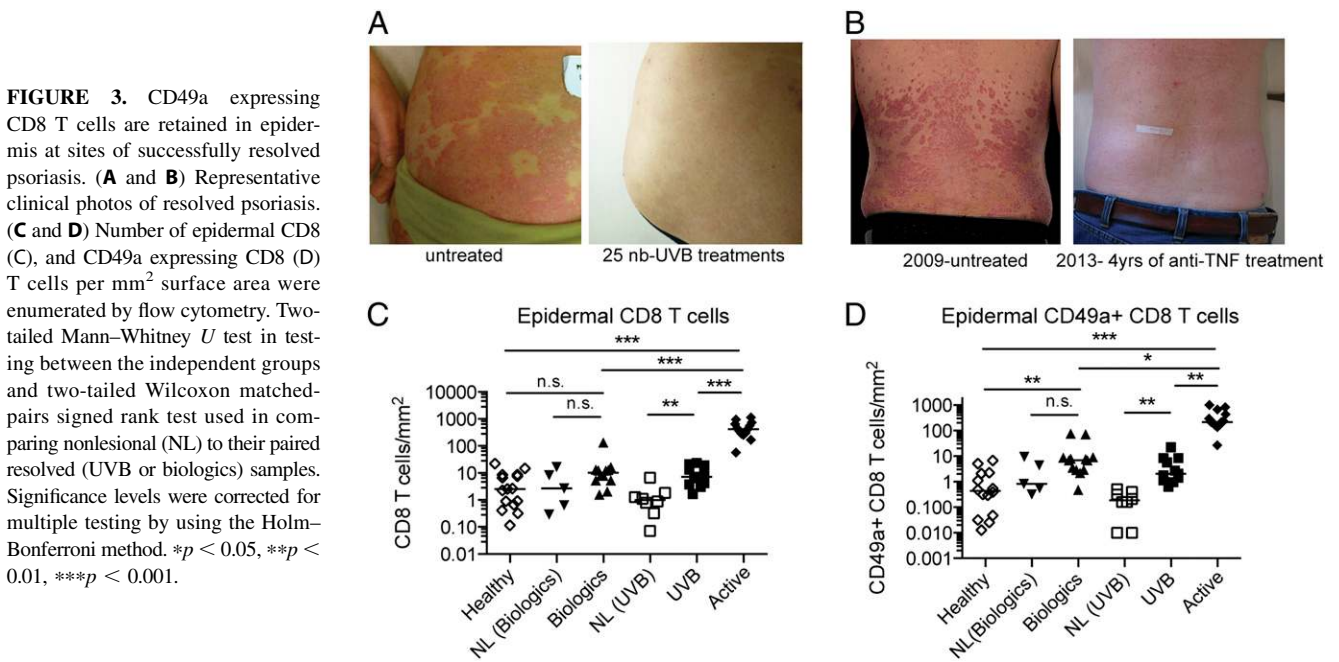
effective nb-UVB treatment ($n = 11$, minimum of 25 times UVB treatments) and during systemic treatment with biologics, infliximab ($n = 7$; median treatment time, 4.5 y), and ustekinumab ($n = 5$; median treatment time, 1.4 y). Patients responding to treatment and where sites of previous inflammation could be identified by patient’s history or by photos taken before and after treatment as shown in Fig. 3A and 3B were included. The overall disease burden was low after treatment as shown in Table I.

During successful treatment with biologics or nb-UVB, the number of epidermal CD4 T cells was normalized whereas increased numbers of dermal CD4 and CD8 T cells was noted (Supplemental Fig. 2B, 2C). In active psoriasis, CD49a expressing CD8 cells dominated the epidermal compartment (Fig. 1F). In successfully treated skin, these cells were dramatically reduced. However, despite normalization of the total number of epidermal CD8 T cells (Fig. 3C), the number of such cells expressing CD49a was 5-fold increased in nb-UVB-treated samples and 16-fold increased in samples collected from patients undergoing biological treatment compared with healthy skin (Fig. 3D). The majority of nb-UVB patients could identify areas of skin that had never been affected by psoriasis (nonlesional skin). Nonlesional epidermis contained a similar density of CD49a expressing CD8 T cells

compared with healthy skin and 10 times lower number of such cells in comparison with resolved lesions. Patients treated with biologics had undergone several different systemic treatments before initiation of the current treatment. Few of these patients could point out areas that had never been affected by psoriasis. Thus, only five nonlesional samples could be identified and analyzed in the biologics group. There was a clear trend toward more CD49a expressing CD8 T cells in resolved as compared with nonlesional epidermis, but this difference did not reach statistical significance. Although both nb-UVB and targeted inhibition of $\text{TNF-}\alpha$ or IL-12/23 dramatically reduced the number of epidermal CD49a expressing CD8 T cells, the increase in CD8 T cells expressing the T_{RM} cell-associated marker CD49a suggested expansion or selective retention of site-specific and potentially pathogenic T_{RM} in resolved lesions.

Cytotoxicity and regulatory gene expression is normalized in epidermal T cells in resolved lesions after UVB and biologic treatments

Epidermal T cells displayed profound changes in gene expression in active psoriasis (Fig. 2). To determine whether altered gene expression persisted in epidermal T cells in resolved lesions, we sorted CD4 and CD8 T cells from nb-UVB- or biologics-treated



lesions and examined their RNA expression profiles. Epidermal CD8 T cells in resolved lesions downregulated cytotoxic effector genes (*GRZA*, *GRZB*, and *PRF1*) regardless of treatment (Fig. 4A). In contrast, expression of *CTLA4* (Fig. 4B) was not normalized in epidermal CD8 T cells from nb-UVB–treated lesions, whereas it was normalized to the level of healthy skin in lesions from patients treated with biologics. The expression of *FOXP3*, *CTLA4*, and *IL10* in epidermal CD4 T cells was significantly reduced in resolved skin in comparison with active psoriasis and were within the range detected in healthy skin (Fig. 4C, 4D).

The Th17 axis gene expression is elevated in epidermal T cells in resolved psoriasis lesions

The Th2-associated transcriptional factor *GATA3* was downregulated in active psoriasis and normalized in CD4 T cells from nb-UVB–treated epidermis (Supplemental Fig. 2E). *IL4* and *IL5* could not be detected in epidermal CD4 T cells. *IL13* was downregulated in active psoriasis and biologics-treated skin in comparison with healthy skin and nb-UVB–treated resolved skin (Supplemental Fig. 2F). *TBX21* expression (Th1-associated transcriptional factor) was elevated in epidermal CD4 T cells in lesional psoriasis and remained elevated in nb-UVB–treated skin.

The Th17-associated transcriptional factor *RORC* expression remained elevated in epidermal CD4 T cells from both nb-UVB– and biologics-treated resolved skin compared with healthy skin, although this increase did not reach statistical significance, and *IL17A* expression remained high in nb-UVB–treated epidermis (Fig. 4E). As shown in Fig. 2A, *IL22* gene expression was upregulated in epidermal T cells from active psoriasis as compared with healthy skin. In resolved lesion, gene expression of *IL22* was not normalized and showed high variability in T cells derived from both nb-UVB– and biologics-treated lesions (Fig. 4F). In some of the donors, *IL22* expression by epidermal CD4 T cells was even higher in resolved as compared with the active lesion (Fig. 4F).

Ex vivo stimulation revealed that epidermal Th22 cells in resolved skin were still functional after several years of disease remission

Our phenotypic analysis suggested an epidermal population of T_{RM} after several years of biologic treatment at sites of previous psoriasis plaques and gene expression analysis indicated a potential retention of IL-17 and IL-22 production in epidermal T cells. To investigate whether skin-derived T cells in resolved lesions have

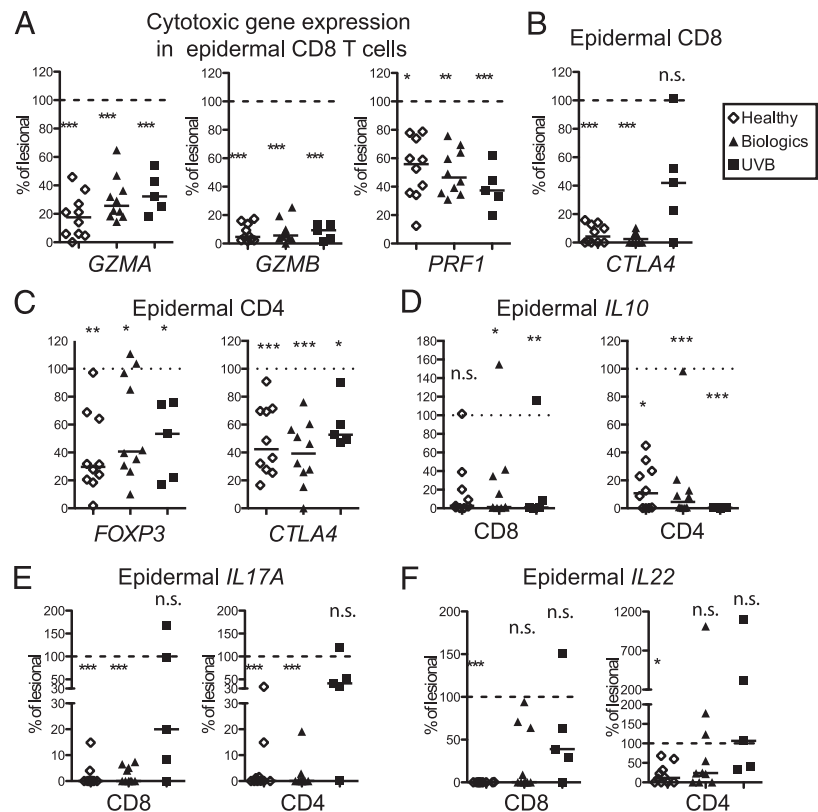
Table I. Clinical characteristics of patients included

	No. of Patients	No. of Total Samples Included in the Analysis Performed			PASI ^a Mean ± SD	Time of Treatment (y) Mean ± SD	Years of Disease (y) Mean ± SD	Age (y) Mean ± SD
		FACS	Gene Expression	Cytokine Analysis				
Lesional psoriasis	21	17	9	9	9.0 ± 5.9	—	21 ± 18	53 ± 14
nb-UVB	12	11	5	6	2.7 ± 1.9	(>25 times)	20 ± 17	50 ± 22
Anti-TNF-α (infliximab)	10	10	5	7	2.4 ± 1.8	4.5 ± 1.8	24 ± 13	42 ± 19
Anti-IL-12/23 (ustekinumab)	12	7	5	9	2.3 ± 1.7	1.8 ± 1.0	33 ± 21	49 ± 23
Healthy controls		15	10	7	—	—	—	42 ± 13

Three infliximab and two ustekinumab patients donated biopsies at two occasions with at least 6-mo intervals. The PASI score and time of treatment is included for both occasions whereas the time of disease and age is only included once for these donors.

^aPASI, psoriasis area and severity index.

FIGURE 4. Gene expression profiles in resolved psoriasis revealed retained *IL17* and *IL22* expression in epidermal T cells. (**A–F**) Gene expression in epidermal T cells sorted from healthy ($n = 10$), biologics treated ($n = 10$, anti-TNF $n = 5$, anti-IL-12/23 $n = 5$), and nb-UVB-treated skin ($n = 5$). Data presented as the percentage of the median gene expression of the corresponding gene from active lesions ($n = 9$). Dashed line indicated 100% gene expression in active lesions. Two-tailed Mann-Whitney U test in testing between the corresponding groups against the active psoriasis lesions. Significance levels were corrected for multiple testing by using the Holm-Bonferroni method and shown above the data dots of each group. $*p < 0.05$, $**p < 0.01$, $***p < 0.001$.



the potential to drive recurrent skin inflammation, we next assessed IL-22 and IL-17A production in skin T cells after short ex vivo stimulation with PMA/ionomycin. In active psoriasis, the proportion of IL-22- and/or IL-17A-producing T cells was increased 4-fold as compared with healthy skin, and half the cytokine-producing epidermal CD4 T cells coexpressed IL-22 and IL-17A as shown in Fig. 5A and 5B. The production of IFN- γ was significantly increased in epidermal CD4 T cells in active psoriasis but not to the same extent as IL-17A and IL-22 (Supplemental Fig. 2H). Dermal T cells from resolved skin showed similar cytokine production as compared with healthy skin (Fig. 5B), and the proportion of IL-17A-expressing CD4 T cells was decreased as compared with lesional skin. In resolved epidermis, the number of IL-17A (Fig. 5B)- and IFN- γ (Supplemental Fig. 2H)-producing CD4 T cells was comparable to healthy skin. Interestingly, IL-22-producing epidermal CD4 T cells in resolved lesions remained on the same level or even higher as compared with active psoriasis (Fig. 5A, 5B). The percentage of IL-22-producing epidermal CD4 T cells did not correlate with the number of treatment years (Supplemental Fig. 2D), indicating a retained effector function in resolved lesions as long as after 6 y of treatment.

Epidermal Tc17 cells maintain their inflammatory capacity in resolved lesions

Epidermal CD8 T cells play a critical role in psoriasis inflammation, and in agreement with previous reports (2, 18), we found that the majority of epidermal CD8 T cells in active psoriasis lesions expressed IL-17A, IL-22, and/or IFN- γ . A higher proportion of CD8 T cells produced IL-17A and IFN- γ as compared with CD4 T cells (Fig. 5C, 5D, Supplemental Fig. 2H). In resolved lesions, a higher frequency of cytokine-producing CD8 T cells was detected after nb-UVB than during biological treatment (Fig. 5C, 5D). This is in agreement with the CD4 T cell cytokine profile

(Fig. 5A, 5B) and our gene expression analysis (Fig. 4) and indicates that epidermal T cells lesions display an activated phenotype despite the normalization of the size of the population in nb-UVB-treated lesions. Interestingly, and contrary to our gene expression data, epidermal CD8 T cells from anti-TNF- α and anti-IL-12/23-treated skin showed increased IL-17A production compared with healthy skin upon PMA/ionomycin stimulation (Fig. 5C, 5D). No significant difference in IFN- γ production among healthy skin, active, and resolved psoriasis samples was noted following PMA/ionomycin stimulation (Supplemental Fig. 2H). A population of IL-17-producing epidermal CD8 T cells was maintained for as long as 6 y after initiation of treatment (Supplemental Fig. 2D), indicating that epidermal T cells are capable of exerting effector functions after long-term biologic treatment.

IL-17 production is maintained by T_{RM} in resolved psoriasis

IL-17 has a critical role in maintaining psoriasis inflammation in skin. Thus, the IL-17-producing epithelial T cells are of particular interest when it comes to creating a disease memory in resolved psoriasis lesions. As shown in Fig. 6A and 6B, epidermal IL-17-producing cells in healthy skin, active, and resolved psoriasis expressed the T_{RM} marker CD103. Likewise, IL-22 production was almost exclusively found in CD103 expressing CD8 T cells in active psoriasis, whereas IL-22-expressing CD8 T cells were absent in healthy skin and resolved lesions (data not shown). The proportion of CD103 expressing cytokine-producing cells showed a large variation in epidermal CD4 T cells as shown in Supplemental Fig. 3. To further characterize the T_{RM} cells in resolved psoriasis, the expression of the skin homing marker cutaneous lymphocyte-associated Ag (CLA) and the phenotypic Th17 markers CCR6 and IL-23R were assessed in epidermal T cells as shown in Fig. 6C and 6D and Supplemental Fig. 3. It is noteworthy that ~40% of the epidermal CD8 and CD4 cells in resolved psoriasis and healthy skin

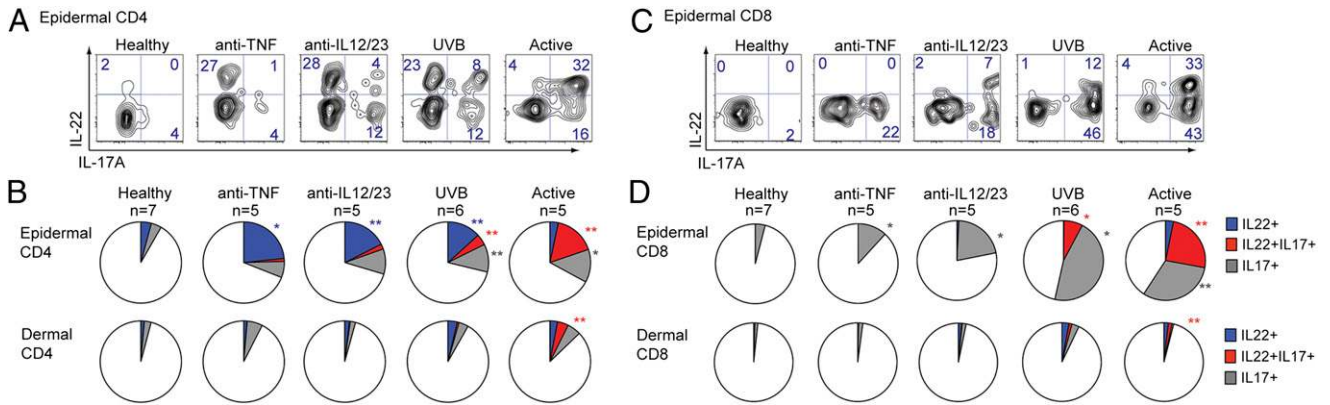


FIGURE 5. Epidermal Th22 and Tc17 were revealed in resolved lesions after several years of treatment upon ex vivo stimulation. **(A and C)** Representative contour plots of intracellular IL-22 and IL-17A expression in epidermal CD4 T **(A)** and CD8 T **(C)** cells after stimulation with PMA and ionomycin in the presence of brefeldin A. **(B and D)** Pie charts depicting the median proportion of IL-22⁺IL-17⁻ (blue), IL-22⁺IL-17⁺ (red), and IL-22⁻IL-17⁺ (gray) production of epidermal and dermal CD4 T **(B)** and CD8 T **(D)** cells. Two-tailed Mann–Whitney *U* test was used in testing between the corresponding groups against healthy CD4 T or CD8 T cells. Significance levels were corrected for multiple testing by using the Holm–Bonferroni method and shown in the corresponding color. **p* < 0.05, ***p* < 0.01.

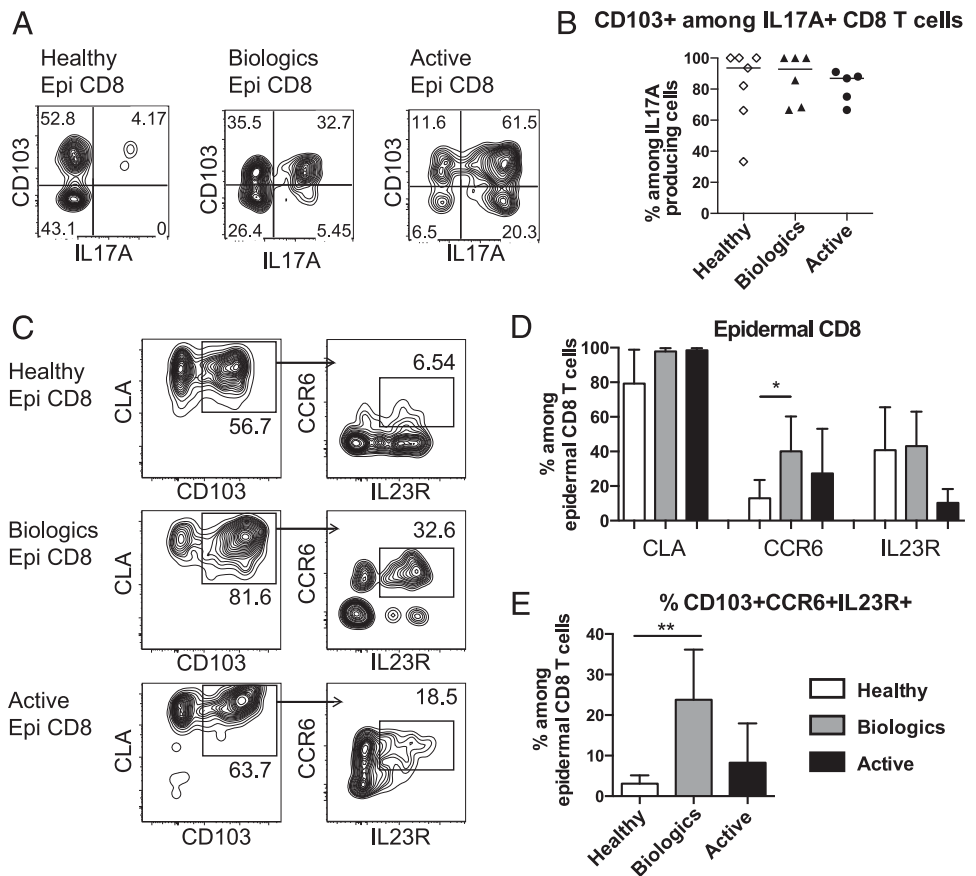
express IL-23R, which indicated that they are susceptible to IL-23 signaling (Fig. 6C, Supplemental Fig 3). Interestingly, a distinct population of epidermal CD8 T cells coexpressing CD103, CCR6, and IL-23R was highly enriched in resolved psoriasis (Fig. 6C, 6D). This suggests that Tc17 cells, with the capacity to respond to IL-23, are retained in the resolved skin lesions.

Discussion

A major therapeutic challenge in treating psoriasis is relapse in previously affected sites when treatment is withdrawn, indicating

the formation of a site-specific disease memory (5, 19, 21). Psoriasis is an immune-mediated T cell driven disease with genetic and pathogenic similarities to other chronic and relapsing inflammatory diseases such as Crohn’s disease, multiple sclerosis and rheumatoid arthritis (22, 23). The cellular architecture and mechanisms underlying site-specificity of recurrent inflammatory diseases are not understood and the skin represents an ideal model system to study mechanisms of localized immune memory in peripheral tissues as it allows sampling from the same area during different phases of the inflammatory process. Thus, identification

FIGURE 6. IL-17 production is maintained by T_{RM} in resolved psoriasis. **(A)** Representative contour plots of epidermal CD8 T cells in resolved psoriasis lesions depicting CD103 with IL-17A staining after 5 h Ionomycin/PMA stimulation. **(B)** The proportion of CD103⁺ among IL-17A–producing live CD8 T cells, healthy skin (*n* = 7), biologics treated resolved lesions (*n* = 5) and active psoriasis (*n* = 5). **(C)** Representative contour plots of CLA, CD103, IL-23R, and CCR6 expression in epidermal CD8 T cells in healthy skin, resolved, and active psoriasis. **(D and E)** Bar graph depicting the proportion of CLA⁺, CCR6⁺, IL23R⁺ **(A)** and CD103⁺CCR6⁺IL23R⁺ **(B)** expressing epidermal CD8, where percent CD103⁺ among IL-17A–producing live CD8 T cells × percentage of CCR6⁺ IL23R⁺ cells among CD103⁺CD8⁺ T cells). Mean and SD are depicted. Healthy skin (*n* = 5) biologics-treated resolved psoriasis (*n* = 5) and active psoriasis (*n* = 2). **p* = 0.012, ***p* = 0.0079.



of mechanisms of tissue pathology in psoriasis may have great impact in development of novel therapeutic strategies for chronic tissue inflammation in different organ systems.

Suarez-Farinas et al. (9) showed that T cell-associated genes remained upregulated in full skin biopsies collected from resolved psoriasis undergoing anti-TNF- α treatment, but the precise localization or identity of disease-driving T cells within the skin was not determined. Vollmar et al. (24) reported that stable oligoclonal populations of epidermal CD8 T cells were found in relapsing disease after periods of complete remission, indicating that a subset of epidermal T cells were retained and enriched in lesional epidermis over time. Oligoclonal expansion of CD8 T cells was confined to the epidermis in active psoriasis lesions and was not detected in lesional dermis, nonlesional skin or peripheral blood, which further strengthens the concept of a T cell-driven disease memory localized in the epidermis (25).

In agreement with previous reports (1, 2, 26–28), our results highlight that CD4 and CD8 T cells infiltrate both epidermis and dermis in psoriasis. In active psoriasis, we show increased expression of *IL17A*, *IL22*, and *IFNG* in epidermal CD4 and CD8 T cells in the immediate vicinity of keratinocytes, whereas dermal T cells show less upregulation of these genes. It should be noted that the area of the dermal vasculature is expanded in psoriasis, and it is possible that an increased proportion of circulating nonpathogenic T cells are included in our analysis and thus dilute the pathogenic signature from dermal T cells entering the tissue. Although we, like other investigators (9, 29), found more dermal T cells in resolved lesions, our data show that these T cells did not respond with higher IL-17A and IL-22 production upon ex vivo stimulation compared with T cells from healthy skin. In contrast, the few remaining epidermal T cells in resolved lesions were highly responsive to ex vivo stimulation.

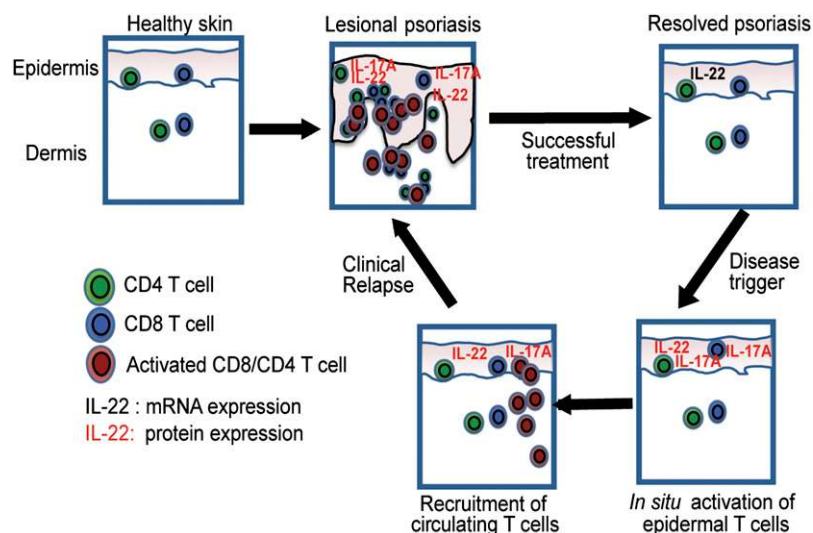
Epidermal CD4 T cells derived from resolved lesions mainly produced IL-22 after ex vivo stimulation. IL-22 has been linked to keratinocyte activation and the formation of epidermal acanthosis, a prominent morphologic feature in psoriasis (4, 30, 31). In contrast, epidermal CD8 T cells in resolved lesions mainly produced IL-17A, which drives the production of proinflammatory cytokines and chemokines by keratinocytes. IL-17A is proposed to be a key mediator of psoriatic inflammation through recruitment and activation of leukocytes into the skin (3). Our data show that epidermal CD4 and CD8 T cells produce different cytokines in resolved lesions during disease remission. A scenario could be envisaged where skin residing CD4 T cells through IL-22 production would

have a direct role on keratinocyte pathology and CD8 T cells would drive inflammation and recruitment of circulating leukocytes into the tissue through IL-17A production. Thus, epidermal T cells would be perfectly placed to drive recurrent episodes of inflammation in previous sites of inflammation. Our data show that epidermal T cells prone to produce the psoriasis pathogenic cytokines IL-17 and IL-22, but not IFN- γ , are specifically retained in resolved lesions, which strengthens the concept of disease driving epidermal T_{RM}.

Elegant ex vivo studies of blood derived T cells showed that circulating T cells have the ability to produce either IL-22 exclusively or together with IL-17 (32). Epidermal T cells producing both IL-22 and IL-17 were detected in active lesions and nb-UVB-treated skin. These double-producing T cells were virtually absent in skin from patients treated with biologics. It is possible that double-producing T cells represent stronger disease driving cells than single producers through the simultaneous induction of IL-22 mediated epidermal hyperplasia and IL-17 mediated recruitment of neutrophils in epidermis within the immediate microenvironment. Data from a murine model of psoriasis indicated that IL-22 production was essential to induce Th17-driven skin inflammation (4) whereas inhibition of IL-17 alone has a promising and impressive effect on disease activity in man (6–8). In resolved epidermis, single-producing IL-17 CD8 T cells and IL-22-producing CD4 T cells were detected, which could strengthen the notion that the IL-17/IL-22 double-producers found during active disease are more pathogenic.

Tissue-resident, long-lived memory T cells are detected in epidermis in murine models of resolved viral infection whereas dermal T cells continuously circulate between the resolved skin and the blood (12, 14, 15). Tissue-resident T cells have been shown in human skin after viral infection (12, 13), in cutaneous lymphomas (33) and in fixed drug eruption (34). At sites of recurrent HSV-2 infection in man, Zhu et al. showed persisting oligoclonal CD8 T cells at the epidermal–dermal border. In contrast to our data, these T cells expressed of *GRZA*, *GRZB*, and *PRF1* in clinically healed lesions 8 wk after active viral infection. The retained cytotoxic activity may reflect a low but continuous Ag stimulation through asymptomatic viral shedding and indeed HSV DNA was detected in two of four investigated tissue samples (35). In fixed drug eruption, resting epidermal CD8 T cells were shown to reside at sites of previous Ag-driven inflammation and respond within hours to oral ingestion of the causative hapten through IFN- γ production and mobilization toward dermis (34). In an in vivo

FIGURE 7. Proposed mechanism of T_{RM} cell-driven recurrent inflammation in psoriasis. The healthy skin is populated by epidermal and dermal CD4 and CD8 T cells. In lesional psoriasis, a massive infiltration of IL-17A- and IL-22-producing CD8 and CD4 T cells occurs in both epidermis and dermis. In resolved lesion, epidermal CD4 T cells retain elevated gene expression of *IL22*. Upon stimulation, epidermal CD4 T cells respond with IL-22 production and epidermal CD8 T cells with IL-17A production. We propose that IL-17A leads to recruitment of inflammatory T cells from the blood and that IL-22 participates in the keratinocyte activation and development of acanthosis leading to recurrent and site-specific psoriasis inflammation.



model of viral mucosal infection, in situ Ag stimulation of T_{RM} cells initiated IFN- γ production, which resulted in rapid recruitment of circulating memory T cells into the skin and initiation of skin inflammation (36). In the context of psoriasis, we here show that although the epidermal T cell population contracted in resolved lesions, epidermal CD8 T cells expressing the T_{RM} marker CD49a were enriched as compared with healthy and nonlesional skin, suggesting the formation of a stable and resting population of T_{RM} cells in resolved psoriasis. Epidermal T cells in healed skin readily responded to *ex vivo* stimulation by production of cytokines known to drive psoriasis. We propose that T_{RM} potentially drive recruitment of circulating leukocytes and recurrent inflammation, and thereby lead to recurrent psoriasis in the previously inflamed skin as shown in schematic Fig. 7.

One of the objectives of the current study was to investigate functional properties of skin resident T cells present in successfully resolved lesions induced by three disparate and common therapeutic strategies—nb-UVB treatment and long-term systemic inhibition of TNF- α or IL-12/23 signaling. The number of epidermal T cells was normalized with all therapeutic strategies investigated. Our combined gene expression, phenotypic and cytokine analyses showed that the remaining population of epidermal T cells in nb-UVB treated lesions resembles activated effector T cells skewed toward constant production of psoriasis driving cytokines. In contrast, RNA expression profiles suggested a less active T_{RM} phenotype in biologics treated skin. There are several potential explanations for the different activation profile of epithelial T cells after nb-UVB and biologics treatment. nb-UVB samples were collected after 2–3 mo of treatment whereas the biologics treated patients had been treated from 1 to 6 y. The development of a stable and resting epithelial T cell population may develop over time after inflammation is resolved. Clinical disease remission is often short after nb-UVB treatment and typically healed lesion display active inflammation within 12–15 wk after finalizing the UVB course (19, 37). Effective nb-UVB treatment induces T cell apoptosis within the skin (38). Highly activated epidermal T may survive the nb-UVB treatment and may have the potential to drive recurrent disease. Alternatively, activated T cells may continuously be recruited from circulation in patients after nb-UVB but not after biologics treatment. Taken the available data on circulating T cells during biologics (39, 40) and nb-UVB treatment (41, 42) it is not possible to predict whether replenishment of skin T cells occur in the different treatments. The inflammatory profiles in epidermal T cells may seem contradictory to previous publications where expression analysis of full skin biopsies 6 wk after nb-UVB treatment suggested normalization of *IL17A* and *IL22* gene expression (43, 44) and highlights the importance of dissecting different T cell populations present within the different anatomical compartments of the skin.

Surprisingly few studies have investigated the effect of systemic inhibition on skin immunity exceeding 3–4 mo of treatment and to our knowledge this is the first report investigating skin T cells after several years of biologic treatment. Infliximab may induce apoptosis of TNF α expressing cells, whereas ustekinumab does not eradicate IL-12/23-expressing cells. In this study, we show that a stable population of T_{RM} promptly produce IL-22 or IL-17 upon restimulation after years of treatment with both infliximab and ustekinumab. A distinct population of epidermal CD8 T cells coexpressing CD103, CCR6, and IL-23R was highly enriched in resolved psoriasis. The expression of the IL-23R in this population indicated that these cells responds to IL-23 stimulation, although we do not formally show this through IL-23 signaling experiments due to ethical constraints in the amount

of human skin that can be collected from psoriasis patients. We speculate that the majority of these epidermal T cells are “resting” T_{RM} that upon the right trigger drive recurrent inflammation in fixed spots of the skin (Fig. 7). Future treatment strategies aimed at long term remission of psoriasis might comprise two phases, the first inhibiting signaling molecules known to maintain chronic inflammation such as anti-IL-12/23 and anti-TNF- α , followed by direct targeting of T_{RM} at sites of previous disease. Clark et al. (33) recently presented proof that T cell eradication through anti-CD52, although effectively depleting circulating T cells, do not eradicate skin T_{RM} in the context of cutaneous lymphomas. Whether systemically administered Abs penetrate into the epidermal compartment in psoriasis, where we clearly detect highly activated T cells in resolved skin, remains unclear. Topical eradication of T_{RM} could be an attractive future therapeutic strategy to avoid relapse of psoriasis in previously affected areas of the skin.

Acknowledgments

We thank all the patients that participated in our study and the staff at the Department of Dermatology at Karolinska University Hospital and the Psoriasis Association Treatment Center in Sundbyberg, Sweden for crucial help in recruiting patients. We also thank Dr. Linda Wakim and Prof. Frank Carbone (Melbourne University, Melbourne, VIC, Australia) and Asst. Prof. Anna Smed-Sörensen and Asst. Prof. John Andersson (Karolinska Institutet) for constructive comments.

Disclosures

L.E. has received lecturing fees from Pfizer and Leo Pharma, and M.S. has received lecturing fees from Pfizer, Abbott, MSD, Novartis, and Janssen-Cilag.

References

- Conrad, C., O. Boyman, G. Tonel, A. Tun-Kyi, U. Laggner, A. de Fougères, V. Kotlianski, H. Gardner, and F. O. Nestle. 2007. $\alpha_1\beta_1$ integrin is crucial for accumulation of epidermal T cells and the development of psoriasis. *Nat. Med.* 13: 836–842.
- Res, P. C. M., G. Piskin, O. J. de Boer, C. M. van der Loos, P. Teeling, J. D. Bos, and M. B. M. Teunissen. 2010. Overrepresentation of IL-17A and IL-22 producing CD8 T cells in lesional skin suggests their involvement in the pathogenesis of psoriasis. *PLoS One* 5: e14108.
- Lowe, M. A., T. Kikuchi, J. Fuentes-Duculan, I. Cardinale, L. C. Zaba, A. S. Haider, E. P. Bowman, J. G. Krueger, L. C. Zaba, L. C. Zaba, et al. 2008. Psoriasis vulgaris lesions contain discrete populations of Th1 and Th17 T cells. *J. Invest. Dermatol.* 128: 1207–1211.
- Ma, H. L., S. Liang, J. Li, L. Napierata, T. Brown, S. Benoit, M. Senices, D. Gill, K. Dunussi-Joannopoulos, M. Collins, et al. 2008. IL-22 is required for Th17 cell-mediated pathology in a mouse model of psoriasis-like skin inflammation. *J. Clin. Invest.* 118: 597–607.
- Leonardi, C. L., A. B. Kimball, K. A. Papp, N. Yeh, C. Guzzo, Y. Wang, S. Li, L. T. Dooley, K. B. Gordon, and PHOENIX 1 study investigators. 2008. Efficacy and safety of ustekinumab, a human interleukin-12/23 monoclonal antibody, in patients with psoriasis: 76-week results from a randomised, double-blind, placebo-controlled trial (PHOENIX 1). *Lancet* 371: 1665–1674.
- Leonardi, C., R. Matheson, C. Zachariae, G. Cameron, L. Li, E. Edson-Heredia, D. Braun, and S. Banerjee. 2012. Anti-interleukin-17 monoclonal antibody ixekizumab in chronic plaque psoriasis. *N. Engl. J. Med.* 366: 1190–1199.
- Papp, K. A., C. Leonardi, A. Menter, J. P. Ortonne, J. G. Krueger, G. Kricorian, G. Aras, J. Li, C. B. Russell, E. H. Thompson, and S. Baumgartner. 2012. Brodalumab, an anti-interleukin-17-receptor antibody for psoriasis. *N. Engl. J. Med.* 366: 1181–1189.
- Hueber, W., D. D. Patel, T. Dryja, A. M. Wright, I. Koroleva, G. Bruin, C. Antoni, Z. Draelos, M. H. Gold, P. Durez, et al. 2010. Effects of AIN457, a fully human antibody to interleukin-17A, on psoriasis, rheumatoid arthritis, and uveitis. *Sci. Transl. Med.* 2: 52ra72.
- Suárez-Fariñas, M., J. Fuentes-Duculan, M. A. Lowe, and J. G. Krueger. 2011. Resolved psoriasis lesions retain expression of a subset of disease-related genes. *J. Invest. Dermatol.* 131: 391–400.
- Clark, R. A., B. Chong, N. Mirchandani, N. K. Brinster, K. Yamanaka, R. K. Dowgiert, and T. S. Kupper. 2006. The vast majority of CLA⁺ T cells are resident in normal skin. *J. Immunol.* 176: 4431–4439.
- Seneschal, J., R. A. Clark, A. Gehad, C. M. Baecher-Allan, and T. S. Kupper. 2012. Human epidermal Langerhans cells maintain immune homeostasis in skin by activating skin resident regulatory T cells. *Immunity* 36: 873–884.

12. Gebhardt, T., L. M. Wakim, L. Eidsmo, P. C. Reading, W. R. Heath, and F. R. Carbone. 2009. Memory T cells in nonlymphoid tissue that provide enhanced local immunity during infection with herpes simplex virus. *Nat. Immunol.* 10: 524–530.
13. Zhu, J., D. M. Koelle, J. Cao, J. Vazquez, M. L. Huang, F. Hladik, A. Wald, and L. Corey. 2007. Virus-specific CD8⁺ T cells accumulate near sensory nerve endings in genital skin during subclinical HSV-2 reactivation. *J. Exp. Med.* 204: 595–603.
14. Mackay, L. K., A. T. Stock, J. Z. Ma, C. M. Jones, S. J. Kent, S. N. Mueller, W. R. Heath, F. R. Carbone, and T. Gebhardt. 2012. Long-lived epithelial immunity by tissue-resident memory T (TRM) cells in the absence of persisting local antigen presentation. *Proc. Natl. Acad. Sci. USA* 109: 7037–7042.
15. Casey, K. A., K. A. Fraser, J. M. Schenkel, A. Moran, M. C. Abt, L. K. Beura, P. J. Lucas, D. Artis, E. J. Wherry, K. Hogquist, et al. 2012. Antigen-independent differentiation and maintenance of effector-like resident memory T cells in tissues. *J. Immunol.* 188: 4866–4875.
16. Eidsmo, L., A. T. Stock, W. R. Heath, S. Bedoui, and F. R. Carbone. 2012. Reactive murine lymph nodes uniquely permit parenchymal access for T cells that enter via the afferent lymphatics. *J. Pathol.* 226: 806–813.
17. Tasew, G., S. Nylén, T. Lieke, B. Lemu, H. Meless, N. Ruffin, D. Wolday, A. Asseffa, H. Yagita, S. Britton, et al. 2010. Systemic FasL and TRAIL neutralisation reduce leishmaniasis induced skin ulceration. *PLoS Negl. Trop. Dis.* 4: e844.
18. Hijnjen, D., E. F. Knol, Y. Y. Gent, B. Giovannone, S. J. Beijm, T. S. Kupper, C. A. Bruijnzeel-Koomen, and R. A. Clark. 2013. CD8⁺ T cells in the lesional skin of atopic dermatitis and psoriasis patients are an important source of IFN- γ , IL-13, IL-17, and IL-22. *J. Invest. Dermatol.* 133: 973–979.
19. Molin, L., and Calcipotriol-UVB Study Group. 1999. Topical calcipotriol combined with phototherapy for psoriasis: the results of two randomized trials and a review of the literature. *Dermatology* 198: 375–381.
20. Gottlieb, A. B., R. Evans, S. Li, L. T. Dooley, C. A. Guzzo, D. Baker, M. Bala, C. W. Marano, and A. Menter. 2004. Infliximab induction therapy for patients with severe plaque-type psoriasis: a randomized, double-blind, placebo-controlled trial. *J. Am. Acad. Dermatol.* 51: 534–542.
21. Reich, K., G. Wozel, H. Zheng, H. J. van Hoogstraten, and L. Flint. 2013. Efficacy and safety of infliximab as continuous or intermittent therapy in patients with moderate-to-severe plaque psoriasis: results of a Randomised, Long-Term Extension Trial (RESTORE2). *Br. J. Dermatol.* 168: 1325–1334.
22. Weaver, C. T., C. O. Elson, L. A. Fouser, and J. K. Kolls. 2013. The Th17 pathway and inflammatory diseases of the intestines, lungs, and skin. *Annu. Rev. Pathol.* 8: 477–512.
23. Zhernakova, A., C. C. van Diemen, and C. Wijmenga. 2009. Detecting shared pathogenesis from the shared genetics of immune-related diseases. *Nat. Rev. Genet.* 10: 43–55.
24. Vollmer, S., A. Menssen, and J. C. Prinz. 2001. Dominant lesional T cell receptor rearrangements persist in relapsing psoriasis but are absent from nonlesional skin: evidence for a stable antigen-specific pathogenic T cell response in psoriasis vulgaris. *J. Invest. Dermatol.* 117: 1296–1301.
25. Menssen, A., P. Trommler, S. Vollmer, D. Schendel, E. Albert, L. Gürtler, G. Riethmüller, and J. C. Prinz. 1995. Evidence for an antigen-specific cellular immune response in skin lesions of patients with psoriasis vulgaris. *J. Immunol.* 155: 4078–4083.
26. Austin, L. M., M. Ozawa, T. Kikuchi, I. B. Walters, and J. G. Krueger. 1999. The majority of epidermal T cells in psoriasis vulgaris lesions can produce type 1 cytokines, interferon- γ , interleukin-2, and tumor necrosis factor- α , defining TC1 (cytotoxic T lymphocyte) and TH1 effector populations: a type 1 differentiation bias is also measured in circulating blood T cells in psoriatic patients. *J. Invest. Dermatol.* 113: 752–759.
27. Ozawa, M., K. Ferenczi, T. Kikuchi, I. Cardinale, L. M. Austin, T. R. Coven, L. H. Burack, and J. G. Krueger. 1999. 312-nanometer ultraviolet B light (narrow-band UVB) induces apoptosis of T cells within psoriatic lesions. *J. Exp. Med.* 189: 711–718.
28. Mitsui, H., M. Suárez-Fariñas, D. A. Belkin, N. Levenkova, J. Fuentes-Duculan, I. Coats, H. Fujita, and J. G. Krueger. 2012. Combined use of laser capture microdissection and cDNA microarray analysis identifies locally expressed disease-related genes in focal regions of psoriasis vulgaris skin lesions. *J. Invest. Dermatol.* 132: 1615–1626.
29. Zaba, L. C., M. Suárez-Fariñas, J. Fuentes-Duculan, K. E. Nogralas, E. Guttman-Yassky, I. Cardinale, M. A. Lowes, and J. G. Krueger. 2009. Effective treatment of psoriasis with etanercept is linked to suppression of IL-17 signaling, not immediate response TNF genes. *J. Allergy Clin. Immunol.* 124: 1022–10.e1–395.
30. Nogralas, K. E., L. C. Zaba, E. Guttman-Yassky, J. Fuentes-Duculan, M. Suárez-Fariñas, I. Cardinale, A. Khatcherian, J. Gonzalez, K. C. Pierson, T. R. White, et al. 2008. Th17 cytokines interleukin (IL)-17 and IL-22 modulate distinct inflammatory and keratinocyte-response pathways. *Br. J. Dermatol.* 159: 1092–1102.
31. Zheng, Y., D. M. Danilenko, P. Valdez, I. Kasman, J. Eastham-Anderson, J. Wu, and W. Ouyang. 2007. Interleukin-22, a T(H)17 cytokine, mediates IL-23-induced dermal inflammation and acanthosis. *Nature* 445: 648–651.
32. Duhén, T., R. Geiger, D. Jarrossay, A. Lanzavecchia, and F. Sallusto. 2009. Production of interleukin 22 but not interleukin 17 by a subset of human skin-homing memory T cells. *Nat. Immunol.* 10: 857–863.
33. Clark, R. A., R. Watanabe, J. E. Teague, C. Schlapbach, M. C. Tawa, N. Adams, A. A. Dorosario, K. S. Chaney, C. S. Cutler, N. R. Leboeuf, et al. 2012. Skin effector memory T cells do not recirculate and provide immune protection in alemtuzumab-treated CTLCL patients. *Sci. Transl. Med.* 4: 117ra117.
34. Mizukawa, Y., Y. Yamazaki, Y. Teraki, J. Hayakawa, K. Hayakawa, H. Nuriya, M. Kohara, and T. Shiohara. 2002. Direct evidence for interferon- γ production by effector-memory-type intraepidermal T cells residing at an effector site of immunopathology in fixed drug eruption. *Am. J. Pathol.* 161: 1337–1347.
35. Zhu, J., T. Peng, C. Johnston, K. Phasouk, A. S. Kask, A. Klock, L. Jin, K. Diem, D. M. Koelle, A. Wald, et al. 2013. Immune surveillance by CD8 α^+ skin-resident T cells in human herpes virus infection. *Nature* 497: 494–497.
36. Schenkel, J. M., K. A. Fraser, V. Vezys, and D. Masopust. 2013. Sensing and alarm function of resident memory CD8 T cells. *Nat. Immunol.* 14: 509–513.
37. Green, C., J. Ferguson, T. Lakshminpathi, and B. E. Johnson. 1988. 311 nm UVB phototherapy—an effective treatment for psoriasis. *Br. J. Dermatol.* 119: 691–696.
38. Krueger, J. G., J. T. Wolfe, R. T. Nabeya, V. P. Vallat, P. Gilleaudeau, N. S. Heftler, L. M. Austin, and A. B. Gottlieb. 1995. Successful ultraviolet B treatment of psoriasis is accompanied by a reversal of keratinocyte pathology and by selective depletion of intraepidermal T cells. *J. Exp. Med.* 182: 2057–2068.
39. Haider, A. S., J. Cohen, J. Fei, L. C. Zaba, I. Cardinale, K. Toyoko, J. Ott, and J. G. Krueger. 2008. Insights into gene modulation by therapeutic TNF and IFN γ antibodies: TNF regulates IFN γ production by T cells and TNF-regulated genes linked to psoriasis transcriptome. *J. Invest. Dermatol.* 128: 655–666.
40. Kagami, S., H. L. Rizzo, J. J. Lee, Y. Koguchi, and A. Blauvelt. 2010. Circulating Th17, Th22, and Th1 cells are increased in psoriasis. *J. Invest. Dermatol.* 130: 1373–1383.
41. Salem, S. A., M. A. Barakat, and C. M. Morcos. 2010. Bath psoralen+ultraviolet A photochemotherapy vs. narrow band-ultraviolet B in psoriasis: a comparison of clinical outcome and effect on circulating T-helper and T-suppressor/cytotoxic cells. *Photodermatol. Photoimmunol. Photomed.* 26: 235–242.
42. Sigmundsdottir, H., A. Johnston, J. E. Gudjonsson, and H. Valdimarsson. 2005. Narrowband-UVB irradiation decreases the production of pro-inflammatory cytokines by stimulated T cells. *Arch. Dermatol. Res.* 297: 39–42.
43. Johnson-Huang, L. M., M. Suárez-Fariñas, M. Sullivan-Whalen, P. Gilleaudeau, J. G. Krueger, and M. A. Lowes. 2010. Effective narrow-band UVB radiation therapy suppresses the IL-23/IL-17 axis in normalized psoriasis plaques. *J. Invest. Dermatol.* 130: 2654–2663.
44. Rácz, E., E. P. Prens, D. Kurek, M. Kant, D. de Ridder, S. Mourits, E. M. Baerveldt, Z. Ozgur, W. F. J. van IJcken, J. D. Laman, et al. 2011. Effective treatment of psoriasis with narrow-band UVB phototherapy is linked to suppression of the IFN and Th17 pathways. *J. Invest. Dermatol.* 131: 1547–1558.