

Epidermolytic hyperkeratosis of the vulva associated with basal cell carcinoma in a patient with vaginal condyloma acuminatum and vaginal intraepithelial neoplasia harboring HPV, type 42

Denisa Kacerovská^{1,2}, Michal Michal^{1,2}, Jana Kašpírková², Dmitry V. Kazakov^{1,2}

¹ Šikl's Department of Pathology, Charles University in Prague, Faculty of Medicine in Pilsen, Pilsen, Czech Republic

² Bioptic Laboratory, Pilsen, Czech Republic

SUMMARY

The occurrence of basal cell carcinoma (BCC) of the vulva is rare. We report the case of a 79-year-old woman with a medical history of intravaginal condyloma acuminatum and vaginal intraepithelial neoplasia 3 (VaIN 3) who presented with a solitary whitish lesion sized 8x5 mm with a central desquamation located on the right labium majus. Histopathologic examination revealed a typical superficial and nodular BCC. Additionally, there were multiple remarkable foci of epidermolytic hyperkeratosis (EH). These foci both merged with superficial BCC or were sharply demarcated from the tumor. Retrospective molecular-biological examination of all the available material revealed HPV type 42 in both condyloma acuminatum and VaIN 3 specimen but not in the BCC associated with EH. To our best knowledge, involvement of the lower female genitalia by EH is a rare finding with six cases published to date. Awareness of EH in this location and its distinction is important because it may be potentially misinterpreted as a viral condyloma.

Keywords: vulva – basal cell carcinoma – epidermolytic hyperkeratosis – human papillomavirus

Epidermolytická hyperkeratóza vulvy asociovaná s bazocelulárním karcinomem u pacientky s vaginálním condyloma acuminatum a vaginální intraepiteliální neoplazií infikovanými HPV typu 42

SOUHRN

Výskyt bazocelulárního karcinomu vulvy je vzácný. Autoři popisují případ 79-leté ženy s anamnézou vaginálního condyloma acuminatum a vaginální intraepiteliální neoplazie 3 (VaIN 3), která měla solitární lézi bělavé barvy s centrální deskvamací, velikosti 8x5 mm v oblasti velkého labia vulvy vpravo. Histopatologické vyšetření prokázalo typický obraz superficiálního a nodulárního bazocelulárního karcinomu. Navíc zde byla přítomná nápadná mnohočetná ložiska epidermolytické hyperkeratózy. Tato ložiska se nacházela v místě superficiálního bazocelulárního karcinomu anebo byla ostře ohraničena od tumoru. Retrospektivní molekulárně biologické vyšetření prokázalo infekci lidskými papilomaviry typu 42, a to jak ve vzorku pocházejícího z vaginálního condyloma acuminatum, tak z VaIN 3, nikoliv však z bazocelulárního karcinomu spojeného s epidermolytickou hyperkeratózou. Podle našich nejlepších znalostí postižení ženského genitálního systému epidermolytickou hyperkeratózou je velmi vzácné s dosud 6 publikovanými případy. Znalost výskytu epidermolytické hyperkeratózy v této oblasti a jeho správné rozpoznání je důležité, neboť může být nesprávně interpretované jako viry způsobená léze.

Klíčová slova: vulva – bazocelulární karcinom – epidermolytická hyperkeratóza – lidský papilomavirus

Cesk Patol 2014; 50(2): 92-94

Basal cell carcinoma (BCC) and epidermolytic hyperkeratosis (EH) are both rare in the vulva. We are reporting on an unusual

Correspondence address:

Denisa Kacerovska, MD, PhD

Šikl's Department of Pathology, Charles University,
Medical Faculty Hospital,

Alej Svobody 80, 304 60, Pilsen, Czech Republic
phone: +420-737220482, Fax: +420-377104650

e-mail: kacarovska@medima.cz

case of BCC carcinoma associated with epidermolytic hyperkeratosis involving the lower female genital tract, a previously unreported event in a patient who also had other lesions in the lower female genital tract, including condyloma acuminatum and vaginal intraepithelial neoplasia.

CASE REPORT

A 79-year-old woman presented with a solitary whitish lesion sized 8 x 5 mm with a central desquamation located on the right

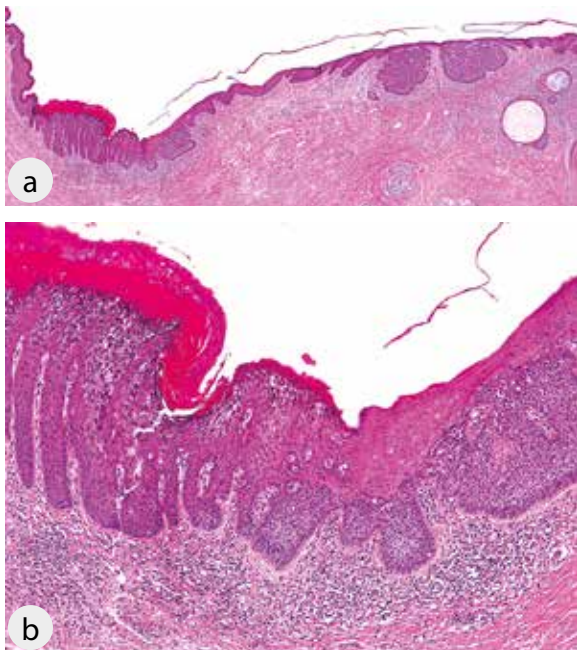


Figure 1. A - Basal cell carcinoma (BCC) associated with foci of epidermolytic hyperkeratosis (EH) (H&E, 20x); **B** - Close-up of the area of EH merging with superficial BCC (H&E, 200x).

labium majus. Histopathologic examination revealed a typical superficial and nodular BCC (Fig. 1A). Additionally, there were multiple remarkable foci of epidermolytic hyperkeratosis composed of cells with cytoplasmic clearing and amphophilic fibrillar material in the lower spinous layer and coarse keratohyaline granules and eosinophilic globules in the upper spinous layer

accompanied with compact hyperkeratosis. These foci both merged with superficial BCC or were sharply demarcated from the tumor (Fig. 1B).

The patient's medical history included an excision of an intravaginal condyloma acuminatum two years ago (Fig. 2B) and a focus of vaginal intraepithelial neoplasia 3 (VaIN 3) from a vaginal vault examined a year ago (Fig. 2C). There was no history of radiotherapy of the pelvic region, immunosuppression or previous trauma in the vulvar region (such as a burn). A retrospective molecular-biological examination performed by PCR and sequencing using general GP5+/6+, and HPV type-specific primers of all the available material revealed HPV type 42 in both the condyloma acuminatum and VaIN 3 specimen retrospectively, but not in the BCC associated with EH.

DISCUSSION

Epidermolytic hyperkeratosis (EH) is an abnormality of epidermal maturation characterized by compact hyperkeratosis, accompanied by granular and vacuolar degeneration of the cells of the spinous and granular layers (1). It may be a congenital or an acquired defect and usually is most commonly identified as a small incidental focus in a specimen submitted for another lesion. This reaction pattern has been described in a variety of acquired solitary skin lesions including fibro-inflammatory lesions, benign and malignant neoplasms (1-4).

Involvement of the lower female genitalia by EH is a rare finding with six cases published to date (5-9). It may occur as a localized/isolated finding or in association with an oral mucosal lesion or as a part of a generalized keratinopathy. Awareness of EH in this location and its distinction is important because it may be potentially misinterpreted as a viral condyloma or even molluscum contagiosum.

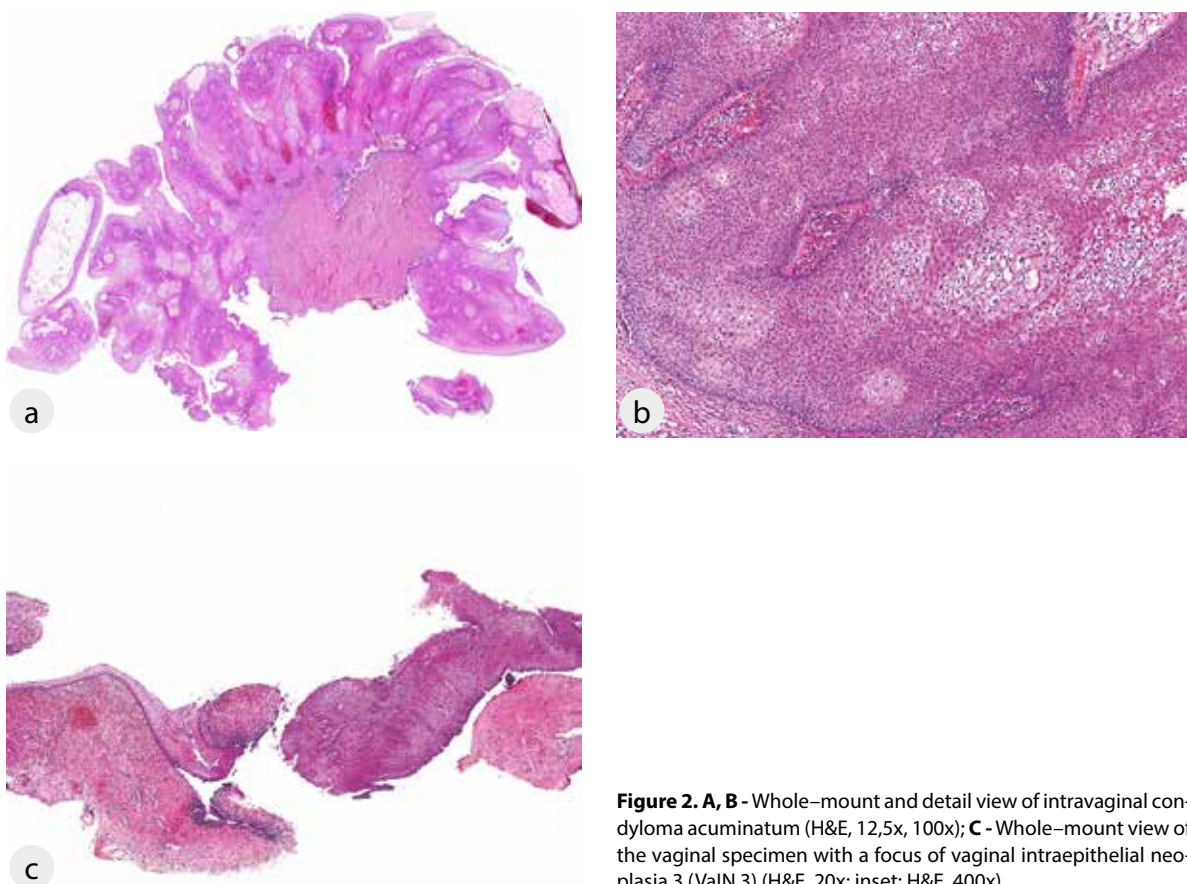


Figure 2. A, B - Whole-mount and detail view of intravaginal condyloma acuminatum (H&E, 12,5x, 100x); **C** - Whole-mount view of the vaginal specimen with a focus of vaginal intraepithelial neoplasia 3 (VaIN 3) (H&E, 20x; inset: H&E, 400x).

Our case represents a co-occurrence of two rare findings on the vulva, i.e. a focus of EH in association with BCC which is an unusual neoplasm in this location. The question is whether these two findings, i.e. EH and BCC are coincidental or related. It is well-known that ultraviolet radiation is an important etiologic factor for BCCs on sun-exposed areas but their occurrence in locations not exposed to the sun raises the possibility of other, not yet defined, etiologic agents. It is interesting in this regard to note that Carlson et al. (10) suggested that it was a possible consequence of clonal expansion of mutated keratinocytes because of long-term exposure to mutagens such as UV light and HPV, thus explaining the presence of EH around neoplastic skin tumors as a reflection of a field cancerization, i.e. multiple genetic defects in tissue, most of which does not result in cancer. Apart from EH, two

other "incidental" findings namely acantholytic dyskeratosis and pronounced acantholysis as found in Hailey-Hailey (10) disease may be considered to be a similar phenomenon. The development of cancers in these regions would be expected to be higher than in areas without these reaction patterns because of the greater possibility of a second mutation leading to malignancy in the mutated population (10). In our case, we identified HPV type 42 in the condyloma acuminatum and ValN 3 specimens but not in the specimen of BCC associated with EH. This low-risk type of HPV belonging to the alpha papillomavirus genus with mucosal tissue tropism has been previously detected in patients with condylomata acuminata (11). Our failure in detection of HPV in vulvar BCC is consistent with other investigations, which have also failed to detect HPV in BCCs from perianal and genital skin (12-14).

LITERATURA

1. **Weedon D.** Weedon's Skin Pathology. 3rd ed. Philadelphia, PA: Churchill Livingstone Elsevier; 2010.
2. **Ackerman AB.** Histopathologic concept of epidermolytic hyperkeratosis. *Arch Dermatol* 1970; 102: 253-259.
3. **Mehregan AH.** Epidermolytic hyperkeratosis: incidental findings in the epidermis and in the intraepidermal eccrine sweat duct units. *J Cutan Pathol* 1978; 5: 76-80.
4. **Mahaisavariya P, Cohen PR, Rapini RP.** Incidental epidermolytic hyperkeratosis. *Am J Dermatopathol* 1995; 17: 23-28.
5. **De Coninck A, Willemsen M, De Dobbeleer G et al.** Vulvar localization of epidermolytic acanthoma. A light- and electron-microscopic study. *Dermatologica* 1986; 172: 276-278.
6. **Quinn TR, Young RH.** Epidermolytic hyperkeratosis in the lower female genital tract: an uncommon stimulant of mucocutaneous papillomavirus infection – a report of two cases. *Int J Gynecol Pathol* 1997; 16: 163-168.
7. **Swann MH, Pujals JS, Pillow J et al.** Localized epidermolytic hyperkeratosis of the female external genitalia. *J Cutan Pathol* 2003; 30: 379-381.
8. **High WA, Miller MD.** Localized epidermolytic hyperkeratosis of the female genitalia: a case report and review of an underappreciated disorder of women. *Med Gen Med* 2005; 7: 33.
9. **Russell P, Valmadre S, Howard V.** Localised epidermolytic hyperkeratosis of the vulva: a case of mistaken identity. *Pathology* 2010; 42: 483-485.
10. **Carlson JA, Scott D, Wharton J et al.** Incidental histopathologic patterns: possible evidence of "field cancerization" surrounding skin tumors. *Am J Dermatopathol* 2001; 23: 494-497.
11. **Tachezy R, Smahelova J, Salakova M et al.** Human papillomavirus genotype distribution in Czech women and men with diseases etiologically linked to HPV. *PLoS One* 2011; 6: e21913.
12. **Gibson GE, Ahmed I.** Perianal and genital basal cell carcinoma: A clinicopathologic review of 51 cases. *J Am Acad Dermatol* 2001; 45: 68-71.
13. **Nehal KS, Levine VJ, Ashinoff R.** Basal cell carcinoma of the genitalia. *Dermatol Surg* 1998; 24: 1361-1363.
14. **Kort R, Faza B, Bouden S.** Perianal basal cell carcinoma. *Int J Dermatol* 1995; 34: 427-428.

INZERCE