

## EPIDIDYMAL PHYSIOLOGY

### II. IMMUNOFLUORESCENT ANALYSES OF EPITHELIAL SECRETION AND ABSORPTION, AND OF BOVINE SPERM MATURATION

L. D. S. BARKER\* AND R. P. AMANN

*Dairy Breeding Research Center, The Pennsylvania State University,  
University Park, Pa. 16802, U.S.A.*

*(Received 22nd September 1970)*

**Summary.** Sites of protein absorption and secretion in the epididymis and changes in sperm antigenicity during their maturation and senescence were investigated. Tissue and sperm samples from normal bulls, unilaterally vasoligated bulls and bulls in which one epididymis was ligated distal to the caput epididymidis were examined using fluorescein-conjugated immune globulins. The globulins were obtained from antisera against spermatozoa from bull cauda epididymidis, ejaculated spermatozoa, plasma from the cauda epididymidis and seminal plasma. In mature spermatids, acrosomal immunofluorescence was homogeneous. After spermatozoa had traversed the first half of the caput epididymidis, the apical body was especially prominent. Specific immunofluorescence of the post-nuclear cap, cytoplasmic droplet, midpiece, and principal piece was not observed except in presumably senescent spermatozoa from spermatozoales.

Non-ciliated, antigen-secreting cells were detected by their immunofluorescence in the epithelium of the efferent ducts within the proximal caput epididymidis. These secretory cells produce sperm-coating proteins which are antigenically similar to certain components of seminal vesicle fluid. Immunofluorescence of the apical cytoplasm and stereocilia in the proximal caput epididymidis indicated that this epithelium probably absorbed sperm-specific proteins emanating from the testis.

Immunofluorescence in the apical cytoplasm of the epithelium lining the corpus and proximal cauda epididymidis was suggestive of secretory activity. Similar fluorescence in the epithelium of the vas deferens may have resulted from the absorption of proteins.

#### INTRODUCTION

The ability of specific regions of the epididymis and vas deferens to secrete and absorb material has been well documented (Mason & Shaver, 1952; Ladman & Young, 1958; Grant, 1958; Burgos, 1964; Martan & Allen, 1964; Crabo,

\* Present address: Department of Biology, Southwest Minnesota State College, Marshall, Minnesota.

1965; Niemi, 1965; Wales, Wallace & White, 1966; Friend & Farquhar, 1967). Although under certain circumstances spermatozoa are absorbed within the excurrent ducts (Simeone & Young, 1931; Amann & Almquist, 1962; Glover, 1962; Salamon, 1968), the physiological importance of this process is uncertain. Evidence for actual phagocytosis or autolysis of large numbers of non-ejaculated spermatozoa under physiological conditions has not been reported. Little is known of the physiological changes associated with sperm maturation or senescence despite numerous reports on morphological and staining differences of spermatozoa from successive regions of the epididymis.

Bull spermatozoa and reproductive fluids are antigenic and spermatozoa obtain coating antigens while in the epididymis and vas deferens (Hunter & Hafs, 1964; Matousek, 1964; Barker & Amann, 1970). The objectives of this study were: (a) to determine the antigenic changes in spermatozoa during their maturation and senescence within the epididymis and (b) to localize areas of antigen secretion and absorption within the epididymis and vas deferens.

## MATERIALS AND METHODS

### *Animals*

Tissue and spermatozoa for this study were taken from three groups of bulls. Group I consisted of eighteen bulls of unknown history, but with macroscopically normal reproductive organs, made available by an abattoir. Group II contained four bulls (255, 256, 257 and 258) unilaterally vasoligated at 18 to 20 weeks of age. Semen was collected (two ejaculates on Mondays, Wednesdays and Fridays) by artificial vagina from each Group-II bull for 6 weeks starting at 75 and 154 weeks of age, and ejaculates were also collected from Bulls 255 and 257 once daily for 12 days immediately preceding slaughter. All four bulls were slaughtered at about 170 weeks of age.

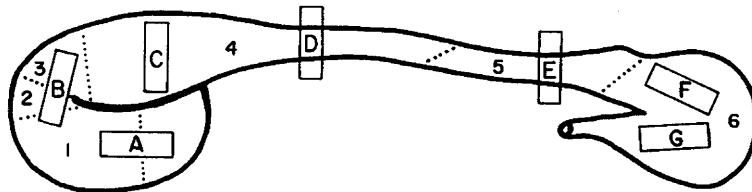
Group III consisted of four bulls (260, 261, 262 and 263) which were unilaterally epididymoligated at 12 weeks of age. The caput-corporis juncture of one epididymis in each bull was isolated, doubly ligated and severed. To obtain vasoepididymal fluid uncontaminated by spermatozoa for use in other analyses (Barker & Amann, 1970), both vasa deferentia were cannulated in Bulls 260 and 261 (Barker, 1969) at 60 weeks of age. Beginning the day after cannulation, ejaculates were collected from Bull 261 once daily (except on Day 11) for 48 days. Nine ejaculates were collected on Day 49, six on Day 50 and the bull was killed on Day 51 at 67 weeks of age. Ejaculates were first collected from Bull 260 2 days after surgery. Daily ejaculates were taken for 13 days (excluding Day 11) and the bull was killed on Day 14 at 64 weeks of age. Bulls 262 and 263 were not cannulated and were sexually rested for 4 weeks before being killed at 64 weeks of age.

### *Sample preparation*

After cannulation, fluids ejaculated into the artificial vagina by Bulls 260 and 261 were examined for the presence of spermatozoa. Only an occasional spermatozoon was seen after 4 days. Starting on Day 6, this ejaculated fluid was clarified by centrifugation at 10,000 g for 15 min at 4° C. The supernatant was

removed and recentrifuged. The final supernatant was designated sperm-free ejaculated fluid and stored at  $-20^{\circ}\text{C}$  for use in other studies (Barker & Amann, 1970). Preparation of the antisera against this fluid and other antigens has been described (Barker & Amann, 1970).

Immediately after a bull was killed, tissue samples were obtained from the testes and seven regions of each epididymis (Text-fig. 1) and frozen at  $-196^{\circ}\text{C}$ . Each vas deferens was sampled proximally, at the level of the dorsal pole of the testis and distally near the ampulla. Tissue was also obtained from the ampullae, seminal vesicles, prostate and bulbourethral glands. The brain, liver, kidney and adrenals from randomly selected bulls were sampled for use in determining the tissue specificity of the antisera. Cryostat sections were fixed in 2-octanol (Maxwell, Ward & Nairn, 1966) and washed in phosphate-buffered saline (Barker, 1969) before use.



TEXT-FIG. 1. Schematic drawing of the right epididymis of a bull showing the locations and approximate limits of the seven regions evaluated (A to G). Region A is in the proximal caput whereas Region G is in the distal cauda epididymidis. For comparison, the six regions described by Nicander (1958) are demarcated by dotted lines.

Sperm smears were prepared from each region for bulls in Groups I and III. Smears also were prepared using cells from the spermatoceles which developed in two Group-II bulls (255 and 257) and in all Group-III bulls. Supplementary smears of cells from spermatoceles of Group-III bulls were prepared with Wright's stain to facilitate identification of macrophages. The remaining fluid was transported to the laboratory where the morphology of the spermatozoa was evaluated by phase-contrast microscopy of wet preparations 2 hr after slaughter. Fluid from each spermatocele was centrifuged and frozen as described for sperm-free ejaculated fluid.

Globulins from rabbit antisera against bull seminal plasma, plasma from the cauda epididymidis, washed ejaculated spermatozoa, washed spermatozoa from the cauda epididymidis and blood serum were conjugated with fluorescein isothiocyanate (Barker, 1969). Non-conjugated antiserum against bovine seminal vesicle fluid was available. Tissue sections and sperm smears were allowed to react with conjugated immune globulin by the direct method. Specificity of fluorescence was established by exposure of samples to conjugated globulin prepared from control rabbit sera and by inhibition tests utilizing non-conjugated immune globulin. Localization of fluorescence in positive reactions was verified by the indirect method using fluorescein-labelled, goat anti-rabbit immune globulin.

## RESULTS

*Effects of ligation and cannulation*

Inflammation resulting from surgery was not excessive and rapidly subsided in all cases. Cannulation resulted in noticeable inflammation of the scrotum of Bull 260 and some swelling persisted. The cannula on the control side of Bull 260 tore loose from the vas deferens and fell out on the 3rd day. Although the cannulae in the ligated sides of Bulls 260 and 261 remained intact for 14 and 29 days, respectively, no vasoepididymal fluid was obtained. From Bull 261, 0.2 to 0.5 ml of fluid was obtained daily for 48 days from the cannula on the control side.

Testicular weights were normal except for Bull 261 in which the testis on the ligated side was markedly lighter than that on the control side (160 g versus 240 g). In all the Group-II and -III bulls, a spermatocele developed just

TABLE 1

INTENSITY AND LOCALIZATION OF IMMUNOFLOUORESCENCE OF UNWASHED EJACULATED BULL SPERMATOZOA\*

<i>Fluorescein-labelled rabbit immune globulin</i>	<i>Sperm component</i>			
	<i>Acrosome</i>	<i>Post-nuclear cap</i>	<i>Midpiece</i>	<i>Principal piece</i>
Anti-washed epididymal spermatozoa	++++	±	±	±
Anti-washed ejaculated spermatozoa	++++	±	±	±
Anti-cauda epididymidis plasma	++++	±	++	+
Anti-seminal plasma	±	+	++	±
Anti-seminal vesicle fluid	±	±	+	+
Anti-blood serum	±	±	++	+
Blood serum	±	+	++	+

\* Pretreatment with unlabelled control globulin blocked all reactions except in the acrosomal region.

proximal to the point of ligation. In addition to small cysts filled with a relatively dry mass of spermatozoa, each spermatocele had portions which contained a thick, creamy, sperm-containing fluid. In each epididymoligated bull, the corpus and cauda epididymidis on the ligated side were smaller than those on the contralateral side. Sufficient fluid for immunological analysis could not be aspirated from the cauda epididymidis on the ligated side of any Group-III bull.

*Sperm immunofluorescence*

Immunofluorescent analyses of ejaculated spermatozoa from normal bulls (Table 1) revealed that only conjugated anti-sperm and anti-cauda epididymidis plasma gave specific reactions. The acrosomal region fluoresced intensely and in each case, previous treatment with homologous unlabelled globulin inhibited the reaction. Acrosomal fluorescence was not diminished by inhibition tests with unlabelled rabbit control globulin, but this pretreatment blocked all reactions of the post-nuclear cap, midpiece and principal piece. With spermatozoa from the testes and epididymides of Group-I bulls and the control side

of Group-III bulls, specific fluorescence of the post-nuclear cap, cytoplasmic droplet, midpiece and principal piece was not observed with conjugated anti-sperm sera.

Differences in the distribution of acrosomal fluorescence were associated with sperm maturation (Pl. 1, Figs. 1 to 4). In young elongated spermatids, the fluorescence was moderately intense and evenly distributed over the entire acrosomal region but, in more mature spermatids, the apical body was especially distinct. In both the spherical and elongated spermatids, the acrosome appeared granular and fluffy around the nucleus. In spermatozoa from Regions A and B of the caput epididymidis, the acrosome still appeared somewhat loosely attached to the nucleus, but the equatorial segment was distinctly non-fluorescent. The apical body region remained exceptionally fluorescent. In spermatozoa from Region C, the acrosome closely surrounded the nucleus but the intensity and distribution of fluorescence were similar to those for spermatozoa in Regions A and B. The acrosome in spermatozoa from Region C and more distal points of the excurrent duct appeared similar to that in ejaculated cells.

Ejaculates were collected from both the bilaterally cannulated Bulls 260 and 261 before slaughter. Spermatozoa from Bull 260 fluoresced as described above. For the control side of Bull 261, the acrosome fluoresced normally in testicular spermatids, but the acrosome of spermatozoa from epididymal Regions A to F had only a weak, dull fluorescence. Nevertheless the distribution of fluorescence and morphology of the acrosome was as described above. The intensity of acrosomal fluorescence was greater in spermatozoa from Region G and the proximal vas deferens and cells with normal immunofluorescence were present in more distal areas of the vas deferens. The obvious treatment difference was that fifteen ejaculates were collected from Bull 261 during the 48 hr before slaughter as compared to sexual rest or collection of two ejaculates during a similar period for all other bulls with a known history.

Fluorescence of spermatids from the ligated side of bulls in Group III was similar to that of cells from the contralateral testis. However, epididymal regions encompassed in the spermatocoele (mainly Region C) contained numerous detached sperm heads, sperm tails and intact spermatozoa which usually did not fluoresce. Phase-contrast microscopy revealed that the acrosome was missing from most spermatozoa in which the acrosomal region did not bind antibodies. In a few spermatozoa, acrosomal fluorescence was typically localized, but was of abnormally low intensity. In such spermatozoa, there often was fluorescence of the post-nuclear cap and midpiece. If, however, the midpiece was markedly swollen and associated with detaching membranous material, it did not fluoresce.

Many small, ill-defined particles were present in each sample of spermatocoele fluid. These particles did not bind any labelled antiserum. Evidence for phagocytosis of spermatozoa was detected only once. The spermatocoele fluid from Bull 263 contained numerous lymphocytes, monocytes, basiphils and a few neutrophils which did not bind sperm specific antiserum. One monocyte had engulfed the annulus region of an intact spermatozoon. White blood cells were not found in spermatocoele fluids from other Group-III bulls.

*Tissue immunofluorescence*

Pretreatment of tissues with non-conjugated anti-blood serum did not inhibit any of the immunofluorescent reactions except where indicated. Unless noted otherwise, tissue reactions described were characteristic of all the epididymides (normal and ligated) which were studied.

A summary of the immunofluorescent reactions observed with conjugated anti-cauda epididymidis plasma following pretreatment with non-conjugated anti-blood serum is presented in Table 2. In Region A, several distinct fluorescent reactions occurred with conjugated anti-cauda epididymidis plasma (Table 2). Non-ciliated cells in the low epithelium of the efferent ducts, adjoining their entrance into the caput epididymidis, contained large droplets which fluoresced very intensely (Pl. 1, Figs. 5 and 6). These cells, hereafter referred to as secretory cells, occurred singly or in groups and varied in morphology from small basal cells containing only one or two fluorescent droplets to large columnar cells filled with numerous droplets of differing size and fluorescent intensity. Secretory cells also fluoresced markedly following exposure to conjugated anti-seminal plasma, anti-seminal vesicle fluid or anti-

TABLE 2

IMMUNOFLUORESCENT REACTIONS OF BOVINE EPIDIDYMAL TISSUE ALLOWED TO REACT WITH CONJUGATED ANTI-BOVINE CAUDA EPIDIDYIMIDIS PLASMA FOLLOWING PRE-TREATMENT WITH ANTI-BOVINE BLOOD SERUM

<i>Region sampled</i>	<i>Corresponding region of Nicander (1958)</i>	<i>Normal bulls (Group I and control sides Groups II and III)</i>	<i>Vasoligated bulls (Group II)</i>	<i>Epididymoligated bulls (Group III)</i>
A	ed  1	Secretory cells, intense; apical cytoplasm and stereocilia, moderate  Diffuse and variable throughout cytoplasm, faint to intense	Secretory cells, intense; apical cytoplasm and stereocilia, moderate  Diffuse and variable throughout cytoplasm, faint to intense	Fewer secretory cells, lower intensity;* apical cytoplasm and stereocilia, moderate  Diffuse and variable throughout cytoplasm, faint to intense
B	2 and 3	Low epithelium containing scattered, intensely reactive secretory cells and isolated cross-sections with a diffuse reaction throughout the cytoplasm  Tall epithelium negative	Scattered secretory cells in low epithelium, intense; intensity and occurrence of diffuse cytoplasm, reaction greater than normal  Tall epithelium negative	Scattered secretory cells in low epithelium, intense; granular reaction of apical cytoplasm and stereocilia, intense  Tall epithelium negative
C	4	Negative	Diffuse reaction throughout cytoplasm in isolated cross-sections, moderate to intense	Spermatocoele(s); epithelium diffuse throughout, faint to moderate
D	4	Occasional reaction of apical cytoplasm (stereocilia?), faint	Occasional reaction of apical cytoplasm (stereocilia?), faint	Apical cytoplasm, moderate; droplets and coagulum in lumen, moderate to intense

TABLE 2—continued

Region sampled	Corresponding region of Nicander (1958)	Normal bulls (Group I and control sides Groups II and III)	Vasoligated bulls (Group II)	Epididymoligated bulls (Group III)
E	5	Occasional reaction of apical cytoplasm (stereocilia?), faint	Apical cytoplasm, intense	Apical cytoplasm, moderate; droplets and coagulum in lumen, moderate to intense
F	6 (proximal)	Apical cytoplasm, negative to moderate; † basal granules (distally), intense	Diffuse throughout entire cytoplasm, negative to moderate; basal granules smaller and less intense than normal; spermato-coele epithelium diffuse throughout, faint to moderate	Basal granules normal, intense
G	6 (distal)	Variable, diffuse reaction of basal cytoplasm, faint to moderate; numerous, large basal granules; intense	Diffuse throughout entire cytoplasm, negative to moderate basal granules smaller and less intense than normal; spermato-coele epithelium diffuse throughout, faint to moderate	Apical cytoplasm, negative; droplets and coagulum in lumen, moderate to intense; basal granules, intense
Vas deferens (proximal)		Variable, diffuse reaction of basal cytoplasm, faint to moderate; numerous, large basal granules, intense; granular reaction of apical cytoplasm, moderate to intense	Diffuse throughout entire cytoplasm, negative to moderate; basal granules smaller and less intense than normal; spermato-coele epithelium diffuse throughout, faint to moderate	Apical cytoplasm, moderate to intense; droplets and coagulum in lumen, moderate to intense; basal granules, intense

\* Secretory cells on the non-ligated side were similarly few in number and of low intensity.

† Only for about half of the caudae examined, others were negative.

epididymal spermatozoa. Pretreatment with non-conjugated anti-seminal vesicle fluid blocked the immunofluorescent reactions of the secretory cells. In contrast, most secretory cells in Region A of epididymides from epididymoligated bulls did not react with conjugated antisera. Those cells which did fluoresce contained relatively small secretory droplets of which only about one-half fluoresced completely; a halo of fluorescence surrounded the other droplets. Since reactions of the secretory cells on the control and epididymoligated sides of the Group-III bulls were similar, conditions imposed by ligation probably were not responsible for the diminished fluorescence.

In the epithelium of certain areas of the distal efferent ducts and proximal ductus epididymidis (Region A), fluorescence with conjugated anti-cauda epididymidis plasma was localized in the apical cytoplasm and stereocilia. A stronger reaction of the stereocilia occurred with both conjugated anti-sperm sera (Pl. 1, Fig. 7), but the stereocilia were faint with conjugated anti-seminal plasma or conjugated anti-seminal vesicle fluid. In the high epithelium

found distally in Region A (Pl. 1, Fig. 8), conjugated anti-cauda epididymidis plasma gave a variable and diffuse reaction of the apical and basal cytoplasm. The apical fluorescence also occurred with both of the conjugated anti-sperm sera, but was faint or negative with conjugated anti-seminal plasma or conjugated anti-seminal vesicle fluid. Pretreatment with non-conjugated anti-seminal vesicle fluid did not block the fluorescence. It is concluded that the primary antigens responsible for these reactions are of testicular origin, differ from those causing fluorescence of the secretory cells described above, and are not found in seminal vesicle fluid.

In Region B (Table 2), isolated tubular cross-sections in normal epididymides contained epithelium which gave a faint, diffuse reaction with conjugated anti-cauda epididymidis plasma. In tissue proximal to a vasoligation, however, such cross-sections of the duct were much more numerous and the diffuse fluorescence was more intense. For tissue proximal to epididymoligation, however, the reaction was localized to the apical cytoplasm and also occurred with both of the conjugated anti-sperm sera. Reactions with conjugated anti-seminal vesicle fluid or anti-seminal plasma were similar but less intense.

The diffuse fluorescence uniform throughout the epithelium in Region C from the vasoligated sides of Group-II bulls (Table 2) was identical to that observed in Region B.

Tissue from Region D of normal and vasoligated epididymides reacted only with conjugated anti-cauda epididymidis plasma. In tissue from Region D distal to an epididymoligation, the apical cytoplasm (excluding the stereocilia)

#### EXPLANATION OF PLATE 1

FIGS. 1 to 4. Immunofluorescence of the spermatid and spermatozoan acrosome. Smears allowed to react with unlabelled anti-blood serum followed by labelled anti-cauda epididymidis spermatozoa washed four times.  $\times 1250$ .

FIGS. 1 and 2. Spermatids from the testis. The acrosome is fluffy with fluorescence either evenly distributed or more conspicuous in the apical body region. Cytoplasmic droplets (D) did not fluoresce.

FIG. 3. Spermatozoa from the proximal caput epididymidis. The acrosome is still fluffy around the nucleus, but the equatorial segment (ES) area did not fluoresce.

FIG. 4. Spermatozoa from the corpus epididymidis. The acrosome closely surrounds the nucleus and the equatorial segment remains non-fluorescent.

FIG. 5. Immunofluorescent secretory cells in the epithelium of Region A of the epididymis. Basement membrane (BM). Allowed to react with unlabelled anti-blood serum followed by labelled anti-cauda epididymidis plasma.  $\times 285$ .

FIG. 6. Immunofluorescent secretory cell in the process of releasing droplets into the lumen (L) in Region A of the epididymis. Stereocilia (SC) are negative. Allowed to react with unlabelled anti-blood serum followed by labelled anti-cauda epididymidis plasma.  $\times 640$ .

FIG. 7. Immunofluorescent stereocilia in the epithelium of Region A of the epididymis. Allowed to react with labelled anti-cauda epididymidis spermatozoa washed four times.  $\times 425$ .

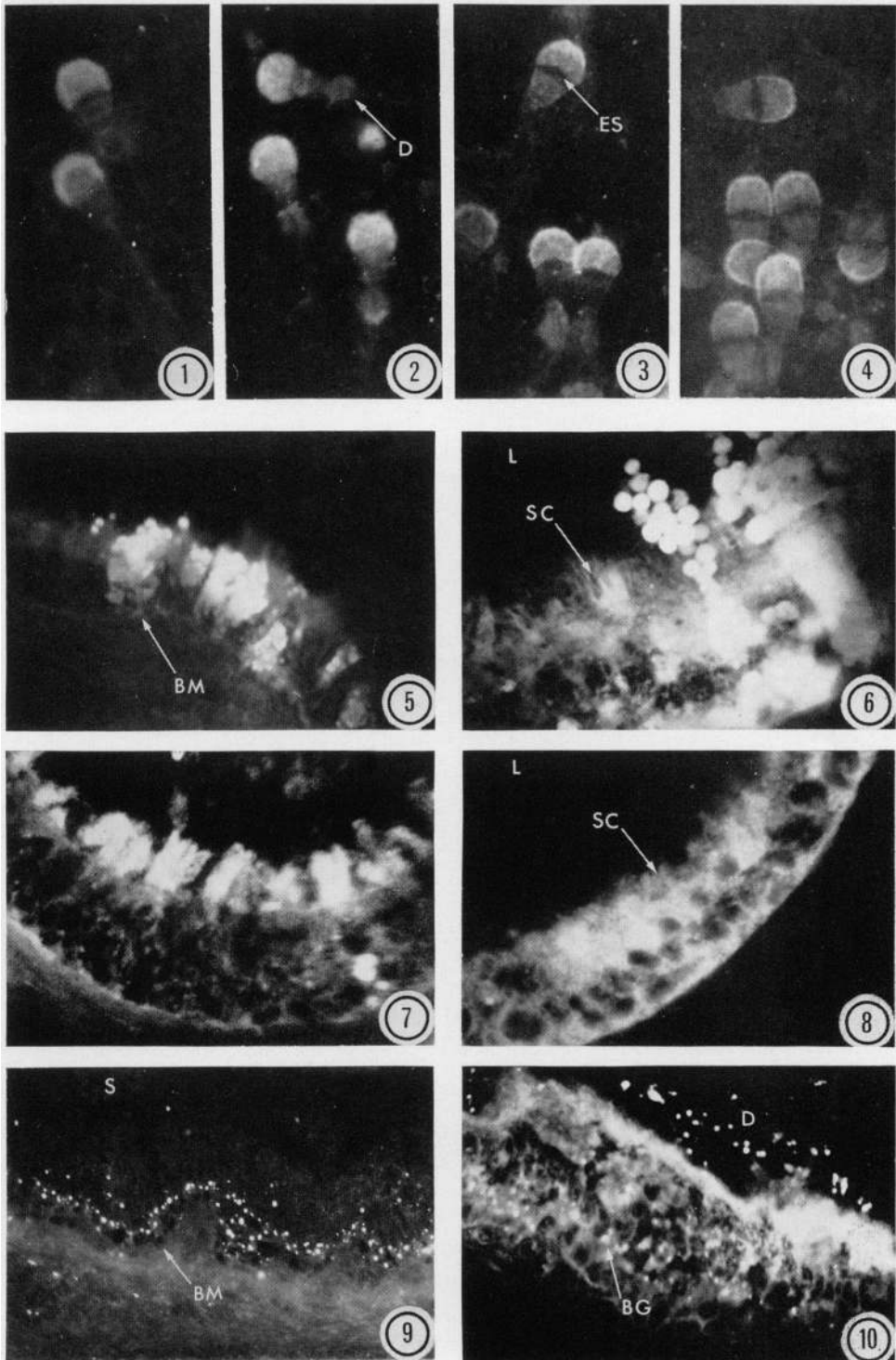
FIG. 8. Diffuse immunofluorescence of the epithelium in Region A of the epididymis. Lumen (L). Stereocilia (SC). Allowed to react with unlabelled anti-blood serum followed by labelled anti-cauda epididymidis plasma.  $\times 285$ .

FIG. 9. Immunofluorescence basal granules in the epithelium of Region G of the epididymis. Spermatozoa (S) in the lumen. Basement membrane (BM). Allowed to react with labelled anti-cauda epididymidis spermatozoa washed four times.  $\times 285$ .

FIG. 10. Immunofluorescence of the epithelium in Region H of the vas deferens from the ligated side of a Group-III bull. The apical cytoplasm, droplets (D) in the lumen and basal granules (BG) are positive. Allowed to react with labelled anti-cauda epididymidis plasma.  $\times 285$ .



PLATE I



*Facing p. 326*

and small spherical droplets within the tubule lumen were fluorescent. The lumen also contained a sparse, granular coagulum which fluoresced markedly after reaction with conjugated anti-cauda epididymidis plasma, but which gave only a faint reaction with conjugated anti-sperm serum. Similar droplets and coagulum were present in other regions distal to the epididymoligation.

About one-half of the normal tissue samples from Region F exhibited apical fluorescence when allowed to react with conjugated anti-cauda epididymidis plasma. This reaction did not appear to include the stereocilia and was faint with conjugated anti-epididymal spermatozoa, but negative with conjugated anti-ejaculated spermatozoa, anti-seminal plasma and anti-seminal vesicle fluid. The apical cytoplasm of Region G from normal epididymides did not react with any of the conjugated antisera.

In normal epididymides, intensely fluorescent granules were conspicuous in the epithelium of the duct at the distal end of Region F. Although most granules were located basally, a few were always present apically. These granules fluoresced intensely with conjugated anti-cauda epididymidis plasma, anti-sperm sera and anti-seminal plasma, but only faintly with conjugated anti-blood serum. Pretreatment with anti-seminal plasma or anti-ejaculated spermatozoa did not completely inhibit the fluorescence caused by conjugated anti-cauda epididymidis plasma or anti-epididymal spermatozoa. Pretreatment with anti-cauda epididymidis plasma or anti-epididymal spermatozoa, however, inhibited the reaction of the granules with all conjugated anti-sera. Proximal to a vasoligation, the immunofluorescent granules were smaller and seemed to fluoresce less intensely than those in normal or ligated epididymides. In Region G (Pl. 1, Fig. 9) and the proximal vas deferens of normal epididymides, the diameter of the granules was two to three times that of the largest granules in Region F. Similar granules were identified in Regions F, G and the proximal vas deferens (Pl. 1, Fig. 10) distal to an epididymoligation.

In the central and distal portions of the normal vas deferens, occasional, small fluorescent basal granules were found. These were similar to those in more proximal regions. Occasionally, following treatment with conjugated anti-cauda epididymidis plasma, apical cytoplasmic fluorescence was detected. Distal to a vasoligation, the vas deferens epithelium was negative when allowed to react with each conjugated antiserum.

#### *Spermatocoele tissue*

Spermatocoeles resulting from vasoligation were located in epididymal Regions F and G or distended the vas deferens just proximal to the ligation. Spermatocoeles resulting from epididymoligation were confined, primarily, to Regions B and C. Regardless of the location of a spermatocoele, its tissue usually gave a distinct, diffuse immunofluorescence with conjugated anti-epididymal plasma. A positive reaction with other conjugated anti-sera was not observed. In spermatocoele tissue, numerous macrophages were present but these did not fluoresce when allowed to react with conjugated antisera.

#### *Other tissues*

Seminal vesicle tissue exposed to conjugated anti-seminal plasma had granu-

lar fluorescence in the apical cytoplasm and fluorescent droplets were sometimes present in the lumen. A similar pattern of fluorescence was observed with the indirect technique using anti-seminal vesicle fluid. A less intense, but similarly localized, fluorescence followed reaction with conjugated anti-cauda epididymidis plasma. Detailed discussion of immunofluorescent reactions for testis, ampulla, prostate, bulbourethral glands, adrenal, brain, kidney and liver are presented elsewhere (Barker, 1969).

## DISCUSSION AND CONCLUSIONS

The non-ciliated secretory cells detected by immunofluoresis in the caput epididymidis appeared similar to the PAS-positive, acid phosphatase-containing holocrine cells found in various regions of epididymides from rats, mice, guinea-pigs and humans (Martan & Risley, 1963a, b; Martan & Allen, 1964; Martan, Risley & Hruban, 1964). Localization of secretory cells in the efferent duct portion of the caput epididymidis of the bull indicates that these are not the cells described by Dubois (1964) which were located in the tall epithelium of Region 1 as described by Nicander (1958). The range in morphology of bull antigen-secreting cells paralleled the stages in development of mouse holocrine cells (Martan & Allen, 1964). However, intact secretory cells were not released; only antigen-containing droplets from secretory cells were detected in the lumen of the bovine ductus epididymidis. Furthermore, although these secretory droplets were PAS-positive, acid phosphatases could not be demonstrated (Amann, unpublished). Immunofluorescent cross-reactions indicated that the antigenic substance(s) was present both in plasma from the cauda epididymidis and in seminal vesicle fluid, but absent from blood serum. The morphology and incidence of secretory cells were similar in the epididymides of the sexually rested bulls and those from which ejaculates were collected and were not influenced by vasoligation or epididymoligation. This consistency is contrary to the report that mating increased the occurrence of mature holocrine cells in rats (Martan & Risley, 1963b). However, secretory cells in tissues from Group-III bulls were virtually devoid of immunofluorescent material. These 64- to 67-week-old bulls were the youngest studied. The paucity of antigen in their secretory cells may reflect incomplete attainment by the epididymis of secretory capabilities characteristic of mature bulls.

The fluorescence of stereocilia and apical cytoplasm in the epithelium of Region A is thought to reflect absorption of antigens from the lumen of the ductus epididymidis. Since pretreatment with anti-seminal vesicle fluid failed to block the reaction with conjugated anti-cauda epididymidis plasma, antigens other than those common to epididymal and seminal vesicle fluids (Barker & Amann, 1970) were involved. Apparently the immunofluorescence of the stereocilia was caused mainly by sperm-specific antigens which had been absorbed by the epithelium. Immunofluorescence in the proximal caput epididymidis increased following ligation of the excurrent duct. This fact and inhibition tests with non-conjugated globulin support the concept that sperm-specific antigens as well as fluid are absorbed by this tissue.

An intense fluorescent reaction of the apical cytoplasm in Region F (proximal

cauda epididymidis) and the proximal vas deferens of normal bulls occurred with conjugated anti-cauda epididymidis plasma, but fluorescence was faint or absent with conjugated anti-sperm sera. Thus, in normal bulls, sperm-specific antigens probably were not absorbed here. For similar tissues from vasoligated bulls (Group II), apical fluorescence was consistently intense after reaction with conjugated anti-sperm sera as well as anti-cauda epididymidis plasma. These immunofluorescent reactions for the Group-II bulls are consistent with the assumption that spermatozoa trapped by ligation were absorbed by the epithelium of the duct. Evidence reported by Grant (1958), Niemi (1965) and Friend & Farquhar (1967) for rats and by Nicander (1958) for stallions, bulls and rams indicates that the epithelia of the corpus and cauda epididymidis and vas deferens have absorptive capabilities.

In contrast to the above evidence for an absorptive function, immunofluorescence of tissues from epididymoligated bulls revealed that the corpus and proximal cauda epididymidis secrete antigenic substances. Although these tissues were not bathed by fluid from the caput epididymidis and testis, their epithelium had intense apical fluorescence when allowed to react with conjugated anti-epididymal plasma. Immunofluorescing substances were also present in the tubule lumen. Fluorescence was not conspicuous using conjugated antisera other than anti-cauda epididymidis plasma. Immunodiffusion tests (Barker & Amann, 1970) showed that some antigens in normal cauda epididymidis plasma were absent in fluid recovered from spermatocoeles in the caput epididymidis. Thus, under physiological conditions, the corpus and cauda epididymidis probably secrete antigens in addition to those secreted by the testis or caput epididymidis. Failure to detect specific antigens in the epithelium of the vas deferens distal to vasoligation suggests that immunofluorescent reactions found in normal vasa deferentia may have resulted from absorption of antigens emanating from more proximal regions of the duct.

The immunofluorescent characteristics of basal granules detected in the cauda epididymidis and proximal vas deferens of normal bulls indicated that these granules might represent lysosome-like structures containing sperm antigens absorbed from the lumen of the duct (Barker & Amann, 1969). However, similar granules subsequently were detected in the cauda epididymidis of each epididymoligated bull. Spermatozoa had never been in contact with these tissues. This unequivocally demonstrates that immunofluorescence of the basal granules is not caused by sperm-specific antigens. If, indeed, the basal granules are lysosomes, they undoubtedly contain many enzymes found in spermatozoa, plasma from the cauda epididymidis or seminal plasma. Both the sperm acrosome and cytoplasmic droplet contain lysosomal enzymes (Dott & Dingle, 1968; Allison & Hartree, 1970). Thus, the antigenicity of lysosomal and other enzymes should not be overlooked and may explain certain immunofluorescent reactions.

Losos (1967) allowed tissue from the bull cauda epididymidis to react with conjugated anti-epididymal sperm sera. He reported a uniform fluorescence of the epithelium but did not mention basal granules. His epididymal sperm antigen, however, was prepared by rinsing epididymal tissue which had been frozen, thawed and macerated. The antigen preparation was contaminated

with tissue cells and, thus, was markedly different from those used in this study.

Morphological differences in the acrosome of spermatozoa from the testis, caput epididymidis and more distal locations are probably related to sperm maturation. Based on immunofluorescence, the major acrosomal modifications were completed in the caput epididymidis. The observed changes agree with maturation-associated alterations in bull sperm ultrastructure (Dickey, 1965), but the virtual non-fluorescence of the equatorial segment of the acrosome (Pl. 1, Fig. 4) remains unexplained. Since bovine cauda epididymidis plasma contains some sperm antigens (Barker & Amann, 1970), a reaction of the sperm acrosome with conjugated anti-epididymal plasma was not surprising.

Although the intensity of acrosomal fluorescence was usually similar for all bulls, spermatozoa from the caput, corpus and proximal cauda of the control epididymis of Bull 261 (ejaculates were collected fifteen times during the 48 hr before slaughter) had acrosomal fluorescence of sub-normal intensity. The frequent ejaculations of this young bull may have altered the sperm environment by removing normal seminal plasma components quicker than they could be produced. Specifically, lack of sperm coating antigen(s) perhaps caused a change in cell membrane permeability so that acrosomal antigens leached out resulting in a decrease in acrosomal immunofluorescence. Amann & Almquist (1962) found that when eleven to twenty-six ejaculates were collected from bulls before slaughter, the percentages of eosinophilic spermatozoa in the corpus and cauda epididymidis increased significantly. They concluded that this sperm eosinophilia was associated with an increase in membrane permeability.

On the basis of immunodiffusion analyses, Barker & Amann (1970) suggested that both spermatozoa from the cauda epididymidis and ejaculated spermatozoa bind coating antigen(s) which are secreted by the proximal caput epididymidis and are also present in seminal vesicle fluid. However, we were unable to detect coating antigens on spermatozoa by immunofluorescent techniques. Probably, the immunofluorescence associated with antibodies against coating antigens is relatively weak compared to that from acrosomal antibodies and indistinguishable from the non-specific fluorescence associated with the conjugated globulin from control sera.

Evaluation of cells from spermatocoeles gave an insight on the changes associated with bull sperm senescence. Initially, permeability of the cell membrane apparently increases, allowing antigenic components in the post-nuclear cap and midpiece to be exposed. Only for certain spermatocoele spermatozoa were the post-nuclear cap and midpiece fluorescent. Concomitantly, the increased permeability allows loss of acrosomal antigenic material as evidenced by a decrease in acrosomal fluorescence. Other data (Barker & Amann, 1970) indicate that washing can alter sperm cell membrane permeability; antigens originating in the sperm acrosome and nucleus were detected in the washing medium. This interpretation is consistent with studies of bull sperm morphology (Marshall & Saacke, 1967) and ultrastructure (Hancock, 1952; Saacke & Almquist, 1964) which revealed that, in ageing or dead spermatozoa the acrosome swells, the cell membrane deteriorates and the acrosomal substance is apparently dispersed.

## ACKNOWLEDGMENTS

Authorized for publication on 3rd September 1969 as paper No. 3654 in the journal series of the Pennsylvania Agricultural Experiment Station. The senior author was recipient of an NDEA Fellowship. Appreciation is expressed to Dr L. C. Griel, Jr, Dr L. R. Harrison, Dr J. F. Hokanson and Dr D. M. Murphy of the Department of Veterinary Science for performing the experimental surgery.

## REFERENCES

- ALLISON, A. C. & HARTREE, E. F. (1970) Lysosomal enzymes in the acrosome and their possible rôle in fertilization. *J. Reprod. Fert.* **21**, 501.
- AMANN, R. P. & ALMQUIST, J. O. (1962) Reproductive capacity of dairy bulls. VI. Effect of unilateral vasectomy and ejaculation frequency on sperm reserves; aspects of epididymal physiology. *J. Reprod. Fert.* **3**, 260.
- BARKER, L. D. S. (1969) *Physiology of the bull reproductive system as revealed by immunofluorescent analyses*. Ph.D. thesis, The Pennsylvania State University, University Park.
- BARKER, L. D. S. & AMANN, R. P. (1969) Sperm antigens and their localization within the bovine epididymal epithelium. *J. Reprod. Fert.* **18**, 155.
- BARKER, L. D. S. & AMANN, R. P. (1970) Epididymal physiology. I. Specificity of antisera against bull spermatozoa and reproductive fluids. *J. Reprod. Fert.* **22**, 441.
- BURGOS, M. H. (1964) Uptake of colloidal particles by cells of the epididymis. *Anat. Rec.* **148**, 517.
- CRABO, B. (1965) Studies on the composition of epididymal content in bulls and boars. *Acta vet. scand.* **6**, Suppl. 5.
- DICKEY, J. F. (1965) *An electron microscope study of bovine spermatozoa undergoing maturation in the male reproductive system*. Ph.D. thesis, The Pennsylvania State University, University Park.
- DOTT, H. M. & DINGLE, J. T. (1968) Distribution of lysosomal enzymes in the spermatozoa and cytoplasmic droplets of bull and ram. *Expt Cell Res.* **52**, 523.
- DUBOIS, M. (1964) Contribution à l'histophysiologie de l'épididyme chez le taureau. *C. r. Séanc. Soc. Biol.* **158**, 1490.
- FRIEND, D. S. & FARQUHAR, M. G. (1967) Functions of coated vesicles during protein absorption in the rat vas deferens. *J. Cell Biol.* **35**, 357.
- GLOVER, T. D. (1962) The response of rabbit spermatozoa to artificial cryptorchidism and ligation of the epididymis. *J. Endocr.* **23**, 317.
- GRANT, J. H. (1958) The passage of trypan blue through the epididymis and its uptake by this organ. *Stud. Fert.* **10**, 95.
- HANCOCK, J. L. (1952) The morphology of bull spermatozoa. *J. exp. Biol.* **29**, 445.
- HUNTER, A. G. & HAFS, H. D. (1964) Antigenicity and cross-reactions of bovine spermatozoa. *J. Reprod. Fert.* **7**, 357.
- LADMAN, A. J. & YOUNG, W. C. (1958) An electron microscopic study of the ductuli efferentes and rete testis of the guinea pig. *J. biophys. biochem. Cytol.* **4**, 219.
- LOSOS, G. J. (1967) *Experimental induction of testicular lesions in bulls by autoimmunization*. Ph.D. thesis, Cornell University, Ithaca.
- MARSHALL, C. E. & SAACKE, R. G. (1967) Acrosomal cap of living bovine spermatozoa. *J. Anim. Sci.* **26**, 947.
- MARTAN, J. & ALLEN, J. M. (1964) Morphological and cytochemical properties of the holocrine cells in the epididymis of the mouse. *J. Histochem. Cytochem.* **12**, 628.
- MARTAN, J. & RISLEY, P. L. (1963a) Holocrine secretory cells of the rat epididymis. *Anat. Rec.* **146**, 173.
- MARTAN, J. & RISLEY, P. L. (1963b) The epididymis of mated and unmated rats. *J. Morph.* **113**, 1.
- MARTAN, J., RISLEY, P. L. & HRUBAN, Z. (1964) Holocrine cells of the human epididymis. *Fert. Steril.* **15**, 180.
- MASON, K. E. & SHAVER, S. L. (1952) Some functions of the caput epididymidis. *Ann. N.Y. Acad. Sci.* **55**, 585.
- MATOUSEK, J. (1964) Antigenic characteristics of spermatozoa from bulls, rams and boars. I. Erythrocytic antigens in bull spermatozoa. *J. Reprod. Fert.* **8**, 1.
- MAXWELL, A., WARD, H. A. & NAIRN, R. C. (1966) Freezing in an isopentane-liquid nitrogen mixture and storage in 2-octanol: technical improvements for immunofluorescence. *Stain Technol.* **44**, 305.

- NICANDER, L. (1958) Studies on the regional histology and cytochemistry of the ductus epididymidis in stallions, rams and bulls. *Acta morph. neerl.-scand.* **1**, 337.
- NIEMI, M. (1965) The fine structure and histochemistry of the epithelial cells of the rat vas deferens. *Acta anat.* **60**, 207.
- SAACKE, R. G. & ALMQUIST, J. O. (1964) Ultrastructure of bovine spermatozoa. I. The head of normal, ejaculated sperm. *Am. J. Anat.* **115**, 143.
- SALAMON, S. (1968) Viability and morphology of ram spermatozoa in the ligated epididymis. *Aust. J. biol. Sci.* **21**, 769.
- SIMEONE, F. A. & YOUNG, W. C. (1931) A study of the function of the epididymis. IV. The fate of non-ejaculated spermatozoa in the genital tract of the male guinea pig. *J. exp. Biol.* **8**, 163.
- WALES, R. G., WALLACE, J. C. & WHITE, I. G. (1966) Composition of bull epididymal and testicular fluid. *J. Reprod. Fert.* **12**, 139.