

Episodic retrieval activates the precuneus irrespective of the imagery content of word pair associates

A PET study

B. J. Krause,^{1,2} D. Schmidt,^{1,2} F. M. Mottaghy,^{1,2} J. Taylor,² U. Halsband,³ H. Herzog,² L. Tellmann² and H.-W. Müller-Gärtner^{1,2}

¹Department of Nuclear Medicine, Heinrich-Heine-University Hospital, Düsseldorf, ²Institute of Medicine, Research Center, Jülich and ³Institute for Medical Psychology and Behavioural Neurobiology, Eberhard-Karls-University, Tübingen, Germany

Correspondence to: B. J. Krause, Department of Nuclear Medicine, Heinrich-Heine-University Hospital Düsseldorf, Moorenstrasse 5, D-40225 Düsseldorf, Germany

Summary

The aim of this study was to evaluate further the role of the precuneus in episodic memory retrieval. The specific hypothesis addressed was that the precuneus is involved in episodic memory retrieval irrespective of the imagery content. Two groups of six right-handed normal male volunteers took part in the study. Each subject underwent six [¹⁵O]butanol-PET scans. In each of the six trials, the memory task began with the injection of a bolus of 1500 MBq of [¹⁵O]butanol. For Group 1, 12 word pair associates were presented visually, for Group 2 auditorily. The subjects of each group had to learn and retrieve two sets of 12 word pairs each. One set consisted of highly

imaginable words and another one of abstract words. Words of both sets were not related semantically, representing 'hard' associations. The presentations of nonsense words served as reference conditions. We demonstrate that the precuneus shows consistent activation during episodic memory retrieval. Precuneus activation occurred in visual and auditory presentation modalities and for both highly imaginable and abstract words. The present study therefore provides further evidence that the precuneus has a specific function in episodic memory retrieval as a multimodal association area.

Keywords: episodic memory retrieval; word pair associates; precuneus; imagery content; PET

Abbreviations: ANCOVA = analysis of covariance; BA = Brodmann area; rCBF = regional cerebral blood flow; SPM = statistical parametric map; SPM{*t*} = SPM of the *t*-statistic

Introduction

Several systems of memory have been described. Among these systems, it is agreed that there are two major ones, as shown in studies performed on human subjects (patients and normals) and animals. (i) 'Explicit' or 'declarative' memory which enables remembering of previously experienced events. Declarative memory is often subdivided into 'episodic' memory relating to the recall of personal events in the subject's life, and general knowledge of the world, referred to as 'semantic' memory (Warrington, 1975; Squire, 1986; Tulving, 1987). (ii) 'Implicit' or 'nondeclarative' memory which allows for accessing a variety of information such as types of skill learning, conditioning and priming, the latter representing facilitation in responding to a stimulus based on past exposure (Squire, 1986; Tulving, 1987; Halsband and Freund, 1990).

A network of prefrontal and posterior cortical structures (Warrington and Weiskrantz, 1982; Goldman-Rakic, 1988) which possesses distinct roles in the different components of episodic memory has been proposed. Previous investigations delineated widespread brain systems in verbal episodic memory including the prefrontal cortex (e.g. Goldman-Rakic, 1987; Grasby *et al.*, 1993; Fletcher *et al.*, 1995*a, b*; Fuster, 1995; Blaxton *et al.*, 1996; Halsband *et al.*, 1998) and the cingulate gyrus (e.g. Valenstein *et al.*, 1987; Rudge and Warrington, 1991; Halsband *et al.*, 1998).

In the present study, we examined the functional anatomy of paired word associates memory tasks. We chose a paradigm in which the word pairs (highly imaginable as well as abstract) were semantically unrelated. Abstract and highly imaginable paired word associates were presented visually

or auditorily during either the encoding or retrieval phase in two groups of six normal subjects each. Regional cerebral blood flow (rCBF) was measured using PET with [¹⁵O]butanol during episodic encoding and retrieval. Two reference tasks were employed during scanning, in which subjects were presented with one or two nonsense words.

Activation of the posterior medial parietal lobe at or near the precuneus has been reported in a number of studies on episodic memory retrieval, and an involvement of the precuneus in imagery processes has been postulated (Grasby *et al.*, 1993; Shallice *et al.*, 1994; Tulving *et al.*, 1994; Andreasen *et al.*, 1995b; Buckner *et al.*, 1995). More recently, it has been suggested by Buckner *et al.* (1996) that there are multiple functionally dissociable areas in the precuneus: a posterior and an anterior area. The posterior area often is activated during episodic retrieval (Andreasen *et al.*, 1995b; Buckner *et al.*, 1995, 1996; Fletcher *et al.*, 1995b), whereas the more anterior area reveals increased rCBF in the context of retrieval effort or mode (Buckner *et al.*, 1995, 1996; Fletcher *et al.*, 1995b, 1996). Fletcher *et al.* (1995b, 1996) showed rCBF changes in medial parietal cortex by manipulating imagery demands in episodic retrieval. However, the location of the area was in the more anterior area of the medial parietal lobe. In the study by Buckner *et al.* (1996), the precuneus activation was not changed although imagery contributions were manipulated. The authors concluded that their findings did not support the hypothesis that the precuneus only participates in imagery processes inherent to episodic retrieval.

The aim of our studies was to specify further the functional role of the precuneus in episodic memory retrieval comparing highly imaginable versus abstract words using differing presentation modalities (verbal–visual versus verbal–auditory). We provide evidence that the precuneus is not only activated significantly during the recall of highly imaginable words but also during the recall of abstract words, and plays a major role in a network of distributed brain regions in episodic associative memory retrieval.

Material and methods

Subjects

Two groups of six right-handed male volunteers each (mean age Group 1, 27.5 ± 1.0 years; Group 2, 27.5 ± 1.4 years), with no history of neurological or psychiatric illness, took part in the study which had been approved by the local ethical committee and federal authorities. All subjects gave informed, written consent for participation in the study. Each subject underwent six PET scans within a single session and an MRI scan on a different day.

Paired word association learning

A paired word associate memory task was used. Subjects were presented with word pair associates that were not related

semantically. These ‘hard’ word associations [introduced by Wechsler (1945) in his associative learning task, Subtest VII, of the Wechsler Memory Scale] were used to increase the mnemonic demands. Study words were two-syllable German words taken from a German linguistic database (800 nouns) (Baschek *et al.*, 1977) which is based on work by Paivio *et al.* (1968). Words were between four and seven letters in length and of moderate frequency (Meier, 1964). The degree of imagery and abstractness is based on a seven-point scale where 1 represents a very abstract word and 7 a highly imaginable word (Baschek *et al.*, 1977). In our study design, words with a scale value ranging from 5 to 7 were considered to be highly imaginable, words with a value ranging from 2 to 4 abstract.

Each subject from the two study groups underwent six PET scans. One group was presented with the verbal material visually, the other group auditorily.

Visual presentation

Word pairs (with the second word under the first to avoid lateralization effects) or single words (centred) were presented on a 17 inch computer monitor placed at a distance of ~70 cm from the eyes (Font: Times New Roman, size: 72 points). The letters were white on a black screen.

Auditory presentation

One list with highly imaginable and one list with abstract word pairs were presented binaurally to Group 2. The subjects had their eyes closed and covered during the auditory presentation.

PET scanning

Scans of rCBF were obtained for each subject using a GE PC4096 Plus scanner which provides 15 transverse sections through the brain spaced 6.5 mm apart (centre to centre). The physical characteristics of this scanner have been described previously (Rota Kops *et al.*, 1990). Transmission scans performed with a ⁶⁸Ge/⁶⁸Ga rotating line source were used for measured attenuation correction. A laser-positioning system helped to record the most caudal images 27 mm above and parallel to the canthomeatal line. On each of the six trials, the cognition task started with the intravenous bolus administration of 1500 MBq of [¹⁵O]butanol (half-life 123 s) (Herzog *et al.*, 1994). Emission data were acquired in list mode for 2 min post-injection starting with the injection of [¹⁵O]butanol. The list mode data were framed into a single frame of 40 s starting at the entry of the tracer into the brain (Herzog *et al.*, 1996). Using filtered back-projection, the reconstructed image resolution was ~9 mm (full-width half-maximum). The activity images were not quantified further and were regarded as estimates of rCBF.

PET acquisition protocol

During scan 1 (reference 1) the volunteers were presented with 12 single nonsense words (two-syllable pseudowords that obey German spelling rules) which they either read or heard and had to repeat silently (presentation rate: 2 s single nonsense word, 0.5 s interval). During scan 2 (first encoding) subjects were randomly presented either with 12 highly imaginable or 12 abstract word pairs and had to either read or hear and encode them silently (presentation rate: 2 s word pair presentation, 0.5 s interval). Between scan 2 (first storage) and scan 3 (retrieval) the same word pairs were presented in random order for the same number of times for highly imaginable as well as abstract words to each subject. During scan 3 (retrieval) the first words of the paired associates were presented (presentation rate: 2 s first word of a word pair, 0.5 s interval). The subjects either read or heard the words and had to generate associates silently. Immediately after the retrieval scan, subjects had to generate associates aloud to check for performance. Scans 4–6 were performed in the same way as scans 1–3, except that during reference 2, double nonsense words were presented and, depending on the word list used in scan 2, the word list with highly imaginable or abstract words was used, respectively. The number of presentations of the word pairs between first encoding and retrieval was equal for highly imaginable and abstract words within subjects. The current report focuses on the episodic retrieval so that not all data acquired in this study are presented here.

It should be noted that in this type of experiment two problems may arise from the fact that (i) recalling abstract words is more difficult (Baddeley, 1990) and, therefore, different levels of performance might influence the interpretations, and (ii) that a difference in the number of pre-scan presentations affects the novelty of the presented material within subjects. We gave subjects the same number of pre-scan presentations of highly imaginable and abstract material to compensate for the effect of variation in the novelty of the material.

Data analysis

Image analysis was performed using the Statistical Parametric Mapping (SPM) software (Friston *et al.*, 1995a, b) on a SPARC 20 workstation (Sun Microsystems). Calculations were performed in Matlab (MatLab version 4.2c).

Each reconstructed [¹⁵O]butanol scan was realigned and reoriented along the bi-commissural line using a PET template into a standard stereotactic space (Talairach and Tournoux, 1988). In the standard space, 1 voxel represents 2 × 2 × 4 mm in the *x*, *y* and *z* dimensions, respectively (Friston *et al.*, 1995a). A Gaussian filter with a full-width half-maximum (15 mm) was applied to smooth each image to compensate for inter-subject differences and to suppress high frequency noise in the images. Differences in global activity within and between subjects were removed by the

analysis of covariance (ANCOVA) on a voxel by voxel basis, with global counts as covariate and regional activity across subjects for each task, as inter- and intra-subject differences in global activity may obscure regional alterations in activity following cognitive stimulation. For each pixel in stereotactic space, the ANCOVA generated a condition-specific, adjusted mean rCBF value (normalized to 50 ml/100 ml/min) and an associated adjusted error variance. The ANCOVA allowed comparison of the means across two conditions (encoding/retrieval of word pair associates and reference condition) using *t*-statistics. The resulting *t*-map constituted a statistical parametric map (SPM{*t*}) (Friston *et al.*, 1995b).

Five main comparisons were carried out. (i) We determined areas of increased rCBF associated with the retrieval of visually presented highly imaginable as well as abstract word pair associates and compared them with scans acquired during the reference condition. (ii) We analysed increases in rCBF during retrieval of auditorily presented highly imaginable as well as abstract word pair associates and compared them with the reference condition. Further, we carried out a cognitive subtraction analysis in which the retrieval of highly imaginable and abstract word pair associates was compared directly. (iii) Increased brain activity during retrieval of highly imaginable minus abstract words as well as (iv) during retrieval of abstract minus highly imaginable words was evaluated. (v) We also carried out the comparison of auditorily presented (retrieval minus reference) with visually presented (retrieval minus reference) abstract words to evaluate whether the subjects during retrieval used all means including attempts to image the verbal material.

Voxels were identified as significantly activated if they passed the height threshold of $Z = 3.72$ ($P < 0.0001$) and at least belonged to a cluster of 33 activated voxels [$P < 0.05$, corrected for multiple comparisons (Friston *et al.*, 1994)]. Additionally, we also applied a threshold of $Z = 2.33$ ($P < 0.01$) uncorrected for multiple comparisons in order to explore the data from analyses (iii)–(v) at a more lenient threshold.

Results

Memory performance

During the PET measurement, recall after two, three or four presentations (depending on an individual subject's performance) was $94 \pm 11\%$ correct for the highly imaginable word pairs and $36 \pm 20\%$ correct for the abstract word pairs. There was a statistically significant difference between the performance for highly imaginable versus abstract words (paired *t*-test Group 1, $P < 0.0005$; Group 2, $P < 0.0001$). There was no statistical difference in performance for highly imaginable and abstract word pair associates between visual–verbal versus auditory–verbal presentation modalities (paired *t*-test: abstract word pairs; $P = 0.37$, highly imaginable word pairs; $P = 0.93$). Post-measurement questioning of the subjects in our study indicated that most subjects had used

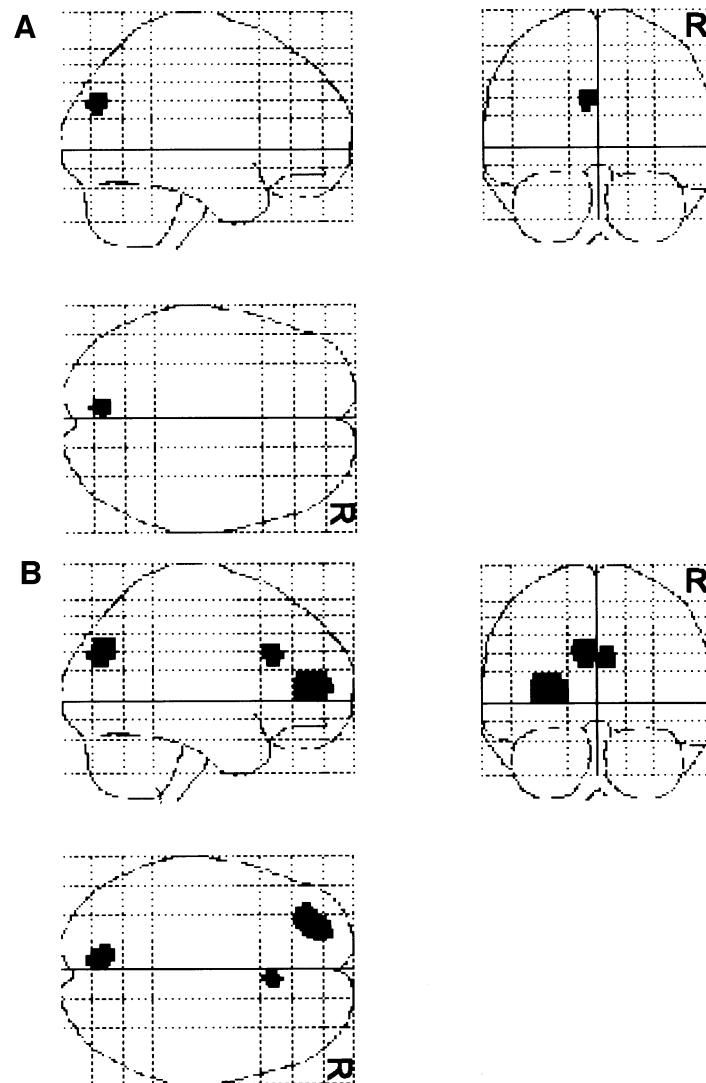


Fig. 1. (A) Visual presentation—highly imaginable words. Comparison of adjusted mean regional cerebral flow (rCBF) in six subjects for retrieval minus single nonsense words (i). Spatial distributions of significantly activated voxels are shown as integrated projections along sagittal, coronal and transverse views of the brain. Pixels were identified as significantly activated if they passed the height threshold of $Z = 3.72$ and at least belonged to a cluster of 33 activated pixels ($P < 0.05$, corrected for multiple comparisons) (R = right). (B) Visual presentation—abstract words. Comparison of adjusted mean rCBF in six subjects for retrieval minus single nonsense words (i). Spatial distributions of significantly activated voxels are shown as integrated projections along sagittal, coronal and transverse views of the brain (R = right).

imagery when recalling the high imagery items in the episodic memory task, whereas for abstract words the subjects mainly indicated that they had used direct association with no imagery when recalling the abstract items.

Changes in rCBF

Visual presentation

(i) The retrieval of highly imaginable–abstract word pair associates minus reference task 1 revealed significant increases in blood flow in the left precuneus [Brodmann area (BA) 7], as seen in Fig. 1A and Table 1A. During retrieval

of abstract word pairs, the left precuneus (BA 7), the left prefrontal cortex (BA 10/46) and the anterior cingulate (BA 24) were activated (Fig. 1B and Table 1B).

Auditory presentation

(ii) The retrieval of highly imaginable–abstract word pair associates minus reference task 2 resulted in significant increases in blood flow in the left precuneus (BA 7) and the left prefrontal cortex (Fig. 2A and Table 2A). During retrieval of abstract word pairs, the right precuneus (BA7) and the left and the right dorsolateral prefrontal cortex were activated

Table 1 Visual presentation

Region	BA	Region size	Stereotactic coordinate			Z value
			x	y	z	
(A) Retrieval of visually encoded highly imaginable word pairs compared with reference condition						
Precuneus, left	7	46	-6	-78	28	4.60
(B) Retrieval of visually encoded abstract word pairs compared with reference condition						
Precuneus, left	7	112	-8	-76	32	5.22
Frontal (lateral), left	10/46	262	-24	54	4	5.09
Frontal (medial)/anterior cingulate	24	56	6	26	28	4.52

The stereotactic coordinates of maximal activations during retrieval **(A)** of visually presented highly imaginable word pairs and **(B)** of visually presented abstract word pairs. Coordinates are according to the atlas of Talairach and Tournoux (1988). Pixels were identified as significantly activated if they passed the height threshold of $Z = 3.72$ and at least belonged to a cluster of 33 activated pixels ($P < 0.05$, corrected for multiple comparisons).

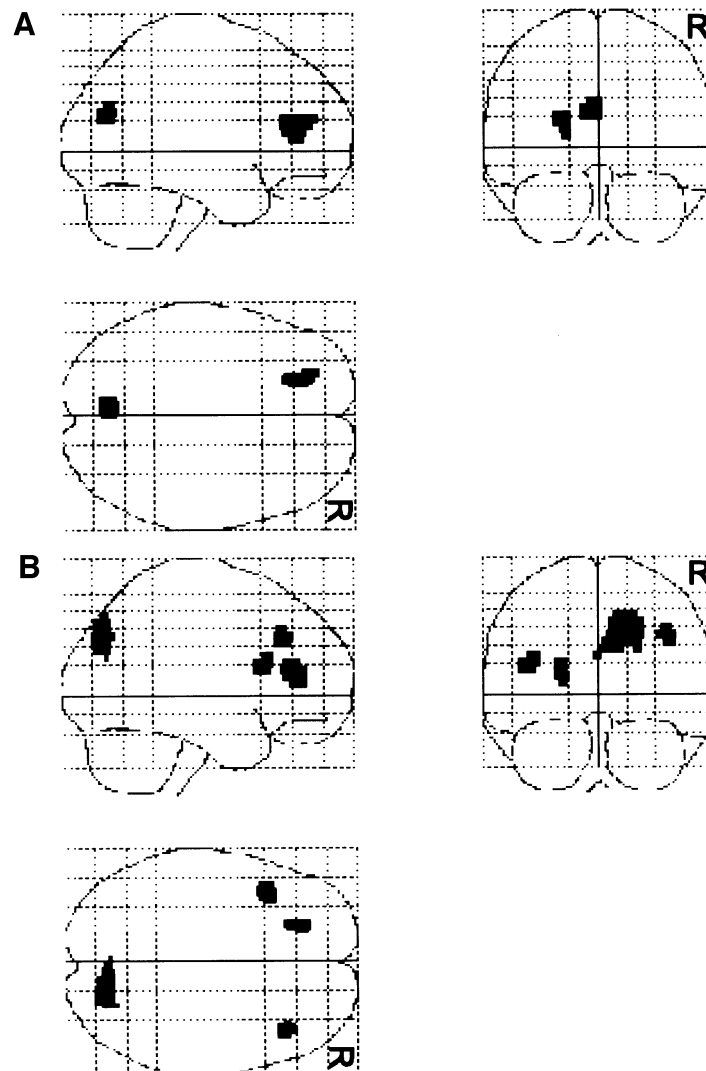


Fig. 2. (A) Auditory presentation—highly imaginable words. Comparison of adjusted mean regional cerebral flow (rCBF) in six subjects for retrieval minus single nonsense words (ii). Spatial distributions of significantly activated voxels are shown as integrated projections along sagittal, coronal and transverse views of the brain (R = right). (B) Auditory presentation—abstract words. Comparison of adjusted mean rCBF in six subjects for retrieval minus single nonsense words (ii). Spatial distributions of significantly activated voxels are shown as integrated projections along sagittal, coronal and transverse views of the brain (R = right).

Table 2 Auditory presentation

Region	BA	Region size	Stereotactic coordinate			Z value
			x	y	z	
(A) Retrieval of auditorily encoded highly imaginable word pairs compared with reference condition						
Precuneus, left	7	66	-6	-74	20	4.43
Frontal (lateral), left	10/46	99	-20	38	16	4.37
(B) Retrieval of auditorily encoded abstract word pairs compared with reference condition						
Precuneus, right	7	198	12	-76	32	5.04
Frontal (lateral), right	10/46	37	42	30	36	4.36
Frontal (lateral), left	46	55	-42	18	20	4.11
Frontal (lateral), left	46	62	-22	38	16	4.15

The stereotactic coordinates of maximal activations during retrieval **(A)** of auditorily presented highly imaginable word pairs and **(B)** of auditorily presented abstract word pairs.

(Fig. 2B and Table 2B). (iii) The direct analysis of differences in activation patterns associated with retrieval of highly imaginable word pairs minus retrieval of abstract word pairs showed no statistically significant differences. (iv) The direct analysis of differences in activation patterns associated with retrieval of abstract word pairs minus highly imaginable word pairs showed no statistically significant differences. (v) The comparison of auditorily presented (retrieval minus reference) with visually presented (retrieval minus reference) abstract words also showed no significant differences.

Exploring the data with a more lenient threshold of $Z = 2.33$ ($P < 0.01$) uncorrected for multiple comparisons did not show significant differences in precuneus activation for analyses (iii)–(v).

Discussion

Our study reveals distributed cortical structures with distinct roles in episodic memory retrieval and underlines the important role of the precuneus as a module subserving episodic associative memory retrieval independent of presentation modality and imagery content of the presented material. Recent PET studies of human memory show that retrieval of episodically stored information engages brain regions including the right prefrontal cortex together with posterior regions (Grasby *et al.*, 1993; Shallice *et al.*, 1994; S. Kapur *et al.*, 1995; Fuster, 1995; Fletcher *et al.*, 1995b; Blaxton *et al.*, 1996; Halsband *et al.*, 1998).

The precuneus is a medial parietal brain region situated superior and posterior to the retrosplenial area of the cingulate cortex. Little is known about this structure from lesion studies or about the functions and connectivity of the precuneus. There exist extensive connections between prefrontal and cingulate regions and parietal regions (Mesulam, 1990). Anatomical evidence indicates prefrontal (Petrides and Pandya, 1984; Goldman-Rakic, 1988), temporal, occipital and thalamic connections (Blum *et al.*, 1950; Pribram and Barry, 1956). Pandya and Barnes (1987) have described the afferent connections of the prefrontal cortex in some detail. They report that BA 46 projects to the superior parietal

lobule, the superior temporal regions and to the cingulate gyrus and retrosplenial cortex.

Some, but not all previous functional imaging studies of complex, multicomponent tasks which involve imagery report activation of parietooccipital and temporooccipital cortex. Increased activation in the medial parietal lobes has been found in several memory studies with respect to retrieval. In some cases, the activation has been bilateral (Tulving *et al.*, 1994; Schacter *et al.*, 1995). In other cases, unilateral activation has been observed primarily in the right hemisphere (Grady *et al.*, 1995; N. Kapur *et al.*, 1995; S. Kapur *et al.*, 1995; Moscovitch *et al.*, 1995).

Our results show a consistent precuneus activation during episodic memory retrieval using 'hard' word associations. The precuneus activation occurred for both highly imaginable and abstract words using differing presentation modalities (verbal–visual versus verbal–auditory). Our experimental condition differs from the reference condition in at least three ways: words versus nonsense words, greater cognitive effort in one task compared with the other and retrieval of words compared with silent reading of nonsense words. However, by using a subtraction analysis for our data, we can assign the activation patterns during episodic retrieval to differences of regional cerebral blood flow between the experimental condition (memory retrieval) minus the reference condition by subtracting: (i) nonsense words from words; (ii) minor cognitive effort from greater cognitive effort; and (iii) silent reading/hearing of nonsense words from retrieval of words from memory. Therefore, we take into account each of the three factors listed above in our analysis. Our results only highlight brain areas with an increase of regional blood flow above a mental state where subjects (i) perceive nonsense words, (ii) show a minor cognitive effort and (iii) silently read/hear nonsense words.

Activation of the precuneus and cuneus has been reported when subjects are asked to recall visual information (Roland and Seitz, 1989). Roland *et al.* (1990) have described precuneus activation in an experiment involving learning, retrieval and recognition of visual imagery. Previous studies have predicted an involvement of the precuneus in imagery

processes (Grasby *et al.*, 1993; Shallice *et al.*, 1994). In an experiment comparing free word recall from a supra-span list (15 words) with that from a sub-span list (5 words), the precuneus was activated in addition to frontal lobes and posterior cingulate cortex (Grasby *et al.*, 1993). A region of increased blood flow situated bilaterally in the precuneus was described by Tulving *et al.* (1994) for the retrieval of old meaningful sentences. Buckner *et al.* (1995) found a significant increase in mean blood flow in the medial parietal cortex (precuneus) in a visual word stem completion task. Andreasen *et al.* (1995b) reported activation of both retrosplenial cingulate and precuneus in a PET study of a task involving autobiographical memory, a type of episodic memory. These experiments all addressed episodic memory which almost invariably engaged imagery.

In addition to the studies described above, our study design allowed for the evaluation of different aspects of precuneus activation during episodic memory retrieval related to the presentation modality (visual-verbal versus auditory-verbal). The visual/auditory presentation of highly imaginable words also contained imagery processes.

It has been proposed that the precuneus is concerned with the retrieval of visual images (Roland *et al.*, 1990; Grasby *et al.*, 1993) and that this could be compatible with the known posterior cortical localization of visual imagery (Farah *et al.*, 1988). Fletcher *et al.* (1995c) argued from an episodic auditory-verbal memory category-example task that one possibility is that early visual processing areas might be activated automatically by highly imaginable words, and that the precuneus is required for conscious visual imagery in the context of retrieval. For experiments using a visual paradigm, it appears plausible that the activation of these regions reflects visual imagery, which may have facilitated or accompanied successful recovery of a stored memory as shown by several studies (Roland and Seitz, 1989; Roland *et al.*, 1990; Grasby *et al.*, 1993; Shallice *et al.*, 1994; Tulving *et al.*, 1994; Buckner *et al.*, 1995). These results are consistent with our findings using visual/auditory presentation of highly imaginable words.

However, we showed additionally that the precuneus is not only activated during retrieval of highly imaginable words but also during retrieval of abstract words irrespective of presentation modality. We provide evidence, using abstract and, therefore, non-imaginable words, that the medial parietal activation also occurs in episodic memory retrieval without involving imagery.

Fletcher *et al.* (1995c) demonstrated that directly manipulating imagery demands within an episodic retrieval task changes medial parietal cortex activity. They argued on the basis of their findings that the activation of the precuneus is associated with the use of visual imagery as a mnemonic strategy during episodic retrieval. In their previous work (Grasby *et al.*, 1993; Shallice *et al.*, 1994; Fletcher *et al.* 1995b), they used highly imaginable material and subjects commented on the degree to which they had used imagery as a mnemonic strategy. However, the location of the area

modulated by the imagery manipulation was anterior to the area typically activated during episodic retrieval (Andreasen *et al.*, 1995a; Buckner *et al.*, 1995; Fletcher *et al.*, 1995b; Petrides *et al.*, 1995; Halsband *et al.*, 1998).

Fletcher *et al.* (1996) designed an experiment to test the hypothesis that the precuneus subserves imagery-related retrieval and varied the extent by which visual imagery could be used during retrieval by changing the imagery content and the strength of semantic association. They showed, using a cognitive subtraction paradigm, that, comparing the retrieval of imaginable and non-imaginable word pair associates, activation differences of the precuneus, the left anterior cingulate cortex, the right superior temporal gyrus and the right fusiform gyrus occurred. Also, comparing the retrieval of non-imaginable and imaginable word pair associates, Fletcher *et al.* (1996) showed activation differences of the left dorsolateral prefrontal cortex.

However, it cannot be ruled out that the effects observed by Fletcher *et al.* (1996) might be explained by different levels of precuneus activation, since the cognitive subtraction in their experimental design involved no reference condition. We demonstrate here, by comparing retrieval of highly imaginable and abstract words with a reference condition, that in both cases there is significant precuneus activation irrespective of presentation modality. According to these results, we predicted that differences in precuneus activation should not be detectable by cognitive subtraction. Our cognitive subtractions indeed revealed no differences in precuneus activation for the retrieval of highly imaginable and abstract words. Taken together, these results show that cognitive subtraction would indicate differences in activation, whereas comparing the retrieval with a reference condition yields information about the functional topography of the whole set of regions involved in the retrieval task.

However, it has to be noticed that comparing the differences in precuneus activation by our cognitive subtraction yields slightly different results from the results of Fletcher *et al.* (1996) with respect to the comparison of retrieval of highly imaginable and abstract word pair associates; they describe (differences in) precuneus activation whereas there is no evidence for a difference in our studies. In our experiments, however, we have different levels of performance between the retrieval of highly imaginable and abstract word pair associates possibly being a confounding factor. Moreover, one cannot exclude the possibility that subjects could have used some degree of imagery in the retrieval of the abstract pairs. However, subjective ratings of the volunteers of the amount of imagery used during the scanning phase indicates a higher rating of imagery used with the recall of highly imaginable pairs.

Conclusions

We demonstrate that the precuneus is not only activated significantly during the recall of highly imaginable words but also during recall of abstract words. Although the more

detailed role of the precuneus is unclear, the present study indicates a specific role for the precuneus in episodic memory retrieval independent of imagery content of the words and of differing presentation modalities (verbal–visual versus verbal–auditory). Our findings are compatible with a model of memory function wherein the prefrontal regions drive the retrieval process, which is successful only when the retrieval attempt leads to a reactivation of an engram stored in the posterior multimodal association cortices, especially including the precuneus.

References

- Andreasen NC, O'Leary DS, Arndt S, Cizaldo T, Hurtig R, Rezaï K, Watkins G, et al. Short-term and long-term verbal memory: a positron emission tomography study. *Proc Natl Acad Sci USA* 1995a; 92: 5111–5.
- Andreasen NC, O'Leary DS, Cizaldo T, Arndt S, Rezaï K, Watkins GL, et al. Remembering the past: two facets of episodic memory explored with positron emission tomography. *Am J Psychiatry* 1995b; 152: 1576–85.
- Baddeley AD. *Human memory: theory and practice*. Boston: Allyn and Bacon; 1990.
- Baschek IL, Bredenkamp J, Oehle B, Wippich W. Bestimmung der Bildhaftigkeit, Konkretheit und der Bedeutungshaltigkeit von 800 Substantiven. *Z Exp Psychol* 1977; XXIV: 353–96.
- Blaxton TA, Bookheimer SY, Zeffiro TA, Figlozzi CM, Gaillard WD, Theodore WH. Functional mapping of human memory using PET: comparisons of conceptual and perceptual tasks. *Can J Exp Psychol* 1996; 50: 42–56.
- Blum JS, Chow KL, Pribram KH. A behavioral analysis of the organization of the parieto-temporo-preoccipital cortex. *J Comp Neurol* 1950; 93: 53–100.
- Buckner RL, Peterson SE, Ojemann JG, Miezin FM, Squire LR, Raichle ME. Functional anatomical studies of explicit and implicit memory retrieval tasks. *J Neurosci* 1995; 15: 12–29.
- Buckner RL, Raichle ME, Miezin FM, Petersen SE. Functional anatomic studies of memory retrieval for auditory words and visual pictures. *J Neurosci* 1996; 16: 6219–35.
- Farah MJ, Levine DN, Calvanio R. A case study of mental imagery deficit. *Brain Cogn* 1988; 8: 147–164.
- Fletcher PC, Dolan RJ, Frith CD. The functional anatomy of memory. *Experientia* 1995a; 51: 1197–207.
- Fletcher PC, Frith CD, Grasby PM, Shallice T, Frackowiak RS, Dolan RJ. Brain systems for encoding and retrieval of auditory verbal memory: an in vivo study in humans. *Brain* 1995b; 118: 401–16.
- Fletcher PC, Frith CD, Baker SC, Shallice T, Frackowiak RS, Dolan RJ. The mind's eye—precuneus activation in memory-related imagery. *Neuroimage* 1995c; 2: 195–200.
- Fletcher PC, Shallice T, Frith CD, Frackowiak RS, Dolan RJ. Brain activity during memory retrieval: the influence of imagery and semantic cueing. *Brain* 1996; 119: 1587–96.
- Friston KJ, Worsley KJ, Frackowiak RS, Mazziotta JC, Evans AC. Assessing the significance of focal activations using their spatial extent. *Hum Brain Mapp* 1994; 1: 210–20.
- Friston KJ, Ashburner J, Frith CD, Poline J-B, Heather JD, Frackowiak RS. Spatial registration and normalization of images. *Hum Brain Mapp* 1995a; 3: 165–89.
- Friston KJ, Holmes AP, Worsley KJ, Poline J-B, Frith CD, Frackowiak RS. Statistical parametric mapping in functional imaging: a general linear approach. *Hum Brain Mapp* 1995b; 2: 189–210.
- Fuster JM, editor. *Memory in the cerebral cortex*. Cambridge (MA): MIT Press; 1995.
- Goldman-Rakic PS. Circuitry of primate prefrontal cortex and regulation of behaviour by representational memory. In: Mountcastle VB, Plum F, editors. *Handbook of physiology, Sect. I, Vol. 5, Pt 1*. Bethesda (MD): American Physiological Society; 1987. p. 373–417.
- Goldman-Rakic PS. Topography of cognition: parallel distributed networks in primate association cortex. [Review]. *Annu Rev Neurosci* 1988; 11: 137–56.
- Grady CL, McIntosh AR, Horwitz B, Maisog JM, Ungerleider LG, Mentis MJ, et al. Age-related reductions in human recognition memory due to impaired encoding. *Science* 1995; 269: 218–21.
- Grasby PM, Frith CD, Friston KJ, Bench C, Frackowiak RS, Dolan RJ. Functional mapping of brain areas implicated in auditory–verbal memory function. *Brain* 1993; 166: 1–20.
- Halsband U, Freund H-J. Premotor cortex and conditional motor learning in man. *Brain* 1990; 113: 207–22.
- Halsband U, Krause BJ, Schmidt D, Herzog H, Tellmann L, Müller-Gärtner H-W. Encoding and retrieval in declarative learning: a positron emission tomography study. *Behav Brain Res* 1998; 97: 69–78.
- Herzog H, Seitz RJ, Tellmann L, Schlaug G, Kleinschmidt A, Nebeling B, et al. Pharmacokinetics and radiation dose of oxygen-15 labelled butanol in rCBF studies in humans. *Eur J Nucl Med* 1994; 21: 138–43.
- Herzog H, Seitz RJ, Tellmann L, Rota Kops E, Jülicher F, Schlaug G, et al. Quantitation of regional cerebral blood flow with O-15-butanol and positron emission tomography in humans. *J Cereb Blood Flow Metab* 1996; 16: 645–9.
- Kapur N, Friston KJ, Young A, Frith CD, Frackowiak RS. Activation of human hippocampal formation during memory for faces: a PET study. *Cortex* 1995; 31: 99–108.
- Kapur S, Craik FIM, Jones C, Brown GM, Houle S, Tulving E. Functional role of the prefrontal cortex in retrieval of memories: a PET study. *Neuroreport* 1995; 6: 1880–4.
- Meier H. *Deutsche Sprachstatistik*. Hildesheim: Olms-Verlag; 1964.
- Mesulam MM. Large-scale neurocognitive networks and distributed processing for attention, language, and memory. [Review]. *Ann Neurol* 1990; 28: 597–613.
- Moscovitch C, Kapur S, Köhler S, Houle S. Distinct neural correlates of visual long-term memory for spatial location and object identity: a positron emission tomography study in humans. *Proc Natl Acad Sci USA* 1995; 92: 3721–5.

- Paivio A, Yuille JC, Madigan SA. Concreteness, imagery, and meaningfulness values for 925 nouns. *J Exp Psychol* 1968; 76 (1 Suppl): 1–25.
- Pandya DN, Barnes CL. Architecture and connections of the frontal lobes. In: Perecman E, editor. *The frontal lobes revisited*. New York: IRBN Press; 1987. p. 41–72.
- Petrides M, Pandya DN. Projections to the frontal cortex from the posterior parietal region in the rhesus monkey. *J Comp Neurol* 1984; 228: 105–16.
- Petrides M, Alivisatos B, Evans AC. Functional activation of the human ventrolateral frontal cortex during mnemonic retrieval of verbal information. *Proc Natl Acad Sci USA* 1995; 92: 5803–7.
- Pribram HB, Barry J. Further behavioral analysis of parieto-temporo-preoccipital cortex. *J Neurophysiol* 1956; 19: 99–106.
- Roland PE, Seitz RJ. Mapping of learning and memory functions in the human brain. In: Ottoson D, Rostene W, editors. *Visualization of brain functions*. Basingstoke: Macmillan Press; 1989. p. 141–51.
- Roland PE, Gulyas B, Seitz RJ, Bohm CJ, Stone-Elander S. Functional anatomy of storage, recall, and recognition of a visual pattern in man. *Neuroreport* 1990; 1: 53–6.
- Rota Kops E, Herzog H, Schmid A, Holte S, Feinendegen L. Performance characteristics of an eight-ring whole body PET scanner. *J Comput Assist Tomogr* 1990; 14: 437–45.
- Rudge P, Warrington EK. Selective impairment of memory and visual perception in splenial tumours. *Brain* 1991; 114: 349–60.
- Schacter DL, Reiman E, Uecker A, Polster MR, Yung LS, Cooper LA. Brain regions associated with retrieval of structurally coherent visual information. *Nature* 1995; 376: 587–90.
- Shallice T, Fletcher P, Frith CD, Grasby P, Frackowiak RS, Dolan RJ. Brain regions associated with acquisition and retrieval of verbal episodic memory. *Nature* 1994; 368: 633–5.
- Squire LR. Mechanisms of memory. *Science* 1986; 232: 1612–9.
- Talairach J, Tournoux P. *Co-planar stereotactic atlas of the human brain: 3-dimensional proportional system: an approach to cerebral imaging*. Stuttgart: Thieme; 1988.
- Tulving E. Multiple memory systems and consciousness. *Hum Neurobiol* 1987; 6: 67–80.
- Tulving E, Kapur S, Markowitsch HJ, Craik FI, Habib R, Houle S. Neuroanatomical correlates of retrieval in episodic memory: auditory sentence recognition [see comments]. *Proc Natl Acad Sci USA* 1994; 91: 2012–5. Comment in: *Proc Natl Acad Sci USA* 1994; 91: 1989–91.
- Valenstein E, Bowers D, Verfaellie M, Heilman KM, Day A, Watson RT. Retrosplenial amnesia. *Brain* 1987; 110: 1631–46.
- Warrington EK. The selective impairment of semantic memory. *Q J Exp Psychol* 1975; 27: 635–57.
- Warrington EK, Weiskrantz L. Amnesia: a disconnection syndrome? *Neuropsychologia* 1982; 20: 233–48.
- Wechsler D. A standardized memory scale for clinical use. *J Psychol* 1945; 19: 87–95.

Received April 30, 1998. Revised August 6, 1998.

Accepted September 25, 1998