

Single Case

Erythropoietin-Resistant Anemia Secondary to Zinc-Induced Hypocupremia in a Hemodialysis Patient

Stephanie Munie^a Pairach Pintavorn^b

^aMedical University of South Carolina College of Medicine, Charleston, SC, USA; ^bEast Georgia Kidney and Hypertension, Augusta, GA, USA

Keywords

Zinc toxicity · Copper deficiency · Erythropoietin-resistant anemia

Abstract

Excessive intake of zinc is a known but often forgotten cause of copper deficiency, and its consequences in the context of end-stage renal disease (ESRD) are not widely discussed. Zinc-induced copper deficiency (ZICD) can result in erythropoietin (EPO)-resistant anemia and may not be considered as a possible etiology when conducting the work-up. We present a case wherein an ESRD patient had been receiving excess zinc for several months and subsequently experienced EPO-resistant anemia. Our patient's GI work-up was negative, and increased doses of iron and EPO-stimulating agent were ineffective. She underwent a bone marrow biopsy and more serological testing. She was ultimately diagnosed with ZICD, and cessation of her zinc supplement and initiation of copper replacement proved effective in restoring EPO responsiveness. Awareness of ZICD as a possible factor in EPO-resistant anemia could lead to an expedited diagnosis and avoid an unnecessary and extensive work-up.

© 2021 The Author(s)

Introduction

Erythropoietin (EPO)-resistant anemia is a common clinical problem in hemodialysis (HD) patients resulting from various etiologies, including iron deficiency, inflammation, blood loss, infection, inadequate dialysis, and severe secondary hyperparathyroidism [1, 2]. By definition, EPO-resistant anemia is an inability to maintain a desired hemoglobin (Hgb) level despite a dose of 450 U/kg/week of intravenous (IV) EPO [1]. This would equate to 300 U/kg/week of subcutaneous EPO or 1.5 µg/kg/week of darbepoetin alfa using the Kidney Disease Outcomes Quality Initiative (KDOQI) criteria [3]. Copper deficiency is an uncommon and often overlooked cause of anemia in the dialysis population. We present a case of excessive zinc intake causing copper deficiency, which resulted in acquired EPO resistance in an HD patient.

Case Report

The patient was a 57-year-old woman with a past medical history of end-stage renal disease (ESRD), Von Hippel-Lindau syndrome, renal cell carcinoma with bilateral nephrectomy, chronic anemia, and hemangioblastomas in the posterior fossa and retina. She started HD treatment after her second nephrectomy for renal cell carcinoma. She was admitted in May 2017 with pleural effusion, and when she was discharged home, she was prescribed zinc sulfate 220 mg daily presumably for upper respiratory infection symptoms. She continued to take zinc sulfate daily after her discharge until she was diagnosed with zinc toxicity in Spring 2018. She had also been using denture cream (Fixodent – average zinc absorption is estimated to be about 2 mg/day if used as directed) daily for several years. She was taking a zinc-free renal vitamin during that time (commonly prescribed renal vitamins contain varying amounts of zinc, ranging from 0–50 mg/tablet).

Her chronic anemia had been well controlled before May 2017 on darbepoetin alfa 60 µg every 2 weeks, with a stable Hgb level around 10–11 g/dL. However, she started to become more anemic with an Hgb level of 8.2 g/dL in October 2017, and her EPO-stimulating agent and iron doses were adjusted at that time. In early 2018, her Hgb level declined further, ranging from 5 to 7 g/dL (and dropping as low as 5.6 g/dL in April), despite adequate iron stores and a higher dose of darbepoetin alfa (150 µg every 2 weeks, or about 1.8 µg/kg/week). She had adequate dialysis, acceptable parathyroid hormone levels, and no overt evidence of inflammation or infection. She received 4 units of packed red blood cells over a period of 2 months. Her GI work-up showed negative fecal occult blood and unremarkable upper and lower endoscopies. A bone marrow biopsy showed mildly hypocellular marrow (30%) and dyserythropoiesis with nuclear irregularities and nuclear cytoplasmic dissociation. Neutrophils showed left shift with megaloblastoid changes. There were 4% blasts, and the myeloid-to-erythroid ratio was 3.3:1. Hyperzincemia-induced hypocupremia was not considered as a possible cause until Spring 2018 after exhausting all other work-ups, since serum zinc and

copper levels were not routinely checked at our dialysis unit. Serum zinc was elevated at 236 µg/dL (normal range: 60–120), serum copper was <10 µg/dL (normal range: 80–155), and ceruloplasmin was low at 3 mg/dL (normal range: 17–54). The reverse osmosis feed and reverse osmosis product water zinc were both <0.00 mg/L (normal range: 0.000–0.100 mg/L).

Her zinc sulfate was discontinued, and she was advised to change to zinc-free denture cream. We analyzed her serum zinc level before and after a session of dialysis and noted that her pre-HD and post-HD zinc levels were not significantly different at 216 and 215 µg/dL, respectively. She was given a dose of cupric chloride 0.5 mg IV when she was admitted for a transfusion. Cupric chloride was not covered by her insurance, however, and she was subsequently started on an oral copper supplement at 8 mg/day, tapering to 5 mg and 2 mg/day. Several weeks after starting the copper replacement, her copper level improved, and her Hgb level stabilized. Copper replacement was continued for 2 months. Figure 1 shows the relationship between her copper and zinc levels over the course of treatment upon diagnosis of zinc-induced copper deficiency (ZICD), with levels returning to normal limits after approximately 1 month of copper supplementation and remaining normal several months off zinc and copper supplements. Her Hgb level also stabilized with a significantly reduced EPO dose (Fig. 2; Table 1).

Discussion

Both copper and zinc are essential in countless physiological processes, including oxidation-reduction reactions, catecholamine metabolism, hematopoiesis (copper), and basic cell functioning (e.g., cell proliferation, differentiation, and metabolism) (zinc) [4, 5]. Absorption of these elements occurs in the small intestine and is dependent on the relative concentrations of each element. One theory for ZICD focuses on the interaction of copper and zinc with metallothionein (MT) proteins in the small intestine. MT proteins form disulfide bonds with metals such as cadmium, zinc, and copper, and help maintain stable metal ion levels in the body [6]. Increased levels of zinc stimulate an increased expression of MT genes, resulting in more MT proteins and thus more binding sites for copper and zinc on enterocytes (Fig. 3). Copper outcompetes zinc in binding to MT due to its greater affinity for the ligand [5]. Copper that is bound to MT is unable to be absorbed. The turnover rate for enterocytes is relatively rapid, and ultimately, copper bound to MT is lost in the stool as enterocytes are shed and replaced [7]. Therefore, when zinc levels are exceedingly high, copper deficiency can ensue, and ZICD complications such as anemia can arise. To minimize the risk of ZICD, Nishime et al. [8] suggest a safe upper zinc limit of 78.3 µg/dL for HD patients. In addition to excessive zinc intake, excessive dietary iron can also hinder the absorption of copper [7]. Since iron competes with copper for absorption, increasing a patient's oral iron replacement for EPO-resistant anemia could actually worsen the problem if the anemia is secondary to copper deficiency [7].

Copper deficiency can be found after gastric surgery, celiac disease, excessive zinc use, or prolonged parenteral nutrition, and can present as anemia, leukopenia, neutropenia, or myeloneuropathy [7, 9]. Copper deficiency anemia is not a traditional part of the work-up for EPO resistance. Iron deficiency and inflammation are common culprits of EPO-resistant anemia, as

well as the other known etiologies previously listed. Conducting an iron study is often the first step in the work-up, along with ensuring patient compliance and adequacy of dialysis. In our case, the patient had adequate iron stores and met the target for dialysis adequacy as well as for bone and mineral metabolism. Additionally, extensive GI work-ups were negative. We neglected to notice the association of her zinc supplement as the cause of her anemia. Higuchi et al. [10] account 5 similar cases involving ESRD patients who experienced neutropenia and EPO-resistant anemia secondary to copper deficiency, conditions that resolved after a few months of sufficient copper replacement. The main difference between our case and these 5 cases is EPO-resistant anemia stemming from ZICD in our case versus inadequate enteral copper supplementation in the others.

ESRD patients might be at risk for disturbances in trace elements depending on dietary intake and elimination via dialysis of individual trace elements [11]. The potential presence of trace elements in the water source might be a factor in this risk as well [11]. However, trace element disorders are uncommonly described in dialysis patients, and specifically, studies of ZICD in ESRD patients are not widespread. Zinc deficiency is more common in ESRD patients than zinc toxicity and actually has a relatively high prevalence in this patient population. Lee et al. [12] observed low levels of zinc in 78% of the 456 dialysis patients they examined. Hypoalbuminemia, commonly observed in dialysis patients, is strongly associated with hypozincemia. Zinc deficiency may lead to impaired protein synthesis, resulting in hypoalbuminemia. Zinc is mainly bound to plasma albumin, and hypoalbuminemia will lead to hypozincemia as well [13].

Tonelli et al. [11], Lin et al. [14], and Bhogade et al. [15] also demonstrate the occurrence of trace element disturbances in HD patients. The study by Tonelli et al. [11] involving 128 subjects, including individuals with and without ESRD, showed that ESRD patients had significantly less serum zinc and more serum copper than non-ESRD individuals. Lin et al. [14] noted increased zinc and copper after HD compared to levels before treatment. Bhogade et al. [15], however, found significantly lower serum copper and zinc levels after dialysis treatment. Though there are some discrepancies in the data, a tendency towards trace element imbalances in HD patients is overall apparent. With regard to copper levels and anemia in ESRD patients, Zeraati et al. [16] highlight the fact that current data are somewhat conflicting as well. They examined 84 subjects, consisting of ESRD patients with and without anemia as well as individuals without ESRD (controls). They initially assumed that there would be a direct relationship between copper deficiency and anemia, noting the deficiency as a rare and sometimes “forgotten” etiology for anemia. However, comparing the HD patients with and those without anemia, they found that the copper levels were greater in the anemic patients [16]. This outcome contrasts with our case of anemia secondary to copper deficiency as well as with the 5 cases Higuchi et al. [10] present.

A concrete dosing regimen is not available for ZICD; however, IV and oral copper supplementation proved effective in our case (in addition to discontinuation of excess zinc intake). Similarly, Hoffman et al. [5] describe a case where a 35-year-old woman experienced ZICD-related anemia and had successful resolution of the condition with IV cupric chloride 0.4 mg/mL for 5 days followed by 2 mg/day of copper acetate. Initial treatment with 2 mg of copper per day (along with cessation of her zinc supplements and iron replacement) did not seem

to have helped over the course of 2 months. This points to a necessary time factor in the reduction of zinc levels to a normal range prior to achieving the full effectiveness of copper replacement [5]. Furthermore, Rissardo and Caprara [17] present a case of ZICD-induced myelopathy in a 65-year-old woman on HD. Discontinuation of her zinc and initiation of copper replacement (2 mg IV daily for 1 week succeeded by 8 mg daily of oral copper tapering to 2 mg/day) relieved her myelopathy [17].

Conclusions

Iron replacement and a GI work-up were part of our initial plan as well as that of Hoffman et al. [5]. ZICD was not an obvious differential diagnosis for these patients. Similarly, as exemplified in the cases presented by Willis et al. [9], ZICD was not a forefront differential diagnosis during the evaluation of their 3 patients experiencing either neuropathy or hematologic dysfunction secondary to copper deficiency. In those 3 cases, bone marrow biopsies led to the final diagnoses [9]. Ultimately, a more widespread awareness of ZICD complications could improve treatment plans and therefore patient outcomes. ZICD-related EPO-resistant anemia in HD patients specifically warrants additional attention. As discussed, zinc toxicity is relatively rare in ESRD patients. Due to the low prevalence of excessive serum zinc levels in ESRD patients and the lack of extensive clinical data on the condition, zinc toxicity in patients with EPO resistance may not always be considered at first glance. An in-depth evaluation of the patient's past medical history and medications, including over-the-counter supplements, could point towards a ZICD diagnosis. If ZICD is suspected, a basic serological test for zinc and copper levels could offer a rapid diagnosis and potentially spare the patient from an undesirable GI work-up.

A normal diet can typically supply an adequate daily intake of copper and zinc in most conditions. The recommended daily zinc intake for adult men and women is 11 and 8 mg, respectively, with a maximum of 40 mg for healthy adults [18]. The recommended daily copper intake for adults is 900 µg, with a maximum of 10 mg [18]. With more interest in zinc supplementation during the SARS-CoV-2 pandemic, we should recognize the possibility of zinc toxicity as a cause of copper deficiency anemia in our patients. Periodic screening of zinc and copper levels should be performed in patients who received prolonged zinc supplementation and have developed unexplained anemia.

Statement of Ethics

This study was conducted ethically in accordance with the World Medical Association Declaration of Helsinki. The patient has provided written informed consent to publish this case.

Conflict of Interest Statement

The authors have no conflicts of interest to declare.

Funding Sources

No funding was received.

Author Contributions

Both authors contributed to the composition and revision of this report. Stephanie Munie wrote parts of the manuscript and prepared Table 1 and Figures 1 and 2. Pairach Pintavorn wrote parts of the manuscript and prepared Figure 3. Both authors contributed equally in proof reading, securing references, and reviewing the manuscript.

References

- 1 IV. NKF-K/DOQI clinical practice guidelines for anemia of chronic kidney disease: update 2000. *Am J Kidney Dis*. 2001 Jan;37(1 Suppl 1):S182–238.
- 2 Alves MT, Vilaça SS, Carvalho M, Fernandes AP, Dusse LM, Gomes KB. Resistance of dialyzed patients to erythropoietin. *Rev Bras Hematol Hemoter*. 2015 May-Jun;37(3):190–7.
- 3 Locatelli F, Aljama P, Bárány P, Canaud B, Carrera F, Eckardt KU, et al.; European Best Practice Guidelines Working Group. Revised European best practice guidelines for the management of anaemia in patients with chronic renal failure. *Nephrol Dial Transplant*. 2004 May;19 Suppl 2:ii1–47.
- 4 Mehri A. Trace elements in human nutrition (II) – an update. *Int J Prev Med*. 2020 Jan;11:2.
- 5 Hoffman HN 2nd, Phyliky RL, Fleming CR. Zinc-induced copper deficiency. *Gastroenterology*. 1988 Feb;94(2):508–12.
- 6 Si M, Lang J. The roles of metallothioneins in carcinogenesis. *J Hematol Oncol*. 2018 Aug;11(1):107.
- 7 Kumar N. Copper deficiency myelopathy (human swayback). *Mayo Clin Proc*. 2006 Oct;81(10):1371–84.
- 8 Nishime K, Kondo M, Saito K, Miyawaki H, Nakagawa T. Zinc burden evokes copper deficiency in the hypoalbuminemic hemodialysis patients. *Nutrients*. 2020 Feb;12(2):577.
- 9 Willis MS, Monaghan SA, Miller ML, McKenna RW, Perkins WD, Levinson BS, et al. Zinc-induced copper deficiency: a report of three cases initially recognized on bone marrow examination. *Am J Clin Pathol*. 2005 Jan;123(1):125–31.
- 10 Higuchi T, Matsukawa Y, Okada K, Oikawa O, Yamazaki T, Ohnishi Y, et al. Correction of copper deficiency improves erythropoietin unresponsiveness in hemodialysis patients with anemia. *Intern Med*. 2006;45(5):271–3.
- 11 Tonelli M, Wiebe N, Hemmelgarn B, Klarenbach S, Field C, Manns B, et al.; Alberta Kidney Disease Network. Trace elements in hemodialysis patients: a systematic review and meta-analysis. *BMC Med*. 2009 May;7(1):25.
- 12 Lee SH, Huang JW, Hung KY, Leu LJ, Kan YT, Yang CS, et al. Trace Metals' abnormalities in hemodialysis patients: relationship with medications. *Artif Organs*. 2000 Nov;24(11):841–4.
- 13 Katayama K, Kawaguchi T, Shiraishi K, Ito T, Suzuki K, Koreeda C, et al. The prevalence and implication of zinc deficiency in patients with chronic liver disease. *J Clin Med Res*. 2018 May;10(5):437–44.
- 14 Lin TH, Chen JG, Liaw JM, Juang JG. Trace elements and lipid peroxidation in uremic patients on hemodialysis. *Biol Trace Elem Res*. 1996 Mar;51(3):277–83.

- 15 Bhogade RB, Suryakar AN, Joshi NG. Effect of hemodialysis on serum copper and zinc levels in renal failure patients. *Eur J Gen Med*. 2013;10(3):154–7.
- 16 Zeraati A, Azimi SA, Shahri SM, Sharifipour F, Hekmat R, BeladiMousavi S. The evaluation of serum copper level in hemodialysis patients with and without anemia compared with healthy controls. *Bangladesh J Med Sci*. 2014;14(1):43–8.
- 17 Rissardo JP, Caprara AL. Copper deficiency myelopathy secondary to parenteral zinc supplementation during chronic dialysis. *Neurol Asia*. 2019;24(1):79–82.
- 18 Institute of Medicine (US) Panel on Micronutrients. Dietary Reference Intakes for Vitamin A, Vitamin K, Arsenic, Boron, Chromium, Copper, Iodine, Iron, Manganese, Molybdenum, Nickel, Silicon, Vanadium, and Zinc. Washington (DC): National Academies Press (US); 2001.

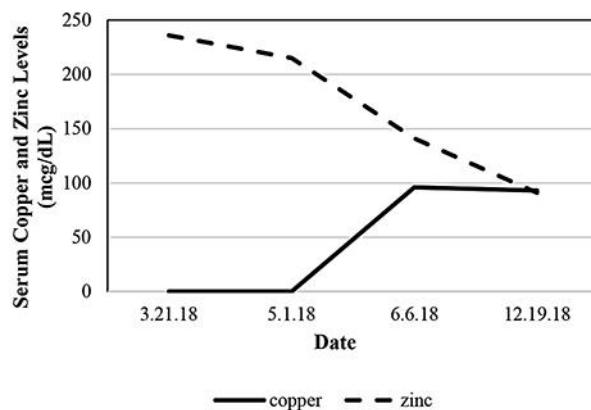


Fig. 1. The relationship between zinc and copper levels over the course of treatment of zinc-induced copper deficiency. Initiation of copper replacement and discontinuation of excess zinc returned the patient's copper and zinc levels to normal ranges. The normal range for copper is 80–155 $\mu\text{g}/\text{dL}$, and the normal range for zinc is 60–120 $\mu\text{g}/\text{dL}$.

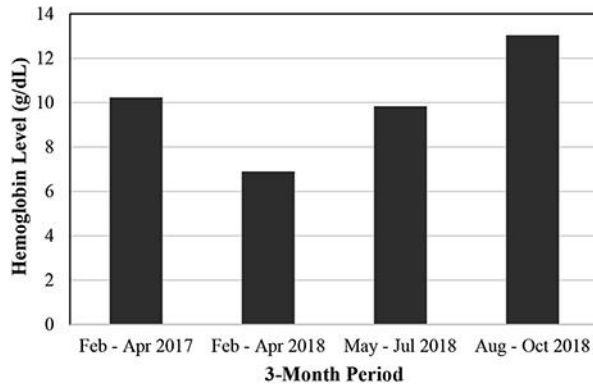


Fig. 2. Three-month average hemoglobin levels over the course of treatment. February–April 2017 was before zinc sulfate was started. February–April 2018 was when the patient manifested severe zinc-induced copper deficiency (ZICD) anemia. May–July 2018 was during treatment of ZICD. August–October 2018 was after completion of her copper supplementation (off zinc supplement and using zinc-free denture cream). Zinc was started in May 2017. She was on darbepoetin alfa 40 µg every 2 weeks in April 2017 and on 150 µg every week in April 2018. She was completely off darbepoetin alfa between September and early November 2018 and was started on low-dose methoxy polyethylene glycol-epoetin beta at 30 µg every 2 weeks in December 2018.

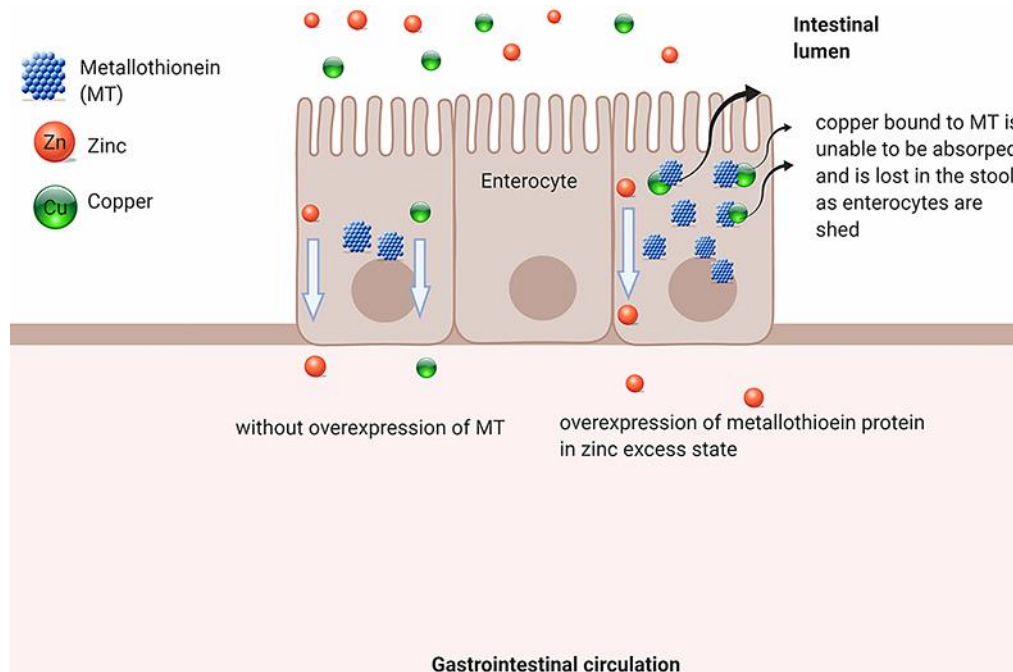


Fig. 3. Metallothionein in Cu and Zn absorption.

Table 1. Average Hgb and TSAT values over the course of treatment

	Feb–Apr 2017	Feb–Apr 2018	May–Jul 2018	Aug–Oct 2018
Hgb, g/dL	10.23	6.9	9.8	13.0
TSAT, %	32.6	35.7	19.7	58.7

Zinc was started in May 2017. The patient was on darbepoetin alfa 40 µg every 2 weeks in April 2017 and on 150 µg every week in April 2018. She was completely off darbepoetin alfa between September and early November 2018 and was started on low-dose methoxy polyethylene glycol-epoetin beta at 30 µg every 2 weeks in December 2018. Hgb, hemoglobin; TSAT, transferrin saturation.