

SHORT COMMUNICATIONS & CASE REPORTS

Escherichia coli keratitis treated with ultraviolet A/riboflavin corneal cross-linking: a case report

TOMMASO MICELLI FERRARI, MARCO LEOZAPPA, MASSIMO LORUSSO, ENRICO EPIFANI, LUISA MICELLI FERRARI

UOC Oculistica, Ospedale Generale Regionale F. Miulli, Acquaviva delle Fonti, Bari - Italy

PURPOSE. *To describe a case of keratitis caused by the Gram-negative Escherichia coli, treated with UVA-riboflavin cross linking.*

METHODS. *Case report.*

RESULTS. *A 78-year-old woman with diabetes presented with a 1-week history of pain, photophobia, foreign body sensation, and lacrimation in the right eye. The patient underwent topical and systemic antimicrobial therapy, without improvement. The authors treated the patient with riboflavin and corneal UVA crosslinking, with the aim to promote healing of the ulceration. One day after the procedure, the corneal ulceration was covered by cicatricial tissue, and the patient reported a significant improvement in symptoms. One month after the treatment, corneal edema was almost completely resolved, corneal ulceration was healed, and the painful symptoms of the patient had disappeared.*

CONCLUSIONS. *UVA-riboflavin crosslinking can be useful for the treatment of corneal ulceration unresponsive to medical treatment. (Eur J Ophthalmol 2009; 19: 295-7)*

KEY WORDS. *Riboflavin, C3R, Crosslinking, Keratitis, Corneal ulceration*

Accepted: September 4, 2008

INTRODUCTION

Crosslinking of the cornea by means of riboflavin/UVA (370 nm) is a new therapeutic approach to re-increase the mechanical stability of corneal tissue that is progressively decreasing. The procedure of corneal crosslinking was developed from 1993 until 1997 by Spoerl et al at the University of Dresden (1).

UVA radiation with concomitant administration of riboflavin/dextran solution as a photosensitizer generates singlet oxygen and superoxide free radicals. This process leads to physical crosslinking of the corneal collagen fibers.

Intrahelical or interhelical crosslinks can be formed within or between the tropocollagen units that comprise the individual collagen fibrils, and intermicrofibrillar crosslinks can form between adjacent collagen microfibrils that comprise the collagen lamellae (1).

A normal cornea soaked with riboflavin absorbs about 95% of the total radiation so that, in a 400- μ m-thick

cornea saturated with riboflavin, the irradiance at the endothelial level is 0.18 mW/cm (2).

UV light and riboflavin cause irreversible damage to the RNA and DNA of viruses, bacteria, and parasites, preventing them from replicating and causing disease.

The combined application of riboflavin and light inactivates pathogens in two ways: UV light alone has been shown to cause changes in the nucleic acids of pathogens so they cannot replicate. UVA does not damage DNA directly like UVB and UVC, but it can generate highly reactive chemical intermediates, such as hydroxyl and oxygen radicals, which in turn can damage DNA; riboflavin molecules form complexes with nucleic acids of pathogens. Exposure to UV light activates the riboflavin in the complex and causes a chemical alteration to functional groups of the nucleic acids (primarily guanine bases), making pathogens unable to replicate (3).

Recently, Iseli et al reported five cases of infectious keratitis not responding to systemic and topical antibiotic therapy treated with corneal crosslinking; in all cases, the pro-

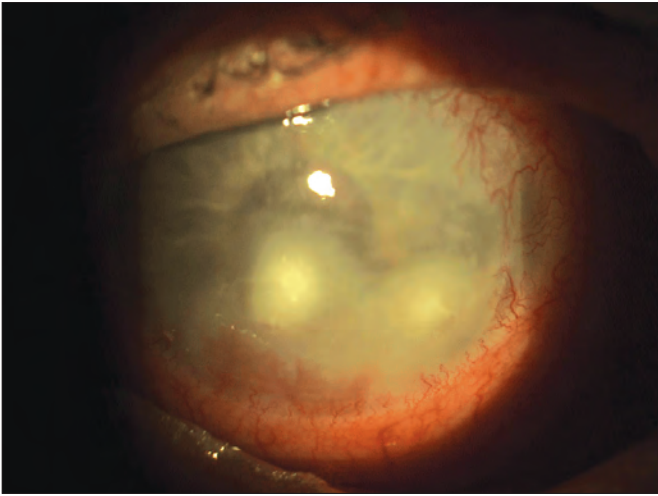

Fig. 1 - On slit-lamp examination, a corneal ulcer with a central abscess and peripheral cornea edema was noted.

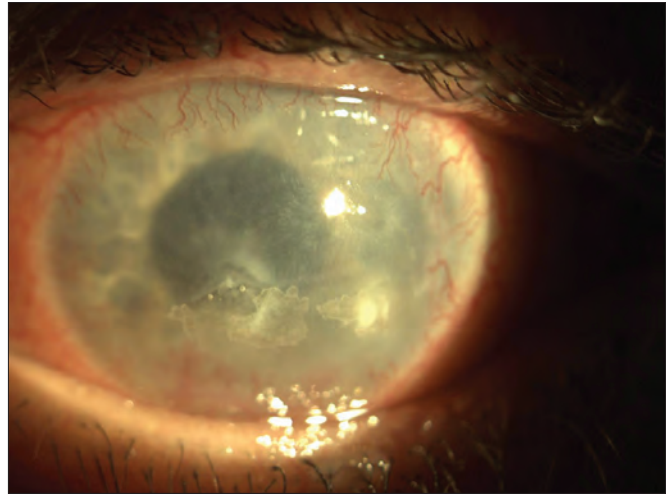


Fig. 2 - The day after the treatment, corneal ulceration was covered by cicatricial tissue.

gression of corneal melting was halted after corneal crosslinking treatment (4).

Case report

A 78-year-old woman presented with a 1-week history of pain, photophobia, foreign body sensation, and lacrimation in the right eye. Previous medical history included diabetes mellitus treated with oral hypoglycemic agents and bilateral cataract phacoemulsification with intraocular lens implantation 5 years ago. The patient presented a 10-year history of diabetic proliferative retinopathy, associated with neovascular glaucoma topically treated with beta-blockers and carbonic anhydrase inhibitors.

On first examination, the patient showed strong ciliary and conjunctival injection; there was a sub-complete limbal vascularization and inferior corneal ulceration with diffuse corneal edema; a moderate flare was present (Fig. 1). The patient presented with visual acuity of light perception in the right eye and best-corrected visual acuity of 20/40 in the left eye.

B-scan ultrasonography of right eye showed severe diabetic retinopathy with diffuse fibrovascular tissue proliferation.

The patient underwent topical therapy with eyedrops of tobramycin and levofloxacin every hour and adjunctive systemic antibiotic treatment with ceftazidime (intravenously administered).

After 7 days of treatment, eye objectivity and symptoms

were not minimally improved. The patient complained of increased pain, not decreased even after adding in therapy systemic anti-inflammatory drugs and topical atropine 1% drops.

Therefore, we decided to treat the patient with riboflavin and corneal UVA crosslinking, with the aim to promote healing of the ulceration.

We used the VEGA CBM X linker (CSO; Firenze, Italy) and RICROLIN solution containing riboflavin 0.1% and dextran 20% produced by SOOFT Italia.

After instillation of oxybuprocaine, the edge of the corneal ulcer was scraped with a knife and material was sent to the bacteriology laboratory for microbiological investigation and antibiogram.

Photosensitizing riboflavin drops were applied on the ulceration site, once every minute for the duration of 10 minutes.

After this time, the eye was exposed to UVA, repeating the instillation of riboflavin every minute. Radiant energy was 3 mW/cm² or 5.4 joule/cm² for a 5-minute exposure at 1 cm from the corneal apex.

Before the surgical procedure we made a pachymetry map with Visante OCT (Carl Zeiss Meditec; Dublin, CA) and we decided to reduce the time exposure because the thinnest point was 0.390 mm.

At the end of treatment, the eye was medicated with povidone iodine (one drop for 30 seconds) and netilmicin, and dressed with a bandage.

One day after the procedure, slit-lamp examination

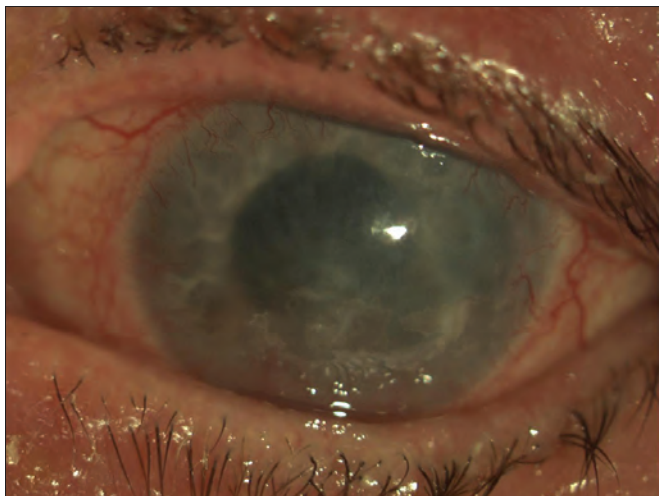


Fig. 3 - Slit-lamp examination 1 month after the intervention showed involvement of corneal edema around the healed ulceration.

showed the corneal ulceration covered by cicatricial tissue and a partial decrease of corneal edema (Fig. 2). The patient reported a significant improvement in symptoms and reduction of pain and continued therapy with only antibiotic drops (tobramycin and levofloxacin, 4 times/day). One month after the treatment, corneal edema was almost completely resolved, corneal ulceration was healed, and the painful symptoms of the patient had disappeared (Fig. 3).

Microbiological analysis of corneal scraping was positive for *Escherichia coli*, negative for *Acanthamoeba*.

The antibiogram revealed sensitivity to all the most common antibiotics, although the use of these had not brought any benefit to the patient.

DISCUSSION

We describe a case of corneal ulceration in a diabetic patient with blind and painful eye. The management of such patients is not easy, and should include the treatment of the pain, the prevention of the spread of infection, whereas the visual prognosis is poor. UVA/riboflavin corneal crosslinking is a widespread technique in the treatment of keratoconus, which is based mainly on combined action of riboflavin and UVA rays in determining a structural rearrangement of corneal collagen. The chemistry of riboflavin and its ability to inactivate viruses and bacteria when exposed to light has been described in the literature

for over 30 years. Riboflavin is a naturally occurring vitamin supplement with a long historical record of safety in humans. It is a water-soluble vitamin that the body easily breaks down and eliminates.

The use of this technique for other purposes, such as we reported, is not yet widespread. The case that we reported shows that in a patient not responding to maximal therapy for corneal ulceration, the use of UVA/riboflavin corneal crosslinking led to the healing of the lesion, with a remarkable and rapid improvement in symptoms. More experience is needed so that we can better refine the technique and the use of riboflavin crosslinking in the management of these corneal diseases.

The authors report no proprietary interest or grants or funds in support of the study.

Reprint requests to:
Tommaso Micelli Ferrari, MD
UOC Oculistica Ospedale F. Miulli
via Santeramo Km 4,100
Acquaviva delle Fonti (Bari) - Italy
tommasomicelliferrari@alice.it

REFERENCES

1. Spoerl E, Huhle M, Seiler T. Induction of cross-links in corneal tissue. *Exp Eye Res* 1998; 66: 97-103.
2. Kumar V, Lockerbie O, Keil SD, et al. Riboflavin and UV-light based pathogen reduction. Extent and consequence of DNA damage at the molecular level. *Photochem Photobiol* 2004; 80: 15-21.
3. Spoerl E, Seiler T. Techniques for stiffening the cornea. *J Refract Surg* 1999; 15: 711-3.
4. Iseli HP, Thiel MA, Hafezi F, Kampmeier J, Seiler T. Ultraviolet A/riboflavin corneal cross-linking for infectious keratitis associated with corneal melts. *Cornea* 2008; 27: 590-4.

Copyright of European Journal of Ophthalmology is the property of Wichtig Editore and its content may not be copied or emailed to multiple sites or posted to a listserv without the copyright holder's express written permission. However, users may print, download, or email articles for individual use.