

Institutional report - Esophagus

Esophageal foreign bodies under cricopharyngeal level in children: an analysis of 1116 cases

Akın Eraslan Balcı*, Şevval Eren, Mehmet Nesimi Eren

Department of Thoracic and Cardiovascular Surgery, Dicle University School of Medicine, 21280 Diyarbakır, Turkey

Received 9 October 2002; received in revised form 19 June 2003; accepted 12 August 2003

Abstract

Esophageal foreign bodies (FBs) in children are a commonly seen complaint that can cause severe morbidity. Different methods are used for their extraction. We reviewed our cases and described direct extraction technique. The specifications of 1116 children with esophageal FBs between 1990 and 2000 were evaluated. All FB cases were considered emergencies and intervention was performed in the operating theater. Patients with coins were only sedated and relaxed while the FB was removed under direct vision by McGill forceps. Other FBs were removed under general anesthesia by rigid esophagoscope. There were 1035 coins in 1007 patients and 112 other FBs in 109 children. Mean age was 4.2 years, ranging from 1 month to 15 years. Immediate interventions were performed in 16 (1.4%) patients. Reasons included respiratory distress from pressure in eight (five coins, three toy pieces), increased rupture risk after 4 days in three (all coins) and esophageal rupture in five patients. Four (0.3%) perforations occurred during intervention; two (0.02%, 2/1116) arose from coin extraction, and another two (1.8%, 2/109) were caused by esophagoscopy removal. The success rate for esophagoscopy removal was 95.4% (105/109). Three (0.2%) of 1116 patients underwent surgery to remove FBs. All were esophagoscopy patients, thus the surgery ratio for esophagoscopy removal was 2.7% (3/109). If an FB is diagnosed quickly and removed few problems arise. Esophageal coins can be successfully extracted under direct vision.

© 2003 Elsevier B.V. All rights reserved.

Keywords: Foreign body; Esophagus; Children

1. Introduction

The natural curiosity of children leads them to ingest many types of non-edible objects [1,2], and inevitably some of these objects become lodged in the esophagus [3].

For removal, some authors have advocated the use of a Foley catheter [4,5], esophageal bougienage [6] or flexible fiberoptic endoscopy [7]. In our hospital, most foreign bodies (FBs) found in the esophagus are removed under direct laryngoscopic vision by forceps in the thoracic surgery department. Herein, we retrospectively review our clinical experience and discuss the clinical, radiologic and surgical features of 1128 cases with FBs and also describe a relatively easy and safe technique to remove esophageal coins.

2. Materials and methods

From 1990 to 2001, 1116 children with esophageal FBs were presented to our hospital. FBs were classified in four ways according to history, diagnostic methods and post-intervention findings: (1) coins, (2) non-opaque matter, (3) metals and (4) foods. None of the patients had previous histories or findings of esophageal disease. Symptoms of failure to swallow saliva and dysphagia were carefully looked for in all patients. All had a two-sided chest X-ray. For the possibility of an FB moving distally, especially for coins, chest X-rays were repeated if they had ingested the FB at least 2 h before admittance. Seventeen patients in whom coins had passed down to the first esophageal constriction in later X-rays were excluded from our study. For patients with ingestion histories and whose X-rays showed no FB, further radiographic investigations were performed (esophagography in 11 and tomography in seven cases). If further investigations showed no findings of a suspected FB, two methods were adopted: When the history

* Corresponding author. Present address: Department of Thoracic Surgery, Fırat University School of Medicine, 23100 Elazığ, Turkey. Tel.: +90-424-238-8080x139; fax: +90-424-233-5038.

E-mail address: abalci@firat.edu.tr (A.E. Balcı).

was clear, formal rigid esophagoscopy under general anesthesia was performed, and the procedure adopted is described below. When the history was not clear, flexible esophagoscopy was performed electively.

All FB cases were considered emergencies and intervention was performed in the operating theater. The extraction of FBs was undertaken after a fasting period of at least 4 h, except in 16 patients who underwent intervention immediately following admission. Patients with coins in the first esophageal constriction had the coin removed under direct vision with rigid bronchoscopy forceps. If the FB had passed the first esophageal constriction, which is the narrowest part of the esophagus encountered during the procedure, intervention was aborted as the FB could also pass to more distal parts of the gastrointestinal tract (stomach, duodenum, etc.) that are of a larger diameter. These cases were followed up with abdominal X-rays (Observation).

Coin patients were sedated and relaxed without the use of general anesthesia. The following protocol was used for coin patients: propofol 1–1.5 mg/kg intravenously for sedation (dose can be increased until response); and succinylcholine dichloride 1 mg/kg intravenously for light muscle relaxation. This additional dose gives the physician 6–8 min in which to remove the coin. If the object cannot be removed within this period, 2 µg/kg of cisatracurium intravenously and enflurane by mask were given for an additional 15 min.

All other FBs (i.e. other than coins) were removed under general anesthesia. A rigid esophagoscope was used to remove them by seeking to place an object inside the esophagoscope, if at all possible, so as to not cause further injury to the esophagus.

If the procedure lasted more than 15 min, dexamethasone was given to prevent possible soft-tissue edema. A post-procedure chest radiograph was obtained. Following the procedure, the children's parents/guardians were advised to forbid the child any oral intake for 12 h; the children were generally discharged on the same day.

3. Results

We located 1035 coins in 1007 patients and 112 other foreign bodies in 109 children, thus making 1147 FBs in 1116 patients. The mean age was 4.2 years, ranging from 1 month to 15 years. The male–female ratio varied from 1.23 in the 0–3-year age group to 0.72 for those 12–15 years old. Most (54%) of the children were in the 0–3-year age group. The most frequently (90.2%) encountered FBs were coins. The frequency of ingested FBs differed relative to the age group concerned. Coins were frequently (56.6%) ingested by small children, while foodstuffs mostly (43.8%) lodged in the esophagi of older children. Non-opaque objects (mostly plastic toys or pieces of pencils) had a peak level in

Table 1
Distribution of foreign bodies to age groups

Age (years)	Coin (%)	Non-opaque (%)	Metal (%)	Food (%)	Total (%)
0–3	586 (56.6)	16 (25)	12 (37.5)	2 (12.5)	615 (54)
4–7	307 (29.6)	10 (15.6)	10 (31.2)	2 (12.5)	329 (24)
8–11	105 (10.1)	30 (46.8)	7 (22)	5 (31.2)	147 (14)
12–15	37 (3.6)	8 (12.5)	3 (9.3)	7 (43.8)	55 (8)
Total	1035 (90.2)	64 (5.6)	32 (2.8)	16 (1.4)	1147 (100)

children attending school or play groups, as expected (Table 1).

The most prominent symptom was hypersalivation (drooling), which resulted from the inability to swallow saliva (Fig. 1). Of 1116 patients, 929 (83.2%) were admitted within the first 12 h, 102 (9.1%) within 12–24 h and 79 (7.1%) later than 24 h. Six patients (0.5%) were admitted to hospital after 3 days; one of these had an esophagus perforated by a coin that was detected by esophagoscopy. This patient underwent cervical esophagus repair using the two-layer technique and experienced an uneventful post-operative period.

3.1. Coins

Almost all coins were removed during a single session. Two coins were found in 15 patients, three coins in five patients, and four coins in one patient. They were all removed during one session of surgery. The coins removed were between 2.3 and 2.7 cm in diameter for 85% of the patients. In 18 (1.6%) patients, the coins passed down during the procedure; none of these patients reported any complications and all coins were recovered from later stools. In 14 (1.2%) patients, coins were associated with another form of FB (pen cap, four; eraser, two; toy, two; nail, two; safety pin, two; hairpin, two). Such secondary FBs were noted during direct laryngoscopy and removed without the use of an esophagoscope after two or three manipulations. One patient, however, had dysphagia after the removal of a coin, and so esophagoscopy was performed. A pen cap was later seen and removed. Multiple FBs other than coins were present in five (0.4%) children, and one of these had Down syndrome. The overall results for coins are summarized in Table 2. In four patients (0.3%), esophageal FBs were associated with airway FBs. Removal was synchronized under general anesthesia in two patients following diagnosis by lateral X-ray. One X-ray taken after esophagoscopy showed a needle in the left main bronchus. Eight hours after removing a hairpin, the needle of the same hairpin was removed by bronchoscopy performed under sedation.

3.2. Non-coin FBs

Five of 109 (4.6%) non-coin FB patients needed more than one session for the removal of objects: three patients

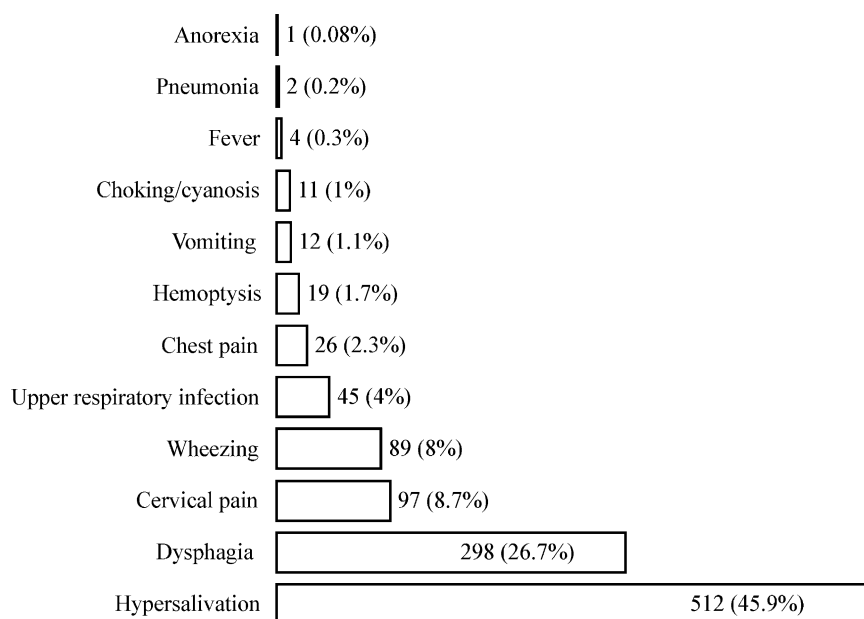


Fig. 1. Symptoms of the children with esophageal foreign bodies.

required a second session while one patient required a third and another a fourth session. Metallic objects were common in the upper esophagus, food in the middle esophagus and non-opaque objects in the lower esophageal third (Table 2). During esophagoscopy, one patient was found to have two FBs while a different patient had three FBs present. The success rate for esophagoscopy removal was 95.4% (105/109). Three (0.2%) of 1116 patients underwent surgery for FB removal. All were formal rigid esophagoscopy patients (non-coins). Thus surgery rate for esophagoscopy removal was 2.7% (3/109). The primary reasons for surgery were failed extraction by esophagoscopy in one who underwent four attempts and sharp edges or broadness of the object in two. Preoperative esophagography with barium was performed in two children to determine FB location in one patient and evaluate possible perforation in another. Perforation was not determined during esophagography or surgery. One patient died on the 18th postoperative day, and thus the mortality rate from surgery was 11%. This 15-month-old child had a hairpin inside his esophagus for approximately 5 months (this hairpin had been missing for 5 months according to the parents). The esophagus was long, thick and wide in diameter intraoperatively (Fig. 2a,b).

Immediate interventions were performed in 16 (1.4%) patients. Causes included respiratory distress from pressure in eight (five coins, three toy pieces), increased rupture risk due to presence of FB for more than 4 days in three (all coins) and esophageal rupture in five patients. Esophageal ruptures were diagnosed by esophagoscopy, which was performed on those with acute and serious symptoms (neck pain, blood in saliva and severe dysphagia). All of these cases occurred 36 h after ingestion (mean 74.6, range 37–120 h). Four were coins and one was a sharp-edged hairpin. All were operated on using cervical incision and

two-layer esophageal suture. These patients had an uneventful early postoperative period and have reported no long-term complications (mean 4.8 years). In two children aged 9 and 11 years, needles were removed from the supraclavicular region. Both had swallowed the needles in the previous 1 or 2 days and a radiographic view of the needles was obtained. Esophagoscopy showed nothing in the esophagus; the needles were only seen by immediate post-intervention X-ray.

Four (0.3%) perforations occurred at the time of intervention; two arose from coin extraction. Thus, the perforation rate when using direct view and forceps extraction under sedation was 0.02% (2/1107). One perforation was diagnosed at the time of the procedure, thus the patient was anesthetized and intubated; the esophagus was repaired via primary suture by cervical incision. Another perforation case was diagnosed by esophagography performed on the second postoperative day. Reasons for performing esophagography included cervical pain, fever and dysphagia with the suspicion of perforation. After stopping all oral intake and under antibiotic pressure, the patient was operated on using the same method on the 4th postoperative day. Two (1.8%, 2/109) perforations were caused by esophagoscopy

Table 2
Non-coin foreign bodies removed by esophagoscopy

	Food (%)	Metals (%)	Non-opaques (%)	Total (%)
Upper	4 (3.6)	21 (18.7)	11 (9.8%)	36 (32.1)
Middle	33 (29.4)	18 (16)	6 (5.3)	57 (50.9)
Lower	6 (5.3)	5 (4.4)	8 (7.1)	19 (17)
Total	43 (38.4)	44 (39.3)	25 (22.3)	112 (100)

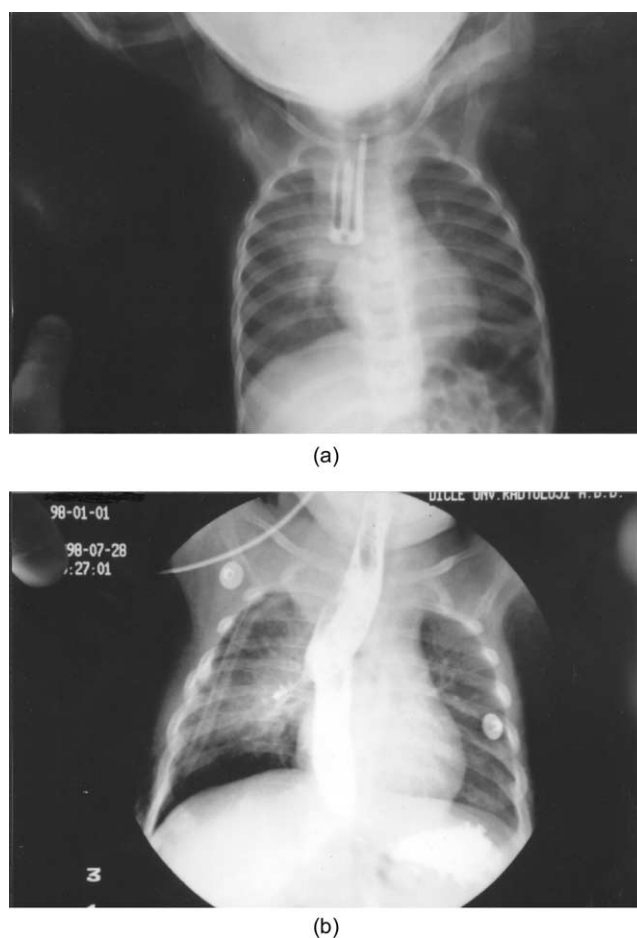


Fig. 2. (a) A hairpin on plain film of 15-month-old child. (b) Postoperative esophagography with barium.

removal, and these were diagnosed during the procedure. Both were at the second constriction of the esophagus and were repaired by thoracotomy incision.

4. Discussion

Four methods have been described for removing esophageal FBs in children: (1) rigid or flexible esophagoscopy, (2) extraction using a balloon catheter under radiographic guidance, (3) pushing the FB into the stomach by using bougienage, and (4) temporization, which allows the foreign body a chance to pass into the stomach on its own if it is lodged in the distal portion of the esophagus [3]. A sharp object in the esophagus is removed best upon presentation and must be removed under direct vision with a rigid or flexible esophagoscope. An esophagoscope may allow withdrawal of the object into the sheath for atraumatic removal [2,3,8]. Muscle relaxation due to anesthesia may cause bodies to move distally. Extractions by balloon catheter, flexible esophagoscope, bougienage or downward pressure were not used routinely. Only five coins were removed by balloon catheter and two needles by flexible

esophagoscope to improve our experience with these methods. Such methods were abandoned due to cost or relative difficulty compared to rigid esophagoscopy and direct extraction.

We have a great deal of experience regarding the extraction of coins, and emphasize that the technique we recommended herein was easy and did not require the use of general anesthesia and/or intubation. The natural curiosity of children to ingest objects is well known, and the tendency of many adults to give coins to children as gifts may be contribute to the high incidence of coin-related ingestion injuries.

We used the temporization method only for coins that passed down to the first constriction of the esophagus; no complications ensued from temporization. If the object passed into the stomach, the child's guardians were advised to watch for its passage in later stools [2,3]. Abdominal pain may be an indication of the need for surgical removal. Rigid esophagoscopy can assist in the passage of coins by causing esophageal dilatation. We do not recommend this method as it may displease children and their parents/guardians and increase the potential risk of perforation.

The success rate for the removal of FBs from the esophagus is 95–100%, regardless of the technique used [1–3]. The complication rate is generally reported to be less than 2% [3,9]. Possible severe complications arising from esophageal FBs include esophageal stricture, mediastinitis, lung abscess and esophagoaortic fistula [1,2,10]. We only encountered perforations in our patients, and this may be because our series did not include patients older than 15 years. Perforation due to swallowed FBs is rare, representing only 12–25% of all cases [11]. Esophagoscopy is associated with a perforation rate of 0.15–0.5% [12]. With perforation due to FBs, it is difficult to know with certainty the exact time of perforation, as perforation may occur at ingestion or may develop gradually through the erosion of an impacted FB through the esophageal wall [1,8,11]. The prognosis of instrumental perforation is generally better than spontaneous perforation [1,2,11]. No complications occurred after the repair of instrumental or spontaneous perforations.

It is important to try to determine how long a FB has been present because those lodged for longer than 24 h represent a greater risk of erosion or other damage to the esophagus [1,5]. This, in turn, will affect the choice of procedure for removing the FB [3]. We found the risk of perforation to be higher in children who had swallowed coins more than 36 h prior to admission.

5. Conclusion

If an FB is diagnosed early, removal should be easy. Coins can be diagnosed by X-ray and safely removed while the patient is sedated by using direct vision and forceps.

References

- [1] Eren N, Özgen G, Kuseyirgil F, Yaman T, Ceran S. Les Corps étrangers oesophagiens (apropos 48 cas). *J Dicle Univ Sch Med* 1985; 12:119–27.
- [2] Yavuzer S, Aslan R, Akay H, Ulus T, Özek A, İçöz V, Ersöz A, Işın E, Urak G. Foreign bodies of the oesophagus. Review of 52 cases. *J Ankara Univ Sch Med* 1977;30:77–105.
- [3] McGahren ED. Esophageal foreign bodies. *Pediatr Rev* 1999;20: 129–33.
- [4] Campbell JB, Foley LC. A safe alternative to endoscopic removal of blunt esophageal foreign bodies. *Arch Otolaryngol* 1983;109:323–5.
- [5] Morrow SE, Bickler SW, Kennedy AP, Synder CL, Sharp RJ, Ashcraft KW. Balloon extraction of esophageal foreign bodies in children. *J Pediatr Surg* 1998;33:266–70.
- [6] Bonadio WA, Jona JZ, Gliklich M, Cohen R. Esophageal bougienage technique for coin ingestion in children. *J Pediatr Surg* 1988;23: 917–8.
- [7] Bendig DW. Removal of blunt esophageal foreign bodies by flexible endoscopy without general anesthesia. *Am J Dis Child* 1986;140: 789–90.
- [8] Gilchrist BF, Valerie EP, Nguyen M, Coren C, Klotz D, Ramenofsky ML. Pearls and perils in the management of prolonged, peculiar, penetrating esophageal foreign bodies in children. *J Pediatr Surg* 1997;32:1429–31.
- [9] Singh B, Kantu M, Har-el G, Lucente FE. Complications associated with 327 foreign bodies of the pharynx, larynx and esophagus. *Ann Otol Rhinol Laryngol* 1997;106:301–4.
- [10] Sheen TS, Lee SY. Complete esophageal stricture resulting from a neglected foreign body. *Am J Otolaryngol* 1996;14:272–5.
- [11] Nashef SAM, Klein C, Martigne C, Velly JF, Couraud L. Foreign body perforation of the normal esophagus. *Eur J Cardiothorac Surg* 1992;6:565–6.
- [12] Eliashar R, Dano I, Dangoor E, Braverman I, Sichel JY. Computed tomography diagnosis of esophageal bone impaction: a prospective study. *Ann Otol Rhinol Laryngol* 1999;108:708–10.