

 Open access • Journal Article • DOI:10.1111/NMO.14058

Esophageal motility disorders on high-resolution manometry: Chicago classification version 4.0© — [Source link](#)

Rena Yadlapati, Peter J. Kahrilas, Mark A. Fox, Albert J. Bredenoord ...+50 more authors





Institutions: University of California, San Diego, Northwestern University, University of Zurich, University of Amsterdam ...+35 more institutions

Published on: 01 Jan 2021 - Neurogastroenterology and Motility (Wiley-Blackwell)

Topics: Esophageal motility disorder, High resolution manometry and Esophageal spasm

Related papers:

- [The Chicago Classification of esophageal motility disorders, v3.0.](#)
- [Chicago Classification Criteria of Esophageal Motility Disorders Defined in High Resolution Esophageal Pressure Topography](#)
- [Evaluation of Esophageal Motility Utilizing the Functional Lumen Imaging Probe.](#)
- [Modern diagnosis of GERD: the Lyon Consensus](#)
- [Rapid Drink Challenge in high-resolution manometry: an adjunctive test for detection of esophageal motility disorders](#)

Share this paper:    

View more about this paper here: <https://typeset.io/papers/esophageal-motility-disorders-on-high-resolution-manometry-aekmrg7lj>

Esophageal motility disorders on high-resolution manometry: Chicago classification version 4.0[©]

Rena Yadlapati¹  | Peter J. Kahrilas² | Mark R. Fox^{3,4}  | Albert J. Bredenoord⁵ | C. Prakash Gyawali⁶  | Sabine Roman^{7,8}  | Arash Babaei⁹  | Ravinder K. Mittal^{1,10}  | Nathalie Rommel¹¹ | Edoardo Savarino¹² | Daniel Sifrim¹³  | André Smout⁵  | Michael F. Vaezi¹⁴ | Frank Zerbib¹⁵  | Junichi Akiyama¹⁶ | Shobna Bhatia¹⁷ | Serhat Bor¹⁸  | Dustin A. Carlson²  | Joan W. Chen¹⁹ | Daniel Cisternas²⁰  | Charles Cock²¹  | Enrique Coss-Adame²² | Nicola de Bortoli²³  | Claudia Defilippi²⁴ | Ronnie Fass²⁵  | Uday C. Ghoshal²⁶  | Sutepon Gonlachanvit²⁷ | Albis Hani²⁸ | Geoffrey S. Hebbard²⁹ | Kee Wook Jung³⁰  | Philip Katz³¹ | David A. Katzka³² | Abraham Khan³³  | Geoffrey Paul Kohn³⁴ | Adriana Lazarescu³⁵ | Johannes Lenglinger³⁶ | Sumeet K. Mittal³⁷ | Taher Omari³⁸  | Moo In Park³⁹  | Roberto Penagini⁴⁰  | Daniel Pohl⁴¹ | Joel E. Richter⁴² | Jordi Serra⁴³  | Rami Sweis⁴⁴ | Jan Tack⁴⁵ | Roger P. Tatum⁴⁶ | Radu Tutuian^{47,48} | Marcelo F. Vela⁴⁹ | Reuben K. Wong⁵⁰ | Justin C. Wu⁵¹ | Yinglian Xiao⁵² | John E. Pandolfino²

¹Center for Esophageal Diseases, Division of Gastroenterology & Hepatology, University of California San Diego, La Jolla, CA, USA

²Division of Gastroenterology & Hepatology, Northwestern University Feinberg School of Medicine, Chicago, IL, USA

³Division of Gastroenterology and Hepatology, University Hospital, Zurich, Switzerland

⁴Department of Integrative Gastroenterology, Klinik Arlesheim, Arlesheim, Switzerland

⁵Department of Gastroenterology and Hepatology, Amsterdam University Medical Center, Amsterdam, the Netherlands

⁶Division of Gastroenterology & Hepatology, Washington University School of Medicine, St. Louis, MO, USA

⁷Digestive Physiology, Hospices Civils de Lyon, Université Lyon I, Univ Lyon, Lyon, France

⁸Hospices Civils de Lyon, INSERM, LabTAU, Université Lyon I, Univ Lyon, Lyon, France

⁹National Jewish Health, Denver, Co, USA

¹⁰Veteran Affairs San Diego Healthcare System, La Jolla, CA, USA

¹¹Department of Gastroenterology, Neurosciences, Experimental ORL, Neurogastroenterology & Motility, Deglutology - University Hospitals Leuven, University of Leuven, Leuven, Belgium

¹²Department of Surgery, Oncology and Gastroenterology, University of Padua, Padua, Italy

¹³Wingate institute of Neurogastroenterology, Queen Mary University of London, London, UK

¹⁴Vanderbilt University Medical Center, Nashville, TN, USA

¹⁵CHU de Bordeaux, Centre Medico-chirurgical Magellan, Hôpital Haut-Lévêque, Gastroenterology Department, INSERM CIC 1401, Université de Bordeaux, Bordeaux, France

¹⁶National Center for Global Health and Medicine, Tokyo, Japan

¹⁷Sir HN Reliance Foundation Hospital, Mumbai, India

¹⁸Div. Gastroenterology, Ege University School of Medicine, Izmir, Turkey

¹⁹University of Michigan, Ann Arbor, MI, USA

Abbreviations: CCv4.0, Chicago classification version 4.0; CD, crural diaphragm; CDP, contractile deceleration point; DCI, distal contractile integral; DL, distal latency; EGJ, esophagogastric junction; EGJ-CI, EGJ contractile integral; EGJOO, EGJ outflow obstruction; FLIP, functional lumen imaging probe; GRADE, grading of Recommendations Assessment Development and Evaluation; HRM, high-resolution manometry; IEM, ineffective esophageal motility; IRP, integrated relaxation pressure; LES, lower esophageal sphincter; MRS, multiple repetitive swallow; RAM, RAND Appropriateness Method; RDC, rapid drink challenge; REDCap, research Electronic Database Capture; RIP, respiratory inversion point; TBE, timed barium esophagram; UES, upper esophageal sphincter.

- ²⁰Clínica Alemana de Santiago, Facultad de Medicina Clínica Alemana, Universidad del Desarrollo, Santiago, Chile
- ²¹Flinders University, Adelaide, SA, Australia
- ²²Gastroenterology Department, Instituto Nacional de Ciencias Médicas y Nutrición, Ciudad de México, CDMX, Mexico
- ²³Department of Translational Research and New Technologies in Medicine and Surgery, University of Pisa, Pisa, Italy
- ²⁴University Hospital, University of Chile, Santiago, Chile
- ²⁵MetroHealth System and case Western Reserve University, Cleveland, OH, USA
- ²⁶Department of Gastroenterology, Sanjay Gandhi Postgraduate Institute of Medical Sciences, Lucknow, India
- ²⁷Excellence Center on Neurogastroenterology and Motility, Division of Gastroenterology, Department of Medicine, Faculty of Medicine, Chulalongkorn University, Bangkok, Thailand
- ²⁸Pontificia Universidad Javeriana-Hospital San Ignacio, Bogota, Colombia
- ²⁹Royal Melbourne Hospital, University of Melbourne, Parkville, Vic, Australia
- ³⁰Department of Gastroenterology, Asan Medical Center, University of Ulsan College of Medicine, Seoul, South Korea
- ³¹Weill Cornell Medicine, New York, NY, USA
- ³²Mayo Clinic, Rochester, MN, USA
- ³³Langone Health, New York University, New York, NY, USA
- ³⁴Monash University, Melbourne, Vic, Australia
- ³⁵University of Alberta, Edmonton, AB, Canada
- ³⁶University of Bern, Bern, Switzerland
- ³⁷Norton Thoracic Institute, Phoenix, AZ, USA
- ³⁸College of Medicine & Public Health, Flinders University, Adelaide, SA, Australia
- ³⁹Department of Internal Medicine, Kosin University College of Medicine, Busan, Korea
- ⁴⁰Gastroenterology Unit, Fondazione IRCCS Ca, Granda Ospedale Maggiore Policlinico and Department of Pathophysiology and Transplantation, University of Milan, Milan, Italy
- ⁴¹Division of Gastroenterology and Hepatology, University Hospital Zurich, Zurich, Switzerland
- ⁴²University of South Florida Morsani College of Medicine, Tampa, Florida, USA
- ⁴³CIBERehd, University Hospital Germans Trias i Pujol, Badalona, Spain
- ⁴⁴University College London Hospital, London, UK
- ⁴⁵TARGID, University of Leuven, Leuven, Belgium
- ⁴⁶Department of Surgery/VA Puget Sound HCS, University of Washington, Seattle, WA, USA
- ⁴⁷Bürgerspital Solothurn, University of Bern, Bern, Switzerland
- ⁴⁸Bürgerspital Solothurn, University of Zurich, Zurich, Switzerland
- ⁴⁹Mayo Clinic Arizona, Scottsdale, Arizona, USA
- ⁵⁰Yong Loo Lin of Medicine, National University of Singapore, Singapore, Singapore
- ⁵¹The Chinese University of Hong Kong, Hong Kong SAR
- ⁵²Department of Gastroenterology, the First Affiliated Hospital, Sun Yat-sen University, Guangzhou, China

Correspondence

John E. Pandolfino, Hans Popper
Professor of Medicine, Division of
Gastroenterology & Hepatology,
Northwestern University Feinberg School
of Medicine, 676 N. St. Clair Street,
Chicago, IL 60611, USA.
Email: j-pandolfino@northwestern.edu

Funding information

National Institute of Diabetes and
Digestive and Kidney Diseases, Grant/
Award Number: P01 DK092217

[Listen to the podcast for this article.](#)

Abstract

Chicago Classification v4.0 (CCv4.0) is the updated classification scheme for esophageal motility disorders using metrics from high-resolution manometry (HRM). Fifty-two diverse international experts separated into seven working subgroups utilized formal validated methodologies over two-years to develop CCv4.0. Key updates in CCv4.0 consist of a more rigorous and expansive HRM protocol that incorporates supine and upright test positions as well as provocative testing, a refined definition of esophagogastric junction (EGJ) outflow obstruction (EGJO), more stringent diagnostic criteria for ineffective esophageal motility and description of baseline EGJ metrics. Further, the CCv4.0 sought to define motility disorder diagnoses as conclusive and inconclusive based on associated symptoms, and findings on provocative testing as well as supportive testing with barium esophagram with tablet and/or functional lumen imaging probe. These changes attempt to minimize ambiguity in prior iterations

of Chicago Classification and provide more standardized and rigorous criteria for patterns of disorders of peristalsis and obstruction at the EGJ.

KEYWORDS

achalasia, esophageal spasm, integrated relaxation pressure, lower esophageal sphincter, peroral endoscopic myotomy

1 | INTRODUCTION

The Chicago Classification categorizes esophageal motility disorders via an algorithmic scheme using metrics from esophageal high-resolution manometry (HRM). The first full version of the Chicago Classification was published in 2009, with two updates, most recently version 3.0 published in 2015.¹⁻³ Over the past 5 years, both clinical applications and research investigations involving HRM have expanded, with introduction of novel HRM metrics. Therefore, an International HRM Working Group of 52 members worked for two years to develop the Chicago Classification version 4.0 (CCv4.0). This overview document will summarize the CCv4.0 initiative and present the updated modern day Chicago Classification of esophageal motility disorders. Although the Chicago Classification provides a framework for classification of esophageal motility disorders based on HRM, the final clinical diagnosis may require supportive testing to refine clinical decisions, particularly in borderline cases or instances where discordant findings are noted in different positions or during provocative testing.

2 | METHODS

The CCv4.0 Working Group is comprised of 52 members selected by six international motility societies, representative of 20 countries. Characteristics of the working group are detailed in Table S1. The CCv4.0 initiative was a two-year process (November 2018 to October 2020), which included three international meetings (May 2019, San Diego, CA; October 2019, Barcelona, Spain; August 2020, web-conference), multiple subgroup meetings, and seven surveys.

An initial survey conducted in January 2019 identified priority areas for update and modification from the previous 3.0 version (Table S1). Accordingly, members were assigned to seven subgroups: Standard HRM protocol, Achalasia, Esophagogastric junction (EGJ) outflow obstruction (EGJO), Distal esophageal spasm (DES), Hypercontractile esophagus, Ineffective esophageal motility (IEM), and EGJ metrics. Each subgroup was led by two co-chairs and included a non-voting member who independently reviewed supportive literature and assessed level of evidence. Co-chairs and sub-group members were tasked with developing statements to define a conclusive diagnosis of the motility disorder assigned to their sub-group, as well as to describe inconclusive scenarios for motility

disorders and the value of supportive testing. These statements were based on literature review and expert consensus.

In addition to expert consensus, a priority for CCv4.0 was to utilize formally validated methodologies to determine both appropriateness of statements, and level of supportive evidence for each statement. The RAND Appropriateness Method (RAM) was utilized, with two rounds of independent electronic voting to determine appropriateness of each statement per RAM using University of California San Diego Research Electronic Database Capture (REDCap). Statements were considered appropriate when meeting $\geq 80\%$ agreement, and are included in the final CCv4.0.^{4,5} Statements with $\geq 85\%$ agreement were considered strong recommendations, while those with 80 to 85% agreement were considered conditional recommendations. Statements nearly meeting criteria and/or those generating controversy were discussed at working group meetings. Additionally, statements that met criteria for inclusion in the final CCv4.0 underwent further independent evaluation to assess the level of supportive evidence, using the Grading of Recommendations Assessment, Development and Evaluation (GRADE) process, when possible.⁶ Two experts external to the working sub-groups, one a formally trained GRADE methodologist, independently evaluated the supportive literature provided by the sub-groups. Some statements were not amenable to the GRADE process, either because of the structure of the statement or lack of available evidence.

This document summarizes the final recommendations of the CCv4.0 working group. Separate technical reviews specific to each working group will summarize the statement development process, survey results and supporting literature. These will be published separately in future issues of *Neurogastroenterology and Motility* over the coming months.

3 | STANDARD HRM PROTOCOL & THRESHOLDS

3.1 | Standard HRM Protocol

A priority of the Chicago Classification was a standardized manometry protocol for motility laboratories around the world, to facilitate procedural consistency, improve diagnostic reliability and promote collaborative research. The final standard esophageal HRM protocol is summarized below, in Figure 1, and depicted in Figure 2. Details regarding positions, maneuvers, and bolus consistency are described in the subsequent technical review on HRM protocol.

HIGH RESOLUTION ESOPHAGEAL MANOMETRY STANDARD PROTOCOL CHICAGO CLASSIFICATION VERSION 4.0[®]

STUDY PROCEDURE

Study begins in supine position [use supine normative values]

- ≥ 60 second adaptation period
- Document position with at least 3 deep inspirations
- ≥ 30 second baseline period
- 10 supine wet (5mL) swallows
- 1 multiple rapid swallow (MRS) sequence (MRS may be repeated up to 3 sequences if failed attempt or abnormal response)

Change position to upright [use upright normative values]

- ≥ 60 second adaptation period
- Document position with at least 3 deep inspirations
- ≥ 30 second baseline period
- ≥ 5 upright wet (5mL) swallows
- 1 rapid drink challenge

If no major motility disorder is found consider the following manometric evaluations

- For high probability of a missed EGJ outflow obstruction: Solid test swallows, solid test meal, and/or pharmacologic provocation
- For suspected rumination/belching disorder: Post-prandial high-resolution impedance observation

If equivocal results are found and/or there is suspicion for an obstruction that does not fulfill criteria for achalasia, consider the following supportive tests

- Timed barium esophagram, preferably with tablet
- Endoluminal functional lumen imaging planimetry (FLIP)

CONSIDERATIONS

Prior to procedure patients should fast for at least 4 hours and informed consent should be obtained. The CCv4.0 Working Group recommends using a solid state high-resolution manometry catheter with less than 2cm sensor spacing with combined impedance sensors. However, the protocol and classification can be performed with water perfused catheters if appropriate normative values are used. Although the protocol designed by the CCv4.0 working group is considered to be the optimal protocol, clinicians can modify this protocol based on limited resources and time as long as normative values are applied and other positions and provocative tests are used appropriately. Physicians choosing to begin the study in the upright position should consider performing 10 upright swallows.

Classification is based on the primary position in which 10 wet swallows are performed, either supine or upright. Assessment of swallows in the secondary position and with provocation provide supportive data

In addition to Chicago Classification v3.0 metrics, final report should include baseline measures of the esophagogastric junction (EGJ) and symptoms experienced during the study and within 15 seconds of a motility dysfunction.

FIGURE 1 Standard high-resolution esophageal manometry protocol: Chicago Classification version 4.0 (C)

Prior to the procedure, patients should fast for at least 4 hours (small amounts of clear fluid allowed) and informed consent should be obtained.

The study begins in the supine position (Figure 2A). Following catheter placement, a minimum of 60 seconds of quiet rest allows for an adaptation period, following which catheter position is confirmed using a minimum of three deep inspirations. Next, a baseline period of at least 30 seconds is captured to enable identification of anatomic landmarks including the upper esophageal sphincter (UES), lower esophageal sphincter (LES), respiratory inversion point (RIP) and basal EGJ pressure. Following this, ten 5 ml wet swallows of ambient temperature water or saline (when using high-resolution impedance manometry) are performed. There should be at least 30 seconds between wet swallows to avoid effects of deglutitive inhibition. Finally, one multiple rapid swallow (MRS) sequence is performed (five 2 ml wet swallows administered using a 10 ml syringe 2–3 seconds apart), which can be repeated up to three times if there is a failed attempt or an abnormal contractile response.^{7,8}

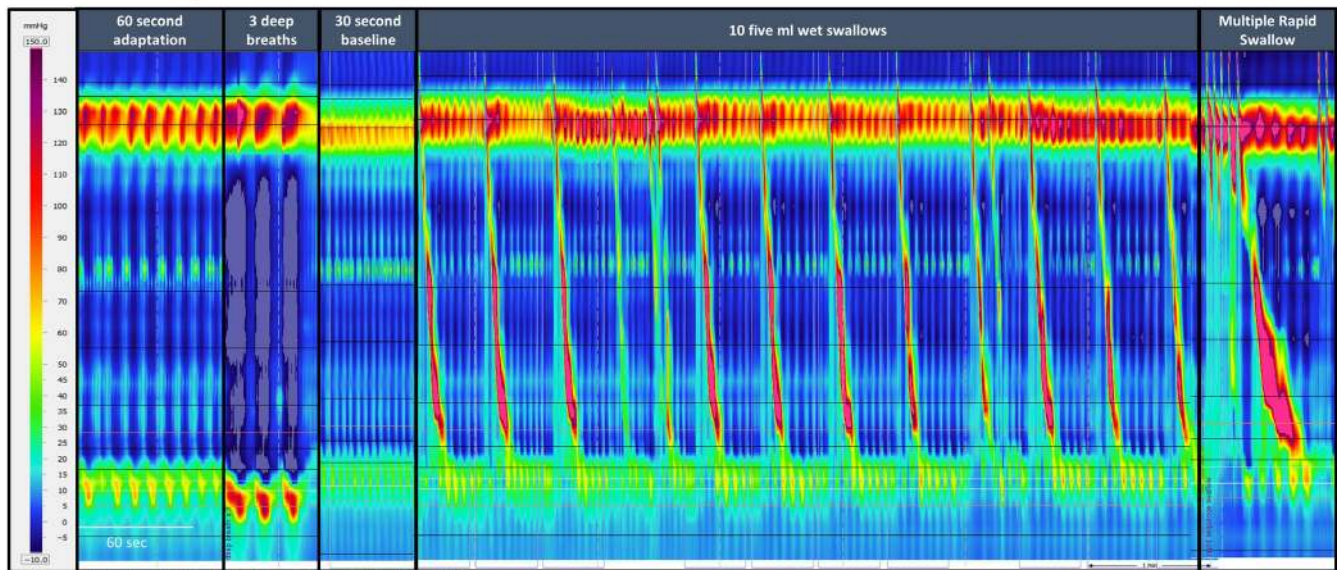
Patient position is then changed to the upright position (sitting at 80 degrees or higher with legs hanging off side of bed, but not hunched or leaning over) (Figure 2B). Following the position change, a minimum of 60 seconds to allow for adaptation, a minimum of three deep inspirations to assess catheter position, and a baseline

period of at least 30 seconds to enable identification of anatomic landmarks are once again performed. Next, at least five 5 ml wet swallows are performed. There should be at least 30 seconds between wet swallows to avoid effects of deglutitive inhibition. Finally, one rapid drink challenge (RDC) with 200 ml water, ingested as fast as possible through a straw, is performed.⁹

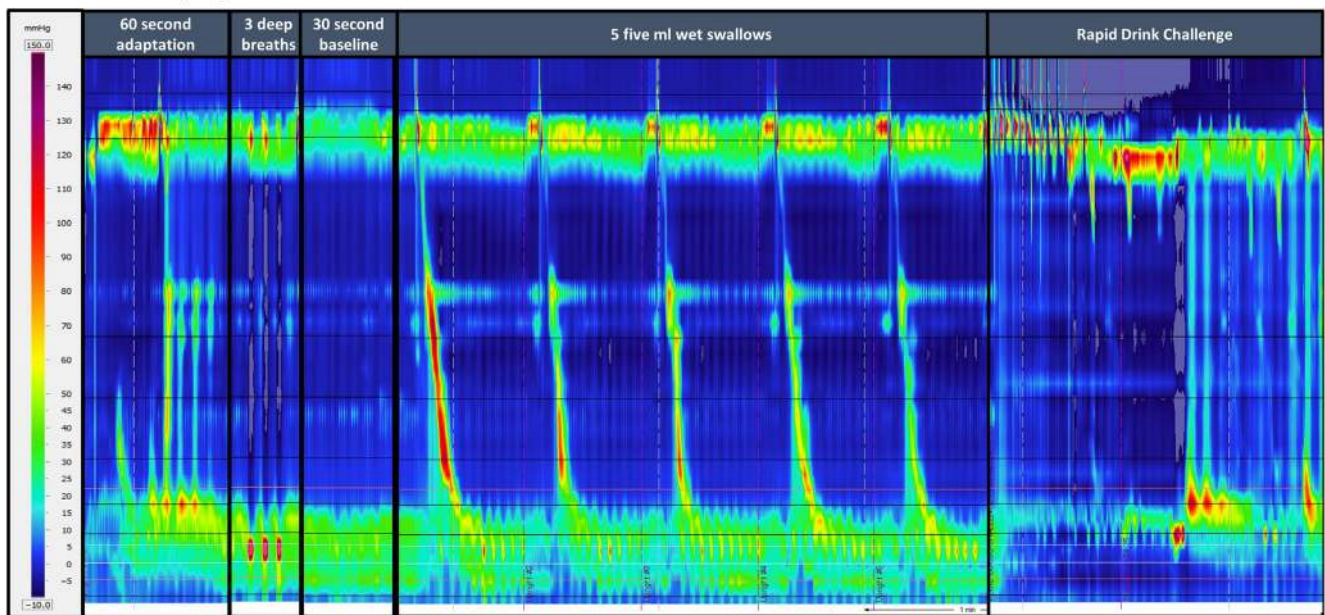
If no conclusive evidence of a major motility disorder is identified, if results from the standard esophageal HRM protocol are not fully consistent with clinical presentation and/or if findings do not explain patient symptoms, additional HRM supportive measures can be considered including solid test swallows and solid test meal to assess for EGJ obstruction, and/or post-prandial observation for rumination and/or belching disorder.¹⁰ Pharmacologic provocation, if available, can also be performed to help support a diagnosis of a true disorder of EGJ obstruction. (Figures S1–S3)¹¹

Additionally, if equivocal results are identified and/or there is a suspicion for an EGJ outflow obstruction that does not fulfill the criteria for achalasia, a timed barium esophagram (TBE), preferably in conjunction with a barium tablet swallow, and/or endoluminal functional lumen imaging probe (FLIP) should be obtained as independent supportive tests to assess for EGJ obstruction.^{12,13}

The CCv4.0 Working Group recommends using a solid-state HRM catheter with less than 2 cm sensor spacing. However, the

(A) Protocol in Supine Position

Courtesy of University of California San Diego Center for Esophageal Diseases

(B) Protocol in Upright Position

Courtesy of University of California San Diego Center for Esophageal Diseases

FIGURE 2 High-resolution manometry images depicted the standard protocol. A, The supine position includes a 60 second adaptation period, 3 deep breaths, 30 second baseline period, 10 five ml wet swallows and at least one multiple rapid swallow. B, Position is changed to the upright position followed by a 60 second adaptation, 3 deep breaths, 30 second baseline period, 5 five ml wet swallows, and a rapid drink challenge

protocol and classification can be performed with water perfused catheters if appropriate normative values are used (with the limitation of only supine swallows and maneuvers possible with water perfused manometry). Using high-resolution impedance manometry is recommended, though not required, to optimally assess intrabolus pressure, bolus clearance and bolus flow through the EGJ. The protocol should be performed as efficiently as possible to minimize potential of pressure drift, reduce patient discomfort, and improve patient tolerance.

3.2 | Diagnostic Thresholds and Definitions

The key HRM metrics utilized in the CCv4.0 consist of assessment of deglutitive relaxation across the LES/EGJ using integrated relaxation pressure (IRP), vigor of esophageal body contraction using distal contractile integral (DCI), contractile wavefront integrity at 20 mmHg isobaric contour setting, and latency of deglutitive inhibition using distal latency (DL) (Table 1). The thresholds for median IRP are higher in the supine position compared to the upright position.

TABLE 1 HRM Metrics and Thresholds

Assessment	Pressure Topography Metrics	Definition	Diagnostic Threshold	Additional Considerations
Relaxation pressure across the esophagogastric junction in response to deglutition	Integrated relaxation pressure (IRP)	Mean of the 4 s of maximal deglutitive relaxation in the 4-s window beginning at UES relaxation, contiguous or non-contiguous, referenced to gastric pressure	Abnormal deglutitive IRP relaxation: <ul style="list-style-type: none"> Supine median IRP ≥ 15 mmHg (Medtronic) Supine median IRP ≥ 22 mmHg (Laborie/Diversatek) Upright median IRP ≥ 12 mmHg (Medtronic) Upright median IRP ≥ 15 mmHg (Laborie/Diversatek) 	IRP >12 mmHg (Medtronic) on rapid drink challenge (RDC) or IRP >25 mmHg (Medtronic) on solid test meal supports outflow obstruction
Esophageal peristalsis	Distal Contractile Integral (DCI) - Contractile Vigor	Amplitude \times duration \times length (mmHg \bullet s \bullet cm) of the distal esophageal contraction exceeding 20 mmHg from the transition zone to the proximal margin of the LES	<ul style="list-style-type: none"> Normal Contraction: DCI 450–8,000 mmHg\bullets\bulletcm Weak Contraction: DCI >100 and <450 mmHg\bullets\bulletcm Failed Peristalsis: DCI <100 mmHg\bullets\bulletcm Hypercontractile Swallow: DCI $>8,000$ mmHg\bullets\bulletcm Ineffective Swallow: weak contraction or failed peristalsis Ineffective Swallow: Peristaltic break >5 cm in setting of a DCI ≥ 450 mmHg\bullets\bulletcm 	Intact contractile response on multiple rapid swallow (MRS): DCI <100 mmHg \bullet s \bullet cm during MRS and DCI greater than single swallow mean DCI following MRS
Latency of deglutitive inhibition	Contractile Wavefront Integrity Distal latency (DL)	Contiguity of peristalsis in an isobaric contour of 20 mmHg Interval between UES relaxation and CDP	<ul style="list-style-type: none"> Premature/Spastic contraction: DL <4.5 seconds in setting of a DCI ≥ 450 mmHg\bullets\bulletcm 	
Pressurization	Isobaric Contour		<ul style="list-style-type: none"> Panesophageal pressurization: isobaric contour of ≥ 30 mmHg Intrabolus pressurization: isobaric contour of ≥ 20 mmHg in the supine position (Medtronic) 	Panesophageal pressurization >20 mmHg on RDC or solid test meal supports outflow obstruction

Upper esophageal sphincter (UES); lower esophageal sphincter (LES).

The thresholds for DCI and DL are the same for both supine and upright positions.

3.2.1 | Integrated relaxation pressure

- Threshold for median IRP in the supine position is 15 mmHg for Medtronic systems and 22 mmHg for Laborie/Diversatek systems (Moderate GRADE, Strong Recommendation).^{14–17}
- Threshold for median IRP in the upright position is 12 mmHg for Medtronic systems and 15 mmHg for Laborie/Diversatek systems (Low GRADE, Strong Recommendation).^{16–18}

3.2.2 | Contractility in the esophageal body

Contractility in the esophageal body is assessed by contractile vigor and contractile pattern.^{16,17}

- Normal Contraction: DCI of 450 mmHg•s•cm to 8,000 mmHg•s•cm
- Ineffective Swallow includes any of the following:
 - a. Weak Contraction: DCI between 100 mmHg•s•cm and less than 450 mmHg•s•cm
 - b. Failed Peristalsis: DCI <100 mmHg•s•cm
 - c. Fragmented Swallow: Transition zone defect of peristalsis greater than 5 cm under an isobaric contour of 20 mmHg in the setting of a DCI of 450 mmHg•s•cm or greater
- Hypercontractile Swallow: DCI greater than 8,000 mmHg•s•cm.
 - a. Available literature on normal values suggests that the threshold of 8,000 mmHg•s•cm is suitable across HRM systems.

3.2.3 | Latency of deglutitive inhibition

Distal latency is measured as the interval from the start of relaxation of the UES to the contractile deceleration point (CDP). The CDP is the inflection point between the proximal rapid and the distal slow phase of the esophageal contraction, located within 3 cm of the proximal aspect of the pre-swallow EGJ high-pressure zone. Physiologically, this likely represents conversion from smooth muscle esophageal body contraction to the LES after-contraction.

- Premature contraction: A distal latency shorter than 4.5 seconds, in the setting of a DCI of 450 mmHg•s•cm or greater¹⁶

If the CDP is difficult to determine, a horizontal line can be drawn 2–3 cm above the proximal aspect of the pre-swallow EGJ high-pressure zone and the DL can be determined by the duration of time from the start of the UES relaxation to the intersection at the contractile wavefront. It is important that this horizontal line is extended to the contraction and not to the pressurization front

that can be compartmentalized ahead of the peristaltic contractile wavefront. Esophageal contractile activity must be distinguished from other causes of pressure rise in the distal esophagus such as intrabolus pressure and/or artifact. (Very Low GRADE, Strong Recommendation).^{19,20}

3.2.4 | Pressurization

- Panesophageal pressurization: The cutoff for panesophageal pressurization is set at 30 mmHg using the isobaric contour tool (Very Low GRADE, Strong Recommendation).²¹
- Intrabolus pressurization: The intrabolus pressure threshold for supine wet swallows using the Medtronic system is 20 mmHg using the isobaric contour tool (Moderate GRADE, Strong Recommendation).^{14,22,23}

3.2.5 | Response to provocation

- Multiple Rapid Swallows: An intact response to MRS is defined as absence of esophageal body contractility (DCI < 100 mmHg•s•cm) with complete deglutitive inhibition of the LES during the repetitive swallows, and presence of post-MRS contraction augmentation (DCI post-MRS greater than single swallow mean DCI; Table 2).^{7,24–26} The post-MRS contraction needs to be true peristaltic contractility and not artifact or pressurization.
- Rapid Drink Challenge: An intact response to RDC is defined as absence of esophageal body contractility (DCI < 100 mmHg•s•cm) with complete deglutitive inhibition of the LES during the RDC. When assessing response to RDC, IRP >12 mmHg (using Medtronic software) over the first 30 seconds of the RDC challenge and panesophageal pressurization >20 mmHg are criteria for outflow obstruction (Low GRADE, Conditional Recommendation).^{9,26–29} The presence of a normal contraction sequence following the RDC is a specific marker of normal contractility; however, this is not present in all healthy controls.^{9,27,28}
- Solid Test Swallows: An intact esophageal body contractile response to solid swallows requires presence of >20% pharyngeal swallows, followed by an effective esophageal contraction defined by DCI > 1000 mmHg•s•cm and without a large break (>5 cm) in the contractile front. The upper limit of normal IRP (using Medtronic software) with solid swallows is 25 mmHg.³⁰ Temporal association of ineffective contractions with patient symptoms (e.g. dysphagia) supports diagnosis of clinically relevant, abnormal peristaltic function.^{10,29}
- Pharmacologic Provocation: If available at the motility laboratory, pharmacologic provocation using either an amyl nitrite and/or cholecystokinin protocol can be useful to evaluate physiology at the EGJ. The protocol and physiologic responses to pharmacologic provocation are detailed in Table 2.^{31,32}

TABLE 2 Supportive manometric measures which may increase confidence for a disorder

Supportive measure	Protocol	Normal response
Multiple Rapid Swallows (MRS)	Five swallows of 2-mL liquid at 2–3 second intervals	Absence of esophageal body contractility (DCI <100 mmHg•s•cm) with complete deglutitive inhibition of the LES during MRS and presence of post-MRS contraction augmentation (DCI post-MRS greater than single swallow mean DCI).
Rapid Drink Challenge (RDC)	Rapid drink of 200 ml of liquid	Absence of esophageal body contractility (DCI <100 mmHg•s•cm) with complete deglutitive inhibition of the LES during RDC and no evidence of major motility disorder post-RDC.
Solid Test Swallows	Ten swallows of ~1-cm ³ soft solid (eg bread, soft boiled rice, marshmallow)	Presence of >20% pharyngeal swallows being followed by an effective esophageal contraction defined by DCI >1000 mmHg•s•cm and without a large break (>5 cm) in the contractile front.
Solid Test Meal (STM)	200 g of soft solid meal (eg soft boiled rice, bread) ingested at normal rate for patient. Study stopped if STM not completed in 8-min.	Presence of >20% pharyngeal swallows being followed by an effective esophageal contraction defined by DCI >1000 mmHg•s•cm and without a large break (>5 cm) in the contractile front. No symptoms during STM (any symptoms should be recorded in electronic record to assess association with abnormal motility or function). Slow eating with <200 g ingested during 8 minutes also considered abnormal.
Post-Prandial Meal (High-resolution impedance manometry)	Administration of a STM or a self-identified symptom inducing meal followed by extended monitoring (minimum of 10 minutes and occurrence of abnormal activity)	Absence of symptoms and abnormal motility or function during post-prandial period. Maximum 4 transient LES relaxations (TLESRs) with belching during initial 10-minute post-prandial, no volume regurgitation, no rumination or supra-gastric belching episodes.
Pharmacologic Provocation	Amyl Nitrite inhalator (4–5 sniffs) in recumbent position	Profound distal esophageal and LES smooth muscle inhibition with reduction in deglutitive IRP. In healthy controls amyl nitrite-induced EGJ IRP is similar to deglutitive IRP. In patients with a disorder of EGJ obstruction, such as achalasia and true functional EGJOO, amyl nitrite-induced EGJ pressure drop is markedly lower (≥ 10 mmHg) than compromised deglutitive IRP (i.e., relaxation gain). In contrast, amyl nitrite in patients with EGJOO secondary to other factors than LES smooth muscle dysfunction will display little amyl nitrite-induced EGJ pressure change (< 10 mmHg).
	Cholecystokinin (CCK) 40 ng/kg IV in recumbent position	CCK generally triggers a biphasic esophageal motor response. Phase 1 is always present and starts shortly after injection. In healthy controls, CCK induces a mild esophageal shortening (2 cm or less) associated with incomplete EGJ relaxation (inspiratory crural diaphragm contraction preserved). In contrast, CCK in patients with inhibitory dysfunction such as achalasia induces a paradoxical EGJ contraction of more than 50 mmHg.

Classification is based on the primary position in which 10 wet swallows are performed, either supine or upright. Assessment of swallows in the secondary position and with provocation serves as supportive data (with the exception of EGJOO and absent contractility).

Abbreviations: DCI, Distal Contractile Integral; EGJ, esophagogastric junction; EGJOO, EGJ outflow obstruction; IRP, integrated relaxation pressure; LES, lower esophageal sphincter.

3.3 | Key considerations for protocol in context of the Chicago classification

It is expected that the majority of laboratories will continue with the convention of starting the manometry protocol in the supine position. Although the standard HRM protocol described is considered to be optimal and inclusive, clinicians can modify this protocol to adapt to available resources and time, as long as established normative values are applied and other positions and supportive measures are used appropriately. Clinicians choosing to begin the

study in the upright position should perform 10 upright swallows at the outset.

Classification using CCv.4.0 is based on 10 wet swallows in the primary test position, either supine or upright. Assessment of swallows in the secondary position and with provocation provides supportive data (with the exception of EGJOO and absent contractility as detailed later in this document). CCv.4.0 recognizes the potential for variation in findings when changing test position. Concordant findings in the secondary position and with provocation increase strength of confidence of the classification and eventual diagnosis.

On the other hand, discordant findings in the secondary position and/or with provocation should prompt reconsideration of the diagnosis, and further supportive testing prior to a conclusive diagnosis.

4 | CHICAGO CLASSIFICATION v4.0 OF ESOPHAGEAL MOTILITY DISORDERS

The hierarchical classification scheme of past versions of the Chicago Classification is maintained in CCv4.0, whereby motility disorders are classified as disorders of EGJ outflow and/or disorders of peristalsis (Table 3, Figure 3). The classification scheme applies to patients with normal foregut anatomy, without prior surgical or invasive foregut intervention and without large hiatal hernias and/or paraesophageal hernias, as these anatomical changes can alter measurement of the CC metrics and are associated with contact artifacts due to bending of the catheter that may persist after position change. Additionally, a careful index endoscopy is crucial prior to manometry testing, as endoscopic or radiographic evidence of mechanical obstruction precludes the use of CCv4.0. An additional update in CCv4.0 is the

emphasis that specific motility disorders should be considered clinically relevant only in the context of compatible symptoms and/or supportive testing, as detailed in this document and indicated by an asterisk in the figures.

5 | DISORDERS OF EGJ OUTFLOW (TABLE S2)

Consistent with prior iterations of Chicago Classification, disorders of EGJ outflow include achalasia (types I, II, and III) and EGJ outflow obstruction. All disorders of EGJ outflow require an abnormal median IRP in the primary position. Given the high pre-test probability of achalasia with the requirement of 100% absent peristalsis, an abnormal IRP in the primary position is considered conclusive for achalasia. On the other hand, the presence of appreciable peristalsis in EGJOO lowers the pre-test probability of true LES dysfunction, and thus a conclusive manometric diagnosis of EGJOO requires an abnormal median IRP in both primary and secondary positions, as well as complimentary testing to confirm the diagnosis.

TABLE 3 Classification and Definition of Manometric Disorders

Classification	Disorder	Definition
Disorders of EGJ Outflow	Type I Achalasia	Abnormal median IRP & 100% failed peristalsis
	Type II Achalasia	Abnormal median IRP, 100% failed peristalsis, & $\geq 20\%$ swallows with panesophageal pressurization
	Type III Achalasia ^a	Abnormal median IRP & $\geq 20\%$ swallows with premature/spastic contraction and no evidence of peristalsis
	EGJ Outflow Obstruction ^{b,c}	Abnormal median IRP (supine and upright), $\geq 20\%$ elevated intrabolus pressure (supine), and not meeting criteria for achalasia
Disorders of Peristalsis	Absent Contractility	Normal median IRP (supine and upright) & 100% failed peristalsis
	Distal Esophageal Spasm ^c	Normal median IRP & $\geq 20\%$ swallows with premature/spastic contraction
	Hypercontractile Esophagus ^c	Normal median IRP & $\geq 20\%$ hypercontractile swallows
	Ineffective Esophageal Motility	Normal median IRP, with $>70\%$ ineffective swallows or $\geq 50\%$ failed peristalsis

Distal Contractile Integral (DCI); integrated relaxation pressure (IRP); esophagogastric junction (EGJ)

^aCCv4.0 recognizes that the distinction between type III achalasia and conclusive EGJOO can be difficult and was vague in CCv3.0. In CCv4.0 achalasia is defined by 100% absent peristalsis which is inclusive of swallows that are either failed or premature and Type III achalasia should not have evidence of normal peristalsis [normal or ineffective swallows].

^bPatients with EGJ obstruction and evidence of peristalsis would fulfill strict criteria for EGJOO and may have features suggestive of achalasia or other patterns of peristalsis defined by criteria used for disorders of peristalsis: EGJOO with spastic features [presence of $\geq 20\%$ premature swallows], EGJOO with hypercontractile features, EGJOO with ineffective motility, or EGJOO with no evidence of disordered peristalsis.

^cDenote manometric patterns of unclear clinical relevance. A clinically relevant conclusive diagnosis requires additional information which may include clinically relevant symptoms and/or supportive testing (as detailed in the document).

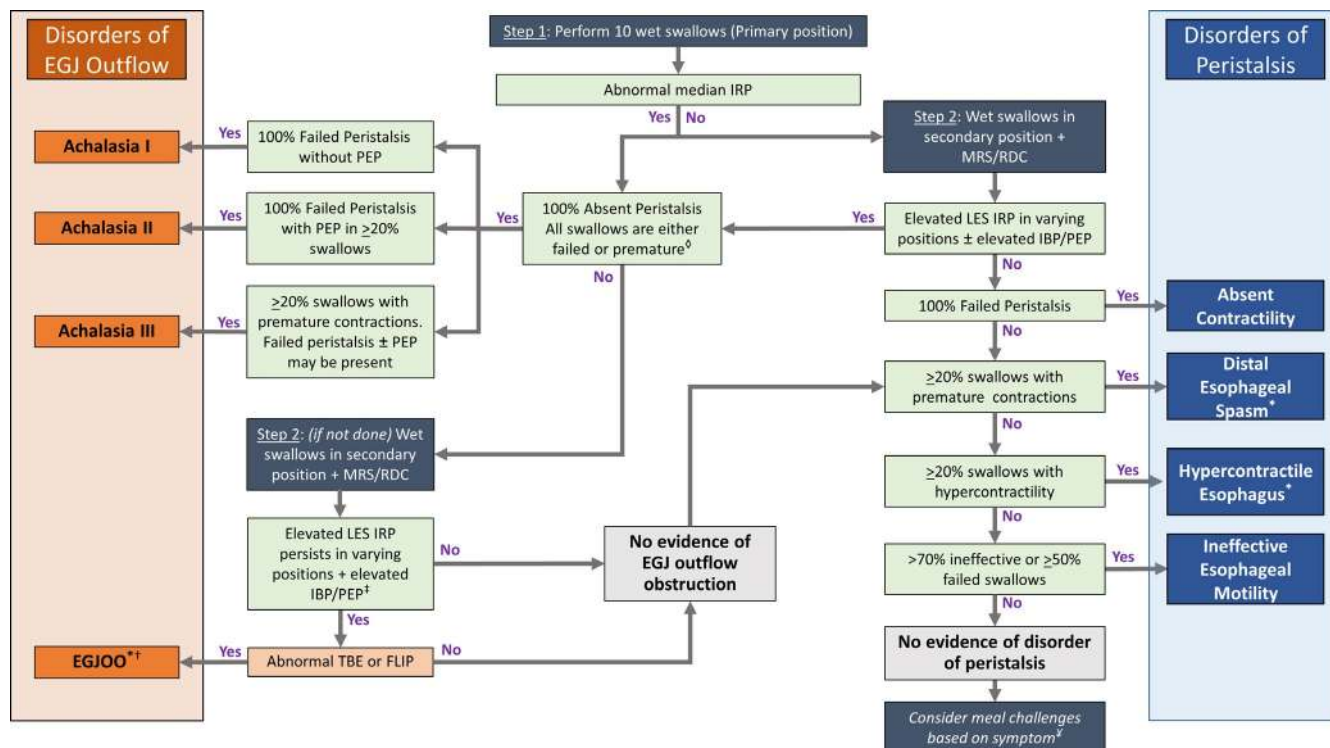


FIGURE 3 Chicago Classification 4.0 Hierarchical Classification Scheme. This flow diagram represents a conceptual model of a state-of-the-art algorithm that defines the flow process of how the CCv4.0 diagnosis is generated within the constructs of the various phases of the protocol. In this conceptual model, the current protocol allows for some flexibility if the diagnosis is conclusive with 10 swallows in either the primary supine or upright position and allows for a sequenced progression of the protocol to help confirm or rule out the diagnosis. This flow diagram represents the optimal flow process, however exceptions will exist based on the fact that some cutoffs are arbitrary and that the model assumes that a motility expert or a highly qualified motility technician or nurse is performing the protocol and analysis. *Denote manometric patterns of unclear clinical relevance. A clinically relevant conclusive diagnosis requires additional information which may include clinically relevant symptoms and/or supportive testing (as detailed in the document). †Patients with EGJ obstruction and presence of peristaltic swallows would fulfill strict criteria for EGJOO and may have features suggestive of achalasia or other patterns of peristalsis defined by criteria for disorders of peristalsis: EGJOO with spastic features, EGJOO with hypercontractile esophagus, EGJOO with ineffective motility, or EGJOO with no evidence of disordered peristalsis. ‡RDC, solid test swallows, and/or pharmacologic provocation with amyl nitrite or cholecystokinin (if available) can be instituted here to assess for obstruction. §Patients previously defined absent contractility based on 10 swallows in the primary position may have achalasia if the IRP is elevated in the alternate position, with the RDC, and/or with MRS. These cases should be considered inconclusive for type I or II achalasia as appropriate and evaluated further with TBE/FLIP. ¶ If no evidence of a disorder of peristalsis or EGJ outflow in a patient with high probability of a missed EGJOO, a solid test meal can be added to rule out an obstructive pattern; if abnormal then possibility of a mechanical obstruction should be readdressed. In a patient with regurgitation or belching, post-prandial high-resolution impedance monitoring can be used to assess for rumination/belching disorder. Integrated relaxation pressure (IRP); Multiple rapid swallow (MRS); Rapid drink challenge (RDC); Lower esophageal sphincter (LES); Intrabulbar pressurization (IBP); Panesophageal pressurization (PEP); Esophagogastric junction (EGJ); EGJ outflow obstruction (EGJOO); Timed barium esophagram (TBE); Functional lumen imaging probe (FLIP)

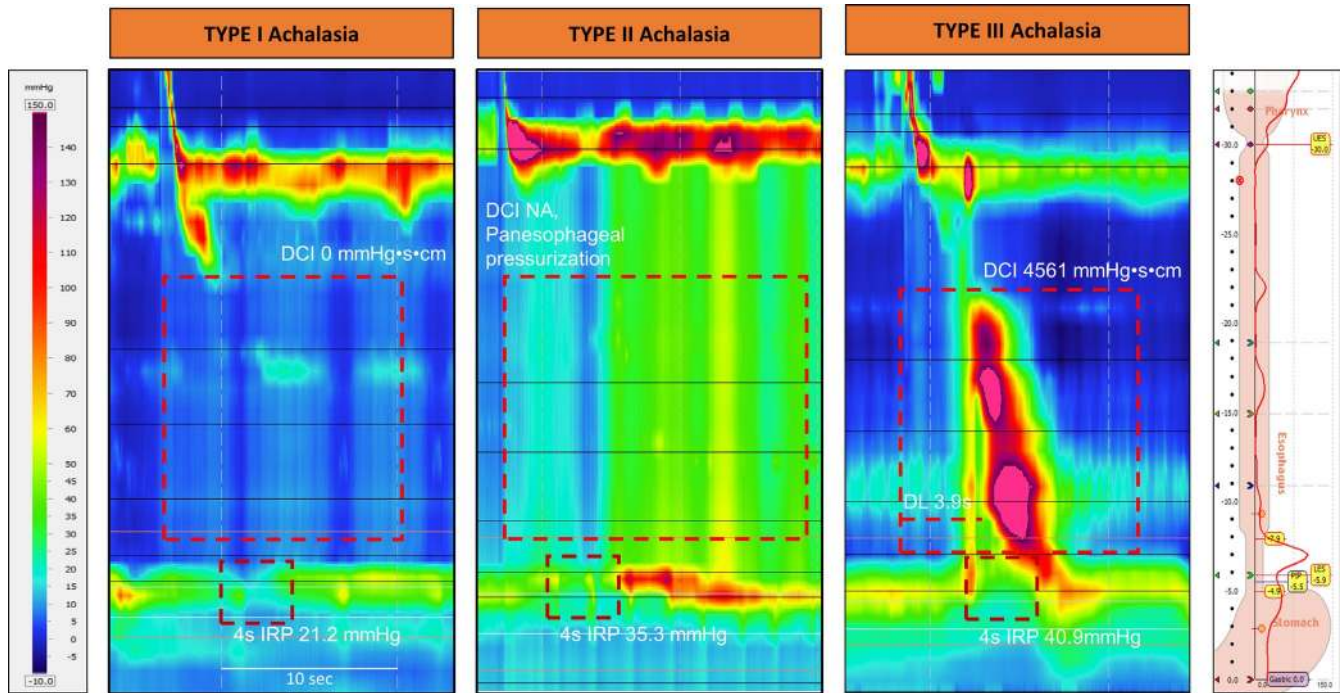
6 | ACHALASIA

CCv4.0 maintains three subtypes of achalasia: type I akin to classic achalasia, type II seen with panesophageal pressurization, and type III, or spastic, achalasia (Figure 4). As mentioned, a CCv4.0 update for achalasia is that an abnormal median IRP can be observed in either a primary supine position or a primary upright position (if performed with 10 wet swallows) and does not require an abnormal median IRP in both supine and upright positions. Further, in CCv4.0 a definition of achalasia requires 100% absent peristalsis, defined as all swallows with either failed peristalsis or premature contraction.

6.1 | Conclusive Diagnosis of Achalasia

Type I Achalasia: A conclusive diagnosis of type I achalasia is defined as an abnormal median IRP and absent contractility (100% failed peristalsis) (Very Low GRADE, Strong Recommendation).^{21,33-36}

Type II Achalasia: A conclusive diagnosis of type II achalasia is defined as an abnormal median IRP and absent contractility (100% failed peristalsis) with panesophageal pressurization in 20% or more swallows (Very Low GRADE, Strong Recommendation).^{21,33-36}



Courtesy of University of California San Diego Center for Esophageal Diseases

FIGURE 4 Achalasia Subtypes. Type I Achalasia: integrated relaxation pressure (IRP) is elevated with failed peristalsis (distal contractile integral (DCI) <100 mmHg·s·cm), and without panesophageal pressurization. Type II Achalasia: IRP is elevated with failed peristalsis and panesophageal pressurization. Type III Achalasia: IRP is elevated with a normal DCI, and a reduced distal latency. Not applicable (NA)

Type III Achalasia: A conclusive diagnosis of type III achalasia is defined as an abnormal IRP and evidence of spasm (20% or more swallows with premature contraction) with no evidence of peristalsis (Very Low GRADE, Strong Recommendation).^{21,33–36}

6.2 | Inconclusive Diagnosis of Achalasia

- An inconclusive diagnosis of type I or II achalasia includes absent contractility with no appreciable peristalsis in the setting of IRP values at the upper limit of normal in both positions, with or without panesophageal pressurization in 20% or more swallows (Strong Recommendation) (Figure 5).
- Evidence of appreciable peristalsis with changing position in the setting of a type I or II achalasia pattern in the primary position can shift the diagnosis toward an inconclusive diagnosis requiring supportive testing (Accepted Clinical Observation).
- An inconclusive diagnosis of type III achalasia includes an abnormal IRP with evidence of spasm and evidence of peristalsis. If these cases fulfill strict criteria for EGJOO (as detailed in the EGJOO section), these patients should be classified as EGJOO with spastic features, which may represent an achalasia variant.

6.3 | Additional Considerations for Achalasia

- The cutoff of spasm in 20% of swallows is arbitrary, and confidence in a diagnosis of a type III achalasia variant may

be increased with a higher number of premature/spastic swallows.

- Supportive testing with a TBE, preferably in conjunction with a barium tablet swallow, and/or FLIP should be performed in patients with an inconclusive diagnosis of achalasia in the setting of dysphagia as a presenting symptom (Very Low GRADE, Strong Recommendation).^{12,13,37–43}
- Opioids are associated with type III achalasia and patients should be studied off opioid medication if possible (Low GRADE, Conditional Recommendation).^{44,45} Timing of opioid discontinuation should be based on medication half-life.

The following achalasia statements did not meet criteria for agreement, but are recommended considerations for HRM studies suggestive of achalasia as detailed further in the technical reviews. The pressure cutoff value for panesophageal pressurization is meant to be a guide rather than a hard threshold. The distinction between type I and II achalasia is somewhat arbitrary and does not have important clinical implications beyond the very low levels (typically <15 mmHg) seen with moderate to severe esophageal dilation and an inability to generate emptying pressurization. Patients with panesophageal pressurization values above 70 mmHg may have embedded spasm, which may impact clinical outcome.

7 | EGJ OUTFLOW OBSTRUCTION

A critical update in CCv4.0 is clarification and rigorous definition of EGJOO (Figure 6). Following introduction of EGJOO

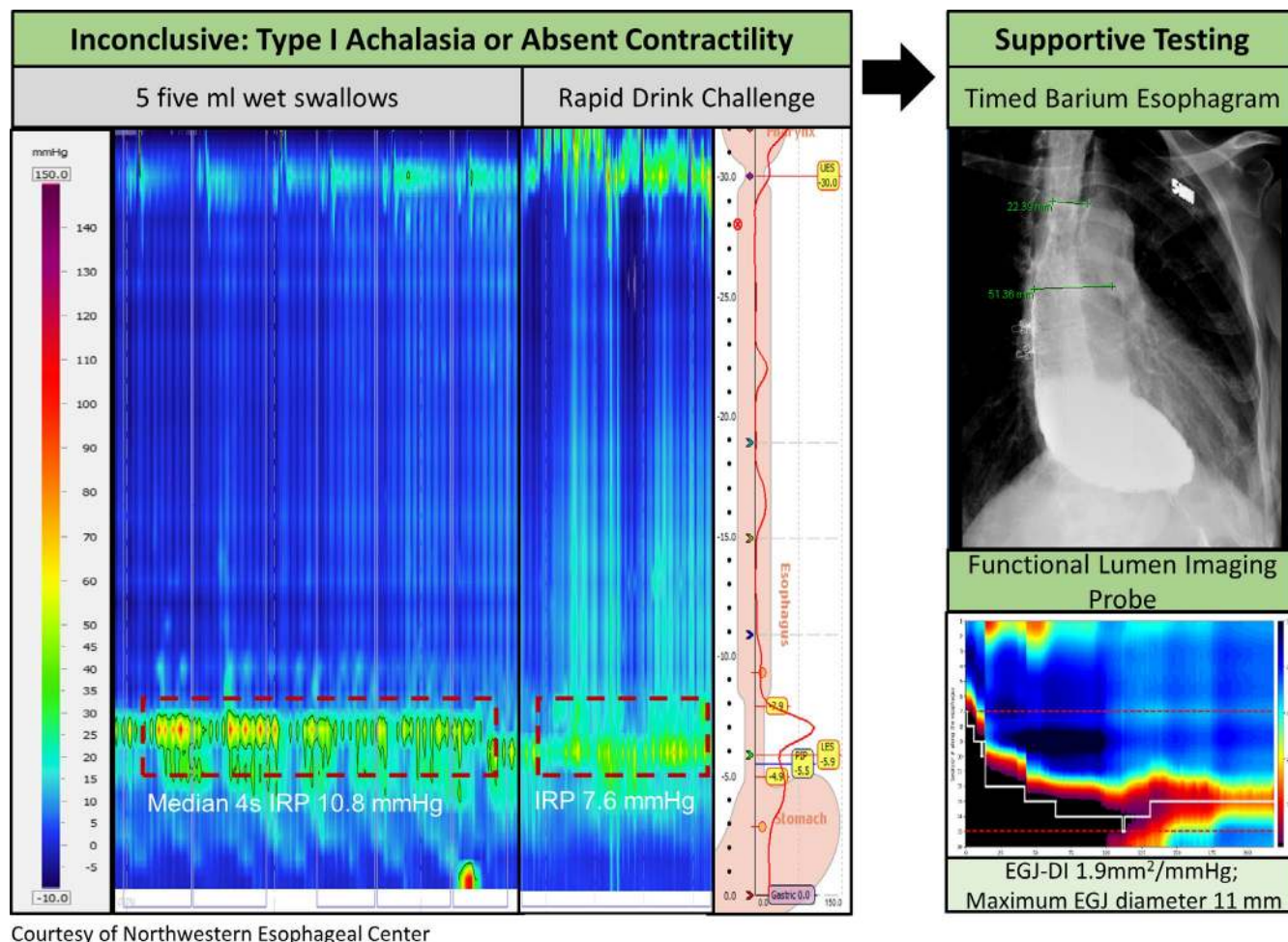
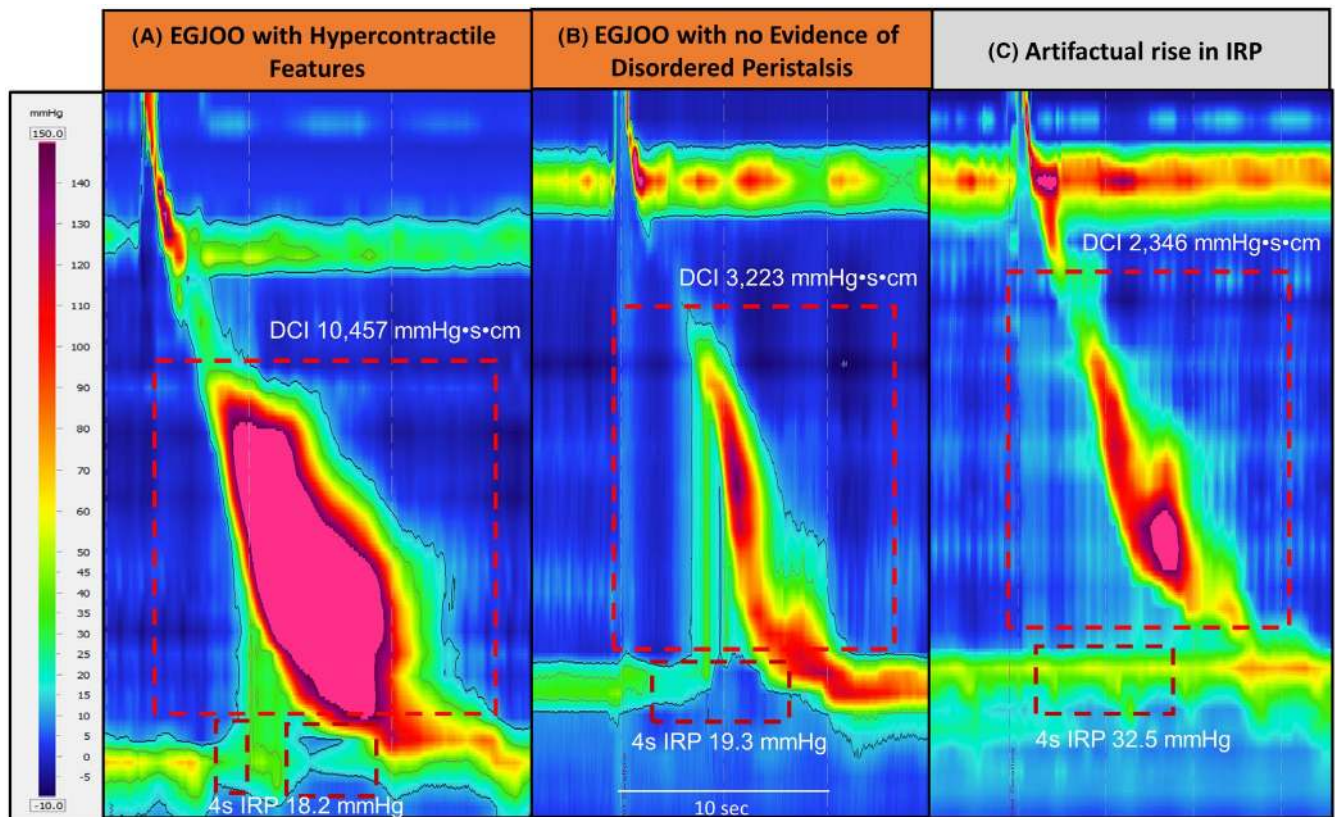


FIGURE 5 Inconclusive Diagnosis for Achalasia or Absent Contractility Requires Supportive Testing. Findings are inconclusive for type I achalasia or absent contractility as there is 100% failed peristalsis but the median integrated relaxation pressure (IRP) is at the upper limit of normal with 5 ml wet swallows. With the rapid drink challenge, there is absence of deglutitive inhibition across the lower esophageal sphincter (LES). Supportive testing is required in the setting of inconclusive findings with timed barium esophagram and/or functional lumen imaging probe (FLIP). Here, the timed barium esophagram demonstrates a dilated distal esophagus with barium retention. On FLIP, the esophagogastric junction (EGJ) distensibility index (EGJ-DI) is reduced, maximal EGJ diameter is reduced and there is absent contractile response to distension

as a motility disorder, nearly 10% of patients undergoing HRM were identified to have an EGJOO motility pattern.^{18,46} While a proportion of EGJOO may evolve toward achalasia or represent a variant of achalasia, more than one-third of cases may be clinically irrelevant and related to benign etiologies including mechanical effects, opioid use, and artifact as detailed in the subsequent EGJOO technical review. To avoid unnecessary treatments and to optimize outcomes, there is a critical need to clarify which patients with manometric EGJOO have obstructive physiology causing symptoms and requiring intervention.^{13,18,22,23,39,46–52} Therefore, CCv4.0 recommends the following to distinguish between clinically relevant EGJOO that may represent an underlying pathologic motor disorder responsive to treatment versus a clinically irrelevant manometric observation.

7.1 | Clinically Relevant Conclusive Diagnosis of EGJOO

- A manometric diagnosis of EGJOO is always considered clinically inconclusive (Strong Recommendation).
- A manometric diagnosis of EGJOO is defined as an elevated median IRP in the primary and secondary position and $\geq 20\%$ swallows with elevated intrabolus pressure in the supine position, with evidence of peristalsis (Low GRADE, Conditional Recommendation).^{11,18,46,50,51,53–55}
- A clinically relevant conclusive diagnosis of EGJOO requires a manometric diagnosis of EGJOO and clinically relevant symptoms with at least one of the following supportive investigations supporting obstruction (TBE, preferably in conjunction with a barium tablet swallow, and/or FLIP) (Moderate GRADE, Conditional Recommendation).^{11–13,18,37}



Courtesy of National Jewish Health, Esophageal Function Laboratory

FIGURE 6 EGJOO subtypes: A) EGJOO with hypercontractile features: IRP is elevated with intrabolus pressurization and hypercontractile swallow. B) EGJOO with no evidence of disordered peristalsis: IRP is elevated with normal contractile vigor. C) Manometric EGJOO related to artifactual rise in IRP: IRP is elevated in the absence of intrabolus pressurization and is likely associated with artifact. Esophagogastric junction (EGJ); EGJ outflow obstruction (EGJOO); integrated relaxation pressure (IRP); distal contractile integral (DCI)

- Clinically relevant symptoms of EGJOO include dysphagia and/or non-cardiac chest pain (Low GRADE, Conditional Recommendation).^{23,39,47,49–51,56,57}

if temporally associated with patient symptoms (Conditional Recommendation)^{10,30} (Figure S1)

- Supportive evidence for a manometric diagnosis of EGJOO includes abnormal EGJ function following pharmacologic provocation¹¹ (Conditional Recommendation) (Figure S2)

7.2 | Inconclusive Diagnosis of EGJOO

- Isolated elevated abnormal findings are inconclusive for a manometric diagnosis of EGJOO. These include isolated elevated supine IRP, isolated elevated upright IRP, or isolated elevated supine intrabolus pressure (Low GRADE, Strong Recommendation).^{46,58,59}

EGJOO should be described in the context of the pattern of peristalsis: EGJOO with spastic features (features of type III achalasia), EGJOO with hypercontractile features, EGJOO with ineffective motility, or EGJOO with no evidence of disordered peristalsis. (Accepted Clinical Observation).

7.3 | Additional Considerations for EGJOO

The following are not essential but provide supportive evidence for a diagnosis of EGJOO.

- Supportive evidence for a manometric diagnosis of EGJOO includes outflow obstruction and esophageal pressurization during the RDC (Very Low GRADE, Conditional Recommendation)^{9,10,27–30,46}
- Supportive evidence for a manometric diagnosis of EGJOO includes outflow obstruction during the solid test meal, especially

8 | DISORDERS OF PERISTALSIS (TABLE S3)

Consistent with prior iterations of Chicago Classification, absent contractility, DES, hypercontractile esophagus, and IEM are considered disorders of peristalsis. Fragmented peristalsis is now removed as a disorder and incorporated into the overall diagnosis of IEM (Very Low GRADE, Strong Recommendation).^{60,61} Disorders of peristalsis are considered when a disorder of EGJ outflow has been ruled out. There is potential for overlapping features of abnormal peristalsis to exist.

In these scenarios, a hierarchical approach to diagnostic classification should be used in the order of DES first, hypercontractile esophagus next, and last IEM, with a comment acknowledging presence of overlapping features.

It is again highlighted that diagnostic determination should be based on the primary position in which 10 wet swallows are performed, either supine or upright. Assessment of swallows in the secondary position and with provocation provides supportive evidence. Concordance of peristaltic classification with changing positions strengthens the confidence in the classification and eventual clinical diagnosis, whereas discordance should prompt reconsideration of the classification and eventual diagnosis with consideration of further supportive testing.

An important update in CCv4.0 is the recognition that DES and hypercontractile esophagus are manometric patterns that do not always equate to a clinical disease, similar to concepts underlying EGJOO. Per CCv4.0 these disorders of peristalsis are clinically relevant only in the appropriate clinical context and when they are supported by further testing, as detailed in this section.

9 | ABSENT CONTRACTILITY

Criteria for a diagnosis of absent contractility were not revised in CCv4.0.

- A conclusive diagnosis for absent contractility is defined as normal median IRP in the supine and upright position and 100% failed peristalsis (DCI <100 mmHg•s•cm) (Accepted Clinical Observation) (Figure 7).

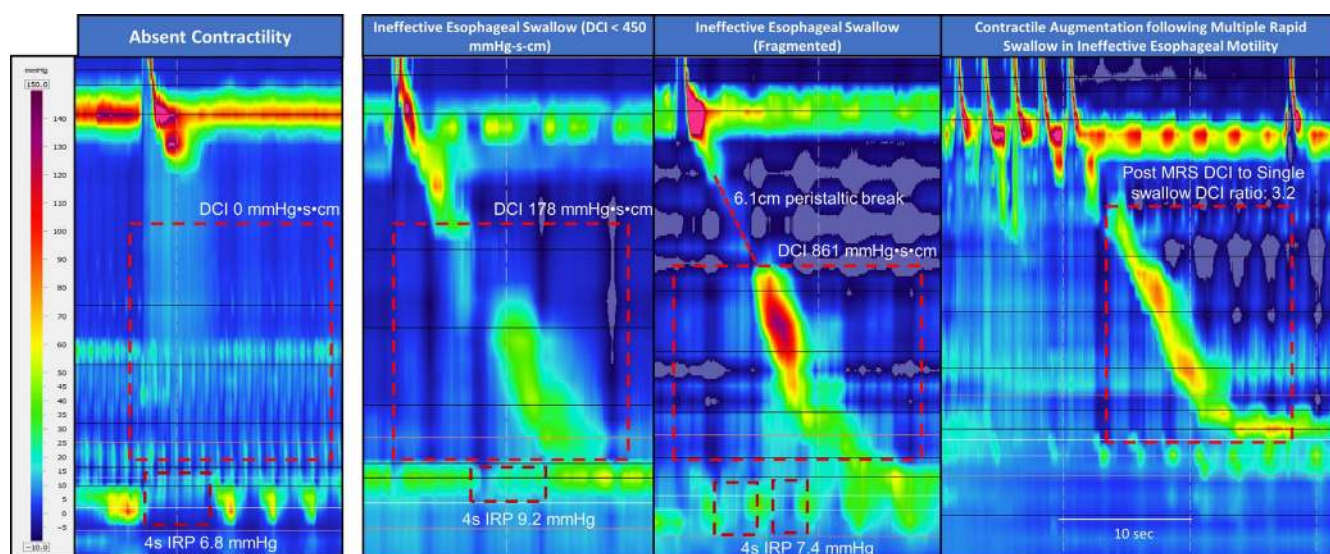
In the context of absent contractility, borderline median IRP values, particularly supine median IRP of 10 mmHg to 15 mmHg using the Medtronic system, should prompt consideration of type I achalasia. As discussed in the Achalasia section, supportive testing with TBE, preferably in conjunction with a barium tablet swallow, and FLIP should be considered in these cases if dysphagia is the dominant symptom (Figure 5).

10 | DISTAL ESOPHAGEAL SPASM

DES describes a specific abnormal esophageal motor pattern characterized by spastic or premature contractions in the distal esophagus (Figure 8), defined as contractions with a distal latency shorter than 4.5 seconds, in the setting of a DCI greater than 450 mmHg•s•cm. Manometric DES may have varying clinical significance, and thus, an update in CCv4.0 is the distinction between clinically relevant DES and clinically irrelevant manometric observations.

10.1 | Clinically Relevant Diagnosis of Distal Esophageal Spasm

- A clinically relevant diagnosis of DES requires both clinically relevant symptoms and a conclusive manometric diagnosis of DES (Low GRADE, Conditional Recommendation).¹⁹
- A conclusive manometric diagnosis of DES is defined as presence of at least 20% of premature contractions (Low GRADE, Strong Recommendation).¹⁹



Courtesy of University of California San Diego Center for Esophageal Diseases

FIGURE 7 Disorders of Peristalsis with Reduced Contractile Vigor or Integrity of Peristalsis. These include absent contractility or ineffective esophageal motility (either related to reduced contractile vigor or fragmented peristalsis). In this example of Absent Contractility, there is failed peristalsis with a normal IRP. In the first example of IEM, the DCI is reduced with a normal IRP. In the second example of IEM, the DCI is normal with a fragmentation in peristalsis of >5 cm in the setting of a normal IRP. During the multiple rapid swallows (MRS), there is absence of contractile activity and there is deglutitive inhibition of lower esophageal sphincter followed by DCI which is greater than the single swallow DCI, signifying an intact contractile augmentation

- Clinically relevant symptoms for DES include dysphagia and non-cardiac chest pain (Accepted Clinical Observation).

10.2 | Inconclusive Diagnosis of Distal Esophageal Spasm

- The presence of at least 20% contractions with a reduced distal latency (DL <4.5 seconds) but with a DCI < 450 mmHg•s•cm is inconclusive for a manometric diagnosis of DES (Low GRADE, Conditional Recommendation).¹⁹

The CCv4.0 Working Group recognizes that the CDP might be difficult to identify. In this setting, alternative methodologies need to be considered to diagnose DES (Strong Recommendation). This is further detailed in the section above on metrics and will be further addressed in the subsequent DES technical review.

11 | HYPERCONTRACTILE ESOPHAGUS

Hypercontractile esophagus describes a distinct manometric abnormality defined by excessive peristaltic vigor, which may include excessive LES after-contraction, not associated with a mechanical obstruction (Figure 8) (Very Low GRADE, Conditional Recommendation).^{62–64} Obstruction at the EGJ or the distal esophagus can induce a hypercontractile response, and it is crucial that obstruction is ruled out before a diagnosis of hypercontractile

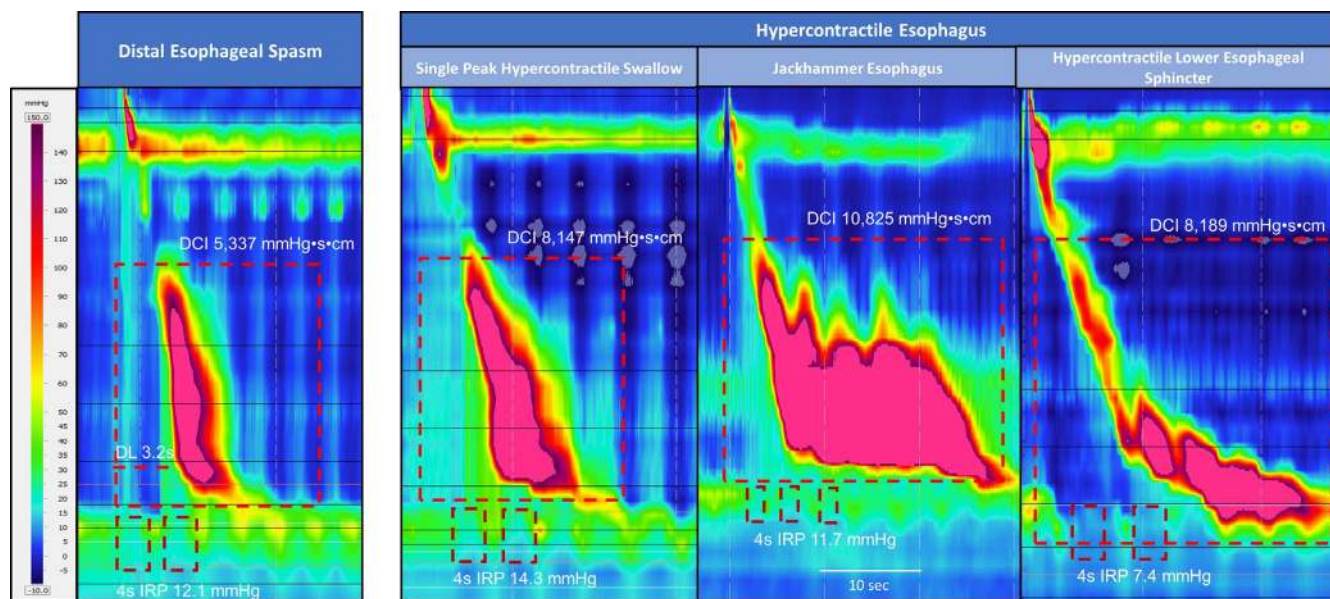
esophagus is considered. Heterogeneous motor patterns can meet manometric criteria for hypercontractile esophagus and have varying clinical significance. Therefore, similar to DES, an important update in CCv4.0 is to distinguish between clinically relevant hypercontractile esophagus versus clinically irrelevant manometric observations.

11.1 | Clinically Relevant Conclusive Diagnosis of Hypercontractile Esophagus

- A clinically relevant diagnosis of hypercontractile esophagus requires both clinically relevant symptoms and a conclusive manometric diagnosis of hypercontractile esophagus (Very Low GRADE, Strong Recommendation).^{56,62,64,65}
- A conclusive manometric diagnosis of hypercontractile esophagus is defined as 20% or more hypercontractile supine swallows (Very Low GRADE, Conditional Recommendation).^{62–64}
- Clinically relevant symptoms of hypercontractile esophagus include dysphagia and non-cardiac chest pain (Very Low GRADE, Strong Recommendation).^{56,62,64,65}

11.2 | Additional Considerations for Hypercontractile Esophagus

- A diagnosis of hypercontractile esophagus can only be made when criteria for achalasia or distal esophageal spasm are not met



Courtesy of University of California San Diego Center for Esophageal Diseases; Northwestern Esophageal Center; and Mayo Clinic Arizona Motility Lab

FIGURE 8 Disorders of Peristalsis with Esophageal Spasticity or Hypercontractility. These include distal esophageal spasm or hypercontractile esophagus. In this example of Distal Esophageal Spasm, the DCI is normal with a reduced distal latency and normal IRP. Hypercontractile esophagus includes sub-groups: Single peak hypercontractile swallow, hypercontractile with jackhammer esophagus, and hypercontractile with LES after-contraction. Integrated relaxation pressure (IRP); distal contractile integral (DCI); lower esophageal sphincter (LES)

and a mechanical obstruction has been carefully ruled out (Very Low GRADE, Strong Recommendation).⁶²⁻⁶⁴

Given the heterogeneity of hypercontractile patterns, the group advocated for a cautious approach in terms of treating contractile vigor as an endpoint and advocated for conservative medical therapy before endoscopic or surgical interventions are considered. The hypercontractile esophagus working group also proposed statements which did not meet criteria for agreement, further detailed in the subsequent technical review. There are three general sub-groups of hypercontractile esophagus: single-peaked hypercontractile swallows, jackhammer with repetitive prolonged contractions (especially in the post-peak phase), and hypercontractile swallows with a vigorous LES after-contraction. The jackhammer subgroup of hypercontractile esophagus is typically associated with higher DCI values and worse symptom severity.⁶⁶⁻⁶⁸ Overall the CCv4.0 working group recognizes the critical need for further research to better characterize physiologic phenotypes and clinical outcomes in hypercontractile esophagus.

12 | INEFFECTIVE ESOPHAGEAL MOTILITY

Prior iterations of Chicago Classification categorized IEM and fragmented peristalsis as minor motility disorders. In CCv4.0, fragmented peristalsis is included under the definition of IEM. Further, the diagnostic criteria for IEM have been made more stringent, commensurate with emerging data. As a result of these changes to IEM and fragmented peristalsis, CCv4.0 does not distinguish between major or minor disorders (Figure 7).

12.1 | Conclusive Diagnosis of Ineffective Esophageal Motility

- A conclusive diagnosis of IEM requires more than 70% ineffective swallows or at least 50% failed peristalsis (Very Low GRADE, Strong Recommendation).^{60,69-71}

As detailed in Diagnostic Thresholds and in Table 1, an ineffective swallow includes a weak contraction ($DCI \geq 100 \text{ mmHg} \bullet \text{s} \bullet \text{cm}$ and $<450 \text{ mmHg} \bullet \text{s} \bullet \text{cm}$), failed peristalsis ($DCI <100 \text{ mmHg} \bullet \text{s} \bullet \text{cm}$), or a fragmented swallow.

12.2 | Inconclusive Diagnosis of Ineffective Esophageal Motility

- The presence of 50 to 70% of ineffective swallows is inconclusive for a diagnosis of IEM. Supportive testing will strengthen confidence in IEM diagnosis in these cases (Very Low GRADE, Conditional Recommendation).^{61,72}

12.3 | Additional Considerations for Ineffective Esophageal Motility

The following are not required for the definition of IEM, but can provide supportive evidence:

- Supportive evidence for a diagnosis of IEM includes poor bolus transit on impedance or barium esophagram (Very Low GRADE, Conditional Recommendation).⁷³⁻⁷⁵
- Supportive evidence for a diagnosis of IEM includes lack of contraction reserve on MRS (Very Low GRADE, Conditional Recommendation).^{25,76}

13 | ESOPHAGOGASTRIC JUNCTION METRICS

An advantage of modern day high-resolution esophageal pressure topography over conventional line tracing is the ability to precisely assess the EGJ barrier function at rest including the relationship between the LES, crural diaphragm (CD), and respiratory inversion point (RIP), as well as the EGJ contractile integral (EGJ-CI), a measure of EGJ contractility in relation to respiration. Thus, a priority of CCv4.0 was to provide guidance to enable better characterization of the EGJ complex during a baseline recording in the primary position.

- The EGJ complex should be measured during quiet respiration in the baseline recording in a segment relatively devoid of swallowing and/or recording artifacts. This also refers to measurement of intragastric pressure, which should be measured below the CD over three complete respiratory cycles, preferably in the same segment as used to measure the EGJ-CI (Strong Recommendation).
- The RIP is the axial location at which the inspiratory change in pressure transitions from an inspiratory increase, characteristic of intra-abdominal recordings, to an inspiratory decrease, characteristic of intrathoracic recordings. (Strong Recommendation)
- The EGJ-CI should be referenced to intragastric pressure and expressed in units of $\text{mmHg} \bullet \text{cm}$. (Strong Recommendation). While not met with agreement, it was suggested that an EGJ-CI (or LES-contractile integral) value of $<25 \text{ mmHg} \bullet \text{cm}$ be considered a hypotensive EGJ.⁷⁷⁻⁸⁵
- LES-CD separation should be scored as the distance between the center of the CD and LES signal during inspiration, unless obscured in which case the LES position should be scored at expiration (Strong Recommendation).
- The EGJ complex should be defined based on LES-CD separation and location of the RIP. (Low GRADE, Conditional Recommendation)⁸⁶⁻⁹²

As for EGJ morphology, it was acknowledged that there were three subtypes: 1) normal with the CD superimposed on the LES and

the RIP localizing proximal to the complex; 2) LES-CD separation with the RIP localized proximal to the CD; and 3) LES-CD separation with the RIP localized proximal to the LES. However, there was no consensus regarding the subtype classification scheme (I, II, III vs A, C, B) and both versions were deemed acceptable (Figure S4).^{86,91} More research is clearly needed applying standardized, pre-specified methodology. The EGJ Metrics technical review details further recommendations regarding measurement of the EGJ complex in setting of hiatal hernia and temporal variability, as well as intragastric pressure and the role of end-expiratory LES pressure.

14 | CONCLUSION

CCv4.0 is the state-of-the-art classification scheme of esophageal motility disorders derived from a two-year international initiative involving 52 esophageal motility experts representing professional societies from five continents. The Chicago Classification has always been a dynamic process, subject to revision and refinement with every new iteration. True to this concept, CCv4.0 presents updates that improve precision of previously characterized motility diagnoses, and deletions of infrequently encountered diagnoses or clinically irrelevant criteria. A key update in CCv4.0 is the recognition that, similar to other medical investigations, HRM patterns alone may not equate to a conclusive diagnosis that explains patient symptoms and guides effective management (actionable pathology). Thus, CCv4.0 separates patterns that do provide a conclusive diagnosis (eg achalasia) from other patterns that are suggestive but inconclusive for a diagnosis, where additional clinical information and supportive testing may either confirm or refute the diagnosis in question. In particular, EGJOO, hypercontractile esophagus and DES are manometric patterns that require presence of dysphagia and/or non-cardiac chest pain to be considered clinically relevant. Further, a conclusive diagnosis of EGJOO requires corroboration with at least one supportive test (eg TBE, FLIP).

The methodologic rigor that has been applied to the CCv4.0 process consists of the use of formal consensus methods and formal level of evidence review when applicable. Further, CCv4.0 recommends a standardized HRM protocol to improve technical consistency and diagnostic accuracy, so that future iterations of the Chicago Classification can rely on further research from comprehensive, uniformly collected data. Finally, CCv4.0 represents motility perspectives from a diverse working group in terms of geography, age, gender, practice type, years in practice, and research contributions to the field.

CCv4.0 also highlights areas ripe for future investigation and clarity, as further summarized in the specific technical reviews. Future iterations of Chicago Classification will need to delineate the role of impedance topography for intrabolar pressure and bolus flow. Additional outcomes studies are needed to better understand the reliability of solid test swallows and meals in identifying clinically relevant abnormal EGJ and peristaltic function. With refinement of the diagnostic criteria for EGJOO in CCv4.0,

it will be important to understand the natural history and treatment outcome of EGJOO, with and without supportive testing. Understanding mechanisms of spastic esophageal disorders remains of great interest, as well as exploring overlaps with opioid induced esophageal dysfunction.⁴⁵ Understanding the spectrum of hypercontractile disorders will require further work to explore whether jackhammer esophagus represents a unique subtype with clinical significance. Future iterations of Chicago Classification may propose manometric criteria for therapy selection, such as role of per-oral endoscopic myotomy for spastic disorders, and risk stratification and tailoring of fundoplication to prevent post-fundoplication dysphagia.

CONFLICTS OF INTEREST

Rena Yadlapati: Institutional Consulting Agreement: Medtronic, Ironwood Pharmaceuticals, Diversatek; Research support: Ironwood Pharmaceuticals; Advisory Board: Phatom Pharmaceuticals.

Peter J. Kahrilas: Consultant: Ironwood Pharmaceuticals; Advisory Board: Ironwood Pharmaceuticals; Research Grant: Ironwood Pharmaceuticals; Royalties: Medtronic; Licensing Agreement: Medtronic.

Mark R. Fox: Speaker: Medtronic, Diversatek, Laborie; Research Grant: Medtronic, Diversatek, Laborie.

Albert J. Bredenoord: Consulting: Medtronic, Laborie, AstraZeneca, Gossamer, Arena, EsoCap, Calypso, Regeneron, Dr Falk; Speaker: Medtronic, Laborie, Dr Falk; Advisory Board: Medtronic, Laborie, AstraZeneca, Gossamer, Arena, EsoCap, Calypso, Regeneron, Dr Falk; Research Grants: Medtronic, Laborie, Nutricia, SST; Stock Options: SST.

C. Prakash Gyawali: Consulting: Medtronic, Diversatek, Ironwood Pharmaceuticals, Isothrive, Quintiles.

Sabine Roman: Consulting: Medtronic; research Grants: Medtronic, Diversatek Healthcare.

Nathalie Rommel: Patent on Automated Impedance Manometry technology.

Edoardo Savarino: Consulting: Unifarco; Speaker: Medtronic, Reckitt Benckiser, Takeda, Abbvie, Novartis, Sandoz, Sofar, Malesci, Janssen, Grifols, Aurora Pharma, Innovamedica, Johnson&Johnson, SILA, Alfasigma, Shire, EG Stada Group; Advisory Board: Merck & Co, Bristol-Myers Squibb, Amgen, Fresenius Kabi; Research Grant: Sofar.

Michael F. Vaezi: Consulting: Diversatek; Phathom; Ironwood; Speaker: Diversatek; Advisory Board: Diversatek; Phathom; Ironwood; Research Grants: Diversatek; Phathom; Ironwood; Patent: Mucosal Integrity Testing.

Frank Zerbib: Consulting: Reckitt Benckiser.

Junichi Akiyama: Speaker: StarMedical, Takeda, AstraZeneca, Otsuka, Daiichi Sankyo.

Serhat Bor: Speaker: Laborie.

Dustin A. Carlson: Consulting: Medtronic, Speaker: Medtronic.

Daniel Cisternas: Speaker: Medtronic.

Enrique Coss-Adame: Consulting: Asofarma de México, Ferrer de México, Siegfried Rhein, Takeda de México, Medtronic de Mexico;

Speaker: Asofarma de México, Ferrer de México, Siegfried Rhein, Takeda de México, Medtronic de Mexico, Grunenthal de Mexico.; Advisory Board: Asofarma de México, Ferrer de México, Siegfried Rhein, Takeda de México, Medtronic de Mexico.

Ronnie Fass: Consulting: Ironwood, Takeda, Daewoong, Medtronic, Phathom; Speaker: Astrazeneca, Takeda, Diversatek, Eisai; Advisory Board: Phathom; Research Grants: Ironwood, Salix; Royalties: UpToDate.

Philip Katz: Consulting: Medtronic; Research Grants: Diversatek.

David A. Katzka: Consulting: Shire.

Abraham Khan: Consulting: Medtronic; Speaker: Medtronic.

Daniel Pohl: Consulting: Medtronic, Sanofi; Speaker: Permamed, Alfa Sigma, Schwabe Pharma, Takeda, Advisory Board: Sanofi, Schwabe Pharma.

Jordi Serra: Consulting: Reckit Benckiser; Speaker: Norgine, Allergan, Cassen Recordati, AB biotics; Advisory Board: Almirall; Research Grants: Bayer, Salvat Biotech, Zespri.

Rami Sweis: Speaker: Medtronic, Covidian, Given, Falk Pharma, Ethicon; Advisory Board: Falk Pharma, Ethicon.

Jan Tack: Research Grant: Sofar Pharmaceuticals.

Radu Tutuian: Consulting: Laborie MMS; Speaker: Laborie MMS; Royalties: UpToDate.

Marcelo F. Vela: Consulting: Medtronic.

Reuben Wong: Consulting: MMS Laborie, Speaker: MMS Laborie.

John E. Pandolfino: Consultant: Medtronic, Ironwood Pharmaceuticals, Diversatek; Research support: Ironwood Pharmaceuticals, Takeda; Advisory Board: Medtronic, Diversatek; Stock Options: Croson Inc.

None to report: Arash Babaei, Ravinder K. Mittal, Daniel Sifrim, Andre Smout, Shobna Bhatia, Joan Chen, Charles Cock, Nicola de Bortoli, Claudia Defilippi, Uday C. Ghoshal, Sutep Gonlachanvit, Albis Hani, Geoffrey S. Hebbard, Kee Wook Jung, Geoffrey P. Kohn, Adriana Lazarescu, Johannes Lenglinger, Sumeet K. Mittal, Taher Omari, Moo In Park, Roberto Penagini, Joel E. Richter, Roger P. Tatum, Justin Wu, Yinglian Xiao.

Research Funding Support: P01 DK092217 (John E. Pandolfino) from the US Public Health Service.

AUTHOR CONTRIBUTIONS

Study design/conception: RY, JEP; Contribution to data collection: All authors; Analysis of data: RY, PK, RT, DK, RP, NDB, JR; Interpretation of data: All authors; Literature review: All authors; Drafting of manuscript: RY, JEP; Critical revision of manuscript: All authors; Final approval of manuscript to be published: All authors.

ORCID

Rena Yadlapati  <https://orcid.org/0000-0002-7872-2033>

Mark R. Fox  <https://orcid.org/0000-0003-4394-5584>

C. Prakash Gyawali  <https://orcid.org/0000-0002-3388-0660>

Sabine Roman  <https://orcid.org/0000-0002-7798-7638>

Arash Babaei  <https://orcid.org/0000-0001-6790-2402>

Ravinder K. Mittal  <https://orcid.org/0000-0001-5228-9617>

Daniel Sifrim  <https://orcid.org/0000-0002-4894-0523>

André Smout  <https://orcid.org/0000-0001-7796-6282>

Frank Zerbib  <https://orcid.org/0000-0002-6802-2121>

Serhat Bor  <https://orcid.org/0000-0001-5766-9598>

Dustin A. Carlson  <https://orcid.org/0000-0002-1702-7758>

Daniel Cisternas  <https://orcid.org/0000-0003-0909-5192>

Charles Cock  <https://orcid.org/0000-0003-3578-1137>

Nicola de Bortoli  <https://orcid.org/0000-0003-1995-1060>

Ronnie Fass  <https://orcid.org/0000-0002-4807-3052>

Uday C. Ghoshal  <https://orcid.org/0000-0003-0221-8495>

Kee Wook Jung  <https://orcid.org/0000-0002-3771-3691>

Abraham Khan  <https://orcid.org/0000-0002-8683-2320>

Taher Omari  <https://orcid.org/0000-0001-5108-7378>

Moo In Park  <https://orcid.org/0000-0003-2071-6957>

Roberto Penagini  <https://orcid.org/0000-0001-6918-9479>

Jordi Serra  <https://orcid.org/0000-0003-2120-6270>

REFERENCES

- Kahrilas PJ, Bredenoord AJ, Fox M, et al. The Chicago classification of esophageal motility disorders, v3.0. *Neurogastroenterol Motil.* 2015;27:160–174.
- pandolfino JE, fox MR, bredenoord AJ, et al. High-resolution manometry in clinical practice: utilizing pressure topography to classify oesophageal motility abnormalities. *Neurogastroenterol Motil.* 2009;21:796–806.
- Bredenoord AJ, Fox M, Kahrilas PJ, et al. Chicago classification criteria of esophageal motility disorders defined in high resolution esophageal pressure topography. *Neurogastroenterol Motil.* 2012;24(Suppl 1):57–65.
- Yadlapati R, Gawron AJ, Keswani RN, et al. Identification of quality measures for performance of and interpretation of data from Esophageal manometry. *Clin Gastroenterol Hepatol.* 2016;14:526–534.
- Yadlapati R, Vaezi MF, Vela MF, et al. Management options for patients with GERD and persistent symptoms on proton pump inhibitors: recommendations from an expert panel. *Am J Gastroenterol.* 2018;113:980–986.
- Balshem H, Helfand M, Schünemann HJ, et al. GRADE guidelines: 3. Rating the quality of evidence. *J Clin Epidemiol.* 2011;64:401–406.
- Shaker A, Stoikes N, Drapekin J, et al. Multiple rapid swallow responses during esophageal high-resolution manometry reflect esophageal body peristaltic reserve. *Am J Gastroenterol.* 2013;108:1706–1712.
- Mauro A, Savarino E, De Bortoli N, et al. Optimal number of multiple rapid swallows needed during high-resolution esophageal manometry for accurate prediction of contraction reserve. *Neurogastroenterol Motil.* 2018;30:e13253.
- Woodland P, Gabieta-Sonmez S, Arguero J, et al. 200 mL Rapid drink challenge during high-resolution manometry best predicts objective Esophagogastric junction obstruction and correlates with symptom severity. *J Neurogastroenterol Motil.* 2018;24:410–414.
- Ang D, Misselwitz B, Hollenstein M, et al. Diagnostic yield of high-resolution manometry with a solid test meal for clinically relevant, symptomatic oesophageal motility disorders: serial diagnostic study. *Lancet Gastroenterol Hepatol.* 2017;2:654–661.
- Babaei A, Shad S, Szabo A, et al. Pharmacologic interrogation of patients with esophagogastric junction outflow obstruction using amyl nitrite. *Neurogastroenterol Motil.* 2019;31:e13668.
- Triggs JR, Carlson DA, Beveridge C, et al. Functional luminal imaging probe panometry identifies achalasia-type esophagogastric junction outflow obstruction. *Clin Gastroenterol Hepatol.* 2020;18:2209–2217.

13. Clayton SB, Patel R, Richter JE. Functional and anatomic esophagogastric junction outflow obstruction: manometry, timed barium esophagram findings, and treatment outcomes. *Clin Gastroenterol Hepatol*. 2016;14:907–911.
14. Herregods TVK, Roman S, Kahrilas PJ, et al. Normative values in esophageal high-resolution manometry. *Neurogastroenterol Motil*. 2015;27:175–187.
15. Kuribayashi S, Iwakiri K, Kawada A, et al. Variant parameter values-as defined by the Chicago Criteria-produced by ManoScan and a new system with Unisensor catheter. *Neurogastroenterol Motil*. 2015;27:188–194.
16. Sifrim D, Roman S, Savarino E, et al. Normal values and regional differences in oesophageal impedance-pH metrics: a consensus analysis of impedance-pH studies from around the world. *Gut*. 2020. <https://doi.org/10.1136/gutjnl-2020-322627>. [Epub ahead of print].
17. Rengarajan A, Rogers BD, Wong Z, et al. High-resolution manometry thresholds and motor patterns among asymptomatic individuals. *Clin Gastroenterol Hepatol*. 2020. <https://doi.org/10.1016/j.cgh.2020.10.052>. [Epub ahead of print].
18. Triggs JR, Carlson DA, Beveridge C, et al. Upright integrated relaxation pressure facilitates characterization of esophagogastric junction outflow obstruction. *Clin Gastroenterol Hepatol*. 2019;17:2218–2226.
19. Pandolfino JE, Roman S, Carlson D, et al. Distal esophageal spasm in high-resolution esophageal pressure topography: defining clinical phenotypes. *Gastroenterology*. 2011;141:469–475.
20. Roman S, Kahrilas PJ, Kia L, et al. Effects of large hiatal hernias on esophageal peristalsis. *Arch Surg*. 2012;147:352–357.
21. Pandolfino JE, Kwieciek MA, Nealis T, et al. Achalasia: a new clinically relevant classification by high-resolution manometry. *Gastroenterology*. 2008;135:1526–1533.
22. Biasutto D, Mion F, Garros A, et al. Rapid drink challenge test during esophageal high resolution manometry in patients with esophago-gastric junction outflow obstruction. *Neurogastroenterol Motil*. 2018;30:e13293.
23. Song BG, Min YW, Lee H, et al. Clinicomanometric factors associated with clinically relevant esophagogastric junction outflow obstruction from the Sandhill high-resolution manometry system. *Neurogastroenterol Motil*. 2018;30(3):e13221.
24. Elvevi A, Mauro A, Pugliese D, et al. Usefulness of low- and high-volume multiple rapid swallowing during high-resolution manometry. *Dig Liver Dis*. 2015;47:103–107.
25. Martinucci I, Savarino EV, Pandolfino JE, et al. Vigor of peristalsis during multiple rapid swallows is inversely correlated with acid exposure time in patients with NERD. *Neurogastroenterol Motil*. 2016;28:243–250.
26. Krause AJ, Su H, Triggs JR, et al. Multiple rapid swallows and rapid drink challenge in patients with esophagogastric junction outflow obstruction on high-resolution manometry. *Neurogastroenterol Motil*. 2020:e14000. <https://doi.org/10.1111/nmo.14000>. [Epub ahead of print].
27. Ang D, Hollenstein M, Misselwitz B, et al. Rapid Drink Challenge in high-resolution manometry: an adjunctive test for detection of esophageal motility disorders. *Neurogastroenterol Motil*. 2017;29(1):e12902.
28. Marin I, Serra J. Patterns of esophageal pressure responses to a rapid drink challenge test in patients with esophageal motility disorders. *Neurogastroenterol Motil*. 2016;28:543–553.
29. Sanagapalli S, McGuire J, Leong RW, et al. The clinical relevance of manometric esophagogastric junction outflow obstruction can be determined using rapid drink challenge and solid swallows. *Am J Gastroenterol*. 2020. <https://doi.org/10.14309/ajg.0000000000000988>. [Epub ahead of print].
30. Hollenstein M, Thwaites P, Bütikofer S, et al. Pharyngeal swallowing and oesophageal motility during a solid meal test: a prospective study in healthy volunteers and patients with major motility disorders. *Lancet Gastroenterol Hepatol*. 2017;2:644–653.
31. Babaei A, Shad S, Massey BT. Diagnostic differences in the pharmacologic response to cholecystokinin and amyl nitrite in patients with absent contractility vs type I Achalasia. *Neurogastroenterol Motil*. 2020;32:e13857.
32. Babaei A, Shad S, Massey BT. Motility patterns following esophageal pharmacologic provocation with amyl nitrite or cholecystokinin during high-resolution manometry distinguish idiopathic vs opioid-induced type 3 achalasia. *Clin Gastroenterol Hepatol*. 2020;18(4):813–821.
33. Andolfi C, Fisichella PM. Meta-analysis of clinical outcome after treatment for achalasia based on manometric subtypes. *Br J Surg*. 2019;106:332–341.
34. Lee JY, Kim N, Kim SE, et al. Clinical characteristics and treatment outcomes of 3 subtypes of achalasia according to the Chicago classification in a tertiary institute in Korea. *J Neurogastroenterol Motil*. 2013;19:485–494.
35. Min M, Peng LH, Yang YS, et al. Characteristics of achalasia subtypes in untreated Chinese patients: a high-resolution manometry study. *J Dig Dis*. 2012;13:504–509.
36. Rohof WO, Salvador R, Annese V, et al. Outcomes of treatment for achalasia depend on manometric subtype. *Gastroenterology*. 2013;144(4):718–725.
37. Blonski W, Kumar A, Feldman J, et al. Timed barium swallow: diagnostic role and predictive value in untreated achalasia, esophagogastric junction outflow obstruction, and non-achalasia dysphagia. *Am J Gastroenterol*. 2018;113:196–203.
38. Clayton SB, Shin CM, Ewing A, et al. Pneumatic dilation improves esophageal emptying and symptoms in patients with idiopathic esophago-gastric junction outflow obstruction. *Neurogastroenterol Motil*. 2019;31:e13522.
39. Okeke FC, Raja S, Lynch KL, et al. What is the clinical significance of esophagogastric junction outflow obstruction? evaluation of 60 patients at a tertiary referral center. *Neurogastroenterol Motil*. 2017;29(6):e13061.
40. Carlson DA, Kahrilas PJ, Lin Z, et al. Evaluation of esophageal motility utilizing the functional lumen imaging probe. *Am J Gastroenterol*. 2016;111:1726–1735.
41. Kim E, Yoo IK, Yon DK, et al. Characteristics of a subset of achalasia with normal integrated relaxation pressure. *J Neurogastroenterol Motil*. 2020;26:274–280.
42. Ponds FA, Bredenoord AJ, Kessing BF, et al. Esophagogastric junction distensibility identifies achalasia subgroup with manometrically normal esophagogastric junction relaxation. *Neurogastroenterol Motil*. 2017;29(1):e12908.
43. Sanagapalli S, Roman S, Hastier A, et al. Achalasia diagnosed despite normal integrated relaxation pressure responds favorably to therapy. *Neurogastroenterol Motil*. 2019;31:e13586.
44. Babaei A, Szabo A, Shad S, et al. Chronic daily opioid exposure is associated with dysphagia, esophageal outflow obstruction, and disordered peristalsis. *Neurogastroenterol Motil*. 2019;31:e13601.
45. Ratuapli SK, Crowell MD, DiBaise JK, et al. Opioid-induced esophageal dysfunction (OIED) in patients on chronic opioids. *Am J Gastroenterol*. 2015;110:979–984.
46. Misselwitz B, Hollenstein M, Bütikofer S, et al. Prospective serial diagnostic study: the effects of position and provocative tests on the diagnosis of oesophageal motility disorders by high-resolution manometry. *Aliment Pharmacol Ther*. 2020;51:706–718.
47. Beveridge CA, Falk GW, Ahuja NK, et al. Low yield of cross-sectional imaging in patients with esophagogastric junction outflow obstruction. *Clin Gastroenterol Hepatol*. 2020;18:1643–1644.
48. DeLay K, Austin GL, Menard-Katcher P. Anatomic abnormalities are common potential explanations of manometric esophagogastric junction outflow obstruction. *Neurogastroenterol Motil*. 2016;28:1166–1171.

49. Liu A, Woo M, Nasser Y, et al. Esophagogastric junction outflow obstruction on manometry: Outcomes and lack of benefit from CT and EUS. *Neurogastroenterol Motil.* 2019;31:e13712.
50. Pérez-Fernández M-T, Santander C, Marinero A, et al. Characterization and follow-up of esophagogastric junction outflow obstruction detected by high resolution manometry. *Neurogastroenterol Motil.* 2016;28:116–126.
51. van Hoeij FB, Smout AJ, Bredenoord AJ. Characterization of idiopathic esophagogastric junction outflow obstruction. *Neurogastroenterol Motil.* 2015;27:1310–1316.
52. Wang YT, Tai LF, Yazaki E, et al. Investigation of dysphagia after antireflux surgery by high-resolution manometry: impact of multiple water swallows and a solid test meal on diagnosis, management, and clinical outcome. *Clin Gastroenterol Hepatol.* 2015;13:1575–1583.
53. Hoscheit M, Gabbard S. Elevated intrabolar pressure predicts abnormal timed barium esophagram in esophagogastric junction outflow obstruction. *J Neurogastroenterol Motil.* 2019;25:521–524.
54. Quader F, Reddy C, Patel A, et al. Elevated intrabolar pressure identifies obstructive processes when integrated relaxation pressure is normal on esophageal high-resolution manometry. *Am J Physiol Gastrointest Liver Physiol.* 2017;313:G73–G79.
55. Singendonk MJ, Lin Z, Scheerens C, et al. High-resolution impedance manometry parameters in the evaluation of esophageal function of non-obstructive dysphagia patients. *Neurogastroenterol Motil.* 2019;31:e13505.
56. Schupack D, Katzka DA, Geno DM, et al. The clinical significance of esophagogastric junction outflow obstruction and hypercontractile esophagus in high resolution esophageal manometry. *Neurogastroenterol Motil.* 2017;29:1–9.
57. Song BG, Min YW, Lee H, et al. Combined multichannel intraluminal impedance and high-resolution manometry improves detection of clinically relevant esophagogastric junction outflow obstruction. *J Neurogastroenterol Motil.* 2019;25:75–81.
58. Babaei A, Lin EC, Szabo A, et al. Determinants of pressure drift in Manoscan() esophageal high-resolution manometry system. *Neurogastroenterol Motil.* 2015;27:277–284.
59. Babaei A, Szabo A, Yorio SD, et al. Pressure exposure and catheter impingement affect the recorded pressure in the Manoscan 360 system. *Neurogastroenterol Motil.* 2018;30(8):e13329.
60. Zerbib F, Marin I, Cisternas D, et al. Ineffective esophageal motility and bolus clearance. A study with combined high-resolution manometry and impedance in asymptomatic controls and patients. *Neurogastroenterol Motil.* 2020;32(9):e13876.
61. Rogers BD, Rengarajan A, Mauro A, et al. Fragmented and failed swallows on esophageal high-resolution manometry associate with abnormal reflux burden better than weak swallows. *Neurogastroenterol Motil.* 2020;32:e13736.
62. Herregods TVK, Smout AJPM, Ooi JLS, et al. Jackhammer esophagus: Observations on a European cohort. *Neurogastroenterol Motil.* 2017;29(4):e12975.
63. Kahn A, Al-Qaisi MT, Obeid RA, et al. Clinical features and long-term outcomes of lower esophageal sphincter-dependent and lower esophageal sphincter-independent jackhammer esophagus. *Neurogastroenterol Motil.* 2019;31:e13507.
64. Roman S, Pandolfino JE, Chen J, et al. Phenotypes and clinical context of hypercontractility in high-resolution esophageal pressure topography (EPT). *Am J Gastroenterol.* 2012;107:37–45.
65. Al-Qaisi MT, Siddiki HA, Crowell MD, et al. The clinical significance of hypercontractile peristalsis: comparison of high-resolution manometric features, demographics, symptom presentation, and response to therapy in patients with Jackhammer esophagus versus Nutcracker esophagus. *Dis Esophagus.* 2017;30:1–7.
66. Philonenko S, Roman S, Zerbib F, et al. Jackhammer esophagus: Clinical presentation, manometric diagnosis, and therapeutic results—Results from a multicenter French cohort. *Neurogastroenterol Motil.* 2020;32(11):e13918.
67. Xiao Y, Carlson DA, Lin Z, et al. Jackhammer esophagus: Assessing the balance between prepeak and postpeak contractile integral. *Neurogastroenterol Motil.* 2018;30:e13262.
68. Xiao Y, Carlson DA, Lin Z, et al. Chaotic peak propagation in patients with Jackhammer esophagus. *Neurogastroenterol Motil.* 2020;32:e13725.
69. Bulsiewicz WJ, Kahrilas PJ, Kwiatek MA, et al. Esophageal pressure topography criteria indicative of incomplete bolus clearance: a study using high-resolution impedance manometry. *Am J Gastroenterol.* 2009;104:2721–2728.
70. Jain A, Baker JR, Chen JW. In ineffective esophageal motility, failed swallows are more functionally relevant than weak swallows. *Neurogastroenterol Motil.* 2018;30:e13297.
71. Roman S, Lin Z, Kwiatek MA, et al. Weak peristalsis in esophageal pressure topography: classification and association with Dysphagia. *Am J Gastroenterol.* 2011;106:349–356.
72. Rengarajan A, Bolkhir A, Gor P, et al. Esophagogastric junction and esophageal body contraction metrics on high-resolution manometry predict esophageal acid burden. *Neurogastroenterol Motil.* 2018;30:e13267.
73. Chugh P, Collazo T, Dworkin B, et al. Ineffective esophageal motility is associated with impaired bolus clearance but does not correlate with severity of dysphagia. *Dig Dis Sci.* 2019;64:811–814.
74. Lin Z, Nicodème F, Lin C-Y, et al. Parameters for quantifying bolus retention with high-resolution impedance manometry. *Neurogastroenterol Motil.* 2014;26:929–936.
75. Wu J-F, Tsai I-J, Tong T-W, et al. Pressure-impedance analysis: Assist the diagnosis and classification of ineffective esophageal motility disorder. *J Gastroenterol Hepatol.* 2020;35:1317–1324.
76. Quader F, Rogers B, Sievers T, et al. Contraction reserve with ineffective esophageal motility on esophageal high-resolution manometry is associated with lower acid exposure times compared with absent contraction reserve. *Am J Gastroenterol.* 2020;115(12):1981–1988. <https://doi.org/10.14309/ajg.0000000000000811>
77. Gor P, Li Y, Munigala S, et al. Interrogation of esophagogastric junction barrier function using the esophagogastric junction contractile integral: an observational cohort study. *Dis Esophagus.* 2016;29:820–828.
78. Ham H, Cho YK, Lee HH, et al. Esophagogastric junction contractile integral and morphology: Two high-resolution manometry metrics of the anti-reflux barrier. *J Gastroenterol Hepatol.* 2017;32:1443–1449.
79. Jasper D, Freitas-Queiroz N, Hollenstein M, et al. Prolonged measurement improves the assessment of the barrier function of the esophago-gastric junction by high-resolution manometry. *Neurogastroenterol Motil.* 2017;29(2). <https://doi.org/10.1111/nmo.12925>
80. Nicodème F, Pipa-Muniz M, Khanna K, et al. Quantifying esophagogastric junction contractility with a novel HRM topographic metric, the EGJ-Contractile Integral: normative values and preliminary evaluation in PPI non-responders. *Neurogastroenterol Motil.* 2014;26:353–360.
81. Rengarajan A, Gyawali CP. High-resolution manometry can characterize esophagogastric junction morphology and predict esophageal reflux burden. *J Clin Gastroenterol.* 2020;54:22–27.
82. Tolone S, De Bortoli N, Marabotto E, et al. Esophagogastric junction contractility for clinical assessment in patients with GERD: a real added value? *Neurogastroenterol Motil.* 2015;27:1423–1431.
83. Wang D, Patel A, Mello M, et al. Esophagogastric junction contractile integral (EGJ-CI) quantifies changes in EGJ barrier function with surgical intervention. *Neurogastroenterol Motil.* 2016;28:639–646.
84. Xie C, Wang J, Li Y, et al. Esophagogastric junction contractility integral reflect the anti-reflux barrier dysfunction in patients

- with gastroesophageal reflux disease. *J Neurogastroenterol Motil.* 2017;23:27–33.
85. Rogers BD, Rengarajan A, Abrahao L, et al. Esophagogastric junction morphology and contractile integral on high-resolution manometry in asymptomatic healthy volunteers: An international multicenter study. *Neurogastroenterol Motil.* 2020:e14009. <https://doi.org/10.1111/nmo.14009>. [Epub ahead of print].
86. Akimoto S, Singhal S, Masuda T, et al. Classification for esophagogastric junction (EGJ) complex based on physiology. *Dis Esophagus.* 2017;30:1–6.
87. Akimoto S, Singhal S, Masuda T, et al. Esophagogastric junction morphology and distal esophageal acid exposure. *Dig Dis Sci.* 2016;61:3537–3544.
88. Mittal RK, Zifan A, Kumar D, et al. Functional morphology of the lower esophageal sphincter and crural diaphragm determined by three-dimensional high-resolution esophago-gastric junction pressure profile and CT imaging. *Am J Physiol Gastrointest Liver Physiol.* 2017;313:G212–G219.
89. Nicodème F, Lin Z, Pandolfino JE, et al. Esophagogastric Junction pressure morphology: comparison between a station pull-through and real-time 3D-HRM representation. *Neurogastroenterol Motil.* 2013;25:e591–e598.
90. Niebisch S, Wilshire CL, Peters JH. Systematic analysis of esophageal pressure topography in high-resolution manometry of 68 normal volunteers. *Dis Esophagus.* 2013;26:651–660.
91. Pandolfino JE, Kim H, Ghosh SK, et al. High-resolution manometry of the EGJ: an analysis of crural diaphragm function in GERD. *Am J Gastroenterol.* 2007;102:1056–1063.
92. Tolone S, de Cassan C, de Bortoli N, et al. Esophagogastric junction morphology is associated with a positive impedance-pH monitoring in patients with GERD. *Neurogastroenterol Motil.* 2015;27:1175–1182.

SUPPORTING INFORMATION

Additional supporting information may be found online in the Supporting Information section.

How to cite this article: Yadlapati R, Kahrilas PJ, Fox MR, et al. Esophageal motility disorders on high-resolution manometry: Chicago classification version 4.0[©]. *Neurogastroenterology & Motility.* 2020;33:e14058. <https://doi.org/10.1111/nmo.14058>