

We are IntechOpen, the world's leading publisher of Open Access books Built by scientists, for scientists

5,900

Open access books available

145,000

International authors and editors

180M

Downloads

Our authors are among the

154

Countries delivered to

TOP 1%

most cited scientists

12.2%

Contributors from top 500 universities



WEB OF SCIENCE™

Selection of our books indexed in the Book Citation Index
in Web of Science™ Core Collection (BKCI)

Interested in publishing with us?
Contact book.department@intechopen.com

Numbers displayed above are based on latest data collected.
For more information visit www.intechopen.com



Etiology and Treatment Approach for Visual Hallucinations in PD Dementia

*Yuki Asahara, Taiji Mukai, Machiko Suda
and Masahiko Suzuki*

Abstract

Visual hallucinations are a common symptom of Parkinson's disease dementia. These can cause delusions and violent behaviors that can be significant burdens on patients and caregivers. The cause of visual hallucinations is considered to be the dysregulation of the default mode network due to the presence of Lewy bodies in the cortex and the degeneration of dopaminergic and cholinergic neurons. Dopaminergic agents, especially non-ergoline dopamine agonists, can exacerbate visual hallucinations. Reducing the dosage can ameliorate symptoms in many cases; however, this frequently worsens parkinsonism. In contrast, the administration of cholinesterase inhibitors is effective and rarely worsens motor symptoms. In advanced cases, antipsychotic drugs are required; clinical studies have shown that some drugs are beneficial while the adverse events are acceptable. An optimal treatment protocol should be selected depending on the patient's condition.

Keywords: Parkinson's disease, dementia, hallucinations, dopaminergic agents, cholinesterase inhibitors, antipsychotic agents

1. Introduction

Advanced Parkinson's disease (PD) patients often have dementia due to widespread Lewy bodies in the cerebrum [1]. Lewy bodies are inclusion bodies consisting of a protein, named alpha-synuclein [2]. In Parkinson's disease dementia (PDD), visual hallucinations (VH), defined as hallucinations accompanied by delusions, which are abnormal beliefs that are endorsed by patients as real, that persist in spite of evidence to the contrary, and that are not part of a patient's culture or subculture, are a common symptom as in dementia with Lewy bodies (DLB) [3]. VH can cause delusions and violent behavior that can be a considerable burden on patients and their caregivers [4–6]; therefore, optimal treatments are indispensable.

In the early stages of PD, VH are usually a simple presentation like blurred moving images [3]. Complex VH, which are consisting of well-organized unreal visual perception, appear as the disease progresses. In a study of early-stage patients within 7 years from onset, VH were found in 17% during 4-year follow-up [7]. On the other hand, the lifetime incidence was reported as 50% [8].

The main form of treatment is the adjustment of medication dosage. In many cases, a reduction of the dose of dopaminergic agents ameliorates symptoms [2]. In contrast, the administration of antidementia medications, especially cholinesterase inhibitors, is an effective alternative that can relieve VH without worsening motor symptoms [2]. However, antipsychotic agents are required for some patients [2]. In this chapter, we review previous studies on drug management to propose a clinical approach for treating VH in PDD patients.

2. Etiology of visual hallucinations

Visual identification of objects processes from the occipital lobes to the temporal lobes [9]. The object is recognized when this visual information is linked to memories. It is considered that this linking occurs partly in a network called the default mode network (DMN) [3, 10]. The DMN is activated when a person does not focus on any task in particular [3, 11]. The DMN comprises multiple parts of the brain such as the medial prefrontal cortex, precuneus, posterior cingulate cortex, inferior parietal cortex, and lateral temporal cortex (**Figure 1**) [12]. In contrast, the network activated by attention-demanding tasks is called the task-positive network (TPN) [3, 11], which includes the lateral frontal cortex, superior parietal cortex, insula cortex, and frontal operculum cortex [12]. The TPN modulates the DMN, and it is hypothesized that overactivity of the DMN causes VH (**Figure 2**) [3].

Findings from a pathological study are consistent with this hypothesis. One study compared Lewy body deposits in patients with and without VH [13]. Patients with VH had more accumulation of Lewy bodies at many sites, and the most statistically significant difference was seen in the frontal cortex. Most of this area is part of the TPN, and the damage incurred by Lewy bodies can lead to the dysregulation of the DMN.

Furthermore, dopaminergic and cholinergic agents can affect VH [14]. Dopaminergic neurons and cholinergic neurons are associated with visual recognition. The prefrontal cortex and striatum receive dopaminergic stimulation and control attention and working memory [15–19]. The nucleus basalis of Meynert projects acetylcholine across the entire cerebral cortex [20]. These are related to the TPN; therefore, dopaminergic or cholinergic dysfunction can cause dysregulation of the DMN.

Although the pathophysiology of VH is not fully understood, it is reasonable to adjust dopaminergic agents and administer antidementia drugs to treat VH of PDD patients.

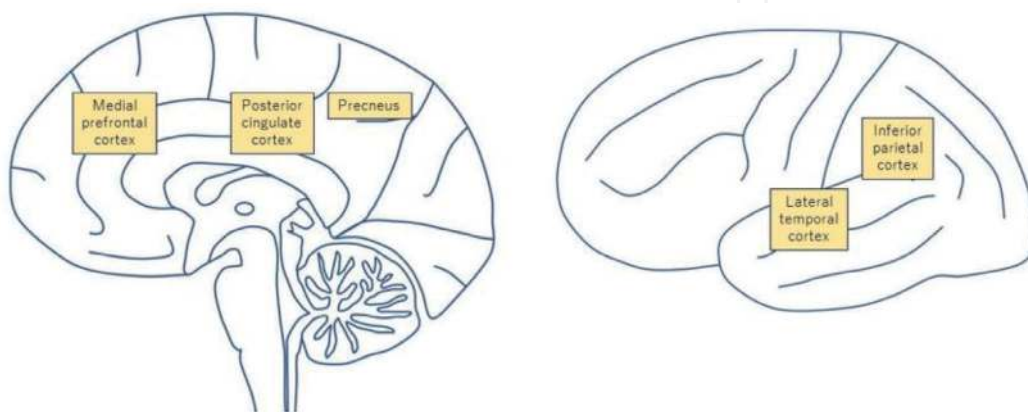


Figure 1. DMN components. DMN is mainly composed of the medial prefrontal cortex, precuneus, posterior cingulate cortex, inferior parietal cortex, and lateral temporal cortex.

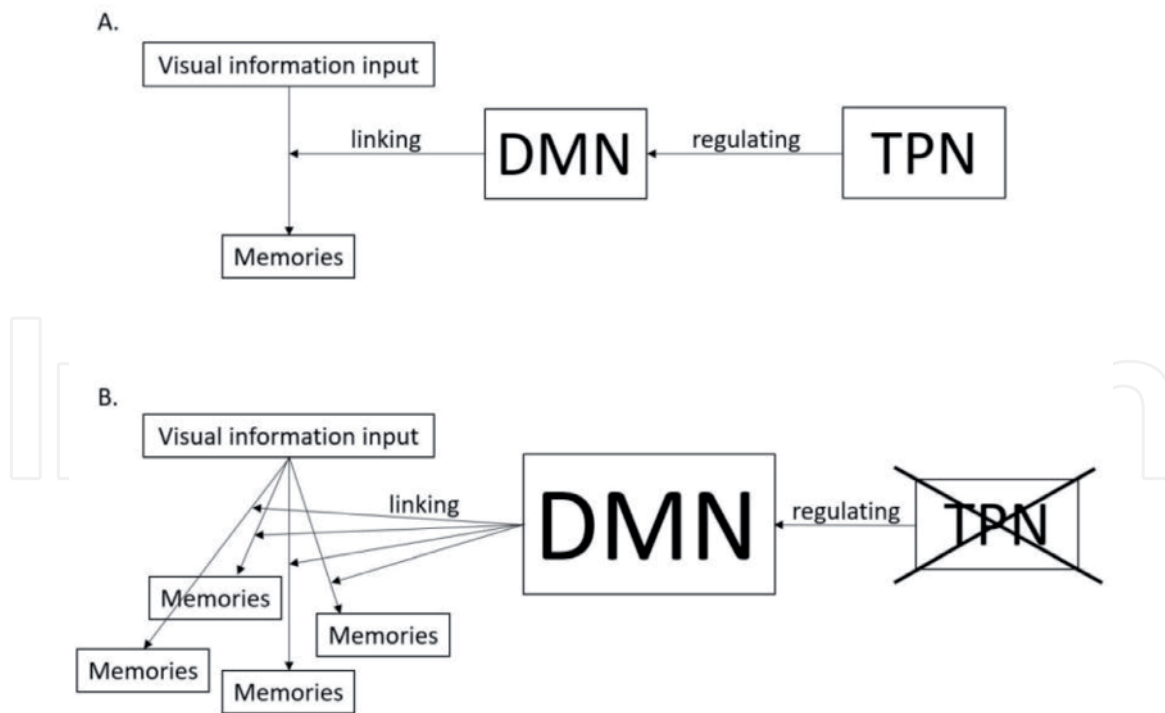


Figure 2.
Brain network process of linking visual input to memories. DMN properly links visual information input to memories under regulation by TPN (A). DMN links visual information input to inappropriate memories without adequate regulation by TPN (B).

3. Management of dopaminergic agents

Most PDD patients with VH use dopaminergic agents (e.g., levodopa, dopamine agonists, monoamine oxidase inhibitors, catechol-O-methyltransferase inhibitors, or amantadine) to ameliorate motor symptoms. However, these drugs may exacerbate VH in patients with PDD [14]. This exacerbation is considered to be due to the overactivity of the mesolimbic system caused by an unnatural dopaminergic stimulation. Of course, other drugs, such as anticholinergics, antidepressants, and N-methyl-D-aspartate (NMDA) antagonists, can cause VH; however, these are less frequently used, and most of them have a low risk [3, 14]. Thus, reducing the dose of dopaminergic agents ameliorates the symptoms of VH.

Not all patients require VH treatment since, in some mild cases, patients can understand that VH are unreal. In such cases, motor symptom treatment is prioritized; therefore, dopaminergic agents can be continued. Goetz et al. evaluated the prognosis of PD patients who have VH with insight [21]. Eighty-one percent of the patients progressed to VH without insight during 3-year follow-up (**Figure 3**). If VH cause delusions or violent behavior, doses of dopaminergic agents should be reduced. However, abruptly discontinuing them can cause severe rigidity and rhabdomyolysis, possibly leading to neuroleptic malignant syndrome [22, 23]; thus, gradual tapering is recommended.

Among dopaminergic agents, non-ergoline dopamine agonists pose a greater risk of VH than do others [24], which have different dopamine receptor binding profiles compared with dopamine [25]. It is considered that this profile difference causes VH. Four non-ergoline dopamine agonists, pramipexole, ropinirole, rotigotine, and apomorphine, received U.S. Food and Drug Administration (FDA) approval as PD treatment agents and are globally used. In PDD patients with VH using these drugs, a reduction in the dose is recommended. In particular, slow tapering is strongly recommended to avoid dopamine agonist withdrawal syndrome [26]. This syndrome can cause miscellaneous symptoms, such as anxiety,

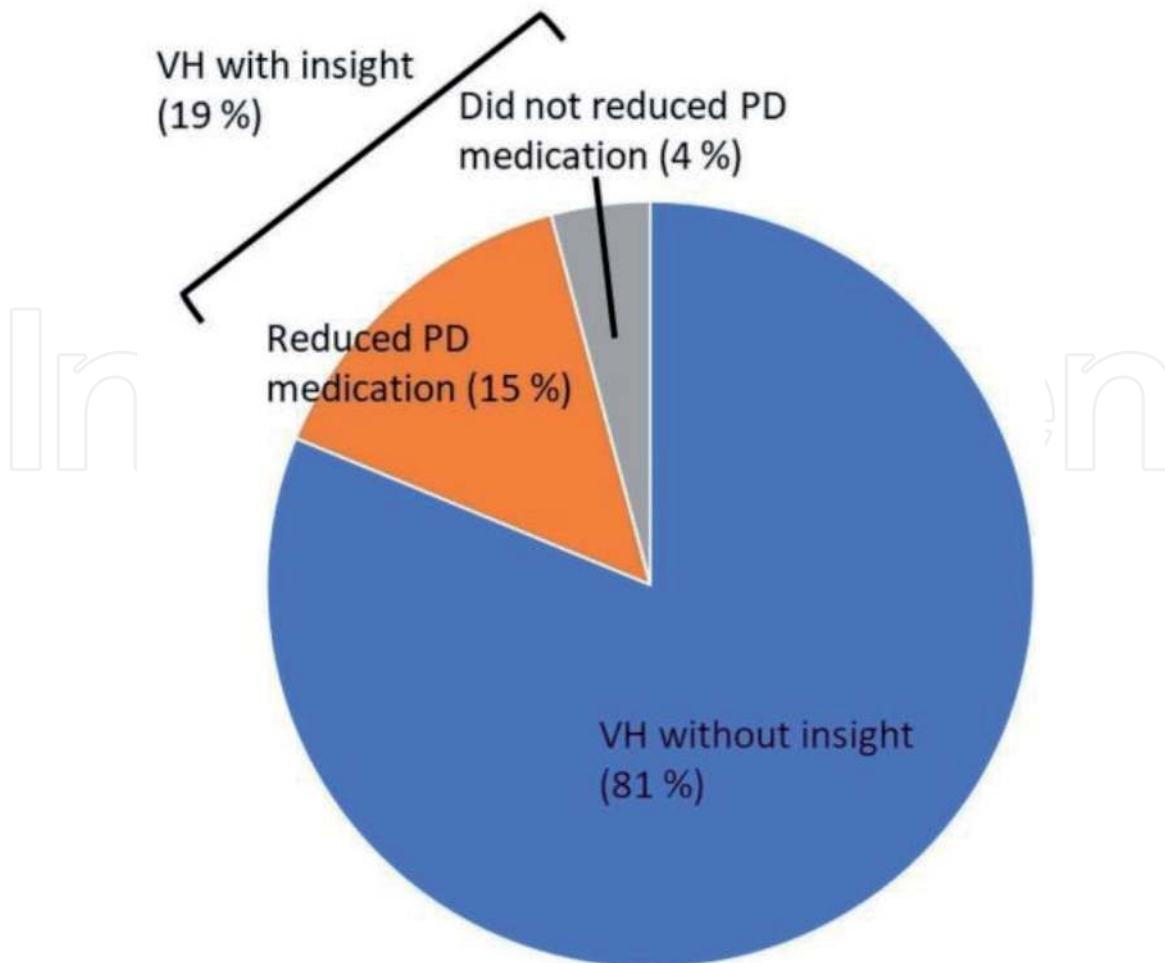


Figure 3. Three-year follow-up result of PD patients who had VH with insight [21]. Eighty-one percent of the patients progressed to VH without insight. Fifteen percent reduced PD medication and retained insight.

depression, irritability, fatigue, nausea, pain, and suicidal ideation [27, 28]. Careful monitoring is required after reducing drug dosage, since patients can show symptoms even during slow tapering [27, 29].

Reducing dopaminergic agents worsens motor symptoms in most cases. Since most PDD patients are in the advanced disease stage, worsening bradykinesia due to the drug reduction can lead to fatal complications such as pneumonia [30]. Therefore, it may be necessary to change from a high-risk drug to a relatively safe drug rather than merely reduce it (e.g., non-ergoline dopamine agonist replacement by levodopa). However, all dopaminergic agents can cause VH [3, 14], and deterioration of motor functions may be unavoidable in some cases. This is a trade-off situation, and it is necessary to comprehensively consider the balance of all symptoms and adjust the optimal prescription for each patient [31].

4. Therapeutic drugs

4.1 Overview of therapeutic drugs

Several studies have reported the therapeutic effects of antidementia and antipsychotic drugs on VH. There are two types of globally used antidementia drugs, cholinesterase inhibitors and NMDA receptor antagonists. We reviewed key previous studies on these drugs.

Cholinesterase inhibitors reduce VH and mostly do not worsen parkinsonism [32–43]. They can be used as first-line drugs. Although there is no study showing that memantine ameliorates VH sufficiently, it may improve cognitive function [44]. It can be used as an additional drug. Antipsychotic drugs should be used in a minimal dose due to high risks of mortality and adverse events [45]. However, some of them reduce VH without causing intolerable adverse events [46, 47]. They should be used for cases that are difficult to control.

Hereafter, we will explain the studies on and detailed characteristics of these drugs and propose a treatment strategy.

4.2 Cholinesterase inhibitors

Previous studies have revealed that PDD patients have cholinergic deficits [48]. Alpha-synuclein pathology usually occurs in the nucleus basalis of Meynert, which projects acetylcholine throughout the cerebral cortex [20]. This can cause TPN dysfunction leading to VH [49]. Cholinesterase inhibitors ameliorate cognitive functions and reduce VH in PDD and DLB patients [32–43]. They rarely worsen parkinsonism. Research has been conducted on three agents: rivastigmine, donepezil, and galantamine. These drugs are clinically used in North America, Latin America, Europe, the Middle East, Asia, and Oceania.

Rivastigmine was the first cholinesterase inhibitor that showed a reduction in VH in DLB patients in a randomized controlled trial (RCT) [36]. It not only inhibits acetylcholinesterase but also suppresses butyrylcholinesterase [50]. It was suggested that this dual inhibition may be beneficial for the long-term treatment of Alzheimer's disease (AD) [51, 52]. As half of the PDD patients have AD pathology [53], this pharmacological characteristic may also be preferable for PDD treatment. A large double-blind RCT suggested that rivastigmine ameliorates VH as well as cognitive function in PDD patients [39]. In this study, significant improvements in both neuropsychiatric inventory (NPI) and mini-mental state examination (MMSE) scores were observed. Although it caused a significantly high frequency of gastrointestinal adverse events, a transdermal patch is available [54], which is less likely to cause gastrointestinal events [55]. Another study compared rivastigmine effect on PDD patients with and without VH [42]. The cognitive function improvement was greater in patients with VH. These previous studies suggest rivastigmine is beneficial for PDD patients with VH.

Donepezil is a selective acetylcholinesterase inhibitor and delays the hydrolysis of acetylcholine in the brain neuronal synapses [56]. Stinton et al. performed a systematic review and meta-analysis of donepezil studies for PDD patients [32]. They compared MMSE scores between donepezil and placebo groups in four double-blind RCTs [34, 38, 41, 43]. Donepezil group showed better scores, but without significant difference. They found significantly better scores of NPI [38, 41], which suggests a possibly beneficial effect of donepezil on VH. The most frequent adverse event was gastrointestinal symptoms [34, 38, 41, 43]. In the largest study, 21% of the donepezil group patients experienced nausea, and the frequency was significantly higher than in the placebo group [41]. However, no discontinuation rate difference was found. Mori et al. performed a double-blind RCT of donepezil for DLB patients [35]. In this study, the experimental group had fewer VH and significant improvement of NPI. Furthermore, a positron emission tomography study showed a significant change of glucose metabolism in occipital lobes after administration of donepezil [33]. Although we need to be aware of the side effects, donepezil is a reasonable choice for VH treatment. We have summarized the RCTs of donepezil in **Table 1**.

Authors	Year	Patients	Protocol	Improved primary outcome
Aarsland et al. [43]	2002	PD patients with cognitive impairment	Randomized double-blind placebo-controlled crossover study	Mini-mental state examination and clinician's interview-based impression of change plus caregiver input scale
Ravina et al. [34]	2005	PDD patients	Randomized double-blind placebo-controlled crossover study	None (not significant trend for better Alzheimer's disease assessment scale-cognitive subscale scores)
Leroi et al. [38]	2004	PD patients with cognitive impairment	Randomized double-blind placebo-controlled study	The memory subscale of the dementia rating scale
Dubois et al. [41]	2012	PDD patients	Randomized double-blind placebo-controlled study	Clinician's interview-based impression of change plus caregiver input scale

Each study did not show the beneficial effect of donepezil on VH. However, Stinton's systematic review showed significantly better NPI scores, which suggested that donepezil possibly ameliorates VH [32].

Table 1.
RCTs of donepezil on PDD or PD patients with cognitive impairment.

Galantamine is another acetylcholinesterase inhibitor commonly used. It is also an allosteric potentiating ligand for nicotinic acetylcholine receptors [56, 57]. (The pharmacological characteristics of each cholinesterase inhibitor are described in **Figure 4**.) We did not find a double-blind RCT for galantamine. However, a small open-label controlled trial showed significant amelioration of VH, as well as MMSE and NPI scores [37]. The drug-related adverse events were seen in 30% of the experimental group, and the most frequent one was drooling. Edwards et al. performed a 24-week open-label study on DLB patients [40]. This study suggested that galantamine ameliorates VH similar to rivastigmine and donepezil in DLB patients. Galantamine is a possible option in PDD patients with VH, based on these studies.

Cholinesterase inhibitors generally ameliorate VH without worsening motor symptoms. Each of them has a different advantage, and they should as such be selected depending on the patient's condition. Donepezil is the most clinically studied drug, and its efficacy is reliable [34, 38, 41, 43]. Besides, the administration burden is small since it requires oral intake only once a day due to its long elimination half-life [58]. In contrast, galantamine requires oral administration twice daily [59]. However, it can ameliorate agitation and disinhibition due to its nicotinic effect [60]. The most remarkable benefit of rivastigmine is the availability of the transdermal patch [54]. It can be administered to patients who refuse oral intake.

4.3 Memantine

Memantine is an antidementia drug that blocks NMDA receptors [61]. It is approved for clinical use in North America, Latin America, Europe, the Middle East, Asia, and Oceania. Many RCTs and meta-analytic studies have demonstrated the beneficial effect of memantine in AD patients [62–66]. In contrast, according to a meta-analysis of three RCTs of PDD and DLB patients, no significant amelioration of cognitive function or VH was found [32, 67–69]. However, another meta-analysis reported a small but significant improvement in the score of clinicians'

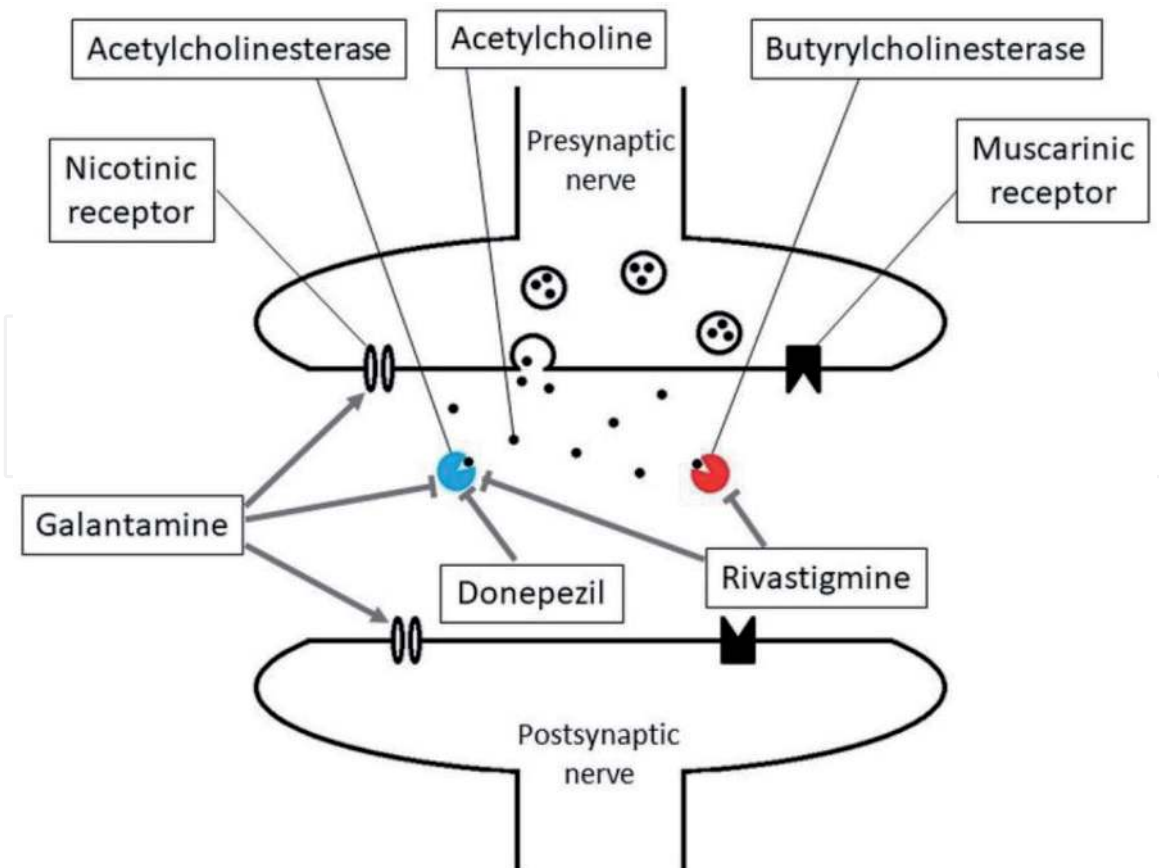


Figure 4.
The pharmacological characteristics of each cholinesterase inhibitor. Rivastigmine, donepezil, and galantamine inhibit acetylcholinesterase. Rivastigmine also suppresses butyrylcholinesterase. Galantamine binds to the nicotinic receptors and allosterically enhances their response to acetylcholine.

global impression of change [44]. Memantine has very few drug-related adverse events [67–69], and it can be used as an additional treatment for cognitive function improvement. However, findings from a case series suggested that memantine may exacerbate VH [70]. As other NMDA antagonists, such as ketamine, can cause hallucinations, memantine may have a similar effect [3]. Although the evidence suggesting exacerbation of VH is limited with most RCTs reporting no significant deterioration [67–69], memantine should be used with caution.

4.4 Antipsychotic agents

Antipsychotic agents compromise dopaminergic function and ameliorate psychiatric symptoms including VH. They should be used in a minimal dose owing to high risks of mortality and adverse events in these patients [45]. However, several studies have reported the beneficial effect of atypical antipsychotic agents.

A systematic review suggested that clozapine is efficacious in the treatment of psychosis in PD patients [46]. Two double-blind placebo-controlled RCTs were performed, and both studies showed significant amelioration of psychosis without worsening of motor symptoms [71, 72]. One of them showed significant alleviation of VH [72]. However, in a 12-week open-label extension study of these RCTs, one withdrawal out of 108 patients due to leukocytopenia was registered [73, 74]. Clozapine leukocytopenia can be fatal, and weekly blood sampling is required for several months according to each country's regulation [75]. In addition, it may cause myocarditis and hyperglycemia [76, 77]. Therefore, clozapine is clinically useful but requires monitoring.

Quetiapine is possibly useful for VH in PD patients, but the evidence is insufficient [46]. Five double-blind placebo-controlled RCTs were performed [78–82]. No significant amelioration of psychiatric symptoms was demonstrated in four studies [78–81]. However, one study showed significant improvement of the clinical global impression scale and the hallucination item of the brief psychiatric rating scale scores [82]. In addition, two RCTs compared effects of quetiapine and clozapine, and both were almost equally effective on psychosis [83, 84]. No worsening of motor symptoms was seen in all of these studies. Quetiapine is possibly beneficial for PDD patients with VH. However, it should be used cautiously because it is associated with risks of arrhythmia and hyperglycemia [85, 86]. We have summarized the quetiapine studies in **Table 2**.

Pimavanserin is a serotonin 5-HT_{2A} agonist without dopaminergic affinity [87]. A systematic review reported it effective in the treatment of PD psychosis [46], and it is the only drug that has FDA approval for the PD psychosis treatment. A double-blind, placebo-controlled RCT showed significantly better amelioration of VH and other psychiatric symptoms compared with that in the placebo group [88]. A subgroup analysis revealed that it was also efficacious and safe for cognitively impaired patients; therefore, it may be useful for PDD patients [89]. However, ten out of 105 experimental patients discontinued the treatment due to adverse events. Six of these patients experienced psychosis. In addition, pimavanserin may prolong the QT interval, and thus, it should not be used in patients with arrhythmias [90]. Pimavanserin administration requires caution and careful monitoring for psychiatric adverse events.

Other antipsychotic agents (e.g., olanzapine, risperidone, or aripiprazole) lack evidence of the beneficial effect on VH or other psychiatric symptoms. If other antipsychotic agents, especially typical ones, are required, they should be administered for as short a period as possible.

Authors	Year	Patients	Protocol	Main outcome
Morgante et al. [84]	2004	45 PD patients with psychosis	Randomized rater-blinded prospective comparison with clozapine	No significant difference
Ondo et al. [81]	2005	31 Non-demented PD patients with VH	Randomized double-blind, placebo-controlled, unforced titration parallel trial	No significant difference
Merims et al. [83]	2006	27 PD patients with psychosis	Randomized rater-blinded prospective comparison with clozapine	Significantly less delusions in clozapine group
Kurlan et al. [78]	2007	40 patients with DLB or PDD or AD	Randomized double-blind placebo-controlled trial	No significant difference
Rabey et al. [79]	2007	58 PD patients with psychosis	Randomized double-blind placebo-controlled trial	No significant difference
Shotbolt et al. [80]	2009	24 PD patients with psychosis	Randomized double-blind placebo-controlled trial	No significant difference
Fernandez et al. [82]	2009	16 PD patients with VH	Randomized double-blind placebo-controlled trial	Significantly better VH status in quetiapine group

The clinical evidence of quetiapine's beneficial effect on PD patients is not sufficient because most RCTs did not show preferable results.

Table 2.
Studies of quetiapine on PD patients.

4.5 Treatment strategy

In mild cases, the administration of cholinesterase inhibitors is the first option. When VH are troublesome, modification of dopaminergic agent is recommended. If VH are not controlled by dopaminergic agent modification and cholinesterase inhibitors, antipsychotic agents are recommended. We propose a treatment plan in light of these findings (Figure 5). The optimal treatment will be different for each patient and should be selected depending on the patient's condition.

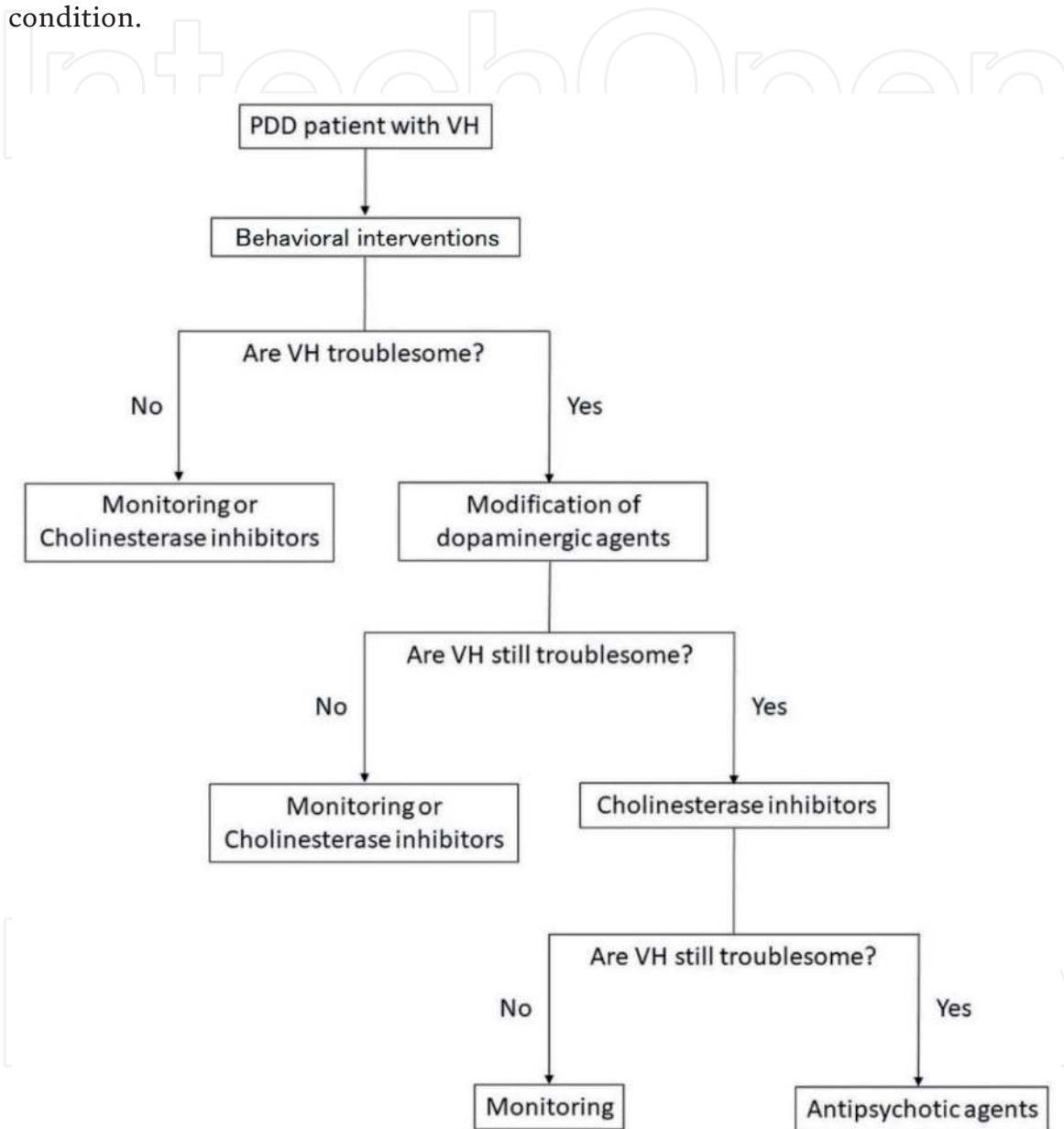


Figure 5. Flowchart for management of PD patients with VH. Optimal education about VH can ameliorate the behavioral symptoms in some patients. The need for medical treatment depends on whether VH are troublesome after behavioral interventions. However, if VH do not cause problems, it can worsen in the disease course and must be monitored.

5. Conclusion

VH are a frequent symptom in PDD. The lifetime incidence was reported as 50% [8]. VH can cause delusions and violent behavior that can be a considerable burden on patients and their caregivers [4–6]; therefore, optimal treatments are indispensable.

The cause of VH is hypothesized to be linked to the overactivity of the DMN [3]. Dopaminergic or cholinergic dysfunction is associated with dysregulation of the DMN. It is reasonable to adjust dopaminergic agents and administer anticholinergic drugs to treat the VH of PDD patients.

Reducing dopaminergic drug dosage can ameliorate symptoms [2]. However, this frequently worsens motor symptoms. The administration of cholinesterase inhibitors is effective and rarely worsens parkinsonism [2].

Antipsychotic agents should be used in a minimal dose because of adverse events [45]. However, several studies have reported that clozapine and pimavanserin can ameliorate VH without worsening motor symptoms [46]. Although there is not sufficient evidence, quetiapine is possibly useful too [46].

An optimal treatment plan should be selected depending on the patient's condition.

Conflict of interest


The authors declare no conflict of interest.

Author details

Yuki Asahara*, Taiji Mukai, Machiko Suda and Masahiko Suzuki
Department of Neurology, The Jikei University Katsushika Medical Center,
Tokyo, Japan

*Address all correspondence to: yuki.asahara.1988@jikei.ac.jp

IntechOpen

© 2021 The Author(s). Licensee IntechOpen. This chapter is distributed under the terms of the Creative Commons Attribution License (<http://creativecommons.org/licenses/by/3.0>), which permits unrestricted use, distribution, and reproduction in any medium, provided the original work is properly cited. 

References

- [1] Walker Z, Possin KL, Boeve BF, Aarsland D. Lewy body dementias. *Lancet*. 2015;**386**(10004):1683-1697. DOI: 10.1016/s0140-6736(15)00462-6
- [2] Kalia LV, Lang AE. Parkinson's disease. *Lancet*. 2015;**386**(9996):896-912. DOI: 10.1016/s0140-6736(14)61393-3
- [3] Russo M, Carrarini C, Dono F, Rispoli MG, Di Pietro M, Di Stefano V, et al. The pharmacology of visual hallucinations in synucleinopathies. *Frontiers in Pharmacology*. 2019;**10**:1379. DOI: 10.3389/fphar.2019.01379
- [4] Martinez-Martin P, Rodriguez-Blazquez C, Forjaz MJ, Frades-Payo B, Agüera-Ortiz L, Weintraub D, et al. Neuropsychiatric symptoms and caregiver's burden in Parkinson's disease. *Parkinsonism & Related Disorders*. 2015;**21**(6):629-634. DOI: 10.1016/j.parkreldis.2015.03.024
- [5] Aarsland D, Brønnick K, Ehrt U, De Deyn PP, Tekin S, Emre M, et al. Neuropsychiatric symptoms in patients with Parkinson's disease and dementia: Frequency, profile and associated caregiver stress. *Journal of Neurology, Neurosurgery, and Psychiatry*. 2007;**78**(1):36-42. DOI: 10.1136/jnnp.2005.083113
- [6] Kulisevsky J, Pagonabarraga J, Pascual-Sedano B, García-Sánchez C, Gironell A. Prevalence and correlates of neuropsychiatric symptoms in Parkinson's disease without dementia. *Movement Disorders*. 2008;**23**(13):1889-1896. DOI: 10.1002/mds.22246
- [7] Biglan KM, Holloway RG Jr, McDermott MP, Richard IH. Risk factors for somnolence, edema, and hallucinations in early Parkinson disease. *Neurology*. 2007;**69**(2):187-195. DOI: 10.1212/01.wnl.0000265593.34438.00
- [8] Williams DR, Lees AJ. Visual hallucinations in the diagnosis of idiopathic Parkinson's disease: A retrospective autopsy study. *Lancet Neurology*. 2005;**4**(10):605-610. DOI: 10.1016/s1474-4422(05)70146-0
- [9] Mishkin M, Ungerleider LG, Macko KA. Object vision and spatial vision: Two cortical pathways. *Trends in Neurosciences*. 1983;**6**:414-417. DOI: [https://doi.org/10.1016/0166-2236\(83\)90190-X](https://doi.org/10.1016/0166-2236(83)90190-X)
- [10] Raichle ME. The restless brain: How intrinsic activity organizes brain function. *Philosophical Transactions of the Royal Society of London. Series B, Biological Sciences*. 2015;**370**(1668):20140172. DOI: 10.1098/rstb.2014.0172
- [11] Fox MD, Snyder AZ, Vincent JL, Corbetta M, Van Essen DC, Raichle ME. The human brain is intrinsically organized into dynamic, anticorrelated functional networks. *Proceedings of the National Academy of Sciences of the United States of America*. 2005;**102**(27):9673-9678. DOI: 10.1073/pnas.0504136102
- [12] Blumenfeld H. Neuroanatomical basis of consciousness. In: *The Neurology of Consciousness*. Amsterdam: Elsevier; 2016. pp. 3-29
- [13] Gallagher DA, Parkkinen L, O'Sullivan SS, Spratt A, Shah A, Davey CC, et al. Testing an aetiological model of visual hallucinations in Parkinson's disease. *Brain* 2011;**134** (Pt 11):3299-3309. DOI: 10.1093/brain/awr225
- [14] Connolly BS, Lang AE. Pharmacological treatment of Parkinson disease: A review. *Journal of the American Medical Association*. 2014;**311**(16):1670-1683. DOI: 10.1001/jama.2014.3654

- [15] Bilder RM, Volavka J, Lachman HM, Grace AA. The catechol-O-methyltransferase polymorphism: Relations to the tonic-phasic dopamine hypothesis and neuropsychiatric phenotypes. *Neuropsychopharmacology*. 2004;**29**(11):1943-1961. DOI: 10.1038/sj.npp.1300542
- [16] Meyer-Lindenberg A, Kohn PD, Kolachana B, Kippenhan S, McInerney-Leo A, Nussbaum R, et al. Midbrain dopamine and prefrontal function in humans: Interaction and modulation by COMT genotype. *Nature Neuroscience*. 2005;**8**(5):594-596. DOI: 10.1038/nn1438
- [17] Williams GV, Goldman-Rakic PS. Modulation of memory fields by dopamine D1 receptors in prefrontal cortex. *Nature*. 1995;**376**(6541):572-575. DOI: 10.1038/376572a0
- [18] Kroener S, Chandler LJ, Phillips PE, Seamans JK. Dopamine modulates persistent synaptic activity and enhances the signal-to-noise ratio in the prefrontal cortex. *PLoS ONE*. 2009;**4**(8):e6507. DOI: 10.1371/journal.pone.0006507
- [19] Chudasama Y, Robbins TW. Dopaminergic modulation of visual attention and working memory in the rodent prefrontal cortex. *Neuropsychopharmacology*. 2004;**29**(9):1628-1636. DOI: 10.1038/sj.npp.1300490
- [20] Kalaitzakis ME, Christian LM, Moran LB, Graeber MB, Pearce RK, Gentleman SM. Dementia and visual hallucinations associated with limbic pathology in Parkinson's disease. *Parkinsonism & Related Disorders*. 2009;**15**(3):196-204. DOI: 10.1016/j.parkreldis.2008.05.007
- [21] Goetz CG, Fan W, Leurgans S, Bernard B, Stebbins GT. The malignant course of "benign hallucinations" in Parkinson disease. *Archives of Neurology*. 2006;**63**(5):713-716. DOI: 10.1001/archneur.63.5.713
- [22] Stotz M, Thümmler D, Schürch M, Renggli JC, Urwyler A, Pargger H. Fulminant neuroleptic malignant syndrome after perioperative withdrawal of antiParkinsonian medication. *British Journal of Anaesthesia*. 2004;**93**(6):868-871. DOI: 10.1093/bja/ae269
- [23] Ong KC, Chew EL, Ong YY. Neuroleptic malignant syndrome without neuroleptics. *Singapore Medical Journal*. 2001;**42**(2):85-88
- [24] Talati R, Baker WL, Patel AA, Reinhart K, Coleman CI. Adding a dopamine agonist to preexisting levodopa therapy vs. levodopa therapy alone in advanced Parkinson's disease: A meta analysis. *International Journal of Clinical Practice*. 2009;**63**(4):613-623. DOI: 10.1111/j.1742-1241.2009.02027.x
- [25] Gerlach M, Double K, Arzberger T, Leblhuber F, Tatschner T, Riederer P. Dopamine receptor agonists in current clinical use: Comparative dopamine receptor binding profiles defined in the human striatum. *Journal of Neural Transmission (Vienna)*. 2003;**110**(10):1119-1127. DOI: 10.1007/s00702-003-0027-5
- [26] Nirenberg MJ. Dopamine agonist withdrawal syndrome: Implications for patient care. *Drugs & Aging*. 2013;**30**(8):587-592. DOI: 10.1007/s40266-013-0090-z
- [27] Rabinak CA, Nirenberg MJ. Dopamine agonist withdrawal syndrome in Parkinson disease. *Archives of Neurology*. 2010;**67**(1):58-63. DOI: 10.1001/archneurol.2009.294
- [28] Pondal M, Marras C, Miyasaki J, Moro E, Armstrong MJ, Strafella AP, et al. Clinical features of dopamine agonist withdrawal syndrome in a movement disorders clinic. *Journal of*

Neurology, Neurosurgery, and Psychiatry. 2013;**84**(2):130-135. DOI: 10.1136/jnnp-2012-302684

[29] Cunnington A-L, White L, Hood K. Identification of possible risk factors for the development of dopamine agonist withdrawal syndrome in Parkinson's disease. *Parkinsonism & Related Disorders*. 2012;**18**(9):1051-1052. DOI: 10.1016/j.parkreldis.2012.05.012

[30] Mizuno Y, Takubo H, Mizuta E, Kuno S. Malignant syndrome in Parkinson's disease: Concept and review of the literature. *Parkinsonism & Related Disorders*. 2003;**9**(Suppl 1):S3-S9. DOI: 10.1016/s1353-8020(02)00125-6

[31] Suchowersky O. Parkinson's disease: Medical treatment of moderate to advanced disease. *Current Neurology and Neuroscience Reports*. 2002;**2**(4):310-316. DOI: 10.1007/s11910-002-0006-5

[32] Stinton C, McKeith I, Taylor JP, Lafortune L, Mioshi E, Mak E, et al. Pharmacological management of Lewy body dementia: A systematic review and meta-analysis. *The American Journal of Psychiatry*. 2015;**172**(8):731-742. DOI: 10.1176/appi.ajp.2015.14121582

[33] Satoh M, Ishikawa H, Meguro K, Kasuya M, Ishii H, Yamaguchi S. Improved visual hallucination by donepezil and occipital glucose metabolism in dementia with Lewy bodies: The Osaki-Tajiri project. *European Neurology*. 2010;**64**(6):337-344. DOI: 10.1159/000322121

[34] Ravina B, Putt M, Siderowf A, Farrar JT, Gillespie M, Crawley A, et al. Donepezil for dementia in Parkinson's disease: A randomised, double blind, placebo controlled, crossover study. *Journal of Neurology, Neurosurgery, and Psychiatry*. 2005;**76**(7):934-939. DOI: 10.1136/jnnp.2004.050682

[35] Mori E, Ikeda M, Kosaka K. Donepezil for dementia with Lewy bodies: A randomized, placebo-controlled trial. *Annals of Neurology*. 2012;**72**(1):41-52. DOI: 10.1002/ana.23557

[36] McKeith I, Del Ser T, Spano P, Emre M, Wesnes K, Anand R, et al. Efficacy of rivastigmine in dementia with Lewy bodies: A randomised, double-blind, placebo-controlled international study. *Lancet*. 2000;**356**(9247):2031-2036. DOI: 10.1016/s0140-6736(00)03399-7

[37] Litvinenko IV, Odinak MM, Mogil'naya VI, Emelin AY. Efficacy and safety of galantamine (reminyl) for dementia in patients with Parkinson's disease (an open controlled trial). *Neuroscience and Behavioral Physiology*. 2008;**38**(9):937-945. DOI: 10.1007/s11055-008-9077-3

[38] Leroi I, Brandt J, Reich SG, Lyketsos CG, Grill S, Thompson R, et al. Randomized placebo-controlled trial of donepezil in cognitive impairment in Parkinson's disease. *International Journal of Geriatric Psychiatry*. 2004;**19**(1):1-8. DOI: 10.1002/gps.993

[39] Emre M, Aarsland D, Albanese A, Byrne EJ, Deuschl G, De Deyn PP, et al. Rivastigmine for dementia associated with Parkinson's disease. *The New England Journal of Medicine*. 2004;**351**(24):2509-2518. DOI: 10.1056/NEJMoa041470

[40] Edwards K, Royall D, Hershey L, Lichter D, Hake A, Farlow M, et al. Efficacy and safety of galantamine in patients with dementia with Lewy bodies: A 24-week open-label study. *Dementia and Geriatric Cognitive Disorders*. 2007;**23**(6):401-405. DOI: 10.1159/000101512

[41] Dubois B, Tolosa E, Katzenschlager R, Emre M, Lees AJ, Schumann G, et al. Donepezil in

Parkinson's disease dementia: A randomized, double-blind efficacy and safety study. *Movement Disorders*. 2012;**27**(10):1230-1238. DOI: 10.1002/mds.25098

[42] Burn D, Emre M, McKeith I, De Deyn PP, Aarsland D, Hsu C, et al. Effects of rivastigmine in patients with and without visual hallucinations in dementia associated with Parkinson's disease. *Movement Disorders*. 2006;**21**(11):1899-1907. DOI: 10.1002/mds.21077

[43] Aarsland D, Laake K, Larsen JP, Janvin C. Donepezil for cognitive impairment in Parkinson's disease: A randomised controlled study. *Journal of Neurology, Neurosurgery, and Psychiatry*. 2002;**72**(6):708-712. DOI: 10.1136/jnnp.72.6.708

[44] Wang HF, Yu JT, Tang SW, Jiang T, Tan CC, Meng XF, et al. Efficacy and safety of cholinesterase inhibitors and memantine in cognitive impairment in Parkinson's disease, Parkinson's disease dementia, and dementia with Lewy bodies: Systematic review with meta-analysis and trial sequential analysis. *Journal of Neurology, Neurosurgery, and Psychiatry*. 2015;**86**(2):135-143. DOI: 10.1136/jnnp-2014-307659

[45] Ballard C, Isaacson S, Mills R, Williams H, Corbett A, Coate B, et al. Impact of current antipsychotic medications on comparative mortality and adverse events in people with Parkinson disease psychosis. *Journal of the American Medical Directors Association*. 2015;**16**(10):898.e891-897. DOI: 10.1016/j.jamda.2015.06.021

[46] Seppi K, Ray Chaudhuri K, Coelho M, Fox SH, Katzenschlager R, Perez Lloret S, et al. Update on treatments for nonmotor symptoms of Parkinson's disease-an evidence-based medicine review. *Movement Disorders*. 2019;**34**(2):180-198. DOI: 10.1002/mds.27602

[47] Seppi K, Weintraub D, Coelho M, Perez-Lloret S, Fox SH, Katzenschlager R, et al. The movement disorder society evidence-based medicine review update: Treatments for the non-motor symptoms of Parkinson's disease. *Movement Disorders*. 2011; **26 Suppl 3**(03):S42-S80. DOI: 10.1002/mds.23884

[48] Halliday GM, Leverenz JB, Schneider JS, Adler CH. The neurobiological basis of cognitive impairment in Parkinson's disease. *Movement Disorders*. 2014;**29**(5):634-650. DOI: 10.1002/mds.25857

[49] Bohnen NI, Kaufer DI, Hendrickson R, Ivanco LS, Lopresti BJ, Constantine GM, et al. Cognitive correlates of cortical cholinergic denervation in Parkinson's disease and parkinsonian dementia. *Journal of Neurology*. 2006;**253**(2):242-247. DOI: 10.1007/s00415-005-0971-0

[50] Kandiah N, Pai MC, Senanarong V, Looi I, Ampil E, Park KW, et al. Rivastigmine: The advantages of dual inhibition of acetylcholinesterase and butyrylcholinesterase and its role in subcortical vascular dementia and Parkinson's disease dementia. *Clinical Interventions in Aging*. 2017;**12**:697-707. DOI: 10.2147/cia.S129145

[51] Blesa R, Bullock R, He Y, Bergman H, Gambina G, Meyer J, et al. Effect of butyrylcholinesterase genotype on the response to rivastigmine or donepezil in younger patients with Alzheimer's disease. *Pharmacogenetics and Genomics*. 2006;**16**(11):771-774. DOI: 10.1097/01.fpc.0000220573.05714.ac

[52] Perry EK, Perry RH, Blessed G, Tomlinson BE. Changes in brain cholinesterases in senile dementia of Alzheimer type. *Neuropathology and Applied Neurobiology*. 1978;**4**(4):273-277. DOI: 10.1111/j.1365-2990.1978.tb00545.x

- [53] Irwin DJ, Lee VM, Trojanowski JQ. Parkinson's disease dementia: Convergence of α -synuclein, tau and amyloid- β pathologies. *Nature Reviews Neuroscience*. 2013;**14**(9):626-636. DOI: 10.1038/nrn3549
- [54] Yang LP, Keating GM. Rivastigmine transdermal patch: In the treatment of dementia of the Alzheimer's type. *CNS Drugs*. 2007;**21**(11):957-965. DOI: 10.2165/00023210-200721110-00007
- [55] Winblad B, Cummings J, Andreasen N, Grossberg G, Onofri M, Sadowsky C, et al. A six-month double-blind, randomized, placebo-controlled study of a transdermal patch in Alzheimer's disease--rivastigmine patch versus capsule. *International Journal of Geriatric Psychiatry*. 2007;**22**(5):456-467. DOI: 10.1002/gps.1788
- [56] Anand P, Singh B. A review on cholinesterase inhibitors for Alzheimer's disease. *Archives of Pharmacal Research*. 2013;**36**(4):375-399. DOI: 10.1007/s12272-013-0036-3
- [57] Harvey AL. The pharmacology of galanthamine and its analogues. *Pharmacology & Therapeutics*. 1995;**68**(1):113-128. DOI: 10.1016/0163-7258(95)02002-0
- [58] Asiri YA, Mostafa GA. Donepezil. Profiles of Drug Substances Excipients and Related Methodology. 2010;**35**:117-150. DOI: 10.1016/s1871-5125(10)35003-5
- [59] Farlow MR. Clinical pharmacokinetics of galantamine. *Clinical Pharmacokinetics*. 2003;**42**(15):1383-1392. DOI: 10.2165/00003088-200342150-00005
- [60] Herrmann N, Rabheru K, Wang J, Binder C. Galantamine treatment of problematic behavior in Alzheimer disease: Post-hoc analysis of pooled data from three large trials. *The American Journal of Geriatric Psychiatry*. 2005;**13**(6):527-534. DOI: 10.1176/appi.ajgp.13.6.527
- [61] Johnson JW, Kotermanski SE. Mechanism of action of memantine. *Current Opinion in Pharmacology*. 2006;**6**(1):61-67. DOI: 10.1016/j.coph.2005.09.007
- [62] Wilkinson D, Wirth Y, Goebel C. Memantine in patients with moderate to severe Alzheimer's disease: Meta-analyses using realistic definitions of response. *Dementia and Geriatric Cognitive Disorders*. 2014;**37**(1-2):71-85. DOI: 10.1159/000353801
- [63] Reisberg B, Doody R, Stöffler A, Schmitt F, Ferris S, Möbius HJ. Memantine in moderate-to-severe Alzheimer's disease. *The New England Journal of Medicine*. 2003;**348**(14):1333-1341. DOI: 10.1056/NEJMoa013128
- [64] McShane R, Areosa Sastre A, Minakaran N. Memantine for dementia. *Cochrane Database Systematic Review*. 2006;(2):Cd003154. DOI: 10.1002/14651858.CD003154.pub5
- [65] Jiang J, Jiang H. Efficacy and adverse effects of memantine treatment for Alzheimer's disease from randomized controlled trials. *Neurological Sciences*. 2015;**36**(9):1633-1641. DOI: 10.1007/s10072-015-2221-2
- [66] Doody RS, Tariot PN, Pfeiffer E, Olin JT, Graham SM. Meta-analysis of six-month memantine trials in Alzheimer's disease. *Alzheimer's & Dementia*. 2007;**3**(1):7-17. DOI: 10.1016/j.jalz.2006.10.004
- [67] Aarsland D, Ballard C, Walker Z, Bostrom F, Alves G, Kossakowski K, et al. Memantine in patients with Parkinson's disease dementia or dementia with Lewy bodies: A double-blind, placebo-controlled, multicentre trial. *Lancet Neurology*. 2009;**8**(7):613-618. DOI: 10.1016/s1474-4422(09)70146-2

- [68] Emre M, Tsolaki M, Bonuccelli U, Destée A, Tolosa E, Kutzelnigg A, et al. Memantine for patients with Parkinson's disease dementia or dementia with Lewy bodies: A randomised, double-blind, placebo-controlled trial. *Lancet Neurology*. 2010;**9**(10):969-977. DOI: 10.1016/s1474-4422(10)70194-0
- [69] Leroi I, Overshott R, Byrne EJ, Daniel E, Burns A. Randomized controlled trial of memantine in dementia associated with Parkinson's disease. *Movement Disorders*. 2009;**24**(8):1217-1221. DOI: 10.1002/mds.22495
- [70] Ridha BH, Josephs KA, Rossor MN. Delusions and hallucinations in dementia with Lewy bodies: Worsening with memantine. *Neurology*. 2005;**65**(3):481-482. DOI: 10.1212/01.wnl.0000172351.95783.8e
- [71] Clozapine in drug-induced psychosis in Parkinson's disease. The French clozapine Parkinson study group. *Lancet*. 1999;**353**(9169):2041-2042
- [72] Parkinson Study Group. Low-dose clozapine for the treatment of drug-induced psychosis in Parkinson's disease. *The New England Journal of Medicine*. 1999;**340**(10):757-763. DOI: 10.1056/nejm199903113401003
- [73] Pollak P, Tison F, Rascol O, Destée A, Péré JJ, Senard JM, et al. Clozapine in drug induced psychosis in Parkinson's disease: A randomised, placebo controlled study with open follow up. *Journal of Neurology, Neurosurgery, and Psychiatry*. 2004;**75**(5):689-695. DOI: 10.1136/jnnp.2003.029868
- [74] Factor SA, Friedman JH, Lannon MC, Oakes D, Bourgeois K. Clozapine for the treatment of drug-induced psychosis in Parkinson's disease: Results of the 12 week open label extension in the PSYCLOPS trial. *Movement Disorders*. 2001;**16**(1):135-139. DOI: 10.1002/1531-8257(200101)16:1<135::aid-mds1006>3.0.co;2-q
- [75] Nielsen J, Young C, Ifteni P, Kishimoto T, Xiang YT, Schulte PF, et al. Worldwide differences in regulations of clozapine use. *CNS Drugs*. 2016;**30**(2):149-161. DOI: 10.1007/s40263-016-0311-1
- [76] Joshi RS, Singh SP, Panicker MM. 5-HT(2A) deletion protects against clozapine-induced hyperglycemia. *Journal of Pharmacological Sciences*. 2019;**139**(2):133-135. DOI: 10.1016/j.jphs.2018.11.015
- [77] Bellissima BL, Tingle MD, Cicović A, Alawami M, Kenedi C. A systematic review of clozapine-induced myocarditis. *International Journal of Cardiology*. 2018;**259**:122-129. DOI: 10.1016/j.ijcard.2017.12.102
- [78] Kurlan R, Cummings J, Raman R, Thal L. Quetiapine for agitation or psychosis in patients with dementia and parkinsonism. *Neurology*. 2007;**68**(17):1356-1363. DOI: 10.1212/01.wnl.0000260060.60870.89
- [79] Rabey JM, Prokhorov T, Miniovitz A, Dobronevsky E, Klein C. Effect of quetiapine in psychotic Parkinson's disease patients: A double-blind labeled study of 3 months' duration. *Movement Disorders*. 2007;**22**(3):313-318. DOI: 10.1002/mds.21116
- [80] Shotbolt P, Samuel M, Fox C, David AS. A randomized controlled trial of quetiapine for psychosis in Parkinson's disease. *Neuropsychiatric Disease and Treatment*. 2009;**5**:327-332. DOI: 10.2147/ndt.s5335
- [81] Ondo WG, Tintner R, Voung KD, Lai D, Ringholz G. Double-blind, placebo-controlled, unforced titration parallel trial of quetiapine for

dopaminergic-induced hallucinations in Parkinson's disease. *Movement Disorders*. 2005;20(8):958-963. DOI: 10.1002/mds.20474

[82] Fernandez HH, Okun MS, Rodriguez RL, Malaty IA, Romrell J, Sun A, et al. Quetiapine improves visual hallucinations in Parkinson disease but not through normalization of sleep architecture: Results from a double-blind clinical-polysomnography study. *The International Journal of Neuroscience*. 2009;119(12):2196-2205. DOI: 10.3109/00207450903222758

[83] Merims D, Balas M, Peretz C, Shabtai H, Giladi N. Rater-blinded, prospective comparison: Quetiapine versus clozapine for Parkinson's disease psychosis. *Clinical Neuropharmacology*. 2006;29(6):331-337. DOI: 10.1097/01.Wnf.0000236769.31279.19

[84] Morgante L, Epifanio A, Spina E, Zappia M, Di Rosa AE, Marconi R, et al. Quetiapine and clozapine in parkinsonian patients with dopaminergic psychosis. *Clinical Neuropharmacology*. 2004;27(4):153-156. DOI: 10.1097/01.wnf.0000136891.17006.ec

[85] Aghaienia N, Brahm NC, Lussier KM, Washington NB. Probable quetiapine-mediated prolongation of the QT interval. *Journal of Pharmacy Practice*. 2011;24(5):506-512. DOI: 10.1177/0897190011415683

[86] Domon SE, Cargile CS. Quetiapine-associated hyperglycemia and hypertriglyceridemia. *Journal of the American Academy of Child and Adolescent Psychiatry*. 2002;41(5):495-496. DOI: 10.1097/00004583-200205000-00004

[87] Vanover KE, Weiner DM, Makhay M, Veinbergs I, Gardell LR, Lameh J, et al. Pharmacological and behavioral profile of N-(4-fluorophenylmethyl)-N-(1-

methylpiperidin-4-yl)-N'-(4-(2-methylpropyloxy)phenylmethyl) carbamide (2R,3R)-dihydroxy butanedioate (2:1) (ACP-103), a novel 5-hydroxytryptamine(2A) receptor inverse agonist. *The Journal of Pharmacology and Experimental Therapeutics*. 2006;317(2):910-918. DOI: 10.1124/jpet.105.097006

[88] Cummings J, Isaacson S, Mills R, Williams H, Chi-Burris K, Corbett A, et al. Pimavanserin for patients with Parkinson's disease psychosis: A randomised, placebo-controlled phase 3 trial. *Lancet*. 2014;383(9916):533-540. DOI: 10.1016/s0140-6736(13)62106-6

[89] Cummings J, Ballard C, Tariot P, Owen R, Foff E, Youakim J, et al. Pimavanserin: Potential treatment for dementia-related psychosis. *The Journal of Prevention of Alzheimer's Disease*. 2018;5(4):253-258. DOI: 10.14283/jpad.2018.29

[90] Cruz MP. Pimavanserin (Nuplazid): A treatment for hallucinations and delusions associated with Parkinson's disease. *P T*. 2017;42(6):368-371