

Etiology of Valvular Heart Disease in the 21st Century

HARISIOS BOUDOULAS

Division of Cardiology, College of Medicine and Public Health, The Ohio State University, Columbus, Ohio, USA

Key words: **Valvular heart disease, etiology.**

Manuscript received:
July 15, 2002;
Accepted:
August 20, 2002

Address:
Harisios Boudoulas

The Ohio State University, 473 West, 12th Avenue, 2nd floor, Columbus, Ohio, 432 10
e-mail:
Boudoulas-1@medctr.osu.edu

Structural abnormalities and disorders of cardiac valve function result in valvular heart disease. The etiology of valvular heart disease has changed dramatically in the last forty to fifty years¹⁻³. A significant reduction in the incidence of acute rheumatic fever and its sequelae, the increase of life expectancy, the recognition of new causes of valvular heart disease and the advancement of technology are responsible for the metamorphosis in the etiology and pathogenesis of valvular disorders (Figure 1). Clinical entities which are associated with valvular heart disease are shown in Table 1.

Heritable-Congenital

Heritable disorders of connective tissue origin

Connective tissue abnormalities are of etiologic importance in a broad spectrum of cardiovascular disorders. The Marfan syndrome and the Ehlers-Danlos syndrome, well recognized heritable disorders of connective tissue, represent accepted examples of this association. The association between adult polycystic kidney disease and cardiovascular disease of connective tissue has been recognized with increasing frequency during the last decades. Aortic root dilatation, aortic valvular regurgitation and floppy mitral valve (FMV)/mitral valve prolapse (MVP)/mitral valvular regurgitation, have been described in patients with adult polycystic kidney disease⁴. Isolated valvular abnor-

malities, such as FMV/MVP, multivalvular prolapse, annuloaortic ectasia, certain forms of isolated aortic regurgitation, and pulmonary artery dilatation, have been reported to be of connective tissue etiology^{1,4}.

Congenital heart disease

Bicuspid aortic valve. Congenital aortic stenosis is a well defined anomaly which can be of different severity. Bicuspid aortic valve without clinically significant stenosis at birth is a common congenital anomaly in adults with a male predominance. Most patients develop aortic valvular regurgitation or aortic stenosis and all have an increased risk of infective endocarditis. The association of bicuspid aortic valve with coarctation of the aorta and thoracic aortopathy, manifest as aortic root dilatation or aortic dissection, has clinical significance in terms of comprehensive diagnosis and long-term prognosis.

Mitral stenosis, mitral regurgitation. Congenital mitral valvular stenosis is a rare finding in adults. Atrioventricular septal defects and corrected transposition of the great vessels are among the congenital abnormalities that produce mitral regurgitation in adults.

Inflammatory - Immunologic

Rheumatic fever. A variety of epidemiologic studies have shown that the incidence of rheumatic fever and the prevalence of rheumatic heart disease have declined

Table 1. Valvular Heart Disease: Etiology

Heritable - Congenital
Inflammatory - Immunologic
Endocardial Disorders
Myocardial Dysfunction
Disease and Disorders of other Organs
Aging
Post-Interventional Valvular Disease
Drugs and Physical Agents

dramatically over the last decades in developed countries (Figure 1). A number of reasons have been postulated to explain such a decrease: improvement in living standards, better access to medical care, wider use of antibiotics, as well as natural changes in the streptococcal strains. In the developing countries, however, the situation is similar to that of industrialized nations in the early 20th century, when rheumatic fever was one of the leading causes of death and disability in young people. Recently, important progress towards the development of an effective vaccine to protect against streptococcal nasopharyngeal infection opens up the possibility of better control of rheumatic fever in these countries⁵.

The clinical presentation of acute rheumatic mitral valvulitis is mitral regurgitation. The most common chronic valvular abnormality resulting from rheumatic fever is mitral stenosis. Aortic valve insufficiency is common and in rare instances, the tricuspid valve may also be involved.

Acquired Immune Deficiency Syndrome (AIDS). Cardiac involvement based on postmortem examinations of patients with AIDS includes myocardial disease, pericardial disease or endocardial disease with valvular involvement^{1,2}. The most common endocardial lesion reported in patients with AIDS is nonbacterial thrombotic endocarditis (NBTE) with

valvular vegetation formation which can involve all four valves, but left-sided lesions are more common. Vegetations consist of platelets within a fibrin mesh and a few inflammatory cells. Thromboembolic phenomena may occur. Right heart involvement with infective endocarditis occurs in patients who are addicted to intravenous drugs in general, and in particular in patients with AIDS.

Kawasaki's disease. Kawasaki's disease is an acute febrile illness which affects infants and young children. In about 20% of the patients, vasculitis of the coronary vasa vasorum leads to coronary arterial aneurysm formation, thrombosis and myocardial infarction. Less often, mitral regurgitation, acute or chronic, may occur^{1,2}.

Cardiovascular syphilis. Despite extensive public educational efforts and the availability of effective antibiotic treatment for syphilis, cases of cardiovascular syphilis still occur. Aortitis occurs in the tertiary form of syphilis in 70-80% of patients with untreated syphilis. Cardiovascular syphilis may present as aortic regurgitation, aortic aneurysm or coronary ostial stenosis. Aortic regurgitation, the most common complication of syphilitic aortitis, usually occurs in the second or third decade after the infection¹.

Seronegative spondylarthropathies. A group of immunologic syndromes such as ankylosing spondylitis, Reiter's disease, psoriatic arthropathy, arthritis of inflammatory bowel disease, Whipple's disease and Bechet's disease which may be associated with valvular heart disease, are all grouped under the term "seronegative spondylarthropathies". They are distinguished from rheumatoid arthritis by the absence of rheumatoid factor and the presence of HLA-B27 antigen. However, the precise role of this antigen in the pathogenesis of the spondylarthropathies is not clear. Aortic regurgitation, second

Etiology of Valvular Heart Disease

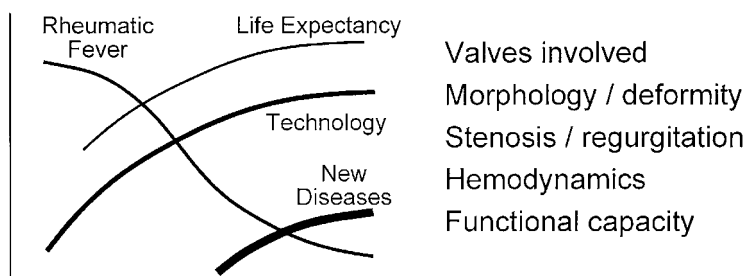


Figure 1. Factors contributing to the metamorphosis in the etiology and pathogenesis of valvular heart disease.

dary to aortic dilatation, is the primary valvular lesion described in ankylosing spondylitis. The aortic ring is dilated and the cusps appear to be somewhat rolled and inverted. The most significant morphologic changes are encountered in the proximal three to four centimeter of the aorta. Mitral valvular regurgitation may also occur.

Systemic lupus erythematosus. Systemic lupus erythematosus may produce mitral valve and tricuspid valve disease. Libman and Sacks described four patients with an atypical form of verrucose endocarditis, with involvement of all four valves and the mural endocardium⁶. The clinical picture included pericarditis and systemic embolic phenomena. A high correlation between lupus pericarditis and Libman-Sacks verrucose endocarditis has been a consistent finding since the original report. Valvular heart disease in patients with systemic lupus erythematosus has been reported regardless of the presence or absence of antiphospholipid antibodies.

Cardiac valve disease associated with the antiphospholipid syndrome. The syndrome is caused by the appearance of circulating antiphospholipid (aPL) antibodies. aPL are spontaneously acquired immunoglobulins directed against negatively charged phospholipids. aPL antibodies were initially found in sera of patients with systemic lupus erythematosus. They have since been found occasionally in other connective tissue diseases, malignancies, infectious disorders, may be induced by drugs and also may be present in subjects without any underlying disorder⁷.

aPL in vitro act as an anticoagulant that prolongs the clotting time, although no specific deficiency of the clotting factors is detectable. Despite its anticoagulant behavior in vitro, patients with aPL present with a high incidence of arterial and venous thrombosis. The presence of aPL antibodies and either arterial or venous occlusive events constitute "the antiphospholipid syndrome"⁷. Valvular lesions may involve the mitral and the aortic valves, usually resulting in mitral or aortic regurgitation; in certain cases the valvular regurgitation may be severe enough to require surgical intervention. The pathogenesis of valvular lesions is not clear. It is likely that deposition of thrombi is the initial valve abnormality that subsequently promotes an inflammatory response.

The isolated finding of aPL antibodies in the absence of clinical manifestations requires no treatment. Patients with thromboembolic manifestations should be fully anticoagulated. Patients with valvular involvement should be managed the same way as

patients with valvular heart disease of other etiologies.

Endocardial disorders

NBTE. NBTE, referred to in the earlier literature as marantic endocarditis, occurs most often in patients with malignant disease, but may also complicate other chronic wasting diseases, such as tuberculosis, uraemia, or AIDS. The initiating factor in the pathogenesis of NBTE is not known⁸. Endothelial damage caused by circulating cytokines such as tumor necrosis factor or interleukin-1, which can be increased in patients with malignancy or chronic wasting diseases, might trigger platelet deposition. Sterile vegetations, (Libman-Sacks endocarditis), sometimes develop in patients with systemic lupus erythematosus. The diagnosis of NBTE is frequently made at autopsy, however, echocardiographic recognition now complements its clinical suspicion.

Infective endocarditis. Although infective endocarditis may occur on a previously normal valve, it is most often seen in valves deformed by congenital or rheumatic disease, or on FMV producing MVP and mitral valvular regurgitation^{1,4}. Degenerative cardiac diseases, such as calcified mitral or aortic valves, also predispose to the development of infective endocarditis. Infective endocarditis may result in endocardial vegetations with thromboembolic potential, valvular destruction, endomyocardial lesions and acute valvular regurgitation. The incidence of infective endocarditis increases with age and thus, is less common in children. The distribution ranges from 24% to 45% for the mitral valve alone, 5% to 36% for the aortic valve alone and 5% to 35% for the aortic and mitral valves combined. Tricuspid valve involvement with infective endocarditis is less common, but may be frequent in addicts who take intravenous drugs; the pulmonary valve is rarely involved.

Endomyocardial fibroelastosis. Endomyocardial fibroelastosis may be associated with valvular heart disease but it is rare in developed countries.

Myocardial dysfunction

Ischemic heart disease. Mitral regurgitation is common in patients with ischemic heart disease. This is related to papillary muscle dysfunction in combination with left ventricular segmental contraction abnormalities due to ischemic cardiomyopathy, or in rare cases due to papillary muscle rupture. Tricuspid regurgitation

on an ischemic basis may also occur in patients with septal or right ventricular infarction, or chronic ischemic cardiomyopathy.

Dilated cardiomyopathy. Mitral regurgitation is also common in patients with dilated cardiomyopathy and is due to changes in left ventricular architecture, wall motion abnormalities and papillary muscle dysfunction. Tricuspid regurgitation may occur as a result of changes in right ventricular architecture, papillary muscle and right ventricular dysfunction.

Hypertrophic cardiomyopathy. Mitral regurgitation is common in patients with hypertrophic cardiomyopathy. It is related to the systolic anterior motion of the mitral valve which may produce obstruction of the left ventricular outflow tract and mitral regurgitation. The incidence of FMV/MVP in patients with hypertrophic cardiomyopathy, is the same as in the general population¹⁴.

Diseases and disorders of other organs

Chronic renal failure. Valvular abnormalities occur in patients with chronic renal failure⁹. Dystrophic calcification as well as infective endocarditis may cause valvular heart disease in these patients. Mitral annular calcification preferentially involves the posterior mitral leaflet but can affect both leaflets. Mitral regurgitation is usually the sequel of the calcification, but when it is severe may cause mitral stenosis or may extend to the aortic valve and produce aortic stenosis as well.

Carcinoid heart disease. Cardiac abnormalities occur in over two-thirds of patients with carcinoid, but only a quarter of them develop clinically apparent right-sided valvular heart disease. The tricuspid and/or pulmonary valve are the usually affected valves, but in rare cases left sided valvular heart disease has been described¹⁰. Carcinoid plaques may appear on either the atrial or ventricular side of the leaflets and are composed of fibrous connective tissue with no elastic fibers.

Aging

Calcific aortic stenosis, mitral annular calcification. Although there has been a dramatic reduction in rheumatic valve disease in the industrialized countries over the past 40 years, there has not been a similar reduction in valve surgery. This is because the types of patients being referred for surgery have changed. Calcific aortic stenosis and mitral annular calcifi-

cation are common valvular abnormalities in the elderly and their incidence has increased due to increase in life expectancy (Figure 1).

Although the incidence of degenerative valve disease increases with age, aging itself does not appear to be the only factor, because valve disease is not present universally in the elderly. Moreover, the initial lesion of calcific aortic valve disease seems to involve an active process similar to that of atherosclerosis, including lipid deposition, macrophage infiltration, and production of osteopontin and other proteins^{1,2}.

Mitral annulus calcification also occurs primarily in the elderly patients, however, it may be present in younger patients with the Marfan syndrome and chronic renal failure^{1,9}.

Taking into consideration that atherosclerotic coronary artery disease is to a certain extent a preventable condition, the same principles for prevention should be applied to degenerative valve disease. Accordingly, early forms of aortic stenosis and probably, of aortic sclerosis and mitral annulus calcification should be considered as indicators for implementation of measures generally used to treat atherosclerotic vascular disease.

Post-Interventional valvular disease

Balloon valvulotomy. Balloon mitral valvulotomy is effective treatment for many patients with valvular mitral stenosis. Long-term results after the procedure depend on baseline patient characteristics but residual mitral stenosis is present in most of the cases and mitral regurgitation may also occur. The results of balloon aortic valvulotomy are less satisfactory and this procedure at best is considered as a short-term palliative procedure for elderly patients with symptomatic aortic valvular stenosis. Significant residual aortic stenosis is always present and aortic insufficiency is often seen following aortic valvulotomy¹.

Valve reconstructive surgery. Mitral valve reconstruction is possible in a high percentage of patients with FMV/MVP, mitral valvular regurgitation. With reconstructive surgery, many of the long-term problems associated with valve prostheses can often be avoided and thus, early operation in less symptomatic patients with significant mitral regurgitation may be recommended. Mitral valve repair can be performed in a significant number of young patients with rheumatic valvular disease. The result, however,

in this group of patients is less optimal as compared to patients with mitral regurgitation secondary to FMV/MVP.

Valve replacement. Prosthetic heart valves have certain hemodynamic limitations even when functioning “normally”. These devices represent a type of iatrogenic valvular heart disease. Prosthetic valves are prone to several complications such as valvular thrombosis or regurgitation and infective endocarditis which may further compromise valvular function.

Drugs and physical agents

Chronic use of ergotamine products. Patients who have been treated with ergotamine products for migraine headaches may develop valvular heart disease. Mitral regurgitation in combination with mitral stenosis and/or tricuspid regurgitation with stenosis are the most common valvular abnormalities. The lesions are characterized by irregular proliferation of myofibroblasts within an avascular myxoid or collagenous matrix that encases the leaflets and chordal structures. The fibrotic endocardial process forms proliferative mounds reminiscent of those seen in patients with carcinoid valve disease^{1,2,10}. The mechanism by which ergot alkaloid agents induce valvular disease is unclear. The similarities in chemical structure of serotonin, methysergide and ergotamine and the similarities in the valvular abnormalities produced by these chemicals, strongly suggest a common pathophysiological mechanism for ergot alkaloid-associated valve disease and carcinoid valve. For management of this disorder, discontinuation of the drug is an important measure. Cessation of therapy may be associated with an improvement of valvular lesions. Otherwise, the patients have to be managed conventionally, with appropriate medical and surgical interventions as they apply for the treatment of valvular heart disease of other etiologies.

Appetite suppressant drugs and cardiac valve disease. Reports on the efficacy of the combination of fenfluramine and phentermine in the treatment of obesity appeared in 1992. In 1997, a series of 24 patients who had taken the fenfluramine-phentermine combination for an average of 11 months and valvular regurgitation have been reported². Histologic findings were similar to those reported in serotonin related valvular abnormalities. For this reason, the drugs were withdrawn from the market. Other reports later confirmed the association between the cardiac valve disease and these drugs, although the

magnitude of risk was much lower^{2,11}. The probability of developing valvular heart disease was related to time of exposure to therapy and the amount of drug used. All these drugs with exception of phentermine act via the serotonin pathways. The main difference between what happened with the appetite suppressant drugs and the ergot alkaloid drugs was that in the former the valve damage occurred after only a few months of treatment, in the latter valvular abnormalities occurred only with very long periods of therapy.

Radiation induced valvular disease. Although the heart is generally resistant to the effects of ionizing radiation, damage to the pericardium, myocardium, endocardium, microvasculature and epicardial coronary arteries may occur after significant exposure to radiation. When the endocardium is involved, fibrosis and fibroelastosis may distort the atrioventricular valves and result in mitral and tricuspid regurgitation. The more common clinical expression of radiation valvular heart disease occurs months or years after the exposure.

Trauma induced valvular disease. Aortic regurgitation is the most common clinically recognized valvular lesion as a result of chest trauma. This is secondary to aortic valve rupture or cusp perforation. In autopsy studies, rupture of an atrioventricular valve has been reported to be more common than rupture of the aortic valve. Rupture of the atrioventricular valves, however, is usually associated with other significant cardiac injuries and frequently with cardiac rupture. This explains why rupture of the aortic valve has been reported more frequently in clinical series. Nevertheless, isolated mitral valve rupture may also occur after chest trauma. Complete rupture of a left sided papillary muscle results in massive mitral regurgitation and death. Survival may occur with lesser degrees of mitral regurgitation resulting from rupture of the head of a papillary muscle, rupture of chordae tendineae, or rarely, a tear in one of the leaflets. Variable degrees of mitral regurgitation can also result from simple contusion of the papillary muscles. Tricuspid valve regurgitation can result from rupture of a papillary muscle, rupture of chordae tendineae, a torn leaflet, or simple contusion of the papillary muscle.

Etiology of common valvular abnormalities in clinical practice

Many medical disorders may cause or may be associated with valvular heart disease. The most

Table 2. Common Cause of Valvular Disease and Multivalvular Involvement.*Mitral Regurgitation*

Ischemic heart disease
 Dilated cardiomyopathy
 Floppy mitral valve / mitral valve prolapse
 Mitral annular calcification

Mitral Stenosis

Rheumatic

Aortic Regurgitation

Bicuspid aortic valve
 Floppy aortic valve

Aortic Stenosis

Bicuspid aortic valve
 Calcific senile

Tricuspid Regurgitation

Dilated cardiomyopathy with right ventricular enlargement and/or dysfunction
 Ischemic cardiomyopathy
 Floppy tricuspid valve/tricuspid valve prolapse
 Infective endocarditis

Combined Mitral and Tricuspid Regurgitation

Dilated cardiomyopathy
 Ischemic cardiomyopathy
 Heritable connective tissue disorders

Mitral Stenosis and Aortic Regurgitation

Rheumatic

common causes of valvular disease and multivalvular diseases are shown in table 2. Patients with valvular heart disease and multivalvular involvement require consideration of the etiologies of the valvular involvement. For example, cardiomyopathy is a common etiology in patients with combined mitral and tricuspid regurgitation. Heritable connective tissue disorders also cause mitral and tricuspid regurgitation as well as aortic and mitral valvular regurgitation. When mitral stenosis is one of the lesions in patients with multivalvular disease, rheumatic heart disease is the most likely cause¹.

Recent advances in imaging techniques and hemodynamic studies allow clinicians to better define

valvular structure and the pathophysiology of valvular heart disease in clinical practice. When combined with careful clinical history taking and thoughtful clinical examination, the correlation of laboratory studies with the clinical picture should permit definition of the etiology of valvular heart disease in the majority of the patients (Figure 1).

References

1. Boudoulas H, Vavuranakis M, Wooley CF: Valvular heart disease: The influence of changing etiology on nosology. *J Heart Valv Dis* 1994; 3: 516-526.
2. Soler-Soler J: Valve Disease. Worldwide perspective of valve disease. *Heart* 2000; 83: 721-725.
3. Boudoulas H, Gravanis MB: Valvular heart disease. *Cardiovascular Disorders*, Gravanis MB (ed), Mosby 1993; 64-117.
4. Boudoulas H, Wooley CF: *Mitral Valve: Floppy Mitral Valve, Mitral Valve Prolapse, Mitral Valvular Regurgitation*. Futura Publishing Company, Inc, Second edition, 2000.
5. Dale JB: Group A streptococcal vaccines. *Infect Dis Clin North Am* 1999; 13: 227-243.
6. Libman E, Sacks B: A hitherto undescribed form of valvular and mural endocarditis. *Arch Intern Med* 1924; 33: 701-737.
7. Asherson RA, Cervera R: Antiphospholipid antibodies and the heart. Lessons and pitfalls for the cardiologist. *Circulation* 1991; 84: 920-923.
8. Lopez JA, Ross RS, Fishbein MC, Seigel RJ: Non-bacterial thrombotic endocarditis: A review. *Am Heart J* 1987; 113: 773.
9. Boudoulas H: Involvement of other structures of the heart and other disease processes induced by renal failure. *Cardiorenal disorders and diseases*, Leier CV, Boudoulas H (eds) Mount Kisco, NY: Futura Publishing Co., Inc 1991 Second Edition, 1992, pp 57-81 and 193-225.
10. Ross EM, Roberts WC: The carcinoid syndrome: Comparison of 21 necropsy subjects with carcinoid heart disease to 15 necropsy subjects without carcinoid heart disease. *Am J Med* 1985; 70: 339.
11. Weissman NJ, Tighe JF, Gottdiener JS, et al: Sustained-Release Dexfenfluramine Study Group. An assessment of heart-valve abnormalities in obese patients taking dexfenfluramine, sustained-release dexfenfluramine or placebo. *N Engl J Med* 1998; 339: 725-732.