

European guidelines for quality assurance in cervical cancer screening: recommendations for cervical cytology terminology

A. Herbert*, C. Bergeron[†], H. Wiener[‡], U. Schenck[§], P. Klinkhamer[¶], J. Bulten** and M. Arbyn^{††}

*Guy's & St Thomas' Hospital NHS Foundation Trust, London, UK, [†]Laboratoire Pasteur Cerba, Cergy Pontoise, France, [‡]Institute of Clinical Pathology, University Vienna, Vienna, Austria, [§]Institute of Pathology, Technical University Munich, Munich, Germany, [¶]PAMM, Eindhoven, The Netherlands, **Institute of Pathology, Radboud University Nijmegen Medical Centre, Nijmegen, The Netherlands and ^{††}Unit of Cancer Epidemiology, Scientific Institute of Public Health, Brussels, Belgium

Accepted for publication 20 April 2007

A. Herbert, C. Bergeron, H. Wiener, U. Schenck, P. Klinkhamer, J. Bulten and M. Arbyn

European guidelines for quality assurance in cervical cancer screening: recommendations for cervical cytology terminology

There are many different systems of cytology classification used in the member states of the European Union (EU) and many different languages. The following short annexe to Chapter 3 of the *European Guidelines for Quality Assurance in Cervical Cancer Screening* provides a framework that will allow different terminologies and languages to be translated into standard terminology based on the Bethesda system (TBS) for cytology while retaining the cervical intraepithelial neoplasia (CIN) classification for histology. This approach has followed extensive consultation with representatives of many countries and professional groups as well as a discussion forum published in *Cytopathology* (2005;16:113).

This article will describe the reporting of specimen adequacy, which is dealt with in more detail elsewhere in Chapter 3 of the guidelines, the optional general categorization recommended in TBS, the interpretation/cytology result and other comments that may be made on reports such as concurrent human papillomavirus testing and the use of automation review and recommendations for management. The main categories in TBS will be described in the context of CIN, dyskaryosis and dysplasia terminologies so that all may be translated into the same framework. These guidelines should allow European countries to adapt their terminology in such a way as to make their screening programmes comparable with each other as well as with programmes elsewhere in the world.

Keywords: European guidelines, cervical cancer screening, cervical cytology terminology, sample adequacy, Bethesda system, quality assurance

Introduction

Cytology reports should include a text report but this should be concise. All reports should include a classification broadly corresponding to the categories described below (and also shown diagrammatically in Figure 1. The Bethesda system (TBS) was first

proposed in 1988 as a model for the interpretation of cervical cell cytology.¹ The aim was to unify the terminology (Table 1) and thereby improve patient management. Following several years of testing, the system was evaluated in 1991 during a second workshop² and was modified again after an international consensus conference in 2001, which forms the basis for the system currently in use throughout much of the world and is summarized in Table 2.³ The following European guidelines strongly recommend that all terminology systems should be translatable into the categories used by TBS.⁴

Correspondence:

A. Herbert, Guy's & St Thomas' Hospital NHS Foundation Trust, London, UK.
Tel.: +44(0)20 7188 2926; Fax: +44(0)20 7401 3661;
E-mail: amanda.herbert@kcl.ac.uk

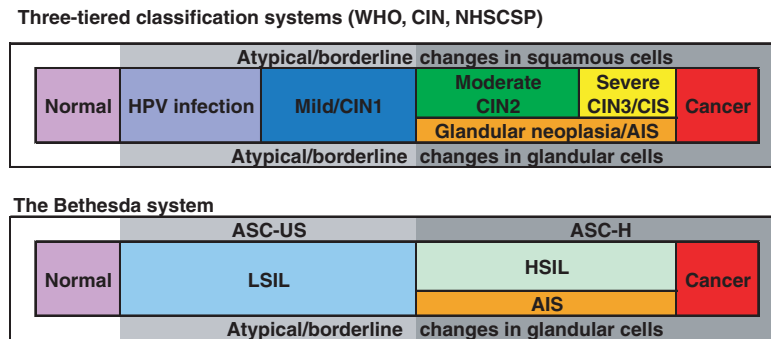


Figure 1. Conceptual categorization of cytological findings in a Pap smear of the uterine cervix.^{11,12}

Table 1. Conversion table for different cytological classification systems

Papanicolaou	WHO	CIN ¹⁰	TBS 1991 ²	TBS 2001 ⁵
I	Normal			Negative for epithelial abnormality
II	Atypia		Infection, reactive repair ASCUS	ASC-US ASC-H
III	Atypical glandular cells Mild dysplasia	Condyloma CIN I	AGUS LSIL	Atypical glandular cells LSIL
IV	Moderate dysplasia Severe dysplasia CIS	CIN II CIN III	HSIL	HSIL
V	AIS Invasive carcinoma	CGIN	AGUS	AIS

Specimen adequacy

It is inevitable that some cytological specimens will be unsatisfactory for evaluation either because there are too few cells or the cells are poorly fixed or obscured by blood or exudate. The assessment of adequacy is subjective and the cytologist should provide in the text report their reason for that assessment.

Laboratories are recommended to use TBS criteria for adequacy as a minimum, requiring at least 8000–12 000 squamous cells on a conventional smear and at least 5000 cells on a liquid-based preparation. Comments may be given on the report about inflammatory exudate and transformation zone sampling on conventional smears and liquid-based preparations so that nurses and doctors taking the samples may make clinical decisions as to whether

the test should be repeated.⁵ In the UK, tests are not repeated unless recommended by the laboratory, and local protocols may be more stringent than those recommended by TBS.⁶

The European guidelines and TBS state that a judgement on sample quality must be given as to whether the sample is regarded as satisfactory or not.^{5,7} Evidence of transformation zone sampling should be recorded, although this is not a requirement on its own for a satisfactory sample.^{4,5,6}

General categorization

This is an optional category in TBS, which allows for statistical analysis of principal categories: negative for epithelial lesion or malignancy, epithelial abnormalities and other (see Table 2).

Table 2. The 2001 Bethesda system: terminology for reporting the results of cervical cytology³

Specimen adequacy
Satisfactory for evaluation (note presence/absence of endocervical/transformation zone component)
Unsatisfactory for evaluation . . . (specify reason)
Specimen rejected/not processed (specify reason)
Specimen processed and examined, but unsatisfactory for evaluation of epithelial abnormality because of (specify reason)
General categorization (optional)
Negative for intraepithelial lesion or malignancy
Epithelial cell abnormality
Other
Interpretation/result
Negative for intraepithelial lesion or malignancy
Organisms
<i>Trichomonas vaginalis</i>
Fungal organisms morphologically consistent with <i>Candida</i> species
Shift in flora suggestive of bacterial vaginosis
Bacteria morphologically consistent with <i>Actinomyces</i> species
Cellular changes consistent with herpes simplex virus
Other non-neoplastic findings (optional to report; list not comprehensive)
Reactive cellular changes associated with inflammation (includes typical repair)
Radiation
Intrauterine contraceptive device
Glandular cells status posthysterectomy
Atrophy
Epithelial cell abnormalities
Squamous cell
Atypical squamous cells (ASC) of undetermined significance (ASC-US)
Atypical squamous cells cannot exclude HSIL (ASC-H)
Low-grade squamous intraepithelial lesion (LSIL), encompassing: human papillomavirus/mild dysplasia/cervical intraepithelial neoplasia (CIN) 1
High-grade squamous intraepithelial lesion (HSIL), encompassing: moderate and severe dysplasia, carcinoma <i>in situ</i> ; CIN 2 and CIN 3
Squamous cell carcinoma
Glandular cell
Atypical glandular cells (AGC) (specify endocervical, endometrial, or not otherwise specified)
Atypical glandular cells, favour neoplastic (specify endocervical or not otherwise specified)
Endocervical adenocarcinoma <i>in situ</i> (AIS)
Adenocarcinoma
Other (list not comprehensive)
Endometrial cells in a woman 40 years of age
Automated review and ancillary testing (include as appropriate)
Educational notes and suggestions (optional)

Interpretation/result

Negative for intraepithelial lesion or malignancy

The category 'negative for intraepithelial lesion or malignancy' in TBS regroups the categories 'normal and benign alterations'. Numerous variants of benign cellular findings have been described and need not be reported if they do not imply an increased risk of

neoplasia: these include hormonal patterns (postpartum or atrophic), repair changes, microglandular hyperplasia, tubo-endometrioid metaplasia, tubal metaplasia, sampling of the lower uterine segment, irradiation changes or alterations resulting from inflammation or the presence of an intrauterine contraceptive device (IUD) and benign glandular cells occasionally seen in posthysterectomy specimens.⁸ As long as these changes are recognized as such they

need not be reported. The presence of certain organisms, such as *Trichomonas vaginalis*, *Candida*, actinomycetes-like organisms and herpes virus multinucleated cells may be reported as they have potential clinical relevance.

Cells indicating squamous intraepithelial lesion/neoplasia/dysplasia

There are many linguistic and terminological differences in the systems used to describe the spectrum of precancerous cell change, still widely described as mild, moderate and severe dysplasia/carcinoma *in situ*,⁹ which broadly correlates with cervical intraepithelial neoplasia (CIN) grades 1–3.¹⁰ In cytology, the dysplasia/CIN spectrum has been simplified in TBS as low-grade and high-grade squamous intraepithelial lesion (LSIL and HSIL).⁵ The National Health Service Cervical Screening Programme (NHSCSP) continues to use the descriptive term ‘dyskaryosis’ for cytology, which broadly correlates with CIN on histology⁶ but the British Society for Clinical Cytology (BSCC) has proposed to move to a two-tier system of low-grade and high-grade dyskaryosis equivalent to LSIL and HSIL.^{11,12} Numerical systems (Papanicolaou I–V) should not be used: textual systems such as dyskaryosis and SIL are nowadays recommended in preference. CIN should be used for histology rather than cytology.

It is sometimes difficult for countries to change their terminology (and there will always be linguistic differences) but it is strongly recommended that all local cytology terminologies should be translatable into the TBS as the latter is used so widely in the world today. The old WHO classification recognizes three grades of dysplasia (mild, moderate and severe) and carcinoma *in situ*. For all practical purposes severe dysplasia may be merged with carcinoma *in situ*. In TBS, which is now used by WHO, LSIL equates to human papillomavirus (HPV)/mild dysplasia/CIN1 and HSIL to moderate and severe dysplasia, carcinoma *in situ*/CIN2 and CIN3 (Table 2).¹³

LSIL, mild dysplasia, cellular changes suggesting CIN1

LSIL includes changes known to be associated with infection by HPV, most obviously manifest by koilocytosis. LSIL cannot be distinguished from transient HPV infection by cytology alone, which is the rationale for surveillance to identify the minority that progress to high-grade lesions. LSIL in TBS and mild

dyskaryosis in NHSCSP correspond to the histopathological diagnoses mild dysplasia and CIN1.⁶

HSIL, cellular changes suggesting CIN2/moderate dysplasia

CIN2 is an intermediate grade, in which the changes fall short of CIN3/carcinoma *in situ*. CIN2 is equivalent to moderate dysplasia and moderate dyskaryosis and is included in HSIL. Cytological reports of HSIL or high-grade dyskaryosis may include a text report favouring CIN2 or moderate dyskaryosis. Most terminological systems already link moderate with severe dysplasia as high-grade lesions and this is strongly recommended. Whether or not clinical management of moderate dysplasia is different from severe dysplasia, moderate dysplasia should be classified as high grade rather than low grade.

Some systems (such as the Munich system) link moderate with mild dysplasia, which is the only significant difference among European terminologies. A European panel discussion on this subject reported in *Cytopathology* came to the conclusion that those systems ‘linking moderate dysplasia with mild rather than severe dysplasia would need to define moderate dysplasia as such, if their results were to be translatable, which would be preferable to their using a different definition of low-grade and high-grade lesions’.¹⁴

HSIL, cellular changes suggesting CIN3/severe dysplasia/carcinoma in situ

HSIL, suggesting CIN3, is the cytological equivalent of severe dysplasia and carcinoma *in situ*. HSIL includes moderate and severe dyskaryosis but the text report may favour CIN3 or severe dyskaryosis.

Invasive squamous cell carcinoma

The diagnosis of invasive cancer requires a histological biopsy but there are cytological changes that suggest the possibility of invasion. Most systems, including TBS, recognize the importance of reporting such changes and define a separate category for the commonest type of invasive cancer (squamous cell carcinoma) or for changes in which the cell type of invasive cancer is not evident.

Atypical/borderline squamous cells

In practice, with all terminologies, atypical/borderline changes are frequently reported, although the category

should be reserved for cases in which there is genuine doubt as to whether the changes are reactive or neoplastic. Most of these changes border on LSIL/mild dysplasia¹⁵ and are described in TBS as atypical squamous cells of undetermined significance (ASC-US). It has been decided to keep this category, which has been shown to be associated with approximately 10% of CIN2–3 on biopsies.^{16,17} Not more than 3% of the smears should have this designation¹⁶ but rates will depend on local rates for LSIL and HSIL. When recognized as such, reactive changes associated with inflammation come out of this group and should now be included among normal smears. These recommendations are similar to those for 'borderline, not otherwise specified' in the proposed BSCC classification.¹¹

Atypical squamous cells – high-grade not excluded (ASC-H)

ASC-H is a subgroup of atypical/borderline changes in which the changes are suspicious of HSIL and occasionally cancer. It is sometimes used when the abnormal cells are so few that the diagnosis is uncertain. Most systems recommend that these cases, which should be unusual, should be identified in text reports or as a separate category. The BSCC proposes to call this category 'borderline, high-grade not excluded'.¹¹ This term should apply to no more than 5–10% of atypical squamous cell alterations and are often associated with CIN2-3 confirmed on colposcopically directed biopsy.^{18–20} The use of this term should be monitored and controlled in order to avoid its use for recognizable HSIL/high-grade dyskaryosis.

Glandular cell abnormalities

Glandular lesions are less common than their squamous cell counterparts but form an important group as they are more difficult to detect by cytological screening and more difficult to recognize at colposcopy.

Endocervical adenocarcinoma in situ AIS is defined as a recognizable sub-type in many terminologies including TBS. It corresponds to high-grade cervical glandular intraepithelial neoplasia (CGIN) but as there are no clear criteria for diagnosing low-grade CGIN on cytology, CGIN is usually reported and managed as one entity.

Adenocarcinoma As with squamous cell carcinoma, the diagnosis of invasion requires a histological

biopsy. In some instances there are cytological changes suggesting invasive adenocarcinoma. In the UK, the difficulty of distinguishing *in situ* from invasive adenocarcinoma is recognized and these entities are included as '?glandular neoplasia'.⁶ It may be possible to distinguish cytological changes suggesting endometrial or extra-uterine from endocervical adenocarcinoma and this should be made clear in the text report.

Atypical/borderline changes in glandular cells As with squamous cell changes, there are some instances when equivocal glandular cell changes are reported on cytology, although the relative rarity of glandular neoplasia should make this unusual. TBS identifies a separate group of 'atypical glandular cells' and the BSCC also proposes to separate 'borderline changes in glandular cells' from the far commoner borderline changes in squamous cells. Glandular cell changes in cervical cytology are diverse and, where possible, text reports should distinguish changes likely to be endometrial rather than endocervical. Occasionally, such as in the presence of an IUD, atypical/borderline changes in glandular cells may be considered likely to be benign and an early repeat may be recommended for re-assurance. Such changes should be investigated if they persist on a second occasion. Furthermore, if the changes on any occasion are thought to favour glandular neoplasia, but are insufficient for a firm diagnosis, the category 'atypical glandular cells suggesting neoplasia' has been proposed by TBS. This category is badly defined on morphological grounds^{21–23} but as the observation of atypical glandular cells is often associated with underlying neoplasia or cancer, a recommendation for investigation is warranted.

Other cellular changes

Cervical cytology is not a good diagnostic assay for endometrial cancer. Morphologically benign endometrial cells were not mentioned in the 1988 Bethesda system, except referring to menopausal women. The category 'other' is now proposed to classify smears without morphological abnormalities but which have apparently benign endometrial cells, in women over 40 years. The presence of these cells indicates an increased risk for endometrial cancer, and therefore requires endometrial exploration.^{24,25} Benign glandular cells may be found after total hysterectomy and need not be reported.⁸

Additional remarks

Automated review The automated system for reading slides should be mentioned in the report and the printout from the machine attached. If the slide was rechecked by microscopy, this should also be mentioned separately in the report.

Ancillary testing It is considered useful to propose recommendations for additional tests, which may be complementary to cytology. High-risk HPV DNA detection is a prime example of an additional test that can be complementary to cytology for a diagnosis of ASC-US.

Educational notes and suggestions Recommendations for patient management should be clear and concise. They must be given as 'suggestions' and in accordance with national and international good clinical practice.

Summary

If the principles of this classification are used, there should be more similarities than differences between terminologies used across Europe and it should be possible for any system to be translatable into TBS. Throughout these guidelines, the CIN classification is reserved to describe histological lesions, whereas TBS is used for cytological abnormalities.

No European equivalent of TBS can be proposed as the only unique classification system for the EU but all systems should at least be translatable into TBS. Cytological classification systems may continue to use three-tier systems within the framework of TBS. Nevertheless, each member state should define a nationally agreed reporting scheme. A three-tier system distinguishing (i) mild dysplasia or dyskaryosis (including HPV associated lesions), (ii) moderate dysplasia or dyskaryosis and (iii) severe dysplasia or dyskaryosis is perfectly acceptable as long as moderate and severe are linked as high grade. A two-tier system lumping mild and moderate dysplasia into one category is not recommended. The fact that, in certain countries, women with a first result of moderate dysplasia are followed up conservatively is not a sufficient reason to link mild with moderate.

Acknowledgments

Financial support of the European Communities through the European Cervical Cancer Screening

Network and the European Cancer Network is gratefully acknowledged.

Disclaimer

The views expressed in the Article are those of the authors and do not necessarily reflect the official position of the European Commission.

References

1. National Cancer Institute. The 1988 Bethesda system for reporting cervical/vaginal cytologic diagnoses. *JAMA* 1989;**262**:931–4.
2. The revised Bethesda system for reporting cervical/vaginal cytological diagnoses. Report of the 1991 Bethesda Workshop. *Acta Cytol* 1992;**36**: 273–6.
3. Solomon D, Davey D, Kurman R *et al*. The 2001 Bethesda system: terminology for reporting results of cervical cytology. *JAMA* 2002;**287**:2140–1.
4. European Commission. In: *European Guidelines for Quality Assurance in Cervical Cancer Screening*. Arbyn M, Anttila A, Jordan J, Ronco G, Schenck U, Segnan N, Wiener H (eds). Luxembourg: Office of Official Publ EU; 2007 (in press).
5. Solomon D, Nayar R. *The Bethesda System for Reporting Cervical Cytology: Definitions, Criteria and Explanatory Notes*, 2nd edn. New York: Springer; 2004.
6. National Health Service Cervical Screening Programme. *Achievable Standards, Benchmarks for Reporting, and Criteria for Evaluating Cervical Cytopathology*. Second edition including revised performance indicators. NHSCSP publication 1. Sheffield: NHS Cancer Screening Programmes; 2000: pp. 1–36.
7. Wiener HG, Klinkhamer K, Schenck U *et al*. European guidelines for quality assurance in cervical cancer screening. *Cytopathology* 2007;**18**: 67–78.
8. Tambouret R, Pitman M, Bell DA. Benign glandular cells in posthysterectomy vaginal smears. *Acta Cytol* 1998;**42**:1403–8.
9. Riotton G, Christopherson WM, Lunt R. *Cytology of the Female Genital Tract*. Geneva: World Health Organization; 1973.
10. Richart RM. Cervical intraepithelial neoplasia. *Pathol Annu* 1973;**8**:301–23.
11. Herbert A. BSCC terminology for cervical cytology: two or three tiers? Why not five, seven or even 14? *Cytopathology* 2004;**15**:245–51.
12. Herbert A. Terms without borders: an international approach to terminology. *Diagn Cytopathol* 2005;**33**: 352–5.
13. World Health Organization. *Pathology and Genetics of Tumours of the Breast and Female Genital Organs*. Lyon: IARC Press; 2003.

14. Kocjan G, Priollet BC, Desai M *et al.* BSCC, Bethesda or other? Terminology in cervical cytology: European panel discussion. *Cytopathology* 2005;**16**:113–9.
15. Borderline Nuclear Changes National Slide Exchange Study Group. Quality Assurance Reference Centre for the Trent NHSCSP. Do borderline nuclear changes in gynaecological cytology constitute a reliable reporting category? *Cytopathology* 2002;**13**:220–31.
16. Davey DD, Woodhouse S, Styer P, Stastny J, Mody D. Atypical epithelial cells and specimen adequacy: current laboratory practices of participants in the College of American Pathologists Interlaboratory Comparison Program in Cervicovaginal Cytology. *Arch Pathol Lab Med* 2000;**124**:203–11.
17. Arbyn M, Buntinx F, Van Ranst M, Paraskevaidis E, Martin-Hirsch P, Dillner J. Virologic versus cytologic triage of women with equivocal Pap smears: a meta-analysis of the accuracy to detect high-grade intraepithelial neoplasia. *J Natl Cancer Inst* 2004;**96**:280–93.
18. Sherman ME, Tabbara SO, Scott DR *et al.* “ASCUS, rule out HSIL”: cytologic features, histologic correlates, and human papillomavirus detection. *Mod Pathol* 1999;**12**:335–42.
19. Quddus MR, Sung CJ, Steinhoff MM, Lauchlan SC, Singer DB, Hutchinson ML. Atypical squamous metaplastic cells: reproducibility, outcome, and diagnostic features on ThinPrep Pap test. *Cancer* 2001;**93**:16–22.
20. Sherman ME, Solomon D, Schiffman MA. ASCUS LSIL Triage Study Group. Qualification of ASCUS. A comparison of equivocal LSIL and equivocal HSIL cervical cytology in the ASCUS LSIL Triage study. *Am J Clin Pathol* 2001;**116**:386–94.
21. Lee KR, Manna EA, Jones MA. Comparative cytologic features of adenocarcinoma in situ of the uterine cervix. *Acta Cytol* 1991;**35**:117–26.
22. Biscotti CV, Gero MA, Toddy SM, Fischler DF, Easley KA. Endocervical adenocarcinoma in situ: an analysis of cellular features. *Diagn Cytopathol* 1997;**17**:326–32.
23. Soofer SB, Sidawy MK. Atypical glandular cells of undetermined significance: clinically significant lesions and means of patient follow-up. *Cancer* 2000;**90**:207–14.
24. Montz FJ. Significance of “normal” endometrial cells in cervical cytology from asymptomatic postmenopausal women receiving hormone replacement therapy. *Gynecol Oncol* 2001;**81**:33–9.
25. Fadare O, Ghofrani M, Chacho MS, Parkash V. The significance of benign endometrial cells in cervicovaginal smears. *Adv Anat Pathol* 2005;**12**:274–87.