

European Society of Endocrinology Clinical Practice Guidelines on the management of adrenocortical carcinoma in adults, in collaboration with the European Network for the Study of Adrenal Tumors

Martin Fassnacht^{1,2}, Olaf M Dekkers^{3,4,5}, Tobias Else⁶, Eric Baudin^{7,8}, Alfredo Berruti⁹, Ronald R de Krijger^{10,11,12,13}, Harm R Haak^{14,15,16}, Radu Mihai¹⁷, Guillaume Assie^{18,19} and Massimo Terzolo²⁰

¹Division of Endocrinology and Diabetes, Department of Internal Medicine I, University Hospital, ²Comprehensive Cancer Center Mainfranken, University of Würzburg, Würzburg, Germany, ³Department of Clinical Epidemiology, ⁴Department of Clinical Endocrinology and Metabolism, Leiden University Medical Centre, Leiden, the Netherlands, ⁵Department of Clinical Epidemiology, Aarhus University Hospital, Aarhus, Denmark, ⁶Division of Metabolism, Endocrinology and Diabetes, Department of Internal Medicine, University of Michigan, Ann Arbor, Michigan, USA, ⁷Endocrine Oncology and Nuclear Medicine, Institut Gustave Roussy, Villejuif, France, ⁸INSERM UMR 1185, Faculté de Médecine, Le Kremlin-Bicêtre, Université Paris Sud, Paris, France, ⁹Department of Medical and Surgical Specialties, Radiological Sciences, and Public Health, Medical Oncology, University of Brescia at ASST Spedali Civili, Brescia, Italy, ¹⁰Department of Pathology, Erasmus MC University Medical Center, Rotterdam, the Netherlands, ¹¹Department of Pathology, University Medical Center Utrecht, Utrecht, the Netherlands, ¹²Department of Pathology, Reinier de Graaf Hospital, Delft, the Netherlands, ¹³Princess Maxima Center for Pediatric Oncology, Utrecht, the Netherlands, ¹⁴Department of Internal Medicine, Máxima Medical Centre, Eindhoven/Veldhoven, the Netherlands, ¹⁵Maastricht University, CAPHRI School for Public Health and Primary Care, Ageing and Long-Term Care, Maastricht, the Netherlands, ¹⁶Division of General Internal Medicine, Department of Internal Medicine, Maastricht University Medical Centre+, Maastricht, the Netherlands, ¹⁷Department of Endocrine Surgery, Churchill Cancer Centre, Oxford University Hospitals NHS Foundation Trust, Oxford, UK, ¹⁸Department of Endocrinology, Reference Center for Rare Adrenal Diseases, Reference Center for Rare Adrenal Cancers, Hôpital Cochin, Assistance Publique Hôpitaux de Paris, Paris, France, ¹⁹Institut Cochin, Institut National de la Santé et de la Recherche Médicale U1016, Centre National de la Recherche Scientifique UMR8104, Université Paris Descartes, Sorbonne Paris Cité, Paris, France, and ²⁰Department of Clinical and Biological Sciences, Internal Medicine, San Luigi Hospital, University of Turin, Orbassano, Italy

Correspondence should be addressed to M Fassnacht or M Terzolo
Email
fassnacht_m@ukw.de or terzolo@usa.net

Abstract

Adrenocortical carcinoma (ACC) is a rare and in most cases steroid hormone-producing tumor with variable prognosis. The purpose of these guidelines is to provide clinicians with best possible evidence-based recommendations for clinical management of patients with ACC based on the GRADE (Grading of Recommendations Assessment, Development and Evaluation) system. We predefined four main clinical questions, which we judged as particularly important for the management of ACC patients and performed systematic literature searches: (A) What is needed to diagnose an ACC by histopathology? (B) Which are the best prognostic markers in ACC? (C) Is adjuvant therapy able to prevent recurrent disease or reduce mortality after radical resection? (D) What is the best treatment option for macroscopically incompletely resected, recurrent or metastatic disease? Other relevant questions were discussed within the group. Selected Recommendations: (i) We recommend that all patients with suspected and proven ACC are discussed in a multidisciplinary expert team meeting. (ii) We recommend that every patient with (suspected) ACC should undergo careful clinical assessment, detailed endocrine work-up to identify autonomous hormone excess and adrenal-focused imaging. (iii) We recommend that adrenal surgery for (suspected) ACC should be performed only by surgeons experienced in adrenal and oncological surgery aiming at a complete *en bloc* resection (including resection of oligo-metastatic disease). (iv) We suggest that all suspected ACC should be reviewed by an expert adrenal pathologist using the Weiss score and providing Ki67 index. (v) We suggest adjuvant mitotane treatment in patients after radical surgery that have a perceived high risk of recurrence (ENSAT stage III, or R1 resection, or Ki67 >10%). (vi) For advanced ACC

not amenable to complete surgical resection, local therapeutic measures (e.g. radiation therapy, radiofrequency ablation, chemoembolization) are of particular value. However, we suggest against the routine use of adrenal surgery in case of widespread metastatic disease. In these patients, we recommend either mitotane monotherapy or mitotane, etoposide, doxorubicin and cisplatin depending on prognostic parameters. In selected patients with a good response, surgery may be subsequently considered. (vii) In patients with recurrent disease and a disease-free interval of at least 12 months, in whom a complete resection/ablation seems feasible, we recommend surgery or alternatively other local therapies. Furthermore, we offer detailed recommendations about the management of mitotane treatment and other supportive therapies. Finally, we suggest directions for future research.

European Journal of
Endocrinology
(2018) 179, G1–G46

1. Summary of recommendations

1.1. Overarching recommendations

R.1.1. We recommend that all patients with suspected and proven adrenocortical carcinoma (ACC) are discussed in a multidisciplinary expert team meeting (including health care providers experienced in care of adrenal tumors, including at least the following disciplines: endocrinology, oncology, pathology, radiology, surgery) at least at the time of initial diagnosis. In addition, this team should have access to adrenal-specific expertise in interventional radiology, radiation therapy, nuclear medicine and genetics as well as to palliative care teams.

R.1.2. We suggest that at any time of decision making regarding therapy, enrollment in a clinical trial (if available) should be considered. Furthermore, we encourage patients' participation in registries and the collection of biological material as part of structured research programs aimed at defining biomarkers of diagnosis, prognosis and treatment response.

1.2. Diagnostic procedures in suspected ACC

R.2.1. The diagnosis of ACC is not always obvious. We recommend establishing as soon as possible whether an adrenal mass is malignant, using all required diagnostic tools in a timely fashion.

R.2.2. We recommend that every patient with (suspected) ACC should undergo careful assessment including case history, clinical examination for symptoms and signs of adrenal hormone excess.

R.2.3. We recommend that all patients with suspected ACC undergo a detailed hormonal work-up to identify potential autonomous excess of glucocorticoids, sex hormones, mineralocorticoids and adrenocortical steroid

hormone precursors. In addition, a pheochromocytoma must be excluded.

R.2.4. We recommend adrenal-focused imaging in all patients with suspected ACC.

R.2.5. We recommend in any case where there is high suspicion for ACC performing a chest CT, in addition to an abdominal-pelvic cross-sectional imaging (CT or MRI), because the results might influence therapeutic decision making.

R.2.6. We suggest performing additional imaging (e.g. bone and brain imaging) only in case of clinical suspicion of metastatic lesions.

R.2.7. We recommend against the use of an adrenal biopsy in the diagnostic work-up of patients with suspected ACC unless there is evidence of metastatic disease that precludes surgery and histopathologic proof is required to inform oncological management.

1.3. Surgery for suspected localized ACC

R.3.1. We recommend that adrenal surgery for suspected/confirmed ACC should be performed only by surgeons experienced in adrenal and oncological surgery.

R.3.2. We recommend complete *en bloc* resection of all adrenal tumors suspected to be ACC including the peritumoral/periadrenal retroperitoneal fat. We recommend against enucleation and partial adrenal resection for suspected ACC. If adjacent organs are suspected to be invaded, we recommend *en bloc* resection. However, we suggest against the routine resection of the ipsilateral kidney in the absence of direct renal invasion.

R.3.3. Open surgery is the standard surgical approach for confirmed or highly suspected ACC. Therefore, we recommend open surgery for all tumors with radiological

findings suspicious of malignancy and evidence for local invasion. However, for tumors <6 cm without any evidence of local invasion, laparoscopic adrenalectomy (respecting the principles of oncological surgery) is reasonable if the surgeon has sufficient experience in these types of surgery.

R.3.4. We suggest that routine loco-regional lymphadenectomy should be performed with adrenalectomy for highly suspected or proven ACC. It should include (as a minimum) the periadrenal and renal hilum nodes. All suspicious or enlarged lymph nodes identified on preoperative imaging or intraoperatively should be removed.

R.3.5. We recommend that individualized treatment decisions are made in cases of tumors with extension into large vessels based on multidisciplinary surgical team. Such tumors should not be regarded 'unresectable' until reviewed in an expert center.

R.3.6. If the first surgery was suboptimal and macroscopically incomplete (R2 resection), we suggest to discuss repeat surgery in a multidisciplinary expert team.

R.3.7. We recommend perioperative hydrocortisone replacement in all patients with hypercortisolism that undergo surgery for ACC.

1.4. Pathological work-up

R.4.1. We recommend that the diagnosis of ACC should be confirmed by histopathology (+++0).

R.4.2. We suggest that all adrenal tumors, which cannot be readily classified, and all suspected ACC, should be reviewed by an expert adrenal pathologist (++OO).

R.4.3. We suggest the use of immunohistochemistry for steroidogenic factor-1 (SF1) for the distinction of primary adrenocortical tumors and non-adrenocortical tumors (+OOO).

R.4.4. We recommend the use of the Weiss system, based on a combination of nine histological criteria that can be applied on hematoxylin and eosin-stained slides, for the distinction of benign and malignant adrenocortical tumors (++OO).

R.4.5. We recommend the use of Ki67 immunohistochemistry for every resection specimen of an adrenocortical tumor (++OO).

R.4.6. We recommend that the pathology report of a suspected ACC should at least contain the following information: Weiss score (including the exact mitotic count), exact Ki67 index, resection status and pathological tumor stage (indicating invasion or not of the capsule and/or surrounding tissue and organs) and nodal status (+OOO).

1.5. Staging classification and prognostic factors

R.5.1. At initial diagnosis, we recommend using the European Network for the Study of Adrenal Tumours (ENSAT) staging classification (+++O).

R.5.2. At initial diagnosis, we recommend taking the following factors into account when assessing the prognosis and treatment options: tumor stage, resection status, Ki67 index (or mitotic count), autonomous cortisol secretion and the patient's general condition (++OO).

R.5.3. During follow-up, we recommend re-assessing prognosis at each evaluation, to guide treatment strategy (++OO).

1.6. Methods and time interval for imaging and hormonal assessment during follow-up

R.6.1. We recommend following patients with regular cross-sectional imaging of the abdomen, pelvis and chest for disease recurrence or progression.

R.6.2. After complete resection, we suggest radiological imaging every 3 months for 2 years, then every 3–6 months for a further 3 years. The majority of the panel suggests continuation of follow-up imaging beyond 5 years, but surveillance should then be adapted.

R.6.3. For advanced ACC, we recommend surveillance based on prognostic factors, expected treatment efficacy and treatment-related toxicity, as well as the available alternative treatment options.

R.6.4. In all patients, we recommend regular screening for hormone secretion.

1.7. Adjuvant therapy

R.7.1. For adrenal tumors with uncertain malignant potential, we recommend against adjuvant therapy (+OOO).

R.7.2. We suggest adjuvant mitotane treatment in those patients without macroscopic residual tumor after surgery but who have a perceived high risk of recurrence (+OOO). However, we cannot suggest for or against adjuvant therapy for patients at low/moderate risk of recurrence (stage I–II, R0 resection and Ki67 ≤10%) and adjuvant therapy options should be discussed on an individual basis.

R.7.3. Once the decision for mitotane treatment is established, we recommend starting mitotane as soon as clinically possible after surgery (+OOO).

R.7.4. In patients without recurrence who tolerate mitotane in an acceptable manner, we suggest to administer adjuvant mitotane for at least 2 years, but not longer than 5 years (+OOO).

R.7.5. The panel did not come to a definitive consensus on adjuvant radiation therapy. However, we suggest against the routine use of radiation therapy in patients with stage I–II and R0 resection (+OOO). The panel suggests considering radiation in addition to mitotane therapy on an individualized basis therapy in patients with R1 or Rx resection or in stage III.

R.7.6. If adjuvant radiation therapy is administered, we recommend starting treatment as soon as clinically possible after surgery and to deliver radiation therapy at the dose of 50–60Gy to the previous tumor bed in fractionated doses of approximately 2Gy each (+OOO).

R.7.7. The panel did not come to a definitive consensus on adjuvant use of cytotoxic drugs. We suggest against the routine use of cytotoxic drugs in the adjuvant setting. However, the panel suggests considering adjuvant chemotherapy in selected patients with very high risk for recurrence.

1.8. Treatment of recurrent and/or advanced ACC

R.8.1. For patients presenting at time of initial diagnosis with limited intra-abdominal metastases, we suggest surgical therapy if complete resection of all lesions seems feasible (+OOO). In case of limited extra-abdominal lesions, we suggest adrenal tumor resection in conjunction with therapy aiming at long-term tumor control of the other lesions (+OOO). In all patients, we recommend to start mitotane therapy as soon as clinically possible (+OOO).

R.8.2. The panel is convinced that in addition to surgery other local therapeutic measures (e.g. radiation therapy, radiofrequency ablation, cryoablation, microwave ablation, chemoembolization) are of value for therapy of advanced ACC. We suggest individualization of the decision on the method of choice based on the localization of the tumor lesion(s), local expertise, prognostic factors and patient's preference (+OOO).

R.8.3. We suggest against the routine use of adrenal surgery in case of widespread metastatic disease at the time of first diagnosis (+OOO).

R.8.4. In patients with advanced ACC at the time of diagnosis not qualifying for local treatment, we recommend either mitotane monotherapy or mitotane+EDP depending on prognostic parameters (+++O).

R.8.5. In patients with recurrent disease and a disease-free interval of at least 12 months, in whom a complete resection/ablation seems feasible, we recommend surgery or alternatively other local therapies (+OOO).

We recommend starting mitotane as soon as possible after the intervention.

R.8.6. We recommend EDP-M as first-line treatment if the time interval between last surgery/loco-regional therapy and recurrence is less than 6 months (++OO), rather than repeat loco-regional measures.

R.8.7. For all other patients with recurrent disease, an individualized approach is needed.

R.8.8. In patients who progress under mitotane monotherapy, we recommend to add EDP (+++O).

R.8.9. In patients who respond to medical therapy (including achievement of long-term stable disease), we suggest re-considering local measures aiming at long-term tumor control. Such an approach could also be considered in patients attaining a generally good control of the disease, in which a limited number of lesions are progressing.

R.8.10. In patients who progress under EDP-M, we suggest considering additional therapies including clinical trials on an individual basis (+OOO).

R.8.11. The optimal timing of mitotane discontinuation is currently unknown and the panel could not come to a specific recommendation on this issue.

1.9. Special considerations on mitotane

R.9.1. We recommend starting therapy with mitotane in an escalating regimen depending on the performance status of the patient as well as the tolerability in the first weeks.

R.9.2. We recommend monitoring of blood concentration of mitotane. The general aim is to reach a mitotane blood level above 14 mg/L (+OOO).

R.9.3. We recommend glucocorticoid replacement in all patients treated with mitotane (except those with ongoing cortisol excess). We suggest using hydrocortisone/cortisone acetate for this purpose. Due to increased steroid clearance and increase cortisol-binding globulin at least twice the standard replacement dose is usually required.

R.9.4. We recommend regular monitoring of mitotane-induced adverse effects and to treat them appropriately. To increase tolerability of mitotane, we suggest starting supportive therapy ideally before severe toxicity occurs.

R.9.5. We recommend being aware of significant drug interactions of mitotane (e.g. due to strong induction of CYP3A4). All concomitant medication should be checked for CYP3A4 interactions and substituted for an alternative if necessary and available. Other care providers should be advised not to initiate other drug therapies without consultation.

1.10. Other supportive therapies

R.10.1. We recommend medical therapy to control hormone excess in all patients with clinically relevant hormone-producing ACC.

R.10.2. We recommend therapy with anti-resorptive treatment in patients with bone metastasis.

R.10.3. We recommend palliative radiation for symptom palliation in advanced/metastatic ACC patients.

R.10.4. We recommend integrating palliative care into standard oncology care for all patients with advanced ACC.

R.10.5. We suggest counseling for fertility protection in female patients in reproductive age. Fertility counseling should not only be restricted to patients undergoing cytotoxic chemotherapy, but also given to patients who plan to embark on mitotane therapy.

1.11. Genetic counseling

R.11.1. For adults with ACC, we recommend at least a basic clinical genetic evaluation, exploring personal and family history for evidence of a hereditary predisposition syndrome.

R.11.2. The panel does not recommend for or against genetic tumor testing for somatic alterations.

1.12. Pregnancy and ACC

R.12.1. When an adrenal mass suspected to be an ACC is diagnosed during pregnancy, we recommend prompt surgical resection regardless of pregnancy trimester.

R.12.2. Patients should be informed on pregnancy-related concerns specific to the current or past diagnosis of ACC.

R.12.3. We recommend avoiding pregnancy while being on mitotane treatment.

2. ACC – epidemiology, pathogenesis clinical presentation and general prognosis

Epidemiology and pathogenesis

The estimated incidence of adult ACC is between 0.7 and 2.0 per million per year (1, 2). ACC can occur at any age with a peak incidence between 40 and 60 years, and with women being more often affected (55–60%). In adults, the vast majority of ACCs are sporadic. Occasionally, however, they occur as part of hereditary syndromes such as Li-Fraumeni syndrome, Lynch syndrome, multiple endocrine neoplasia (MEN) 1 and familial adenomatous

polyposis (3, 4). In recent years, several multicenter studies have shed light on the pathogenesis of ACC (5, 6, 7, 8), but ‘multi-omic’ studies (9, 10, 11) reveal that only a minority of ACC cases have pathogenic driver mutations. For details on this topic, we refer to recent reviews (12, 13, 14).

Clinical presentation

ACC may present with autonomous adrenal hormone excess or with symptoms caused by an abdominal mass. An increasing number of cases are diagnosed within the group of incidentally discovered adrenal masses (incidentalomas) (\approx 10–15%). However, the likelihood of an adrenal incidentaloma being an ACC is low (15, 16, 17). About 50–60% of patients with ACC have clinical hormone excess. Hypercortisolism (Cushing syndrome) or mixed Cushing and virilizing syndromes are observed in the majority of these patients. Pure androgen excess is less frequent while estrogen or mineralocorticoid excess are very rare (13, 18, 19, 20, 21, 22). Non-specific symptoms from an abdominal mass include abdominal discomfort (nausea, vomiting, abdominal fullness) or back pain. Classical malignancy-associated symptoms such as weight loss, night sweats, fatigue or fever are rarely present (Table 1).

General prognosis

The median overall survival of all ACC patients is about 3–4 years. The prognosis is, however, heterogeneous. Complete surgical resection provides the only means of cure. In addition to radical surgery, disease stage, proliferative activity/tumor grade, and cortisol excess are independent prognostic parameters (see also Sections 4.2 and 5.5). Five-year survival is 60–80% for tumors confined to the adrenal space, 35–50% for locally advanced disease, and much lower in case of metastatic disease with reported percentages ranging from 0% to 28% (19, 21, 25, 26, 27, 28, 29, 30).

3. Methods

3.1. Guideline working group

This guideline was developed by The European Society of Endocrinology (ESE) in collaboration with the ENSAT. The chairs of the working group Martin Fassnacht and Massimo Terzolo as well as the methodological expert Olaf Dekkers were appointed by the ESE Clinical Committee. Tobias

Table 1 Clinical presentation of ACC.#

Autonomous adrenal hormone excess	50–60
Hypercortisolism (Cushing syndrome)*	50–70
Androgen excess (virilization) in female patients*	20–30
Estrogen excess (feminization) in male patients*	5
Mineralocorticoid excess*	2–3
Non-specific symptoms from an abdominal mass	30–40
Incidentally detected by imaging for other purpose	10–15

#Number derived from: (20, 23, 24), and the ENSAT ACC registry; *frequently combined.

Else served as representative of the Endocrine Society, USA, and Radu Mihai as representative of the European Society of Endocrine Surgeons. The other members were suggested by the chairs and approved by the Clinical Committee of ESE. The multidisciplinary team consisted of the following experts: endocrinologists (Guillaume Assie (France), Olaf Dekkers (the Netherlands), Tobias Else (USA), Martin Fassnacht (Germany), Harm Haak (the Netherlands), Massimo Terzolo (Italy)), oncologists (Eric Baudin (France), Alfredo Berruti (Italy), a pathologist Ronald de Krijger (the Netherlands)) and an endocrine surgeon Radu Mihai (UK). The working group had three in-person meetings (November 2016, September 2017, and March 2018) and communicated by phone and email. Consensus was reached upon discussion; minority positions were taken into account in the rationale behind recommendations. Prior to the process, all participants completed conflict of interest forms.

3.2 Target group

This guideline was developed for healthcare providers involved in the care of patients with ACC, i.e., endocrinologists, oncologists, surgeons, radiologists, nuclear medicine physicians, radio-oncologists, pathologists, specialists in general internal medicine and nurse specialists. However, general practitioners or gynecologists or dermatologists (who are involved in the diagnostic of androgen excess) might also find the guideline useful, as might our patients. In addition, the guideline document can serve as a source document for the preparation of patient information leaflets.

3.3 Aims

The overall purpose of this guideline is to provide clinicians with practical guidance for the management of patients with ACC. In clinical practice, treatment decisions should take into account the recommendations but also the clinical judgment of the treating physician.

Recommendations are thus never meant to replace clinical judgment. In some countries not all recommended tests and treatments, or both, might be available. Thus, the recommendations have certainly been interpreted in the context of available resources/treatment in the community, in which the patient is being seen.

3.4 Summary of methods used for guideline development

The methods used have been described in more detail previously (31). In short, the guideline used GRADE (Grading of Recommendations Assessment, Development and Evaluation) as a methodological base. The first step was to define clinical question(s) (see Section 3.5), the second being a systematic literature search (see Section 3.6). After including all relevant articles, we (1) rated the quality of the evidence and (2) estimated an average effect for specific outcomes (if possible). The quality of evidence behind the recommendations is classified as very low (+OOO), low (++OO), moderate (+++O) and strong (++++).

For the recommendations we took into account: (1) quality of the evidence, (2) balance of desirable and undesirable outcomes and (3) values and preferences (patient preferences, goals for health, costs, management inconvenience, feasibility of implementation, etc.) (32, 33). The recommendations are worded as recommend (strong recommendation) and suggest (weak recommendation). The meaning of a strong recommendation can be stated as follows: reasonably informed persons (clinicians, politicians and patients) would want the management in accordance with the recommendation. For a weak recommendation, most persons would still act in accordance with the guideline, but a substantial number would not (33). Formal evidence syntheses were performed and graded only for recommendations addressing our initial four questions. Recommendations based on good practice and experience of the panelists were not graded (34). Recommendations were derived from majority consensus of the guideline development committee, but

if at least one member had substantial disagreements, this is acknowledged in the manuscript. If two or more panelists did not agree with a recommendation, this was considered as not consensus. For transparency, all recommendations are accompanied by text explaining why specific recommendations were made.

3.5. Clinical question, eligibility criteria and endpoint definition

At the beginning of the guideline development process, the panel agreed on 30 clinical questions in the management of patients with ACC that should be addressed in the guidelines. In a next step, we agreed on four most relevant clinical questions (Table 2), for which a detailed literature search and review was subsequently performed.

3.6 Description of search and selection of literature

A literature search of electronic medical databases was performed for all four clinical questions. As we expected that single publications could contribute to different questions (for example 2 and 4) we decided to perform one overarching search using broad search terms. The search revealed 5988 papers, of which 615 were duplicates. In summary, we included 18 publications for clinical question 1 (diagnostics for ACC), 35 studies for clinical question 2 (prognosis), 10 publications for clinical question 3 (adjuvant therapy) and 48 publications for clinical question 4 (recurrent/advanced disease). The review of hormonal overproduction as prognostic factor was published as stand-alone paper (35). For question 3, we included one study after having been provided with baseline characteristics and adjusted estimates for mitotane therapy not reported in the original publication (36).

3.7. Review process and endorsement of other societies

A draft of the guideline was reviewed by four experts in the field (see 'Acknowledgments' section) and has been submitted for comments by ESE and ENSAT members. In addition, the following societies and networks were asked for review and finally endorsed the guidelines: the European Society of Endocrine Surgeons, the Endocrine Society, USA, the European Society of Pathology, the American-Australian-Asian Adrenal Alliance (A5), the European Reference Network on Rare Endocrine Conditions (Endo-ERN) and the European Reference Network on Rare Adult Solid Cancers (ERN EURACAN).

Furthermore, patient groups were approached to review the guidelines. All comments and suggestions were then discussed and implemented as appropriate by the panel (all comments and responses are provided in Appendix 8, see section on [appendix](#) given at the end of this article).

4. Summary and conclusions from systematic literature reviews

4.1. Clinical question 1: Pathology

We included 17 publications (37, 38, 39, 40, 41, 42, 43, 44, 45, 46, 47, 48, 49, 50, 51, 52, 53) that contributed data to either the diagnosis of ACC in the context of adrenal vs non-adrenal distinction (4 studies) or in the context of benign vs malignant adrenocortical tumor distinction (15 studies) (two of them contributing to both subquestions (40, 45)). Details of studies are shown in Appendix 1 (in all samples, diagnosis based on histological examination). Melan-A and inhibin-alpha were studied in three publications; all other markers were studied in one or two publications only. In total, data for 27 diagnostic markers were reported. Since many publications included patients who did not reflect the target population in question for this guideline (i.e. patients with a suspicion for ACC), positive or negative predictive values were not provided. A formal meta-analysis was not performed given the low number of studies per marker. Importantly, no study reported on the combined diagnostic ability of a set of markers, which actually may reflect the approach in clinical practice.

4.2. Clinical question 2: Prognostic factors

Thirty-five studies reporting on risk factors for recurrence and/or mortality, and that included more than 100 patients with histologically proven ACC, were analyzed (1, 8, 20, 25, 26, 29, 54, 55, 56, 57, 58, 59, 60, 61, 62, 63, 64, 65, 66, 67, 68, 69, 70, 71, 72, 73, 74, 75, 76, 77, 78, 79, 80, 81, 82) (see Appendix 2 for details of studies included, and Appendix 3 for an overview of all prognostic factors studied). The threshold of 100 cases was defined upfront as with $n=100$ and an expected number of deaths of 50, statistical power was considered sufficient. Almost all studies reported age, sex and tumor stage as prognostic factors, although several different staging systems were used. A formal comparison of the studies was difficult due to heterogeneity regarding clinical characteristics, use of varying definitions of characteristics (e.g. stage) and

Table 2 Overview of the key clinical questions and predefined outcome parameters.

Clinical question	Predefined selection criteria and key outcome parameters	Metrics of the literature search
<p>Question 1: Pathology – what is needed to diagnose an ACC?</p> <p>Sub-question 1A: How to make a distinction between adrenocortical/non-adrenocortical tumor?</p> <p>Sub-question 1B: How to make a distinction between benign or malignant or indeterminate behavior in adrenocortical tumors?</p>	<p>Population:</p> <ul style="list-style-type: none"> Adrenal masses <p>Restriction:</p> <ul style="list-style-type: none"> Minimum 25 ACC patients Each marker has to be reported in at least two independent cohorts <p>Outcome:</p> <ul style="list-style-type: none"> Diagnostic accuracy (sensitivity/specificity/NPV/PPV) <p>Diagnostic marker:</p> <ul style="list-style-type: none"> (Weiss score), Ki67, reticulin, Helsinki, SF-1, melan-A, inhibin, calretinin, chromogranin, SRC1 <p>Reference standard:</p> <ul style="list-style-type: none"> Weiss-score^a Recurrence 	<p>Number of papers included:</p> <p>1a: <i>n</i> = 4</p> <p>1b: <i>n</i> = 15</p> <p>(2 papers contributed to both)</p>
<p>Question 2: Which are the best prognostic markers in ACC?</p>	<p>Population (minimum 100 ACC patients):</p> <ol style="list-style-type: none"> Patients after radically resected ACC Patients with advanced ACC <p>Restriction:</p> <ul style="list-style-type: none"> Prognostic marker has to be reported in at least two independent cohorts <p>Prognostic markers to be considered:</p> <ul style="list-style-type: none"> Tumor stage (different systems: Sullivan, Lee, UICC, ENSAT, etc.), sex, age, Ki67, hormone section, Weiss score, mitotic index, R status, molecular/immunohistological markers <p>Outcome</p> <ul style="list-style-type: none"> Overall survival, disease-free and progression-free survival, prognostic ability 	<p>Number of papers included: 35</p>
<p>Question 3: Is adjuvant therapy able to prevent recurrent disease or reduce mortality after radical resection?</p>	<p>Population:</p> <ul style="list-style-type: none"> Diagnosis of ACC with macroscopic radical resection (R0, R1, Rx) <p>Restriction:</p> <ul style="list-style-type: none"> Studies with >10 patients in the intervention group Only studies providing baseline data per treatment group, and providing age and stage adjusted estimates In case of >25% overlap only inclusion of the largest study <p>Intervention:</p> <ul style="list-style-type: none"> Adjuvant treatment with either mitotane, radiation therapy or cytotoxic chemotherapy <p>Control group:</p> <ul style="list-style-type: none"> Without therapy or other treatment <p>Outcomes:</p> <ul style="list-style-type: none"> Disease-free survival, overall survival, quality of life, adverse events 	<p>Number of papers included:</p> <p>Mitotane <i>n</i> = 6</p> <p>Radiation therapy <i>n</i> = 4</p>
<p>Question 4: What is the best treatment option for macroscopically incompletely resected, recurrent or metastatic disease?</p>	<p>Population:</p> <ul style="list-style-type: none"> Macroscopically incompletely resected, recurrent or metastatic ACC <p>Restriction:</p> <ul style="list-style-type: none"> Studies >10 patients in the intervention group. Only studies providing baseline data per treatment group <p>Interventions:</p> <ul style="list-style-type: none"> Cytotoxic drugs including mitotane, surgery, radiation therapy, radiofrequency ablation, chemoembolization <p>Control:</p> <ul style="list-style-type: none"> Not mandatory (single arm cohort studies eligible) <p>Outcome:</p> <ul style="list-style-type: none"> Overall survival, progression-free survival, tumor response, quality of life, adverse events 	<p>Number of papers included:</p> <p>Cytotoxic drugs including mitotane: <i>n</i> = 27</p> <p>Surgery: <i>n</i> = 16</p> <p>Radiation therapy: <i>n</i> = 1</p> <p>Radiofrequency ablation: <i>n</i> = 1</p> <p>Radionuclide therapy: <i>n</i> = 1</p>

^aWe are aware that the Weiss score was never properly validated, but we decided that there is no other 'gold standard'.

NPV, negative predictive value; PPV, positive predictive value; R status, Resection status; R0, microscopically complete resection; R1, microscopically incomplete resection; Rx uncertain resection status; SF-1, steroidogenic factor 1; SRC1, steroid receptor coactivator 1.

different cut-offs (e.g. tumor size, age). Furthermore, the multivariable models presented include adjustment for different additional variables. We acknowledge a concern over the number of variables included in models relative to the number of events and that this may have the potential to lead to false-positive results.

The association between staging and prognosis was robust (+++O), despite different systems being used (29, 55, 70, 83, 84, 85, 86, 87, 88, 89). In a formal comparison, the ENSAT staging (29) was slightly superior to the UICC staging (88). Additionally, the association between hypercortisolism and mortality was consistent and remained with a positive hazard ratio after adjustments for tumor stage HR: 1.71, 95% CI: 1.18–2.47 (35). Ki67 was studied in five publications, showing worse prognosis with increasing Ki67 in all studies. Other molecular markers have been studied in single cohorts only (Appendices 2 and 3).

It is important to mention that relative risks, even if statistically significant, cannot inform clinical decision making unless translated into predictive values or incorporated in prediction models. Only one study presented a formal prediction model (including the variables tumor size, stage, mitotic index, venous invasion and endocrine activity), showing a sensitivity of 0.91 and a specificity of 0.90 (63). Another study provided nomograms to facilitate prognosis in individual patients (68). None of these models, however, has been validated externally.

4.3. Clinical question 3: Adjuvant therapy

No randomized clinical trial has been published yet exploring adjuvant therapies; no studies comparing quality of life after different treatment modalities were found. We included six studies that assessed the effect of mitotane on recurrence and mortality (36, 58, 90, 91, 92, 93). Appendix 4 for details and Appendix 5 for risk of bias assessment. Due to an overlap of the study population of >25% between studies (36, 58, 90) only the German study cohort from Beuschlein *et al.* was considered, but not the validation cohort (58). In one study, 47 patients were enrolled in four Italian centers where adjuvant mitotane was routinely recommended, 55 patients in four Italian centers where no adjuvant strategy was undertaken (control group 1) and 75 German patients left untreated after surgery (control group 2) (90, 94). However, only the most recent update of these series was included in the analysis (90). In order to avoid counting data twice only control group 1 was included.

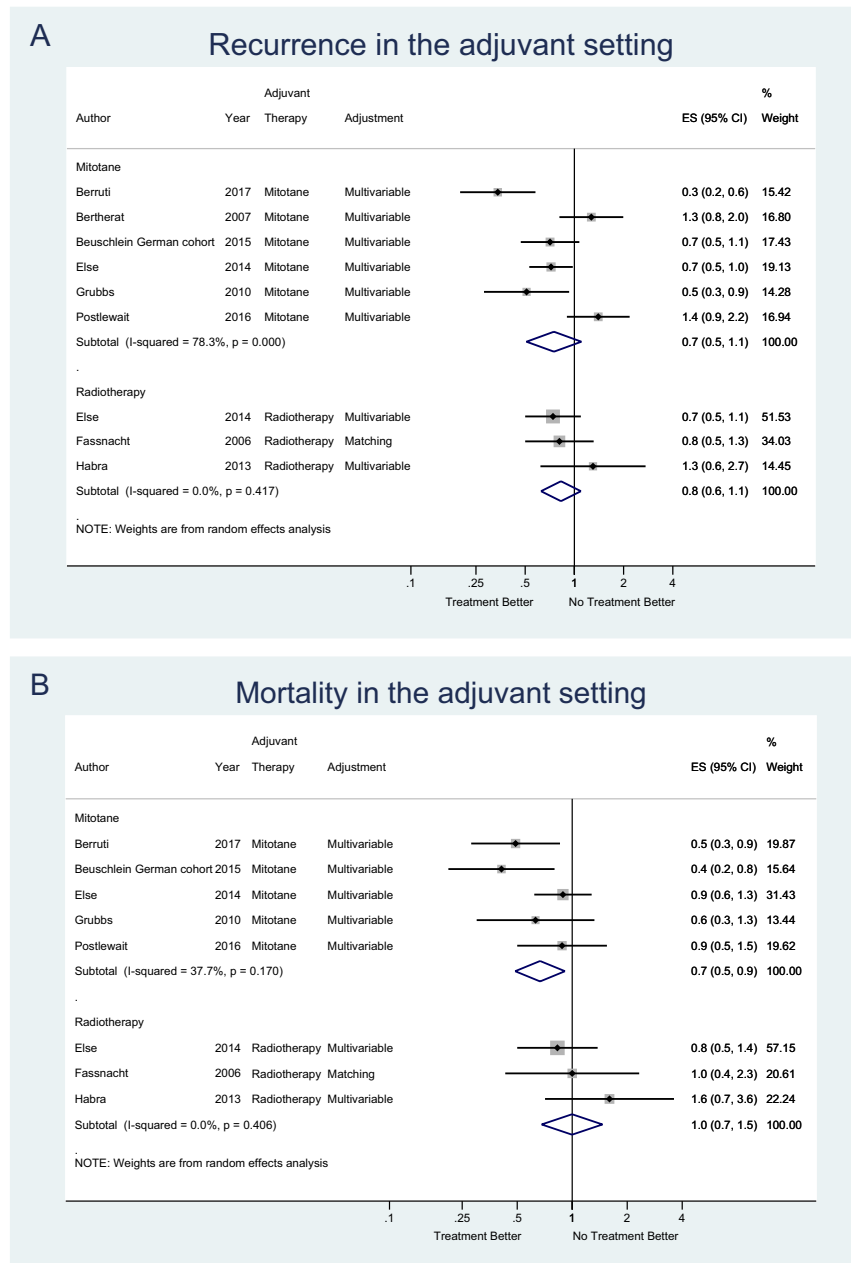
In a meta-analysis, the pooled hazard ratio for recurrence was 0.7, 95% CI: 0.5–1.1; for mortality (5 studies) the pooled hazard ratio was 0.7, 95% CI: 0.5–0.9 (Fig. 1). All six studies were non-randomized with the potential of a (residual) confounding effect, meaning that treatment choices are based on prognosis (such as performance status of the patient, tumor stage etc.), which introduces imbalance in prognostic factors. It is known that when studying therapeutic effects, this confounding effect is difficult to remedy statistically (95). One study (90) circumvented the confounding effect by comparing two treatment strategies applied in different settings; such comparison relies on other assumptions (96). A further bias in this context is immortal time bias, which can occur if treatment is initiated after follow-up time starts, and this is not accounted for in the analysis. Such biases tend to overestimate treatment effects (97) and were not explicitly accounted for in most studies. Only one study applied a landmark analysis to address this bias (90). The overall quality rating was very low (+OOO).

Four studies assessed the impact of adjuvant radiation therapy (91, 98, 99, 100). See Appendix 4 for details and Appendix 5 for risk of bias assessment. The study by Sabolch *et al.* (100) was only considered for data on local recurrence, not for recurrence and mortality given the overlap with another study of the same group (91). In all but one study (59) patients treated with adjuvant radiation therapy (91) were small. We found a pooled hazard ratio of 0.8 (95% CI: 0.6–1.1) for recurrence and for mortality of 1.0 (95% CI: 0.7–1.5) (Fig. 1). The pooled hazard ratio for local recurrence (three studies) after treatment with radiotherapy was 0.3 (93% CI: 0.1–1.9).

All studies were observational with the potential of (residual) confounding effects, immortal time bias was not explicitly accounted for in most studies, and the studies were small with imprecise effect estimates; the overall quality rating was therefore very low (+OOO).

4.4. Question 4: Therapy for advanced or recurrent disease

A total of 27 publications reported outcomes of 29 different systemic therapies for advanced or recurrent ACC (30, 66, 101, 102, 103, 104, 105, 106, 107, 108, 109, 110, 111, 112, 113, 114, 115, 116, 117, 118, 119, 120, 121, 122, 123, 124, 125); two were randomized controlled trials ((30, 102); see Appendix 6 for details of studies included). The first randomized trial compared mitotane plus a combination of etoposide, doxorubicin

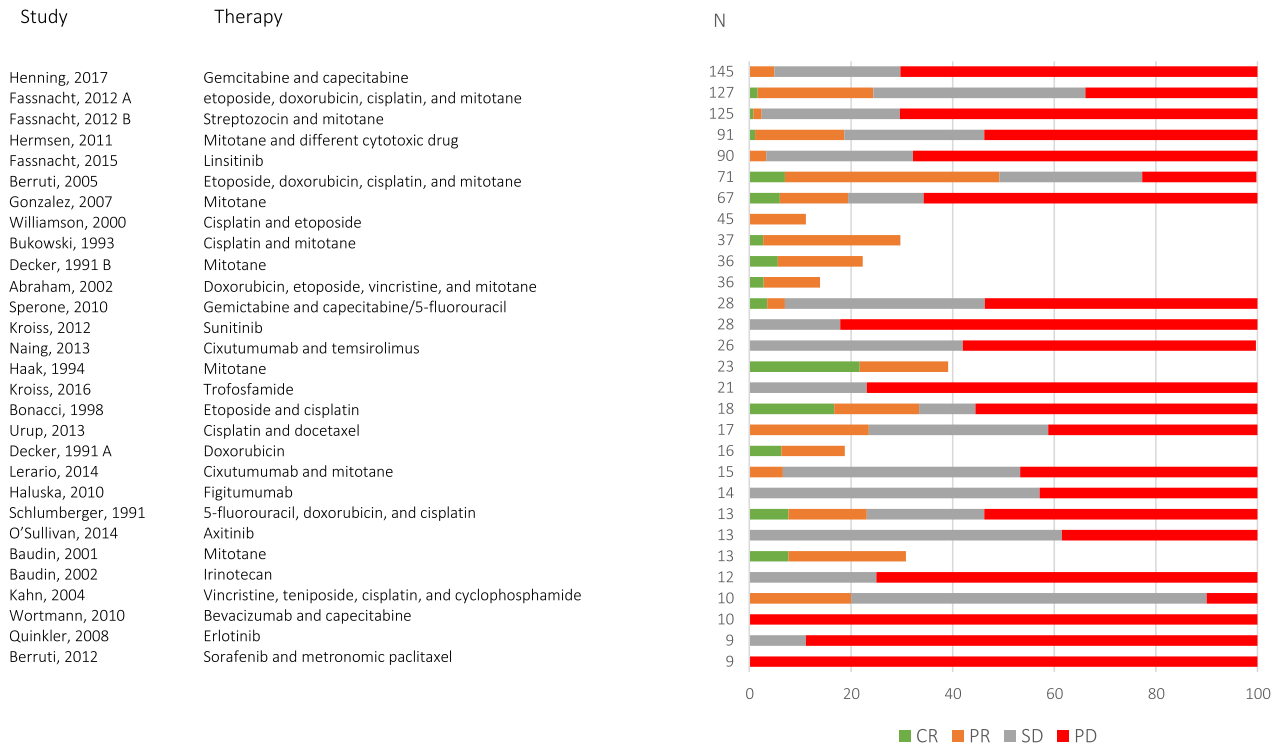
**Figure 1**

Meta-analysis of recurrence (A) and mortality (B) of included studies on adjuvant therapy after radical resection in ACC.

and cisplatin (EDP-M) to mitotane plus streptozocin in 204 patients with advanced ACC (30). The trial showed a positive effect of EPD-M on progression-free survival HR of 0.55 (95% CI: 0.43–0.69; $P < 0.001$), but failed to show a significant effect on mortality (HR: 0.79; 95% CI: 0.61–1.02; $P = 0.07$); (+++O). The second randomized trial compared linsitinib to placebo (total 139 patients, 2:1 randomization to therapy) and did not show a clear effect on either progression-free (HR: 0.83, 95% CI:

0.56–1.21; $P = 0.30$) or overall survival (HR: 0.94; 95% CI: 0.61–1.44; $P = 0.77$) (102); (+++O).

Many publications reported on single arm studies of different therapeutic regimens. These single-arm studies have an inherent risk of selection bias, and direct comparison is not possible. Differences in patient characteristics, definition of response criteria and follow-up duration are a concern (+OOO). Given the uncontrolled design a final conclusion about the optimal treatment

**Figure 2**

Overview of the objective response rates in studies with systemic therapies in ACC. The studies are ordered by number of included patients per regimen. This figure has to be interpreted very cautiously, because study protocols, patient cohorts and characteristics as well as outcome measurements are quite different precluding a direct comparison. CR, complete response; PR, partial response; SD, stable disease; PD, progression of the disease. Some of the older studies did not report stable disease or progression, thus these columns do not sum up to 100%.

for advanced recurrent ACC cannot be given. [Figure 2](#) shows response rates from all studies with data for at least one regimen. For most regimens at least some responses (partial or even complete) were reported; treatment merits in case of stable disease are more difficult to judge as this depends highly on duration of follow-up and biology of the disease. Adverse effects from chemotherapy, however, are common and diverse (see Appendix 6).

Sixteen studies focused on surgery in recurrent and advanced ACC; six publications reported on oligo-metastasectomy (lung and liver) ([126](#), [127](#), [128](#), [129](#), [130](#), [131](#)), whereas ten publications assessed the effect of surgery in local recurrent and/or metastatic disease ([61](#), [66](#), [78](#), [132](#), [133](#), [134](#), [135](#), [136](#), [137](#), [138](#)). In patients with metastasectomy, 5-year survival rates up to 40% were reported ([126](#), [127](#)), although control groups were lacking (+OOO). There were large differences regarding extent of disease, indication and concurrent treatment in studies comparing a surgical approach to a non-surgical approach for recurrent or advanced disease. The reported benefit of

surgery is confounded by differing indications for surgery, and this precludes firm conclusions from being drawn (+OOO). Therefore, the main conclusion is that in patients deemed radically operable by the surgeon/team operation is a treatment option. However, beside prognostic factors like Ki67, a key influencing factor in case of recurrence is the disease-free interval prior to recurrence.

For radionuclide therapy ([139](#)), transcatheter arterial chemoembolization ([140](#)), radiofrequency ablation ([141](#)) and radiation ([142](#)) only one small study per procedure was found, and no conclusions can be drawn.

5. Recommendations

5.1. General remarks

The main part of this guideline addresses the management of adult patients with ACC. We divided the 62 recommendations in 12 sections. In addition, we provide two flow charts on the management of patients

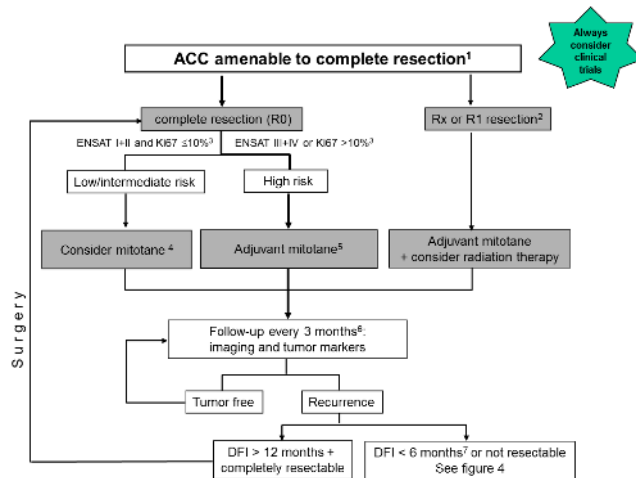


Figure 3

DFI disease-free interval between complete resection and recurrence. ¹All patients with stage I+II and most patients with stage III should be amenable to radical resection. If complete resection is not feasible, consider neo-adjuvant treatment (e.g. mitotane + cisplatin or EDP). In selected patients with single metastases complete resection might be possible as well. ²In patients with R2 resection, consider re-surgery by an expert surgeon (see R.3.6) or Fig. 1B. ³If Ki67 staining is not available, a low (<20 mitoses/50 high power fields) or a high mitotic rate (>20 mitoses/50 high power fields) may be used for risk stratification. ⁴Individual decision (see R.7.2.). If possible enroll in clinical trial like ADIUVO (www.adiuvo-trial.org). ⁵In some patients (e.g. Ki67 >30%, large tumor thrombus in the vena cava, stage IV, or R1 resection) consider additional cytotoxic therapy (e.g. 4 cycle of cisplatin + etoposide). ⁶After two years the time intervals are gradually extended. ⁷If the disease-free interval is between 6 and 12 months or in patients with DFI >12, in whom complete resection is not possible, an individual approach is required (see R.9.7.).

with ACC amenable to radical resection (Fig. 3) and on the management of patients with advanced ACC not amenable to radical resection (Fig. 4) to give an efficient overview. However, we would like to emphasize once more that none of these flow charts nor the entire recommendations can replace clinical judgment of the treating physician and joint decision making with the patient.

5.1. Overarching recommendations

R.1.1. We recommend that all patients with suspected and proven ACC are discussed in a multidisciplinary expert team meeting

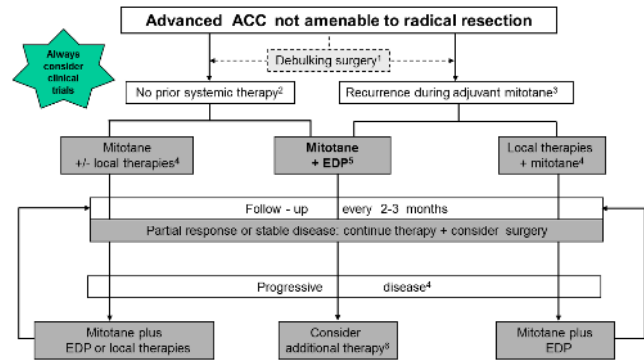


Figure 4

EDP etoposide, doxorubicin, cisplatin. ¹Only in selected patients (e.g. with severe hormone excess). ²The following factors might guide the decision: site of disease involvement, tumor burden, symptoms, tumor grade/Ki67 index. ³The following factors might guide the decision: site of disease involvement, tumor burden, symptoms, tumor grade/Ki67 index, and importantly kinetics of tumor growth. ⁴Radiotherapy, radiofrequency ablation, cryo ablation, microwave ablation, (chemo-) embolization. ⁵Few panelists favored cisplatin + etoposide. ⁶For the currently available cytotoxic regimens see Table 6 and contact specialized center.

(including health care providers experienced in care of adrenal tumors, including at least the following disciplines: endocrinology, oncology, pathology, radiology, surgery) at least at the time of initial diagnosis. In addition, this team should have access to adrenal-specific expertise in interventional radiology, radiation therapy, nuclear medicine and genetics as well as to palliative care teams.

Reasoning:

Despite the lack of studies, the panel was convinced that patients with ACC benefit from multidisciplinary management by a team of experts with experience in care for patients with this rare disease. Ideally, all patients would be managed by such a team throughout the course of their disease, because during the follow-up, considerations of multiple diagnostic and treatment modalities might be required. However, in many health care settings, this is yet an unrealistic expectation. Therefore, we envision that in the future, at least one reference center, that fulfills the above-mentioned criteria, will be established in every country. We believe that it is crucial that every case of suspected ACC is discussed in detail with a panel of experts for this disease at the time of the initial diagnosis. Additionally, this expert team should be ideally requested

every time progress is documented (or suspected) and new treatment options might be required. If there is no accessible center with all the required expertise in all disciplines, or the patient is not able to travel to such a center, telemedicine approaches should be encouraged to compensate for these limitations.

R.1.2. We suggest that at any time of decision making regarding therapy, enrollment in a clinical trial (if available) should be considered. Furthermore, we encourage patients' participation in registries and the collection of biological material as part of structured research programs aimed at defining biomarkers of diagnosis, prognosis and treatment response.

Reasoning:

As described earlier, the evidence for almost all therapeutic strategies for ACC is very low. Furthermore, the efficacy of systemic therapies is limited, including the most commonly used treatments – mitotane and platinum-based chemotherapies, with response rates clearly less than 30% (3, 13, 30, 103, 107, 143). Thus, improved treatment paradigms are needed urgently. Clinical trials are the best way to improve our knowledge and patient care. However, the benefits and risk for the individual patient have to be weighed against available data of agents with known or predicted efficacy in ACC.

Because of the rarity of the disease, it is crucial to include as many patients as possible in research programs for multicenter therapeutic trials, as well as studies for diagnostic, prognostic and predictive markers. A list of ongoing trials is accessible on <https://www.clinicaltrials.gov/>. Biological material may include tumor samples, ideally frozen and paraffin-embedded, blood-derived and urine samples. National and international research networks such as ENSAT (www.ensat.org) (144) and the recently founded A5 (<https://adrenal-a5.org/>) play instrumental roles in coordinating research programs. Centers providing care to patients with ACC should register as investigators with ongoing trials and also facilitate the collection of biological material and ensure appropriate consent.

5.2. Diagnostic procedures in suspected ACC

R.2.1. The diagnosis of ACC is not always obvious. We recommend establishing as soon as possible whether an adrenal mass is malignant, using all required diagnostic tools in a timely fashion.

Reasoning:

Due to the potentially poor prognosis of ACC, it is critical to know as early as possible if an adrenal mass is malignant or not. Therefore, even if there is only a small likelihood that an adrenal mass is an ACC, this diagnosis should be rapidly excluded with the highest possible certainty. A particular suspicion for an ACC might arise from clinical aspects (e.g. rapidly developed features of adrenocortical hormone excess, see R.2.2) or results from hormonal work-up (see R.2.3) or indeterminate or suspicious imaging (see R.2.4). An adrenal biopsy should only be considered in those selected cases in which an adrenal metastasis of an extra-adrenal malignancy is suspected or when the tumor is considered as inoperable (17) (for details and explanation see R.2.7). The proposed diagnostic work-up is summarized in Table 3.

R.2.2. We recommend that every patient with (suspected) ACC should undergo careful assessment including case history, clinical examination for symptoms and signs of adrenal hormone excess.

Reasoning:

All patients should undergo a careful evaluation with detailed history and physical examination. In particular, patients should be evaluated for rapidly developing Cushing syndrome (which frequently presents not as 'full blown' Cushing, but rather predominantly with muscle weakness, hypokalemia, wasting and constitutional symptoms), and symptoms and signs of a large abdominal mass. Clinical evaluation should additionally focus on symptoms and signs of androgen excess, hirsutism or virilization in women or recent onset of gynecomastia in men, because these might be clinical indicators for an androgen- or estrogen-producing ACC, respectively (13, 23, 145, 146, 147, 148). Any evidence of co-secretion of different steroids raises the suspicion of an ACC (especially if sex hormones are involved). In contrast, mild, long-standing hirsutism is usually not caused by an ACC, but rather due to (among other diagnoses) polycystic ovary syndrome and non-classical congenital adrenal hyperplasia (149). Primary aldosteronism is rare in ACC and usually accompanied by severe hypokalemia (150). However, hypokalemia in ACC is more frequently caused by massive cortisol excess overwhelming the renal 11- β hydroxysteroid dehydrogenase type 2 system.

R.2.3. We recommend that all patients with suspected ACC undergo a detailed hormonal

Table 3 Diagnostic work-up in patients with suspected or proven ACC.

Hormonal work-up	
Glucocorticoid excess	<ul style="list-style-type: none"> – 1 mg dexamethasone suppression test or free cortisol in 24-h urine^a – Basal ACTH (plasma)^b
Sex steroids and steroid precursors ^c	<ul style="list-style-type: none"> – DHEA-S – 17-OH-progesterone – Androstenedione – Testosterone (only in women) – 17-beta-Estradiol (only in men and postmenopausal women) – 11-Deoxycortisol
Mineralocorticoid excess	<ul style="list-style-type: none"> – Potassium – Aldosterone/renin ratio (only in patients with arterial hypertension and/or hypokalemia)
Exclusion of a pheochromocytoma	<ul style="list-style-type: none"> – Fractionated metanephrines in 24 h urine or free plasma-metanephrines
Imaging	<ul style="list-style-type: none"> – CT or MRI of abdomen and pelvis – Chest CT – FDG-PET/CT^d – Bone or brain imaging (when skeletal or cerebral metastases are suspected)

^aThe 1-mg dexamethasone test is the preferred method to exclude relevant hypercortisolism. However, if overt Cushing syndrome is evident, then cortisol in 24-h urine might be at least as good to quantify the cortisol excess. Alternatively, salivary or serum bedtime cortisol can be used. ^bACTH can be skipped if hypercortisolism is excluded. The most suitable set of precursors and sex hormones has not yet been established and local availability might be taken into account. ^cThe panel did not agree on the systematic use of FDG-PET/CT (see R.2.4).

work-up to identify potential autonomous excess of glucocorticoids, sex hormones, mineralocorticoids and adrenocortical steroid hormone precursors (Table 3). In addition, a pheochromocytoma must be excluded.

Reasoning:

A comprehensive endocrine work-up is helpful for various reasons. (i) The diagnosis of steroid excess is frequently able to establish the adrenocortical origin of the tumor. (ii) The steroid pattern may indicate whether an adrenal lesion is an ACC. For example, autonomous co-secretion of androgens and cortisol in any patient and secretion of steroid precursors or estradiol in males are highly suspicious for ACC (145). Furthermore, hormonal evaluation is of prognostic value as cortisol-secreting tumors generally have a worse prognosis (35). (iii) If undiagnosed, autonomous cortisol secretion may be followed by life-threatening adrenal insufficiency after complete resection of the primary tumor. The best test to diagnose autonomous cortisol secretion is the 1 mg overnight dexamethasone suppression test (147). If hypercortisolism is present, it is crucial to prove ACTH independency, because an adrenal metastasis of an ectopic ACTH-secreting tumor (e.g. lung cancer) can mimic an ACC. (iv) Elevated hormones prior to surgery may serve as tumor markers during follow-up. Finally, conventional imaging cannot discriminate an ACC from a pheochromocytoma. However, undiagnosed pheochromocytoma may lead to dangerous hypertensive crises (especially during invasive procedures). Therefore, a

pheochromocytoma has to be ruled out in any case of an adrenal tumor whenever no obvious autonomous steroid excess is present (17). It is important to note, however, that slightly elevated metanephrines levels (<2-fold), particularly when inconsistent with a large tumor size, might be non-specific and can be observed in ACC.

R.2.4. We recommend adrenal-focused imaging in all patients with suspected ACC.

Reasoning:

Imaging tools for adrenal tumors were carefully reviewed during the development of the ESE-ENSAT guidelines for adrenal incidentalomas (17, 151). Thus, we refer to these documents for details. Briefly, there are currently three main imaging techniques available for the differentiation of malignant and benign adrenal tumors: CT, MRI and positron emission tomography with ¹⁸F-2-deoxy-D-glucose (mostly combined with CT; FDG-PET/CT). CT and MRI are techniques mainly optimized to identify benign lesions, providing a tool for the exclusion of adrenal malignancy (152, 153, 154, 155). Conversely, FDG-PET/CT is mainly used for the detection of malignant disease (156, 157, 158). A recently performed meta-analysis indicated that the level of evidence is low to very low for all these imaging methods (151). In the last 2 years, some additional studies have been published (159, 160, 161, 162, 163, 164, 165, 166, 167, 168, 169, 170, 171, 172). However, the panel still considers that of the available imaging modalities, only non-contrast CT is sufficiently reliable to rule-out an ACC

when the adrenal lesion is homogenous and has low CT density ≤ 10 HU. In contrast, ACCs are usually large and of inhomogeneous appearance and characterized by low fat content (and hence higher HU density) (173). Recently, FDG-PET has been proposed as possibly the best second-line test to assess indeterminate masses by unenhanced CT (159, 165, 166). However, the experience shows that sensitivity and negative predictive value are much better than specificity or positive predictive value. Therefore, no consensus could be reached for a general recommendation on FDG-PET in all patients. Additional reasons in favor of systematic FDG-PET are whole body imaging (beyond thorax and abdomen, particularly for distant bone metastasis) and in advanced disease, a reference uptake value for all metastases can be established, which can help judging the future evolution of disease. Evidence against FDG-PET includes cost, additional radiation exposure, false-positive findings and difficult access in some countries.

If adrenal imaging indicates an indeterminate mass, other parameters should be considered: For instance, in such a situation a tumor size >4 cm, combined adrenocortical hormone excess (see also **R.2.3**), rapidly developing symptoms or young age (e.g. <40 years) might point to an ACC. However, it is important to note that no single imaging method can definitively prove the diagnosis of ACC.

R.2.5. We recommend in any case where there is high suspicion for ACC performing a chest CT, in addition to an abdominal-pelvic cross-sectional imaging (CT or MRI), because the results might influence therapeutic decision making.

Reasoning:

Since decisions for treatment strategy, particularly decisions for surgery, and prognostication rely on tumor stage, it is mandatory to systematically and rapidly evaluate for metastases, before initiation of any anti-tumor treatment. Thoraco-abdomino-pelvic imaging will cover the vast majority of metastatic locations, which most often are lung and liver and will assess loco-regional tumor extent. Imaging should include contrast-enhanced imaging. For abdominal imaging, there are advantages and disadvantages for both CT and MRI, but for thoracic imaging, CT is the method of choice, because it outperforms all other methods in detecting small pulmonary lesions.

Additional imaging may be required to better characterize tumor vascularization or specific tumor extent such as a vena cava thrombus.

R.2.6. We suggest performing additional imaging (e.g. bone and brain imaging) only in case of clinical suspicion of metastatic lesions.

Reasoning:

Bone and brain metastases are rare events (especially in patients without other metastatic lesions). Therefore, additional imaging focusing on these sites is only warranted when there is increased clinical suspicion or other imaging is suggestive for bone metastases. It should be noted, however, that the basis for this advice has never been studied systematically.

R.2.7. We recommend against the use of an adrenal biopsy in the diagnostic work-up of patients with suspected ACC unless there is evidence of metastatic disease that precludes surgery and histopathologic proof is required to inform oncological management.

Reasoning:

Differentiating benign from malignant adrenocortical tumors is very challenging on a biopsy only and may lead to misdiagnosis (17, 174). Furthermore, the biopsy comes with significant risks such as hemorrhage (175). The risk of tumor dissemination precluding a R0 resection is very low (175). However, a biopsy might be indicated in an adrenal mass without any hormone excess in patients with a history of extra-adrenal cancers to exclude or prove an adrenal metastasis of an extra-adrenal malignancy. For details, see the adrenal incidentaloma guidelines (17).

5.3. Surgery for suspected localized ACC

R.3.1. We recommend that adrenal surgery for suspected/confirmed ACC should be performed only by surgeons experienced in adrenal and oncological surgery.

Reasoning:

ACC surgery requires expertise in both adrenal and oncological surgery due to the specific anatomy, the malignant character of the disease and the potential need for multi-organ *en bloc* resection to optimize the probability of a R0 resection and minimize the risk of complications.

Data comparing outcome between 'high-volume' and 'low-volume' centers for ACC are limited. Published reports from the UK, USA and Spain show an unacceptable low annual workload for the majority of surgeons involved

in any adrenal surgery, with a median 1 case/year (176, 177, 178, 179). This situation is likely to have a negative impact on patient care and contrasts significantly with the current status in other surgical specialties.

Based on the upper quartile distribution of workload of surgeons in the USA, a volume of four adrenalectomies/year was used to define a 'high-volume' surgeon (177), but this threshold might be too low to inspire confidence. Several studies showed that those doing more than 6–7 cases per year have shorter length of stay and fewer complications (176, 177, 180). Despite the perceived benefit of being operated in a high-volume center, published data from Italy and the USA showed no significant association between overall survival/disease-free survival and workload even though patients operated in high-volume centers had more radical surgery, more lymph node assessment and more use of chemotherapy (181, 182). In contrast, the creation of national centers for adrenal surgery in the Netherlands led to significantly improved disease-free survival (1 year: 93% vs 78%, 5 year: 63% vs 42%) (183, 184). Therefore, the panel believes that a minimal annual workload of six adrenalectomies/year seems to be required to ensure sufficient experience in adrenal surgery, but >20 adrenalectomies/year are desirable for those involved in surgery for ACC. Furthermore, due to the complexity of some operations, it is essential to involve surgeons with different expertise (e.g. vascular, liver and cardiac surgeons) for pre-surgical planning and during these complex operations.

Protocols ensuring referral to regional or national centers should be established and patients should feel empowered to ask about the previous experience of individual surgeons.

R.3.2. We recommend complete en bloc resection of all adrenal tumors suspected to be ACC including the peritumoral/periadrenal retroperitoneal fat. We recommend against enucleation and partial adrenal resection for suspected ACC. If adjacent organs are suspected to be invaded, we recommend en bloc resection. However, we suggest against the routine resection of the ipsilateral kidney in the absence of direct renal invasion.

Reasoning:

Complete resection is of utmost importance for all ACCs and successful surgery is a prerequisite for cure. As the diagnosis of ACC might only become apparent after histological analysis, it remains imperative for all adrenalectomies (laparoscopic or open) in patients with a

reasonable suspicion for ACC to respect the principles of oncological surgery in order to ensure complete resection (R0 status) (185, 186).

To ensure that the pathologist can judge the completeness of surgery, any fragmentation of the tumor has to be avoided. Intraoperative tumor rupture or spillage and R2 resection are associated with very high recurrence rates and poor overall survival (26, 133).

Although there are no specific studies comparing outcome of surgery with and without resection of invaded adjacent organs, it is deemed to be 'good surgical practice' to resect adjacent tissues that are/could be invaded by tumor. This holds true for involvement of spleen, distal pancreas, stomach, kidney, right liver, colon, diaphragm, the wall of the IVC or left renal vein. A cohort study compared the oncological results of patients with stage II ACC treated by radical adrenalectomy alone or by *en bloc* resection with kidney. The results did not support the hypothesis that nephrectomy improves the oncological outcome (187). Combined nephrectomy, however, offers a lower risk of capsular rupture and can include complete lymphadenectomy of the renal hilum, but impairs kidney function, and this may limit further access to chemotherapy. Thus, in case of possible invasion in the kidney, partial nephrectomy should be considered on an individual basis.

R.3.3. Open surgery is the standard surgical approach for confirmed or highly suspected ACC. Therefore, we recommend open surgery for all tumors with radiological findings suspicious of malignancy and evidence for local invasion. However, for tumors <6 cm without any evidence of local invasion, laparoscopic adrenalectomy (respecting the principles of oncological surgery) is reasonable if the surgeon has sufficient experience in these types of surgery.

Reasoning:

There is an ongoing debate if laparoscopic adrenalectomy is an acceptable alternative for adrenal tumors with suspicion of ACC. Based on the systematic review on this topic until July 2014 (17) and an additional literature search until December 2017 (188, 189, 190, 191, 192, 193, 194, 195), we conclude that the quality of evidence from these observational studies is still very low. The main concerns with all these studies are differences of baseline characteristics between groups, and between important prognostic factors, such as tumor stage or size. The lack of any randomized trial prevents any final conclusions.

However, in order to provide guidance for clinicians the panel concurs with two other recent European guidelines (17, 185) and agrees that all tumors with some radiological evidence of local invasion (including enlarged lymph nodes) should undergo surgery with an open approach. The likelihood of a benign adrenal tumor is higher in the group of adrenal incidentalomas ≤ 6 cm, for whom a laparoscopic approach is reasonable. However, this cut-off is arbitrary and the experience of the surgeon is the single most important factor. Furthermore, it is advised to convert to an open procedure when obvious signs of invasion are encountered during laparoscopic surgery that would prevent complete resection. For detailed discussion, we refer to the recent recommendations for the surgical management of ACC by ESES and ENSAT (185) and the guidelines on adrenal incidentaloma (17).

Although retroperitoneoscopic adrenalectomy is gaining popularity, only a small number of surgeons are likely to have completed the learning curve to reach sufficient expertise, which is estimated to be at least 20 cases (196, 197). This is a very significant issue in the context of the overall minimal experience of most surgeons offering adrenalectomy (see above). Outside specialized centers with large volume practice, retroperitoneoscopic adrenalectomy should only be considered for benign tumors < 4 cm.

R.3.4. We suggest that routine loco-regional lymphadenectomy should be performed with adrenalectomy for highly suspected or proven ACC. It should include (as a minimum) the periadrenal and renal hilum nodes. All suspicious or enlarged lymph nodes identified on preoperative imaging or intraoperatively should be removed.

Reasoning:

Reports from several databases indicated that patients with stage III tumors and positive lymph nodes can have a 10-year overall survival rate of up to 40% after resection (29, 70, 88, 198, 199). However, the wide range of reported lymph node involvement in ACC (from 4 to 73%) (25, 26, 200) demonstrates that regional lymphadenectomy is neither formally performed by all surgeons nor accurately assessed or reported by all pathologists. According to large American and French series, approximately 10–30% of patients with ACC had formal lymphadenectomy as part of the tumor resection, reflecting the heterogeneity of operative management (25, 198). A minimum of four lymph nodes should be retrieved in order to declare

lymph node-negative cases (201). Furthermore, in an analysis of 120 cases identified from a multi-institutional database, the benefit of lymphadenectomy on overall survival persisted on multivariable analysis controlling for adverse preoperative and intraoperative factors associated with lymphadenectomy, such as tumor size, palpable mass, irregular tumor edges, suspicious nodes on imaging and multivisceral resection (202). The largest series so far included 283 patients and the resection of more than five lymph nodes reduced also the risk of local recurrence and disease-related death in a multivariate analysis (203).

However, the panel is not in favor of a repeat surgery if complete adrenalectomy was performed without lymphadenectomy (e.g. due to perceived benign tumor). The clinical benefit is uncertain and probably lower than the harm (e.g. delayed adjuvant therapy).

R.3.5. We recommend that individualized treatment decisions are made in cases of tumors with extension into large vessels based on multidisciplinary surgical team. Such tumors should not be regarded ‘unresectable’ until reviewed in an expert center.

Reasoning:

Extension of ACC into the adrenal vein, renal vein or inferior vena cava occurs in approximately 15–25% (29, 204, 205). Venous involvement consists mostly of intravenous tumor thrombus. Thrombectomy might require vena cava cross-clamping above or below the hepatic vein confluence or cardiopulmonary bypass, depending on the upper level of extent of the thrombus. The resection might include a complete thrombectomy, a flush maneuver and, occasionally, vascular cuff or prosthetic IVC replacement. A 3-year overall survival rate of about 25% in a large series (206) encourages the performance of a venous resection in the presence of vena cava or renal vein invasion but without distant metastases.

R.3.6. If the first surgery was suboptimal and macroscopically incomplete (R2 resection), we suggest to discuss repeat surgery in a multidisciplinary expert team.

Reasoning:

There has been no prospective study assessing the benefits (or the lack thereof) of early reoperation in patients whose initial adrenalectomy was incomplete (R2 status). It is the panel's view that such patients should have intensive

postoperative monitoring and if local recurrence is detected radiologically, in the absence of other metastases, they should undergo surgery with a curative intent at an expert center, if it is deemed likely to lead to an R0 resection.

R.3.7. We recommend perioperative hydrocortisone replacement in all patients with hypercortisolism that undergo surgery for ACC.

Reasoning:

Overt ACTH-independent Cushing syndrome or biochemical autonomous cortisol secretion might lead to adrenal insufficiency after removal of the adrenal source of cortisol (even in patients with incompletely suppressed ACTH) (207). Therefore, the group unanimously sees a clear indication of intraoperative and postoperative glucocorticoid replacement, preferably with hydrocortisone, in all patients with evidence for '(possible) autonomous cortisol secretion' (post-dexamethasone cortisol >50 nmol/L (>1.8 µg/dL)). This should follow the suggestions for major stress dose replacement as per recent international guidelines (208). Postoperatively, the dose of glucocorticoid should be tapered on an individualized basis by a physician experienced with this clinical scenario.

5.4. Pathological work-up

R.4.1. We recommend that the diagnosis of ACC should be confirmed by histopathology (+++0).

Reasoning:

Histopathology is the gold standard of diagnosing ACC and should in principle be obtained in all patients. For patients deemed operable, this will be done on the basis of the resection specimen and for those patients who are inoperable, a biopsy will be taken in accordance with good oncological practice. However, the majority of panelists argued that in selected cases, biopsy might be omitted when there is advanced disease with unequivocal ACTH-independent cortisol excess, androgen excess (testosterone, DHEAS) or estradiol excess. There is no role for biopsy in a patient who is considered suitable for surgery of the adrenal mass.

R.4.2. We suggest that all adrenal tumors, which cannot be readily classified, and all suspected ACC, should be reviewed by an expert adrenal pathologist (++00).

Reasoning:

Diagnosing ACC can be challenging and misdiagnoses are relatively frequent events. In 21 of 161 of the patients (13%) registered with the German ACC Registry between 2006 and 2009, the diagnosis of ACC had to be revised by the reference pathologist (24). Similar results were found in a large series from Italy with a rate of misdiagnosis in 26 out of 300 cases (9%) (209).

R.4.3. We suggest the use of immunohistochemistry for steroidogenic factor-1 (SF1) for the distinction of primary adrenocortical tumors and non-adrenocortical tumors (+000).

Reasoning:

Generally, the distinction between adrenocortical and non-adrenocortical tumors is clear and can be made on the basis of hematoxylin and eosin-stained slides. In case of doubt, on the basis of histology only, whether a tumor originates from the adrenal cortex or not, immunohistochemistry with SF1 is the most sensitive and specific marker currently available to establish if the tumor in question is of adrenocortical origin, with a sensitivity of 98% and a specificity of 100% (47). If this marker is not available, we advise a combination of markers, which should include inhibin-alpha, melan-A and calretinin (210, 211). Depending on the differential diagnosis, other immunohistochemistry markers used to make alternative diagnoses may be considered following local standard procedures.

R.4.4. We recommend the use of the Weiss system, based on a combination of nine histological criteria that can be applied on hematoxylin and eosin-stained slides, for the distinction of benign and malignant adrenocortical tumors (++00).

Reasoning:

There are many classification systems based on histology and/or a limited number of additional markers for the distinction of benign and malignant adrenocortical tumors. The Weiss system is the most widely used, and although it is not fully standardized (212, 213), the panel favors use of this score. It should be noted that all scoring systems have similar inherent problems. Using the Weiss system, a score of three or higher (on a total of nine criteria, Table 4) indicates ACC (214, 215). A score of 2 and 3 may be considered as borderline between benign and malignant tumors (tumors of uncertain malignant potential). In such instance, one of several

Table 4 Histopathologic criteria by Weiss (214, 215).

The presence of three or more of the following criteria highly correlated with subsequent malignant behavior:

- High nuclear grade (Fuhrman criteria (221))
- >5 mitoses per 50 high power field
- Atypical mitotic figures
- <25% of tumor cells are clear cells
- Diffuse architecture (>33% of tumor)
- Necrosis
- Venous invasion (smooth muscle in wall)
- Sinusoidal invasion (no smooth muscle in wall)
- Capsular invasion

other classification systems, including the van Slooten index (216), the modified Weiss score (41), the Helsinki classification (60, 77) and the addition of reticulin stain assessment (217) may be used.

Special attention should be paid to histological variants of adrenocortical tumors, mainly oncocytic tumors, which, because of their specific characteristics, will always have a Weiss score of at least 3, whether they are benign or malignant. For these tumors, an adapted scoring system should be used, the Lin-Weiss-Bisceglia system (218, 219, 220).

R.4.5. We recommend the use of Ki67 immunohistochemistry for every resection specimen of an adrenocortical tumor (++)

Ki67 immunohistochemistry has been proposed for prognostic purposes. Higher Ki67 levels are consistently associated with poor prognosis. Threshold levels of 10 and 20% have been considered for discriminating low from high Ki67 labeling index (58, 70). However, it is not clear whether any single significant threshold can be determined (see R.5.2).

Ki67 labeling has been shown to be unevenly distributed in tumors. Therefore, determination of the labeling index should be done on whole tumors, with specific attention to the area of highest Ki67 labeling, preferably by use of an image analysis system (222, 223). If only a biopsy is available, a low Ki67 labeling may not be representative and therefore can be misleading.

If Ki67 immunohistochemistry is not available, mitotic count may help in prognostic stratification of ACC. Mitotic count has been proposed for grading of ACC, using >20 mitoses per 50 high power field to define high-grade tumors (56, 87, 215). However, the precise correlation between mitotic count and Ki67 labeling is undetermined.

R.4.6. We recommend that the pathology report of a suspected ACC should at least contain the following information: Weiss score (including the exact mitotic count), exact Ki67 index, resection status and pathological tumor stage (indicating invasion or not of the capsule and/or surrounding tissue and organs) and nodal status (+000).

Reasoning:

The importance of Weiss score and Ki67 index has been discussed in R4.4 and R4.5, respectively. It is important that the exact values are given, because this is of prognostic relevance. Resection status is a major prognostic factor (see R.5.2). Tumor stage, including nodal involvement, is discussed below (see R.5.1).

5.5. Staging classification and prognostic factors

R.5.1. At initial diagnosis, we recommend using the ENSAT staging classification (Table 5) (+++0).

Reasoning:

Tumor staging is the most important prognostic factor. Specifically, the presence of metastases is by far the strongest indicator of poor prognosis. Several staging classifications have been proposed (29, 55, 70, 83, 84, 85, 86, 87, 88, 89). Among these, the ENSAT staging classification appears to be the most discriminant, but the differences between staging systems are minor (17) (see also Section 4.2). The panel felt strongly that a unique staging classification should be adopted across centers in order to improve standardization and documentation of clinical data and so improve patient care and enhance clinical research.

The ENSAT classification requires extensive imaging prior to surgery (see R.2.4), systematic lymph node resection, a complete surgical report (see R.3.3 and R.3.4) and a complete pathological report (see R.4.6.).

Table 5 ENSAT staging classification (17).

ENSAT stage	Definition
I	T1, N0, M0
II	T2, N0, M0
III	T1–T2, N1, M0 T3–T4, N0–N1, M0
IV	T1–T4, N0–N1, M1

T1: tumor ≤5 cm; T2: tumor >5 cm; T3: infiltration into surrounding tissue; T4: tumor invasion into adjacent organs or venous tumor thrombus in vena cava or renal vein; N0: no positive lymph node; N1: positive lymph node; M0: no distant metastases; M1: presence of distant metastases.

R.5.2. At initial diagnosis, we recommend taking the following factors into account when assessing the prognosis and treatment options: tumor stage, resection status, Ki67 index (or mitotic count), autonomous cortisol secretion and the patient's general condition (++)

Reasoning:

Of the many reported prognostic factors, tumor stage is the most important, because it reflects tumor extent. Especially the presence of metastases is strongly pejorative (see **R.5.1**). Resection status is also a strong prognostic factor (24, 26, 70) and should be carefully documented in the surgical and pathology reports. Furthermore, several studies have identified Ki67 immunostaining (or mitotic index) as major prognostic factor (58, 70, 87, 215, 224). As revealed by our systemic literature search, hypercortisolism was also one of the most consistent prognostic factors (see Section 4.2; (20, 35, 225).

Finally, the patient's general condition is an obvious prognostic factor, especially at advanced age (55). It is, however, noticeable that ACC patients often do not show altered general condition despite advanced disease.

From a patient perspective, the panel felt it important to consider two distinct scenarios. First, the risk of recurrence of patients with a localized (stage I–III) disease. For these patients, tumor stage, resection status and Ki67 labeling index are currently the main prognostic factors. This panel proposes to define two classes of localized ACC: low/moderate risk ACC includes stage I–II and R0 and Ki67 ≤10%, whereas high-risk ACC includes stage III, R1 or Ki67 >10%. However, the panel is aware that the dichotomy is arbitrary.

The second scenario to consider deals with the prognosis of patients with advanced disease (stage IV or recurrent disease not amenable to complete resection or R2 resection). In this situation, high tumor burden, high tumor grade, high Ki67 index and uncontrolled symptoms are major factors associated with worse prognosis (56, 70). However, there is consensus that the kinetics of tumor growth might also be relevant, particularly when making the decision for initiation of cytotoxic chemotherapy. However, this parameter has not been formally assessed. Although a correlation of tumor growth and tumor grade exists, it is not true for all tumors.

R.5.3. During follow-up, we recommend re-assessing prognosis at each evaluation, to guide treatment strategy (++)

Reasoning:

After complete surgery, the major prognostic factor is whether there is any tumor recurrence. At the time of recurrence, the main prognostic factors are time between initial surgery and recurrence, tumor burden and resectability (61, 62, 126, 136).

For patients with advanced disease, prognostic factors include Ki67 index, tumor burden, general patient condition and kinetics of tumor growth, as well as response to treatment. Limited evidence is available, but these factors make clinical sense and are corroborated by this panel's experience.

5.6. Methods and time interval for imaging and hormonal assessment during follow-up

R.6.1. We recommend following patients with regular cross-sectional imaging of the abdomen, pelvis and chest for disease recurrence or progression.

Reasoning:

A majority of disease recurrence and progression occurs either loco-regionally or with metastases to lung or liver and therefore should be identified by thoraco-abdomino-pelvic imaging. Bone metastases are infrequent and brain involvement is exceptional (23, 70, 226). In general, 18-FDG-PET/CT might provide additional information (see **R.2.4**) particularly prior to any surgical intervention (156, 227, 228). In addition, change in tracer uptake might inform about disease evolution.

R.6.2. After complete resection, we suggest radiological imaging every 3 months for 2 years, then every 3–6 months for a further 3 years. The majority of the panel suggests continuation of follow-up imaging beyond 5 years, but surveillance should then be adapted.

Reasoning:

There are no published studies that address specifically this issue. Therefore, the suggested imaging interval is in accordance with the practice at many expert centers, and with standards for other malignant tumors. In the experience of the panel few tumors with initial curative surgery will recur after more than 5 years and therefore a 5-year surveillance is likely to include >90% of the ACC population that will experience disease recurrence. However, the majority of the panel felt uncomfortable with the notion of complete cessation of imaging after

5 years and preferred for instance an annual imaging for another 5 years. After stopping regular imaging, patients and primary care physicians should remain vigilant in terms of potential symptoms or signs of late recurrences (see also **R.6.4**).

R.6.3. For advanced ACC, we recommend surveillance based on prognostic factors, expected treatment efficacy and treatment-related toxicity, as well as the available alternative treatment options.

Reasoning:

The imaging interval in advanced ACC depends on the ongoing treatment and the overall prognosis, but will usually be in 2–3 monthly intervals. For patients receiving mitotane alone, imaging intervals might be even more individualized (e.g. 2–5 months) based on tolerability and tumor kinetics. For patients undergoing loco-regional treatments, specific surveillance following procedures must be determined by the team performing these procedures, both to assess efficacy and adverse effects. For patients opting for entirely palliative management, without any antineoplastic therapy, no systematic imaging is advised.

R.6.4. In all patients, we recommend regular screening for hormone secretion.

Reasoning:

Biochemical evaluation together with clinical evaluation fulfills two purposes: (i) it allows in a few patients the early detection of recurrences and (ii) it also identifies patients that might benefit from early anti-hormonal therapy. Biochemical evaluation should focus on steroid hormones or metabolites that were present at the time of diagnosis of the initial tumor. However, some panelists favored a more complete hormonal evaluation, because some tumors might change their steroid secretion pattern over time.

5.7. Adjuvant therapy

R.7.1. For adrenal tumors with uncertain malignant potential, we recommend against adjuvant therapy (+000).

Reasoning:

In certain tumors it is difficult to define if the tumor is truly malignant (see **R.4.4**). Since all adjuvant therapies are associated with potential toxicity, only patients with

a definitive diagnosis of ACC should be considered for adjuvant treatment.

R.7.2. We suggest adjuvant mitotane treatment in those patients without macroscopic residual tumor after surgery but who have a perceived high risk of recurrence (+000). However, we cannot suggest for or against adjuvant therapy for patients at low/moderate risk of recurrence (stage I–II, R0 resection and Ki67 ≤10%) and adjuvant therapy options should be discussed on an individual basis.

Reasoning:

The panel is in favor of offering mitotane to patients with high risk of recurrence (stage III, or R1 resection, or Ki67 >10%; see **R.5.2**) despite the absence of completely convincing evidence (see Section 4.3). The panel decided on the use of mitotane in the adjuvant setting based on three arguments: (i) the perceived effects (28, 36, 90, 91, 92, 93, 94, 229) (acknowledging this is based on low quality evidence) (Fig. 1A and B); (ii) published data showing a tumor response in ~20% of patients with advanced disease treated with mitotane (13, 107, 143, 230) (iii) clinical experience of the panelists. For details on mitotane management (see Section 5.9).

Ki67 has emerged as the most powerful predictor of recurrence, and tumors with Ki67 ≤10% might represent a subset of patients with a good prognosis. For these patients, mitotane might be considered overtreatment. For this subset of patients (<30% of all localized ACCs), the ongoing ADIUVO trial, a prospective study where patients are randomized to adjuvant mitotane vs observation, will provide guidance in a few years.

There is no clinical, histopathological or molecular marker that reliably predicts response to mitotane although several markers have been proposed (231, 232). A study showed that mitotane levels may influence patient outcome in adjuvant setting (233) as it has been reported in advanced ACC. The secretory status of the tumor has a negative prognostic value but does not seem to influence response to treatment (20, 90, 230).

In patients who undergo surgery for recurrence of ACC but who have not previously had medical therapy, the decision on adjuvant mitotane should follow the same lines of reasoning.

R.7.3. Once the decision for mitotane treatment is established, we recommend starting mitotane as soon as clinically possible after surgery (+000).

Reasoning:

The ideal timing to start adjuvant mitotane is unknown; however, by analogy with other oncological adjuvant treatments we are convinced that starting mitotane within 6 weeks is ideal and would not initiate the treatment later than 3 months. This reasoning is sound with the biological concept of adjuvant therapy in general, and with the latency of mitotane to reach effective levels and anti-tumor activity. However, no published data are available to demonstrate the superiority of an early start of treatment or the lack of efficacy when started later than 3 months.

R.7.4. In patients without recurrence who tolerate mitotane in an acceptable manner, we suggest to administer adjuvant mitotane for at least 2 years, but not longer than 5 years (+000).

Reasoning:

The optimal duration of mitotane treatment is unknown and practice varies among different centers. Some members of the panel continue treatment for 3–5 years if tolerated (234), while others discontinue after 2–3 years (3, 13, 19). Prognostic factors at diagnosis, patient compliance with treatment and plasma mitotane levels reached during treatment are factors that influence duration of treatment. Mitotane may possibly act as an oncostatic measure in those patients (235, 236). However, the rate of recurrence 5 years after surgery is potentially too low to advise continuation of therapy treatment beyond this time point. Treatment-related toxicity and lack of experience in long-term administration are additional factors portending against indefinite treatment.

R.7.5. The panel did not come to a definitive consensus on adjuvant radiation therapy. However, we suggest against the routine use of radiation therapy in patients with stage I–II and R0 resection (+000). The panel suggests considering radiation in addition to mitotane therapy on an individualized basis therapy in patients with R1 or Rx resection or in stage III.

Reasoning:

The systematic literature search indicated that radiation therapy is able to prevent local recurrence but does not significantly affect distant recurrences or overall survival (91, 98, 99, 100, 237, 238) (see Section 4.3 and Fig. 1). However, distant metastases account for about 40–60% of tumor relapses (54, 61, 90) and have large impact on the

patient prognosis and are more difficult to treat effectively. Conversely, prevention of the complications due to local recurrence argues in favor of radiation therapy. Adjuvant radiation therapy might be particularly reasonable in patients with R1 resection. This was already suggested by earlier studies and also by a very recent study that was published after the meta-analysis associated with this report (239).

Radiation therapy is not advised for patients who experienced widespread tumor spillage during surgery. The combination of radiation therapy and mitotane is biologically sound (240, 241) and possible but at the cost of greater toxicity (e.g. constitutional, gastrointestinal and liver toxicity). In addition, there is concern that radiation therapy may delay systemic therapy or prevent effective mitotane administration resulting in lower drug levels.

R.7.6. If adjuvant radiation therapy is administered, we recommend starting treatment as soon as clinically possible after surgery and to deliver radiation therapy at the dose of 50–60Gy to the previous tumor bed in fractionated doses of approximately 2Gy each (+000).

Reasoning:

Radiation therapy was delivered following this scheme in previous observational studies (91, 98, 99, 100, 238) and lower dosage seems to be less effective (237).

R.7.7. The panel did not come to a definitive consensus on adjuvant use of cytotoxic drugs. We suggest against the routine use of cytotoxic drugs in the adjuvant setting. However, the panel suggests considering adjuvant chemotherapy in selected patients with very high risk for recurrence.

Reasoning:

Scanty data are available on the use of cytotoxic drugs in an adjuvant setting and the studies did not control the results of treatment with a matched control group of untreated patients or patients treated undergoing mitotane therapy (242). However, the majority of panelists favor discussion of this option with patients with high risk of recurrence (ideally in the setting of clinical trials). Despite the lack of published data, some members of the panel are currently using cisplatin, with or without etoposide, in patients at perceived very high risk of recurrence (e.g. Ki67 >30%. large tumor thrombus in the vena cava, stage IV or R1 resection).

In patients with R2 resection or tumor spillage, the same considerations for treatment of (locally) advanced disease should apply (see Section 5.8).

5.8. Treatment of recurrent and/or advanced ACC

Clinical scenarios of patients with recurrent and/or advanced ACC are highly variable. Therefore, we try to provide recommendations for at least the most frequent presentations (Fig. 4). Although a (small) proportion of patients experience a relatively long survival (13, 29, 70, 243), the prognosis of advanced/metastatic ACC is generally limited. The goal of any therapy is to palliate symptoms and prolong survival. In this situation, it is even more important than that in other scenarios to tailor treatment on an individual basis taking into account the disease extent, the patient performance status and particularly the preference of the patient.

R.8.1. For patients presenting at time of initial diagnosis with limited intra-abdominal metastases we suggest surgical therapy if complete resection of all lesions seems feasible (+000). In case of limited extra-abdominal lesions, we suggest adrenal tumor resection in conjunction with therapy aiming at long-term tumor control of the other lesions (+000). In all patients, we recommend to start mitotane therapy as soon as clinically possible (+000).

Reasoning:

Complete surgery is the best chance to reach long-term disease control although the likelihood of complete tumor removal in advanced ACC is low. If clinically possible, a single surgical approach should be planned. If a one-time surgical approach is impossible (e.g. due to extra-abdominal metastases), other loco-regional approaches (see R.8.2) should be discussed within a multidisciplinary expert team and the patient on an individual basis. Local expertise and preference of the patient should be taken into account. Any initial treatment (surgery, local and/or medical therapy) should be initiated in a timely fashion ($\leq 4-6$ weeks following initial diagnosis).

In general, prognostic parameters (see R.5.2 and R5.3) should influence the overall treatment strategy. If the disease has an aggressive behavior (i.e. increase in tumor burden (e.g. increasing size of existing tumors or new metastasis) observed in subsequent imaging performed within a few weeks) systemic options (chemotherapy plus mitotane) may be favored. If partial responses or

prolonged stabilization are then observed, surgery and/or additional loco-regional options might be particularly useful ('neo-adjuvant approach', see also R.8.3). This strategy could also be potentially advantageous in patients for whom tumor shrinkage might allow a more conservative surgical approach (i.e. patients in whom radical surgery would imply the complete or partial removal of neighboring organs such as kidney, spleen and part of the pancreas) (244).

These patients are at high risk for recurrence and therefore adjuvant mitotane seems to be justified (245). Addition of cytotoxic drugs might be a possible option (although data are lacking; see also R.7.7).

R.8.2. The panel is convinced that in addition to surgery other local therapeutic measures (e.g. radiation therapy, radiofrequency ablation, cryoablation, microwave ablation, chemoembolization) are of value for therapy of advanced ACC. We suggest individualization of the decision on the method of choice based on the localization of the tumor lesion(s), local expertise, prognostic factors and patient's preference (+000).

Reasoning:

Published data on local therapies in advanced ACC are very limited (140, 141, 142, 237) and summarized in Appendix 6. However, the experience of many panelists provides additional support of efficacy of these local measures. Nevertheless, it is impossible to indicate which method is superior. Most importantly, the expertise of the local team in applying these methods should be taken into account when discussing this issue with patients in a shared decision-making process.

R.8.3. We suggest against the routine use of adrenal surgery in case of widespread metastatic disease at the time of first diagnosis (+000).

Reasoning:

Despite the lack of large studies addressing this particular question, a majority of the panel agreed that patients with widespread and unresectable disease will usually not benefit from surgery. However, a few panelists suggested that adrenalectomy could be an option if technically possible.

In patients who respond very well to systemic therapy, surgery should be considered at an appropriate time point; especially if complete resection becomes feasible

(‘neo-adjuvant approach’). However, the published evidence for such an approach is scanty (244, 246).

In selected cases (e.g. patients with severe hormone excess) debulking surgery might be an option, although anti-hormonal drugs (see **R.10.1**) should be considered here. In these cases, surgery might be especially reasonable if >80% of the tumor burden can be removed safely. In patients with a poor clinical condition and significant localized metastatic burden, additional localized therapies (see **R.8.2**) may be considered as an alternative.

R.8.4. In patients with advanced ACC at the time of diagnosis not qualifying for local treatment, we recommend either mitotane monotherapy or mitotane+EDP depending on prognostic parameters (+++0).

Reasoning:

Mitotane is the treatment of choice for patients with advanced ACC (for details about the management of mitotane see Section 5.9). However, a very recent cohort study suggests that patients with metastatic disease at the time of primary diagnosis might not be the ideal candidates for mitotane monotherapy (230). Furthermore, unfavorable prognostic parameters (e.g. high tumor burden, uncontrolled symptoms, high proliferative index, clinical evidence of a fast growing tumor) are important factors favoring a more aggressive/more rapidly active therapeutic approach. If more aggressive therapy is indicated, then the combination of EDP in addition to mitotane (EDP-M) is the most validated regimen (30). EDP-M is the only treatment approach in ACC that is successfully evaluated in a randomized trial, the FIRM-ACT study. It has to be highlighted, however, that only progression-free survival was significantly improved in comparison to the alternative therapy (in this case streptozotocin plus mitotane; 5.0 vs 2.1 months; HR 0.55; 95% CI: 0.43–0.69; $P < 0.001$), whereas for overall survival, the crossover design might have diluted the results (14.8 vs 12.0 months, HR 0.79; 95% CI: 0.61–1.02; $P = 0.07$).

The administration of EDP-M comes with risk of adverse events, and it is important that the treatment will be administered by physicians with sufficient experience in oncology treatments. All cytotoxic drugs induce asthenia, nausea, vomiting and reversible myelotoxicity. In addition, etoposide might lead (among other adverse effects) to liver toxicity and reversible alopecia, doxorubicin to congestive heart failure and reversible alopecia; cisplatin to renal toxicity, ototoxicity and peripheral neuropathy. In some patients, the risks might even outweigh the

benefits (especially in patients with reduced performance status). If there are concerns about the use of doxorubicin, cisplatin/carboplatin with or without etoposide (EP or P) might be an alternative option. Carboplatin may be an alternative to cisplatin, particularly when cardiac or renal function is compromised. Again, in this cohort, loco-regional treatment options may be particularly applicable.

Several studies have tried to find biomarkers that predict response to cytotoxic therapy in ACC (247, 248, 249, 250). However, no reliable marker could be identified yet.

A few centers prefer the combination of etoposide and cisplatin (EP), because there is no single study proving that EDP is truly superior to EP. In patients with poor overall health cisplatin with mitotane may be an option. However, the evidence for etoposide+cisplatin or cisplatin alone is based only on small phase II studies (109, 110, 122).

There is limited evidence that standard chemotherapeutic agents may be more active in the presence of elevated mitotane concentrations (30, 104, 251), but the panel is not in favor of delaying cytotoxic therapy for this reason for more than 14 days. Several centers start mitotane and cytotoxic therapy in parallel.

R.8.5. In patients with recurrent disease and a disease-free interval of at least 12 months, in whom a complete resection/ablation seems feasible, we recommend surgery or alternatively other local therapies (+000). We recommend starting mitotane as soon as possible after the intervention.

R.8.6. We recommend EDP-M as first-line treatment if the time interval between last surgery/loco-regional therapy and recurrence is less than 6 months (++00), rather than repeat loco-regional measures.

R.8.7. For all other patients with recurrent disease an individualized approach is needed.

Reasoning:

It has been suggested that patients with a disease-free interval of 12 months or more have a significantly better prognosis and long-term disease control is achievable, if loco-regional measures are successful (61, 126). The choice of different loco-regional therapies depends again on benefit/risk ratio, local availability and expertise, and the clinical scenario in a given individual patient. Most panelists favor surgery (if complete resection is feasible) followed by mitotane therapy.

If the recurrence occurs during adjuvant mitotane therapy, additional measures could be considered. In patients with local recurrence, adjuvant radiation therapy after surgery should be discussed. In other scenarios, additional administration of cytotoxic drugs should be discussed with the patient, particularly when mitotane blood levels were in the recommended range >14 mg/L.

Patients with early recurrence usually suffer from a very aggressive tumor, which most likely cannot be controlled by surgery or localized therapies. Decision making should incorporate the concern that any local measure will only delay the administration of systemic therapy. Similar to the discussion to R.9.3, the FIRM-ACT data indicate EDP-M as the most effective form of therapy. An exception might be patients in whom incomplete initial surgery is the most likely cause for early progression. In these selected patients repeat surgery at an expert center might be an appropriate alternative (see **R.3.6**).

Patients with recurrence between 6 and 12 months after primary surgery usually have a poor prognosis and would, therefore, benefit from a more aggressive therapeutic approach (e.g. EDP-M). However, this decision should be discussed with the patient taking into account prognostic parameters (see Section 5.5), the feasibility of a R0 resection and patient's general condition. Patients with a disease-free interval >12 months, in whom complete resection or loco-regional therapy is not feasible and who are currently not treated with mitotane, might be good candidates for mitotane monotherapy (230).

R.8.8. In patients who progress under mitotane monotherapy, we recommend to add EDP (+++O).

Reasoning:

Mitotane is a slow-acting drug and in patients with rapidly progressing tumor, it might be too slow or not effective enough. In these patients, based on the FIRM-ACT data (30), additional administration of EDP is the first choice (for alternatives see Reasoning R.8.4). However, if the tumor burden is limited despite obvious progression, another 2–3 months mitotane monotherapy could also be justified, particularly if adequate mitotane levels have not been achieved. In these cases, additional loco-regional options should be considered.

R.8.9. In patients who respond to medical therapy (including achievement of long-term stable disease), we suggest re-considering local measures aiming at long-term tumor control.

Such an approach could be also considered in patients attaining a generally good control of the disease, in which a limited number of lesions are progressing.

Reasoning:

In some patients, in whom long-term disease control could be achieved, loco-regional measures (in addition to ongoing medical therapy) might be able to reach complete remission or at least significantly reduce tumor burden (101). In patients with 'mixed responses'; e.g. progressive disease limited to few lesions, loco-regional options might be reasonable to add to the ongoing medical therapy.

R.8.10. In patients who progress under EDP-M we suggest considering additional therapies including clinical trials on an individual basis (+OOO).

Reasoning:

Several drugs and drug combinations have been tested in advanced ACC. However, except EDP-M none of them has been successfully evaluated in large randomized trials. Figure 2 outlines the outcomes of the different approaches. However, this figure has to be interpreted with great caution, because differences in the characteristics of the patients included in the different cohorts preclude direct comparison between studies. Therefore, it is not possible to draw definitive conclusions. Due to the limited treatment options, the panel clearly favors enrollment of patients with progressing tumors in clinical trials investigating experimental therapies including phase I trials. However, the panel felt that despite the lack of convincing data, some guidance might be helpful for patients that cannot be enrolled in clinical trials (Table 6). Beyond cisplatin-based therapies, the two reasonably well-studied second-line cytotoxic regimens are gemcitabine+capecitabine (+/- mitotane) (104, 124) and streptozotocin+mitotane (30, 242). However, objective response rates are clearly below 10% and median progression-free survival (PFS) is generally <4 months, but a few patients with long-term disease control and even complete responses in single patients are described. Nevertheless, a few panelists argued against the use of streptozotocin, because median PFS in the FIRM-ACT trial was only two months (30). As for EDP, these cytotoxic drugs should be administered only by physicians experienced with chemotherapy. Typical adverse effects of streptozotocin are nausea, vomiting, diarrhea, renal and liver toxicity

Table 6 Systemic therapies for recurrent/advanced ACC.

First-line therapies (see text for details)

- Surgery +/- other local measures (see **R.8.1** and **R.8.4**)
- Mitotane monotherapy
 - details on the management see Section 5.9
- Etoposide, doxorubicin and cisplatin (EDP) plus mitotane (EDP/M) (30)
 - Every 28 days:
 - day 1 40 mg/m² doxorubicin (D)
 - day 2 100 mg/m² etoposide (E)
 - day 3+4 100 mg/m² etoposide (E) +40 mg/m² cisplatin (P)
 - Plus oral mitotane aiming at a blood level between 14 and 20 mg/L
 - In patients unfit for the EDP-M regimen, (E)P-M may constitute a reasonable alternative.
 - Every 28 days
 - day 1 100 mg/m² etoposide (E)
 - day 2+3 100 mg/m² etoposide (E) +40 mg/m² cisplatin (P)

Additional therapeutic options

- Consider enrollment of patients in clinical trials (www.clinicaltrials.gov)
- Consider loco-regional therapies
- Gemcitabine plus capecitabine (104, 124)
 - 800 mg/m² gemcitabine on days 1 and 8 (repeated every 3 weeks)
 - 1500 mg capecitabine orally per day in a continuous fashion
 - Mitotane can be continued (individualized decision)
- Streptozotocin plus mitotane (Sz/M) (30)
 - Induction: day 1–5: 1 g Sz/day
 - Afterwards 2 g/day Sz every 21 days
 - Plus oral mitotane aiming at a blood level between 14 and 20 mg/L

and of the association gemcitabine and capecitabine nausea, vomiting and reversible myelotoxicity.

Loco-regional measures can be particularly useful when progression is limited, or only affects limited areas (e.g. single organs). In these cases, such localized therapies (see **R.8.2**) might be able to provide higher response rates for these specific organ/tissue areas than second-line systemic options.

Several tyrosine kinase inhibitors have been investigated in advanced ACC (102, 108, 116, 118), but the results were largely disappointing. However, in retrospect, drug efficacy could have been hampered by increased metabolism of the TKI due to mitotane-induced CYP3A4 activity. Nevertheless, currently no specific TKI can be suggested for the treatment of advanced ACC. Targeting the IGF2/IGF receptor signaling pathway was pathophysiologically a very promising approach and initial small studies suggested some efficacy (113, 117, 125, 252, 253, 254, 255, 256, 257, 258). However, the large placebo-controlled phase III GALACCTIC trial demonstrated that the IGF1R inhibitor linsitinib did not improve progression-free or overall survival

(102). Therefore, monotherapy with drugs targeting this pathway are not reasonable for therapy in an unselected patient population.

R.8.11. The optimal timing of mitotane discontinuation is currently unknown and the panel could not come to a specific recommendation on this issue.

Reasoning:

A recent cohort study reported that discontinuation of mitotane should be considered in patients who experienced progressive disease after one year of mitotane therapy (259). Part of the panel considers mitotane discontinuation when there is progressive disease despite mitotane blood levels above 14 mg/L while others often continue mitotane indefinitely in their practice. Tolerability of treatment is an important issue to consider in this decision. Moreover, it has to be considered that CYP3A4 induction by mitotane can greatly enhance metabolism of many drugs (260), including a number of experimental anti-ACC compounds, and so potentially limit their effectiveness.

5.9. Special considerations on mitotane

If mitotane therapy is started (independent of the clinical scenario) the following issues have to be considered.

R.9.1. We recommend starting therapy with mitotane in an escalating regimen depending on the performance status of the patient as well as the tolerability in the first weeks.

Reasoning:

There are different regimens to administer mitotane, but none of them has been proven to be superior. In patients with good performance status some panelists use a high starting dose approach: mitotane is administered at a starting dose of 1.5 g/day and if well tolerated from a gastrointestinal perspective the dose is increased on day two to 3 g/day, on day three to 4.5 g/day and on day four to 6 g/day (261, 262). This dosage will be administered until first mitotane blood level is assessed. In this high-dose regimen, it is strongly recommended to measure mitotane blood levels 2–3 weeks after initiation of therapy. Afterwards dosage will be adjusted according to blood concentrations and tolerability. Other panelists prefer a low starting dose approach. With this approach, mitotane is administered at a starting dose of 1 g/day and

increased when there is good gastrointestinal tolerance every 3 days by 0.5 g up to a total dose of 3.0–4.0 g/day and then adjusted according to blood concentrations and tolerability (234, 263, 264).

In a formal comparative pharmacokinetic study, the high-dose starting regimen led to slightly higher mitotane plasma levels within 12 weeks of treatment, and more patients reached the target level of 14 mg/L (265). However, these results were not statistically significant due to lack of power. Beyond these two regimens, there is a variety of other possibilities and choice depends on personal practice, clinical scenario and patient conditions.

Mitotane is a lipophilic drug and is supposed to be better absorbed from the gut with a high fat content of the diet, e.g. with milk or chocolate. (266). In case of limited gastrointestinal tolerance, symptomatic treatments of nausea and or diarrhea may be proposed.

R.9.2. We recommend monitoring of blood concentration of mitotane. The general aim is to reach a mitotane blood level above 14 mg/L (+000).

Reasoning:

As long as mitotane plasma levels are increasing and have not yet reached a plateau at >14 mg/L, mitotane plasma levels will be assessed every 3–4 weeks. Mitotane plasma level determination is best done as morning trough

sampling, at least 12 h after the last dose, preventing false high levels (267). When mitotane plasma levels have reached a plateau, it is usually sufficient to measure blood levels every 6–12 weeks.

Usually it takes several weeks (sometimes months) to reach mitotane levels >14 mg/L. As long as the concentration is <14 mg/L it is reasonable to continue to increase the dosage if this is tolerated by the patient. Due to slow pharmacokinetic characteristics, the dose of mitotane can be reduced in most patients as soon as a plasma level of >14 mg/L is reached. Over time, mitotane dosage will be titrated to the best tolerable dose while maintaining a plasma level >14 mg/L. Most patients experience adverse effects to a certain extent and these usually correlate with the plasma mitotane level (although there is major inter-individual variability) (Table 7). However, some gastrointestinal adverse effects (like diarrhea) seem to correlate more with the oral dosage than with the plasma level and occur more frequently in the first phase of treatment (146, 234, 263, 264, 268). Several studies (107, 112, 269) have shown that CNS-related adverse events in particular occur more frequently when the plasma mitotane is >20 mg/L. Therefore, many experts recommend aiming to keep plasma concentrations below 20 mg/L. However, it can be speculated that higher plasma levels may also be associated with better clinical efficacy. Furthermore, some patients do not experience relevant adverse events even at plasma levels well above 20 mg/L.

Table 7 Adverse effects during mitotane treatment.*

Adverse effect	Frequency
Gastrointestinal: nausea, vomiting, diarrhea, anorexia	Very common
Adrenal insufficiency	Very common
CNS: lethargy, somnolence, vertigo, ataxia	Common
Confusion, depression, dizziness, decreased memory	Common
Increase of hepatic enzymes (in particular gamma-GT)	Very common
Liver failure	Rare
Hepatic microsomal enzyme induction with increased metabolism of glucocorticoids and other steroids and barbiturates, phenytoin, warfarin, and many other drugs (Appendix 7)	Very common
Increase in hormone-binding globulins (CBG, SHBG, TBG, etc.)	Common
Disturbance of thyroid parameters (interference with binding of T4 to TBG, total T4↓, free T4↓, TSH↓)	Very common
Hypercholesterolemia, hypertriglyceridemia	Very common
Gynecomastia	Very common
Skin rash	Common
Primary hypogonadism in men	Common
Prolonged bleeding time	Common
Leucopenia	Common
Thrombocytopenia, anemia	Rare
Autoimmune hepatitis	Rare

Frequency is defined according to the following convention: very common ($\geq 1/10$), common ($\geq 1/100$ to $< 1/10$), uncommon ($\geq 1/1000$ to $< 1/100$), rare ($\geq 1/10\ 000$ to $< 1/10\ 000$), very rare ($< 1/10\ 000$), not known (cannot be estimated from the available data).

*Modified by the authors based on information published by the European Medicine Agency (EMA): http://www.ema.europa.eu/ema/index.jsp?curl=pages/medicines/human/medicines/000521/human_med_000895.jsp&mid=WC0b01ac058001d124 and clinical experience.

Regarding the lower limit it has to be acknowledged that in at least a few patients objective responses are seen even though plasma levels of >14mg/L were not achieved (230). Therefore, some panelists favored a target range of plasma mitotane of 8–30mg/L, whereas others aim at an individualized target level of mitotane.

Most studies addressing plasma mitotane levels analyze patients with advanced disease. However, there is one study suggesting that the same target level is also reasonable for the adjuvant setting (233). Therefore, the panel is in favor to use the same approach for both patient groups.

R.9.3. We recommend glucocorticoid replacement in all patients treated with mitotane (except those with ongoing cortisol excess). We suggest to using hydrocortisone/cortisone acetate for this purpose. Due to increased steroid clearance and increase cortisol-binding globulin at least twice the standard replacement dose is usually required.

Reasoning:

A possible strategy is to start concomitant treatment on day one of mitotane treatment with hydrocortisone 20mg/day. Alternatively, patients can be instructed to start hydrocortisone later (e.g. after 2–3 weeks or in case they experience adrenal insufficiency), because impairment of glucocorticoid effectiveness is rarely observed within the first few weeks. Due to the increased clearance and increased cortisol-binding globulin (268, 270, 271, 272) with increasing mitotane plasma levels and based on clinical symptoms, the total hydrocortisone replacement dose will usually increased to a typical total daily dose of 50mg in two or three divided doses. However, some patients require daily dosages up to 100mg. There is no reliable laboratory marker to guide the optimal dosage of hydrocortisone (271), which has to be based on clinical judgment similar to the management of patients with adrenal insufficiency (208). Mitotane-induced increase in cortisol-binding globulin may confound interpretation of serum cortisol measurement. The measurement of free cortisol may offer additional information, but more studies are required to clarify the value of this method (273). Some panelists measure plasma ACTH and use ACTH levels more than 2-fold of the upper limit of normal as evidence for insufficient glucocorticoid replacement. Other centers prefer a combined measurement of plasma

ACTH and 24-h urine free cortisol levels to assess adequacy of and optimize glucocorticoid replacement for patients receiving mitotane. However, when urinary cortisol is measured by immunoassays, interference by cortisol metabolites induced by mitotane might occur.

In case of acute adverse events and/or hospital admission, patients should be treated intravenously with high-dose hydrocortisone (e.g. 100mg TID) until resolution of symptoms.

Some patients experience symptoms and signs of insufficient mineralocorticoid activity (hyperkalemia, hyponatremia, hypotension, decreased well-being) despite full-dose substitution with hydrocortisone. In these patients, addition of fludrocortisone should be considered. Clinical judgment, electrolytes, and plasma renin concentration can be used for decision making whether to start fludrocortisone (146, 234, 264, 268).

R.9.4. We recommend regular monitoring of mitotane-induced adverse effects (Table 7) and to treat them appropriately (Table 8). To increase tolerability of mitotane, we suggest starting supportive therapy ideally before severe toxicity occurs.

Reasoning:

In addition to adrenal insufficiency (see **R.9.3**) mitotane treatment comes with a plethora of potential adverse events (268) (Table 2). Therefore, it is important to evaluate the patients regularly (e.g. in the first 6 months every 3–4 weeks, thereafter every 6–12 weeks).

Gastrointestinal adverse effects are frequent, particularly in the first months of therapy. Supportive therapy should include antiemetic and anti-diarrheal medication, as needed. Some centers even start supportive therapy at initiation of mitotane therapy. However, one has to be aware that nausea may also be a sign of adrenal insufficiency that needs recognition and appropriate treatment. Nevertheless, it should be emphasized that despite optimization of dosing schedules, the key factor influencing build-up of appropriate mitotane plasma levels is patient tolerability, so efforts should be made in order to optimize this.

In case of central nervous system (CNS) adverse effects grade 2 (moderate) and/or gastrointestinal adverse effects grade 3 (severe, but not life-threatening), mitotane dose should be reduced by 1–1.5g/day. In case of CNS severe, but not life-threatening (grade 3) adverse effects or any relevant grade 4 toxicity (life-threatening), and/

Table 8 Monitoring during mitotane treatment.

Parameter	Interval	Comment
Recommended monitoring		
Mitotane blood level	Every 3–4 weeks, as soon as plateau of blood level is reached every 2–3 months	Target blood level >14 mg/L (details see R.9.2)
GOT, GPT, bilirubin, (gGT)	Initially every 3–4 weeks, after 6 months every 2–3 months	GGT is invariably elevated without clinical consequences. If other liver enzymes are rapidly increasing (>5-fold of baseline), there is risk of liver failure: interrupt mitotane
Blood count	Initially after 3–4 weeks, then every 3–4 months	Check for rare and in most cases not significant leucopenia, thrombocytopenia, and anemia
Suggested monitoring		
ACTH	Suspected glucocorticoid deficiency or excess	Glucocorticoid status is difficult to determine Target: ACTH in the normal range or slightly above
TSH, fT4	Every 3–4 months	Disturbance of thyroid hormones is frequent Thyroid hormone replacement is only recommended in patients with clinical symptoms of hypothyroidism
Renin	Every 6 months	If renin ↑ and clinical symptoms of hypoaldosteronism are present, add fludrocortisone
Cholesterol (HDL, LDL)	Every 3–4 months (in adjuvant setting)	If LDL/HDL cholesterol ↑↑ consider treatment with statins in selected cases
Testosterone and SHBG in men	Every 3–4 months (in adjuvant setting)	If testosterone is low and clinical symptoms of hypogonadism are present add testosterone

or increase of liver enzymes >5 times baseline (except GGT), mitotane should be interrupted until significant improvement of symptoms occurs and be restarted at 50–75% of the last dose.

Assessment of thyroid hormone status (TSH, FT4, every 3 months) is advised as mitotane may induce a clinical picture similar to central hypothyroidism (268, 274), possibly through a direct effect on the pituitary gland or induction of thyroid hormone metabolism. Replacement therapy with levothyroxine can be considered for these patients.

In men with signs of hypogonadism, assessment of testosterone and sex hormone-binding globulin levels is warranted, as hypogonadism is common (268). Mitotane-induced increase in SHBG may confound interpretation of testosterone measurement. Testosterone supplementation may be considered in patients with low testosterone and symptoms of hypogonadism, but inhibition of 5- α reductase might prevent full activity of testosterone (270).

Ovarian steroid synthesis is less affected but women in childbearing age treated with mitotane may develop multiple, and sometimes huge, ovarian cysts that may be painful and sometimes require treatment.

Cholesterol levels very frequently increase during mitotane treatment (275). Hypercholesterolemia can be treated with statin therapy using agents not metabolized by CYP3A4 (e.g. rosuvastatine or pravastatine). However, HDL cholesterol is usually also elevated significantly and this should be taken in consideration. Thus, statin therapy might only be beneficial in selected patients (e.g. with good

prognosis in an adjuvant setting, high LDL cholesterol and additional high cardiovascular risk factors). Therefore, an individual decision making regarding the benefits of any lipid lowering therapy is necessary.

Psychological and social aspects of treatment should not be neglected, i.e., professional counseling may be warranted. Follow-up on patient's well-being may be performed by questionnaire-based assessment of toxicity upon the start of the treatment and by repeating this assessment every 3 months.

R.9.5. We recommend being aware of significant drug interactions of mitotane (e.g. due to strong induction of CYP3A4). All concomitant medication should be checked for CYP3A4 interactions and substituted for an alternative if necessary and available. Other care providers should be advised not to initiate other drug therapies without consultation.

Reasoning:

A comprehensive (but not exhaustive) summary of relevant drug interactions with mitotane is provided in Kroiss *et al.* (260) and in the Appendix 7.

5.10. Other supportive therapies

R.10.1. We recommend medical therapy to control hormone excess in all patients with clinically relevant hormone-producing ACC.

Reasoning:

Overt glucocorticoid excess causes significant morbidity, such as diabetes, osteoporosis, muscle weakness and immunosuppression, conditions that can impact quality of life and increase mortality. Mitotane is effective in controlling adrenocortical hormone excess syndromes, but its efficacy is delayed by several weeks. In general, mild hormone secretion can be effectively managed by mitotane alone. However, severe Cushing syndrome needs a more rapid control. Furthermore, these patients should receive appropriate anticoagulation and also pneumocystis directed antibiotic prophylaxis until cortisol levels are safely controlled (276). In selected patients, surgery might even be postponed for few weeks until Cushing syndrome is partly under control with the use of rapid agents inhibiting steroidogenesis (i.e. metyrapone). However, some panelists argued that surgery might be the fastest way to control severe hypercortisolism.

Available steroidogenic enzyme inhibitors and steroid receptor antagonists are able to attain quick reduction of cortisol effects. Anti-hormonal agents can be initiated together with mitotane. Once therapeutic mitotane levels are established, anti-steroidogenic action is also maximized, and other anti-hormonal drugs can be reduced guided by tolerability, symptoms and biochemical measurements. If possible doses should be titrated to normalization of hormone levels, or in the case of receptor antagonists to improved well-being, accepting that assessment of this can be challenging in cancer patients.

Despite the lack of comparative studies, the majority of panel members considers that metyrapone is the first therapeutic choice for the management advanced ACC patients with severe Cushing syndrome. The drug is well tolerated and can be safely administered in association with mitotane and cytotoxic chemotherapy (277). Moreover, its metabolism and elimination are not altered by concomitant mitotane. Ketoconazole an inhibitor of several key cytochrome P450 (CYP) enzymes involved in multiple steps of steroidogenesis in the adrenal cortex, is another alternative, but often less effective than metyrapone and requires regular monitoring of liver function tests. Its advantage is that it also inhibits androgen production. Ketoconazole should be avoided at initiation of mitotane therapy because both substances are potentially hepatotoxic and it will be difficult to attribute the hepatotoxicity to one or the other drug. Hypercortisolemia can also be treated with mifepristone, a glucocorticoid antagonist, but dosing is based on clinical judgment as cortisol levels remain elevated or rise further on therapy (278). Moreover, the high circulating cortisol

levels when on mifepristone may cause mineralocorticoid effects, including hypertension and hypokalemia that necessitate treatment with high doses of spironolactone. Patients treated with enzyme inhibitors or receptor antagonists need to be educated about symptoms and signs of adrenal insufficiency. All patients at risk for adrenal insufficiency need to be supplied with emergency medication and instructions. Intravenous etomidate can be used for seriously ill patients with severe hypercortisolemia who cannot take oral medication.

In the management of severe Cushing syndrome, loco-regional options (see **R.8.2**) should also be discussed, in selected cases.

Androgen excess in women can impact quality of life due to hirsutism and virilization. It can be treated with androgen receptor antagonists, such as bicalutamide, flutamide, or spironolactone.

Only a small fraction of all tumors produce aldosterone, leading to hypertension and hypokalemia. Mineralocorticoid excess is best treated with mineralocorticoid receptor antagonists, such as spironolactone or eplerenone. However, patients with severe Cushing syndrome may also experience hypokalemia, related to mineralocorticoid receptor activation. In case of severe hypokalemia, spironolactone and epithelial sodium channel inhibitors such as amiloride can be used, potentially at high doses, along with potassium supplementation. In such cases, frequent serum electrolyte measurement, initially several times a week, are mandatory, as there is a risk of rapid occurrences of hyperkalemia and hyponatremia.

In the rare situation of estradiol production by tumors in male patients, therapy with estrogen receptor antagonists or aromatase inhibitors could be considered.

R.10.2. We recommend therapy with anti-resorptive treatment in patients with bone metastasis.

Reasoning:

Bone metastasis in cancer patients are associated with poor quality of life due to bone pain and increased risk of adverse skeletal-related events (SREs) such as pathological fractures, spinal cord compression and hypercalcemia. Several randomized phase III trials have demonstrated that bone resorption inhibitors such as bisphosphonates and denosumab are efficacious in the prevention of SREs in patients with bone metastasis from breast, prostate, lung and others primary malignancies. No data are available for ACC patients. However, based on these results, it has

become general practice to treat patients with any kind of bone metastasis with anti-resorptive therapies. The administration of denosumab or bisphosphonates in 'oncological doses' in association with calcium intake and vitamin D supplementation are therefore advisable in ACC patients with metastatic bone disease, with the aim to prevent adverse SREs and improve control of bone pain.

In patients with ACC with Cushing syndrome that cannot be otherwise controlled anti-resorptive treatment, using 'anti-osteoporotic doses', should be considered, because it is well established that glucocorticoid excess increases the risk of osteoporotic fractures. Since fracture risk declines rapidly after lowering excess cortisol, or antagonizing its effects, anti-osteoporotic therapies are usually not required once cortisol secretion is controlled (either by surgery or medical therapy).

R.10.3. We recommend palliative radiation for symptom palliation in advanced/metastatic ACC patients.

Reasoning:

Palliative radiation therapy is a commonly utilized intervention for symptom relief among patients with metastatic cancer. Two schedules of irradiation are commonly used, which include 8 Gy in a single fraction or 30 Gy in ten fractions. This treatment modality is highly effective in achieving relief of symptoms arising from bone metastases, with positive responses in up to 50–90% of cancer patients (279, 280). Painful bone metastases are, therefore, the main indication of palliative radiation in metastatic ACC patients (237). Other indications are symptomatic recurrences, severe mass effect and the rare case of brain metastases.

R.10.4. We recommend integrating palliative care into standard oncology care for all patients with advanced ACC.

Reasoning:

According to the WHO palliative care is defined as 'an approach that improves the quality of life of patients and their families facing the problems associated with life-threatening illness, through the prevention and relief of suffering by means of early identification and impeccable assessment and treatment of pain and other problems, physical, psychosocial and spiritual' (WHO: WHO definition of palliative care. <http://www.who.int/cancer/palliative/definition/en/>).

As previously stated, the goal of care for metastasized ACC is to obtain long-term disease control and prolong patient survival. Although prognosis of patients with advanced ACC is often poor, there is a patient subset destined to obtain a relatively long survival, while treated with antineoplastic therapies. The needs of patients with cancer and their families have changed over time. According to the ASCO guidelines the best model to manage metastatic patients is to integrate palliative care early in the course of the disease and throughout the trajectory of care, extending to long-term survivorship as well as end-of-life (hospice) care. In this integrated approach the primary endocrinologists and oncologists focus on the primary oncologic disease, and the palliative care team addresses the majority of the patient's physical and psychological concerns. The team plans all therapy aiming to integrate patient wishes and employ treatment options balancing quality of life and increased survival with therapy associated risks and complications (281).

R.10.5. We suggest counseling for fertility protection in female patients in reproductive age. Fertility counseling should not only be restricted to patients undergoing cytotoxic chemotherapy, but also given to patients who plan to embark on mitotane therapy.

Reasoning:

A considerable proportion of patients are diagnosed with ACC during their reproductive years. Several drugs used to treat ACC harbor significant risk for impairment of fertility or the exact risks are unknown (e.g. mitotane). On the other hand, in recent years several treatment options for preservation of fertility have been introduced. However, none of them has gained general acceptance. Therefore, we just advise to discuss this topic with every patient. This discussion should include the consideration given in Section 5.12 on pregnancy and ACC in general.

5.11. Genetic counseling

R.11.1. For adults with ACC, we recommend at least a basic clinical genetic evaluation, exploring personal and family history for evidence of a hereditary predisposition syndrome.

Reasoning:

The detection of germline mutations impacts on the clinical care and surveillance of index patients and offers the possibility to identify at risk family members. Probably,

up to 5% of adult ACC arise in patients with germline *TP53* mutations (282, 283, 284) and about 3% of all ACC patients have an underlying diagnosis of Lynch syndrome (11, 285). Special attention should be given to these two hereditary syndromes, because for them there are well-established screening guidelines available (286, 287, 288, 289, 290). Up to 13% of all adrenal lesions in patients with *MEN1* represent adrenal cancer (22084155). Cases of ACC have been reported in patients with Beckwith-Wiedemann syndrome (children), Familial Adenomatous Polyposis (*APC*) and Carney Complex (4).

Germline genetic testing for ACC patients should primarily be considered for the genes related to Li-Fraumeni syndrome and Lynch syndrome. ACC is an integral part of Li-Fraumeni syndrome and when considering germline genetic testing, it is important to keep in mind that at least 20% of germline *TP53* pathogenic variants occur as de novo mutations in the absence of any family history. Lynch syndrome is present in the same fraction of ACC patients as in colorectal cancer patients (3–5%), where general screening for Lynch syndrome is recommended (286, 291). Both, Li-Fraumeni syndrome and Lynch syndrome have well established surveillance guidelines for carriers of pathogenic variants (286, 287, 288, 289, 290). Evaluation for Lynch syndrome can be initiated by immunohistochemistry for *MSH2*, *MLH1*, *PMS2*, *MSH6* and microsatellite instability testing, or direct genetic germline analysis of *MSH2*, *MLH1*, *PMS2*, *MSH6* and *EPCAM*. Genetic diagnosis of Li-Fraumeni syndrome is usually done by germline analysis for variants in *TP53*. For other syndromes (depending on family history and clinical suspicion) we refer to other sources (4, 292).

Although not the topic of this guideline, all children with a diagnosis of ACC should undergo a systematic search of germline *TP53* pathogenic variants, because 50–90% of ACC in children are related to germline pathogenic *TP53* variants (293, 294, 295).

R.11.2. The panel does not recommend for or against genetic tumor testing for somatic alterations.

Reasoning:

While the panel recognizes that there is great hope that testing for somatic mutations and other markers in cancers general may allow tailoring of therapy and personalized approaches for therapy, for ACCs this approach is not yet established in routine clinical practice. Therefore,

molecular testing should be offered within the framework of structured and systematic research projects.

5.12. Pregnancy and ACC

R.12.1. When an adrenal mass suspected to be an ACC is diagnosed during pregnancy, we recommend prompt surgical resection regardless of pregnancy trimester.

Reasoning:

Considering the poor prognosis of ACC and the importance of a prompt and complete surgical removal for prognosis, adrenal surgery should be pursued independent of the term of the pregnancy (296). Preterm delivery (especially in the third trimester) and pregnancy loss are obvious risks when surgery is performed. Therefore, the patient and their family, obstetric providers and the ACC care team must engage in an informed discussion considering disease prognosis and the risk to the mother and fetus as related to the underlying disease and interventional procedures. A shared decision making after discussion of all options is imperative.

R.12.2. Patients should be informed on pregnancy-related concerns specific to the current or past diagnosis of ACC.

Reasoning:

No evidence is available regarding how long patients should wait after the treatment of an ACC before they can safely consider pregnancy.

Importantly, the main concern is the poor prognosis of the malignant tumor and the potential that pregnancy could be a negative prognostic factor, possibly increasing the risk of recurrence. There is limited evidence that ACC occurring during pregnancy or in the postpartum period is associated with a worse prognosis than in non-pregnant women (297). The hypothesis that pregnancy could favor the development of a more aggressive variant of ACC was raised.

Due to the extreme paucity of information about this issue, it seems prudent to relay the information to the patient that there is a substantial risk of disease recurrence in the first years following the diagnosis of ACC.

Since ACC may express estrogen receptors and there are preclinical data showing that estrogen may facilitate tumor development and progression through cross-talk with the IGF pathway (298), contraceptive measures other than estrogen-containing preparations are preferred.

R.12.3. We recommend avoiding pregnancy while being on mitotane treatment.

Reasoning:

The main concern with mitotane therapy is the potential of teratogenic effects, due to the suspicion that the drug may cross the placenta and cause adrenolytic activity on the human fetus. However, there are only few case reports of pregnancies when on mitotane therapy (299). Therefore, it is impossible to draw definitive conclusions about the safety of mitotane treatment or its associated risks. Woman treated with mitotane should be informed about these risks, and ensure effective contraception to avoid pregnancy. Moreover, when mitotane treatment is discontinued, it seems wise to ensure undetectable mitotane plasma levels before considering pregnancy (300), which might take 3–12 months. In case a patient becomes pregnant while on mitotane therapy, the uncertainty regarding risks of mitotane for the fetus should be discussed. In case the patient wishes to continue pregnancy mitotane therapy should be withheld.

6. Future directions and recommended research

Due to the fact that the evidence for most of the recommendations provided in these guidelines is weak or even very weak, there are no doubts that major efforts are needed to improve diagnosis, treatment, and quality of life for patients with ACC.

Among many important research questions, we selected ten topics as particularly important. All of them can only be addressed in an international collaborative interdisciplinary manner.

1. Clinical response to the best available therapy (i.e. EDP+mitotane) for advanced ACC is very limited with an objective response rate of less than 25%. Therefore, we undeniably lack efficient drugs for treating this disease. Thus, identifying new therapeutic targets and options is a high priority. Here is a comprehensive but by far not complete list of emerging therapies: internal radionuclide therapy, such as metomidate-based therapies; drugs targeting the following pathways or targets: Wnt/beta-catenin; CDKN2A/TP53/RB; IGF2/mTOR; telomeres; drugs targeting histone modifications. In general, a combined approach seems to be reasonable. There is a growing notion that individual patients and individual tumors might respond better to certain therapies, depending on their molecular landscape. Therefore, studies focusing on subgroup classification and identification are important. Due to the mitotane-associated pharmacological issues (e.g. CYP3A4 induction), it might be reasonable to test experimental drugs in mitotane-naïve patients within clinical studies.
2. Immunotherapy is the latest revolution in cancer therapy, however preliminary data with single immune check point inhibitors showed a modest activity in ACC patients. Molecular and oncogenic pathways either in tumor cells or tumor microenvironment that can impair induction or execution of a local anti-tumor immune response should be carefully studied in ACC.
3. Since currently available systemic therapies have limited efficacy, but a subgroup of patient is destined to obtain a consistent benefit from them, the identification of predictive markers of efficacy (either clinical or molecular) of standard treatments is of paramount importance in order to spare toxic regimens to patients not destined to obtain a disease response.
4. With regards to improvement of surgery for ACC, standardization of procedures (e.g. laparoscopic vs open surgery, lymph node dissection) should be promoted and tested in clinical trials.
5. The high recurrence rate in the majority of patients even after complete resection calls for improvement of adjuvant therapy. There are significant gaps in our understanding, which patients might truly benefit from the different adjuvant therapies and prospective trials are urgently needed. The ongoing ADIUVO trial will hopefully provide important information for low/intermediate risk patients, but a trial in high-risk patients (e.g. mitotane vs mitotane+cisplatin+etoposide) is equally important.
6. Despite extensive efforts, the mechanism of action and pharmacodynamics of mitotane remain poorly understood (301, 302, 303, 304). In addition, mitotane is a strong inducer of xenobiotics metabolism, probably negatively impacting subsequent and parallel therapies. Therefore, further understanding and improving the pharmacology and mechanism of action of mitotane with the goal of development of mitotane related drugs that do not share the negative adverse effects would be a significant goal.
7. Translational research with the goal of rational treatment stratification should be promoted. Recent molecular classifications, identifying distinct molecular subtypes with different outcomes, should

be tested prospectively. These markers could provide a cornerstone for stratifying treatment strategies. This would mean that some patients of the 'better outcome' molecular group might benefit from forgoing any adjuvant therapy. Reversely, patients in the 'poor outcome' molecular group could be included in a randomized trial testing mitotane + cytotoxic drugs as an adjuvant therapy. In addition, it will be important to define differences in pharmacogenomics or tumor genomics that define exceptional responders to mitotane and/or EDP. This data can fuel further sub-stratification of ACC patients for certain therapies.

8. In addition to improving treatment, other future research directions may include the use of artificial intelligence in diagnostic work-up of adrenal tumors and the improvement of screening and follow-up procedures using non-invasive techniques such as urine or serum steroid metabolomics (305, 306, 307, 308) or 'liquid biopsies' with circulating tumor cells (309), circulating miRNAs (310, 311, 312), or circulating cell-free tumor DNA (313, 314) for early diagnosis or detection of recurrence.
9. In the long term, a better understanding of the pathogenesis of ACC is needed to pave the way for future progress. Therefore, basic research efforts have to continue. Preclinical models are needed, to test new treatments, including additional new cell lines, tumor organoids, and new animal models. Mechanisms of tumorigenesis, tumor evolution (genetic heterogeneity, clonal evolution) and further definition of known and future therapeutic targets should be encouraged.
10. No studies so far have revealed the wishes and experiences of patients. Given the poor prognosis and the toxic therapies, there is a definite need for 'Patient Related Outcomes'. PRO's should be measured (PROM's) and incorporated in our strategy for value based cure and care.

In general, it is our common task to overcome the major limitation in ACC research – the rarity of this disease. Therefore, beyond proofs of concept requiring few patients, clinical trials can only be performed if a large number of centers gather multicenter studies. This underscores the critical role of adrenal research networks, such as ENSAT or A5, to coordinate these efforts. Ideally a limited number of large prospective trials should continuously be ongoing, in order to allow for sufficient patient recruitment. In the same context, we envision that at least one reference center in every country will be

established to provide multidisciplinary expertise for this rare disease to all patients.

Altogether, owing to its rarity and its severity, ACC should continue to mobilize researchers, physicians and patients in a coordinated engaged effort.

Appendix

This is linked to the online version of the paper at <https://doi.org/10.1530/EJE-18-0608>.

Declaration of interest

Guillaume Assié: Speakers fee/travel support for congresses from: HRA Pharma (2016); Ipsen Pharma (2013, 2014); Novartis (2012, 2013, 2014, 2015, 2016). Eric Baudin: Speakers fee: HRA Pharma; Research support by HRA Pharma. Alfredo Berruti: Member of remunerated Advisory Boards of Astellas, Sanofi, Janssen, Merck Sharp and Dome, Novartis, Ipsen; Speakers fee/travel support for congresses from: Astellas, Sanofi, Janssen, Novartis, Ipsen; Research support by Janssen (Phase II trial of Abiraterone in the management of Cushing syndrome induced by Adrenocortical Carcinoma; 2016); Sanofi: Phase II trial of Cabazitaxel as second-line treatment in the treatment of patients with advanced Adrenocortical Carcinoma; 2014). Martin Fassnacht: Advisory board member: of HRA Pharma (2015; not remunerated); Atterocor (2013); Astellas Pharma (2012); Speakers fee/travel support for congresses from: HRA Pharma (2013); Ipsen Pharma (2011, 2012); Editorial Board member of EJE. Harm Haak: Research support by HRA Pharma (2016). Massimo Terzolo: Advisory Board member of HRA Pharma (2013; not remunerated), Atterocor-Millendo (2013–2015); Research support by HRA Pharma (2016); Speaker fee/travel support from HRA Pharma (2014, 2015). The other authors declare no conflict of interest.

Funding

This guideline was sponsored by the European Society of Endocrinology with support by the European Network for the Study of Adrenal Tumors.

Acknowledgements

The authors of the guideline would like to thank and acknowledge Mouhamed Habra, Electron Kebebew and Britt Skogseid for their expert review and additional members of the European Society of Endocrinology, the European Network for the Study of Adrenal Tumors or representatives of national endocrine societies for valuable and critical comments. In addition, they thank three patient representatives who provided valuable feedback for the guideline. The comments of the reviewers as well as the authors' responses are available as [Appendix 8](#). Furthermore, they thank John Newell-Price for very helpful English proof-reading. Finally they would like to thank Annemarie Venemans for her support in the systematic literature search.

Endorsement

These guidelines are endorsed by the Society for Endocrinology (www.endocrinology.org).

References

- 1 Kebebew E, Reiff E, Duh QY, Clark OH & McMillan A. Extent of disease at presentation and outcome for adrenocortical carcinoma: have we made progress? *World Journal of Surgery* 2006 **30** 872–878. (<https://doi.org/10.1007/s00268-005-0329-x>)

- 2 Kerkhofs TM, Verhoeven RH, Van der Zwan JM, Dieleman J, Kerstens MN, Links TP, Van de Poll-Franse LV & Haak HR. Adrenocortical carcinoma: a population-based study on incidence and survival in the Netherlands since 1993. *European Journal of Cancer* 2013 **49** 2579–2586. (<https://doi.org/10.1016/j.ejca.2013.02.034>)
- 3 Berruti A, Baudin E, Gelderblom H, Haak HR, Porpiglia F, Fassnacht M & Pentheroudakis G. Adrenal cancer: ESMO Clinical Practice Guidelines for diagnosis, treatment and follow-up. *Annals of Oncology* 2012 **23** 131–138.
- 4 Petr EJ & Else T. Genetic predisposition to endocrine tumors: diagnosis, surveillance and challenges in care. *Seminars in Oncology* 2016 **43** 582–590. (<https://doi.org/10.1053/j.seminoncol.2016.08.007>)
- 5 de Reynies A, Assie G, Rickman DS, Tissier F, Groussin L, Rene-Corail F, Dousset B, Bertagna X, Clauser E & Bertherat J. Gene expression profiling reveals a new classification of adrenocortical tumors and identifies molecular predictors of malignancy and survival. *Journal of Clinical Oncology* 2009 **27** 1108–1115. (<https://doi.org/10.1200/JCO.2008.18.5678>)
- 6 Fragoso MC, Almeida MQ, Mazzucco TL, Mariani BM, Brito LP, Goncalves TC, Alencar GA, Lima L de O, Faria AM, Bourdeau I *et al.* Combined expression of BUB1B, DLGAP5, and PINK1 as predictors of poor outcome in adrenocortical tumors: validation in a Brazilian cohort of adult and pediatric patients. *European Journal of Endocrinology* 2012 **166** 61–67. (<https://doi.org/10.1530/EJE-11-0806>)
- 7 Ronchi CL, Sbera S, Leich E, Henzel K, Rosenwald A, Allolio B & Fassnacht M. Single nucleotide polymorphism array profiling of adrenocortical tumors – evidence for an adenoma carcinoma sequence? *PLoS ONE* 2013 **8** e73959. (<https://doi.org/10.1371/journal.pone.0073959>)
- 8 Jouinot A, Assie G, Libe R, Fassnacht M, Papatthomas T, Barreau O, de la Villeon B, Faillot S, Hamzaoui N, Neou M *et al.* DNA methylation is an independent prognostic marker of survival in adrenocortical cancer. *Journal of Clinical Endocrinology and Metabolism* 2017 **102** 923–932.
- 9 Assie G, Letouze E, Fassnacht M, Jouinot A, Luscap W, Barreau O, Omeiri H, Rodriguez S, Perlemoine K, Rene-Corail F *et al.* Integrated genomic characterization of adrenocortical carcinoma. *Nature Genetics* 2014 **46** 607–612. (<https://doi.org/10.1038/ng.2953>)
- 10 Juhlin CC, Goh G, Healy JM, Fonseca AL, Scholl UI, Stenman A, Kunstman JW, Brown TC, Overton JD, Mane SM *et al.* Whole-exome sequencing characterizes the landscape of somatic mutations and copy number alterations in adrenocortical carcinoma. *Journal of Clinical Endocrinology and Metabolism* 2015 **100** E493–E502. (<https://doi.org/10.1210/jc.2014-3282>)
- 11 Zheng S, Cherniack AD, Dewal N, Moffitt RA, Danilova L, Murray BA, Lerario AM, Else T, Knijnenburg TA, Ciriello G *et al.* Comprehensive pan-genomic characterization of adrenocortical carcinoma. *Cancer Cell* 2016 **29** 723–736. (<https://doi.org/10.1016/j.ccell.2016.04.002>)
- 12 Assie G, Jouinot A & Bertherat J. The ‘omics’ of adrenocortical tumours for personalized medicine. *Nature Reviews Endocrinology* 2014 **10** 215–228. (<https://doi.org/10.1038/nrendo.2013.272>)
- 13 Else T, Kim AC, Sabolch A, Raymond VM, Kandathil A, Caoili EM, Jolly S, Miller BS, Giordano TJ & Hammer GD. Adrenocortical carcinoma. *Endocrine Reviews* 2014 **35** 282–326. (<https://doi.org/10.1210/er.2013-1029>)
- 14 Faillot S & Assie G. ENDOCRINE TUMOURS: The genomics of adrenocortical tumors. *European Journal of Endocrinology* 2016 **174** R249–R265. (<https://doi.org/10.1530/EJE-15-1118>)
- 15 Terzolo M, Ali A, Osella G & Mazza E. Prevalence of adrenal carcinoma among incidentally discovered adrenal masses. A retrospective study from 1989 to 1994. Gruppo Piemontese Incidentalomi Surrenali. *Archives of Surgery* 1997 **132** 914–919. (<https://doi.org/10.1001/archsurg.1997.01430320116020>)
- 16 Cawood TJ, Hunt PJ, O’Shea D, Cole D & Soule S. Recommended evaluation of adrenal incidentalomas is costly, has high false-positive rates and confers a risk of fatal cancer that is similar to the risk of the adrenal lesion becoming malignant; time for a rethink? *European Journal of Endocrinology* 2009 **161** 513–527. (<https://doi.org/10.1530/EJE-09-0234>)
- 17 Fassnacht M, Arlt W, Bancos I, Dralle H, Newell-Price J, Sahdev A, Tabarin A, Terzolo M, Tsagarakis S & Dekkers OM. Management of adrenal incidentalomas: European Society of Endocrinology Clinical Practice Guideline in collaboration with the European Network for the Study of Adrenal Tumors. *European Journal of Endocrinology* 2016 **175** G1–G34. (<https://doi.org/10.1530/EJE-16-0467>)
- 18 Seccia TM, Fassina A, Nussdorfer GG, Pessina AC & Rossi GP. Aldosterone-producing adrenocortical carcinoma: an unusual cause of Conn’s syndrome with an ominous clinical course. *Endocrine-Related Cancer* 2005 **12** 149–159. (<https://doi.org/10.1677/erc.1.00867>)
- 19 Fassnacht M, Libe R, Kroiss M & Allolio B. Adrenocortical carcinoma: a clinician’s update. *Nature Reviews Endocrinology* 2011 **7** 323–335. (<https://doi.org/10.1038/nrendo.2010.235>)
- 20 Berruti A, Fassnacht M, Haak H, Else T, Baudin E, Sperone P, Kroiss M, Kerkhofs T, Williams AR, Ardito A *et al.* Prognostic role of overt hypercortisolism in completely operated patients with adrenocortical cancer. *European Urology* 2014 **65** 832–838. (<https://doi.org/10.1016/j.euro.2013.11.006>)
- 21 Kerkhofs TM, Eттаieb MH, Hermsen IG & Haak HR. Developing treatment for adrenocortical carcinoma. *Endocrine-Related Cancer* 2015 **22** R325–R338. (<https://doi.org/10.1530/ERC-15-0318>)
- 22 Fassnacht M, Kroiss M & Allolio B. Update in adrenocortical carcinoma. *Journal of Clinical Endocrinology and Metabolism* 2013 **98** 4551–4564. (<https://doi.org/10.1210/jc.2013-3020>)
- 23 Fassnacht M & Allolio B. Clinical management of adrenocortical carcinoma. *Best Practice and Research Clinical Endocrinology and Metabolism* 2009 **23** 273–289.
- 24 Johanssen S, Hahner S, Saeger W, Quinkler M, Beuschlein F, Dralle H, Haaf M, Kroiss M, Jurowich C, Langer P *et al.* Deficits in the management of patients with adrenocortical carcinoma in germany. *Deutsches Arzteblatt International* 2010 **107** U885–U889.
- 25 Icard P, Goudet P, Charpenay C, Andreassian B, Carnaille B, Chapuis Y, Cougard P, Henry JF & Proye C. Adrenocortical carcinomas: surgical trends and results of a 253-patient series from the French Association of Endocrine Surgeons study group. *World Journal of Surgery* 2001 **25** 891–897. (<https://doi.org/10.1007/s00268-001-0047-y>)
- 26 Bilimoria KY, Shen WT, Elaraj D, Bentrem DJ, Winchester DJ, Kebebew E & Sturgeon C. Adrenocortical carcinoma in the United States: treatment utilization and prognostic factors. *Cancer* 2008 **113** 3130–3136. (<https://doi.org/10.1002/cncr.23886>)
- 27 Sturgeon C, Shen WT, Clark OH, Duh QY & Kebebew E. Risk assessment in 457 adrenal cortical carcinomas: how much does tumor size predict the likelihood of malignancy? *Journal of the American College of Surgeons* 2006 **202** 423–430. (<https://doi.org/10.1016/j.jamcollsurg.2005.11.005>)
- 28 Fassnacht M, Johanssen S, Fenske W, Weismann D, Agha A, Beuschlein F, Fuhrer D, Jurowich C, Quinkler M, Petersenn S *et al.* Improved survival in patients with stage II adrenocortical carcinoma followed up prospectively by specialized centers. *Journal of Clinical Endocrinology and Metabolism* 2010 **95** 4925–4932.
- 29 Fassnacht M, Johanssen S, Quinkler M, Bucsky P, Willenberg HS, Beuschlein F, Terzolo M, Mueller HH, Hahner S & Allolio B. Limited prognostic value of the 2004 International Union Against Cancer staging classification for adrenocortical carcinoma: proposal for a Revised TNM Classification. *Cancer* 2009 **115** 243–250. (<https://doi.org/10.1002/cncr.24030>)
- 30 Fassnacht M, Terzolo M, Allolio B, Baudin E, Haak H, Berruti A, Welin S, Schade-Brittinger C, Lacroix A, Jarzab B *et al.* Combination chemotherapy in advanced adrenocortical carcinoma. *New England Journal of Medicine* 2012 **366** 2189–2197. (<https://doi.org/10.1056/NEJMoa1200966>)

- 31 Bollerslev J, Rejnmark L, Marcocci C, Shoback DM, Sitges-Serra A, van Biesen W & Dekkers OM. European Society of Endocrinology Clinical Guideline: treatment of chronic hypoparathyroidism in adults. *European Journal of Endocrinology* 2015 **173** G1–G20. (<https://doi.org/10.1530/EJE-15-0628>)
- 32 Andrews J, Guyatt G, Oxman AD, Alderson P, Dahm P, Falck-Ytter Y, Nasser M, Meerpohl J, Post PN, Kunz R *et al.* GRADE guidelines: 14. Going from evidence to recommendations: the significance and presentation of recommendations. *Journal of Clinical Epidemiology* 2013 **66** 719–725. (<https://doi.org/10.1016/j.jclinepi.2012.03.013>)
- 33 Andrews JC, Schunemann HJ, Oxman AD, Pottie K, Meerpohl JJ, Coello PA, Rind D, Montori VM, Brito JP, Norris S *et al.* GRADE guidelines: 15. Going from evidence to recommendation—determinants of a recommendation's direction and strength. *Journal of Clinical Epidemiology* 2013 **66** 726–735. (<https://doi.org/10.1016/j.jclinepi.2013.02.003>)
- 34 Guyatt GH, Schunemann HJ, Djulbegovic B & Akl EA. Guideline panels should not GRADE good practice statements. *Journal of Clinical Epidemiology* 2015 **68** 597–600. (<https://doi.org/10.1016/j.jclinepi.2014.12.011>)
- 35 Vanbrabant T, Fassnacht M, Assie G & Dekkers OM. Influence of hormonal functional status on survival in adrenocortical carcinoma: systematic review and meta-analysis. *European Journal of Endocrinology* 2018.
- 36 Bertherat J, Coste J & Bertagna X. Adjuvant mitotane in adrenocortical carcinoma. *New England Journal of Medicine* 2007 **357** 1256–1257; author reply 1259. (<https://doi.org/10.1056/NEJMc076267>)
- 37 Blanes A & Diaz-Cano SJ. Histologic criteria for adrenocortical proliferative lesions – value of mitotic figure variability. *American Journal of Clinical Pathology* 2007 **127** 398–408. (<https://doi.org/10.1309/MCGUQ3R4A4WWN3LB>)
- 38 Creemers SG, van Koetsveld PM, van Kemenade FJ, Papanthomas TG, Franssen GJ, Dogan F, Eekhoff EM, van der Valk P, de Herder WW, Janssen JA *et al.* Methylation of IGF2 regulatory regions to diagnose adrenocortical carcinomas. *Endocrine-Related Cancer* 2016 **23** 727–737. (<https://doi.org/10.1530/ERC-16-0266>)
- 39 Erickson LA, Jin L, Sebo TJ, Lohse C, Pankratz VS, Kendrick ML, van Heerden JA, Thompson GB, Grant CS & Lloyd RV. Pathologic features and expression of insulin-like growth factor-2 in adrenocortical neoplasms. *Endocrine Pathology* 2001 **12** 429–435. (<https://doi.org/10.1385/EP:12:4:429>)
- 40 Arola J, Liu J, Heikkila P, Ilvesmaki V, Salmenkivi K, Voutilainen R & Kahri AI. Expression of inhibin alpha in adrenocortical tumours reflects the hormonal status of the neoplasm. *Journal of Endocrinology* 2000 **165** 223–229. (<https://doi.org/10.1677/joe.0.1650223>)
- 41 Aubert S, Wacrenier A, Leroy X, Devos P, Carnaille B, Proye C, Wemeau JL, Lecomte-Houcke M & Leteurtre E. Weiss system revisited: a clinicopathologic and immunohistochemical study of 49 adrenocortical tumors. *American Journal of Surgical Pathology* 2002 **26** 1612–1619. (<https://doi.org/10.1097/00000478-200212000-00009>)
- 42 Busam KJ, Iversen K, Coplan KA, Old LJ, Stockert E, Chen YT, McGregor D & Jungbluth A. Immunoreactivity for A103, an antibody to melan-A (Mart-1), in adrenocortical and other steroid tumors. *American Journal of Surgical Pathology* 1998 **22** 57–63. (<https://doi.org/10.1097/00000478-199801000-00007>)
- 43 Kamio T, Shigematsu K, Sou H, Kawai K & Tsuchiyama H. Immunohistochemical expression of epidermal growth factor receptors in human adrenocortical carcinoma. *Human Pathology* 1990 **21** 277–282. ([https://doi.org/10.1016/0046-8177\(90\)90227-V](https://doi.org/10.1016/0046-8177(90)90227-V))
- 44 Komminoth P, Roth J, Schroder S, Saremaslani P & Heitz PU. Overlapping expression of immunohistochemical markers and synaptophysin mRNA in pheochromocytomas and adrenocortical carcinomas. Implications for the differential diagnosis of adrenal gland tumors. *Laboratory Investigation* 1995 **72** 424–431.
- 45 Pan CC, Chen PCH, Tsay SH & Ho DMT. Differential immunoprofiles of hepatocellular carcinoma, renal cell carcinoma, and adrenocortical carcinoma: a systemic immunohistochemical survey using tissue array technique. *Applied Immunohistochemistry and Molecular Morphology* 2005 **13** 347–352. (<https://doi.org/10.1097/01.pai.0000146525.72531.19>)
- 46 Rubin B, Regazzo D, Redaelli M, Mucignat C, Citton M, Iacobone M, Scaroni C, Betterle C, Mantero F, Fassina A *et al.* Investigation of N-cadherin/beta-catenin expression in adrenocortical tumors. *Tumour Biology* 2016 **37** 13545–13555. (<https://doi.org/10.1007/s13277-016-5257-x>)
- 47 Sbiera S, Schull S, Assie G, Voelker HU, Kraus L, Beyer M, Ragazzon B, Beuschlein F, Willenberg HS, Hahner S *et al.* High diagnostic and prognostic value of steroidogenic factor-1 expression in adrenal tumors. *Journal of Clinical Endocrinology and Metabolism* 2010 **95** E161–E171.
- 48 Stojadinovic A, Brennan MF, Hoos A, Omeroglu A, Leung DH, Dudas ME, Nissan A, Cordon-Cardo C & Ghossein RA. Adrenocortical adenoma and carcinoma: histopathological and molecular comparative analysis. *Modern Pathology* 2003 **16** 742–751. (<https://doi.org/10.1097/01.MP.0000081730.72305.81>)
- 49 Volante M, Sperone P, Bollito E, Frangipane E, Rosas R, Daffara F, Terzolo M, Berruti A & Papotti M. Matrix metalloproteinase type 2 expression in malignant adrenocortical tumors: Diagnostic and prognostic significance in a series of 50 adrenocortical carcinomas. *Modern Pathology* 2006 **19** 1563–1569. (<https://doi.org/10.1038/modpathol.3800683>)
- 50 Wajchenberg BL, Albergaria Pereira MA, Medonca BB, Latronico AC, Campos Carneiro P, Alves VA, Zerbini MC, Liberman B, Carlos Gomes G & Kirschner MA. Adrenocortical carcinoma: clinical and laboratory observations. *Cancer* 2000 **88** 711–736. ([https://doi.org/10.1002/\(SICI\)1097-0142\(20000215\)88:4<711::AID-CNCR1>3.0.CO;2-W](https://doi.org/10.1002/(SICI)1097-0142(20000215)88:4<711::AID-CNCR1>3.0.CO;2-W))
- 51 Wang C, Sun Y, Wu H, Zhao D & Chen J. Distinguishing adrenal cortical carcinomas and adenomas: a study of clinicopathological features and biomarkers. *Histopathology* 2014 **64** 567–576. (<https://doi.org/10.1111/his.12283>)
- 52 Zhang HY, Bu H, Chen HJ, Wei B, Liu WP, Guo J, Li FY, Liao DY, Tang Y & Zhang Z. Comparison of immunohistochemical markers in the differential diagnosis of adrenocortical tumors – immunohistochemical analysis of adrenocortical tumors. *Applied Immunohistochemistry and Molecular Morphology* 2008 **16** 32–39.
- 53 Kovach AE, Nucera C, Lam QT, Nguyen A, Dias-Santagata D & Sadow PM. Genomic and immunohistochemical analysis in human adrenal cortical neoplasia reveal beta-catenin mutations as potential prognostic biomarker. *Discoveries* 2015 **3** e40.
- 54 Amini N, Margonis GA, Kim Y, Tran TB, Postlewait LM, Maithel SK, Wang TS, Evans DB, Hatzaras I, Shenoy R *et al.* Curative resection of adrenocortical carcinoma: rates and patterns of postoperative recurrence. *Annals of Surgical Oncology* 2016 **23** 126–133. (<https://doi.org/10.1245/s10434-015-4810-y>)
- 55 Asare EA, Wang TS, Winchester DP, Mallin K, Kebebew E & Sturgeon C. A novel staging system for adrenocortical carcinoma better predicts survival in patients with stage I/II disease. *Surgery* 2014 **156** 1378–1386. (<https://doi.org/10.1016/j.surg.2014.08.018>)
- 56 Assie G, Antoni G, Tissier F, Caillou B, Abiven G, Gicquel C, Leboulloux S, Travagli JP, Dromain C, Bertagna X *et al.* Prognostic parameters of metastatic adrenocortical carcinoma. *Journal of Clinical Endocrinology and Metabolism* 2007 **92** 148–154.
- 57 Ayala-Ramirez M, Jasim S, Feng L, Ejaz S, Deniz F, Busaidy N, Waguespack SG, Naing A, Sircar K, Wood CG *et al.* Adrenocortical carcinoma: clinical outcomes and prognosis of 330 patients at a tertiary care center. *European Journal of Endocrinology* 2013 **169** 891–899. (<https://doi.org/10.1530/EJE-13-0519>)

- 58 Beuschlein F, Weigel J, Saeger W, Kroiss M, Wild V, Daffara F, Libe R, Ardito A, Ghuzlan AA, Quinkler M *et al.* Major prognostic role of Ki67 in localized adrenocortical carcinoma after complete resection. *Journal of Clinical Endocrinology and Metabolism* 2015 **100** 841–849. (<https://doi.org/10.1210/jc.2014-3182>)
- 59 Canter DJ, Mallin K, Uzzo RG, Egleston BL, Simhan J, Walton J, Smaldone MC, Master VA, Bratslasky G & Kutikov A. Association of tumor size with metastatic potential and survival in patients with adrenocortical carcinoma: an analysis of the National Cancer Database. *Canadian Journal of Urology* 2013 **20** 6915–6921.
- 60 Duregon E, Cappellesso R, Maffei V, Zaggia B, Ventura L, Berruti A, Terzolo M, Fassina A, Volante M & Papotti M. Validation of the prognostic role of the 'Helsinki Score' in 225 cases of adrenocortical carcinoma. *Human Pathology* 2017 **62** 1–7. (<https://doi.org/10.1016/j.humpath.2016.09.035>)
- 61 Erdogan I, Deutschbein T, Jurowich C, Kroiss M, Ronchi C, Quinkler M, Waldmann J, Willenberg HS, Beuschlein F, Fottner C *et al.* The role of surgery in the management of recurrent adrenocortical carcinoma. *Journal of Clinical Endocrinology and Metabolism* 2013 **98** 181–191.
- 62 Ettaieb MH, Duker JC, Feelders RA, Corssmit EP, Menke-van der Houven van Oordt CW, Timmers HJ, Kerstens MN, Wilmlink JW, Zelissen PM, Havekes B *et al.* Synchronous vs metachronous metastases in adrenocortical carcinoma: an analysis of the dutch adrenal network. *Hormones and Cancer* 2016 **7** 336–344. (<https://doi.org/10.1007/s12672-016-0270-5>)
- 63 Freire DS, Siqueira SAC, Zerbini MCN, Wajchenberg BL, Correa-Giannella ML, Lucon AM & Pereira MAA. Development and internal validation of an adrenal cortical carcinoma prognostic score for predicting the risk of metastasis and local recurrence. *Clinical Endocrinology* 2013 **79** 468–475. (<https://doi.org/10.1111/cen.12174>)
- 64 Gicquel C, Bertagna X, Gaston V, Coste J, Louvel A, Baudin E, Bertherat J, Chapuis Y, Duclos JM, Schlumberger M *et al.* Molecular markers and long-term recurrences in a large cohort of patients with sporadic adrenocortical tumors. *Cancer Research* 2001 **61** 6762–6767.
- 65 Glover AR, Zhao JT, Ip JC, Lee JC, Robinson BG, Gill AJ, Soon PS & Sidhu SB. Long noncoding RNA profiles of adrenocortical cancer can be used to predict recurrence. *Endocrine-Related Cancer* 2015 **22** 99–109. (<https://doi.org/10.1530/ERC-14-0457>)
- 66 Gonzalez RJ, Tamm EP, Ng C, Phan AT, Vassilopoulou-Sellin R, Perrier ND, Evans DB & Lee JE. Response to mitotane predicts outcome in patients with recurrent adrenal cortical carcinoma. *Surgery* 2007 **142** 867–874. (<https://doi.org/10.1016/j.surg.2007.09.006>)
- 67 Kendrick ML, Curlee K, Lloyd R, Farley DR, Grant CS, Thompson GB, Rowland C, Young WF Jr, Van Heerden JA, Duh QY *et al.* Aldosterone-secreting adrenocortical carcinomas are associated with unique operative risks and outcomes. *Surgery* 2002 **132** 1008–1012. (<https://doi.org/10.1067/msy.2002.128476>)
- 68 Kim Y, Margonis GA, Prescott JD, Tran TB, Postlewait LM, Maitzel SK, Wang TS, Evans DB, Hatzaras I, Shenoy R *et al.* Nomograms to predict recurrence-free and overall survival after curative resection of adrenocortical carcinoma. *JAMA Surgery* 2016 **151** 365–373. (<https://doi.org/10.1001/jamasurg.2015.4516>)
- 69 Kim Y, Margonis GA, Prescott JD, Tran TB, Postlewait LM, Maitzel SK, Wang TS, Glenn JA, Hatzaras I, Shenoy R *et al.* Curative surgical resection of adrenocortical carcinoma: determining long-term outcome based on conditional disease-free probability. *Annals of Surgery* 2017 **265** 197–204. (<https://doi.org/10.1097/SLA.0000000000001527>)
- 70 Libe R, Borget I, Ronchi CL, Zaggia B, Kroiss M, Kerkhofs T, Bertherat J, Volante M, Quinkler M, Chabre O *et al.* Prognostic factors in stage III-IV adrenocortical carcinomas (ACC): an European Network for the Study of Adrenal Tumor (ENSAT) study. *Annals of Oncology* 2015 **26** 2119–2125. (<https://doi.org/10.1093/annonc/mdv329>)
- 71 Livhits M, Li N, Yeh MW & Harari A. Surgery is associated with improved survival for adrenocortical cancer, even in metastatic disease. *Surgery* 2014 **156** 1531–1540; discussion 1540–1531. (<https://doi.org/10.1016/j.surg.2014.08.047>)
- 72 Lucon AM, Pereira MA, Mendonca BB, Zerbini MC, Saldanha LB & Arap S. Adrenocortical tumors: results of treatment and study of Weiss's score as a prognostic factor. *Revista do Hospital das Clinicas da Faculdade de Medicina da Universidade de Sao Paulo* 2002 **57** 251–256. (<https://doi.org/10.1590/S0041-87812002000600002>)
- 73 Margonis GA, Kim Y, Prescott JD, Tran TB, Postlewait LM, Maitzel SK, Wang TS, Evans DB, Hatzaras I, Shenoy R *et al.* Adrenocortical carcinoma: impact of surgical margin status on long-term outcomes. *Annals of Surgical Oncology* 2016 **23** 134–141. (<https://doi.org/10.1245/s10434-015-4803-x>)
- 74 Margonis GA, Kim Y, Tran TB, Postlewait LM, Maitzel SK, Wang TS, Glenn JA, Hatzaras I, Shenoy R, Phay JE *et al.* Outcomes after resection of cortisol-secreting adrenocortical carcinoma. *American Journal of Surgery* 2016 **211** 1106–1113. (<https://doi.org/10.1016/j.amjsurg.2015.09.020>)
- 75 Millis SZ, Ejadi S & Demeure MJ. Molecular profiling of refractory adrenocortical cancers and predictive biomarkers to therapy. *Biomarkers in Cancer* 2015 **7** 69–76. (<https://doi.org/10.4137/BIC.S34292>)
- 76 Paton BL, Novitsky YW, Zerey M, Harrell AG, Norton HJ, Asbun H, Kercher KW & Heniford BT. Outcomes of adrenal cortical carcinoma in the United States. *Surgery* 2006 **140** 914–920; discussion 919–920. (<https://doi.org/10.1016/j.surg.2006.07.035>)
- 77 Pennanen M, Heiskanen I, Sane T, Remes S, Mustonen H, Haglund C & Arola J. Helsinki score—a novel model for prediction of metastases in adrenocortical carcinomas. *Human Pathology* 2015 **46** 404–410. (<https://doi.org/10.1016/j.humpath.2014.11.015>)
- 78 Schulick RD & Brennan MF. Long-term survival after complete resection and repeat resection in patients with adrenocortical carcinoma. *Annals of Surgical Oncology* 1999 **6** 719–726. (<https://doi.org/10.1007/s10434-999-0719-7>)
- 79 Tran TB, Postlewait LM, Maitzel SK, Prescott JD, Wang TS, Glenn J, Phay JE, Keplinger K, Fields RC, Jin LDX *et al.* Actual 10-year survivors following resection of adrenocortical carcinoma. *Journal of Surgical Oncology* 2016 **114** 971–976. (<https://doi.org/10.1002/jso.24439>)
- 80 Xiao WJ, Zhu Y, Dai B, Zhang HL, Shi GH, Shen YJ, Zhu YP & Ye DW. Conditional survival among patients with adrenal cortical carcinoma determined using a national population-based surveillance, epidemiology, and end results registry. *Oncotarget* 2015 **6** 44955–44962.
- 81 Zini L, Capitanio U, Jeldres C, Lughezzani G, Sun M, Shariat SF, Isbarn H, Arjane P, Widmer H, Perrotte P *et al.* External validation of a nomogram predicting mortality in patients with adrenocortical carcinoma. *BJU International* 2009 **104** 1661–1667. (<https://doi.org/10.1111/j.1464-410X.2009.08660.x>)
- 82 Ronchi CL, Sbiera S, Leich E, Tissier F, Steinhauer S, Deutschbein T, Fassnacht M & Allolio B. Low SGK1 expression in human adrenocortical tumors is associated with ACTH-independent glucocorticoid secretion and poor prognosis. *Journal of Clinical Endocrinology and Metabolism* 2012 **97** E2251–E2260. (<https://doi.org/10.1210/jc.2012-2669>)
- 83 Macfarlane DA. Cancer of the adrenal cortex; the natural history, prognosis and treatment in a study of fifty-five cases. *Annals of the Royal College of Surgeons of England* 1958 **23** 155–186.
- 84 Sullivan M, Boileau M & Hodges CV. Adrenal cortical carcinoma. *Journal of Urology* 1978 **120** 660–665. ([https://doi.org/10.1016/S0022-5347\(17\)57317-6](https://doi.org/10.1016/S0022-5347(17)57317-6))
- 85 Lee JE, Berger DH, el-Naggar AK, Hickey RC, Vassilopoulou-Sellin R, Gagel RF, Burgess MA & Evans DB. Surgical management, DNA content, and patient survival in adrenal cortical carcinoma.

- Surgery* 1995 **118** 1090–1098. ([https://doi.org/10.1016/S0039-6060\(05\)80119-9](https://doi.org/10.1016/S0039-6060(05)80119-9))
- 86 DeLellis RA, Lloyd RV, Heitz PU & Eng C. World Health Organization classification of tumours. *Pathology and Genetics of Tumours of Endocrine Organs* 2004 **136**.
- 87 Miller BS, Gauger PG, Hammer GD, Giordano TJ & Doherty GM. Proposal for modification of the ENSAT staging system for adrenocortical carcinoma using tumor grade. *Langenbecks Archives of Surgery* 2010 **395** 955–961. (<https://doi.org/10.1007/s00423-010-0698-y>)
- 88 Lughezzani G, Sun M, Perrotte P, Jeldres C, Alasker A, Isbarn H, Budaus L, Shariat SF, Guazzoni G, Montorsi F *et al.* The European Network for the Study of Adrenal Tumors staging system is prognostically superior to the international union against cancer-staging system: a North American validation. *European Journal of Cancer* 2010 **46** 713–719. (<https://doi.org/10.1016/j.ejca.2009.12.007>)
- 89 Lam AK. Update on adrenal tumours in 2017 World Health Organization (WHO) of endocrine tumours. *Endocrine Pathology* 2017 **28** 213–227. (<https://doi.org/10.1007/s12022-017-9484-5>)
- 90 Berruti A, Grisanti S, Pulzer A, Claps M, Daffara F, Loli P, Mannelli M, Boscaro M, Arvat E, Tiberio G *et al.* Long-term outcomes of adjuvant mitotane therapy in patients with radically resected adrenocortical carcinoma. *Journal of Clinical Endocrinology and Metabolism* 2017 **102** 1358–1365. (<https://doi.org/10.1210/jc.2016-2894>)
- 91 Else T, Williams AR, Sabolch A, Jolly S, Miller BS & Hammer GD. Adjuvant therapies and patient and tumor characteristics associated with survival of adult patients with adrenocortical carcinoma. *Journal of Clinical Endocrinology and Metabolism* 2014 **99** 455–461. (<https://doi.org/10.1210/jc.2013-2856>)
- 92 Grubbs EG, Callender GG, Xing Y, Perrier ND, Evans DB, Phan AT & Lee JE. Recurrence of adrenal cortical carcinoma following resection: surgery alone can achieve results equal to surgery plus mitotane. *Annals of Surgical Oncology* 2010 **17** 263–270. (<https://doi.org/10.1245/s10434-009-0716-x>)
- 93 Postlewait LM, Ethun CG, Tran TB, Prescott JD, Pawlik TM, Wang TS, Glenn J, Hatzaras I, Shenoy R, Phay JE *et al.* Outcomes of adjuvant mitotane after resection of adrenocortical carcinoma: a 13-institution study by the US Adrenocortical Carcinoma Group. *Journal of the American College of Surgeons* 2016 **222** 480–490. (<https://doi.org/10.1016/j.jamcollsurg.2015.12.013>)
- 94 Terzolo M, Angeli A, Fassnacht M, Daffara F, Tauchmanova L, Conton PA, Rossetto R, Buci L, Sperone P, Grossrubatscher E *et al.* Adjuvant mitotane treatment for adrenocortical carcinoma. *New England Journal of Medicine* 2007 **356** 2372–2380. (<https://doi.org/10.1056/NEJMoa063360>)
- 95 Bosco JL, Silliman RA, Thwin SS, Geiger AM, Buist DS, Prout MN, Yood MU, Haque R, Wei F & Lash TL. A most stubborn bias: no adjustment method fully resolves confounding by indication in observational studies. *Journal of Clinical Epidemiology* 2010 **63** 64–74. (<https://doi.org/10.1016/j.jclinepi.2009.03.001>)
- 96 Hernan MA & Robins JM. Instruments for causal inference: an epidemiologist's dream? *Epidemiology* 2006 **17** 360–372. (<https://doi.org/10.1097/01.ede.0000222409.00878.37>)
- 97 Suissa S. Immortal time bias in pharmaco-epidemiology. *American Journal of Epidemiology* 2008 **167** 492–499. (<https://doi.org/10.1093/aje/kwm324>)
- 98 Fassnacht M, Hahner S, Polat B, Koschker AC, Kenn W, Flentje M & Allolio B. Efficacy of adjuvant radiotherapy of the tumor bed on local recurrence of adrenocortical carcinoma. *Journal of Clinical Endocrinology and Metabolism* 2006 **91** 4501–4504.
- 99 Habra MA, Ejaz S, Feng L, Das P, Deniz F, Grubbs EG, Phan AT, Waguespack S, Montserrat AR, Jimenez C *et al.* A Retrospective Cohort Analysis of the Efficacy of Adjuvant Radiotherapy after Primary Surgical Resection in Patients with Adrenocortical Carcinoma. *Journal of Clinical Endocrinology and Metabolism* 2013 **98** 192–197. (<https://doi.org/10.1210/jc.2012-2367>)
- 100 Sabolch A, Else T, Griffith KA, Ben-Josef E, Williams A, Miller BS, Worden F, Hammer GD & Jolly S. Adjuvant radiation therapy improves local control after surgical resection in patients with localized adrenocortical carcinoma. *International Journal of Radiation Oncology, Biology, Physics* 2015 **92** 252–259. (<https://doi.org/10.1016/j.ijrobp.2015.01.007>)
- 101 Berruti A, Terzolo M, Sperone P, Pia A, Della Casa S, Gross DJ, Carnaghi C, Casali P, Porpiglia F, Mantero F *et al.* Etoposide, doxorubicin and cisplatin plus mitotane in the treatment of advanced adrenocortical carcinoma: a large prospective phase II trial. *Endocrine-Related Cancer* 2005 **12** 657–666. (<https://doi.org/10.1677/erc.1.01025>)
- 102 Fassnacht M, Berruti A, Baudin E, Demeure MJ, Gilbert J, Haak H, Kroiss M, Quinn DJ, Hesseltine E, Ronchi CL *et al.* Linsitinib (OSI-906) versus placebo for patients with locally advanced or metastatic adrenocortical carcinoma: a double-blind, randomised, phase 3 study. *Lancet Oncology* 2015 **16** 426–435. ([https://doi.org/10.1016/S1470-2045\(15\)70081-1](https://doi.org/10.1016/S1470-2045(15)70081-1))
- 103 Hermesen IG, Fassnacht M, Terzolo M, Houterman S, den Hartigh J, Leboulleux S, Daffara F, Berruti A, Chadarevian R, Schlumberger M *et al.* Concentrations of o,p' DDD, o,p' DDA, and o,p' DDE as predictors of tumor response to mitotane in adrenocortical carcinoma: results of a retrospective ENS@T multicenter study. *Journal of Clinical Endocrinology and Metabolism* 2011 **96** 1844–1851.
- 104 Sperone P, Ferrero A, Daffara F, Priola A, Zaggia B, Volante M, Santini D, Vincenzi B, Badalamenti G, Intrivici C *et al.* Gemcitabine plus metronomic 5-fluorouracil or capecitabine as a second-/third-line chemotherapy in advanced adrenocortical carcinoma: a multicenter phase II study. *Endocrine-Related Cancer* 2010 **17** 445–453. (<https://doi.org/10.1677/ERC-09-0281>)
- 105 Abraham J, Bakke S, Rutt A, Meadows B, Merino M, Alexander R, Schrupp D, Bartlett D, Choyke P, Robey R *et al.* A phase II trial of combination chemotherapy and surgical resection for the treatment of metastatic adrenocortical carcinoma: continuous infusion doxorubicin, vincristine, and etoposide with daily mitotane as a P-glycoprotein antagonist. *Cancer* 2002 **94** 2333–2343. (<https://doi.org/10.1002/cncr.10487>)
- 106 Baudin E, Docao C, Gicquel C, Vassal G, Bachelot A, Penfornis A & Schlumberger M. Use of a topoisomerase I inhibitor (irinotecan, CPT-11) in metastatic adrenocortical carcinoma. *Annals of Oncology* 2002 **13** 1806–1809. (<https://doi.org/10.1093/annonc/mdf291>)
- 107 Baudin E, Pellegriti G, Bonnay M, Penfornis A, Laplanche A, Vassal G & Schlumberger M. Impact of monitoring plasma 1,1-dichlorodiphenildichloroethane (o,p' DDD) levels on the treatment of patients with adrenocortical carcinoma. *Cancer* 2001 **92** 1385–1392. ([https://doi.org/10.1002/1097-0142\(20010915\)92:6<1385::AID-CNCR1461>3.0.CO;2-2](https://doi.org/10.1002/1097-0142(20010915)92:6<1385::AID-CNCR1461>3.0.CO;2-2))
- 108 Berruti A, Sperone P, Ferrero A, Germano A, Ardito A, Priola AM, De Francia S, Volante M, Daffara F, Generali D *et al.* Phase II study of weekly paclitaxel and sorafenib as second/third-line therapy in patients with adrenocortical carcinoma. *European Journal of Endocrinology* 2012 **166** 451–458. (<https://doi.org/10.1530/EJE-11-0918>)
- 109 Bonacci R, Gigliotti A, Baudin E, Wion-Barbot N, Emy P, Bonnay M, Cailleux AF, Nakib I & Schlumberger M. Cytotoxic therapy with etoposide and cisplatin in advanced adrenocortical carcinoma. *British Journal of Cancer* 1998 **78** 546–549. (<https://doi.org/10.1038/bjc.1998.530>)
- 110 Bukowski RM, Wolfe M, Levine HS, Crawford DE, Stephens RL, Gaynor E & Harker WG. Phase II trial of mitotane and cisplatin in patients with adrenal carcinoma: a Southwest Oncology Group study. *Journal of Clinical Oncology* 1993 **11** 161–165. (<https://doi.org/10.1200/JCO.1993.11.1.161>)
- 111 Decker RA, Elson P, Hogan TF, Citrin DL, Westring DW, Banerjee TK, Gilchrist KW & Horton J. Eastern-Cooperative-Oncology-Group

- Study 1879 – mitotane and adriamycin in patients with advanced adrenocortical carcinoma. *Surgery* 1991 **110** 1006–1013.
- 112 Haak HR, Hermans J, van de Velde CJ, Lentjes EG, Goslings BM, Fleuren GJ & Krans HM. Optimal treatment of adrenocortical carcinoma with mitotane: results in a consecutive series of 96 patients. *British Journal of Cancer* 1994 **69** 947–951. (<https://doi.org/10.1038/bjc.1994.183>)
- 113 Haluska P, Worden F, Olmos D, Yin D, Schteingart D, Batzel GN, Paccagnella ML, de Bono JS, Gualberto A & Hammer GD. Safety, tolerability, and pharmacokinetics of the anti-IGF-1R monoclonal antibody figitumumab in patients with refractory adrenocortical carcinoma. *Cancer Chemotherapy and Pharmacology* 2010 **65** 765–773. (<https://doi.org/10.1007/s00280-009-1083-9>)
- 114 Khan TS, Sundin A, Juhlin C, Wilander E, Oberg K & Eriksson B. Vincristine, cisplatin, teniposide, and cyclophosphamide combination in the treatment of recurrent or metastatic adrenocortical cancer. *Medical Oncology* 2004 **21** 167–177. (<https://doi.org/10.1385/MO:21:2:167>)
- 115 Kroiss M, Deutschbein T, Schlottelburg W, Ronchi CL, Neu B, Muller HH, Quinkler M, Hahner S, Heidemeier A & Fassnacht M. Salvage treatment of adrenocortical carcinoma with trofosfamide. *Hormones and Cancer* 2016 **7** 211–218. (<https://doi.org/10.1007/s12672-016-0260-7>)
- 116 Kroiss M, Quinkler M, Johanssen S, van Erp NP, Lankheet N, Pollinger A, Laubner K, Strasburger CJ, Hahner S, Muller HH *et al.* Sunitinib in refractory adrenocortical carcinoma: a phase II, single-arm, open-label trial. *Journal of Clinical Endocrinology and Metabolism* 2012 **97** 3495–3503. (<https://doi.org/10.1210/jc.2012-1419>)
- 117 Naing A, LoRusso P, Fu S, Hong D, Chen HX, Doyle LA, Phan AT, Habra MA & Kurzrock R. Insulin growth factor receptor (IGF-1R) antibody cixutumumab combined with the mTOR inhibitor temsirolimus in patients with metastatic adrenocortical carcinoma. *British Journal of Cancer* 2013 **108** 826–830. (<https://doi.org/10.1038/bjc.2013.46>)
- 118 O'Sullivan C, Ederly M, Velarde M, Wilkerson J, Venkatesan AM, Pittaluga S, Yang SX, Nguyen D, Balasubramaniam S & Fojo T. The VEGF inhibitor axitinib has limited effectiveness as a therapy for adrenocortical cancer. *Journal of Clinical Endocrinology and Metabolism* 2014 **99** 1291–1297.
- 119 Quinkler M, Hahner S, Wortmann S, Johanssen S, Adam P, Ritter C, Strasburger C, Allolio B & Fassnacht M. Treatment of advanced adrenocortical carcinoma with erlotinib plus gemcitabine. *Journal of Clinical Endocrinology and Metabolism* 2008 **93** 2057–2062. (<https://doi.org/10.1210/jc.2007-2564>)
- 120 Schlumberger M, Brugieres L, Gicquel C, Travagli JP, Droz JP & Parmentier C. 5-Fluorouracil, doxorubicin, and cisplatin as treatment for adrenal-cortical carcinoma. *Cancer* 1991 **67** 2997–3000. ([https://doi.org/10.1002/1097-0142\(19910615\)67:12<2997::AID-CNCR2820671211>3.0.CO;2-#](https://doi.org/10.1002/1097-0142(19910615)67:12<2997::AID-CNCR2820671211>3.0.CO;2-#))
- 121 Urup T, Pawlak WZ, Petersen PM, Pappot H, Rorth M & Daugaard G. Treatment with docetaxel and cisplatin in advanced adrenocortical carcinoma, a phase II study. *British Journal of Cancer* 2013 **108** 1994–1997. (<https://doi.org/10.1038/bjc.2013.229>)
- 122 Williamson SK, Lew D, Miller GJ, Balcerzak SP, Baker LH & Crawford ED. Phase II evaluation of cisplatin and etoposide followed by mitotane at disease progression in patients with locally advanced or metastatic adrenocortical carcinoma – a Southwest Oncology Group study. *Cancer* 2000 **88** 1159–1165. ([https://doi.org/10.1002/\(SICI\)1097-0142\(20000301\)88:5<1159::AID-CNCR28>3.0.CO;2-R](https://doi.org/10.1002/(SICI)1097-0142(20000301)88:5<1159::AID-CNCR28>3.0.CO;2-R))
- 123 Wortmann S, Quinkler M, Ritter C, Kroiss M, Johanssen S, Hahner S, Allolio B & Fassnacht M. Bevacizumab plus capecitabine as a salvage therapy in advanced adrenocortical carcinoma. *European Journal of Endocrinology* 2010 **162** 349–356. (<https://doi.org/10.1530/EJE-09-0804>)
- 124 Henning JEK, Deutschbein T, Altieri B, Steinhauer S, Kircher S, Sbiara S, Wild V, Schlottelburg W, Kroiss M, Perotti P *et al.* Gemcitabine-based chemotherapy in adrenocortical carcinoma: a multicenter study of efficacy and predictive factors. *Journal of Clinical Endocrinology and Metabolism* 2017 **102** 4323–4332. (<https://doi.org/10.1210/jc.2017-01624>)
- 125 Lerario AM, Worden FP, Ramm CA, Hesselstine EA, Stadler WM, Else T, Shah MH, Agamah E, Rao K & Hammer GD. The combination of insulin-like growth factor receptor 1 (IGF1R) antibody cixutumumab and mitotane as a first-line therapy for patients with recurrent/metastatic adrenocortical carcinoma: a multi-institutional NCI-sponsored trial. *Hormones and Cancer* 2014 **5** 232–239. (<https://doi.org/10.1007/s12672-014-0182-1>)
- 126 Datrice NM, Langan RC, Ripley RT, Kemp CD, Steinberg SM, Wood BJ, Libutti SK, Fojo T, Schrupp DS & Avital I. Operative management for recurrent and metastatic adrenocortical carcinoma. *Journal of Surgical Oncology* 2012 **105** 709–713. (<https://doi.org/10.1002/jso.23015>)
- 127 Gaujoux S, Al-Ahmadie H, Allen PJ, Gonen M, Shia J, D'Angelica M, Dematteo R, Fong Y, Blumgart L & Jarnagin WR. Resection of adrenocortical carcinoma liver metastasis: is it justified? *Annals of Surgical Oncology* 2012 **19** 2643–2651. (<https://doi.org/10.1245/s10434-012-2358-7>)
- 128 Kemp CD, Ripley RT, Mathur A, Steinberg SM, Nguyen DM, Fojo T & Schrupp DS. Pulmonary resection for metastatic adrenocortical carcinoma: the National Cancer Institute experience. *Annals of Thoracic Surgery* 2011 **92** 1195–1200. (<https://doi.org/10.1016/j.athoracsur.2011.05.013>)
- 129 Kwak S & Burt M. Pulmonary metastases from adrenal cortical carcinoma: results of resection. *Journal of Surgical Oncology* 1993 **53** 243–246. (<https://doi.org/10.1002/jso.2930530411>)
- 130 op den Winkel J, Pfannschmidt J, Muley T, Grunewald C, Dienemann H, Fassnacht M & Allolio B. Metastatic adrenocortical carcinoma: results of 56 pulmonary metastasectomies in 24 patients. *Annals of Thoracic Surgery* 2011 **92** 1965–1970. (<https://doi.org/10.1016/j.athoracsur.2011.07.088>)
- 131 Ripley RT, Kemp CD, Davis JL, Langan RC, Royal RE, Libutti SK, Steinberg SM, Wood BJ, Kammula US, Fojo T *et al.* Liver resection and ablation for metastatic adrenocortical carcinoma. *Annals of Surgical Oncology* 2011 **18** 1972–1979. (<https://doi.org/10.1245/s10434-011-1564-z>)
- 132 Bellantone R, Ferrante A, Boscherini M, Lombardi CP, Crucitti P, Crucitti F, Favia G, Borrelli D, Boffi L, Capussotti L *et al.* Role of reoperation in recurrence of adrenal cortical carcinoma: results from 188 cases collected in the Italian National Registry for Adrenal Cortical Carcinoma. *Surgery* 1997 **122** 1212–1218. ([https://doi.org/10.1016/S0039-6060\(97\)90229-4](https://doi.org/10.1016/S0039-6060(97)90229-4))
- 133 Crucitti F, Bellantone R, Ferrante A, Boscherini M, Crucitti P, Carbone G, Casaccia M, Campisi C, Cavallaro A, Sapienza P *et al.* The Italian registry for adrenal cortical carcinoma: analysis of a multiinstitutional series of 129 patients. *Surgery* 1996 **119** 161–170. ([https://doi.org/10.1016/S0039-6060\(96\)80164-4](https://doi.org/10.1016/S0039-6060(96)80164-4))
- 134 Dy BM, Wise KB, Richards ML, Young WE, Grant CS, Bible KC, Rosedahl J, Harmsen WS, Farley DR & Thompson GB. Operative intervention for recurrent adrenocortical cancer. *Surgery* 2013 **154** 1292–1299. (<https://doi.org/10.1016/j.surg.2013.06.033>)
- 135 Jensen JC, Pass HI, Sindelar WF & Norton JA. Recurrent or metastatic disease in select patients with adrenocortical carcinoma – aggressive resection vs chemotherapy. *Archives of Surgery* 1991 **126** 457–461. (<https://doi.org/10.1001/archsurg.1991.01410280059008>)
- 136 Simon G, Pattou F, Mirallie E, Lifante JC, Nomine C, Arnault V, de Calan L, Gaillard C, Carnaille B, Brunaud L *et al.* Surgery for recurrent adrenocortical carcinoma: a multicenter retrospective study. *Surgery* 2017 **161** 249–255. (<https://doi.org/10.1016/j.surg.2016.08.058>)
- 137 Tran TB, Liou D, Menon VG & Nissen NN. Surgical management of advanced adrenocortical carcinoma: a 21-year population-based analysis. *American Surgeon* 2013 **79** 1115–1118.

- 138 Dy BM, Strajina V, Cayo AK, Richards ML, Farley DR, Grant CS, Harmsen WS, Evans DB, Grubbs EG, Bible KC *et al.* Surgical resection of synchronously metastatic adrenocortical cancer. *Annals of Surgical Oncology* 2015 **22** 146–151. (<https://doi.org/10.1245/s10434-014-3944-7>)
- 139 Hahner S, Kreissl MC, Fassnacht M, Haenschel H, Knoedler P, Lang K, Buck AK, Reiners C, Allolio B & Schirbel A. [131I] Iodometomidate for targeted radionuclide therapy of advanced adrenocortical carcinoma. *Journal of Clinical Endocrinology and Metabolism* 2012 **97** 914–922. (<https://doi.org/10.1210/jc.2011-2765>)
- 140 Cazejust J, De Baere T, Aupeirin A, Deschamps F, Hechelhammer L, Abdel-Rehim M, Schlumberger M, Leboulleux S & Baudin E. Transcatheter arterial chemoembolization for liver metastases in patients with adrenocortical carcinoma. *Journal of Vascular and Interventional Radiology* 2010 **21** 1527–1532.
- 141 Wood BJ, Abraham J, Hvizda JL, Alexander HR & Fojo T. Radiofrequency ablation of adrenal tumors and adrenocortical carcinoma metastases. *Cancer* 2003 **97** 554–560. (<https://doi.org/10.1002/cncr.11084>)
- 142 Ho J, Turkbey B, Ederly M, Alimchandani M, Quezado M, Camphausen K, Fojo T & Kaushal A. Role of radiotherapy in adrenocortical carcinoma. *Cancer Journal* 2013 **19** 288–294. (<https://doi.org/10.1097/PPO.0b013e31829e3221>)
- 143 Hahner S & Fassnacht M. Mitotane for adrenocortical carcinoma treatment. *Current Opinion in Investigational Drugs* 2005 **6** 386–394.
- 144 Stell A & Sinnott R. The ENSAT registry: a digital repository supporting adrenal cancer research. *Studies in Health Technology and Informatics* 2012 **178** 207–212.
- 145 Fassnacht M, Kenn W & Allolio B. Adrenal tumors: how to establish malignancy? *Journal of Endocrinological Investigation* 2004 **27** 387–399. (<https://doi.org/10.1007/BF03351068>)
- 146 Allolio B & Fassnacht M. Clinical review: adrenocortical carcinoma: clinical update. *Journal of Clinical Endocrinology and Metabolism* 2006 **91** 2027–2037. (<https://doi.org/10.1210/jc.2005-2639>)
- 147 Nieman LK, Biller BM, Findling JW, Newell-Price J, Savage MO, Stewart PM & Montori VM. The diagnosis of Cushing's syndrome: an Endocrine Society Clinical Practice Guideline. *Journal of Clinical Endocrinology and Metabolism* 2008 **93** 1526–1540. (<https://doi.org/10.1210/jc.2008-0125>)
- 148 Libe R, Fratticci A & Bertherat J. Adrenocortical cancer: pathophysiology and clinical management. *Endocrine-Related Cancer* 2007 **14** 13–28. (<https://doi.org/10.1677/erc.1.01130>)
- 149 Legro RS, Arslanian SA, Ehrmann DA, Hoeger KM, Murad MH, Pasquali R & Welt CK. Diagnosis and treatment of polycystic ovary syndrome: an Endocrine Society clinical practice guideline. *Journal of Clinical Endocrinology and Metabolism* 2013 **98** 4565–4592. (<https://doi.org/10.1210/jc.2013-2350>)
- 150 Funder JW, Carey RM, Mantero F, Murad MH, Reincke M, Shibata H, Stowasser M & Young WF Jr. The management of primary aldosteronism: case detection, diagnosis, and treatment: an Endocrine Society Clinical Practice Guideline. *Journal of Clinical Endocrinology and Metabolism* 2016 **101** 1889–1916. (<https://doi.org/10.1210/jc.2015-4061>)
- 151 Dinnes J, Bancos I, Ferrante di Ruffano L, Chortis V, Davenport C, Bayliss S, Sahdev A, Guest P, Fassnacht M, Deeks JJ *et al.* MANAGEMENT OF ENDOCRINE DISEASE: Imaging for the diagnosis of malignancy in incidentally discovered adrenal masses: a systematic review and meta-analysis. *European Journal of Endocrinology* 2016 **175** R51–R64. (<https://doi.org/10.1530/EJE-16-0461>)
- 152 Peppercorn PD, Grossman AB & Reznick RH. Imaging of incidentally discovered adrenal masses. *Clinical Endocrinology* 1998 **48** 379–388. (<https://doi.org/10.1046/j.1365-2265.1998.00475.x>)
- 153 Caoili EM, Korobkin M, Francis IR, Cohan RH, Platt JF, Dunnick NR & Raghupathi KI. Adrenal masses: characterization with combined unenhanced and delayed enhanced CT. *Radiology* 2002 **222** 629–633. (<https://doi.org/10.1148/radiol.2223010766>)
- 154 Blake MA, Kalra MK, Sweeney AT, Lucey BC, Maher MM, Sahani DV, Halpern EF, Mueller PR, Hahn PF & Boland GW. Distinguishing benign from malignant adrenal masses: multi-detector row CT protocol with 10-minute delay. *Radiology* 2006 **238** 578–585. (<https://doi.org/10.1148/radiol.2382041514>)
- 155 Ilias I, Sahdev A, Reznick RH, Grossman AB & Pacak K. The optimal imaging of adrenal tumours: a comparison of different methods. *Endocrine-Related Cancer* 2007 **14** 587–599. (<https://doi.org/10.1677/ERC-07-0045>)
- 156 Mackie GC, Shulkin BL, Ribeiro RC, Worden FP, Gauger PG, Mody RJ, Connolly LP, Kunter G, Rodriguez-Galindo C, Wallis JW *et al.* Use of [18F]fluorodeoxyglucose positron emission tomography in evaluating locally recurrent and metastatic adrenocortical carcinoma. *Journal of Clinical Endocrinology and Metabolism* 2006 **91** 2665–2671. (<https://doi.org/10.1210/jc.2005-2612>)
- 157 Groussin L, Bonardel G, Silveira S, Tissier F, Coste J, Abiven G, Libe R, Bienvenu M, Alberini JL, Salenave S *et al.* 18F-Fluorodeoxyglucose positron emission tomography for the diagnosis of adrenocortical tumors: a prospective study in 77 operated patients. *Journal of Clinical Endocrinology and Metabolism* 2009 **94** 1713–1722. (<https://doi.org/10.1210/jc.2008-2302>)
- 158 Deandreis D, Leboulleux S, Caramella C, Schlumberger M & Baudin E. FDG PET in the management of patients with adrenal masses and adrenocortical carcinoma. *Hormones and Cancer* 2011 **2** 354–362. (<https://doi.org/10.1007/s12672-011-0091-5>)
- 159 Cistaro A, Niccoli Asabella A, Coppolino P, Quartuccio N, Altini C, Cucinotta M, Alongi P, Balma M, Sanfilippo S, Buschiazzo A *et al.* Diagnostic and prognostic value of 18F-FDG PET/CT in comparison with morphological imaging in primary adrenal gland malignancies – a multicenter experience. *Hellenic Journal of Nuclear Medicine* 2015 **18** 97–102.
- 160 Altinmakas E, Hobbs BP, Ye H, Grubbs EG, Perrier ND, Prieto VG, Lee JE & Ng CS. Diagnostic performance of (18)-F-FDG-PET-CT in adrenal lesions using histopathology as reference standard. *Abdominal Radiology* 2017 **42** 577–584. (<https://doi.org/10.1007/s00261-016-0915-4>)
- 161 Ciftci E, Turgut B, Cakmakcilar A & Erturk SA. Diagnostic importance of 18F-FDG PET/CT parameters and total lesion glycolysis in differentiating between benign and malignant adrenal lesions. *Nuclear Medicine Communications* 2017 **38** 788–794. (<https://doi.org/10.1097/MNM.0000000000000712>)
- 162 Bluemel C, Hahner S, Heinze B, Fassnacht M, Kroiss M, Bley TA, Wester HJ, Kropf S, Lapa C, Schirbel A *et al.* Investigating the chemokine receptor 4 as potential theranostic target in adrenocortical cancer patients. *Clinical Nuclear Medicine* 2017 **42** e29–e34. (<https://doi.org/10.1097/RLU.0000000000001435>)
- 163 Werner RA, Kroiss M, Nakajo M, Muggé DO, Hahner S, Fassnacht M, Schirbel A, Bluemel C, Higuchi T, Papp L *et al.* Assessment of tumor heterogeneity in treatment-naive adrenocortical cancer patients using ¹⁸F-FDG positron emission tomography. *Endocrine* 2016 **53** 791–800. (<https://doi.org/10.1007/s12020-016-0970-1>)
- 164 Wu YW & Tan CH. Determination of a cutoff attenuation value on single-phase contrast-enhanced CT for characterizing adrenal nodules via chemical shift MRI. *Abdominal Radiology* 2016 **41** 1170–1177. (<https://doi.org/10.1007/s00261-016-0654-6>)
- 165 Nakajo M, Jinguji M, Shinaji T, Nakabeppu Y, Fukukura Y & Yoshiura T. Texture analysis of FDG PET/CT for differentiating between FDG-avid benign and metastatic adrenal tumors: efficacy of combining SUV and texture parameters. *Abdominal Radiology* 2017 **42** 2882–2889. (<https://doi.org/10.1007/s00261-017-1207-3>)
- 166 Guerin C, Pattou F, Brunaud L, Lifante JC, Mirallie E, Haissaguerre M, Huglo D, Olivier P, Houzard C, Ansquer C *et al.* Performance of 18F-FDG PET/CT in the characterization of adrenal masses in noncancer patients: a prospective study. *Journal of Clinical Endocrinology and Metabolism* 2017 **102** 2465–2472. (<https://doi.org/10.1210/jc.2017-00254>)

- 167 Marty M, Gaye D, Perez P, Auder C, Nunes ML, Ferriere A, Haissaguerre M & Tabarin A. Diagnostic accuracy of computed tomography to identify adenomas among adrenal incidentalomas in an endocrinological population. *European Journal of Endocrinology* 2018 **178** 439–446. (<https://doi.org/10.1530/EJE-17-1056>)
- 168 Kim SJ, Lee SW, Pak K, Kim IJ & Kim K. Diagnostic accuracy of (18) F-FDG PET or PET/CT for the characterization of adrenal masses: a systematic review and meta-analysis. *British Journal of Radiology* 2018 **91** 20170520. (<https://doi.org/10.1259/bjr.20170520>)
- 169 Delivanis DA, Bancos I, Atwell TD, Schmit GD, Eiken PW, Natt N, Erickson D, Maraka S, Young WF & Nathan MA. Diagnostic performance of unenhanced computed tomography and (18) F-fluorodeoxyglucose positron emission tomography in indeterminate adrenal tumours. *Clinical Endocrinology* 2018 **88** 30–36. (<https://doi.org/10.1111/cen.13448>)
- 170 Romeo V, Maurea S, Cuocolo R, Petretta M, Mainenti PP, Verde F, Coppola M, Dell'Aversana S & Brunetti A. Characterization of adrenal lesions on unenhanced MRI using texture analysis: a machine-learning approach. *Journal of Magnetic Resonance Imaging* 2018 **48** 198–204. (<https://doi.org/10.1002/jmri.25954>)
- 171 Thomas AJ, Habra MA, Bhosale PR, Qayyum AA, Ahmed K, Vicens R & Elsayer KM. Interobserver agreement in distinguishing large adrenal adenomas and adrenocortical carcinomas on computed tomography. *Abdominal Radiology* 2018 Epub. (<https://doi.org/10.1007/s00261-018-1603-3>)
- 172 Ng CS, Altinmakas E, Wei W, Ghosh P, Li X, Grubbs EG, Perrier NA, Prieto VG, Lee JE & Hobbs BP. Combining washout and noncontrast data from adrenal protocol CT: improving diagnostic performance. *Academic Radiology* 2018 **25** 861–868. (<https://doi.org/10.1016/j.acra.2017.12.005>)
- 173 Petersenn S, Richter PA, Broemel T, Ritter CO, Deutschbein T, Beil FU, Allolio B & Fassnacht M. Computed tomography criteria for discrimination of adrenal adenomas and adrenocortical carcinomas: analysis of the German ACC registry. *European Journal of Endocrinology* 2015 **172** 415–422. (<https://doi.org/10.1530/EJE-14-0916>)
- 174 Bancos I, Tamhane S, Shah M, Delivanis DA, Alahdab F, Arlt W, Fassnacht M & Murad MH. DIAGNOSIS OF ENDOCRINE DISEASE: The diagnostic performance of adrenal biopsy: a systematic review and meta-analysis. *European Journal of Endocrinology* 2016 **175** R65–R80. (<https://doi.org/10.1530/EJE-16-0297>)
- 175 Williams AR, Hammer GD & Else T. Transcutaneous biopsy of adrenocortical carcinoma is rarely helpful in diagnosis, potentially harmful, but does not affect patient outcome. *European Journal of Endocrinology* 2014 **170** 829–835. (<https://doi.org/10.1530/EJE-13-1033>)
- 176 Palazzo F, Dickinson A, Phillips B, Sahdev A, Bliss R, Rasheed A, Krukowski Z & Newell-Price J. Adrenal surgery in England: better outcomes in high-volume practices. *Clinical Endocrinology* 2016 **85** 17–20. (<https://doi.org/10.1111/cen.13021>)
- 177 Park HS, Roman SA & Sosa JA. Outcomes from 3144 adrenalectomies in the United States: which matters more, surgeon volume or specialty? *Archives of Surgery* 2009 **144** 1060–1067. (<https://doi.org/10.1001/archsurg.2009.191>)
- 178 Lindeman B, Hashimoto DA, Bababekov YJ, Stapleton SM, Chang DC, Hodin RA & Phitayakorn R. Fifteen years of adrenalectomies: impact of specialty training and operative volume. *Surgery* 2018 **163** 150–156. (<https://doi.org/10.1016/j.surg.2017.05.024>)
- 179 Villar JM, Moreno P, Ortega J, Bollo E, Ramirez CP, Munoz N, Martinez C, Dominguez-Adame E, Sancho J, Del Pino JM *et al.* Results of adrenal surgery. Data of a Spanish National Survey. *Langenbecks Archives of Surgery* 2010 **395** 837–843. (<https://doi.org/10.1007/s00423-010-0697-z>)
- 180 Gallagher SF, Wahi M, Haines KL, Baksh K, Enriquez J, Lee TM, Murr MM & Fabri PJ. Trends in adrenalectomy rates, indications, and physician volume: a statewide analysis of 1816 adrenalectomies. *Surgery* 2007 **142** 1011–1021; discussion 1011–1021. (<https://doi.org/10.1016/j.surg.2007.09.024>)
- 181 Lombardi CP, Raffaelli M, Boniardi M, De Toma G, Marzano LA, Miccoli P, Minni F, Morino M, Pelizzo MR, Pietrabissa A *et al.* Adrenocortical carcinoma: effect of hospital volume on patient outcome. *Langenbecks Archives of Surgery* 2012 **397** 201–207. (<https://doi.org/10.1007/s00423-011-0866-8>)
- 182 Gratian L, Pura J, Dinan M, Reed S, Scheri R, Roman S & Sosa JA. Treatment patterns and outcomes for patients with adrenocortical carcinoma associated with hospital case volume in the United States. *Annals of Surgical Oncology* 2014 **21** 3509–3514. (<https://doi.org/10.1245/s10434-014-3931-z>)
- 183 Hermsen IG, Kerkhofs TM, den Butter G, Kievit J, van Eijck CH, Nieveen van Dijkum EJ & Haak HR. Surgery in adrenocortical carcinoma: Importance of national cooperation and centralized surgery. *Surgery* 2012 **152** 50–56. (<https://doi.org/10.1016/j.surg.2012.02.005>)
- 184 Kerkhofs TM, Verhoeven RH, Bonjer HJ, van Dijkum EJ, Vriens MR, De Vries J, Van Eijck CH, Bonsing BA, Van de Poll-Franse LV & Haak HR. Surgery for adrenocortical carcinoma in The Netherlands: analysis of the national cancer registry data. *European Journal of Endocrinology* 2013 **169** 83–89. (<https://doi.org/10.1530/EJE-13-0142>)
- 185 Gaujoux S & Mihai R. European Society of Endocrine Surgeons (ESES) and European Network for the Study of Adrenal Tumours (ENSAT) recommendations for the surgical management of adrenocortical carcinoma. *British Journal of Surgery* 2017 **104** 358–376. (<https://doi.org/10.1002/bjs.10414>)
- 186 Gaujoux S & Brennan MF. Recommendation for standardized surgical management of primary adrenocortical carcinoma. *Surgery* 2012 **152** 123–132. (<https://doi.org/10.1016/j.surg.2011.09.030>)
- 187 Porpiglia F, Fiori C, Daffara FC, Zaggia B, Ardito A, Scarpa RM, Papotti M, Berruti A, Scagliotti GV & Terzolo M. Does nephrectomy during radical adrenalectomy for stage II adrenocortical cancer affect patient outcome? *Journal of Endocrinological Investigation* 2016 **39** 465–471. (<https://doi.org/10.1007/s40618-015-0422-4>)
- 188 Donatini G, Caiazzo R, Do Cao C, Aubert S, Zerrweck C, El-Kathib Z, Gauthier T, Leteurtre E, Wemeau JL, Vantghem MC *et al.* Long-term survival after adrenalectomy for stage I/II adrenocortical carcinoma (ACC): a retrospective comparative cohort study of laparoscopic versus open approach. *Annals of Surgical Oncology* 2014 **21** 284–291. (<https://doi.org/10.1245/s10434-013-3164-6>)
- 189 Sgourakis G, Lanitis S, Kouloura A, Zaphiriadou P, Karkoulas K, Raptis D, Anagnostara A & Caraliotas C. Laparoscopic versus open adrenalectomy for stage I/II adrenocortical carcinoma: meta-analysis of outcomes. *Journal of Investigative Surgery* 2015 **28** 145–152. (<https://doi.org/10.3109/08941939.2014.987886>)
- 190 Autorino R, Bove P, De Sio M, Miano R, Micali S, Cindolo L, Greco F, Nicholas J, Fiori C, Bianchi G *et al.* Open versus laparoscopic adrenalectomy for adrenocortical carcinoma: a meta-analysis of surgical and oncological outcomes. *Annals of Surgical Oncology* 2016 **23** 1195–1202. (<https://doi.org/10.1245/s10434-015-4900-x>)
- 191 Langenhuijsen J, Birtle A, Klatté T, Porpiglia F & Timsit MO. Surgical management of adrenocortical carcinoma: impact of laparoscopic approach, lymphadenectomy, and surgical volume on outcomes—a systematic review and meta-analysis of the current literature. *European Urology Focus* 2016 **1** 241–250. (<https://doi.org/10.1016/j.euf.2015.12.001>)
- 192 Lee CW, Salem AI, Schneider DF, Levenson GE, Tran TB, Poultsides GA, Postlewait LM, Maithel SK, Wang TS, Hatzaras I *et al.* Minimally invasive resection of adrenocortical carcinoma: a multi-institutional study of 201 patients. *Journal of Gastrointestinal Surgery* 2017 **21** 352–362. (<https://doi.org/10.1007/s11605-016-3262-4>)
- 193 Zheng GY, Li HZ, Deng JH, Zhang XB & Wu XC. Open adrenalectomy versus laparoscopic adrenalectomy for adrenocortical carcinoma: a retrospective comparative study on short-term

- oncologic prognosis. *OncoTargets and Therapy* 2018 **11** 1625–1632. (<https://doi.org/10.2147/OTT.S157518>)
- 194 Mpaili E, Moris D, Tsilimigras DI, Oikonomou D, Pawlik TM, Schizas D, Papalampros A, Felekouras E & Dimitroulis D. Laparoscopic versus open adrenalectomy for localized/locally advanced primary adrenocortical carcinoma (ENSAT I-III) in adults: is margin-free resection the key surgical factor that dictates outcome? A review of the literature. *Journal of Laparoendoscopic and Advanced Surgical Techniques Part A* 2018 **28** 408–414. (<https://doi.org/10.1089/lap.2017.0546>)
- 195 Huynh KT, Lee DY, Lau BJ, Flaherty DC, Lee J & Goldfarb M. Impact of laparoscopic adrenalectomy on overall survival in patients with nonmetastatic adrenocortical carcinoma. *Journal of the American College of Surgeons* 2016 **223** 485–492. (<https://doi.org/10.1016/j.jamcollsurg.2016.05.015>)
- 196 Barczynski M, Konturek A, Golkowski F, Cichon S, Huszno B, Peitgen K & Walz MK. Posterior retroperitoneoscopic adrenalectomy: a comparison between the initial experience in the invention phase and introductory phase of the new surgical technique. *World Journal of Surgery* 2007 **31** 65–71. (<https://doi.org/10.1007/s00268-006-0083-8>)
- 197 Schreinemakers JM, Kiela GJ, Valk GD, Vriens MR & Rinkes IH. Retroperitoneal endoscopic adrenalectomy is safe and effective. *British Journal of Surgery* 2010 **97** 1667–1672. (<https://doi.org/10.1002/bjs.7191>)
- 198 Nilubol N, Patel D & Kebebew E. Does lymphadenectomy improve survival in patients with adrenocortical carcinoma? A population-based study. *World Journal of Surgery* 2016 **40** 697–705. (<https://doi.org/10.1007/s00268-015-3283-2>)
- 199 Saade N, Sadler C & Goldfarb M. Impact of regional lymph node dissection on disease specific survival in adrenal cortical carcinoma. *Hormone and Metabolic Research* 2015 **47** 820–825. (<https://doi.org/10.1055/s-0035-1549877>)
- 200 Harrison LE, Gaudin PB & Brennan MF. Pathologic features of prognostic significance for adrenocortical carcinoma after curative resection. *Archives of Surgery* 1999 **134** 181–185. (<https://doi.org/10.1001/archsurg.134.2.181>)
- 201 Panjwani S, Moore MD, Gray KD, Finnerty BM, Beninato T, Brunaud L, Fahey TJ 3rd & Zarnekar R. The impact of nodal dissection on staging in adrenocortical carcinoma. *Annals of Surgical Oncology* 2017 **24** 3617–3623. (<https://doi.org/10.1245/s10434-017-6064-3>)
- 202 Gerry JM, Tran TB, Postlewait LM, Maithele SK, Prescott JD, Wang TS, Glenn JA, Phay JE, Keplinger K, Fields RC *et al.* Lymphadenectomy for adrenocortical carcinoma: is there a therapeutic benefit? *Annals of Surgical Oncology* 2016 **23** 708–713. (<https://doi.org/10.1245/s10434-016-5536-1>)
- 203 Reibetanz J, Jurowich C, Erdogan I, Nies C, Rayes N, Dralle H, Behrend M, Allolio B & Fassnacht M. Impact of lymphadenectomy on the oncologic outcome of patients with adrenocortical carcinoma. *Annals of Surgery* 2012 **255** 363–369. (<https://doi.org/10.1097/SLA.0b013e3182367ac3>)
- 204 Chiche L, Dousset B, Kieffer E & Chapuis Y. Adrenocortical carcinoma extending into the inferior vena cava: presentation of a 15-patient series and review of the literature. *Surgery* 2006 **139** 15–27. (<https://doi.org/10.1016/j.surg.2005.05.014>)
- 205 Turbendian HK, Strong VE, Hsu M, Ghossein RA & Fahey TJ. Adrenocortical carcinoma: the influence of large vessel extension. *Surgery* 2010 **148** 1057–1064. (<https://doi.org/10.1016/j.surg.2010.09.024>)
- 206 Mihai R, Iacobone M, Makay O, Moreno P, Frilling A, Kraimps JL, Soriano A, Villar del Moral J, Barczynski M, Duran MC *et al.* Outcome of operation in patients with adrenocortical cancer invading the inferior vena cava – a European Society of Endocrine Surgeons (ESES) survey. *Langenbecks Archives of Surgery* 2012 **397** 225–231. (<https://doi.org/10.1007/s00423-011-0876-6>)
- 207 Eller-Vainicher C, Morelli V, Salcuni AS, Battista C, Torlontano M, Coletti F, Iorio L, Cairoli E, Beck-Peccoz P, Arosio M *et al.* Accuracy of several parameters of hypothalamic-pituitary-adrenal axis activity in predicting before surgery the metabolic effects of the removal of an adrenal incidentaloma. *European Journal of Endocrinology* 2010 **163** 925–935. (<https://doi.org/10.1530/EJE-10-0602>)
- 208 Bornstein SR, Allolio B, Arlt W, Barthel A, Don-Wauchope A, Hammer GD, Husebye ES, Merke DP, Murad MH, Stratakis CA *et al.* Diagnosis and treatment of primary adrenal insufficiency: an Endocrine Society Clinical Practice Guideline. *Journal of Clinical Endocrinology and Metabolism* 2016 **101** 364–389. (<https://doi.org/10.1210/jc.2015-1710>)
- 209 Duregon E, Volante M, Bollito E, Goia M, Buttiglieri C, Zaggia B, Berruti A, Scagliotti GV & Papotti M. Pitfalls in the diagnosis of adrenocortical tumors: a lesson from 300 consultation cases. *Human Pathology* 2015 **46** 1799–1807. (<https://doi.org/10.1016/j.humpath.2015.08.012>)
- 210 Sangoi AR, Fujiwara M, West RB, Montgomery KD, Bonventre JV, Higgins JP, Rouse RV, Gokden N & McKenney JK. Immunohistochemical distinction of primary adrenal cortical lesions from metastatic clear cell renal cell carcinoma: a study of 248 cases. *American Journal of Surgical Pathology* 2011 **35** 678–686. (<https://doi.org/10.1097/PAS.0b013e3182152629>)
- 211 Weissferdt A, Phan A, Suster S & Moran CA. Adrenocortical carcinoma: a comprehensive immunohistochemical study of 40 cases. *Applied Immunohistochemistry and Molecular Morphology* 2014 **22** 24–30. (<https://doi.org/10.1097/PAI.0b013e31828a96cf>)
- 212 Tissier F, Aubert S, Leteurtre E, Alghuzlan A, Patey M, Decaussin M, Dousset L, Gobet F, Hoang C, Mazerolles C *et al.* Adrenocortical tumors (ACT): evaluation and harmonization of the reading of the Weiss system criteria at the French level. *Laboratory Investigation* 2010 **90** 133A.
- 213 Tissier F, Aubert S, Leteurtre E, Al Ghuzlan A, Patey M, Decaussin M, Doucet L, Gobet F, Hoang C, Mazerolles C *et al.* Adrenocortical tumors: improving the practice of the weiss system through virtual microscopy a national program of the French Network INCa-COMETE. *American Journal of Surgical Pathology* 2012 **36** 1194–1201. (<https://doi.org/10.1097/PAS.0b013e31825a6308>)
- 214 Weiss LM. Comparative histologic study of 43 metastasizing and nonmetastasizing adrenocortical tumors. *American Journal of Surgical Pathology* 1984 **8** 163–169. (<https://doi.org/10.1097/00000478-198403000-00001>)
- 215 Weiss LM, Medeiros LJ & Vickery AL Jr. Pathologic features of prognostic significance in adrenocortical carcinoma. *American Journal of Surgical Pathology* 1989 **13** 202–206. (<https://doi.org/10.1097/00000478-198903000-00004>)
- 216 van Slooten H, Schaberg A, Smeenk D & Moolenaar AJ. Morphologic characteristics of benign and malignant adrenocortical tumors. *Cancer* 1985 **55** 766–773. ([https://doi.org/10.1002/1097-0142\(19850215\)55:4<766::AID-CNCR2820550414>3.0.CO;2-7](https://doi.org/10.1002/1097-0142(19850215)55:4<766::AID-CNCR2820550414>3.0.CO;2-7))
- 217 Duregon E, Fassina A, Volante M, Nesi G, Santi R, Gatti G, Cappellesso R, Dalino Ciaramella P, Ventura L, Gambacorta M *et al.* The reticulin algorithm for adrenocortical tumor diagnosis: a multicentric validation study on 245 unpublished cases. *American Journal of Surgical Pathology* 2013 **37** 1433–1440. (<https://doi.org/10.1097/PAS.0b013e31828d387b>)
- 218 Bisceglia M, Ludovico O, Di Mattia A, Ben-Dor D, Sandbank J, Pasquinelli G, Lau SK & Weiss LM. Adrenocortical oncocytic tumors: report of 10 cases and review of the literature. *International Journal of Surgical Pathology* 2004 **12** 231–243. (<https://doi.org/10.1177/106689690401200304>)
- 219 Duregon E, Volante M, Cappia S, Cuccurullo A, Bisceglia M, Wong DD, Spagnolo DV, Szpak-Ulczuk S, Bollito E, Daffara F *et al.* Oncocytic adrenocortical tumors: diagnostic algorithm and mitochondrial DNA profile in 27 cases. *American Journal of*

- Surgical Pathology* 2011 **35** 1882–1893. (<https://doi.org/10.1097/PAS.0b013e31822da401>)
- 220 Wong DD, Spagnolo DV, Bisceglia M, Havlat M, McCallum D & Platten MA. Oncocytic adrenocortical neoplasms – a clinicopathologic study of 13 new cases emphasizing the importance of their recognition. *Human Pathology* 2011 **42** 489–499. (<https://doi.org/10.1016/j.humpath.2010.08.010>)
- 221 Fuhrman SA, Lasky LC & Limas C. Prognostic significance of morphologic parameters in renal cell carcinoma. *American Journal of Surgical Pathology* 1982 **6** 655–663. (<https://doi.org/10.1097/0000478-198210000-00007>)
- 222 Lu H, Papatomas TG, van Zessen D, Palli I, de Krijger RR, van der Spek PJ, Dinjens WN & Stubbs AP. Automated Selection of Hotspots (ASH): enhanced automated segmentation and adaptive step finding for Ki67 hotspot detection in adrenal cortical cancer. *Diagnostic Pathology* 2014 **9** 216. (<https://doi.org/10.1186/s13000-014-0216-6>)
- 223 Papatomas TG, Pucci E, Giordano TJ, Lu H, Duregon E, Volante M, Papotti M, Lloyd RV, Tischler AS, van Nederveen FH *et al.* An international Ki67 reproducibility study in adrenal cortical carcinoma. *American Journal of Surgical Pathology* 2016 **40** 569–576. (<https://doi.org/10.1097/PAS.0000000000000574>)
- 224 Morimoto R, Satoh F, Murakami O, Suzuki T, Abe T, Tanemoto M, Abe M, Uruno A, Ishidoya S, Arai Y *et al.* Immunohistochemistry of a proliferation marker Ki67/MIB1 in adrenocortical carcinomas: Ki67/MIB1 labeling index is a predictor for recurrence of adrenocortical carcinomas. *Endocrine Journal* 2008 **55** 49–55. (<https://doi.org/10.1507/endocrj.K07-079>)
- 225 Abiven G, Coste J, Groussin L, Anract P, Tissier F, Legmann P, Dousset B, Bertagna X & Bertherat J. Clinical and biological features in the prognosis of adrenocortical cancer: poor outcome of cortisol-secreting tumors in a series of 202 consecutive patients. *Journal of Clinical Endocrinology and Metabolism* 2006 **91** 2650–2655.
- 226 Burotto M, Tajeja N, Rosenberg A, Mahalingam S, Quezado M, Velarde M, Edgerly M & Fojo T. Brain metastasis in patients with adrenocortical carcinoma: a clinical series. *Journal of Clinical Endocrinology and Metabolism* 2015 **100** 331–336. (<https://doi.org/10.1210/jc.2014-2650>)
- 227 Leboulleux S, Dromain C, Bonniaud G, Auperin A, Caillou B, Lumbroso J, Sigal R, Baudin E & Schlumberger M. Diagnostic and prognostic value of 18-fluorodeoxyglucose positron emission tomography in adrenocortical carcinoma: a prospective comparison with computed tomography. *Journal of Clinical Endocrinology and Metabolism* 2006 **91** 920–925.
- 228 Ardito A, Massaglia C, Pelosi E, Zaggia B, Basile V, Brambilla R, Vigna-Taglianti F, Duregon E, Arena V, Perotti P *et al.* 18F-FDG PET/CT in the post-operative monitoring of patients with adrenocortical carcinoma. *European Journal of Endocrinology* 2015 **173** 749–756. (<https://doi.org/10.1530/EJJE-15-0707>)
- 229 Berruti A, Fassnacht M, Baudin E, Hammer G, Haak H, Leboulleux S, Skogseid B, Allolio B & Terzolo M. Adjuvant therapy in patients with adrenocortical carcinoma: a position of an international panel. *Journal of Clinical Oncology* 2010 **28** e401–e402; author reply e403. (<https://doi.org/10.1200/JCO.2009.27.5958>)
- 230 Megerle F, Herrmann W, Schloetelburg W, Ronchi CL, Pulzer A, Quinkler M, Beuschlein F, Hahner S, Kroiss M & Fassnacht M. Mitotane monotherapy in patients with advanced adrenocortical carcinoma. *Journal of Clinical Endocrinology and Metabolism* 2018 **103** 1686–1695. (<https://doi.org/10.1210/jc.2017-02591>)
- 231 Volante M, Terzolo M, Fassnacht M, Rapa I, Germano A, Sbiera S, Daffara F, Sperone P, Scagliotti G, Allolio B *et al.* Ribonucleotide reductase large subunit (RRM1) gene expression may predict efficacy of adjuvant mitotane in adrenocortical cancer. *Clinical Cancer Research* 2012 **18** 3452–3461. (<https://doi.org/10.1158/1078-0432.CCR-11-2692>)
- 232 Ronchi CL, Sbiera S, Volante M, Steinhauer S, Scott-Wild V, Altieri B, Kroiss M, Bala M, Papotti M, Deutschbein T *et al.* CYP2W1 is highly expressed in adrenal glands and is positively associated with the response to mitotane in adrenocortical carcinoma. *PLoS ONE* 2014 **9** e105855. (<https://doi.org/10.1371/journal.pone.0105855>)
- 233 Terzolo M, Baudin AE, Ardito A, Kroiss M, Leboulleux S, Daffara F, Perotti P, Feelders RA, deVries JH, Zaggia B *et al.* Mitotane levels predict the outcome of patients with adrenocortical carcinoma treated adjuvantly following radical resection. *European Journal of Endocrinology* 2013 **169** 263–270. (<https://doi.org/10.1530/EJJE-13-0242>)
- 234 Terzolo M, Daffara F, Ardito A, Zaggia B, Basile V, Ferrari L & Berruti A. Management of adrenal cancer: a 2013 update. *Journal of Endocrinological Investigation* 2014 **37** 207–217. (<https://doi.org/10.1007/s40618-013-0049-2>)
- 235 Huang H & Fojo T. Adjuvant mitotane for adrenocortical cancer – a recurring controversy. *Journal of Clinical Endocrinology and Metabolism* 2008 **93** 3730–3732. (<https://doi.org/10.1210/jc.2008-0579>)
- 236 Terzolo M, Fassnacht M, Ciccone G, Allolio B & Berruti A. Adjuvant mitotane for adrenocortical cancer – working through uncertainty. *Journal of Clinical Endocrinology and Metabolism* 2009 **94** 1879–1880. (<https://doi.org/10.1210/jc.2009-0120>)
- 237 Polat B, Fassnacht M, Pfreundner L, Guckenberger M, Bratengeier K, Johansen S, Kenn W, Hahner S, Allolio B & Flentje M. Radiotherapy in adrenocortical carcinoma. *Cancer* 2009 **115** 2816–2823. (<https://doi.org/10.1002/cncr.24331>)
- 238 Sabolch A, Else T, Jackson W, Williams A, Miller BS, Worden F, Hammer GD & Jolly S. Improved local control with adjuvant radiation therapy in localized adrenocortical carcinoma: a case-matched retrospective study. *International Journal of Radiation Oncology Biology Physics* 2013 **1** S84. (<https://doi.org/10.1016/j.ijrobp.2013.06.219>)
- 239 Nelson DW, Chang SC, Bandera BC, Fischer TD, Wollman R & Goldfarb M. Adjuvant radiation is associated with improved survival for select patients with non-metastatic adrenocortical carcinoma. *Annals of Surgical Oncology* 2018 **25** 2060–2066. (<https://doi.org/10.1245/s10434-018-6510-x>)
- 240 Cerquetti L, Bucci B, Marchese R, Misiti S, De Paula U, Miceli R, Muleti A, Amendola D, Piergrossi P, Brunetti E *et al.* Mitotane increases the radiotherapy inhibitory effect and induces G2-arrest in combined treatment on both H295R and SW13 adrenocortical cell lines. *Endocrine-Related Cancer* 2008 **15** 623–634. (<https://doi.org/10.1677/erc.1.1315>)
- 241 Cerquetti L, Sampaoli C, Amendola D, Bucci B, Misiti S, Raza G, De Paula U, Marchese R, Brunetti E, Toscano V *et al.* Mitotane sensitizes adrenocortical cancer cells to ionizing radiations by involvement of the cyclin B1/CDK complex in G2 arrest and mismatch repair enzymes modulation. *International Journal of Oncology* 2010 **37** 493–501.
- 242 Khan TS, Imam H, Juhlin C, Skogseid B, Grondal S, Tibblin S, Wilander E, Oberg K & Eriksson B. Streptozocin and o,p'DDD in the treatment of adrenocortical cancer patients: long-term survival in its adjuvant use. *Annals of Oncology* 2000 **11** 1281–1287. (<https://doi.org/10.1023/A:1008377915129>)
- 243 Hermsen IGC, Gelderblom H, Kievit J, Romijn JA & Haak HR. Extremely long survival in six patients despite recurrent and metastatic adrenal carcinoma. *European Journal of Endocrinology* 2008 **158** 911–919. (<https://doi.org/10.1530/EJJE-07-0723>)
- 244 Bednarski BK, Habra MA, Phan A, Milton DR, Wood C, Vauthey N, Evans DB, Katz MH, Ng CS, Perrier ND *et al.* Borderline resectable adrenal cortical carcinoma: a potential role for preoperative chemotherapy. *World Journal of Surgery* 2014 **38** 1318–1327. (<https://doi.org/10.1007/s00268-014-2484-4>)
- 245 Wangberg B, Khorram-Manesh A, Jansson S, Nilsson O, Nilsson O, Jakobsson CE, Lindstedt S, Oden A & Ahlman H. The long-term survival in adrenocortical carcinoma with active surgical management and use of monitored mitotane. *Endocrine-Related Cancer* 2010 **17** 265–272. (<https://doi.org/10.1677/ERC-09-0190>)

- 246 Rangel C, Scattolin G, Pais-Costa SR, Vieira E & Gaio E. Neoadjuvant chemotherapy and salvage surgery for an aldosterone-producing adrenal carcinoma with inferior vena cava thrombus: case report and literature review. *Asian Journal of Surgery* 2013 **36** 134–136. (<https://doi.org/10.1016/j.asjsur.2012.08.008>)
- 247 Ronchi CL, Sbiera S, Kraus L, Wortmann S, Johanssen S, Adam P, Willenberg HS, Hahner S, Allolio B & Fassnacht M. Expression of excision repair cross complementing group 1 and prognosis in adrenocortical carcinoma patients treated with platinum-based chemotherapy. *Endocrine-Related Cancer* 2009 **16** 907–918. (<https://doi.org/10.1677/ERC-08-0224>)
- 248 Malandrino P, Al Ghuzlan A, Castaing M, Young J, Caillou B, Travagli JP, Elias D, de Baere T, Dromain C, Paci A *et al.* Prognostic markers of survival after combined mitotane- and platinum-based chemotherapy in metastatic adrenocortical carcinoma. *Endocrine-Related Cancer* 2010 **17** 797–807. (<https://doi.org/10.1677/ERC-09-0341>)
- 249 Roca E, Berruti A, Sbiera S, Rapa I, Oneda E, Sperone P, Ronchi CL, Ferrari L, Grisanti S, Germano A *et al.* Topoisomerase2alpha and thymidylate synthase expression in adrenocortical cancer. *Endocrine-Related Cancer* 2017 **24** 299–307. (<https://doi.org/10.1530/ERC-17-0095>)
- 250 Laufs V, Altieri B, Sbiera S, Kircher S, Steinhauer S, Beuschlein F, Quinkler M, Willenberg HS, Rosenwald A, Fassnacht M *et al.* ERCC1 as predictive biomarker to platinum-based chemotherapy in adrenocortical carcinomas. *European Journal of Endocrinology* 2018 **178** 183–190. (<https://doi.org/10.1530/EJE-17-0788>)
- 251 Bates SE, Shieh CY, Mickley LA, Dichek HL, Gazdar A, Loriaux DL & Fojo AT. Mitotane enhances cytotoxicity of chemotherapy in cell lines expressing a multidrug resistance gene (mdr-1/P-glycoprotein) which is also expressed by adrenocortical carcinomas. *Journal of Clinical Endocrinology and Metabolism* 1991 **73** 18–29. (<https://doi.org/10.1210/jcem-73-1-18>)
- 252 Almeida MQ, Fragoso MC, Lotfi CF, Santos MG, Nishi MY, Costa MH, Lerario AM, Maciel CC, Mattos GE, Jorge AA *et al.* Expression of IGF-II and its receptor in pediatric and adult adrenocortical tumors. *Journal of Clinical Endocrinology and Metabolism* 2008 **93** 3524–3531. (<https://doi.org/10.1210/jc.2008-0065>)
- 253 Boule N, Logie A, Gicquel C, Perin L & Le Bouc Y. Increased levels of insulin-like growth factor II (IGF-II) and IGF-binding protein-2 are associated with malignancy in sporadic adrenocortical tumors. *Journal of Clinical Endocrinology and Metabolism* 1998 **83** 1713–1720.
- 254 Gicquel C, Bertagna X, Schneid H, Francillard-Leblond M, Luton JP, Girard F & Le Bouc Y. Rearrangements at the 11p15 locus and overexpression of insulin-like growth factor-II gene in sporadic adrenocortical tumors. *Journal of Clinical Endocrinology and Metabolism* 1994 **78** 1444–1453.
- 255 Giordano TJ, Thomas DG, Kuick R, Lizyness M, Misek DE, Smith AL, Sanders D, Aljundi RT, Gauger PG, Thompson NW *et al.* Distinct transcriptional profiles of adrenocortical tumors uncovered by DNA microarray analysis. *American Journal of Pathology* 2003 **162** 521–531. ([https://doi.org/10.1016/S0002-9440\(10\)63846-1](https://doi.org/10.1016/S0002-9440(10)63846-1))
- 256 Weber MM, Fottner C & Wolf E. The role of the insulin-like growth factor system in adrenocortical tumorigenesis. *European Journal of Clinical Investigation* 2000 **30** (Supplement 3) 69–75. (<https://doi.org/10.1046/j.1365-2362.2000.0300s3069.x>)
- 257 Jones RL, Kim ES, Nava-Parada P, Alam S, Johnson FM, Stephens AW, Simantov R, Poondru S, Gedrich R, Lippman SM *et al.* Phase I study of intermittent oral dosing of the insulin-like growth factor-1 and insulin receptors inhibitor OSI-906 in patients with advanced solid tumors. *Clinical Cancer Research* 2015 **21** 693–700. (<https://doi.org/10.1158/1078-0432.CCR-14-0265>)
- 258 Naing A, Kurzrock R, Burger A, Gupta S, Lei X, Busaidy N, Hong D, Chen HX, Doyle LA, Heilbrun LK *et al.* Phase I trial of cixutumumab combined with temsirolimus in patients with advanced cancer. *Clinical Cancer Research* 2011 **17** 6052–6060. (<https://doi.org/10.1158/1078-0432.CCR-10-2979>)
- 259 Vezzosi D, Do Cao C, Hescot S, Bertherat J, Haissaguerre M, Bongard V, Drui D, De La Fouchardiere C, Illouz F, Borson-Chazot F *et al.* Time until partial response in metastatic adrenocortical carcinoma long-term survivors. *Hormones and Cancer* 2018 **9** 62–69. (<https://doi.org/10.1007/s12672-017-0313-6>)
- 260 Kroiss M, Quinkler M, Lutz WK, Allolio B & Fassnacht M. Drug interactions with mitotane by induction of CYP3A4 metabolism in the clinical management of adrenocortical carcinoma. *Clinical Endocrinology* 2011 **75** 585–591. (<https://doi.org/10.1111/j.1365-2265.2011.04214.x>)
- 261 Faggiano A, Leboulleux S, Young J, Schlumberger M & Baudin E. Rapidly progressing high o,p'-DDD doses shorten the time required to reach the therapeutic threshold with an acceptable tolerance: preliminary results. *Clinical Endocrinology* 2006 **64** 110–113. (<https://doi.org/10.1111/j.1365-2265.2005.02403.x>)
- 262 Mauclere-Denost S, Leboulleux S, Borget I, Paci A, Young J, Al Ghuzlan A, Deandreis D, Drouard L, Tabarin A, Chanson P *et al.* High-dose mitotane strategy in adrenocortical carcinoma (ACC): prospective analysis of plasma mitotane measurement during the first three months of follow-up. *European Journal of Endocrinology* 2011 **166** 261–268. (<https://doi.org/10.1530/EJE-11-0557>)
- 263 Terzolo M, Pia A, Berruti A, Osella G, Ali A, Carbone V, Testa E, Dogliotti L & Angeli A. Low-dose monitored mitotane treatment achieves the therapeutic range with manageable side effects in patients with adrenocortical cancer. *Journal of Clinical Endocrinology and Metabolism* 2000 **85** 2234–2238.
- 264 Terzolo M & Berruti A. Adjunctive treatment of adrenocortical carcinoma. *Current Opinion in Endocrinology, Diabetes and Obesity* 2008 **15** 221–226. (<https://doi.org/10.1097/MED.0b013e3282df4c0>)
- 265 Kerkhofs TM, Baudin E, Terzolo M, Allolio B, Chadarevian R, Mueller HH, Skogseid B, Leboulleux S, Mantero F, Haak HR *et al.* Comparison of two mitotane starting dose regimens in patients with advanced adrenocortical carcinoma. *Journal of Clinical Endocrinology and Metabolism* 2013 **98** 4759–4767. (<https://doi.org/10.1210/jc.2013-2281>)
- 266 Moolenaar AJ, van Slooten H, van Seters AP & Smeenk D. Blood levels of o,p'-DDD following administration in various vehicles after a single dose and during long-term treatment. *Cancer Chemotherapy and Pharmacology* 1981 **7** 51–54. (<https://doi.org/10.1007/BF00258213>)
- 267 Kerkhofs TM, Derijks LJ, Eттаieb MH, Eekhoff EM, Neef C, Gelderblom H, den Hartigh J, Guchelaar HJ & Haak HR. Short-term variation in plasma mitotane levels confirms the importance of trough level monitoring. *European Journal of Endocrinology* 2014 **171** 677–683. (<https://doi.org/10.1530/EJE-14-0388>)
- 268 Daffara F, De Francia S, Reimondo G, Zaggia B, Arosio E, Porpiglia F, Volante M, Termine A, Di Carlo F, Dogliotti L *et al.* Prospective evaluation of mitotane toxicity in adrenocortical cancer patients treated adjuvantly. *Endocrine-Related Cancer* 2008 **15** 1043–1053. (<https://doi.org/10.1677/ERC-08-0103>)
- 269 van Slooten H, Moolenaar AJ, van Seters AP & Smeenk D. The treatment of adrenocortical carcinoma with o,p'-DDD: prognostic implications of serum level monitoring. *European Journal of Cancer and Clinical Oncology* 1984 **20** 47–53. ([https://doi.org/10.1016/0277-5379\(84\)90033-6](https://doi.org/10.1016/0277-5379(84)90033-6))
- 270 Chortis V, Taylor AE, Schneider P, Tomlinson JW, Hughes BA, O'Neil DM, Libé R, Allolio B, Bertagna X, Bertherat J *et al.* Mitotane therapy in adrenocortical cancer induces CYP3A4 and inhibits 5 α -reductase, explaining the need for personalized glucocorticoid and androgen replacement. *Journal of Clinical Endocrinology and Metabolism* 2013 **98** 161–171. (<https://doi.org/10.1210/jc.2012-2851>)
- 271 Reimondo G, Puglisi S, Zaggia B, Basile V, Saba L, Perotti P, De Francia S, Volante M, Zatelli MC, Cannavo S *et al.* Effects of mitotane on the hypothalamic-pituitary-adrenal axis in patients with

- adrenocortical carcinoma. *European Journal of Endocrinology* 2017 **177** 361–367. (<https://doi.org/10.1530/EJE-17-0452>)
- 272 Kerkhofs TM, Derijks LJ, Eттаieb H, den Hartigh J, Neef K, Gelderblom H, Guchelaar HJ & Haak HR. Development of a pharmacokinetic model of mitotane: toward personalized dosing in adrenocortical carcinoma. *Therapeutic Drug Monitoring* 2015 **37** 58–65. (<https://doi.org/10.1097/FTD.000000000000102>)
- 273 Alexandraki KI, Kaltsas GA, le Roux CW, Fassnacht M, Ajodha S, Christ-Crain M, Akker SA, Drake WM, Edwards R, Allolio B *et al.* Assessment of serum-free cortisol levels in patients with adrenocortical carcinoma treated with mitotane: a pilot study. *Clinical Endocrinology* 2010 **72** 305–311. (<https://doi.org/10.1111/j.1365-2265.2009.03631.x>)
- 274 Russo M, Scollo C, Pellegriti G, Cotta OR, Squatrito S, Frasca F, Cannavo S & Gullo D. Mitotane treatment in patients with adrenocortical cancer causes central hypothyroidism. *Clinical Endocrinology* 2016 **84** 614–619. (<https://doi.org/10.1111/cen.12868>)
- 275 Tada H, Nohara A, Kawashiri MA, Inazu A, Mabuchi H & Yamagishi M. Marked transient hypercholesterolemia caused by low-dose mitotane as adjuvant chemotherapy for adrenocortical carcinoma. *Journal of Atherosclerosis and Thrombosis* 2014 **21** 1326–1329. (<https://doi.org/10.5551/jat.27557>)
- 276 Nieman LK, Biller BM, Findling JW, Murad MH, Newell-Price J, Savage MO & Tabarin A. Treatment of Cushing's syndrome: an Endocrine Society Clinical Practice Guideline. *Journal of Clinical Endocrinology and Metabolism* 2015 **100** 2807–2831. (<https://doi.org/10.1210/jc.2015-1818>)
- 277 Claps M, Cerri S, Grisanti S, Lazzari B, Ferrari V, Roca E, Perotti P, Terzolo M, Sigala S & Berruti A. Adding metyrapone to chemotherapy plus mitotane for Cushing's syndrome due to advanced adrenocortical carcinoma. *Endocrine* 2017 **61** 169–172. (<https://doi.org/10.1007/s12020-017-1428-9>)
- 278 Castinetti F, Fassnacht M, Johanssen S, Terzolo M, Bouchard P, Chanson P, Do Cao C, Morange I, Pico A, Ouzounian S *et al.* Merits and pitfalls of mifepristone in Cushing's syndrome. *European Journal of Endocrinology* 2009 **160** 1003–1010. (<https://doi.org/10.1530/EJE-09-0098>)
- 279 Chow E, Hoskin P, Mitera G, Zeng L, Lutz S, Roos D, Hahn C, van der Linden Y, Hartsell W & Kumar E. Update of the international consensus on palliative radiotherapy endpoints for future clinical trials in bone metastases. *International Journal of Radiation Oncology, Biology, Physics* 2012 **82** 1730–1737. (<https://doi.org/10.1016/j.ijrobp.2011.02.008>)
- 280 Pin Y, Paix A, Le Fevre C, Antoni D, Blondet C & Noel G. A systematic review of palliative bone radiotherapy based on pain relief and retreatment rates. *Critical Reviews in Oncology/Hematology* 2018 **123** 132–137. (<https://doi.org/10.1016/j.critrevonc.2018.01.006>)
- 281 Ferrell BR, Temel JS, Temin S, Alesi ER, Balboni TA, Basch EM, Firn JI, Paice JA, Peppercorn JM, Phillips T *et al.* Integration of palliative care into standard oncology care: American Society of Clinical Oncology Clinical Practice Guideline update. *Journal of Clinical Oncology* 2017 **35** 96–112. (<https://doi.org/10.1200/JCO.2016.70.1474>)
- 282 Herrmann LJ, Heinze B, Fassnacht M, Willenberg HS, Quinkler M, Reisch N, Zink M, Allolio B & Hahner S. TP53 germline mutations in adult patients with adrenocortical carcinoma. *Journal of Clinical Endocrinology and Metabolism* 2012 **97** E476–E485. (<https://doi.org/10.1210/jc.2011-1982>)
- 283 Raymond VM, Else T, Everett JN, Long JM, Gruber SB & Hammer GD. Prevalence of germline TP53 mutations in a prospective series of unselected patients with adrenocortical carcinoma. *Journal of Clinical Endocrinology and Metabolism* 2013 **98** E119–E125. (<https://doi.org/10.1210/jc.2012-2198>)
- 284 Waldmann J, Patsalis N, Fendrich V, Langer P, Saeger W, Chaloupka B, Ramaswamy A, Fassnacht M, Bartsch DK & Slater EP. Clinical impact of TP53 alterations in adrenocortical carcinomas. *Langenbecks Archives of Surgery* 2012 **397** 209–216. (<https://doi.org/10.1007/s00423-011-0868-6>)
- 285 Raymond VM, Everett JN, Furtado LV, Gustafson SL, Jungbluth CR, Gruber SB, Hammer GD, Stoffel EM, Greenon JK, Giordano TJ *et al.* Adrenocortical carcinoma is a lynch syndrome-associated cancer. *Journal of Clinical Oncology* 2013 **31** 3012–3018. (<https://doi.org/10.1200/JCO.2012.48.0988>)
- 286 Stoffel EM, Mangu PB, Gruber SB, Hamilton SR, Kalady MF, Lau MW, Lu KH, Roach N & Limburg PJ. Hereditary colorectal cancer syndromes: American Society of Clinical Oncology Clinical Practice Guideline endorsement of the familial risk-colorectal cancer: European Society for Medical Oncology Clinical Practice Guidelines. *Journal of Clinical Oncology* 2015 **33** 209–217. (<https://doi.org/10.1200/JCO.2014.58.1322>)
- 287 Daly MB, Pilarski R, Berry M, Buys SS, Farmer M, Friedman S, Garber JE, Kauff ND, Khan S, Klein C *et al.* NCCN Guidelines Insights: genetic/familial high-risk assessment: breast and ovarian, version 2.2017. *Journal of the National Comprehensive Cancer Network* 2017 **15** 9–20. (<https://doi.org/10.6004/jnccn.2017.0003>)
- 288 Kratz CP, Achatz MI, Brugieres L, Frebourg T, Garber JE, Greer MC, Hansford JR, Janeway KA, Kohlmann WK, McGee R *et al.* Cancer screening recommendations for individuals with Li-Fraumeni syndrome. *Clinical Cancer Research* 2017 **23** e38–e45. (<https://doi.org/10.1158/1078-0432.CCR-17-0408>)
- 289 Ballinger ML, Best A, Mai PL, Khincha PP, Loud JT, Peters JA, Achatz MI, Chojniak R, Balieiro da Costa A, Santiago KM *et al.* Baseline surveillance in Li-Fraumeni syndrome using whole-body magnetic resonance imaging: a meta-analysis. *JAMA Oncology* 2017 **3** 1634–1639. (<https://doi.org/10.1001/jamaoncol.2017.1968>)
- 290 Gupta S, Provenzale D, Regenbogen SE, Hampel H, Slavin TP Jr, Hall MJ, Llor X, Chung DC, Ahnen DJ, Bray T *et al.* NCCN guidelines insights: genetic/familial high-risk assessment: colorectal, version 3.2017. *Journal of the National Comprehensive Cancer Network* 2017 **15** 1465–1475. (<https://doi.org/10.6004/jnccn.2017.0176>)
- 291 Stoffel EM, Mangu PB & Limburg PJ. Hereditary colorectal cancer syndromes: American Society of Clinical Oncology clinical practice guideline endorsement of the familial risk-colorectal cancer: European Society for Medical Oncology clinical practice guidelines. *Journal of Oncology Practice* 2015 **11** e437–e441. (<https://doi.org/10.1200/JOP.2015.003665>)
- 292 Else T. Association of adrenocortical carcinoma with familial cancer susceptibility syndromes. *Molecular and Cellular Endocrinology* 2012 **351** 66–70. (<https://doi.org/10.1016/j.mce.2011.12.008>)
- 293 McDonnell CM & Zacharin MR. Adrenal cortical tumours: 25 years' experience at the Royal Children's Hospital, Melbourne. *Journal of Paediatrics and Child Health* 2003 **39** 682–685. (<https://doi.org/10.1046/j.1440-1754.2003.00268.x>)
- 294 Custodio G, Parise GA, Kiesel Filho N, Komechen H, Sabbaga CC, Rosati R, Grisa L, Parise IZ, Pianovski MA, Fiori CM *et al.* Impact of neonatal screening and surveillance for the TP53 R337H mutation on early detection of childhood adrenocortical tumors. *Journal of Clinical Oncology* 2013 **31** 2619–2626. (<https://doi.org/10.1200/JCO.2012.46.3711>)
- 295 Wasserman JD, Novokmet A, Eichler-Jonsson C, Ribeiro RC, Rodriguez-Galindo C, Zambetti GP & Malkin D. Prevalence and functional consequence of TP53 mutations in pediatric adrenocortical carcinoma: a children's oncology group study. *Journal of Clinical Oncology* 2015 **33** 602–609. (<https://doi.org/10.1200/JCO.2013.52.6863>)
- 296 Eschler DC, Kogekar N & Pessah-Pollack R. Management of adrenal tumors in pregnancy. *Endocrinology Metabolism Clinics of North America* 2015 **44** 381–397. (<https://doi.org/10.1016/j.ecl.2015.02.006>)
- 297 Abiven-Lepage G, Coste J, Tissier F, Groussin L, Billaud L, Dousset B, Goffinet F, Bertagna X, Bertherat J & Raffin-Sanson ML. Adrenocortical carcinoma and pregnancy: clinical and biological

- features and prognosis. *European Journal of Endocrinology* 2010 **163** 793–800. (<https://doi.org/10.1530/EJE-10-0412>)
- 298 Sirianni R, Zolea F, Chimento A, Ruggiero C, Cerquetti L, Fallo F, Pilon C, Arnaldi G, Carpinelli G, Stigliano A *et al.* Targeting estrogen receptor- α reduces adrenocortical cancer (ACC) cell growth in vitro and in vivo: potential therapeutic role of selective estrogen receptor modulators (SERMs) for ACC treatment. *Journal of Clinical Endocrinology and Metabolism* 2012 **97** E2238–E2250. (<https://doi.org/10.1210/jc.2012-2374>)
- 299 Tripto-Shkolnik L, Blumenfeld Z, Bronshtein M, Salmon A & Jaffe A. Pregnancy in a patient with adrenal carcinoma treated with mitotane: a case report and review of literature. *Journal of Clinical Endocrinology and Metabolism* 2013 **98** 443–447.
- 300 de Corbiere P, Ritzel K, Cazabat L, Ropers J, Schott M, Libe R, Koschker AC, Leboulleux S, Deutschbein T, Do Cao C *et al.* Pregnancy in women previously treated for an adrenocortical carcinoma. *Journal of Clinical Endocrinology and Metabolism* 2015 **100** 4604–4611. (<https://doi.org/10.1210/jc.2015-2341>)
- 301 Hescot S, Seck A, Guerin M, Cockenpot F, Huby T, Broutin S, Young J, Paci A, Baudin E & Lombes M. Lipoprotein-free mitotane exerts high cytotoxic activity in adrenocortical carcinoma. *Journal of Clinical Endocrinology and Metabolism* 2015 **100** 2890–2898. (<https://doi.org/10.1210/JC.2015-2080>)
- 302 Hescot S, Slama A, Lombes A, Paci A, Remy H, Leboulleux S, Chadarevian R, Trabado S, Amazit L, Young J *et al.* Mitotane alters mitochondrial respiratory chain activity by inducing cytochrome c oxidase defect in human adrenocortical cells. *Endocrine-Related Cancer* 2013 **20** 371–381. (<https://doi.org/10.1530/ERC-12-0368>)
- 303 Sbiere S, Leich E, Liebisch G, Sbiere I, Schirbel A, Wiemer L, Matysik S, Eckhardt C, Gardill F, Gehl A *et al.* Mitotane inhibits sterol-O-acyl transferase 1 triggering lipid-mediated endoplasmic reticulum stress and apoptosis in adrenocortical carcinoma cells. *Endocrinology* 2015 **156** 3895–3908. (<https://doi.org/10.1210/en.2015-1367>)
- 304 Hescot S, Amazit L, Lhomme M, Travers S, DuBow A, Battini S, Boulate G, Namer IJ, Lombes A, Kontush A *et al.* Identifying mitotane-induced mitochondria-associated membranes dysfunctions: metabolomic and lipidomic approaches. *Oncotarget* 2017 **8** 109924–109940.
- 305 Arlt W, Biehl M, Taylor AE, Hahner S, Libe R, Hughes BA, Schneider P, Smith DJ, Stiekema H, Krone N *et al.* Urine steroid metabolomics as a biomarker tool for detecting malignancy in adrenal tumors. *Journal of Clinical Endocrinology and Metabolism* 2011 **96** 3775–3784. (<https://doi.org/10.1210/jc.2011-1565>)
- 306 Kerkhofs TM, Kerstens MN, Kema IP, Willems TP & Haak HR. Diagnostic value of urinary steroid profiling in the evaluation of adrenal tumors. *Hormones and Cancer* 2015 **6** 168–175. (<https://doi.org/10.1007/s12672-015-0224-3>)
- 307 Taylor DR, Ghataore L, Couchman L, Vincent RP, Whitelaw B, Lewis D, Diaz-Cano S, Galata G, Schulte KM, Aylwin S *et al.* A 13-steroid serum panel based on LC-MS/MS: use in detection of adrenocortical carcinoma. *Clinical Chemistry* 2017 **63** 1836–1846. (<https://doi.org/10.1373/clinchem.2017.277624>)
- 308 Hines JM, Bancos I, Bancos C, Singh RD, Avula AV, Young WF, Grebe SK & Singh RJ. High-resolution, accurate-mass (HRAM) mass spectrometry urine steroid profiling in the diagnosis of adrenal disorders. *Clinical Chemistry* 2017 **63** 1824–1835. (<https://doi.org/10.1373/clinchem.2017.271106>)
- 309 Pinzani P, Scatena C, Salvianti F, Corsini E, Canu L, Poli G, Paglierani M, Piccini V, Pazzagli M, Nesi G *et al.* Detection of circulating tumor cells in patients with adrenocortical carcinoma: a monocentric preliminary study. *Journal of Clinical Endocrinology and Metabolism* 2013 **98** 3731–3738. (<https://doi.org/10.1210/jc.2013-1396>)
- 310 Chabre O, Libe R, Assie G, Barreau O, Bertherat J, Bertagna X, Feige JJ & Cherradi N. Serum miR-483-5p and miR-195 are predictive of recurrence risk in adrenocortical cancer patients. *Endocrine-Related Cancer* 2013 **20** 579–594.
- 311 Szabo DR, Luconi M, Szabo PM, Toth M, Szucs N, Horanyi J, Nagy Z, Mannelli M, Patocs A, Racz K *et al.* Analysis of circulating microRNAs in adrenocortical tumors. *Laboratory Investigation* 2014 **94** 331–339. (<https://doi.org/10.1038/labinvest.2013.148>)
- 312 Perge P, Butz H, Pezzani R, Bancos I, Nagy Z, Paloczi K, Nyiro G, Decmann A, Pap E, Luconi M *et al.* Evaluation and diagnostic potential of circulating extracellular vesicle-associated microRNAs in adrenocortical tumors. *Scientific Reports* 2017 **7** 5474. (<https://doi.org/10.1038/s41598-017-05777-0>)
- 313 Creemers SG, Korpershoek E, Atmodimedjo PN, Dinjens WNM, van Koetsveld PM, Feelders RA & Hofland LJ. Identification of mutations in cell-free circulating tumor DNA in adrenocortical carcinoma: a case series. *Journal of Clinical Endocrinology and Metabolism* 2017 **102** 3611–3615. (<https://doi.org/10.1210/jc.2017-00174>)
- 314 Garinet S, Nectoux J, Neou M, Pasmant E, Jouinot A, Sibony M, Orhant L, Pipoli da Fonseca J, Perlemoine K, Bricaire L *et al.* Detection and monitoring of circulating tumor DNA in adrenocortical carcinoma. *Endocrine-Related Cancer* 2018 **25** L13–L17. (<https://doi.org/10.1530/ERC-17-0467>)

Received 17 July 2018

Accepted 24 July 2018