

Evaluation of alveolar bone loss following rapid maxillary expansion using cone-beam computed tomography

Asli Baysal^a
Tancan Uysal^a
Ilknur Veli^a
Torun Ozer^b
Irfan Karadede^c
Seyit Hekimoglu^d

^aDepartment of Orthodontics, Faculty of Dentistry, Izmir Katip Celebi University, Izmir, Turkey

^bDepartment of Orthodontics, Faculty of Dentistry, Adnan Menderes University, Aydin, Turkey

^cDepartment of Orthodontics, Faculty of Dentistry, Dicle University, Diyarbakir, Turkey

^dPrivate Practice, Diyarbakir, Turkey

Objective: To evaluate the changes in cortical bone thickness, alveolar bone height, and the incidence of dehiscence and fenestration in the surrounding alveolar bone of posterior teeth after rapid maxillary expansion (RME) treatment using cone-beam computed tomography (CBCT). **Methods:** The CBCT records of 20 subjects (9 boys, mean age: 13.97 ± 1.17 years; 11 girls, mean age: 13.53 ± 2.12 year) that underwent RME were selected from the archives. CBCT scans had been taken before (T1) and after (T2) the RME. Moreover, 10 of the subjects had 6-month retention (T3) records. We used the CBCT data to evaluate the buccal and palatal aspects of the canines, first and second premolars, and the first molars at 3 vertical levels. The cortical bone thickness and alveolar bone height at T1 and T2 were evaluated with the paired-samples t-test or the Wilcoxon signed-rank test. Repeated measure ANOVA or the Friedman test was used to evaluate the statistical significance at T1, T2, and T3. Statistical significance was set at $p < 0.05$. **Results:** The buccal cortical bone thickness decreased gradually from baseline to the end of the retention period. After expansion, the buccal alveolar bone height was reduced significantly; however, this change was not statistically significant after the 6-month retention period. During the course of the treatment, the incidence of dehiscence and fenestration increased and decreased, respectively. **Conclusions:** RME may have detrimental effects on the supporting alveolar bone, since the thickness and height of the buccal alveolar bone decreased during the retention period.
[Korean J Orthod 2013;43(2):83-95]

Key words: Rapid maxillary expansion, Cone-beam computed tomography, Periodontium

Received May 29, 2012; Revised September 17, 2012; Accepted October 18, 2012.

Corresponding author: Tancan Uysal.
Professor, Department of Orthodontics, Faculty of Dentistry, Izmir Katip Celebi University, Cigli, Izmir 35640, Turkey.
Tel +90-2323254040 e-mail tancanuysal@yahoo.com

The authors report no commercial, proprietary, or financial interest in the products or companies described in this article.

© 2013 The Korean Association of Orthodontists.

This is an Open Access article distributed under the terms of the Creative Commons Attribution Non-Commercial License (<http://creativecommons.org/licenses/by-nc/3.0>) which permits unrestricted non-commercial use, distribution, and reproduction in any medium, provided the original work is properly cited.

INTRODUCTION

During rapid maxillary expansion (RME), heavy orthodontic forces are transmitted to the maxilla through the teeth,¹ and unfavorable changes may occur in the anchor teeth and their supporting tissues, including buccal crown tipping, root resorption, reduction of buccal bone thickness, and marginal bone loss.²⁻⁴

Rungcharassaeng et al.⁴ performed a study on the CBCT records of 30 subjects taken before and after RME, and found that buccal crown tipping, reduction of buccal bone thickness, and marginal bone loss had occurred within 3 months after RME. Kartalian et al.⁵ compared 25 patients who underwent RME with age- and gender-matched controls using cone-beam computed tomography (CBCT) scans, and showed that the alveoli (but not the teeth) had tipped buccally after RME.

RME has also been reported to produce alveolar bone fenestration and/or dehiscence in the buccal aspects of the maxillary teeth.^{6,7} Garib et al.⁶ investigated the periodontal effects of tooth- and tooth-tissue-borne appliances, and found that RME treatment could lead to bone dehiscence in the buccal aspects of the anchor teeth. Baysal et al.⁸ evaluated root resorption after RME via CBCT and found significant root volume loss in the posterior teeth.

The probing of gingival tissues and radiographic methods are mostly preferred in evaluating the osseous support of the teeth.⁹ In radiographic methods, bitewing and periapical radiographs are widely used.¹⁰ However, radiographic methods have some limitations, including superimposition of the anatomic structures and difficulty in reproducing angles over time.¹¹ Moreover, the destruction of the buccal plate cannot be distinguished from lingual defects.¹² Because of these various issues, conventional radiography remains a limited tool for periodontal diagnosis.¹³

Recently, CBCT was introduced for head and neck applications. The main advantage of CBCT is the ability to evaluate the real anatomy without superimposition of the neighboring structures. CBCT and conventional methods have been compared by linear measurements of periodontal defects, and the methods were found to be comparable in terms of accuracy.¹⁴ Notably, CBCT also provides the ability to observe defects in all three dimensions.¹⁵

Although the effects of RME on cortical bone thickness and alveolar bone height were investigated in previous studies^{4,5} by means of CBCT, no study evaluating the follow-up period has been published. Therefore, the aim of this study was to evaluate the effects of RME on cortical bone thickness, alveolar bone height, and the incidence of dehiscence and fenestration after a

6-month follow-up period. For the purpose of this study, the null hypothesis assumed that no significant changes in the cortical bone thickness, alveolar bone height, and incidence of dehiscence and fenestration would occur after RME treatment.

MATERIALS AND METHODS

The CBCT records of 20 subjects (9 boys, mean age: 13.97 ± 1.17 years; 11 girls, mean age: 13.53 ± 2.12 years) were obtained from the archives of the Oral and Maxillofacial Radiology Department, Dicle University (Diyarbakır, Turkey). All patients fulfilled the following criteria: 1) bilateral cross-bite related to a maxillary transverse deficiency; 2) no history of previous orthodontic treatment or a systemic disease; and 3) all maxillary teeth were present and fully erupted, with the exception of the third molars. All 20 patients had undergone RME with a Hyrax-type expander as a part of their orthodontic treatment. T1 scans were obtained before the placement of the appliance, and T2 scans were acquired directly after the end of the activation. Of the 20 patients, 10 patients had 6-month retention records (T3).

Ethical approval had already been obtained from the Ethical Committee of Dicle University (DUDFEK 2009/21) for the aims of another study; the patients were not exposed to extra radiation for this retrospective study. Therefore, a second ethical approval was not obtained.

In our department, the expansion protocol using the Hyrax screw is as follows: the appliance consists of an expansion screw welded on the bands on the first premolar and molar teeth. The screw is turned twice a day (once in the morning and in the evening) until the palatal cusps of the upper posterior teeth are in contact with the buccal cusps of the lower posterior teeth. During the retention period, the expansion appliance is left in the mouth for the first 3 months, and is replaced with a transpalatal arch when the expander is removed. Fixed orthodontic treatment is initiated after the retention period.

All tomographs were obtained using i-CAT® (Model 17-19; Imaging Sciences International, Hatfield, PA, USA) by the same operator at the following settings: exposures were made at 5.0 mA and 120 kV for 9.6 seconds, and the axial slice thickness was 0.3 mm. The patients were positioned sitting upright in the CBCT machine, with one strap placed over the forehead to orient the Frankfort horizontal plane parallel to the floor.

The Digital Imaging and Communications in Medicine (DICOM) files were imported into Dolphin 3D (Dolphin Imaging, Chatsworth, CA, USA) for further analysis. In this program, the orientation of each 3-dimensional

volumetric data set was standardized by using the Frankfort horizontal line as the x-axis, the transporionic line as the y-axis, and the midsagittal line as the z-axis. The reference planes were defined by using the volumetric rendering view along with the multiple planar views.¹⁶

All of the cortical bone thickness and buccal alveolar height (BAH) measurements were performed using Dolphin Imaging 11.0 Premium (Dolphin Imaging) on hard tissue segmentation by one author who was blinded to the patient time points.

The cortical bone thickness of the maxillary canine, the first and second premolars, and the first molar for the left and right segments were measured using the axial clipping function of the software. To measure

the cortical bone thickness at 3 different levels, cross-sections parallel to the Frankfort horizontal line were obtained at the trifurcation point, the middle of the distobuccal root, and the apex of the distobuccal root of the right first molar tooth. These levels were defined as the furcation-level, middle, and apical cortical bone thickness. To identify precisely the middle and apical thirds of the root, the length was measured with the program automatically on the coronally clipped images.

The distances between the outer border of the cortical bone and the teeth were measured both buccally and palatally, and defined as the buccal and palatal cortical bone thickness (BCBT and PCBT, respectively) (Figure 1). However, the method was modified in the following situations: if the roots of the upper premolars were

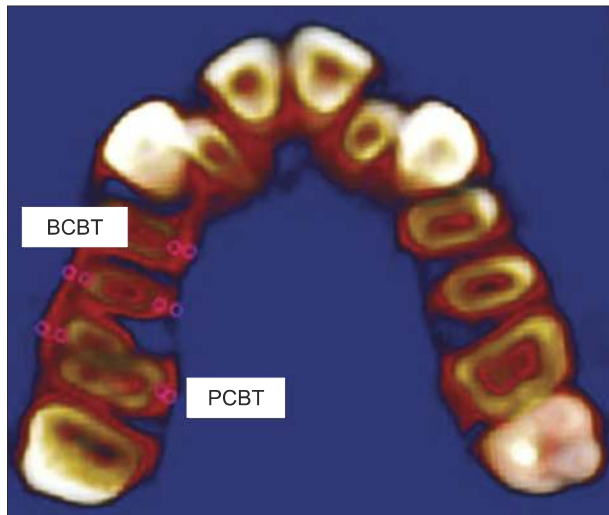


Figure 1. Buccal cortical bone thickness (BCBT) and palatal cortical bone thickness (PCBT) at the level of the trifurcation of the first molar.

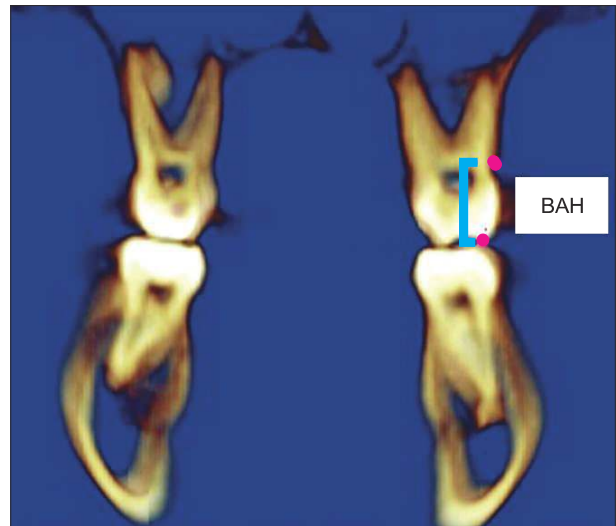


Figure 2. Buccal alveolar height (BAH: distance between the cusp tip and the buccal alveolar crest) of the maxillary first molar.

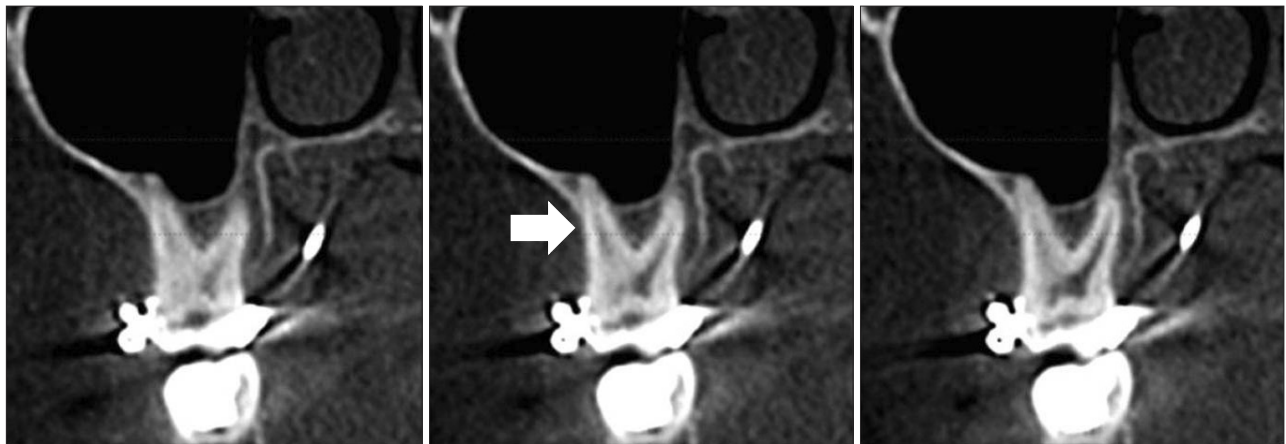


Figure 3. The presence of dehiscence at 3 consecutive views. Arrow shows the localization of dehiscence.

shorter than the distobuccal roots of the first molars, the distances between the outer bone plate and the nearest point to the premolar apices were used for the measurements. When the maxillary sinuses spanned around the roots of the teeth, the distance between the apices and the sinus wall was accepted as zero. In

the case of tooth rotation, the thickness was evaluated using the nearest point of the root to the bone plate.

The other measurement was the BAH of the maxillary posterior teeth. Using the coronal clipping function of the program, the distance between the cusp tips of the posterior teeth and the buccal alveolar crest

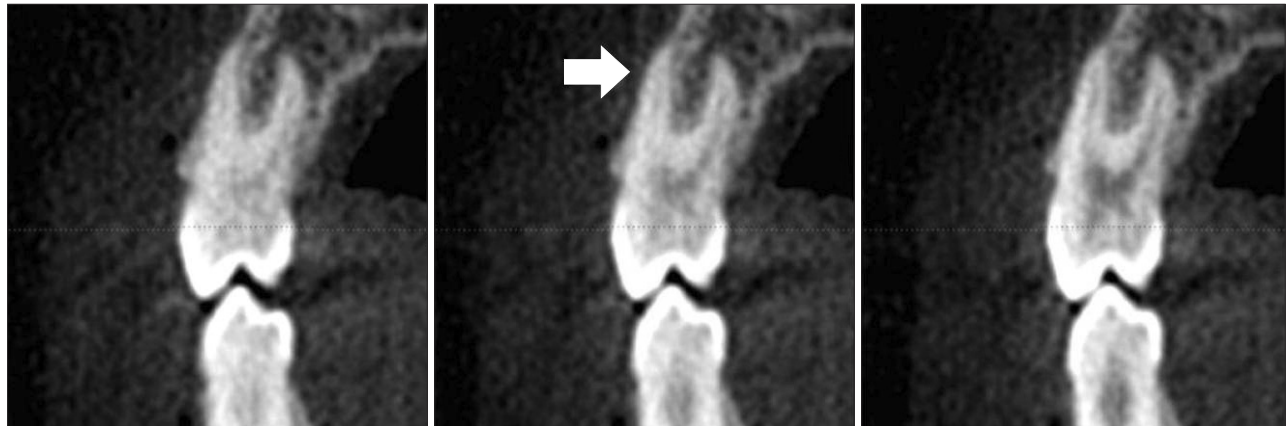

Figure 4. The presence of fenestration at 3 consecutive views. Arrow shows the localization of dehiscence.

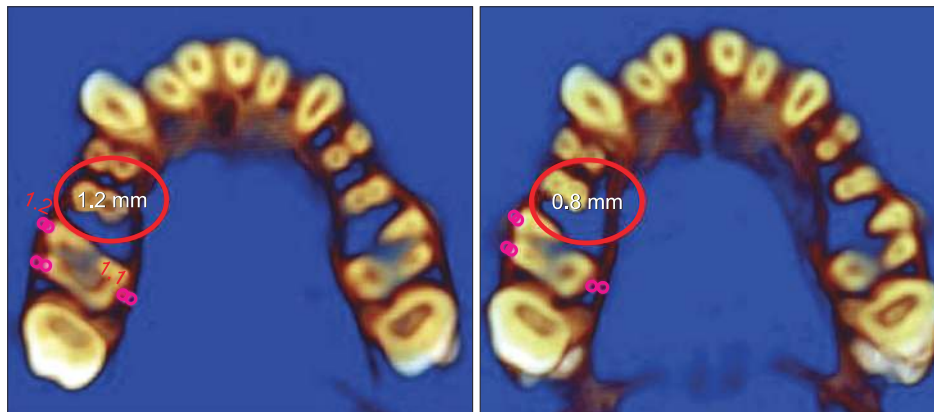

Figure 5. An example of a decrease in the buccal cortical bone thickness of the maxillary right molar.

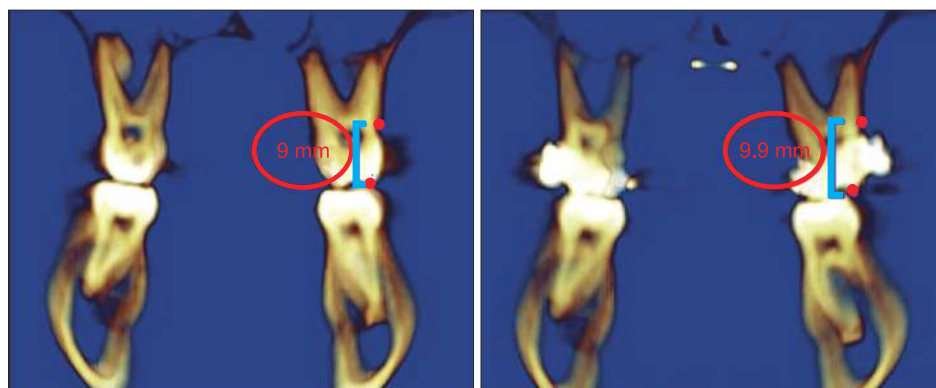


Figure 6. An example of an increase in the buccal alveolar height of the maxillary left molar.

was determined separately for the right and left sides (Figure 2). For the first molar teeth, the buccal crest level was determined from the mesiobuccal, middle, and distobuccal aspects of the teeth.

The presence of dehiscence and fenestration was evaluated on the i-CAT[®] software program according to the method described by Evangelista et al.¹⁷ (Figures 3 and 4). The axial inclination of the tooth was placed perpendicular to the horizontal plane, and the total root length was evaluated in cross-sectional slices at the buccal and palatal surfaces. Images that showed no cortical bone around the tooth in at least 3 consecutive views were recorded as having dehiscence or fenestration. The defect was classified as fenestration when the defect did not involve the alveolar crest. When the alveolar crest was more than 2 mm from the cemento-enamel junction, the defect was recorded as dehiscence.¹⁸

Figures 5 and 6 show the examples of decrease in buccal cortical plate thickness and increase in the buccal alveolar height of maxillary molar teeth after RME, respectively. The palatal cortical bone thickness at baseline, after RME and after retention is presented in Figure 7.

Statistical analysis

All statistical analyses were performed with the SPSS 16.0 (SPSS Inc, Chicago, IL, USA). The Shapiro-Wilk and Levene's variance homogeneity tests were used to determine the normality of the data. For comparing the mean values between the T1 and T2 measurements, a paired t-test and the Wilcoxon signed rank test were used for normally and non-normally distributed data, respectively. For the statistical evaluation of the pre-expansion, post-expansion, and 6-month follow-up data, repeated measure ANOVA with Bonferroni correction was used for normally distributed data, while the Friedman tests were used for non-normally

distributed data. Statistical significance was set at $p < 0.05$. The arithmetic mean and standard deviation were calculated for all measurements.

For determining the errors associated with CBCT measurements, 15 tomographs were selected randomly, and their measurements were repeated 4 weeks after the first measurements by the same examiner. Intraclass correlation coefficients were determined for the 2 sets of measurements and were found to be higher than 0.90, indicating that the reliability of all the measurements was acceptable.

RESULTS

A comparison of the BCBT and PCBT measurements before and after RME treatment is shown in Table 1. With the exception of the apical region of the first and second left premolars, the mesial apical region of the right molar, and the middle region of the right canine, a decrease in the BCBT was observed at the 3 levels for all investigated teeth. For the canine and premolar teeth, the decrease in BCBT was statistically significant only at the furcation level for the right segment. For the second premolar teeth, the decrease was statistically significant in the middle region for both for the left and right segments. In terms of the decrease in BCBT, the first molar mesial and distal roots were the most severely affected among the investigated teeth. The decrease in BCBT was statistically significant for the middle and apical levels of the left segment and for the middle and furcation levels for the right segment.

When the PCBT measurements were evaluated, a general decrease was observed, but the decrease was not symmetrical for the left and right segments. For the canine and second premolar teeth, a decrease was observed on the left side, while an increase occurred at the right side for the middle and apical levels.

A comparison of the BAH before and after RME is shown in Table 2. The BAH measurements of all

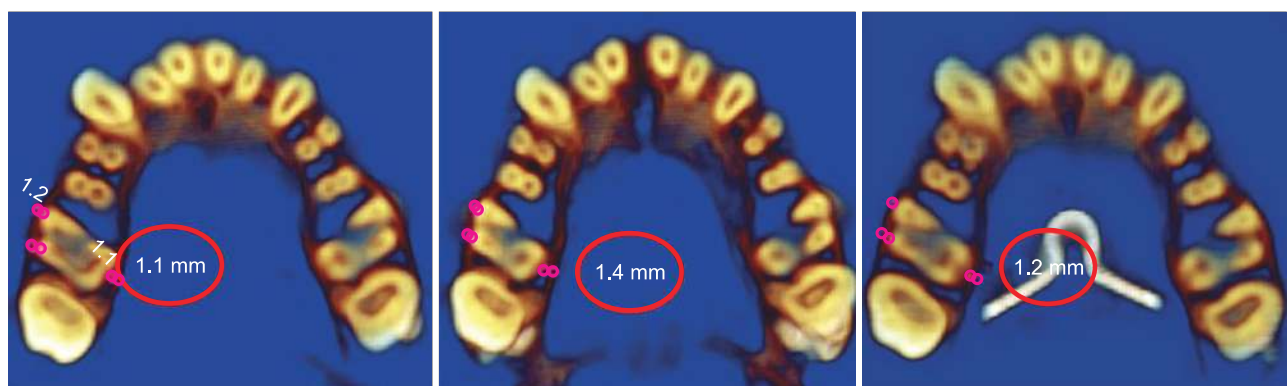


Figure 7. An example of treatment changes: the palatal cortical bone thickness increased after active expansion and decreased at the end of retention.

Table 1. BCBT and PCBT measurements before and after rapid maxillary expansion (20 patients)

Measurement region	Left segment					Right segment				
	n	Before expansion (T1)	After expansion (T2)	Change (T1 - T2)	p-value	n	Before expansion (T1)	After expansion (T2)	Change (T1 - T2)	p-value
BCBT										
Canine										
Furcation	20	0.24 ± 0.43	0.00 ± 0.00	0.24 ± 0.43	0.018	20	0.21 ± 0.35	0.08 ± 0.27	0.13 ± 0.33	NS
Middle	20	0.68 ± 0.60	0.71 ± 0.72	0.03 ± 0.56	NS	20	0.37 ± 0.41	0.41 ± 0.61	-0.04 ± 0.62	NS
Apical	20	1.86 ± 0.85	1.90 ± 1.21	0.04 ± 1.09	NS	20	1.77 ± 0.8	1.47 ± 0.88	0.30 ± 0.82	NS
First premolar										
Furcation	20	0.96 ± 0.44	0.51 ± 0.68	0.45 ± 0.76	0.016	20	0.61 ± 0.48	0.49 ± 0.59	0.13 ± 0.81	NS
Middle	20	0.88 ± 0.46	0.77 ± 0.82	0.11 ± 0.65	NS	20	1.00 ± 0.59	0.64 ± 0.57	0.35 ± 0.71	NS
Apical	20	0.85 ± 0.74	0.88 ± 0.84	-0.03 ± 0.72	NS	20	0.69 ± 0.47	0.7 ± 0.74	0.00 ± 0.58	NS
Second premolar										
Furcation	20	1.52 ± 0.45	1.19 ± 0.70	0.33 ± 0.83	NS	20	1.65 ± 0.51	1.35 ± 0.64	0.31 ± 0.74	NS
Middle	20	1.93 ± 0.54	1.50 ± 0.58	0.42 ± 0.44	< 0.001	20	1.95 ± 0.54	1.24 ± 0.72	0.71 ± 0.71	< 0.001
Apical	20	1.65 ± 0.55	1.95 ± 0.75	-0.30 ± 0.83	NS	20	1.93 ± 0.81	1.57 ± 0.51	0.36 ± 1.09	NS
First molar-mesial										
Furcation	20	0.77 ± 0.50	0.45 ± 0.69	0.31 ± 0.78	NS	20	1.14 ± 0.49	0.56 ± 0.54	0.57 ± 0.61	< 0.001
Middle	20	1.31 ± 0.90	0.67 ± 0.83	0.65 ± 0.85	0.002	20	1.41 ± 0.65	0.79 ± 0.66	0.62 ± 0.68	0.003
Apical	20	1.91 ± 1.27	1.33 ± 1.27	0.59 ± 0.77	0.002	20	2.03 ± 1.19	2.05 ± 1.29	-0.20 ± 0.85	NS
First molar-distal										
Furcation	20	1.27 ± 0.35	1.13 ± 0.78	0.14 ± 0.80	NS	20	1.62 ± 0.45	1.01 ± 1.01	0.61 ± 0.38	< 0.001
Middle	20	1.83 ± 0.86	1.28 ± 1.01	0.55 ± 0.89	0.009	20	1.95 ± 1.00	1.21 ± 0.98	0.74 ± 0.37	< 0.001
Apical	20	2.96 ± 1.72	2.37 ± 1.54	0.59 ± 1.08	0.030	20	2.71 ± 1.63	2.4 ± 1.77	0.31 ± 1.18	NS
PCBT										
Canine										
Furcation	20	1.99 ± 0.91	1.81 ± 0.88	0.18 ± 0.69	NS	20	2.19 ± 0.99	2.38 ± 0.9	-0.19 ± 0.99	NS
Middle	20	2.12 ± 0.90	2.18 ± 0.95	-0.06 ± 0.79	NS	20	2.70 ± 0.93	2.2 ± 0.79	0.49 ± 0.66	0.001
Apical	20	4.19 ± 1.31	4.44 ± 1.25	-0.25 ± 1.28	NS	20	5.22 ± 1.89	4.66 ± 1.65	0.56 ± 1.75	NS
First premolar										
Furcation	20	1.32 ± 0.95	1.59 ± 1.11	-0.28 ± 1.03	NS	20	1.22 ± 0.47	1.76 ± 0.85	-0.54 ± 0.85	0.013
Middle	20	1.64 ± 1.01	1.78 ± 1.25	-0.13 ± 1.00	NS	20	1.68 ± 0.68	2.02 ± 0.88	-0.34 ± 0.75	NS
Apical	20	3.84 ± 1.92	2.73 ± 1.55	1.11 ± 1.42	0.002	20	3.76 ± 1.63	4.28 ± 1.69	-0.52 ± 1.39	NS
Second premolar										
Furcation	20	1.87 ± 0.60	1.91 ± 0.67	-0.04 ± 0.53	NS	20	1.67 ± 0.47	1.81 ± 0.58	-0.14 ± 0.58	NS
Middle	20	1.92 ± 0.64	2.26 ± 0.67	-0.34 ± 0.73	0.043	20	2.06 ± 0.49	2.06 ± 0.81	0.00 ± 0.65	NS
Apical	20	3.78 ± 1.89	4.47 ± 1.96	-0.69 ± 1.83	NS	20	5.31 ± 1.12	4.5 ± 1.85	0.81 ± 2.09	NS
First molar										
Furcation	20	1.19 ± 0.40	1.64 ± 0.54	-0.45 ± 0.51	0.002	20	1.58 ± 0.58	1.5 ± 0.70	0.75 ± 0.60	NS
Middle	20	1.35 ± 0.39	1.53 ± 0.47	-0.17 ± 0.52	NS	20	1.20 ± 0.44	1.65 ± 0.56	-0.44 ± 0.51	0.001
Apical	20	2.01 ± 1.07	1.34 ± 0.60	0.67 ± 1.23	0.025	20	1.60 ± 0.6	1.89 ± 0.87	-0.29 ± 0.77	NS

Values are presented as number or mean ± standard deviation.

Paired t-test and the Wilcoxon signed rank test were used.

BCBT, Buccal cortical bone thickness; PCBT, palatal cortical bone thickness; NS, not significant.

Table 2. Buccal alveolar height measurements before and after rapid maxillary expansion

Measurement region	Left segment					Right segment				
	n	Before expansion	After expansion	Change (T1 - T2)	p-value	n	Before expansion	After expansion	Change (T1 - T2)	p-value
Canine	20	11.96 ± 0.94	12.89 ± 1.29	-0.93 ± 0.99	0.001	20	11.53 ± 1.24	12.35 ± 1.51	-0.82 ± 1.01	0.002
First premolar	20	9.48 ± 0.74	10.81 ± 1.61	-1.32 ± 1.64	0.002	20	9.32 ± 1.18	10.46 ± 1.32	-1.13 ± 1.51	0.003
Second premolar	20	8.80 ± 1.23	9.94 ± 1.67	-1.14 ± 1.45	0.002	20	8.51 ± 0.91	9.49 ± 1.17	-0.97 ± 1.15	0.001
First molar										
Distobuccal	20	8.78 ± 0.74	9.18 ± 0.81	-0.40 ± 0.83	0.045	20	9.24 ± 0.68	10.15 ± 0.86	-0.91 ± 0.85	< 0.001
Midfurcation	20	8.84 ± 0.80	9.06 ± 0.79	-0.22 ± 0.80	NS	20	8.71 ± 0.70	9.44 ± 0.88	-0.73 ± 0.61	< 0.001
Mesiobuccal	20	9.02 ± 1.07	10.45 ± 1.55	-1.42 ± 1.70	0.001	20	9.28 ± 0.72	10.11 ± 0.86	-0.82 ± 0.73	< 0.001

Values are presented as number or mean ± standard deviation. Paired t-test and the Wilcoxon signed rank test were used. NS, Not significant.

investigated posterior teeth were increased. With the exception of the left molar midfurcation level, these differences were found to be statistically significant, indicating the vertical alveolar height decreased immediately after the expansion period.

The descriptive statistics of the BCBT and PCBT measurements and the statistical comparisons of these values at the T1, T2, and T3 time periods are shown in Table 3. Except for the furcation level of the left canine, the BCBT decreased from the baseline to the end of the 6-month follow-up period at all 3 levels. Meanwhile, no significant increase in BCBT was found during retention period (T2 - T3) at the furcation level of the left and right canines and the right premolar and right molar. For the other levels, gradual decreases from T2 to T3 was observed. For the apical part of the canine tooth, a dramatic and statistically significant decrease in the BCBT was observed during the T1 - T3 and T2 - T3 time periods. For the left premolar and molar teeth, no significant decreases were found for the furcation level. Interestingly, for the right segment, no significant difference was recorded for the first premolar teeth. The only statistically significant difference at the furcation level during the T1 - T3 and T2 - T3 time periods was recorded for the right second premolar teeth. At the furcation level of the mesial and distal roots of the first molar, the difference was statistically significant at T2 and recovered at T3.

The PCBT decreases were found to be statistically significant at the apical level for all teeth, with the exception of the left first premolar. The decreases were statistically significant for the right molar teeth at the furcation (T1 - T3), middle (T2 - T3), and apical (T2 - T3) levels.

Comparisons of the BAH measurements from the baseline to the 6-month follow-up are shown in Table 4.

The increase in BAH during the treatment period (T1 - T2) was statistically significant for the right canine tooth ($p = 0.016$). The changes in the T1 - T3 period for the left second premolar and right molar distobuccal level was statistically significant ($p = 0.038$ and $p = 0.035$, respectively). No statistically significant difference was found between the T2 - T3 periods.

The incidence of alveolar defects in the 20 patients before and after RME are shown in Table 5. Meanwhile, the incidence of baseline, post-treatment, and post-retention alveolar defects in 10 of the patients is presented in Table 6. In general, the incidence of dehiscence was greater for the post-treatment and post-retention values than for the baseline ones after RME. The percentage of fenestrations decreased after treatment.

Because the RME treatment had statistically significant effects on the surrounding alveolar bone, the null hypothesis of this study was rejected.

DISCUSSION

RME is a common clinical procedure to correct maxillary constriction and arch length discrepancies.⁴ In adolescents, 65% of the total expansion was shown to be the result of dental movement,¹⁹ and it may be thought that RME may have detrimental effects on the teeth and their supporting tissues.

CBCT scanning provides information for RME, not obtainable from other methods especially from a periodontal perspective. Moreover, as the current study was designed in accordance with the principle of ALARA (as low as reasonably achievable), individuals were not exposed to extra radiation beyond the needs for orthodontic treatment. Also an informed consent form signed by the patients' parents, doctor and technician has to

Table 3. Comparison of BCBT and PCBT measurements before and after rapid maxillary expansion and following the 6-month retention period

Measurement region	Left segment					Right segment					p-value		
	n	Before expansion (T1)	After expansion (T2)	After retention (T3)	p-value	n	Before expansion (T1)	After expansion (T2)	After retention (T3)	p-value	T1 - T2	T1 - T3	T2 - T3
BCBT													
Canine													
Furcation	10	0.14 ± 0.29	0.00 ± 0.00	0.24 ± 0.51	NS	10	0.30 ± 0.48	0.00 ± 0.00	0.10 ± 0.31	NS			
Middle	10	0.60 ± 0.63	0.70 ± 0.76	0.14 ± 0.44	NS	10	0.40 ± 0.51	0.38 ± 0.64	0.10 ± 0.31	NS			
Apical	10	1.93 ± 1.04	1.92 ± 1.40	0.52 ± 0.75	0.004	10	2.20 ± 0.63	1.67 ± 0.96	0.15 ± 0.33	< 0.001	NS	< 0.001	0.001
First premolar													
Furcation	10	0.95 ± 0.41	0.79 ± 0.75	0.63 ± 0.65	NS	10	0.69 ± 0.51	0.33 ± 0.35	0.38 ± 0.47	NS			
Middle	10	1.08 ± 0.51	1.11 ± 0.84	0.20 ± 0.29	0.001	10	1.04 ± 0.53	0.65 ± 0.51	0.59 ± 0.92	NS			
Apical	10	0.96 ± 0.69	1.25 ± 0.86	0.41 ± 0.47	NS	10	0.70 ± 0.36	0.70 ± 0.74	0.48 ± 0.68	NS			
Second premolar													
Furcation	10	1.53 ± 0.42	1.53 ± 0.69	0.97 ± 0.67	NS	10	1.75 ± 0.49	1.62 ± 0.69	0.62 ± 0.58	0.001	NS	0.004	0.008
Middle	10	2.19 ± 0.56	1.77 ± 0.49	1.04 ± 0.77	0.008	10	2.04 ± 0.47	1.55 ± 0.73	0.71 ± 0.74	< 0.001	NS	0.003	0.013
Apical	10	1.63 ± 0.65	2.15 ± 0.61	0.90 ± 0.84	0.001	10	1.55 ± 0.79	1.72 ± 0.32	0.91 ± 0.79	0.015	NS	NS	0.018
First molar-mesial													
Furcation	10	0.80 ± 0.41	0.50 ± 0.76	0.45 ± 0.49	NS	10	1.90 ± 0.48	0.38 ± 0.53	0.46 ± 0.57	0.003	0.002	NS	NS
Middle	10	1.23 ± 0.86	0.87 ± 0.88	0.55 ± 0.49	0.018	10	1.45 ± 0.55	0.75 ± 0.76	0.45 ± 0.50	< 0.001	0.008	0.001	NS
Apical	10	1.88 ± 1.39	1.42 ± 1.41	0.95 ± 1.07	NS	10	1.90 ± 1.17	1.76 ± 1.15	0.69 ± 0.70	0.002	NS	0.036	0.033
First molar-distal													
Furcation	10.1	1.29 ± 0.32	1.19 ± 0.67	1.10 ± 0.58	NS	10	1.54 ± 0.52	0.86 ± 0.62	1.16 ± 0.67	0.013	0.002	NS	NS
Middle	10	1.83 ± 0.86	1.43 ± 1.12	1.18 ± 0.83	0.008	10	2.02 ± 1.32	1.24 ± 1.21	1.06 ± 0.68	0.019	< 0.001	NS	NS
Apical	10	3.10 ± 1.85	2.38 ± 1.81	1.29 ± 1.01	0.000	10	2.58 ± 1.81	2.56 ± 2.30	1.36 ± 1.04	0.020	NS	0.024	NS

Table 3. Continued

Measurement region	Left segment				Right segment				p-value	
	n	Before expansion (T1)	After expansion (T2)	After retention (T3)	n	Before expansion (T1)	After expansion (T2)	After retention (T3)	T1 - T2	T1 - T3
PCBT										
Canine										
Furcation	10	2.25 ± 0.84	2.11 ± 1.01	1.74 ± 0.81	10	1.90 ± 1.10	2.43 ± 1.10	2.33 ± 1.06	NS	NS
Middle	10	2.13 ± 1.06	2.62 ± 0.90	1.88 ± 0.96	10	2.40 ± 0.96	2.02 ± 0.87	1.71 ± 0.98	NS	NS
Apical	10	4.25 ± 1.10	4.69 ± 1.47	2.12 ± 0.95	10	4.40 ± 1.43	4.53 ± 1.56	2.12 ± 0.91	<0.001	NS
First premolar										
Furcation	10	1.13 ± 0.95	1.73 ± 1.32	1.45 ± 0.76	10	1.02 ± 0.46	1.44 ± 0.81	1.68 ± 0.96	NS	NS
Middle	10	1.78 ± 1.39	1.79 ± 1.45	1.74 ± 0.99	10	1.32 ± 0.59	1.73 ± 0.97	1.45 ± 1.10	NS	NS
Apical	10	3.40 ± 2.27	2.34 ± 1.83	1.55 ± 1.18	10	3.44 ± 1.72	4.17 ± 1.75	1.54 ± 1.37	0.005	NS
Second premolar										
Furcation	10	1.75 ± 0.55	1.87 ± 0.79	1.26 ± 1.20	10	1.37 ± 0.47	1.69 ± 0.39	1.40 ± 0.81	NS	NS
Middle	10	2.03 ± 0.49	2.22 ± 0.79	1.29 ± 0.97	10	1.76 ± 0.41	1.80 ± 0.70	1.19 ± 0.89	NS	NS
Apical	10	3.37 ± 2.01	3.87 ± 1.83	1.57 ± 1.44	10	5.14 ± 1.05	4.83 ± 1.48	1.86 ± 1.07	<0.001	NS
First molar										
Furcation	10	1.15 ± 0.46	1.50 ± 0.61	1.01 ± 0.75	10	1.48 ± 0.34	1.58 ± 0.65	0.92 ± 0.34	0.020	NS
Middle	10	1.23 ± 0.45	1.50 ± 0.36	1.02 ± 0.66	10	1.00 ± 0.42	1.49 ± 0.70	0.75 ± 0.24	0.010	NS
Apical	10	2.17 ± 1.18	1.44 ± 0.50	0.72 ± 0.52	10	1.39 ± 0.60	2.01 ± 1.07	0.77 ± 0.49	0.002	NS

Values are presented as number or mean ± standard deviation.
 Repeated measure ANOVA with Bonferroni correction and Friedman test were used.
 BCBT, Buccal cortical bone thickness; PCBT, palatal cortical bone thickness; NS, not significant.

Table 4. Comparison of buccal alveolar height measurements before and after rapid maxillary expansion and following the 6-month observation period

Measurement region	Left segment				Right segment				p-value	
	Before expansion	After expansion	After retention	n	Before expansion	After expansion	After retention	n	T1 - T2	T1 - T3
Canine	11.85 ± 1.04	12.94 ± 1.59	13.07 ± 2.10	10	11.70 ± 1.22	12.72 ± 1.66	12.64 ± 1.74	10	0.016	NS
First premolar	9.48 ± 0.52	11.07 ± 2.02	10.83 ± 2.01	10	9.26 ± 1.05	10.54 ± 1.53	10.31 ± 1.91	10	NS	NS
Second premolar	8.30 ± 1.23	9.48 ± 2.01	10.26 ± 2.01	10	8.26 ± 1.06	9.27 ± 1.46	9.56 ± 1.17	10	NS	NS
First molar										
Distobuccal	9.02 ± 0.86	9.15 ± 1.08	9.36 ± 0.87	10	9.25 ± 0.73	9.80 ± 1.01	9.97 ± 0.99	10	0.012	NS
Midfurcation	9.00 ± 1.04	8.82 ± 0.78	9.27 ± 1.05	10	8.58 ± 0.79	9.22 ± 1.14	9.14 ± 0.87	10	NS	NS
Mesiobuccal	9.11 ± 0.95	9.89 ± 1.26	9.69 ± 0.97	10	9.34 ± 0.87	10.10 ± 1.07	10.25 ± 1.12	10	NS	NS

Values are presented as number or mean ± standard deviation. Repeated measure ANOVA with Bonferroni correction and Friedman test were used. NS, Not significant.

be obtained from every patient that goes under CBCT scanning in our university protocol.

Ekström et al.²⁰ found that the mineralization of a midpalatal suture was completed 3 months after RME, and advocated a retention period of 3 to 6 months for a good long-term stability. In the current study, 6-month retention records were obtained from the archive and used in the analyses, since this period was thought to be adequate for the adaptation of the hard and soft tissues.

The force generated by the activation of the appliance initially leads to compression of the periodontal ligament, bending of the alveolar bone, and tipping of the anchor teeth. Afterwards, a gradual opening of the midpalatal suture occurs.²¹ Hicks²² found that the angulation between the right and left molars increased from 1° to 24° during expansion and showed that these changes are due to alveolar bending and the tipping of the posterior teeth in the alveolar bone. By contrast, Kartalian et al.⁵ showed no statistically significant dental tipping after RME. Hence, one can conclude that RME may result in the tipping of the maxillary posterior teeth. In the present study, the level of the buccal alveolar crest was lowered in all investigated teeth immediately after RME. These changes may be attributed to the tipping of the maxillary posterior teeth, and this tipping movement may lead to resorption of the crestal alveolar bone. This finding is in accordance with previous studies.^{23,24}

After the retention period, the alveolar bone height did not change, but the buccal cortical bone generally continued to decrease. According to Barber and Sims,²⁵ the residual loads may cause the alveolar bone to be compressed toward the buccal aspect of the anchor teeth, which are held rigidly by the expansion devices used as retainers. Cotton²⁶ stated that post-expansion angular changes of the maxillary molars might be due to the stretched fibers of the attached palatal mucosa. Thus, the roots of the posterior teeth may move buccally, and the thickness of the buccal cortical bone may continue to decrease.

In the palatal portion of the tooth, a trend toward an increase in the PCBT after the active phase of the RME was observed. This finding can be attributed to the buccal tipping of the posterior teeth, which increases the distance between the palatal cortical plate and the root surfaces. Meanwhile, the decreases in PCBT in the retention period may show the compensatory resorption under the periosteum. The thickness of the bone may have been maintained through this compensatory response. Sarikaya et al.²⁷ showed compensatory resorption under buccal periosteum when the maxillary incisors were retracted.

Because of the considerable force needed to break the median palatine suture during RME, an evaluation of the periodontal structures, including the alveolar bone

Table 5. Incidence of alveolar defects in 20 patients before and after rapid maxillary expansion

Measurement region	Total surface number	Before treatment		After treatment	
		Dehiscence	Fenestration	Dehiscence	Fenestration
Canine					
Buccal	40	22 (55.0)	3 (7.5)	29 (72.5)	2 (5.0)
Palatal	40	1 (2.5)	0 (0.0)	3 (7.5)	0 (0.0)
First premolar					
Buccal	40	1 (2.5)	11 (27.5)	23 (57.5)	8 (20.0)
Palatal	40	1 (2.5)	1 (2.5)	0 (0.0)	0 (0.0)
Second premolar					
Buccal	40	1 (2.5)	1 (2.5)	4 (10.0)	2 (5.0)
Palatal	40	0 (0.0)	0 (0.0)	5 (12.5)	0 (0.0)
First molar					
Buccal	40	2 (5.0)	9 (22.5)	26 (65.0)	6 (15.0)
Palatal	40	5 (12.5)	8 (20.0)	9 (22.5)	1 (2.5)

Values are presented as number or number (%).

Table 6. Incidence of alveolar defects in 10 patients before and after rapid maxillary expansion and following the observation period

Measurement region	Total surface number	Before treatment		After treatment		After observation	
		Dehiscence	Fenestration	Dehiscence	Fenestration	Dehiscence	Fenestration
Canine							
Buccal	20	14 (70.0)	1 (5.0)	15 (75.0)	1 (5.0)	19 (95.0)	0 (0.0)
Palatal	20	1 (5.0)	0 (0.0)	2 (10.0)	0 (0.0)	8 (40.0)	0 (0.0)
First premolar							
Buccal	20	1 (5.0)	3 (15.0)	11 (55.0)	4 (20.0)	13 (65.0)	3 (15.0)
Palatal	20	1 (5.0)	0 (0.0)	0 (0.0)	0 (0.0)	3 (15.0)	0 (0.0)
Second premolar							
Buccal	20	0 (0.0)	0 (0.0)	0 (0.0)	0 (0.0)	1 (5.0)	1 (5.0)
Palatal	20	0 (0.0)	0 (0.0)	4 (20.0)	0 (0.0)	0 (0.0)	0 (0.0)
First molar							
Buccal	20	2 (10.0)	6 (30.0)	12 (60.0)	3 (15.0)	8 (40.0)	2 (10.0)
Palatal	20	3 (15.0)	6 (30.0)	7 (35.0)	0 (0.0)	8 (40.0)	1 (5.0)

Values are presented as number or number (%).

and gingival biotype, is an important aspect of the procedure.¹⁷ Evangelista et al.¹⁷ compared the presence of alveolar defects (dehiscence and fenestration) in patients with different malocclusions, and found that the maxillary canines and first premolars showed a high prevalence of dehiscence. This finding is of importance for treatments involving RME, since the first premolars, and sometimes the canines, are the supporting teeth for

orthopedic devices. In the current study, the incidence of dehiscence on the buccal surface of posterior teeth varied between 2.5% and 55.0%. Additionally, this incidence increased during the use of the tooth-borne RME appliance (range: 10.0 - 72.5%). We think that the effects of dental inclination and the decrease in alveolar bone height are associated with these alveolar defects.

Wainwright⁷ showed that when the apex of a tooth is

moved facially, cortical bone penetration occurs. This penetration is closed with bone deposition on the buccal surface if the apex of the tooth is moved to the opposite direction and retained in that position. In the present study, the incidence of dehiscence and fenestration increased and decreased after RME, respectively. The potential of a fenestration to become a dehiscence²⁸ may explain this increase. Although a general increase was shown in the occurrence of these alveolar defects for the buccal surface of the first molar teeth, the percentage of alveolar defects decreased overall. This decrease is attributed to the horizontal bone loss. Meanwhile, the least amount of alveolar defects was found in the second premolars. It is logical to find greater alveolar defects in the first premolar and molar teeth, as they are the anchor teeth. Although the canines are not anchor teeth, the initial supra-alveolar position of these teeth might cause dehiscence at the buccal surfaces, and these might not recover.

In the present study, CBCT scans were used to evaluate the alveolar defects. As we can measure the bone around the teeth accurately by means of axial and cross-sectional sections, alveolar bone measurements and bone defects may be judged by CBCT. Leung et al.²⁸ evaluated the accuracy and reliability of CBCT for measuring alveolar bone height and alveolar defects by correlating direct and indirect CBCT measurements. The correlation coefficient with direct and CBCT measurements was 0.870 for the bone margin measurements. On the other hand, the detection of fenestrations and dehiscence was more prone to error. For dehiscence, both the sensitivity and specificity were about 0.80. The diagnosis of alveolar defects depends on the length and thickness of the alveolar cortical plate and the visualization of the periodontal ligament space.¹⁷ Fuhrmann et al.²⁹ observed that when the cortical thickness is less than 0.5 mm, the CBCT scan is relatively accurate. Nonetheless, these measurements are made in extremely small scales. Therefore, the scoring of these thicknesses can be a possible limitation of our study.

Another limitation of this study is the small sample size. To overcome this limitation, the same author performed all measurements. Moreover, the high accuracy of the quantitative measurements on the CBCT images supports the reliability of the outcomes and makes the small sample size acceptable. Furthermore, to prevent the underestimation of *p*-values, repeated measure ANOVA, which is a much more powerful statistical approach than independent ANOVA, was used. Future studies with a large sample size are needed for further evaluation.

CONCLUSION

Within the limitations of this study, the following conclusions can be drawn: 1) RME may have detrimental effects on the supporting alveolar bone, since the thickness and height of the buccal alveolar bone were decreased, 2) the increased dehiscence formation may support these findings.

REFERENCES

1. Langford SR, Sims MR. Root surface resorption, repair, and periodontal attachment following rapid maxillary expansion in man. *Am J Orthod* 1982;81: 108-15.
2. Graber TM. Chapter 10. Dentofacial orthopedics. In: Graber TM, ed. *Current orthodontic concepts and techniques*, Vol 11. Philadelphia: WB Saunders Company; 1969.
3. Odenrick L, Karlander EL, Pierce A, Kretschmar U. Surface resorption following two forms of rapid maxillary expansion. *Eur J Orthod* 1991;13:264-70.
4. Rungcharassaeng K, Caruso JM, Kan JY, Kim J, Taylor G. Factors affecting buccal bone changes of maxillary posterior teeth after rapid maxillary expansion. *Am J Orthod Dentofacial Orthop* 2007; 132:428.e1-8.
5. Kartalian A, Gohl E, Adamian M, Enciso R. Cone-beam computerized tomography evaluation of the maxillary dentoskeletal complex after rapid palatal expansion. *Am J Orthod Dentofacial Orthop* 2010; 138:486-92.
6. Garib DG, Henriques JF, Janson G, Freitas MR, Coelho RA. Rapid maxillary expansion-tooth tissue-borne versus tooth-borne expanders: a computed tomography evaluation of dentoskeletal effects. *Angle Orthod* 2005;75:548-57.
7. Wainwright WM. Faciolingual tooth movement: its influence on the root and cortical plate. *Am J Orthod* 1973;64:278-302.
8. Baysal A, Karadede I, Hekimoglu S, Ucar F, Ozer T, Veli I, et al. Evaluation of root resorption following rapid maxillary expansion using cone-beam computed tomography. *Angle Orthod* 2012;82:488-94.
9. Jeffcoat MK. Current concepts in periodontal disease testing. *J Am Dent Assoc* 1994;125:1071-8.
10. Molander B. Panoramic radiography in dental diagnostics. *Swed Dent J Suppl* 1996;119:1-26.
11. Misch KA, Yi ES, Sarment DP. Accuracy of cone beam computed tomography for periodontal defect measurements. *J Periodontol* 2006;77:1261-6.
12. Rees TD, Biggs NL, Collings CK. Radiographic interpretation of periodontal osseous lesions. *Oral Surg Oral Med Oral Pathol* 1971;32:141-53.

13. Hirschmann PN. Radiographic interpretation of chronic periodontitis. *Int Dent J* 1987;37:3-9.
14. Vandenberghe B, Jacobs R, Yang J. Detection of periodontal bone loss using digital intraoral and cone beam computed tomography images: an in vitro assessment of bony and/or infrabony defects. *Dentomaxillofac Radiol* 2008;37:252-60.
15. Walker L, Enciso R, Mah J. Three-dimensional localization of maxillary canines with cone-beam computed tomography. *Am J Orthod Dentofacial Orthop* 2005;128:418-23.
16. Sanders DA, Rigali PH, Neace WP, Uribe F, Nanda R. Skeletal and dental asymmetries in Class II subdivision malocclusions using cone-beam computed tomography. *Am J Orthod Dentofacial Orthop* 2010;138:542.e1-20.
17. Evangelista K, Vasconcelos Kde F, Bumann A, Hirsch E, Nitka M, Silva MA. Dehiscence and fenestration in patients with Class I and Class II Division 1 malocclusion assessed with cone-beam computed tomography. *Am J Orthod Dentofacial Orthop* 2010;138:133.e1-7.
18. Persson RE, Hollender LG, Laurell L, Persson GR. Horizontal alveolar bone loss and vertical bone defects in an adult patient population. *J Periodontol* 1998;69:348-56.
19. Krebs A. Midpalatal suture expansion studies by the implant method over a seven-year period. *Rep Congr Eur Orthod Soc* 1964;40:131-42.
20. Ekström C, Henrikson CO, Jensen R. Mineralization in the midpalatal suture after orthodontic expansion. *Am J Orthod* 1977;71:449-55.
21. Haas AJ. Rapid expansion of the maxillary dental arch and nasal cavity by opening the midpalatal suture. *Angle Orthod* 1961;31:73-90.
22. Hicks EP. Slow maxillary expansion. A clinical study of the skeletal versus dental response to low-magnitude force. *Am J Orthod* 1978;73:121-41.
23. Thilander B, Nyman S, Karring T, Magnusson I. Bone regeneration in alveolar bone dehiscences related to orthodontic tooth movements. *Eur J Orthod* 1983;5:105-14.
24. Engelking G, Zachrisson BU. Effects of incisor repositioning on monkey periodontium after expansion through the cortical plate. *Am J Orthod* 1982;82:23-32.
25. Barber AF, Sims MR. Rapid maxillary expansion and external root resorption in man: a scanning electron microscope study. *Am J Orthod* 1981;79:630-52.
26. Cotton LA. Slow maxillary expansion: skeletal versus dental response to low magnitude force in *Macaca mulatta*. *Am J Orthod* 1978;73:1-23.
27. Sarikaya S, Haydar B, Çiğler S, Ariyürek M. Changes in alveolar bone thickness due to retraction of anterior teeth. *Am J Orthod Dentofacial Orthop* 2002;122:15-26.
28. Leung CC, Palomo L, Griffith R, Hans MG. Accuracy and reliability of cone-beam computed tomography for measuring alveolar bone height and detecting bony dehiscences and fenestrations. *Am J Orthod Dentofacial Orthop* 2010;137(4 Suppl):S109-19.
29. Fuhrmann RA, Wehrbein H, Langen HJ, Diedrich PR. Assessment of the dentate alveolar process with high resolution computed tomography. *Dentomaxillofac Radiol* 1995;24:50-4.