

Full Length Research Paper

Evaluation of spermatogenesis in prepubertal albino rats with date palm pollen supplement

Salman Iftikhar^{1*}, Munazza Ahmad², Hina Muhammad Aslam³, Tahir Saeed⁴, Yasir Arfat⁵
and Gul-E- Nazish⁶

¹Department of Pharmacology, Lahore Medical and Dental College, Lahore, Pakistan.

²Lahore Medical and Dental College, Lahore, Pakistan.

³Department of Pharmacology, University Of Health Sciences Lahore, Pakistan

⁴Department of Pathology, Shareef Medical and Dental College, Lahore, Pakistan.

⁵Northwestern Polytechnical University Xi'an, China.

⁶Rashid Latif Medical College, Lahore, Pakistan.

Accepted 10 January, 2014

It is suggested that Date Palm Pollen (DPP) increases the concentration of testosterone, follicle stimulating hormone, and luteinizing hormone in rats. We therefore planned this study to examine the effect of DPP on spermatogenesis using prepubertal rats. 4-day old rats were randomly divided into four groups of 12 pups each (Control I, Experimental I, Control II, and Experimental II). Experimental groups I and II were given DPP suspension in a single oral dose of 120 mg/kg daily for 18 and 35 days, respectively. Pups were sacrificed on days 22 and 39 post-natally. Testes were removed for microscopic studies, and spermatogenesis was assessed by a method which depended upon scoring 'cross sectional' profiles of seminiferous tubules according to Johnsen's criterion. There was no statistically significant difference in Control and Experimental groups I. However Pups of the treated group II, who received DPP for 35 days, showed statistically significant increase in seminiferous tubules containing spermatozoa, resulting in a higher Johnsen Score (Control group II: 6.28 ± 0.21 , Experimental group II: 8.06 ± 1.21). This implied that spermatogenesis was present at an advanced stage in the Experimental group as compared to the Control group of animals.

Key words: Spermatogenesis, infertility, testes.

INTRODUCTION

Throughout the world, 50 to 80 million couples suffer from infertility. Male factors are thought to be the major cause of infertility in 30% of cases and contribute to infertility in another 20% (Amelar et al., 1977). Infertility is commonly defined as the failure of conception after at least 12 months of unprotected intercourse (Pant, 2009).

Permanent infertility might be rare, but it is irrelevant to infertile couples who want a child, or to those who already have a child but are unable to conceive again (Hull et al., 1985). It is suggested that around 14 to 17% of couples may be affected at some time in their reproductive lives. Factors like diabetes, bronchiectasis,

high grade fever, long term medication, urinary tract infection, sexually transmitted diseases, epididymitis, testicular injury, un-descended testis, mumps, orchitis, excessive alcohol, smoking, exposure to heat and certain chemicals affect spermatogenesis (Pant, 2009). The idiopathic causes of infertility are oligospermia, asthenozoospermia, teratozoospermia, azospermia etc. Others are obstructive azospermia, isolated seminal abnormalities, sexual or ejaculatory dysfunction and delayed puberty (Pant, 2009). Simply put, male infertility is a failure to fertilize the normal ovum due to a deficiency of functionally competent sperm at the stage of fertilization. The treatment modalities for male infertility include Intracytoplasmic sperm injection (ICSI) as an effective treatment modality for male factor infertility. However, this treatment could promote the transgenerational transmission of genetic defects causing gametogenic failure. The pharmacological treatments include clomiphene citrate, an anti-estrogen, the most commonly prescribed medication for male infertility, and L-carnitine known to improve semen's parameters, which has been recognized as the most effective medication (Meschede et al., 2000). There is not yet sufficient evidence for the routine use of other therapies (Ambler, 2009).

The beneficial health and nutrition values of *Phoenix dactylifera* L. for human and animal consumption have been claimed for centuries (Barrevel, 1993). Experimentally, date extracts have shown to increase sperm count in guinea pigs; and to enhance spermatogenesis and increase the concentration of testosterone, follicle stimulating hormone (FSH), and luteinizing hormone (LH) in rats (El-Mougy et al., 1991). The property of Date Palm pollen to increase serum testosterone level was evaluated in a parallel study (Iftikhar et al., 2011). The present study was designed to see the effect of DPP on the spermatogenesis of prepubertal rats with hopes to add a valuable contribution in advancement to the treatment of infertility.

MATERIALS AND METHODS

This study was carried out at University of Health Sciences (UHS) Lahore, Pakistan.

Preparation of the herbal cocktails

Date Palm pollen was obtained from Dera Ghazi Khan District of Punjab, through University of Health Science, Pakistan and was grounded into powdered form in the Pharmacology laboratory, UHS. It was mixed in distilled water to form a suspension. The dose was adjusted daily according to the body weight of the pups during the course of treatment and administered orally.

Sample size

A total of 48 prepubertal male albino rats weighing 5 g were divided

into four groups, each group consisting of 12 rats. They were kept in the experimental research laboratory of UHS.

Parameter studied

Johnsen's score

Johnsen's criterion was selected as it offers a convenient and rapid method for registration of spermatogenesis.

Experimental procedure

Twelve female and four male adult albino rats were procured from National Institute of Health, Islamabad and were kept for two weeks in Experimental research laboratory of University of Health Sciences for acclimatization. One male and three female rats were housed together in a single cage for mating. Pregnancy was confirmed by observing vaginal plug in the morning after keeping the female and male rats together (Sato et al., 2005). Rats were monitored at 8 h interval to observe the time they deliver (Dhungel et al., 2006). Neonates were born after 21 days; they were kept with their mothers and examined for any congenital anomaly. Each of the 48 male neonates so obtained was given identification mark and divided randomly into following four groups of 12 pups each.

Control I: Received equal amount of distilled water daily as experimental animals for 18 days starting at 4th day of age.

Control II: Received equal amount of distilled water daily as experimental animals for 35 days starting at 4th day of age.

Experimental I: Received 120 mg/kg body weight of DPP suspension (Bahmanpour et al., 2006a), as a single oral dose daily for 18 days starting at 4th day of age (Pico et al., 2007).

Experimental II: Received 120mg/kg body weight of DPP suspension (Bahmanpour et al., 2006b), as a single oral dose daily for 35 days starting at 4th day of age (Pico et al., 2007).

Each group was kept under controlled room temperature ($22 \pm 2^\circ\text{C}$) and humidity of $55 \pm 10\%$. They were kept under natural light and dark cycle. All pups were fed on mother's milk and gradually weaned to normal rat chow and water *ad libitum*. The mothers were, however, fed *ad libitum* on normal rat chow and water. 4-day old rats were selected since the experiment consumed 35 days in total. The pups of Control I and Experimental I groups were weighed and sacrificed on 22nd day post-natally, after 18 days of treatment, to determine if DPP affected the mentioned parameters in the middle of the experimental period, and those of Control II and Experimental II were sacrificed on 39th day post-natally, after 35 days of treatment (Bahmanpour et al., 2006b).

Dissection

Each animal was anesthetized with chloroform. A vertical midline skin incision was given from xyphoid to symphysis pubis; it was extended laterally by a transverse incision on each side of the midline. The skin was reflected laterally and abdomen was opened; both skin and muscles were removed. The testes were retractable and were pushed forward into the body cavity. They were removed by pulling the tails of the epididymides along with their head and body, vas deferens and spermatic blood vessels. The blood vessels and vas deferens were severed allowing removal of the testes and the epididymides (Crawford, 2008).

Table 1. Scoring 'cross-sectional' profiles of seminiferous tubules.

s/No.	Parameter
10	Complete Spermatogenesis with many spermatozoa
9	Many spermatozoa present but disorganized spermatogenesis
8	Only a few (<5) spermatozoa
7	No spermatozoa but many spermatids
6	No spermatozoa and only a few (<5) spermatids
5	No spermatozoa or spermatids but several or many spermatocytes
4	No spermatozoa or spermatids and only a few (<5) spermatocytes
3	Spermatogonia are the only germ cells present
2	No germ cells but sertoli cells are present
1	No cells in tubular section

Histological techniques

The right testis of each animal was sectioned along the midline (Rhoden et al., 2002) and immersed in Bouin's fixative for 24 h (Çiftçi, 2004; Udagawa et al., 2006). Testis was then washed with changes of 50 and 70% ethanol for 72 h to remove the yellow color. After washing, each half of the testis was placed separately in a single tissue cassette. The tissue was processed in the automatic tissue processor (UTECH Product INC. Albany, New York-12203 USA) for 18 h, dehydrated by passing through ascending grades of alcohol using 50, 70, 90% and absolute ethanol, cleared in xylene and infiltrated with molten paraffin wax (58°C) before preparing the block (Bancroft and Gamble, 2008). Paraffin block was prepared by placing the tissue in a base mold. The block was firmly fixed in the chuck of the Leica RM 2125 rotary microtome (Leica Biosystems). Five micrometer thick sections were obtained; these were shifted to water bath kept at 45 to 50°C, folds were removed using camel hair brush. Sections were then transferred on the surface of clean and albumenized glass slides, labeled with diamond pencil. Excess of water was drained off and were then dried on the slide warmer.

Scoring of the tubules

The H&E stained slides were observed under light microscope (OLYMPUS CX31, Model U-DO3, OLYMPUS Japan) at different magnifications. The histological findings were recorded and interpreted according to the method reported by Johnsen (1970). This envisaged scoring 'cross-sectional' profiles of seminiferous tubules according to the criteria given in Table 1. The scoring was performed at ×40 objective exposing several tubules in one field. In case of doubt, the presence of spermatozoa was checked by higher magnification. Tubules in one field, chosen at random, were scored and the slide was then moved sideward to bring the adjacent area within the field. When coming to the edge of the section, the slide was moved up to bring the structure at the top edge to the bottom edge and scoring continued. Damaged tubules, at the edges of the section were rejected.

Ten seminiferous tubules in each section were scored. One stained slide from each of the forty eight animals was examined and four hundred and eighty observations were made. In order to calculate a mean score, the number of tubules recorded at each Johnsen score was multiplied with the score and the sum of all 10 multiplications was divided by the total number of tubules recorded (Johnsen, 1970; Carroll et al., 1997).

Statistical analysis

The statistical analysis was carried out using computer software 'Statistical Package for Social Sciences (SPSS) version 18.0'. The arithmetic mean of observations and standard deviation values were calculated; two independent samples t-tests (null hypothesis) were applied to observe differences in mean values. The difference was regarded statistically significant if the 'p' value was < 0.05.

Ethical considerations

These were according to the instructions given in World Health Organization Declaration of Helsinki.

1. During the experiment, the health of the animal will be of paramount importance. Animals showing any sign of disease will be removed from the experiment
2. Proper diet will be maintained during the experiment.
3. Animals will be sacrificed with utmost regard to keep the process painless. Proper disposal of the dissected animal will be done.

RESULTS

Histological observations of testes

The gland was covered by connective tissue capsule which contained fine reticular connective tissue stroma. Each testis was divided into lobules by incomplete connective tissue septa that projected from the capsule. Seminiferous tubules were lined with stratified epithelium in all the groups; connective tissue stroma formed their interstices. Leydig cells, spherical or ovoid in shape, with a central darkly stained nucleus and lighter staining vacuolated cytoplasm were seen within the inter-tubular tissue of Control and Experimental groups. Sertoli cells with oval euchromatic nuclei containing prominent nucleoli and some apparent eosinophilic stained cytoplasm could be seen resting on the basement membrane (Figure 1).

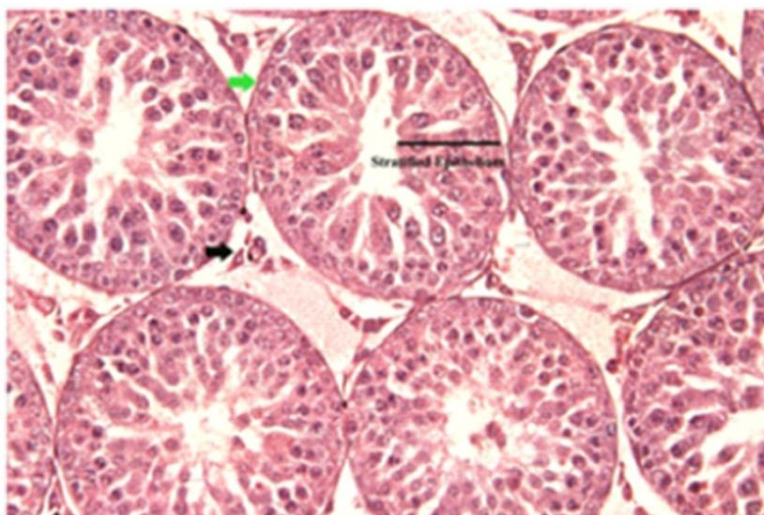


Figure 1. Photomicrograph of a prepubertal testis showing normal architecture. Seminiferous tubules are surrounded by regular and thin basement membrane (green arrow). Leydig cells (black arrow) are arranged in groups. Tubules are lined with stratified epithelium. H&E stain. X200.

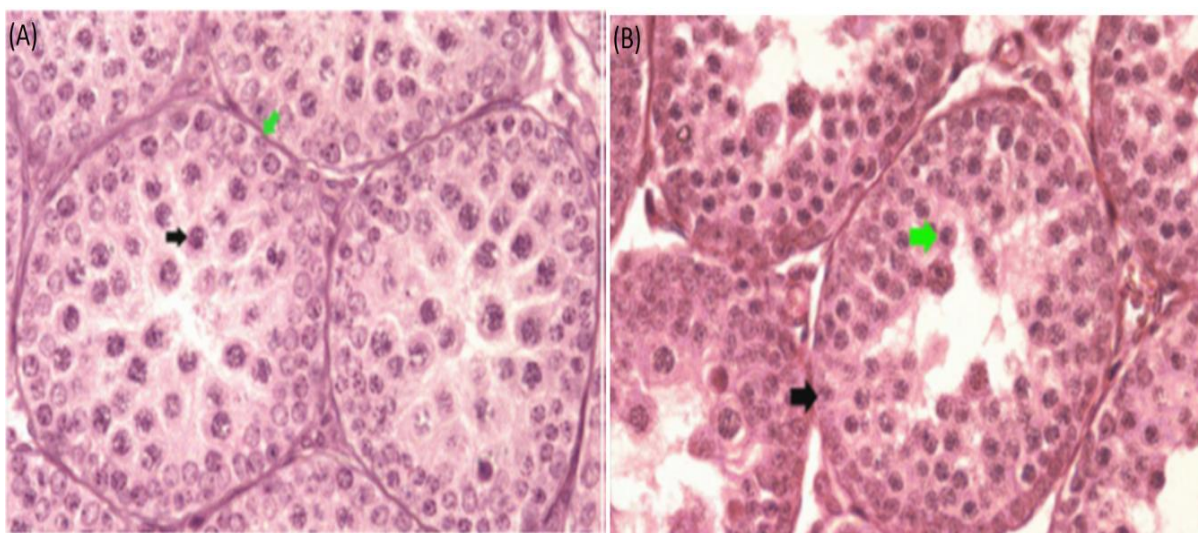


Figure 2. (A) Photomicrograph of testis from Control group I illustrating seminiferous tubule at Johnsen Score 5 which contains spermatogonia (green arrow) and spermatocytes (black arrow) H&E stain. X400. (B) Photomicrograph of testis from Experimental group I illustrating seminiferous tubule at Johnsen Score 5 which contains spermatogonia (black arrow) and spermatocytes (green arrow) H&E stain. X400.

Johnsen score (18 days therapy)

In the Control and Experimental groups I, the most advanced cells seen were spermatocytes, some were in the process of division. Primary spermatocytes, the largest cells of spermatogenic lineage, characterized by the presence of chromosomes in various stages of the coiling process within their nuclei were identified in both

the groups; their nuclei were large with poorly packed chromatin (Figure 2A and B). In the animals of Control group I, Johnsen score of testes varied from 4.1 to 4.6, with an average of 4.37 ± 0.14 ; in the treated group I it ranged from 4.2 to 4.6 with the average of 4.39 ± 0.15 . Difference in Johnsen scores of animals of Control and Experimental groups I was not statistically significant $p = 0.681$ (Figure 3A and Table 2). Spermatogonia, roughly

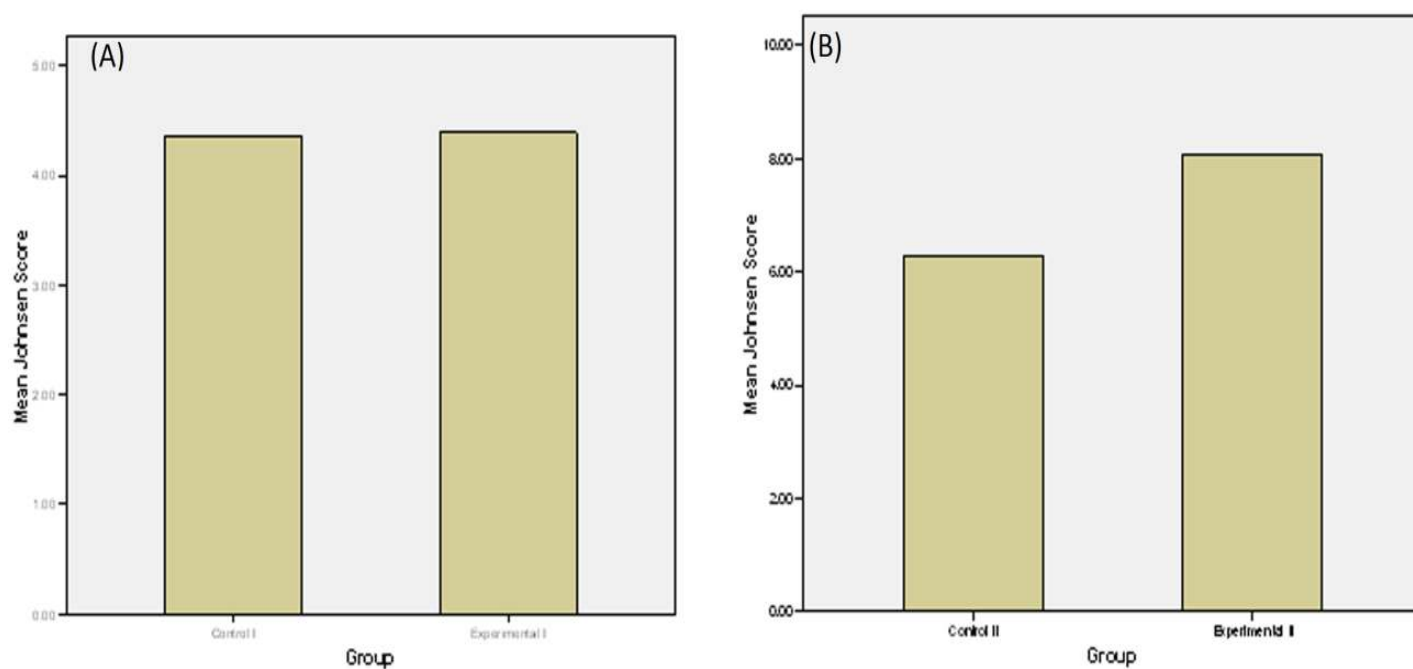


Figure 3. (A) Mean Johnsen scores of animals of control I and experimental I Groups after 18 days therapy. (B) Mean Johnsen Scores of animals of control II and Experimental II groups after 35 days therapy.

Table 2. Comparison of Mean Johnsen scores of animals among experimental and control Groups I after 18 days Therapy.

Parameter	Control Group I (12) Mean ± SD	Experimental Group I (12) Mean ± SD	p-value
Johnsen Score	4.37 ± 0.14	4.39 ± 0.15	0.681

Figure in parenthesis indicate total number of animals in each group.

Table 3. Comparison of mean Johnsen scores of animals among experimental and control Groups II after 35 days therapy.

Parameter	Control Group II (12) Mean ± SD	Experimental Group II (12) Mean ± SD	p-value
Johnsen Score	6.28 ± 0.21	8.06 ± 1.21	<0.001

Figure in parenthesis indicate total number of animals in each group.

spherical in shape, with normal nuclear and cytological morphologies were seen next to the basement membrane; they contained finely granular chromatin within a small nucleus in all the groups.

Johnsen score (35 days therapy)

In the animals of Control group II, Johnsen Score of testes varied from 6.0 to 6.5 with an average of 6.28 ± 0.21 ; in the treated group II it ranged from 6.4 to 9.2 with

the average of 8.06 ± 1.21 . Difference in Johnsen scores of animals of Control and Experimental groups II was statistically significant $p < 0.001$ (Figure 3B and Table 3). The cells of spermatogenic lineage-spermatogonia, spermatocytes and rounded spermatids were stacked in several layers in seminiferous tubules of Control and Experimental groups II. In the Control and Experimental groups II, close to the lumen were the small, pale staining nuclei; these belonged to spermatids. However, seminiferous tubules of Experimental group II showed presence of spermatozoa within the lumen, implying thereby that

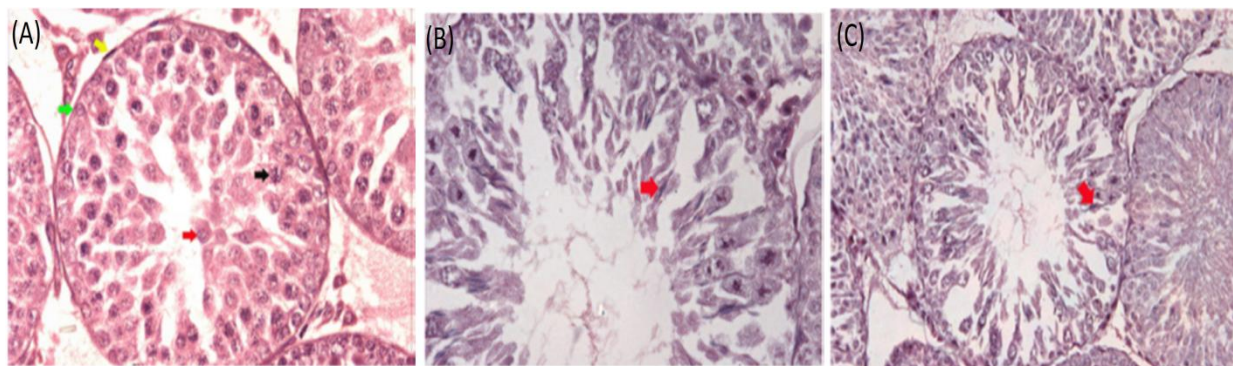


Figure 4. (A) Photomicrograph of testis from Control group II illustrating seminiferous tubule at Johnsen Score 7 which contains spermatogonia (green arrow), spermatocytes (black arrow) and spermatids (red arrow). Myoid cell (yellow arrow) is visible in the peritubular area. H&E stain. X400. (B) Photomicrograph of testis from Experimental group II illustrating seminiferous tubule at Johnsen Score 10 containing spermatozoa (red arrow). H&E stain. X400. (C) Photomicrograph of testis from Experimental group II illustrating seminiferous tubule containing spermatozoa (red arrow) at a lower magnification. H&E stain X200.

spermatogenesis was present at an advanced stage in the Experimental as compared to the Control group II of animals. The cytoplasmic and nuclear structures of all the cells were normal in both groups (Figure 4A to C).

DISCUSSION

Date palm pollen had a positive effect on spermatogenesis in the rat model used. Infertility related stress is considered second to that involving the death of a family member or divorce by couples. It is ranked as one of the greatest source of stress in a person's life (Anderheim et al., 2005, Roudsari et al., 2007). Experimentally, date extracts have been shown to increase the concentration of testosterone, follicle stimulating hormone, and luteinizing hormone in rats (El-Mougy et al., 1991). However, there is not much literature or data available regarding its effect on spermatogenesis of prepubertal animals; therefore, we conducted this study on prepubertal rats to assess its effect.

In this study, spermatogenesis was assessed to see the effect of DPP suspension (120 mg/kg) given orally for 18 and 35 days in premature albino rats. Our data showed that there was no statistically significant difference in the observed parameter after 18 days of treatment with Date Palm pollen suspension in Control and Experimental groups I. It is suggested that processes controlling the absorption, distribution, metabolism, excretion, and pharmacologic effects of drugs are likely to be immature or altered in neonates (Milsap and Jusko, 1994). Moreover, the drugs administered to neonatal animals may exhibit significantly different pharmacokinetic/disposition characteristics than they do in adult animals of the same species (Schwark, 1992). Therefore, inability of DPP to produce its effect in the group treated for 18 days

may be due to age-related differences in maturation pathways responsible for drug absorption, distribution, metabolism and excretion (Espandari et al., 2010) or treatment with DPP took somewhere between 18 and 35 days to produce its effects.

Our data agrees with a study carried out by Bahmanpour Bahmanpour et al. (2006b), where they observed the effect of *Phoenix dactylifera* pollen on sperm parameters and reproductive system of adult male rats, after 35 days of treatment. There was a statistically significant increase in Johnsen's score in the group treated for 35 days with DPP suspension. Johnsen's criterion offers a convenient and rapid method for registration of spermatogenesis (Johnsen, 1970). Mean Johnsen score of control group II was 6.28 ± 0.21 , whereas in the treated group II, it was 8.06 ± 1.21 . The increase in the Johnsen's score of the treated group when compared with the Control group was statistically significant ($p < 0.001$). Johnsen showed a high correlation between log total sperm count and the mean Johnsen score. Thus an increase in the mean Johnsen score in our study is an indirect evidence of improvement in the sperm count. Bahmanpour et al. (2006b) also reported that DPP suspension reduced the sperm DNA denaturation and therefore, seems to improve its DNA quality and sperm parameters.

These findings also agree with the findings of Arsyad (1996) who showed that protodioscin treatment led to increase in concentration of spermatozoa; there was also an increase in the mobility and percentage of normal sperm. The authors attributed this to an increase in the LH level which was responsible for the Leydig cells to enhance testosterone secretion, resulting in an increased testosterone level in the blood stimulating sertoli and germinal cells and as stated earlier, date palm extracts increase these hormones in rats (El-Mougy et al., 1991). The most advanced cell present in the seminiferous

tubules of Control group II were spermatids, whereas testes of Experimental group II showed presence of spermatozoa within the lumen, implying thereby that spermatogenesis was present at an advanced stage in the Experimental as compared to the Control group II of animals.

Conclusion

Date Palm pollen suspension given orally at a dose of 120 mg/kg for 35 days resulted in an increase Johnsen scores. Further, spermatozoa were seen in the seminiferous tubules of Experimental group II. Our data regarding the effects of Date Palm pollen on testis implied that it had a complex stimulating effect on germinative and endocrine functions of the organ.

REFERENCES

- Ambler GR (2009). Androgen therapy for delayed male puberty. *Curr. Opin. Endocrinol. Diabetes Obes.* 16(3):232-239.
- Amelar RD, Dubin L, Walsh PC (1977). *Male infertility*. Philadelphia, WB Saunders Company.
- Anderheim L, Holter H, Bergh C, Moller A (2005). Does psychological stress affect the outcome of in vitro fertilization? *Hum. Reprod.* 20(10):2969-2975.
- Arsyad K (1996). Effect of protodioscin on the quantity and quality of sperms from males with moderate idiopathic oligozoospermia. *Medika* 22(8):614-618.
- Bahmanpour S, Talaei T, Vojdani Z, Panjehshahin M, Poostpasand A, Zareei S, Ghaemina M (2006a). Effect of phoenix dactylifera pollen on sperm parameters and reproductive system of adult male rats. *IJMS* 31(4):208-212.
- Bahmanpour S, Talaei T, Vojdani Z, Panjehshahin M, Poostpasand L, Zareei S, Ghaemina M (2006b). Effect of phoenix dactylifera pollen on sperm parameters and reproductive system of adult male rats. *IJMS* 31(4):208-212.
- Bancroft JD, Gamble M (2008). *Theory and practice of histological techniques*, (6th edition). London, Elsevier Health Sciences.
- Barrevelde W (1993) *Date palm products*. Rome, Italy, FAO.
- Carroll TA, Regan MC, Alyusuf R, Greene D, Curran B, Kay E, Leader M, Fitzpatrick JM (1997). Determination of testicular function after torsion by DNA flow cytometry of serial fine-needle aspirates. *Br. J. Urol.* 79(3):449-454.
- Çiftçi HB (2004). Injecting the prepubertal laboratory mice with a mixture of serine and threonine and its effect on spermatogenic function. *SÜ Ziraat Fakültesi Dergisi* 18(34):41-45.
- Crawford K (2008). 'Rat anaesthesia and dissection'. <http://bioweb.wku.edu/faculty/Crawford/ratlab.htm> (accessed 10th September 2010).
- Dhungel S, Bhattacharya S, Shrestha RN (2006). Effect of restraint stress on the growth rates of young wistar rats. *J. Nepal Health Res. Council* 4(1): 10-16.
- El-Mougy S, Abdel-Aziz S, Al-Shanawany M, Omar A (1991). The gonadotropic activity of palmae in mature male rats. *Alexandria J. Pharmacol.* 5:156-159.
- Espandiari P, Rosenzweig B, Zhang J, Zhou Y, Schnackenberg L, Vaidya VS, Goering PL, Brown RP, Bonventre JV, Mahjoob K, Holland RD, Beger RD, Thompson K, Hanig J, Sadrieh N (2010). Age-related differences in susceptibility to cisplatin-induced renal toxicity. *J. Appl. Toxicol.* 30(2):172-182.
- Hull MG, Glazener CM, Kelly NJ, Conway DI, Foster PA, Hinton RA, Coulson C, Lambert PA, Watt EM, Desai KM (1985). Population study of causes, treatment, and outcome of infertility. *Br. Med. J. Clin. Res.* Ed 291(6510):1693-1697.
- Iftikhar S, Bashir A, Anwar MS, Mastoi SM, Shahzad M (2011). Effect of date palm pollen (dpp) on serum testosterone levels in prepubertal albino rats. *Pak. J. Med. Health Sci.* 6(4):639-644.
- Johnsen SG (1970). Testicular biopsy score count--a method for registration of spermatogenesis in human testes: Normal values and results in 335 hypogonadal males. *Hormones* 1(1):2-25.
- Meschede D, Lemcke B, Behre HM, De Geyter C, Nieschlag E, Horst J (2000). Clustering of male infertility in the families of couples treated with intracytoplasmic sperm injection. *Hum. Reprod.* 15(7):1604-1608.
- Milsap RL, Jusko WJ (1994). Pharmacokinetics in the infant. *Environ. Health Perspect.* 102(Suppl 11):107-110.
- Pant PR (2009). Factors affecting male infertility. *J. Inst. Med.* 31(3):10-12.
- Pico C, Sanchez J, Oliver P, Miralles O, Ceresi E, Palou A (2007). Role of leptin present in maternal milk in the control of energy balance during the post-natal period. *Genes Nutr.* 2(1):139-141.
- Rhoden EL, Gobbi D, Menti E, Rhoden C, Teloken C (2002). Effects of the chronic use of finasteride on testicular weight and spermatogenesis in wistar rats. *BJU int.* 89(9):961-963.
- Roudsari RL, Allan HT, Smith PA (2007). Looking at infertility through the lens of religion and spirituality: A review of the literature. *Hum. Fertil. Camb* 10(3):141-149.
- Sato T, Ban Y, Uchida M, Gondo E, Yamamoto M, Sekiguchi Y, Sakaue A, Kemi M, Nakatsuka T (2005). Atropine-induced inhibition of sperm and semen transport impairs fertility in male rats. *J. Toxicol. Sci.* 30(3):207-212.
- Schwark WS (1992). Factors that affect drug disposition in food-producing animals during maturation. *J. Anim. Sci.* 70(11):3635-3645.
- Udagawa K, Ogawa T, Watanabe T, Tamura Y, Kita K, Kubota Y (2006). Testosterone administration promotes regeneration of chemically impaired spermatogenesis in rats. *Int. J. Urol.* 13(8):1103-1108.