

## EVALUATION OF TREATMENT OF PARACOCIDIOIDOMYCOSIS WITH COTRIMAZINE (COMBINATION OF SULFADIAZINE AND TRIMETOPRIM). PRELIMINARY REPORT

Benedito BARRAVIERA (1), Rinaldo Poncio MENDES (2), Jussara Marcondes MACHADO (3), Paulo Camara Marques PEREIRA (3), Maria Julia de SOUZA (4) & Domingos Alves MEIRA (5)

**KEY WORDS:** Paracoccidioidomycosis, cotrimazine, sulfadiazine and trimetoprim, cerebral paracoccidioidomycosis.

Treatment of paracoccidioidomycosis was started in 1940, when RIBEIRO<sup>11</sup> first used sulfadiazine, a sulfamide derivative. Other derivatives were later tested and found to have an effect against the fungus. According to DEL NEGRO<sup>5</sup>, none of the sulfamide derivatives thus far used for the treatment of paracoccidioidomycosis has proved to be superior to sulfadiazine.

Even though today there are several alternative treatment programs, such as those involving amphotericin B<sup>5, 8, 10</sup>, ketoconazole<sup>9, 10</sup>, or sulfonamides alone<sup>1, 5</sup> or in combination with trimetoprim<sup>2, 3, 7</sup>, some situations require special schedules. When cotrimazine, known by the commercial name TRIGLOBE F<sup>(R)</sup> (820 mg sulfadiazine and 180 mg trimetoprim), was first marketed in Brazil, it became possible to use this combination for the treatment of paracoccidioidomycosis, since potentiation of the fungistatic effects occurs<sup>4</sup> when these drugs are used in com-

ination. The authors<sup>3</sup> tested the efficacy of the drug using 1 tablet of cotrimazine every 12 hours for 6 months. The dose was reduced by half after 6 months and maintained up to the end of 12 months of treatment. After this, the patients were maintained with 500 mg sulfadoxin administered orally twice a week<sup>10</sup>.

Twenty one adult male patients aged 34 to 64 years with a confirmed diagnosis of paracoccidioidomycosis were studied. The clinical form of the disease<sup>6</sup> was the adult chronic type, with 8 unifocal cases (1 mild case and 7 moderate cases) and 13 multifocal cases (4 mild, 7 moderate and 2 severe cases). Therapeutic effectiveness was assessed on the basis of clinical evolution, serology (immunodiffusion on agar gel), radiology and mycology.

Of the 21 patients studied, 18 (85.72%) showed improvement with clinical remission and

(1) Professor Assistente Doutor do Departamento de Moléstias Infecciosas e Parasitárias, Dermatologia e Radiologia da Faculdade de Medicina de Botucatu (UNESP), Botucatu, São Paulo, Brasil.

(2) Professor Adjunto do Departamento de Moléstias Infecciosas e Parasitárias, Dermatologia e Radiologia da Faculdade de Medicina de Botucatu (UNESP), Botucatu, São Paulo, Brasil.

(3) Professor Assistente do Departamento de Moléstias Infecciosas e Parasitárias, Dermatologia e Radiologia da Faculdade de Medicina de Botucatu (UNESP), Botucatu, São Paulo, Brasil.

(4) Técnico do Laboratório de Moléstias Infecciosas e Parasitárias da Faculdade de Medicina de Botucatu (UNESP), Botucatu, São Paulo, Brasil.

(5) Professor Titular do Departamento de Moléstias Infecciosas e Parasitárias, Dermatologia e Radiologia da Faculdade de Medicina de Botucatu (UNESP), Botucatu, São Paulo, Brasil.

**Address for correspondence:** Dr. Benedito Barraviera, Faculdade de Medicina de Botucatu, Universidade Estadual Paulista "Julio de Mesquita Filho" (UNESP), CEP 18610, Botucatu, SP, Brasil.

decreased serum antibody titers, and serology was negative in 3 of them 5, 6 and 9 months after treatment was started. Of the 3 remaining patients, 2 abandoned treatment and 1 showed intolerance for the medication manifested as increased transaminase levels, eosinophilia and

sulfhemoglobin formation. An alternative treatment was instituted for this patient.

The 15 patients with positive serology are described below:

PATIENT	INITIAL SEROLOGY	TIME OF TREATMENT	PRESENT SEROLOGY	CLINICAL FORM
1	1/4	18 months	+ pure	unifocal moderate
2	1/128	18 months	1/4	multifocal severe
3	1/32	18 months	1/4	multifocal moderate
4	1/64	16 months	1/2	multifocal moderate
5	1/32	14 months	1/2	multifocal moderate
6	1/8	13 months	+ pure	unifocal moderate
7	1/32	13 months	+ pure	unifocal moderate
8	1/4	11 months	+ pure	multifocal mild
9	1/128	10 months	1/16	multifocal moderate
10	1/32	10 months	1/4	unifocal moderate
11	1/64	9 months	1/16	unifocal moderate
12	1/32	9 months	1/4	multifocal mild
13	1/16	7 months	1/16	multifocal severe
14	1/4	6 months	1/4	multifocal moderate
15	1/256	6 months	1/64	multifocal moderate

For the two patients with the multifocal severe form, one of whom had skin, oral mucosa and lung lesions (patient 2) and the other lung and central nervous system lesions (patient 13), it was necessary to increase the dose. Since patient 2 showed worsening signs and symptoms after 1 month of treatment, treatment was increased to 2 cotrimazine tablets every 12 hours. This new dosage was maintained for 30 days and improvement occurred, with remission of clinical manifestations and reduction in antibody titer. The dose was then reduced again to 1 tablet every 12 hours and maintained at this level for 12 months.

Patient 13 initially took 2 cotrimazine tablets every 12 hours in combination with 500 mg sulfadiazine every 8 hours. This schedule was maintained for 21 days, after which cotrimazine was reduced to 1 tablet every 12 hours and sulfadiazine maintained at the same dosage. This schedule was maintained for 3 months and the patient is currently taking 1 TRIGLOBE F<sup>®</sup> tablet orally every 12 hours, with obvious improve-

ment in clinical condition and in computerized axial tomography, as shown below. (Fig. 1, 2).

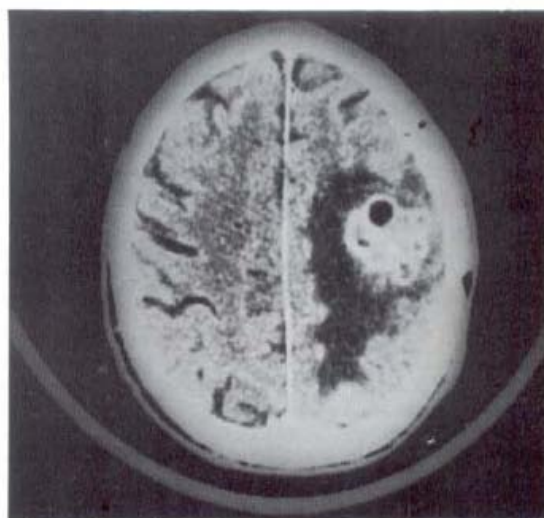


Fig. 1 — Computerized axial tomography of patient 13, before treatment. October 24, 1987 — (with contrast). Polycystic hyperdense mass with hyper-uptake, surrounded by a hypodense area with hypo-uptake. Conclusion: Active multicystic inflammatory process.

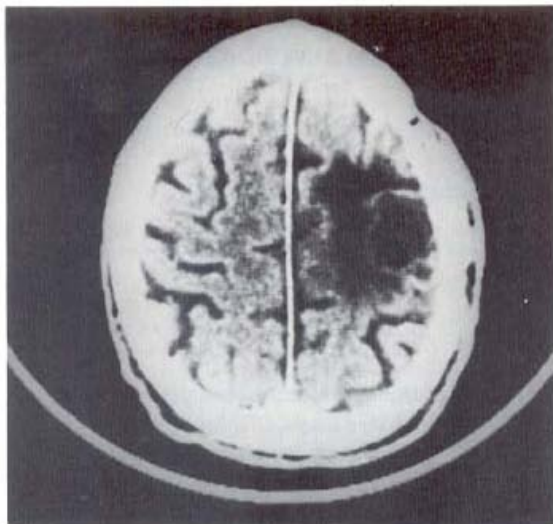


Fig. 2 — During treatment — April 5, 1988 — (with contrast). Polycystic hypodense mass with hypo-uptake, with a healing process.

Conclusion: Healing inflammatory process.

On the basis of these preliminary results, the combination of sulfadiazine and trimetoprim proved to be useful for the treatment of paracoccidioidomycosis patients attended on an outpatient clinic basis. On the other hand, cotrimazine seems to be a good therapeutic alternative for patients with the cerebral form of paracoccidioidomycosis, since both sulfadiazine and trimetoprim cross the cerebrospinal-blood brain barrier quite well.

#### ACKNOWLEDGEMENTS

We wish to thank MERREL-LEPETIT for providing us with TRIGLOBE F.

#### REFERÊNCIAS

1. BARBOSA, W. & DAHER, R. R. — Blastomicose sul americana (Paracoccidioidomycose). In: VERONESI, R. — *Doenças infecciosas e parasitárias*. 7. ed. Rio de Janeiro, Guanabara Koogan, 1982. p. 638-651.
2. BARBOSA, W. & VASCONCELLOS, W. M. de P. V. — Ação da sulfametoxazol associada ao trimetoprim na terapêutica da blastomicose sul americana. *Rev. Pat. trop.*, 2: 329-339, 1973.
3. BARRAVIERA, B.; MENDES, R. P.; MACHADO, J. M.; PEREIRA, P. C. M.; de SOUZA, M. J. & MEIRA, D. A. — Avaliação do tratamento da paracoccidioidomycose pela cotrimazina (associação sulfadiazina e trimetoprim). In: CONGRESSO DA SOCIEDADE BRASILEIRA DE MEDICINA TROPICAL, 24, Manaus, 1988. *Anais. Manaus*, 1988. p. 44.
4. BUDEL, A. R.; FERNANDES, G. P.; LAMEIRA, R. F. & TELLES FILHO, F. Q. — Sensibilidade "in vitro" do *Paracoccidioides brasiliensis* à associação trimetoprim/sulfametoxazol. *Rev. Soc. bras. Med. trop.*, 20 (supl. 1): 76, 1987.
5. DEL NEGRO, G. — Tratamento. Controle de cura. Profilaxia. In: DEL NEGRO, G.; LACAZ, C. S. & FIORILLO, A. M. — *Paracoccidioidomycose (blastomicose sul americana)*. São Paulo, Sarvier; EDUSP, 1982. p. 271-283.
6. FRANCO, M. F.; MONTENEGRO, M. R.; MENDES, R. P.; MARQUES, S. A.; DILLON, N. L. & MOTA, N. G. S. — Paracoccidioidomycose: a recently proposed classification of its clinical forms. *Rev. Soc. bras. Med. trop.*, 20: 129-132, 1987.
7. GUERREIRO, C. A. M.; CHULUC, S. S. D. & BRANCHINI, M. L. N. — A new treatment for large cerebral paracoccidioidomycosis. *Arq. Neuro-psiquit. (S. Paulo)*, 45: 419-423, 1987.
8. MARCONDES, J.; BARRAVIERA, B.; MEIRA, D. A. & MENDES, R. P. — Emprego da anfotericina B corrigida pelo clearance de creatinina em doentes com Paracoccidioidomycose. In: CONGRESSO DA SOCIEDADE BRASILEIRA DE MEDICINA TROPICAL, 18, Ribeirão Preto, 1982. *Anais. Ribeirão Preto*, 1982. p. F-19.
9. MARCONDES, J.; MEIRA, D. A.; MENDES, R. P.; PEREIRA, P. C. M.; BARRAVIERA, B.; MOTA, N. G. S. & MORELLI, J. — Avaliação do tratamento da Paracoccidioidomycose com o ketoconazol. *Rev. Inst. Med. trop. S. Paulo*, 26: 113-121, 1984.
10. MENDES, R. P. — Paracoccidioidomycose. In: MEIRA, D. A. — *Terapêutica de doenças infecciosas e parasitárias*. Rio de Janeiro, EPUME, 1987. Cap. 28. p. 175-182.
11. RIBEIRO, D. O. — Nova terapêutica para a blastomicose. *Publ. méd. (S. Paulo)*, 12: 36-54, 1940.

Recebido para publicação em 9/6/1988.