

CASE REPORT

Ewing's sarcoma of rib

SM Hossain¹, F Kabir², SM Kamal³, DK Ghosh⁴

Abstract

Ewing's sarcoma is an uncommon malignant bone tumour occurring in children, adolescents and young adults. We report a case of a 13 year old male admitted to Khulna Medical College Hospital with history of pain and swelling in chest wall for two weeks. Earlier chest X-ray showed a mass lesion in the left upper part of chest wall and erosion of first rib. Subsequent X-ray revealed left sided massive pleural effusion. CT scan revealed a mass lesion in the left upper part of chest wall originated from left first rib and left sided pleural effusion. FNAC from the mass lesion revealed features suggestive of Ewing's sarcoma. Patient was treated with chemotherapy and after first cycle there was significant improvement of all the signs and symptoms.

Introduction

Ewing's sarcoma is a highly malignant, round cell tumour of bone and occurs in children, adolescents and young adult, most commonly in age between 10-20 years. It has an incidence of less than 1 per 1 million per year and has a higher incidence in males.¹ Although it may develop in any bone, the most frequent sites are tubular bones and metaphysis of long bones especially the femur, ilium, tibia. It is an aggressive tumour showing rapid growth and early metastasis. Metastatic disease has a long term survival of 20%. It arises from mesenchymal progenitor cells. It is a part of spectrum of neoplastic disease known as Ewing's Sarcoma family of tumours.² Radiological characteristics, biopsy report and immunohistochemistry is needed for confirmation of diagnosis.³

We report a case of Ewing's sarcoma of rib to highlight that, it is important to identify this uncommon case of pleural effusion to provide early and appropriate treatment.

Case report:

A 13 year old boy hailing from Jessore was admitted in medicine unit I, Khulna Medical College Hospital with the history of swelling of left upper chest wall for two weeks (Fig. 1). Swelling was gradually increasing in size associated with pain. He had no history of fever, cough, night sweating. On examination patient was mildly anaemic, temperature normal and there was no lymphadenopathy. Systemic examination revealed

a swelling in chest wall and part of left axilla measuring about (10 x 15 cm) which is firm and tender, fixed to the underlying structure. Local temperature was normal over the swelling. Left sided massive pleural effusion present. Other systemic examination revealed normal. Complete blood count, revealed mild anaemia but blood sugar & serum creatinine were normal. X ray chest revealed a mass lesion and erosion of first rib of left side with pleural effusion (Fig. 2 & 3) Pleural fluid study showed red colour fluid, protein 3.6g/dl, total cell count 5260/cmm, lymphocyte 97%, neutrophil 3%. There was no malignant cell. CT scan of chest revealed a mass lesion in the left upper part of chest originated from left first rib and also there was massive pleural effusion. FNAC from the mass lesion revealed many large atypical lymphocyte like cells having coarse irregular granular nuclear chromatin with nuclear fold and grooves and scattered in a background of inflammatory cells and blood. Patient was treated with chemotherapy (cisplatin and Doxorubicin). After giving first cycle of chemotherapy, significant improvement occurs, chest wall swelling disappeared, pain subsided and improvement of pleural effusion. Chemotherapy was given by the oncology department.

Discussion:

In 30% cases Ewing's Sarcoma is multicentric in origin.⁴ In 10-50% cases multiple metastasis

1. Sk Moazzem Hossain FCPS, Junior Consultant (Medicine), Khulna Medical College Hospital.

2. Farjana Kabir FCPS, R/P (Medicine), Khulna Medical College Hospital.

3. SM Kamal FCPS, Professor of Medicine, Khulna Medical College.

4. Debasish Kumar Ghosh MD, Assistant Prof. (Endocrinology), Khulna Medical College.

including cervix are present at the time of diagnosis.⁵ CNS spread is rare. Radiologically

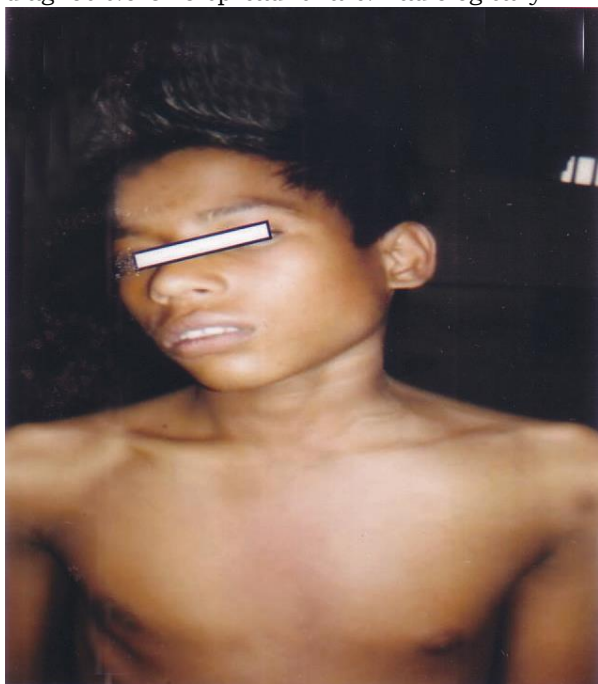

Fig. 1: Patient showing swelling in left chest (Printed with permission)

Ewing's sarcoma appears as an ill defined osteolytic lesion with periosteal elevation or onion skinning.⁶ Histopathologically Ewing's sarcoma is composed of small round anaplastic cell with medium sized round to oval nuclei & scanty peripheral ring of cytoplasm. Small round cells

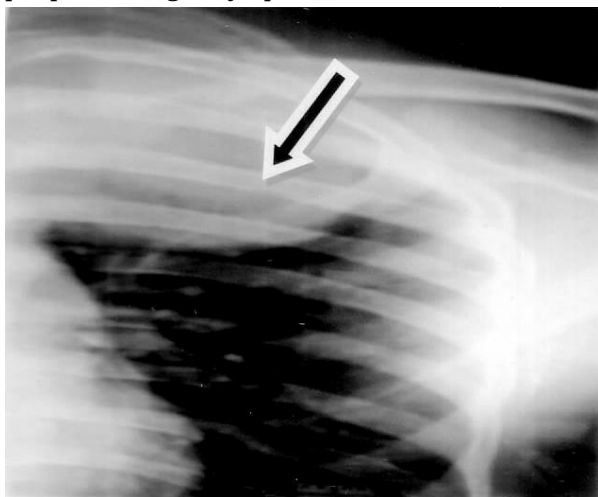


Fig. 2: X-ray chest showing erosion of 1st rib

can be seen in a wide variety of malignancies which can be remembered using the mnemonic "LEMON" (lymphoblastic lymphoma, Ewing's sarcoma, medulloblastoma, oat cell neuroendocrine and neuroblastoma). Immunohistochemistry is needed for diagnosis.

Positivity to CD 99 with membranous accentuation is characteristic of Ewing's sarcoma.⁷ Modalities of treatment are surgery, radiotherapy and chemotherapy. Study demonstrated improved outcome with inclusion of doxorubicin in every chemotherapy protocol.⁸ Survival among patients with primary tumors in pelvic bones is low, whereas survival among patients with lesions in distal bones of the extremities is highest. Three factors seem to be correlated to prognosis: the site of the initial lesion, the chemotherapy protocol and the type of local treatment. Poor prognostic factors also include tumor size ≥ 8 cm, pelvic primary, presence of metastases and age >15 at the time of diagnosis. Systemic symptoms, high ESR, elevated LDH and thrombocytosis are also poor prognostic indicator.^{9,10}

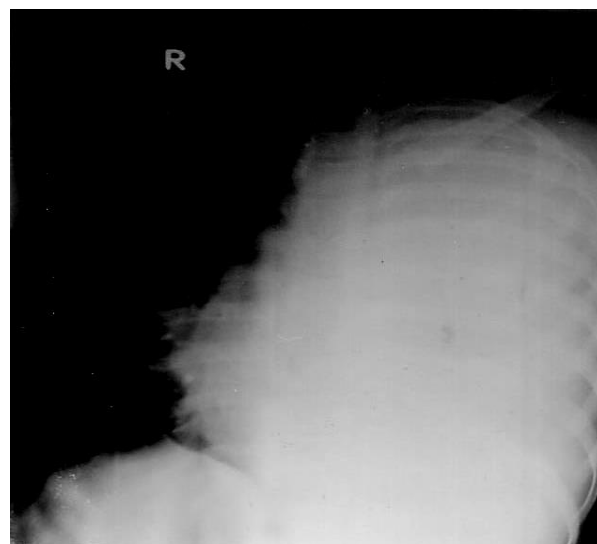


Fig. 3: X-ray chest showing massive pleural effusion

In a case of Ewing's sarcoma of rib in a young male, Soft tissue sarcoma, rhabdomyosarcoma and metastatic lesion should be kept in mind as a differential diagnosis. The patient was managed with chemotherapy (cisplatin and doxorubicine). After giving first cycle of chemotherapy, chest wall swelling disappeared, pain subsided and there was significant improvement of pleural effusion. As an aggressive tumour it needs more prolonged treatment and follow up.

References

1. Canale ST, Beaty JH. Campbell's operative orthopaedics: Ewing sarcoma. 12 th ed: Vol. 1. Philadelphia: Elsevier Mosby; 2013: 918-920.
2. Deshingker's Berpenol. Tupkering Ewing sarcoma of Zygoma oral Mexillofac Pathol. 2009;13: 18-22.
3. WAmoto Y, Diagnosis and treatment of ewing's sarcoma, Jpn J clin oncol 2007; 37: 78-89.

4. Khoury JD. Ewing sarcoma family of tumors. *Adv Anat Pathol*. 2005; 12:212-20.
5. Benbrahim. Z, Haie Meder C, Duvillard P, El Mesbahi O, Primitive neuroectodermal tumor of the cervix uteri: a case report and review of literature. *Int J Hematol Oncol Stem Cell Res*. 2012; 6: 4
6. Indellicato DJ, Keole SF, Shahlaee AH, Impact of local management on longterm outcomes in Ewing tumors of the pelvis and sacral bones: the University of Florida experience. *Int J Radiat Oncol Biol Phys*, 2008. 72: 41-48.
7. Paulussen M, Bielack S, Jurgens H and Casali PG; ESMO Guidelines Working Group. Ewing's sarcoma of the bone: ESMO clinical recommendations for diagnosis, treatment and follow up. *Ann Onco* 2009; 20: 140-142.
8. Grier BE, Krailo MD, Miser Js, Tarbell NJ, et al Addition of ifosfamide and etoposide to standard chemotherapy for Ewing's sarcoma and primitive neuroectodermal tumor of bone. *N Engl J Med* 2003; 348: 694-701.
9. Athale U, Cox S, Siciliano S and Chan AK: Thromboembolism. in children with sarcoma. *Pediatr Blood Cancer* 2007; 49: 171-176.
10. Jedicka P. Ewing's sarcoma, an enigmatic malignancy of likely progenitor cell origin, driven by transcription factor oncogenic fusions. *Int J Clin Exp Pathol*. 2010; 3: 338-47.