

Received: 2012.07.26  
Accepted: 2012.10.09

## Exogenous lipid pneumonia – a case report of a fire-eater

Magdalena Pielaszkiewicz-Wydra<sup>1</sup>, Bożena Homola-Piekarska<sup>2</sup>,  
Ewa Szcześniak<sup>2</sup>, Monika Ciołek-Zdun<sup>1</sup>, Andrzej Fall<sup>2</sup>

<sup>1</sup> Department of Radiology, CMKP (Postgraduate Medical Education Center), Warsaw, Poland

<sup>2</sup> Clinical Department of Internal Medicine and Allergology (Central Clinical Hospital for Ministry of Interior in Warsaw), Warsaw, Poland

**Author's address:** Monika Ciołek-Zdun, Department of Radiology, Central Clinical Hospital Ministry in Warsaw, Warsaw, Poland, e-mail: m.ciolekdun@gmail.com

### Summary

#### Background:

Exogenous lipid pneumonia is an uncommon condition caused by inhalation or aspiration of a fatty substance. It usually presents as chronic respiratory illness mimicking interstitial lung diseases. Acute exogenous lipid pneumonia is uncommon and typically is caused by an episode of aspiration of a large quantity of a petroleum-based product. Radiological findings vary and may imitate many other diseases.

#### Case Report:

We present a rare case of acute exogenous lipid pneumonia in a fire-eater who aspirated liquid paraffin during his flame-blowing show (fire-eater's lung). He was admitted to the hospital with productive cough, fever, hemoptysis, chest pain and dyspnea. Diagnosis was made on the basis of history of exposure to fatty substance, characteristic findings in CT examination and presence of lipid-laden macrophages in bronchoalveolar lavage fluid.

#### Conclusions:

Acute exogenous lipid pneumonia is a very rare disease that typically occurs in fire-eaters and is called a fire-eater's lung. The diagnosis is made on the basis of typical history and radiological, as well as histopathological findings.

#### Key words:

computed tomography • lipid pneumonia • fire-eater's lung • consolidation • radiography

#### PDF file:

<http://www.polradiol.com/fulltxt.php?ICID=883631>

### Background

Exogenous lipid pneumonia is a rare condition caused by inhalation or aspiration of plant, animal or mineral fats and may take an acute or chronic form [1]. Acute exogenous lipid pneumonia occurs sporadically and typically results from exposure to large amounts of mineral oils [2,3]. Acute form is usually associated with accidental poisoning in children. In an adult population it typically occurs in fire-eaters, who use oily substances in their shows.

Chronic exogenous lipid pneumonia usually develops as a result of repeated episodes of aspiration or inhalation of oily substances and is generally diagnosed in older patients predisposed to it by factors such as neurological diseases, poor general condition, psychiatric disorders, gastroesophageal reflux or post-laryngectomy state [4–6]. The most common cause of the disease is use of oily substances as

laxatives, inhaled airway moisturizing agents and, rarely, as nose drops.

Mineral and plant oils induce minimal or moderate inflammatory reaction in lung parenchyma. They are not metabolized by tissue enzymes, but undergo emulsification and become engulfed by macrophages which, with time, may disintegrate and release oily substances surrounded by fibrous tissue and giant cells [7]. On the other hand, animal fats are hydrolyzed by pulmonary lipases to free fatty acids and induce severe inflammatory reaction presenting with local edema and alveolar hemorrhage. Fatty acids may remain in alveoli or be phagocytized by macrophages, which migrate into the interlobular septa and cause their thickening. Inflammatory response may destroy alveolar walls and interstitium leading to lung fibrosis [7].

Clinically, acute lipid pneumonia presents most often with cough, dyspnea and fever [8]. Patients with chronic exogenous lipid pneumonia often do not display clinical symptoms and the disease is diagnosed incidentally in radiological studies. Symptomatic patients complain of chronic cough, dyspnea, rarely fever, weight loss, chest pain and hemoptysis [5,8]. During physical examination there are usually no deviations found on lung auscultation, but sometimes crackles and wheezes may present [8].

Signs of lipid pneumonia in plain radiography are nonspecific [9]. Chest x-ray pictures show consolidation, reticular and mixed alveolar-interstitial changes as well as nodular lesions. Such changes are usually located in lower lobes or right middle lobe, may be multifocal or bilateral [4–6]. Other abnormalities, which may be noted on radiograms are: pneumatocele, pneumothorax, pneumomediastinum and pleural effusion [7,8].

The best imaging method for diagnostics of lipid pneumonia is high-resolution computed tomography (HRCT) [10]. Most commonly, CT shows areas of consolidation and ground glass opacities as well as interstitial changes such as interlobular septal thickening and intralobular lines, fine, poorly demarcated centrilobular nodules and nodular lesions, pneumatocele, pneumothorax, pneumomediastinum, pleural effusion [1,5,6,8,9]. Changes involve one or both lungs and are usually located in lower lobes or in the right middle lobe [5,8]. Depending on the presentation of the disease, these lesions should be differentiated from other forms of pneumonia, interstitial lung diseases, tuberculosis and lung tumors.

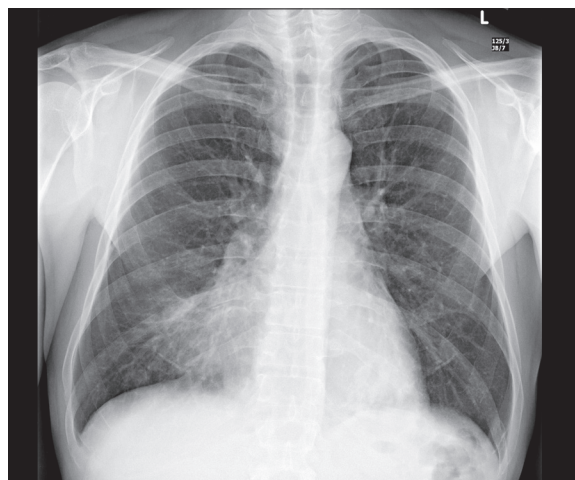
The most characteristic feature of lipid pneumonia in CT imaging is the presence of areas with a negative attenuation coefficient (between  $-150$  and  $-30$  HU). Associated inflammatory process and/or fibrosis may be the factor increasing the value of attenuation coefficient, which makes fatty areas less visible [1,8,11]. Also, a CT examination in lipid pneumonia may reveal an angiogram sign (presence of vessels in areas of opacity following contrast administration) and „cobblestone” appearance [1,5].

During remission of acute lipid pneumonia radiological signs completely or almost completely disappear, leaving fibrous scars [8]. On the other hand, in a chronic form, control imaging studies show either no improvement or even progression of lesions [8].

## Case Report

A 44-year-old patient, an actor performing in fire-blowing shows for the past several years, without other comorbidities, was admitted acutely to the hospital due to  $38^{\circ}\text{C}$  fever, hemoptysis, pleuritic chest pain and dyspnea. Three days before the onset of symptoms the patient aspirated liquid kindling for the grill.

On admission, the patient remained in a relatively good condition, without signs of respiratory failure. On physical examination he presented with tachycardia 100 bpm, numerous crackles on auscultation of the right lung, which were joined by bilateral wheezing and rhonchi after several days.



**Figure 1.** Chest x-ray PA – consolidation and reticular changes in the right inferomedial lung field.

Laboratory studies showed leukocytosis ( $18.51 \times 10^3/\text{uL}$ ) with a left shift and significantly elevated CRP (304 mg/L). A chest X-ray (AP) showed consolidation in inferior and medial region of the right lung (Figure 1).

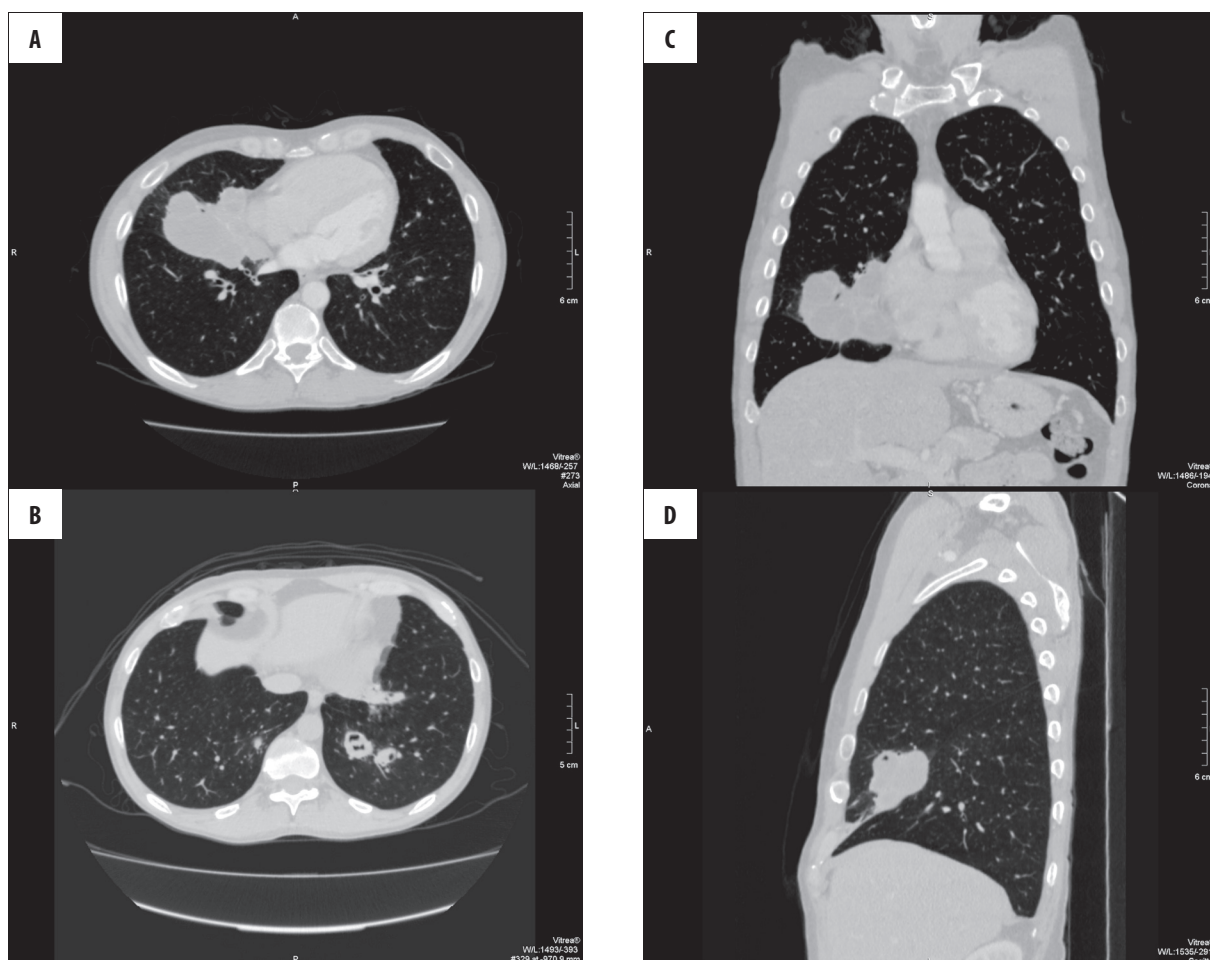
On the first day of hospitalization the patient underwent bronchoscopy, which revealed accumulation of mucopurulent secretions, more pronounced in the middle lobe bronchus. Mucus membranes covering this bronchus were fragile, bleeding and inflamed. Secretions were aspirated and bronchoalveolar lavage fluid was collected for bacteriological studies and cytology. Subsequently, it was rinsed with saline.

Cytological analysis of bronchoalveolar lavage fluid stained with Sudan III showed presence of extracellular drops of fat and fat-laden macrophages. Bronchial lavage during bronchoscopy with local application of colistin and hydrocortisone was performed twice more, but only trace amounts of fatty substance were found on microscopic examination of collections.

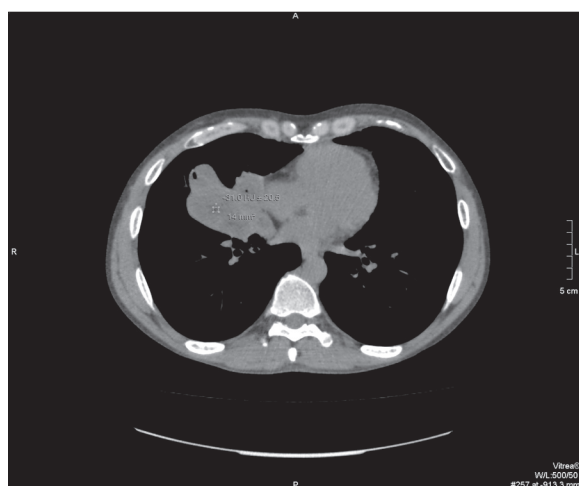Chest computed tomography examination revealed a polycyclic, heterogeneous area of fat-fluid density in the lower part of the right middle lobe. There were contrast-enhancing fibrous bands visible within the tumor and at its peripheries. Smaller lesions of similar morphology and density of adipose tissue were also noted in lower segments of both lungs. Moreover, a pneumatocele was visualized within the mentioned lesion and areas of ground glass opacities and interlobular thickening were noted nearby. There was no fluid in pleural cavities and no hilar and mediastinal lymphadenopathy was noted (Figures 2, 3).

Lipoid pneumonia was diagnosed on the basis of clinical data, bronchoalveolar lavage fluid microscopy and imaging studies.

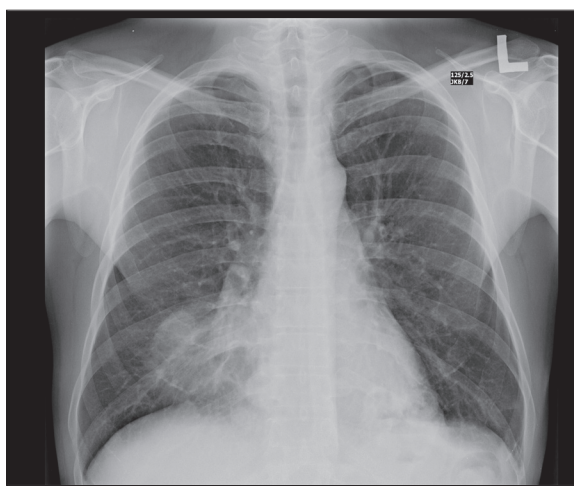
Empirical antibiotic treatment with ceftriaxone (2.0 g/day) and metronidazole ( $2 \times 500$  mg/day) together with intravenous hydrocortisone ( $2 \times 100$  mg/day replaced after several days with 20 mg of prednisone per day) was implemented immediately after admission to hospital. After



**Figure 2.** Chest HRCT – (A) massive opacities in the right middle lung lobe; (B) changes of similar morphology, accompanied by a pneumatocele and thickening of interlobular septa in segments 9 and 10 of the left lung; (C) and (D) presence of opacities in the right middle lung lobe in coronal (C) and sagittal projections (D).



**Figure 3.** Chest HRCT – a polycyclic lesion with areas of fat density is visible in the posteroinferior part of the right middle lung lobe.



**Figure 4.** Chest x-ray PA – follow-up examination performed after 10 days of treatment – consolidation of pulmonary infiltrates.

obtaining the results of bronchoalveolar lavage cultures (*Enterobacter aerogenes*) gentamycin at a dose of 160 mg/day was added to the above pharmacotherapy. As a result, patient's clinical state improved, pathological lung

auscultatory sounds subsided and laboratory parameters normalized (including total blood count and CRP). Control chest X-ray performed after 10 days of treatment showed consolidation of inflammatory infiltrates (Figure 4).

Patient was released into ambulatory care and was ordered to report for follow-up examinations, while continuing therapy with 20 mg of prednisolone per day and oral clindamycin at a dose of 3×600 mg/day to complete a 3-week treatment course. After 4 weeks the patient, a resident of Wrocław, was admitted to the Lower Silesia Center of Lung Disease with a fever of up to 38°C persisting despite antibiotic therapy. In a conventional chest radiogram there was no regression of changes. No significant deviations from normal status were noted on clinical examinations and additional studies beside an elevated CRP (47.04 mg/l) and leukocytosis ( $13.5 \times 10^3/\mu\text{l}$ ) with a left shift in a white cell count differential as well as growth of *Klebsiella pneumoniae* ESBL (+) in bronchoalveolar lavage fluid cultures. Trimethoprim with sulphamethoxazole was commenced according to the antibiogram and, following a decrease in CRP and leukocyte levels and partial regression of radiological lesions, the patient was recommended to continue this treatment out of the hospital for a total number of 10 days (2×960 mg/day) and to continue prednisone treatment at a daily dose of 20 mg.

Three months after this incident of a fatty substance aspiration the patient is still treated with prednisone at a mentioned dose and remains under care of the facility in Lower Silesia.

## Discussion

Acute lipid pneumonia is an extremely rare condition. In an adult population, fire-swallowing artists are at the greatest risk of developing it. Therefore, this condition was called a fire-eater's lung. Cases of fire-eater's lung described in the literature [2,12–18] are similar to the one presented in this article. Patients report to hospital due to cough, dyspnea, chest pain, hemoptysis and fever. They have a history of mineral oil aspiration during fire-swallowing performance. Clinical symptoms develop several dozen hours after the incident. On physical examination they usually present with auscultatory phenomena over the lungs such as crackles and, at later stages, rhonchi and wheezes. Laboratory tests usually reveal elevation of inflammatory markers. Diagnosis can be confirmed by identifying fat drops or fat-laden macrophages in bronchoalveolar lavage fluid.

## References:

1. Laurent F, Philippe JC, Vergier B et al: Exogenous lipid pneumonia: HRCT, MR, and pathologic findings. *Eur Radiol*, 1999; 9: 1190–96
2. Kitchen JM, O'Brien DE, McLaughlin AM: Perils of fire eating: an acute form of lipid pneumonia or fire eater's lung. *Thorax*, 2008; 63: 401–39
3. Facon D, Coumbaras J, Bigot E et al: Acute hydrocarbon pneumonia after white spirit aspiration: sequential HRCT findings. *Eur Radiol*, 2005; 15(1): 31–33
4. Spickard A, Hirschmann J: Exogenous lipid pneumonia. *Arch Intern Med*, 1994; 154: 686–92
5. Gondouin A, Manzoni P, Ranfaing E et al: Exogenous lipid pneumonia: a retrospective multicentre study of 44 cases in France. *Eur Respir J*, 1996; 9: 1463–69
6. Lee JS, Im JG, Song KS et al: Exogenous lipid pneumonia: high-resolution CT findings. *Eur Radiol*, 1999; 9: 287–91
7. Betancourt SL, Martinez-Jimenez S et al: Lipoid Pneumonia: Spectrum of Clinical and Radiologic Manifestations. *AJR*, 2010; 194: 103–9
8. Baron SE, Haramati LB, Rivera VT: Radiological and clinical findings in acute and chronic exogenous lipid pneumonia. *J Thorac Imaging*, 2003; 18: 217–24
9. Lee KS, Müller NL, Hale V et al: Lipoid pneumonia: CT findings. *J Comput Assist Tomogr*, 1995; 19: 48–51
10. Marchiori E, Zanetti G, Mano CM et al: Exogenous lipid pneumonia. Clinical and radiological manifestations. *Respir Med*, 2011; 105(5): 659–66
11. Brechot JM, Buy JN, Laaban JP et al: Computed tomography and magnetic resonance findings in lipid pneumonia. *Thorax*, 1991; 46: 738–39
12. Kadakal F, Uysal MA, Gülhan NB et al: Fire-eater's pneumonia characterized by pneumatocele formation and spontaneous resolution. *Diagn Interv Radiol*, 2010; 16(3): 201–3

Radiological studies of the chest usually show areas of consolidation in the lower and/or mid lung fields. Sometimes, plain radiograms reveal the presence of cavernous lesions with or without fluid level and pleural effusion.

In CT and HRCT studies we may often identify areas of consolidation in the lung interstitium, peribronchial consolidation, areas of ground glass appearance, pneumatocele with or without a fluid level or pleural effusion. Such lesions usually involve the lower lobes of both lungs or right middle lobe. They may be uni- or bilateral.

Due to very few described cases, treatment recommendations are based on the clinical experience up to date. Elimination of the causative factor is the primary concern. Steroids are used in treatment, especially of acute cases. Dosing and duration of therapy are not precisely established: prednisone was used at a dose of at least 0.5 mg/kg for a period of at least few months. Moreover, antibiotic therapy is used for infections that complicate local inflammatory response. It is also recommended to perform a bronchoalveolar lavage. Cases that are associated with respiratory failure require adequate treatment according to generally accepted rules. Therapy is usually followed by clinical improvement and complete or nearly complete remission of radiological signs during the next 1–12 months.

In case of the presented patient, clinical improvement occurred after several dozen days of treatment. Subsequently, despite antibiotic and steroid therapy, there was a superinfection with *Klebsiella pneumoniae* accompanied by a recurrence of fever and elevation of inflammatory markers. Currently, three months after aspiration, the patient is still treated with prednisone. Radiological lesions underwent partial regression.

## Conclusions

Fire-eater's lung is an acute form of exogenous lipid pneumonia. Fire-swallowing artists are at the greatest risk of falling ill with this disease. Diagnosis is based on a history of aspiration or inhalation of an oily substance, changes visible in diagnostic imaging and cytological examination of sputum, bronchoalveolar lavage fluid or on histopathological studies of lung tissue.

- 
13. Şahin F, Yıldız P: Fire Eater's Pneumonia: One of the rare differential diagnoses of pulmonary mass images. *Iranian Journal of Radiology*, 2011; 8(1): 50–52
  14. Beermann B, Christensson T, Moller P et al: Lipoid pneumonia: an occupational hazard of fire eaters. *Br Med J (Clin Res Ed)*, 1984; 289(6460): 1728–29
  15. Brander PE, Taskinen E, Stenius-Aarniala B: Fire-eater's lung. *Eur Respir J*, 1992; 5(1): 112–14
  16. Yigit O, Bektas F, Sayrac AV et al: Fire-eater's pneumonia: two case reports of accidentally aspirated paraffin oil. *J Emerg Med*, 2012; 42(4): 417–19
  17. Lampert S, Schmid A, Wiest G et al: Fire-eater's lung. Two cases and review of the literature, *Dtsch Med Wochenschr*, 2006; 131(7): 319–22
  18. Krychniak-Soszka A, Lewandowska K, Skorupka W et al: Egzogenne lipidowe zapalenie płuc – różnorodność obrazu klinicznego i radiologicznego. *Pneumonol Alergol Pol*, 2005; 73: 182–88 [in Polish]