

Reprinted from ANNALS of SURGERY, Vol. 197, No. 3, March 1983. Copyright. © 1983, by J. B. Lippincott Company.

Printed in U.S.A.



## Experience with 150 Liver Resections

SHUNZABURO IWATSUKI, M.D., BYERS W. SHAW, JR., M.D., THOMAS E. STARZL, M.D., PH.D.

One hundred fifty liver resections were performed with an operative mortality rate of 4%. Indications for liver resections were 43 primary liver malignancies, 43 metastatic liver tumors, and 64 benign liver diseases. The 3-year actuarial survival rate after treatment of primary liver malignancy was 56%, and that after treatment of metastatic liver tumors was 66%. All but one of 59 patients with benign disease who survived operation were alive without development of late symptoms or complications.

**D**URING A 17-year period, from October 1964 to March 1982, 150 subtotal liver resections were performed by the liver transplantation surgeons at the University of Colorado Health Sciences Center and the University Health Center of Pittsburgh, Pennsylvania. This report emphasizes the low mortality and morbidity rates after liver resections, the encouraging survival rates of patients with both primary and metastatic malignant disease, and the value of hepatic resection in treating patients with nonmalignant hepatic lesions.

### Methods

#### Case Material

The medical records of all 150 patients who underwent resection of a portion of the liver for treatment were reviewed. It was possible to trace every patient, and for those still living, the follow-up was to May 1982. Portions of the authors' past experience have been reported earlier.<sup>1-6</sup>

Supported by Grant nos. AM 30183 and AM 17260, National Institutes of Health, Bethesda.

Reprint requests: Shunzaburo Iwatsuki, M.D., Department of Surgery, University Health Center of Pittsburgh, 1084 Scaife Hall, Pittsburgh, Pennsylvania 15261.

Submitted for publication: August 17, 1982.

*From the Department of Surgery, School of Medicine, University Health Center of Pittsburgh, Pittsburgh, Pennsylvania*

The patients ranged in age from 11 months to 77 years. Fourteen of the 150 patients were infants or children ranging in age from 11 months to 16 years. Twelve of the 14 had malignant diseases. Sex distribution in patients with malignant diseases was equal, both with primary and metastatic neoplasms. For adenomas and focal nodular hyperplasias, female predominance was observed.

The number of liver resections has increased sharply through the years (Table 1). During the last 12 months, 42 liver resections were performed at the University Health Center of Pittsburgh. Indications for liver resections are listed in Table 2. Eighty-six patients had malignant diseases of which 43 were primary to the liver. The liver tumors in the 43 patients with resectable metastatic neoplasms were of various origins (Table 2). The 64 patients with benign liver diseases underwent liver resections for therapeutic purposes or because malignancy was suspected.

The patients with benign disease often had acute and life-threatening complications, including the three with hepatic trauma. Three patients with cavernous hemangioma had spontaneous hemorrhage, and two more had emergency resection for bleeding after unwise needle biopsies. Five of the patients with adenomas had resections after the tumors had ruptured. Four patients classified in the benign group had multiple adenomatosis in all segments of the liver with massive hepatomegaly; complications, singly or in combination, included pain, disabling pressure symptoms, or hemorrhage. One year after resection one of these four patients required liver

TABLE 1. Incidence of Liver Resection by Five-Year Period and Indication

	Number of Liver Resections	Indications	
		Malignant Diseases	Benign Diseases
1964-1970	6	2	4
1971-1975	25	16	9
1976-1980	78	45	33
1981-	41	23	18
Total	150	86	64

transplantation when the remaining left lateral segment refilled with rapidly growing adenomas. One patient with polycystic disease was treated with right trisegmentectomy because of debilitating pressure symptoms that had necessitated intravenous hyperalimentation for six weeks.

TABLE 2. Indications for 150 Liver Resections

Malignant Diseases		
Primary malignant neoplasms		<u>43 cases</u>
Hepatoma		29
Squamous cell carcinoma of cyst wall		3
Hepatoblastoma		2
Cholangiocarcinoma		2
Rhabdomyosarcoma		2
Leiomyosarcoma		1
Angiosarcoma		1
Sarcoma, undetermined cell type		1
Cholangiocarcinoma of bile duct		1
Adenocarcinoma of gall bladder		1
Metastatic Neoplasms		<u>43 cases</u>
Colorectal adenocarcinoma		24
Carcinoid tumor		3
Adrenocortical carcinoma		3
Wilm's tumor		2
Adenocarcinoma of kidney		2
Spindle cell sarcoma of intestine		1
Leiomyosarcoma of stomach		1
Glucagonoma		1
Neuroblastoma of adrenal		1
Melanoma of eye		1
Hemangiosarcoma of breast		1
Medullary carcinoma of thyroid		1
Squamous cell carcinoma of endocervix		1
Ovarian carcinoma		1
Benign Diseases		<u>64 cases</u>
Hemangioma		32
Adenoma		14
Cysts:		7
simple	4	
polycystic	2	
Focal nodular hyperplasia		4
Trauma		3
Abscess		1
Fibroma		1
Leiomyoma		1
Regenerative nodule		1
Total		<u>150</u>

### Operative Procedures

The principles of anatomic liver resection have been described previously with emphasis on right trisegmentectomy<sup>1,2</sup> and left trisegmentectomy.<sup>5</sup> In most cases, a bilateral subcostal incision was used with an upper midline extension through which the xiphoid process was exercised. A thoracic extension was not made unless the need for additional exposure became evident after the lesion was assessed. Nonanatomical resections of the liver were classified as local excisions, even though some of these were extremely complex procedures. Diagnostic or therapeutic wedge resections were not considered hepatic resections.

Complete hemostasis was considered the most important factor in preventing postoperative complications. Bile leakage was carefully searched for. Intraoperative cholangiography was often used to identify the source of bile leak and duct kinking. A T-tube or U-tube was used to stent the repair of the bile ducts when these required major reconstruction. The surgical area drained with multiple Penrose drains or with closed suction drainage catheters.

The anatomic resections used (Table 3) were right lobectomy, left lobectomy, left lateral segmentectomy, right trisegmentectomy, and left trisegmentectomy. The right trisegmentectomy involved removal of the true right lobe and the median segment of the left lobe.<sup>1,2</sup> Left trisegmentectomy meant removal of the true left lobe plus the anterior segment of the right lobe.<sup>5</sup> The fact that 68 of the 150 resections were right or left trisegmentectomies reflected the highly screened nature of the case material. Many of the patients were referred by surgeons who had determined at a preliminary operation that an unusually extensive procedure would be necessary.

Six of the right hepatic trisegmentectomies for metastases and one right lobectomy were performed at the same time as resection of the primary tumor. In six of the seven patients, the primary neoplasm was in the right adrenal gland (four examples) or right kidney (two examples), necessitating adrenalectomy in continuity in all six and right nephrectomy in four. The seventh patient had a discontinuous right colectomy for adenocarcinoma of the cecum.

Each variety of the anatomical resections was used for at least one patient with benign disease. There were 18 examples of right lobectomy for benign disease. Right trisegmentectomy was used 14 times to remove a non-malignant lesion (Table 3).

### Adjuvant Therapy

When used, adjuvant therapy was begun after recovery from the surgical procedure seemed assured, one to several weeks after operation. Twenty-eight of the 43

patients with primary hepatic malignancy were given chemotherapy, and five received local irradiation. Twenty-two of the 43 patients with metastatic liver tumors were given chemotherapy, and six received local irradiation. The remaining patients did not receive adjuvant therapy either because they declined such treatment or because they were considered too frail. Some who are still early postoperative may become candidates for later chemotherapy.

The most common treatment for primary liver malignancy<sup>2</sup> was 5-fluorouracil, cyclophosphamide and vincristine, which was followed by adriamycin, if necessary, for recurrences. In the last few years these four drugs have been administered simultaneously rather than holding adriamycin for recurrences. More recently the combination of mytomyacin and 5-fluorouracil has been administered in some patients. For colorectal metastases, 5-fluorouracil has been the most commonly used agent.

**Results**

*Operative Mortality*

Any death within 30 days after liver resection as well as any death during the initial hospitalization for liver resection, regardless of time, was counted as an operative mortality. There were six deaths among 150 liver resections, for an overall operative mortality of 4.0% (Table 3). Details of the mortality after various kinds of resection are given in Table 3. These are right lobectomy, 6.5%; left lobectomy, 0%; right trisegmentectomy, 6.3%; left trisegmentectomy, 0%; left lateral segmentectomy, 0%; local excision, 0%. The mortality after resection for benign and malignant disease, respectively, was two out of 64 (3.1%) and four out of 86 (4.7%).

The circumstances of the deaths are summarized in Table 4. The only patient in whom hepatic failure was not a factor was a 50-year-old man who died intraoperatively as the result of incorrect placement of a central venous catheter. Four of the six deaths were of patients who had pre-existing cirrhosis, and in one of these cases the performance of a resection for a huge and single hyperplastic nodule represented an error both in diagnosis and judgement. Two other patients who died (Cases 3 and 4 in Table 4) had a history of chronic alcoholism, although their livers were not grossly cirrhotic.

Six of the 150 patients who underwent hepatic resection had significant underlying cirrhosis. Three of these patients died from hepatic failure after operation, accounting for one half of the total operative mortality.

*Surgical Complications*

Three of the 150 patients required re-exploration for postoperative bleeding. The hemorrhage that was from

TABLE 3. Extent of Liver Resection, Its Indication and Operative Mortality (Total 150 Resections)

	Rt. Trisegmentectomy		Lt. Trisegmentectomy		Rt. Lobectomy		Lt. Lobectomy		Lt. Lateral Segmentectomy		Local Excision	
	No. of pts.	No. of operative deaths	No. of pts.	No. of operative deaths	No. of pts.	No. of operative deaths	No. of pts.	No. of operative deaths	No. of pts.	No. of operative deaths	No. of pts.	No. of operative deaths
<b>Malignant Diseases</b>	50	3	3	0	13	1	8	0	2	0	3	0
Primary	26	3	2	—	5	1	5	—	3	—	2	—
Metastatic	24	—	1	—	8	—	3	—	6	—	1	—
<b>Benign Diseases</b>	14	0	1	0	18	1	5	0	4	0	22	0
Hemangioma	5	—	1	—	8	—	1	—	3	—	14	—
Adenoma	6	—	—	—	6	—	1	—	—	—	1	—
Focal Nodular hyperplasia	1	—	—	—	—	—	—	—	1	—	2	—
Cysts	1	—	—	—	1	—	2	—	—	—	3	—
Trauma	—	—	—	—	2	—	1	—	—	—	0	—
Others	1	1	—	—	1	1	—	—	—	—	2	—
<b>Total</b>	<b>64</b>	<b>4 (6.3%)</b>	<b>4</b>	<b>0</b>	<b>31</b>	<b>2 (6.5%)</b>	<b>13</b>	<b>0</b>	<b>13</b>	<b>0</b>	<b>25</b>	<b>0</b>

Operative death defines as any death within 30 days as well as any death during the initial hospitalization for liver resection regardless of time.

TABLE 4. Time and Cause of Operative Mortality

Case	Original diagnosis	Final Diagnosis	Procedure	Time of survival (days)	Cause of Death
1	Hepatoma*	Same	RTS	20	Hepatic failure; thrombosis coeliac axis
2	Hepatoma in cirrhotic (thorotrast) liver	Same	RTS	58	Hepatic failure; pulmonary metastases
3	Infected hepatoma	Fungal and bacterial abscess; thrombosis intrahepatic portal and hepatic veins	RTS	32	Hepatic failure; stress ulcer hemorrhage
4	Hepatoma	Same	RTS	45	Hepatic failure; stress ulcer hemorrhage
5	Hepatoma in cirrhotic liver	Same	RL	0	Unrecognized perforation of central venous catheter into mediastinum; hypovolemia and mediastinal tamponade.
6	Ruptured hepatoma in cirrhotic liver	Giant regenerative nodule in cirrhotic liver	RT	4	Hepatic failure

\* Case previously reported.<sup>2</sup> A reversed vena caval graft had been used to drain residual lateral segment after remaining left hepatic vein had been resected.

RTS: right trisegmentectomy.  
RL: right lobectomy.

the raw liver surface was controlled, but the patient whose resection was for a giant hyperplastic nodule died subsequently of hepatic insufficiency. Twelve patients had abscesses form in the right subphrenic space. In six instances the pus collections were drained by reopening anterior drain tracts that had closed prematurely at or near the body wall. Six abscesses were drained posteriorly by removing the right twelfth rib. In six other patients, posterior drainage procedures were carried out in the early postoperative period because of difficulty in effectively irrigating deeply placed cavities from the anterior approach. The complications occurred almost uniformly after right trisegmentectomy.

Major bile leaks occurred after two right and two left trisegmentectomies. In each instance a portion of the bile duct to the residual segment had been involved with tumor and had been resected. The bile ducts had been reconstructed over a T-tube or U-tube stents. In each instance, the bile leaks ceased spontaneously without further operative intervention. Minor bile leaks through the drain site were seen commonly, but these all closed spontaneously within a few days. One patient each had bile duct obstruction several months after right trisegmentectomy and left lobectomy. The etiology was recurrent tumor. In the patients with left lobectomy, the obstruction was distal and was relieved by anastomosing the uninvolved proximal common duct to a Roux-en-Y jejunal loop.

Two patients had major gastrointestinal hemorrhage after right trisegmentectomy, and both died (Table 4).

Another patient developed small bowel obstruction two weeks after right hepatic lobectomy. The problem was rectified by lysis of the responsible adhesions.

#### Long-term Follow-up

The 62 patients with benign disease who survived operation were alive in May 1982. With one exception none had developed late complications. The exceptional patient was the one who developed hepatic adenomatosis in the residual lateral segment after right trisegmentectomy. She was treated with orthotopic liver transplantation after which she promptly recovered.

The actuarial survival of patients with hepatic malignancies is shown graphically in Figures 1 and 2. Standard errors became greater than 10% after three years. The 3-year actuarial survival in patients with primary hepatic malignancy was 56% and with metastatic liver neoplasms, the survival was 66%. The survival up to five years was not statistically significant between those with primary and metastatic liver neoplasms, nor were there significant differences in the subgroups of either of these two major categories. Actuarial survival five years after liver resection for primary hepatic tumors was 46% and for metastatic neoplasms, it was 57%.

#### Discussion

The low mortality and morbidity after liver resection in these 150 cases have made the authors willing to attempt such operations in increasing numbers of patients

with benign and malignant hepatic lesions. The death rate of 4% within the first 30 days or at any time during the hospitalization has compared favorably with that in other large series listed in Table 5.<sup>7-24</sup> Most of the deaths in this series were of patients with pre-existing cirrhosis and/or a history of chronic alcoholism, and in all but one case hepatic insufficiency was responsible for the fatal evolution. Because the surgical principles of hepatic resection are so well standardized,<sup>1,2,5</sup> skillful anesthetic management has become the single most important factor in maintaining an acceptable operative mortality. Gifted anesthesiologists at two institutions have been able over a period of 17 years to cope with the acute blood loss and the intraoperative metabolic and cardiovascular instability that was often seen at the time of parenchymal transection.

In the long history of liver resection, two principal causes of perioperative death have been hemorrhage and infection. Postoperative hemorrhage requiring reoperation was reduced to 2% in this series. However, subphrenic or subhepatic abscesses required operative relief in 12 (8%) of the patients, of whom nine and three, respectively, had right trisegmentectomy and right lobectomy. This complication was not surprising in view of the large right subphrenic dead space created by major right hepatic resections. Previously, the authors recommended broad open drainage of this space at the time of resection usually by leaving open a part of the incision.<sup>1</sup> More recently, closed drainage techniques have been used. The incidence of the infections has been about the same with both methods. The recognition and localization of the abscesses has been greatly simplified by ultrasonography and computerized axial tomography. Secondary drainage by an anterior or posterior approach, or by both with a through and through communication was always successful.

The fact that all but one of the surviving patients with benign disease were cured of their problems was to be expected and was consonant with the numerous reports in the literature. However, the true value of major hepatic resection for primary or metastatic liver disease often has been questioned. Long-term survival data have been given in only a handful of reports (Table 5).

The best data have been for primary hepatic malignancies. In Foster's collection 296 patients with primary liver cancer from the pre-1970 literature, the 2- and 5-year determinant survival rates were 33.3% and 14% overall, but they were 59% and 36% for nonAsian, and 23% and 6% in Asian patients.<sup>7</sup> There were four large Asian series reported in English literature since Foster's review in 1970. Lin from Taiwan reported 3-year and 5-year actual survival of 20% and 19% in 1976.<sup>10</sup> Lee, Wong, and Ong from Hong Kong reported one- and three-year actuarial survival, respectively, of 45% and

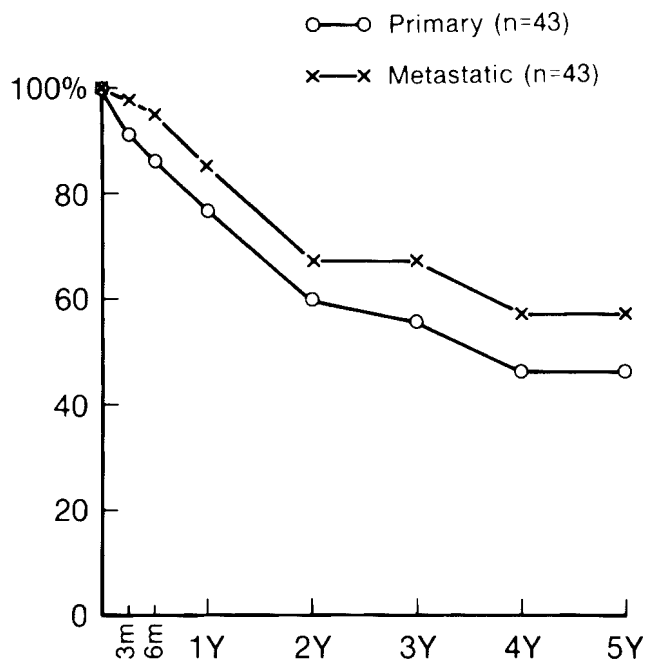


FIG. 1. Actuarial survival after liver resection. Comparison between primary liver malignancies and metastatic liver tumors. There are no statistically significant differences between the two at any point of time.

20%.<sup>11</sup> Balasegaram and Joishy from Malaysia reported a possible survival of 58.5% and 43.6% at one and three years after liver resection;<sup>12,13</sup> however, survival rates

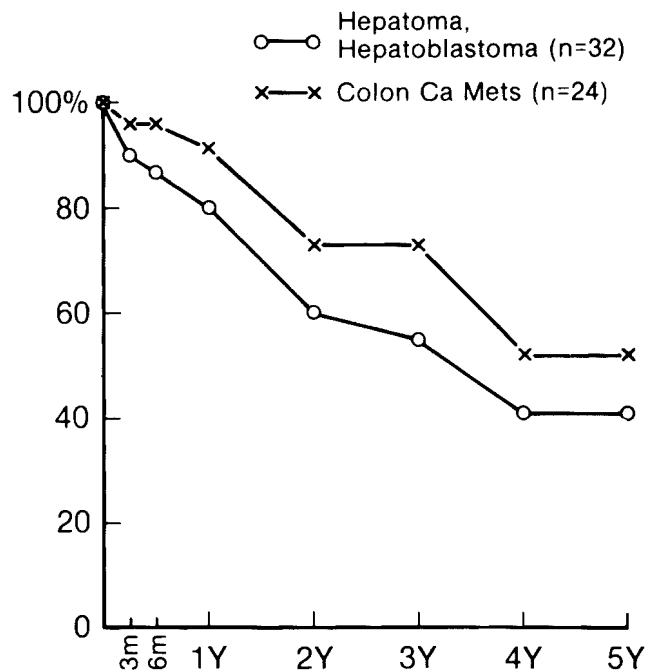


FIG. 2. Actuarial survival after liver resection. Comparison between hepatoma/hepatoblastoma and metastatic colorectal cancer. There are no statistically significant differences between the two at any point of time.

TABLE 5. Literature Survey of Operative Mortality and Long-term Survival After Liver Resection

Investigators	Indications	No. of Patients	Operative Mortality	Survival			
				1 y	2 y	3 y	5 y
Foster's review <sup>7</sup>	Primary liver cancer	296	24.0% (A)		33.3%		14.0%
		Asian	24.0% (A)		23.0%		6.0%
		Non-Asian	22.0% (A)		59.0%		36.0%
Foster's review <sup>8</sup>	Metastatic colorectal cancer	>400 192	11.0% (A)		44.0%		22.0%*
Lin <sup>9,10</sup>	Primary liver cancer	118	11.8% (B)	35.0%*	24.4%*	20.0%*	19.0%*
Lee et al. <sup>11</sup>	Primary liver cancer	165	20.0% (A)	45.0%†	30.0%†	20.0%†	20.0%†
Joishy & Balasegaram <sup>12,13</sup>	Malignant and benign all malignancy primary liver carcinoma	288	11.8% (A)				
		133	12.8% (A)				
		94	14.9% (A)				
Wu et al. <sup>14</sup>	Primary liver carcinoma	181	8.8% (B)	55.9%*	36.8%*	38.9%*	16.0%*
Almersjo et al. <sup>15</sup>	All malignancy	46	30.0% (B)		31.0%*		
Smith <sup>16</sup>	Primary liver malignancy	60	6.7% (D)		26.7%		
Bengmark et al. <sup>17,18</sup>	Primary malignancy colorectal cancer	21	14.3% (A)	47.6%	38.1%		
		32	6.3% (B)			20–25%†	
Longmire et al. <sup>19</sup>	Malignant and benign all malignancy primary liver malignancy	75	9.3% (C)				
		41	12.2% (C)				
		19	21.2% (C)				
Fortner et al. <sup>20,21</sup>	Malignant and benign all malignancy primary liver cancer colorectal cancer colorectal cancer	137	9.3% (B)				
		113	10.6% (B)				
		42	16.7% (B)	85.0%*†		50.0%*†	37.0%*†
		43	9.3% (B)	87.0%*†			
		25	8.0% (B)	88.0%*†	48.0%*†	48.0%*†	
Adson & Weiland <sup>22</sup>	Primary liver neoplasm primary liver malignancy	60	6.7% (B)			65.0%*†	36.0%*†
		46	4.3% (B)				
Wilson & Adson <sup>23</sup>	Colorectal cancer	60	1.7% (B)				28.0%*†
Adson & Van Heerden <sup>24</sup>	Colorectal cancer	34	5.9% (B)	82.0%*	58.0%*	41.0%*	
Present Study	Malignant and benign malignant tumors primary liver malignancy metastatic tumors metastatic colorectal	150	4.0% (A & B)				
		86	4.7% (A & B)				
		43	9.3% (A & B)	77.8%†	59.5%†	55.7%†	46.0%†
		43	0.0% (A & B)	85.3%†	66.7%†	66.7%†	57.2%†
		24	0.0% (A & B)	91.3%†	73.0%†	73.0%†	52.1%†

Definition of Operative Mortality: A = death in initial hospitalization, B = death in 30 days, C = death in 60 days, D = intraoperative death.

\* Operative death excluded.  
† Actuarial survival.

were not determinant since not all of their patients could be followed up. Wu et al. in Shanghai reported the largest series from a single institution in 1980.<sup>14</sup> Their one- to five-year actual survival rates were 55.9%, 36.8%, 28.9%, 21.8% and 16%, excluding an 8.8% operative mortality. Seventy per cent of their patients had cirrhotic livers. In Europe Almersjö, Bengmark, and Hafström reported two-year actual survival of 31%, excluding operative mortality of 30%,<sup>15</sup> and in 1979 Smith reported a 27% survival two years after resection.<sup>16</sup> In the United States

Fortner et al. reported one-, three-, and five-year actuarial survival of, respectively, 85%, 50%, and 37%, excluding the patients who died perioperatively. Since their operative mortality was 16.7%, the uncorrected one-, three- and five-year actuarial survival rate including perioperative deaths would have been approximately 71%, 42%, and 31%, respectively.<sup>20,21</sup> Adson and Weiland reported three- and five-year actuarial survival, respectively, of 65% and 36%, excluding operative deaths.<sup>22</sup> Our one- to five-year uncorrected actuarial survivals,

respectively, of 77.8%, 59.5%, 55.7%, 46%, and 46% for primary liver malignancy, support the commonly held view that liver resection is the treatment of choice for primary liver malignancy.

The results of liver resection for metastatic liver tumors also have been encouraging, particularly since such resections can be performed with minimum mortality. Foster reviewed more than 400 hospital records of patients with metastatic liver tumor from colorectal cancer and reported in 1978 two- and five-year determinant survival, respectively, of 44% and 22%, excluding the patients who died during the initial hospitalization.<sup>8</sup> Fortner et al. reported one-, two-, and three-year actuarial survival of 88%, 48%, and 48% excluding an operative mortality of 8%.<sup>20,21</sup> Wilson and Adson reported a five-year survival of 28% among 60 patients with liver metastasis from colorectal cancer, two thirds of whom were treated by wedge resection of the liver.<sup>23</sup> Later, Adson and Van Heerden reported one-, two-, and three-year actual survival, respectively, of 82%, 58%, and 44% among 34 patients who had major hepatic resections excluding operative deaths.<sup>24</sup> The authors have obtained one-, three-, and five-year actuarial survival, respectively, of 91.3%, 73%, and 52.1% in patients with metastatic colorectal cancer without any operative mortality. Although these survival figures seem to be higher than those of others, there is no statistically significant difference between them at present. If the higher survival figures hold for several more years, this may, at least partly, reflect the policy of extensive liver resections as opposed to local excision for metastatic tumors.

After resection of both primary and metastatic neoplasms, the question of adjuvant therapy remains open. Even with the development of more effective chemotherapy, liver resection when possible for both primary and secondary malignant tumors should continue to be an important component of care.

### References

1. Starzl TE, Bell RH, Beart RW, Putnum CW. Hepatic trisegmentectomy and other liver resections. *Surg Gynecol Obstet* 1975; 141:429-437.
2. Starzl TE, Koep LJ, Weil R III, et al. Right trisegmentectomy for hepatic neoplasms. *Surg Gynecol Obstet* 1980; 150:208-214.
3. Starzl TE, Koep LJ, Weil R III, et al. Excisional treatment of cavernous hemangioma of the liver. *Ann Surg* 1980; 192:25-27.
4. Starzl TE, Putnum CW, Groth CG, et al. Alopecia, ascites and incomplete regeneration after 85-95% liver resection. *Am J Surg* 1975; 129:587-590.
5. Starzl TE, Iwatsuki S, Shaw BW Jr, et al. Left hepatic trisegmentectomy. *Surg Gynecol Obstet* 1982 (in press).
6. Weil R III, Koep LJ, Starzl TE. Liver resection for hepatic adenoma. *Arch Surg* 1979; 114:178-180.
7. Foster JH. Survival after liver resection for cancer. *Cancer* 1970; 26:493-502.
8. Foster JH. Survival after liver resection for secondary tumors. *Am J Surg* 1978; 135:389-394.
9. Lin T. Results in 107 hepatic lobectomies with a preliminary report on the use of a clamp to reduce blood loss. *Ann Surg* 1973; 177:413-421.
10. Lin T. Recent advances in technique of hepatic lobectomy and results of surgical treatment for primary carcinoma of the liver. *Prog Liver Dis* 1976; 5:668-682.
11. Lee NW, Wong J, Ong GB. The surgical management of primary carcinoma of the liver. *World J Surg* 1982; 6:66-75.
12. Joishy SK, Balasegaram M. Hepatic resection for malignant tumors of the liver: essentials for a unified surgical approach. *Am J Surg* 1980; 139:360-369.
13. Balasegaram M, Joishy SK. Hepatic resection: pillars of success built on the foundation of 15 years of experience. *Am J Surg* 1981; 141:360-365.
14. Wu M, Chen H, Zhang K, et al. Primary hepatic carcinoma resection over 18 years. *Chinese Med J* 1980; 93:723-728.
15. Almersjo O, Bengmark S, Halfstrom L. Liver resection for cancer. *Acta Chir Scand* 1976; 142:139-144.
16. Smith R. Tumors of the liver. *Ann Royal Coll Surg Engl* 1979; 61:87-99.
17. Bengmark S, Halfstrom L, Jeppsson B, Sundquist K. Primary carcinoma of the liver: improvement in sight? *World J Surg* 1982; 6:54-60.
18. Bengmark S, Halfstrom L, Jeppsson B, et al. Metastatic disease in the liver from colorectal cancer: an appraisal of liver surgery. *World J Surg* 1982; 6:61-65.
19. Longmire WP Jr, Trout HH III, Greenfield J, Tompkins RK. Elective hepatic surgery. *Ann Surg* 1974; 179:712-721.
20. Fortner JG, Kim DK, Maclean BJ, et al. Major hepatic resections for neoplasia: personal experience in 108 patients. *Ann Surg* 1978; 188:363-371.
21. Fortner JG, Maclean BJ, Kim DK, et al. The seventies evolution in liver surgery for cancer. *Cancer* 1981; 47:2162-2166.
22. Adson MA, Weiland LH. Resection of primary solid hepatic tumors. *Am J Surg* 1981; 141:18-21.
23. Wilson SM, Adson MA. Surgical treatment of hepatic metastases from colorectal cancers. *Arch Surg* 1976; 111:330-334.
24. Adson MA, VanHeerden JA. Major hepatic resections for metastatic colorectal cancer. *Ann Surg* 1980; 191:576-583.