

EXPERIMENTAL CHAGAS' DISEASE IN RHESUS MONKEYS. I. CLINICAL, PARASITOLOGICAL, HEMATOLOGICAL AND ANATOMO-PATHOLOGICAL STUDIES IN THE ACUTE AND INDETERMINATE PHASE OF THE DISEASE

MARIA DA GLÓRIA BONECINI-ALMEIDA; BERNARDO GALVÃO-CASTRO/+;
MARIA HELEOSINA RIBEIRO PESSOA **; CLAUDE PIRMEZ & FRANCISCO LARANJA *

Instituto Oswaldo Cruz, Departamento de Imunologia (WHO Collaborating Center for Research and Training in Parasitic Diseases) *Hospital Evandro Chagas, Caixa Postal 926, 20001 Rio de Janeiro, RJ, Brasil
**Universidade do Estado do Rio de Janeiro, Serviço de Microbiologia e Imunologia, Rio de Janeiro, RJ, Brasil

Rhesus monkeys (Macaca mulatta) were infected subcutaneously with 1.0×10^4 to 1.5×10^4 metacyclic trypomastigotes of Trypanosoma cruzi (Colombian strain). Parasitological and immunological parameters were evaluated in these animals for periods of 1 month to over 3 years. A chagoma was observed between the 3rd and the 13th day after infection (a. i.) and patent parasitaemia between the 13th and 59th day a. i.. Thereafter, parasites were demonstrated only by haemoculture and/or xenodiagnosis. Circulating specific IgM and IgG antibodies were observed as early as in the 2nd week a. i. IgG levels persisted until the end of the experiment, but IgM antibodies were detectable nine months a. i. Haematological alterations comprised leucocytosis and lymphocytosis. Eletrocardiographic alterations were minor and transient, similar to those observed in non-lethal human acute Chagas' myocarditis. Myocarditis and myositis, characterized by multiple foci of lympho-histiocyte inflammatory infiltrate, were present in monkeys sacrificed on the 41th, 70th and 76th day but not in the animal sacrificed 3 years and 3 months a. i.. The results suggest that Chagas' disease in rhesus monkeys reproduces the acute and indeterminate phases of human Chagas' disease.

Key words: *Trypanosoma cruzi* – rhesus monkeys – experimental Chagas' disease

Chagas' disease (Chagas, 1909), can manifest itself in a variety of clinical and pathological forms. The acute phase is characterized by high parasitaemia, which usually subsides spontaneously. The indeterminate phase is characterized by an absence of clinical symptoms, sub-patent parasitaemia, and the infection may remain quiescent for many years or decades. A variable percentage of the patients may develop a progressive chronic form which is characterized by myocarditis and/or megaesophagus and/or megacolon.

The difficulty of studying all the aspects of the disease in human beings has led to the search for an adequate experimental model. Various animal species such as mice, dogs and rabbits have been proposed, but differences from human infection were always observed (WHO,

1984). On the other hand, monkeys seem to be a suitable model for the reproduction of human disease (Muniz et al., 1970; Seah et al., 1974; Marsden et al., 1976; Pung et al., 1988 a, b). However, only one kinetic study in *Cebus apella* monkeys has been carried out up to date (Rosner et al., 1988, 1989). The present study was thus performed in order to investigate the kinetics of the acute and indeterminate forms of Chagas' disease in rhesus monkeys.

MATERIALS AND METHODS

Animals: fifteen male *Macaca mulatta*, 4.4 to 10 years old, with 70 to 77 cm of height weighing from 7.2 to 14.3 kg, were purchased from Primatology Center of the Oswaldo Cruz Foundation, Rio de Janeiro, Brasil (Table). The monkeys were maintained under quarantine for 6 months.

Serological tests for Chagas' disease and the PPD skin test (50IU) were negative and no alteration in electrocardiogram (ECG), chest X rays, haematologic analysis and plasma protein concentrations were observed during this period.

This work was partially supported by TDR/OMS T16/181/8B.

+ Corresponding author.

Received September 13, 1989

Accepted May 15, 1990.

TABLE
Experimental Chagas' disease in rhesus monkeys: general data

Monkeys' identification	Age (years)	Body weight (kg)	Inoculum (<i>T. cruzi</i> /kg x 10 ³)	Duration of parasitaemia ^a (days after infection)
1	7.0	10.4	1.4	22-53
2 ^b	10.0	13.3	1.1	20-41
3	6.0	8.7	1.1	17-59
4 ^c	6.0	7.9	1.3	17-59
5	6.0	12.0	1.2	22-37
6 ^b	10.0	14.3	1.0	16-41
7	10.0	12.2	1.2	15-37
8 ^d	4.4	7.2	2.1	13-55
9	5.5	9.0	1.7	18-55
10 ^e	4.4	11.0	1.4	18-53
11	4.5	9.9	1.5	18-55
12	4.6	7.9	1.9	13-55
13	4.5	8.7	1.7	13-55

- a) as detected by direct observation in optical microscopy
 b) sacrificed 41 days after infection (a. i.)
 c) sacrificed 3 years a. i.
 d) sacrificed 70 days a. i.
 e) sacrificed 76 days a. i.

Trypanosoma cruzi and experimental infection: stabilates of blood trypomastigotes of the *T. cruzi* Colombian strain (Federici et al., 1964) were used to infect mice. *Triatoma infestans* were fed on these mice and metacyclic trypomastigotes were obtained from bug urine 30 days afterwards (Lugo, 1973; Zeledon et al., 1979). This process yielded a 98% pure metacyclic trypomastigote preparation, which was used to inoculate 13 monkeys subcutaneously in the antero-lateral face of the arm (1.0×10^4 to 1.5×10^4 trypomastigotes/monkey). The inoculum size/body weight ratios are shown in the Table. Urine from uninfected bugs was injected in the opposite arm as a control. Two monkeys were maintained non-infected as environmental controls and were simultaneously analyzed during the experiment. No significant alterations were detected on these animals with respect to the different tests performed.

Blood samples: blood samples were collected weekly until the 2nd month a. i. and then monthly from the femoral vein. Serum samples were kept at -70°C until use.

All manipulations were done under anesthesia using 10 mg/kg body weight of ketamine chloride (ketalar) and 0.1 ml of a 2% solution of 2-(2,6 xylidino) 5,6 dihydro 4H-13 thiazine (Rompum) intramuscularly.

Parasitaemia: it was measured using the technique described by Hoff (1974). In 3 monkeys (numbers 1, 5 and 6) the quantification of parasite was not done.

Hemoculture: 1.0 ml of blood was added to 6.0 ml of culture medium (BHI – brain heart infusion and LIT – liver infusion tryptose); these cultures were observed weekly during 2 months.

Xenodiagnosis: forty 4th stage nymphs of *Triatoma infestans* were allowed to feed on each monkey; 30 or 60 days after exposure the bugs were dissected and their gut contents microscopically examined (Cerisola et al., 1971).

Electrocardiographic studies: the records were obtained with a direct writing 3 channel Fukuda electrocardiograph (FP31P model) with subcutaneous needles as electrodes. Six extremity leads and 3 or 6 precordial leads were used with the previously anesthetized animal in a dorsal recumbent position. Pre-infection control records were made in every animal. Serial tracings were made at variable intervals a. i., so that a minimum of 8 and maximum of 207 records were obtained from each animal.

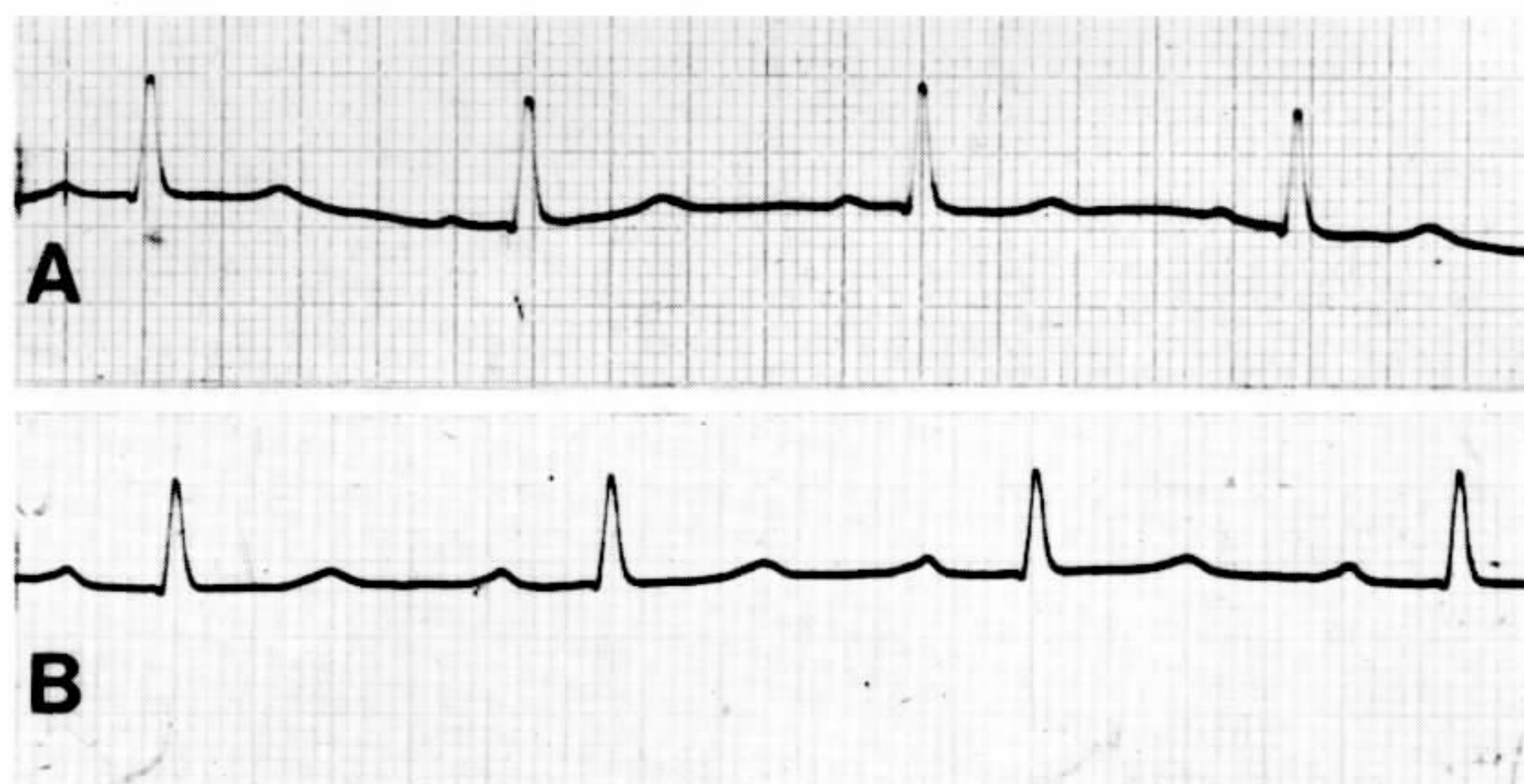


Fig. 1: ECG registred A) before inoculation with *Trypanosoma cruzi* showing normal pattern and B) five weeks after infection showing a first degree atrioventricular block.

Detection of antibodies against T. cruzi and EVI: circulating anti-*Trypanosoma* antibodies were detected by indirect immunofluorescence (IIF) (Camargo & Amato Neto, 1974), using specific fluorescent anti-human IgM and IgG (Cappel Laboratories, USA) and by direct agglutination (DA) using 2-mercaptoethanol (2-ME) treated and non-treated sera (Vattuone & Yvanovsky, 1971). A complement-mediated trypanolytic assay (CoML) was carried out in accordance with the methodology described by Krettli (1982) modified by Romeiro et al. (1984). Antibodies against normal endocardium, blood vessels and interstitium (EVI) were detected as described elsewhere (Cossio et al., 1974).

Anatomo-pathological studies: five animals were sacrificed under anesthesia on the 41st (2 animals), 70th (1 animal) and 76th (1 animal) days a. i. and in 3 years and 3 months a. i. (1 animal) (Table). Samples of each organ were taken and fixed in 10% buffered formalin, paraffin-embedded and stained with haematoxylin-eosin.

Statistical analysis: the Student's t test, corrected for population of unequal variance, was employed.

RESULTS

Clinical aspects and electrocardiographic alterations: during the 1st 3 weeks of infection monkeys were apathetic, with loss of appetite and small loss of weight (mean loss of 6%). In

3 monkeys there was also a small increase in body temperature (of about 1 °C). A chagoma was observed in 9 out of the 13 infected monkeys between the 3rd and 13th day a. i. and disappeared in the majority (7 out of 9) of the animals before the 18th day a. i.. In the other 2 animals the chagoma disappeared on the 20th and 26th day a. i.. The lesion were characterized by an erythema which evolved to a papula. Axillar lymph-nodes were enlarged in all animals. No reaction was observed when only urine from uninfected bugs was injected as control.

ECG disclosed myocardial damage in 9 out of 13 infected monkeys. The abnormalities in all cases were mild and represented by slight degree of auriculo-ventricular conduction disturbance (88.3%), an abnormality of T wave repolarization (77.8%), a decrease in QRS voltage (33.3%) or right bundle branch incomplete block (22.2%). These abnormalities were transient and disappeared at the beginning of the 4th month (Fig. 1).

Parasitaemia and haematological alterations: parasites were detected in the circulating blood between the 13th and 22th days by direct examination (Table). Parasitaemia reached maximum levels between days 27 and 38, being no longer detectable by direct examination after day 59 (Fig. 2). However, the presence of *T. cruzi* in the circulating blood could be demonstrated after that day by hemoculture and/or xenodiagnosis in all animals, in some cases even after 3 years of infection (monkey 4).

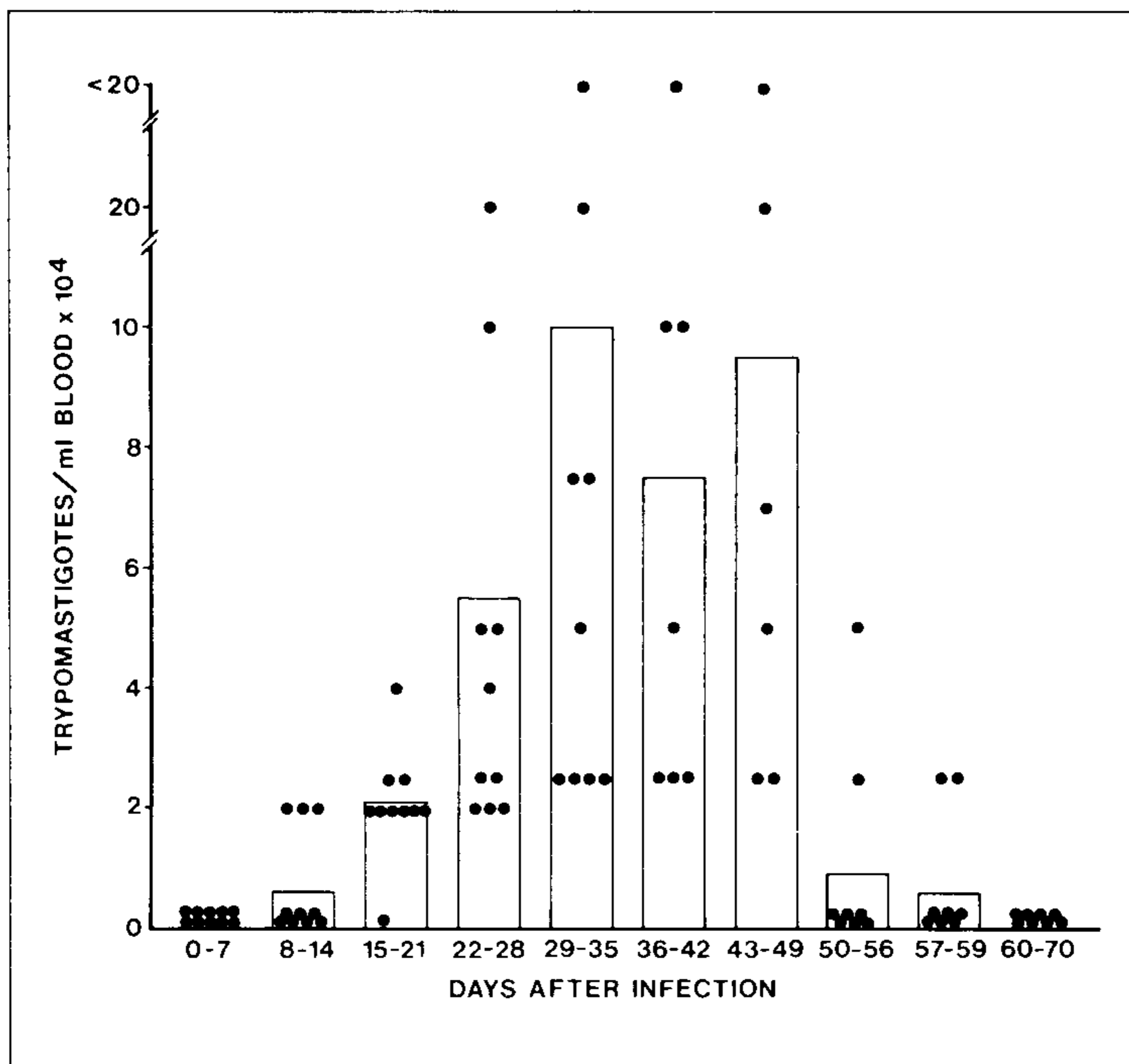


Fig. 2: *Trypanosoma cruzi* parasitaemia in infected rhesus monkeys. Columns represent the mean parasitaemia in each period of time and circles represents individual parasitaemia.

During the acute phase all the monkeys showed a small, but not statistically significant decrease in erythrocyte numbers and haemoglobin levels. Significantly increased numbers of leucocytes and lymphocytes were observed from the 5th week to the 3rd month and 20 days a. i. ($p > 0,05$) reaching maximum numbers in 3 months and 20 days a. i. (Fig. 3). There was a slight increase of monocytes, not statistically significant.

Specific humoral immune response and EVI antibodies: circulating anti-*T. cruzi* antibodies profiles are shown in Fig. 4. Specific IgM and IgG antibodies were first observed by IIF since the 2nd week in 1 out 13 animals and 2 out of

13, respectively. In the 3rd week IgG antibodies were detected in all animals but IgM antibodies were observed in only 8 out of 13 animals. IgM antibodies were present in all animals at the 4th week. However, while these antibodies were no longer detected after the 9th month, the IgG antibodies remained at high levels during all the course of the experiment. Specific antibodies were also detected by agglutination with and without treatment with 2-ME, producing profiles similar of those observed with IIF. Specific lytic antibodies were first detected at the 3rd week, and remained detectable until the end of the experiment in low titers. EVI antibodies were found from the 4th week onwards (with titers ranging from 1:80 to 1:1280).

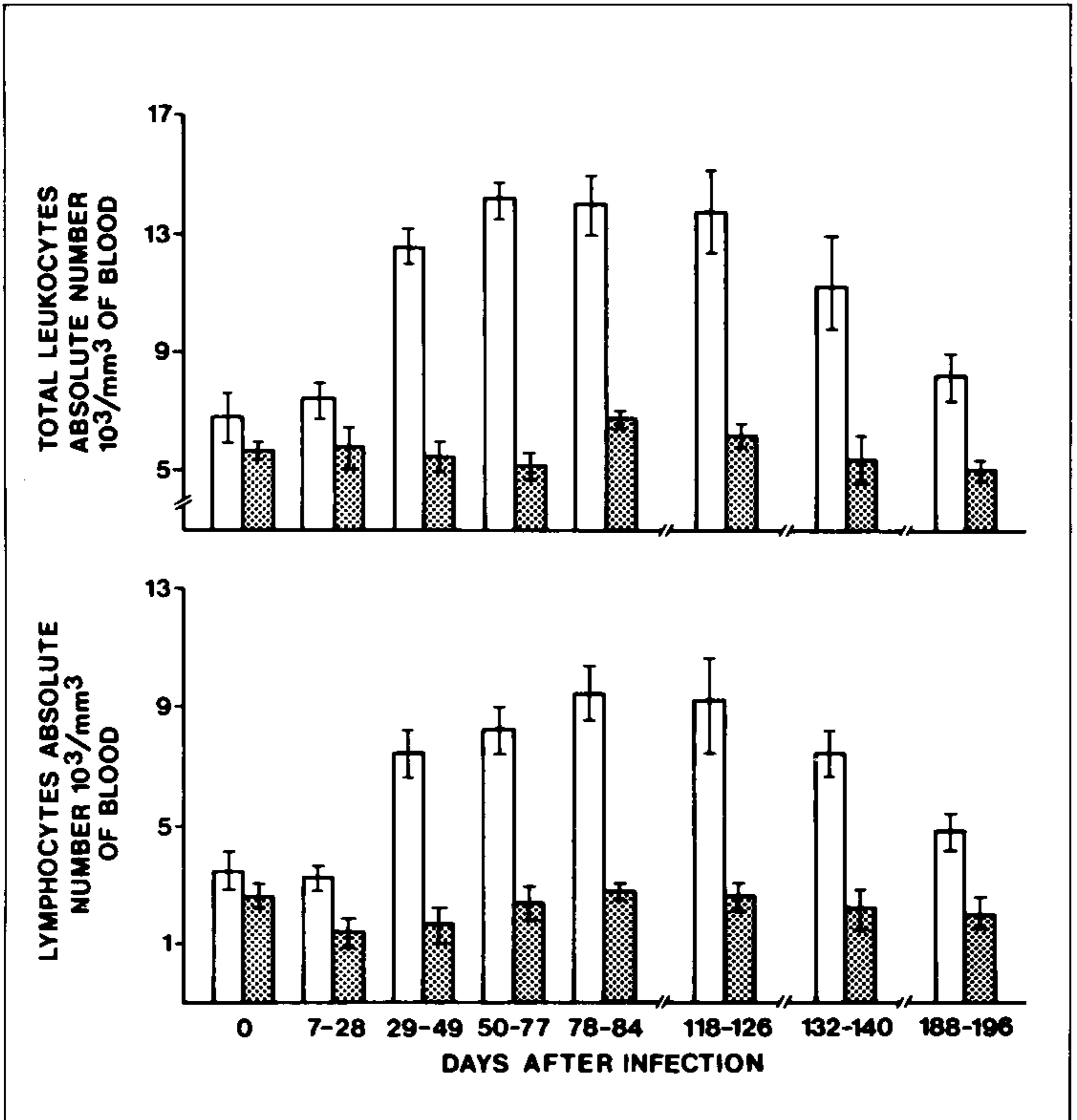


Fig. 3: numbers of leucocytes and lymphocytes in *Trypanosoma cruzi*-infected rhesus monkeys. Open columns represent the mean \pm standard deviation of a minimum of six animals, and hatched columns represent the mean \pm standard deviation of two uninfected animals.

Anatomo-pathological studies: lesions were detected mainly in muscular tissues. Myocarditis and myositis were present in 4 out of 5 of the sacrificed animals, being characterized by multiple foci of lympho-histiocyte inflammatory infiltrate, occasionally associated with fiber destruction (Fig. 5). The inflammatory infiltrate was also found in the muscle layer of the

esophagus, with destruction of muscle fibers and nervous plexuses. Inflammatory reactions were more conspicuous in monkeys which were sacrificed on the 41th and 70th days. Parasitism was more intense in these animals than in those examined later on. In fact, no gross or microscopical alteration was found in the monkey sacrificed 3 years and 3 months a. i..

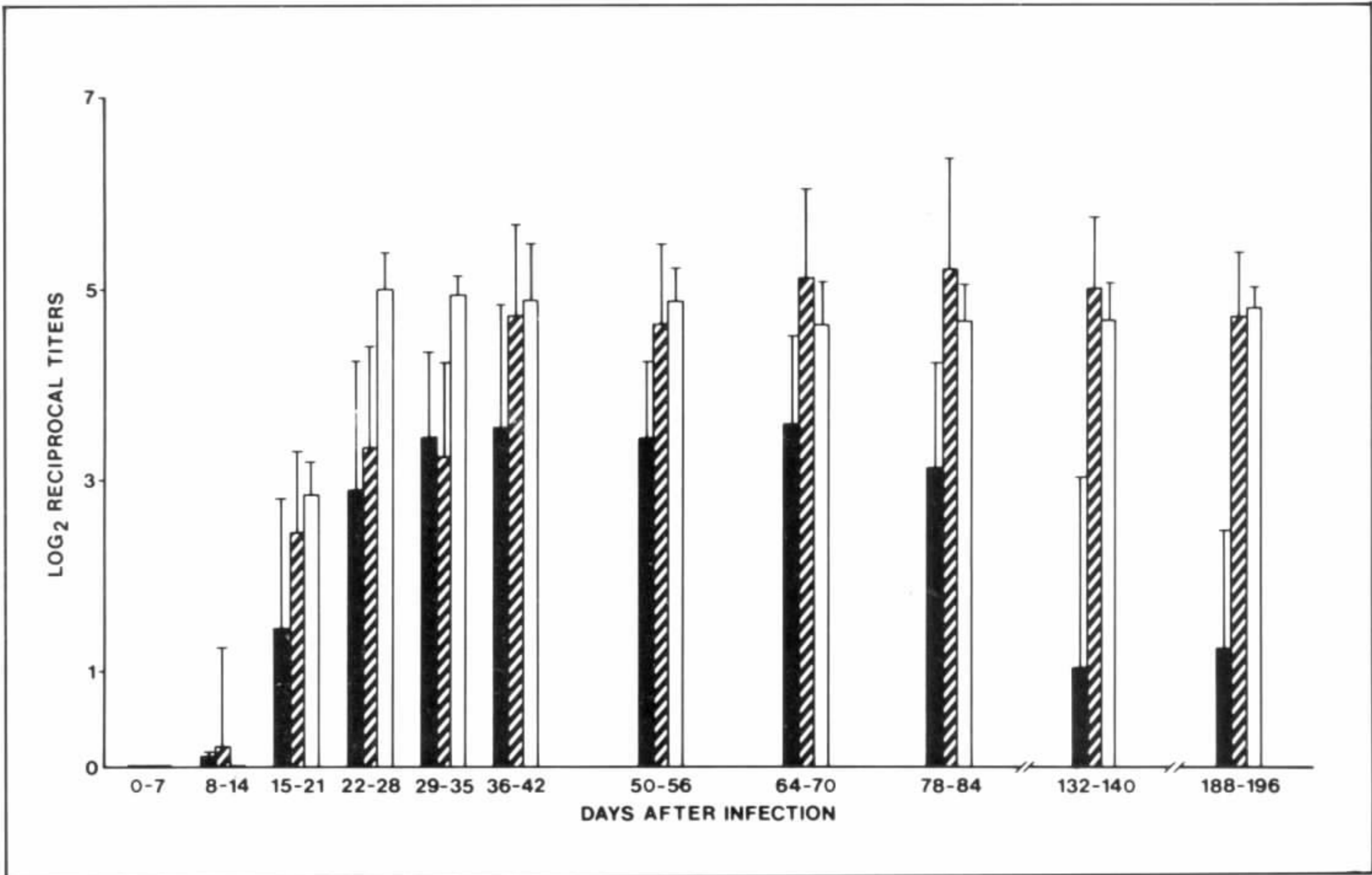


Fig. 4: specific humoral immune response of *Trypanosoma cruzi*-infected rhesus monkeys. Each column represents the mean \pm standard deviation of specific antibody titers detected by immunofluorescence (\blacksquare IgM-IIF / \square IgG-IIF) and \square complement-mediated trypanolytic assay (CoML).

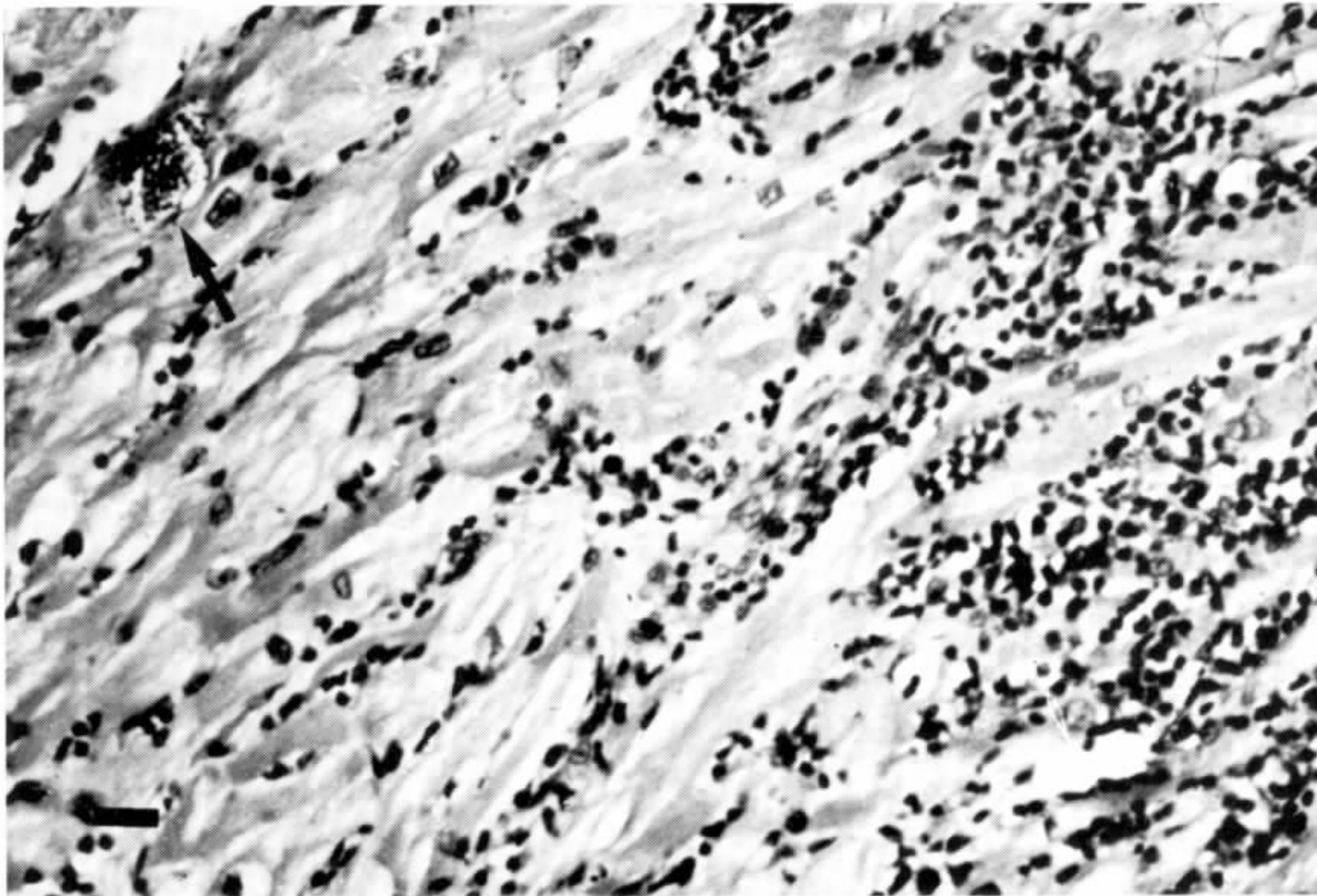


Fig. 5: acute *Trypanosoma cruzi* myocarditis in a monkey 5 weeks after infection. The cellular infiltrate is composed of lymphocytes and macrophages. Arrow indicates nest of amastigotes in muscle fiber. The bar is 10 μ m long.

DISCUSSION

The present data support previous reports that rhesus monkeys experimentally infected with *T. cruzi* reproduce at least the acute and indeterminate phases of human Chagas' disease. Indeed the haematological, electrocardiographic and histopathological pictures observed in the monkeys studied herein are similar to those reported in human cases of Chagas' disease (Dias, 1912; Mazza & Freire, 1940; Laranja et al., 1949, 1956; Muniz et al., 1970, Seah et al., 1974; Marsden et al., 1976; Miles et al., 1979; OPAS, 1982; Baruffa & Alcantara Filho, 1983).

Although there were individual age and weight variations within the monkeys studied in this work, these variations did not seem to constitute critical factors affecting host-parasite relationship as judged from the parameters studied herein, in as much as there was an homogeneous behaviour of the monkeys in terms of disease progression.

The kinetic study of specific antibodies synthesis was also shown to be similar to that reported for human disease (Krettli, 1982). However, specific IgM was detected for a longer period of time than that usually observed in the acute phase of human disease. The presence of *T. cruzi*-specific IgM could be indicative of recent infection and assays for its detection would therefore be useful as an epidemiological tool as suggested previously (Camargo & Amato Neto, 1974; Schmunis et al., 1980; Amato Neto et al., 1984).

Despite the existence of circulating lytic antibodies in all animals, even in that one monkey with more than 3 years of infection in which no histopathological alterations were observed, parasitaemia was concomitantly detected by xenodiagnosis and/or haemoculture, suggesting the existence of mechanism(s) by which the parasite escapes the lysis *in vivo*. This finding is in accordance with data on human disease in which the detection of lytic antibodies is associated with the presence of the parasite (Krettli, 1982).

Previous studies indicate that there is a great variation in histopathological and electrocardiographic findings in different species of monkeys infected with *T. cruzi* (WHO, 1984). These differences may be attributed to several

factors. Firstly, it can reflect differences in *T. cruzi* strains and routes of inoculation. Indeed, murine models display histopathological differences when different strains or clones of *T. cruzi* are employed (Andrade, 1974; Postan et al., 1983). On the other hand, studies conducted in rhesus monkey inoculated by different routes showed similar infections as well as similar histopathological findings (Seah et al., 1974; Marsden et al., 1976). Secondly, it may be related to differences in the species of monkeys employed. To clarify this point it would be necessary to perform experiments using different species of monkeys inoculated with the same strain/clone of *T. cruzi*.

Intense inflammatory lesions occur in both acute and chronic phases of Chagas' disease affecting several organs, specially muscle and nervous tissues. The histopathological findings observed in the infected animals agree closely with what has been described in humans (Andrade & Andrade, 1979). Biopsy of the chagoma lesion showed a chronic inflammation which tended to organize a granuloma, as already observed in human chagomas (Mazza et al., 1940; Galvão-Castro et al., 1981; Meirelles et al., 1990). Acute *T. cruzi* meningoencephalitis in the human is usually fatal but of rare occurrence and, so, the degree of central nervous system involvement is not known yet. No anatomopathological alterations related to Chagas' disease in this area was detected.

The pathogenesis of Chagas' disease is still poorly understood but multiple mechanisms may be involved in the passage from the indeterminate to the chronic phase. Since the experimental Chagas' disease in rhesus monkeys seems to reproduce the acute and indeterminate phases of the disease, this model could be useful in solving the intricate puzzle of Chagas' disease pathogenesis, and also in studies in which the induction or acceleration of the development of chronic Chagas' disease could be tried.

ACKNOWLEDGEMENTS

To the Laboratory Dr Bras Miollino for the haematological analysis, Mr Heloisa M. N. Diniz for the photographic work, Mrs Raimunda T. Melo for technical assistance and Dr Lain Ponte de Carvalho for reviewing this manuscript.

REFERENCES

- AMATO-NETO, V.; NAGASSE, T. K.; MOREIRA, A. A. B.; GOMES, A. E. C. & CAMPOS, R., 1984. Utilização, em politransfundidos, da pesquisa de anticorpos IgM anti-*Trypanosoma cruzi* e anti-*Toxoplasma gondii* para detectar infecções pós transfusionais recentes. *Rev. Inst. Med. Trop. São Paulo*, 26: 83-86.
- ANDRADE, S. G., 1974. Caracterização de cepas do *Trypanosoma cruzi* no Recôncavo baiano. Contribuição ao estudo da patogenia geral da doença de Chagas em nosso meio. *Rev. Pat. Trop.*, 3: 65-121.
- ANDRADE, Z. A. & ANDRADE, S. G., 1979. Patologia, p. 199-248. In: Z. Brener & Z. A. Andrade, (ed.) *Trypanosoma cruzi e doença de Chagas*. Guanabara Koogan, Rio de Janeiro.
- BARUFFA, G. & ALCANTARA-FILHO, A., 1983. Forma aguda da doença de Chagas no Rio Grande do Sul - Aspectos Laboratoriais. *Rev. Goiana Med.*, 29: 9-15.
- CAMARGO, M. E. & AMATO-NETO, V., 1974. Anti-*Trypanosoma cruzi* IgM antibodies as serological evidence of recent infection. *Rev. Inst. Med. Trop. São Paulo*, 16: 200-202.
- CERISOLA, J. A.; ROHEDDER, R. & PRADO, C. E., 1971. Rendimiento del xenodiagnostico en la infección chagásica humana utilizando ninfas de diferentes especies de triatomíneos. *N. Chile Parasitol.*, 26: 57.
- CHAGAS, C., 1909. Nova Trypanosomiase humana. Estudos sobre a morfologia e o ciclo do *Schizopypanum cruzi*, n. gen., n. sp. agente etiológico de uma nova entidade morbida do homem. *Mem. Inst. Oswaldo Cruz*, 1: 158-218.
- COSSIO, P. M.; DIEZ, C.; SZARFMANN, A.; KREUTZER, E.; CANDIOLO, B. & ARANA, R. M., 1974. Chagasic cardiopathy. Demonstration of a serum gamma globulin factor with reacts with endocardium and vascular structures. *Circulation*, 49: 13-21.
- DIAS, E., 1912. Moléstia de Carlos Chagas. Estudos hematológicos. *Mem. Inst. Oswaldo Cruz*, 4: 34-61.
- FEDERICI, E. E.; ABELMANN, W. H. & NEVA, F. A., 1964. Chronic and progressive myocarditis and myositis in C3H mice infected with *Trypanosoma cruzi*. *Am. J. Trop. Med. Hyg.*, 13: 272-280.
- GALVÃO-CASTRO, B.; GRIMALDI, G. JR; de OLIVEIRA-NETO, M. P. & DEANE, L. M., 1981. *Trypanosoma cruzi* em *Macaca mulatta* Estudo morfológico da infecção ao nível da porta de entrada. XI Reunião Anual em Pesquisa Básica em Doença de Chagas, Caxambu, MG, Brasil, p. 53.
- HOFF, R., 1974. A method for counting and concentrating living *Trypanosoma cruzi* in blood lysed with ammonium chloride. *J. Parasitol.*, 60: 527-528.
- KRETTLI, A. U., 1982. Antibodies to *Trypanosoma cruzi* in experimental and human infections. *Afr. Clin. Exp. Immunol.*, 3: 327-345.
- LARANJA, F. S.; DIAS, E. & NOBREGA, G., 1949. Clínica e terapêutica da doença de Chagas. *Mem. Inst. Oswaldo Cruz*, 46: 473-529.
- LARANJA, F. S.; DIAS, E.; NOBREGA, G. & MIRANDA, A., 1956. Chagas' Disease. A clinical, epidemiologic and pathologic study. *Circulation*, 15: 1035-1059.
- LUGO, A., 1973. Influencia de la ruta de inoculation de tripomastigotas de *Trypanosoma cruzi* sobre el desarrollo de la parasitemia em ratones albinos y alopecicos. Curso de Post-gradado de Parasitemia. Enfermedad de Chagas. Merida, Venezuela: Talleres graficos Universitarias, Universidad de Los Andes.
- MARSDEN, P. D.; SEACH, S. K. K.; DRAPER, C. C.; PETITT, L. E.; MILLES, M. A. & VOLLER, A., 1976. Experimental *Trypanosoma cruzi* infection in Rhesus monkeys. II. The early chronic phase. *Trans. R. Soc. Trop. Med. Hyg.*, 70: 247-251.
- MAZZA, S. & FREIRE, R. S., 1940. Manifestaciones cutaneas de inoculacion metastaticas y hematogenas en enfermedad de Chagas. *Public. MEPPRA*, 46: 3-38.
- MEIRELLES, M. N. L.; BONECINI-ALMEIDA, M. G.; PESSOA, M. H. R. & GALVÃO-CASTRO, B., 1990. *Trypanosoma cruzi*: Experimental Chagas' disease in rhesus monkeys II. Ultrastructural and Cytochemical studies of peroxidase and acid phosphatase activities. *Mem. Inst. Oswaldo Cruz*, 85:
- MILES, M. A.; MARSDEN, P. D.; PETTITT, L. E.; DRAPER, C. C.; WATSON, S.; SEACH, S. K. K.; HUTT, M. S. R. & FOWLER, J. M., 1979. Experimental *Trypanosoma cruzi* infection in Rhesus monkeys. III Electrocardiographic and histopathological findings. *Trans. R. Soc. Trop. Med. Hyg.*, 73: 528-532.
- MUNIZ, J.; SOARES, R. R. L.; SOUZA, M. A. & QUINTAO, L. G., 1970. Trypanosomiase americana (Doença de Chagas) dentro dos conceitos da imunopatologia. *Rev. Bras. Malariol. Doenças Trop.*, 22: 355-410.
- OPAS, 1982. Enfermedad de Chagas. *Bol. Epidemiol.*, 3: 1-6.
- POSTAN, M.; DVORAK, J. A. & Mc DANIEL, J. P., 1983. *Trypanosoma cruzi*: A comparative study on the course of infection of inbred mice with two clones isolated from a common source. *Am. J. Trop. Med. Hyg.*, 32: 497-506.
- PUNG, O. J.; HULSEBOS, L. H. & KUHN, R. E., 1988a. Experimental Chagas' disease (*Trypanosoma cruzi*) in the Brazilian squirrel (*Saimiri sciureus*): Hematology, Cardiology, Cellular and Humoral Immune Responses. *Int. J. Parasitol.*, 18: 115-120.
- PUNG, O. J.; HULSEBOS, L. H. & KUHN, R. E., 1988b. Experimental leishmaniose and Chagas' disease in the Brazilian squirrel monkey: Cross immunity and eletrocardiographic studies of monkeys infected with *Leishmania braziliensis* and *Trypanosoma cruzi*. *Int. J. Parasitol.*, 18: 1953-2059.
- ROMEIRO, S. A.; TAKEHARA, H. & MOTA, I., 1984. Isotype of lytic antibodies in serum of Chagas' disease patients. *Clin. Exp. Immunol.*, 55: 413-418.
- ROSNER, J. M.; SHIININI, A.; ROVIRA, T.; DE ARIAS, A.; VELASQUEZ, G.; IDALIA-MONZON, M.; MALDONADO, M.; FERRO, E. A. & GALEANO, R., 1988. Acute Chagas' disease in non-human primates. I- Chronology of parasitemia and immunological parameters in the *Cebus apella* monkey. *Trop. Med. Parasitol.*, 39: 51-55.
- ROSNER, J. M.; BELASSAI, J.; SCHININI, R. T.; DE ARIAS, A. R.; FERRO, E. A.; FERREIRA, E.; VELASQUEZ, G.; MONZON, M. I.; MALDONADO, M.; GALEANO, M. & FRESCO, M. A., 1989.

- Cardiomyopathy in *Cebus apella* monkeys experimentally infected with *Trypanosoma cruzi*. *Trop. Med. Parasitol.*, 40: 24-31.
- SCHMUNIS, G. A.; SZARFMAN, A.; COARASA, L.; GUILLERON, C. & PERALTA, J. M., 1980. Anti-*Trypanosoma cruzi* agglutinins in acute human Chagas' disease. *Am. J. Trop. Med. Hyg.*, 29: 170-178.
- SEAH, S. K. K.; MARSDEN, P. D.; VOLLER, A. & PETTITT, L. E., 1974. Experimental *Trypanosoma cruzi* infection in Rhesus monkeys - The acute phase. *Trans. R. Soc. Trop. Med. Hyg.*, 68: 63-69.
- VATUONE, N. H. & YANOVSKY, J. F. 1971. *Trypanosoma cruzi** agglutination activity of enzyme-treated epimastigotes. *Exp. Parasitol.*, 30: 349-355.
- WHO, 1984. *Report of the Scientific working group on the development and evaluation of animal models for Chagas' Disease*. Geneva.
- ZELEDON, R., ALVARENGA, N. J. & SCHOSINS-TRY, A., 1979. Ecology of *Trypanosoma cruzi* in the insect, p. 59-70. In *Proceedings of International Symposium on Chagas' disease*. New York: Pan American Health Organization.