

## EXPERIMENTAL PARACOCCIDIOIDOMYCOSIS IN THE MOUSE. III. HISTOPATHOLOGICAL AND IMMUNOLOGICAL FINDINGS AFTER INTRAVENOUS INFECTION IN THE PRESENCE OR ABSENCE OF PREVIOUS IMMUNIZATION

Maura Moscardi Bacchi<sup>1</sup> and Marcello Franco<sup>1</sup>

*Fifty male white Swiss mice aged 4 weeks were inoculated with  $5 \times 10^5$  viable yeast forms of Paracoccidioides brasiliensis (strain 18). Ten of these animals had been previously immunized with particulate P. brasiliensis antigen for 4 weeks by intradermal injection. The controls consisted of 10 animals that were only immunized and 10 animals submitted to no treatment. The animals were sacrificed 2, 4, 7, 11 and 16 weeks later. We studied: 1) the anti-P. brasiliensis delayed hypersensitivity response measured by the footpad test 24 hours prior to sacrifice; 2) the specific antibody production measured by double immunodiffusion in agar gel; 3) the histopathology of lungs, liver, spleen, adrenals and kidneys. We observed that: a) the immunized animals developed more intense cell-immune responses than the infected ones; b) infection reduced the cell-immune response of the immunized animals; c) intravenous infection of mice with P. brasiliensis was characterized by a systemic and progressive granulomatous inflammation. The animals infected after previous immunization showed less extensive lung inflammation, with smaller granulomas and fewer fungi. The results indicate that the present murine model mimics some findings of the human subacute form of paracoccidioidomycosis (systemic disease with depressed cellular immunity) and that the extrapulmonary immunization scheme was able to induce a certain degree of protection of the lung from infection with P. brasiliensis.*

**Key words:** Murine paracoccidioidomycosis. Immune response. Immunization.

In previous papers<sup>20 21</sup>, we studied the histopathology and the humoral and cellular immune response of mice experimentally infected by intraperitoneal inoculation of yeast forms of *Paracoccidioides brasiliensis* (*P. brasiliensis*). The peritonitis induced was characterized by a non-specific, localized and self-healing inflammation accompanied by moderate antibody production and persistent levels of cell-immune response. The course, intensity and nature of the peritonitis were similar in infected animals in the presence or absence of previous specific immunization<sup>21</sup>.

Some patients with paracoccidioidomycosis (Pbmycosis) show a localized and benign disease, with adequate immunological response and evolution to 'cure' after treatment. This clinical and immunological presentation of the human disease is comparable to

that observed in the mouse-intraperitoneal inoculation experimental model<sup>20 21</sup>.

In contrast, other patients present a progressive and systemic disease with depressed cell-immune response, which may be fatal even when treated. In order to standardize an experimental model of Pbmycosis with a parallel course to that observed in those patients, we have studied the evolving histopathology and immune response of intravenous infection in mice. With the aim of looking at protective mechanisms against the disease, the infection was further studied in animals that had been previously immunized with *P. brasiliensis*.

### MATERIAL AND METHODS

#### *Experimental groups*

**1. Infection:** Thirty white Swiss male mice aged four weeks were used. Groups of 6 animals were sacrificed 2, 4, 7, 11 and 16 weeks after infection.

**2. Infection after immunization:** Forty mice similar to those described above were distributed into 4

<sup>1</sup> Departamento de Patologia, Faculdade de Medicina de Botucatu da UNESP, 18600 Botucatu, São Paulo, Brazil. Research supported by FINEP (grant B/76/80/231/00/00).

experimental groups: a) 10 infected animals; b) 10 immunized animals; c) 10 animals infected after immunization; d) 10 controls that were neither immunized nor infected, injected only with sterile saline. Subsequently, 5 mice from each group were sacrificed at week 2 and 7.

#### Immunization

Immunization was carried out by the protocol of Rifkind et al<sup>21 24</sup>. Briefly, each mouse received a 0.025 ml intradermal weekly injection of a *P. brasiliensis* particulate antigen for 4 weeks. The animals infected after immunization were inoculated one week after the last immunizing dose.

#### Inoculum

Strain 18 of *P. brasiliensis* was cultured in Fava Netto's medium<sup>7</sup>, at 37°C for 10 days. Each animal was infected through the caudal vein with 0.25 ml of fungal suspension in sterile saline containing  $5 \times 10^5$  colony-forming units<sup>25</sup>. The controls were inoculated with the same volume of sterile saline.

#### Anti-*P. brasiliensis* immune response

*Cellular immunity*: it was evaluated *in vivo* 24

hours prior to sacrifice by the footpad test, as previously described<sup>20 21</sup>.

*Humoral immunity*: it was quantitated at sacrifice, by double immunodiffusion in agar gel, as previously standardized<sup>20 21</sup>.

#### Histopathology

All animals were dissected and the gross findings recorded. Fragments of lung, liver, spleen, adrenals and kidneys were fixed in 10% formalin, embedded in paraffin, cut into 4  $\mu$ m sections and stained with hematoxylin-eosin (HE) and Gomori-Grocott, by routine procedures. The intensity of the granulomatous reaction (number and size of granulomas) and number of fungi in lesions were semiquantitated on a scale to 0 to 4 + in mice with or without previous specific immunization.

## RESULTS

#### Cellular immunity

Table 1 shows the indices of the footpad test in infected, immunized, immunized and infected, and control animals.

Table 1 – Result of the footpad test expressed as the difference in volume between the control and the test footpad, in infected, immunized, immunized and infected, and control animals. Statistical differences between means are expressed by different letters.

Sacrifice (Week)	Groups	Footpad test indices						No of Animals	Mean $\pm$ s.d.	Statistical analysis	
										Infection	Infection vs. Immunization
2	Infection	0.4	0.5	0.7	0.7	0.9	1.1	6	0.7 $\pm$ 0.2	a	
2	Infection	0.4	0.5	0.6	0.8	0.8		5	0.6 $\pm$ 0.2		a
	Immunization	1.5	1.7	1.8	2.0	2.2		5	1.8 $\pm$ 0.2		b
	Immun. + Infection	-0.4	0.2	0.2	0.4	0.6		5	0.2 $\pm$ 0.3		a
	Control	-0.1	0.0	0.1	0.1	0.2		5	0.1 $\pm$ 0.1	b	
4	Infection	0.6	0.8	0.8	1.0	1.3	1.6	6	1.0 $\pm$ 0.3	a	
7	Infection	0.5	0.8	0.8	1.0	1.0	1.0	6	0.8 $\pm$ 0.2	a	
7	Infection	0.9	1.0	1.6	1.8	2.2		5	1.5 $\pm$ 0.5		a
	Immunization	1.4	1.6	1.8	2.7	AI*		5	1.8 $\pm$ 0.5		a
	Immun. + Infection	0.2	0.9	1.3	1.5	AI		5	0.9 $\pm$ 0.5		a
	Control	0.1	0.2	0.3	0.4	0.4		5	0.3 $\pm$ 0.1	b	
11	Infection	0.4	0.5	0.7	0.7	1.0	1.2	6	0.7 $\pm$ 0.3	a	
16	Infection	0.5	0.6	0.7	1.0	1.2	1.6	6	0.9 $\pm$ 0.4	a	

AI = accident during inoculation

Statistical analysis of the results was performed on the basis of three different approaches: 1) infection throughout the experimental period; 2) infection vs. immunization (2nd week); and 3) infection vs. immunization (7th week). The Kruskal-Wallis non-parametric test for independent variables<sup>2</sup> was applied in each case, considering K = 6 groups in approach 1, and K = 3 groups in approaches 2 and 3. The H statistical parameter was calculated with  $\chi^2$  distribution, with K = 1 degree of freedom, under  $H_0$ , where  $H_0$ : there is no effect of treatment. The tests were performed considering  $\alpha = 0.05$ ; in case of rejection of  $H_0$ , contrast between pairs of means was performed.

The control mice showed footpad test indices between -0.1 and 0.4, with mean values of  $0.2 \pm 0.1$ . The infected animals showed positive cell-immune response from the 2nd to the 16th week of infection, with indices ranging from 0.6 to 1.5, with mean values of  $0.8 \pm 0.3$ . In general, the control groups indices were statistically different from those of the infected groups, which however did not differ amongst themselves.

Immunized animals, both at weeks 2 and 7, developed a more intense cell-immune response (mean

$= 1.8 \pm 0.4$ ) than infected animals (mean  $= 1.0 \pm 0.3$ ) with a significant difference at week 2.

The cell-immune response in mice infected after previous immunization (mean  $= 0.5 \pm 0.4$ ), was depressed compared to that of the immunized group (mean  $= 1.8 \pm 0.3$ ), both at week 2 and 7. A significant difference was observed at week 2.

### Humoral Immunity

Table 2 shows the serum titers of anti-*P. brasiliensis* antibodies detected in all mice. The infected animals showed low specific antibody production starting at the 7th week and persisting up to the 16th week. Animals infected after immunization developed a humoral anti-*P. brasiliensis* response at higher frequency and with higher titers than only immunized mice.

### Histopathology

1. *Infection*: Since the 2nd week, the animals showed a diffuse and progressive involvement of the lungs characterized by a loose ill-defined granulomatous inflammation, made up by macrophages, epithelioid cells and neutrophils, around great number of fungi

Table 2—Results of the immunodiffusion test, expressed as the reciprocal of the maximum serum dilution showing a precipitation band, in infected, immunized, immunized and infected and control animals.

Sacrifice (Week)	Groups	Titers						Nº of animals	Median
2	Infection	0	0	0	0	0	0	6	1
2	Infection	0	0	0	0	P <sup>1</sup>		5	0
	Immunization	0	0	0	0	P		5	0
	Immun. + Infection	0	0	P	P	8		5	P
	Control	0	0	0	0	0		5	0
4	Infection	0	0	0	0	0	0	6	0
7	Infection	0	P	P	2	4	P <sup>2</sup>	6	P
7	Infection	2	8	8	16	16		5	8
	Immunization	0	0	0	0	2		5	0
	Immun. + Infection	P	P	8	8	16		5	8
	Control	0	0	0	0	0		5	0
11	Infection	0	0	P	P	2	2	6	P
16	Infection	0	P	2	2	2	8	6	2

1 = Undiluted serum

2 = Insufficient serum volume

(Figure 1A). The inflammation affected both the alveolar septa and lumina. From week 7 onwards, the epithelioid granulomas became more compact, well-

defined and confluent, with Langhans giant cells, surrounded by lymphocytes and plasmacells (Figure 2A).

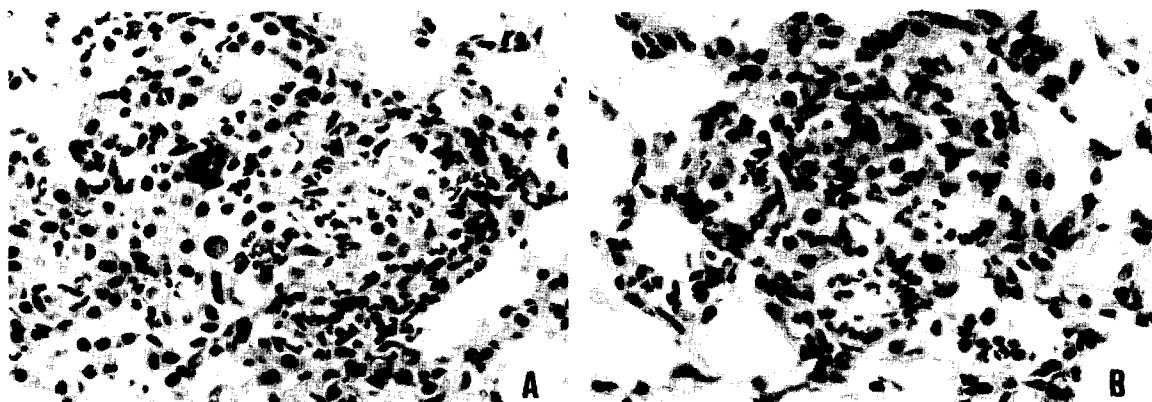


Fig. 1 - Histopathology of the lung at week 2.

A - Infection: loose ill-defined granulomatous inflammation with neutrophils and moderate number of *P. brasiliensis*. (HE 400X).

B - Infection in the presence of previous immunization: inflammation with similar pattern, showing smaller granulomas and diminished number of fungi. (HE 400X).

Throughout the infection, extrapulmonary dissemination occurred to the liver, spleen, kidney and adrenal, with histological pattern similar to that in lungs. The dissemination lesions were progressive, reaching great proportion at week 16 and showing numerous viable and actively multiplying fungi.

2. Infection after previous immunization: During the 2nd week, the histological pattern of the inflammation was similar in infected animals in the

presence or absence of previous immunization. However, in previously immunized mice, the lung granulomas showed a tendency to be smaller and to present a significantly reduced number of fungi (Figure 1B).

At week 7, infected animals showed lung granulomas which were more compact, extensive and with a greater number of fungi when compared to those of previously immunized mice (Figure 2B).

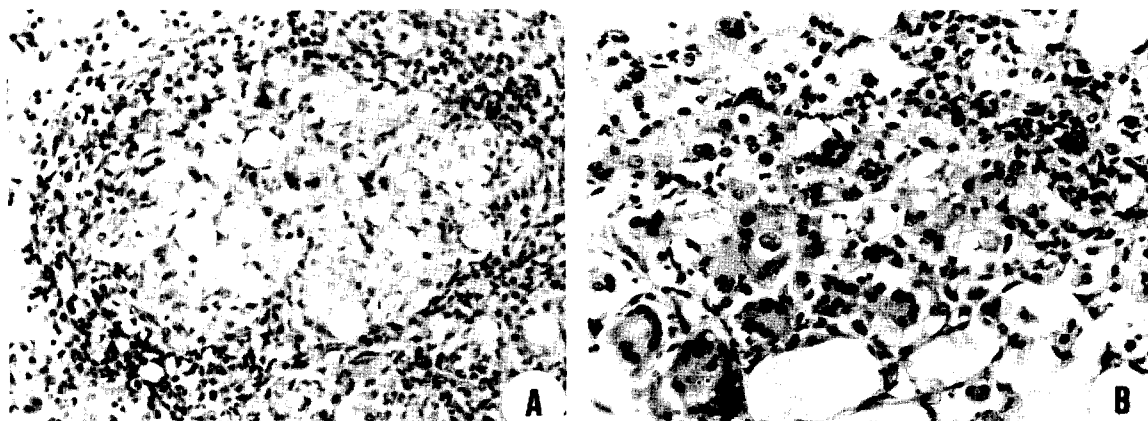


Fig. 2 - Histopathology of the lung at week 7.

A - Infection: well-defined, compact and confluent granulomata with numerous fungi and halo of lymphocytes and plasma cells. (HE 200X).

B - Infection in the presence of previous immunization: small ill-defined loose granuloma with reduced number of fungi. (HE 250 X).

The extent, pattern and number of fungi of the dissemination lesions were similar in both groups.

## DISCUSSION

Intravenous infection of mice with *P. brasiliensis* as standardized in the present study is a chronic, progressive and systemic granulomatous disease that predominantly involves the lungs and the reticuloendothelial system. Up to the 16th week of infection, the mice showed neither clinical signs of the disease nor mortality. However, in view of the evolving character of the lesions and the extent of lung in-

volvement, we believe that the infection would have eventually determined the animals' death.

When we compare the present results with those obtained by other investigators who reproduced the *P. brasiliensis* intravenous infection in mice (Table 3), we note an agreement as regards the systemic, evolving, granulomatous and eventually fatal nature of this Pbmcyosis experimental model.

As reported for mice<sup>13 17</sup> and other animals<sup>3</sup>, the intensity and nature of the *P. brasiliensis* experimental infection vary according to the fungal strain

Table 3 - *Paracoccidioides brasiliensis* intravenous infection in mice.

Author (year)	Nº of mice Strain treatment	Inoculum <i>P. brasiliensis</i> strain	Characteristics of the infection	Organs involved	Survival
Lacaz et al <sup>12</sup> (1949)	9	7 to 12-day culture at 37°C	Systemic Granulomatous	Lungs Liver Spleen Lymph nodes	6 to 45 days
Mackinnon <sup>16</sup> (1959)	18 Swiss white	Strain IHM/1438 Strain IHM/1448 8 to 14-day culture	Systemic Slowly evolving Progressive	Lungs Liver Adrenal Skeletal muscle Tongue Central nervous system	18 days to 5 months
Del Negro & Brito <sup>5</sup> (1963)	15	2 non-specified strain	Systemic	Adrenal	No mortality Sacrifice between 25 and 145 days
Conti-Díaz & Furcolow <sup>4</sup>	30 Swiss white	Strain IHM/1438 50-day mycelial culture 190 and 950 viable fungi/animal	Absence of lesions	Absence of lesions	No mortality Sacrifice between 30 and 40 days
	10 Swiss white	Strain IHM/1438 4-month culture 7650 viable fungi/animal	Absence of lesions	Absence of lesions	No mortality Sacrifice between 30 and 35 days
Linares & Friedman <sup>14</sup> (1972)	110 Swiss white	Strain 3 (New Orleans) Strain 17 (Caracas)	Systemic Slowly evolving	Liver Spleen Skeletal muscle	10% mortality without corticoid treatment and 27% with corticoid
	Strain CDI Corticoid treatment	Strain 1, 7, 9, 10, 11, 12, 19 (Medellín) 5-day culture at 37°C, 1x10 <sup>5</sup> and 5x10 <sup>3</sup> viable colonies/animal		Heart Kidneys Skin Pancreas Intestine	
Linares & Friedman <sup>15</sup> (1972)	10 Swiss white	Strain Alvarez (Medellín) Culture at 37°C, 2x10 <sup>4</sup> viable colonies/animal	Systemic Granulomatous	Lungs Liver Spleen Lymph nodes Intestine	No mortality Sacrifice between 50 and 60 days
Hay & Chandler <sup>10</sup> (1978)	80 Swiss white	Strain 2460 (Atlanta) Culture at 37°C, 1x10 <sup>3</sup> and 1x10 <sup>7</sup> viable forms/animal	Systemic Granulomatous Early hematogenic dissemination	Emphasis on head and neck lesions	No mortality Sacrifice between 1 and 16 weeks
Present work	70 Swiss white	Strain 18 (São Paulo) 10-day culture at 37°C, 5x10 <sup>4</sup> viable colonies/animal	Systemic Granulomatous Slowly evolving	Lungs Liver Spleen Adrenal Kidney	No mortality Sacrifice between 2 and 16 weeks

utilized, the inoculum and the infection route. Our present and previous data<sup>20 21</sup>, taken as a whole, demonstrate the importance of the inoculation route. The systemic, progressive, granulomatous characteristics of the intravenous infection contrast with the localized, benign, non-granulomatous and non-progressive nature of the intraperitoneal infection<sup>20 21</sup>. In both, early specific cell-immune response occurred and was maintained throughout the infection. The humoral immune response was delayed and less intense in the intravenous infection.

Few studies have been carried out on the immune response of mice experimentally infected with *P. brasiliensis*. As observed in the present investigation and in previous studies<sup>6 19 20 21</sup>, cell-immune response is detectable 2 to 8 weeks after infection, persisting or decreasing according to the inoculation route. Levels of circulating specific antibodies tend to be detected later<sup>6</sup>. The immune behavior of fruit-eating bats (*Artibeus lituratus*) in response to intraperitoneal and intranasal infection with *P. brasiliensis*<sup>9</sup> parallels that of mice.

In the present study, intravenous infection caused a depressed cell-immune response in previously immunized mice (Table 1), contrasting with the intraperitoneal model, where infection acted as a booster<sup>21</sup>. Thus the intravenous model mimics the subacute diffuse juvenile form of human Pbmycosis<sup>8</sup> which hallmarks are diffuse, evolving infection with depressed immune response. The presence of large number of actively multiplying *P. brasiliensis* in lesions of both the present experimental model and the human subacute diffuse Pbmycosis represent intense antigen overload, which is probably one of the mechanisms leading to immunologic depression of the host<sup>22</sup>.

The most interesting histopathological finding was the decrease in the number of fungi and intensity of pulmonary granulomas in mice infected after immunization when compared to animals only infected. These data indicate that active immunization with intradermal injection of *P. brasiliensis* antigen was able to induce a certain level of protection in animals subsequently infected by the intravenous route (infectious "challenge"). In these mice, fungi were destroyed more promptly and effectively and as a consequence the pulmonary lesions were less extensive. Similar to this approach, several studies have demonstrated that immunization schemes using extrapulmonary routes induce humoral and cell-immune response in the respiratory tract<sup>18</sup>. Furthermore, the immunization may be protective, as observed in guinea pigs challenged,

by the aerogenous route, with *Pseudomonas* after specific intramuscular immunization<sup>23</sup>.

In the present study, in contrast to what was observed in lungs, the extrapulmonary lesions of mice in the presence or absence of previous immunization were of similar intensity. This appears to indicate a greater ability of the lung to deal with the infection, suggesting a distinct compartmentalized pulmonary response to infectious 'challenge' after previous immunization.

Reports on active immunization as a form of protection against *P. brasiliensis* are scarce and date back many years<sup>1</sup>. This is a matter of great medical importance that is only now beginning to be further explored.

## RESUMO

Cinquenta camundongos suíços, brancos, com quatro semanas de idade, foram inoculados com  $5 \times 10^5$  formas leveduriformes, viáveis de *Paracoccidioides brasiliensis* (cepa 18). Dez destes animais tinham sido previamente imunizados com antígeno particulado de *P. brasiliensis*, durante quatro semanas, por injeção intradérmica. Os controles consistiram de 10 animais que foram somente imunizados e 10 inoculados com solução salina estéril. Os animais foram sacrificados após 2, 4, 7, 11 e 16 semanas. Estudamos: 1) resposta de hipersensibilidade retardada medida pelo teste do coxim plantar, 24 horas antes do sacrifício; 2) anticorpo-gênese específica avaliada pelo teste de imunodifusão dupla em gel de ágar; 3) histopatologia dos pulmões, fígado, baço, supra-renal e rins. Observamos: 1) os animais imunizados desenvolveram resposta imune celular mais intensa que os infectados; 2) a infecção depressiu a resposta imune celular dos animais imunizados; 3) a histopatologia da infecção endovenosa revelou inflamação granulomatosa sistêmica e progressiva. Os animais infectados após imunização prévia apresentaram inflamação pulmonar menos extensa, com granulomas menores e com reduzido número de fungos. O presente modelo murino de paracoccidioidomicose mimetiza alguns achados da forma humana subaguda da micose (doença sistêmica com depressão da imunidade celular). O esquema de imunização extrapulmonar utilizado foi capaz de induzir certo grau de proteção do pulmão contra um desafio infeccioso pelo *P. brasiliensis*.

Palavras chaves: Paracoccidioidomicose murina. Resposta imune. Imunização.

## ACKNOWLEDGEMENTS

The authors are grateful to Mr. Luis Gastão Chamma and Mrs. Sonia Orsi for technical assistance and Dra. Sheila Z. Pinho for the statistical analysis.

## REFERENCES

- Almeida FP. Vacina contra o granuloma paracoccidioidico. *Folia Clinica et Biologica* 10: 195-197, 1938.
- Campos H. Estatística experimental não paramétrica. Piracicaba, Departamento de Matemática e Estatística. ESALQ-USP, 3ª ed., p. 343, 1979.
- Coelho KIR, Defaveri J, Iwasso MTR, Peraçoli MT, Mota NGS. Paracoccidioidomycose experimental. In: Paracoccidioidomycose. São Paulo. Del Negro G, Lacaz LC, Fiorillo AM (Eds.) Editora Sarvier-EDUSP, p. 69-84, 1982.
- Conti-Díaz IA, Furcolow ML. Susceptibility of hamsters and mice to *Paracoccidioides brasiliensis* using different routes of inoculation. *Mycopathologia et Mycologia Applicata* 47: 73-79, 1972.
- Del Negro G, Brito T. Adrenal lesions in mice due to experimental infection by *Paracoccidioides (Blastomyces) brasiliensis*. In: Annals of VII Congresso Internacional de Medicina Tropical, Rio de Janeiro, p. 118, 1963.
- Defaveri J, Rezkallah-Iwasso MT, Franco MF. Experimental pulmonary paracoccidioidomycosis in mice: morphology and correlation of lesions with humoral and cellular immune response. *Mycopathologia* 77: 3-11, 1982.
- Fava Netto C. Estudos quantitativos sobre a fixação do complemento na blastomicose sul-americana com antígeno polissacarídico. *Arquivos de Cirurgia Clínica e Experimental* 18: 197-254, 1955.
- Franco MF, Montenegro MRG. Anatomia Patológica. In: Paracoccidioidomycose. São Paulo. Del Negro G, Lucaz LC, Fiorillo AM (Eds.). Editora Sarvier-EDUSP, p. 97-117, 1982.
- Greer DL, McMurray DN. Pathogenesis and immune response to *Paracoccidioides brasiliensis* in the fructivorous bat, *Artibeus lituratus*. *Sabouraudia* 19: 165-178, 1981.
- Hay RJ, Chandler Jr. FW. Experimental paracoccidioidomycosis: cranial and nasal localization in mice. *British Journal of Experimental Pathology* 59: 339-344, 1978.
- Kaltreider HB. Expression of immune mechanisms in the lung. *American Review of Respiratory Disease* 113: 347-379, 1976.
- Lacaz CS, Iaria ST, Ferreira M, Martins AA, Vega VS. Blastomicose experimental. *O Hospital* 36: 341-349, 1949.
- Lacaz CS. *Micologia Médica*. 6ª ed. São Paulo, Editora Sarvier, 1977.
- Linares LI, Friedman L. Experimental paracoccidioidomycosis in mice. *Infection and Immunity* 5: 681-687, 1972a.
- Linares LI, Friedman L. Pathogenesis of paracoccidioidomycosis in experimental animals. *Scientific Publication Pan American Health Organization* 254: 287-292, 1972b.
- Mackinnon JE. Pathogenesis of South American blastomycosis. *Transactions of the Royal Society of Tropical Medicine and Hygiene* 53: 487-494, 1959.
- Mackinnon JE. Miosites en la blastomicosis sudamericana y en la histoplasmosis. *Mycopathologia et Mycologia Applicata* 15: 171-176, 1961.
- McLeod E, Caldwell JL, Kaltreider B. Pulmonary immune responses of inbred mice. Appearance of antibody forming cells in C57BL/6 mice after intrapulmonary or systemic immunization with sheep erythrocytes. *American Review of Respiratory Disease* 118: 561-571, 1978.
- Montoya F, Garcia-Moreno LF. Effect of sex on delayed hypersensitivity responses in experimental mouse paracoccidioidomycosis. *Journal of the Reticuloendothelial Society* 26: 467-478, 1979.
- Moscardi M, Franco MF. Paracoccidioidomycose experimental do camundongo. I. Aspectos imunopatológicos da infecção intraperitoneal. *Revista do Instituto de Medicina Tropical de São Paulo* 22: 286-293, 1980.
- Moscardi M, Franco MF. Paracoccidioidomycose experimental do camundongo. II. Infecção intraperitoneal após sensibilização prévia. *Revista do Instituto de Medicina Tropical de São Paulo* 23: 204-211, 1981.
- Mota NGS, Rezkallah-Iwasso MT, Peraçoli MTS, Audi RC, Mendes RP, Marcondes J, Marques SA, Dillon NL, Franco, MF. Correlation between cell mediated immunity and clinical forms of paracoccidioidomycosis. *Transactions of the Royal Society of Tropical Medicine and Hygiene*, in press.
- Pennington JE, Hickey WF, Blackwood LL, Arnant MA. Active immunization with lipopolysaccharide

Bacchi MM, Franco M. *Experimental paracoccidioidomycosis in the mouse. III. Histopathological and immunological findings after intravenous infection in the presence or absence of previous immunization. Revista da Sociedade Brasileira de Medicina Tropical* 18: 101-108, Abr-Jun, 1985

*Pseudomonas* antigen for chronic *Pseudomonas* bronchopneumonia in guinea pigs. *Journal of Clinical Investigation* 68: 1140-1148, 1981.

active and passive sensitization. *The Journal of Infectious Diseases* 133: 50-56, 1976.

24. Rifkind D, Frey JA, Peterson EA, Dinowitz M. Delayed hypersensitivity to fungal antigens in mice. I. Use of the intradermal skin and footpad swelling tests as assays of

25. San-Blás F, Cova LJ. Growth curves of the yeast-like form of *Paracoccidioides brasiliensis*. *Sabouraudia* 13: 22-29, 1975.