

Experimental uterus transplantation

Mats Brännström^{1,3}, Caiza A. Wrranning¹, and Albert Altchek²

¹Department of Obstetrics & Gynecology, Sahlgrenska University Hospital, Sahlgrenska Academy, University of Gothenburg, S-413 45 Göteborg, Sweden ²Department of Obstetrics, Gynecology and Reproductive Science, Mount Sinai School of Medicine and Lenox Hill Hospital, New York, NY, USA

³Correspondence address. Fax: +46-31-418717; E-mail: mats.brannstrom@obgyn.gu.se

TABLE OF CONTENTS

- Introduction
- Methods
- Potential patient groups for UTx
- Uterus retrieval
- Ischemia-reperfusion injury
- Surgical technique for UTx
- Rejection and immunosuppression in UTx
- Pregnancy and offspring in UTx
- Ethics and institutional requirements
- Conclusions

BACKGROUND: Uterus transplantation (UTx) is developed in animal models as a future method to treat uterine factor infertility.

METHODS: All published studies in the area of UTx research were identified. Aspects relating to surgery, cold-ischemia/reperfusion, rejection, immunosuppression, pregnancy, ethics and institutional requirements were examined.

RESULTS: Uterus retrieval surgery has been solved in animals, including primates. Studies on cold-ischemia/reperfusion indicate an ischemic tolerance of >24 h. The transplantation procedure, with vascular anastomosis, has not been fully developed in animal models, indicated by frequent thrombosis formation. Pregnancies have only been reported in syngenic/auto-UTx animal models. Several ethical issues in relation to UTx, and requirements for a team that would be suitable to undertake human UTx, exist.

CONCLUSION: Much research on UTx has been performed in appropriate animal models. Several aspects of the procedure have been optimized but some remain to be solved. It is predicted that the research will soon reach a stage that could merit introduction of human UTx as an experimental procedure.

Key words: infertility / pregnancy / transplantation / uterus

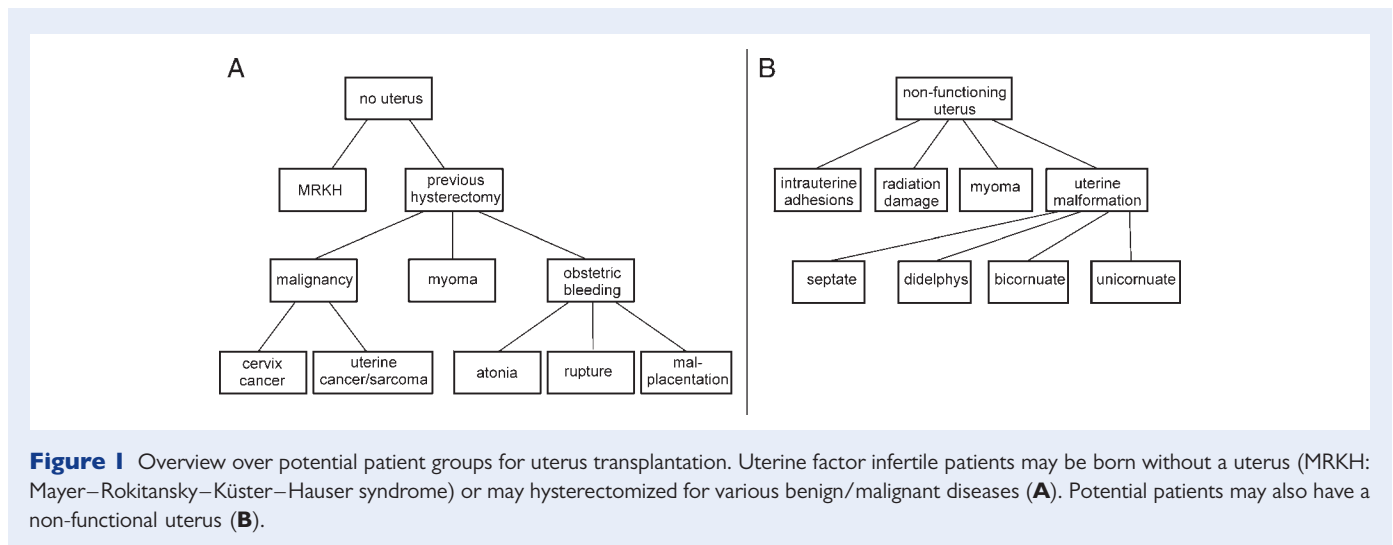
Introduction

Medical science and clinical medicine have made tremendous advancements during the last decades. Two milestones were the first reports of successful transplantation of a solid organ, the kidney (Merril *et al.*, 1956; Murray *et al.*, 1960), and live birth after IVF (Steptoe and Edwards, 1978). These achievements opened up the new clinical fields of transplantation surgery and reproductive medicine.

New techniques in reproductive medicine have led to bypassing most categories of infertility. Transplantation surgery has come to include types of organ/tissue transplantation that will enhance the quality-of-life as exemplified by transplantation of the hand

(Dubernard *et al.*, 1999), the abdominal wall (Levi *et al.*, 2003), the larynx (Birchall *et al.*, 2006) and the face (Devauchelle *et al.*, 2006). For many women, experiencing a pregnancy, giving birth and bringing up a child are very important aspects of quality-of-life and uterus transplantation (UTx), to fulfil this need, may be justified.

Women that either lack or have a non-functional uterus are today unconditionally infertile. Gestational surrogacy is a way to achieve genetic parenthood (Goldfarb *et al.*, 2000), but is associated with ethical/legal problems in terms of autonomy, payment, informed consent, gestational carrier health and welfare of the future child (Shenfield *et al.*, 2005; Nakash and Herdman, 2007). UTx, to cure permanent uterine factor infertility (Altchek, 2003; Brännström



et al., 2003), may become a procedure that markedly enhances the quality-of-life for couples that today are irreversibly infertile.

To date one human UTX attempt has been performed. In year 2000 a 26-year-old woman received a uterus from a 46-year-old woman (Fageeh et al., 2002). The uterus survived for 3 months and the trial was criticized because of uncertainties concerning informed consent (Kandela, 2000) and the minimal research experience.

During the 1970s research on tubal/uterotubal transplantation, to treat tubal factor infertility, was conducted. Transplantation of the oviduct in animal models resulted in pregnancies (Winston and Browne, 1974; Scott et al., 1987), but human tubal allo-transplantation was unsuccessful (Sillo-Seidl, 1975; Cohen, 1976; Wood et al., 1978). Transplantation of the oviducts together with the uterus was suggested as a better method since anastomosing the larger uterine blood vessels would ensure high tubal blood flow with the uterotubal junction surgically undisturbed (Eraslan et al., 1966; Barzilai et al., 1973), but introduction of IVF during the 1980s caused a cessation of this research.

Methods

A systemic search of PubMed using the terms uterus/uterine and transplantation was done. All relevant articles and additional articles cited in primary references are included.

Potential patient groups for UTX

Several groups of patients can be classified as involuntarily infertile due to absence/dysfunction of the uterus (Fig. 1).

Congenital uterine malformations

Congenital uterine infertility constitutes forms of uterine malformations which lead to infertility, pregnancy loss, preterm delivery or other obstetric complications (Heinonen et al., 1982). The prevalence of uterine malformations is 6.7% in the general female population, 7.3% among infertile women and 16.7% in women with recurrent miscarriage (Saravelos et al., 2008). The majority of these patients are

fertile, despite their uterine malformation, but many are irreversibly infertile.

The most common type of uterine anomaly among infertile women is septate uterus (Saravelos et al., 2008) comprising 35% of uterine malformations (Grimbizis et al., 2001). Spontaneous miscarriage occurs in about 80% of pregnancies in surgically untreated septate uteri (Homer et al., 2000) and hysteroscopic metroplasty decreases the rate substantially (Homer et al., 2000) but some remain infertile (Pabuccu and Gomel, 2004). The second most common type of uterine malformation is the bicornuate uterus, accounting for 25% of uterine malformations (Grimbizis et al., 2001). Spontaneous miscarriage occurs in around 35% of the pregnancies (Buttram, 1983) and metroplasty may cure some (Papp et al., 2006), but many cannot carry a pregnancy to second/third trimester. Unicornuate and didelphic uteri comprise around 20% of uterine malformations (Grimbizis et al., 2001). About one-third of pregnancies in these groups end in spontaneous miscarriage and the live birth rate is just above 50% (Grimbizis et al., 2001). There is no demonstrated benefit of surgical removal of rudimentary horn or unification of horns (Taylor and Gomel, 2008). Taken together, although the majority of patients with uterine malformations are fertile, a modest estimation is that around 20% of the patients with these partial Müllerian anomalies remain infertile.

The least common uterine anomaly is uterine agenesis, constituting 3% of all Müllerian anomalies (Grimbizis et al., 2001) and seen in 1:4000 of females (Griffin et al., 1976; Folch et al., 2000). This syndrome of a rudimentary solid bipartite uterus with absence of vagina was described in 1829 by the anatomist Mayer (1829) and later by Rokitansky (1838). The syndrome is today named the Mayer–Rokitansky–Küster–Hauser (MRKH) syndrome, based on the two observations from the 19th century and later case-series (Küster, 1910; Hauser and Schreiner, 1961). The majority of MRKH are sporadic (Guerrier et al., 2006) and typically diagnosed due to primary amenorrhea (Carson et al., 1983) but familial aggregates exist (Jones and Mermut, 1972). The syndrome seems to be inherited as a polygenic, multifactorial trait as suggested by the outcome of gestational surrogate pregnancies with MRKH-patients as the genetic mothers (Petrozza et al., 1997). Embryos from 58 MRKH women

resulted in 34 live births (17 female) and no genital malformation was seen. Girls with MRKH syndrome have normal karyotype and develop into female adults, with functioning sexual life after creation of a neovagina (Davies and Creighton, 2007; Brucker *et al.*, 2008).

Three distinct MRKH-subtypes exist, with a typical subtype in around 50% of cases. The atypical subtype, with associated malformations in the renal system, is seen in ~20% of patients, and the severe MURCS (Müllerian duct aplasia, Renal aplasia and Cervicothoracic Somite dysplasia) accounts for the remaining 30% (Oppelt *et al.*, 2006). Existence of a MURCS-like syndrome in males with azoospermia may exist (Wellesley and Slaney, 1995).

Women with the typical MRKH syndrome would be suitable patients for initial UTx attempts since they would be relatively young and with excellent IVF outcome (Goldfarb *et al.*, 2000).

Hysterectomy

The largest group of women with absolute uterine factor infertility is hysterectomized patients of younger age (Farquhar and Steiner, 2002) as illustrated by that 50% of women enrolled in an IVF surrogate program were hysterectomized (Goldfarb *et al.*, 2000). The reasons to perform a hysterectomy at young age are described below.

Gynaecologic cancer

Cervical cancer is the most common gynecologic malignancy worldwide (Quinn *et al.*, 2006), but with low incidence in developed countries (Andrae *et al.*, 2008). More than 30% of women with cervical cancer are below 40 years (Sonoda *et al.*, 2004; Quinn *et al.*, 2006) and many are nulliparous. The 5-year survival rate of early-stage cervical cancer is above 75% (Quinn *et al.*, 2006). In patients with squamous cell carcinoma of <2 cm and invasion depth of <10 mm fertility-preserving vaginal (D'Argent *et al.*, 2000) or abdominal (Ungar *et al.*, 2005) trachelectomy is used. Larger tumours, occurring in about 50% of younger patients (Sonoda *et al.*, 2004), are treated with radical hysterectomy and this group of patients could be UTx-candidates after exclusion of persistent genital human papillomavirus infection (Bosch *et al.*, 2008). Early-stage endometrial cancer and uterine sarcoma are uncommon during fertile age with only around 2.5% in women below 40 years of age (You *et al.*, 2005; Creasman *et al.*, 2006).

Other malignancies

Non-gynecological cancer during childhood/early adult life affects around 1:400 females with survival now >70% (Mertens *et al.*, 2001). Chemotherapy during childhood does not affect adult uterine size (Larsen *et al.*, 2004) but may be gonadotoxic (Donnez *et al.*, 2006). Radiotherapy over the pelvis causes irreversible reduction of uterine size (Bath *et al.*, 1999; Larsen *et al.*, 2004) with around 60% decrease in size (Holm *et al.*, 1999). A small proportion of these women will achieve pregnancies but with increased miscarriage rate (Critchley and Wallace, 2005). External radiation is gonadotoxic and doses of 5–20 Gy over the ovaries impairs gonadal function (Wallace *et al.*, 2005) with immediate menopause in >90% of post-pubertal females and less toxicity before puberty (Sanders *et al.*, 1996). In the light of recent reports of a total of six live births after ovarian cryopreservation (Donnez *et al.*, 2004; Meirou *et al.*, 2005; Demeestere *et al.*, 2007; Andersen *et al.*, 2008; Silber *et al.*, 2008)

and further developments in the area (Donnez *et al.*, 2006; Brännström and Milenkovic, 2008) ovarian fertility preservation will probably in the near future become readily available and may be combined with UTx.

Leiomyoma

The incidence of uterine leiomyoma increases with age (Marino *et al.*, 2004), with a prevalence of around 8% in Swedish women between 33 and 40 years (Borgfeldt and Andolf, 2000). A similar incidence was seen in Caucasian women in the USA, with an almost double incidence in Afro-Americans (Chen *et al.*, 2001). Around 1% of all women 30–34 years and 2.5% of those 35–39 years will undergo hysterectomy because of myoma (Marshall *et al.*, 1997). Submucosal (Farhi *et al.*, 1995) and large intramural (Oliveira *et al.*, 2004) myoma can cause infertility and hysteroscopic resection (Fernandez *et al.*, 2001) or myomectomy (Connolly *et al.*, 2000) may improve pregnancy chance. Those that remain infertile or have been hysterectomized may be candidates for UTx.

Intrauterine adhesions

Intrauterine adhesions (IUAs), also named Asherman's syndrome (Asherman, 1948), may cause uterine factor infertility. The prevalence of IUA among females is around 1.5% (Al-Inany, 2001) but higher prevalence rates exist in the developing world due high prevalence of genital tuberculosis (Lönnroth and Raviglione, 2008), which causes obliteration of the uterine cavity in >50% of cases (Bukulmez *et al.*, 1999). Other causes of IUA are endometritis due to other pathogens and surgical trauma, particularly after uterine curettage to a vulnerable gravid uterus (Friedler *et al.*, 1993). Untreated IUA (of any severity) results in infertility in around 50% of women and 40% of pregnancies end in spontaneous miscarriage (Schenker and Margalioth, 1982). Hysteroscopic adhesiolysis cure infertility in mild, moderate and severe IUA in around 90, 70 and 30%, respectively (Fernandez *et al.*, 2006). Hysterectomy, followed by UTx, remains an alternative for the patients with IUA that stay infertile.

Emergency peripartum hysterectomy

Emergency peripartum hysterectomy (EPH) is life-saving in situations of severe bleeding due to uterus atony, uterine rupture, invasive malplacentaion or Caesarean section. Although new effective uterus compression sutures have been introduced (El-Hamamy and B-Lynch C, 2005; Sciller *et al.*, 2007), the EPH-rate (1:2000) increases due to common use of Caesarean section (Kwee *et al.*, 2006; Habek and Becarevic, 2007).

Summary: potential patient groups for UTx

Several patient categories may become candidates for UTx (Fig.1). There are no population-based studies to exactly determine the size of this group but in the UK it may include 12 000–15 000 women (Sieunarine *et al.*, 2005a).

Uterus retrieval

Uterus retrieval surgery in animals models vary depending on size/anatomy of the uterus and vasculature. The small animal UTx-models use donors that are sacrificed, since the vascular segments of the graft

contain the aorta and vena cava. The large animal models mainly use techniques that allow donor survival. The uterus retrieval procedure is technically demanding and should be developed in animal models to ensure a safe procedure for a human living donor.

Human

In the human UTx attempt (Fageeh et al., 2002) a 46-year-old woman, with bilateral multilocular ovarian cysts, donated her uterus. There existed some controversy regarding informed consent (Kandela, 2000), but in a later apology in the same journal this was clarified. Through a midline incision the ovaries were removed and frozen sections indicated benign cysts. It should be emphasized that surgery for supposedly benign ovarian cysts generally is performed by laparoscopy (Hilger et al., 2006) without hysterectomy. The round ligaments were transected and the paracervical/pararectal spaces were opened to facilitate separation of uterine vessels from ureters. A small ureteric laceration was sutured. Heparin was given after vaginal transection and the uterine arteries were divided 25 mm away from the uterus. The division-level of the uterine veins and their anatomy are not mentioned. The location of uterine veins vary with typically one or two major veins following the uterine artery but also some crossing the ureter posteriorly with all merging with the vaginal veins into a utero-vaginal venous plexus that drains into the internal iliac (Cicinelli et al., 2004). The duration of uterus retrieval surgery is not given but since frozen section and dissections of ureters/blood vessels were performed, the duration was most likely at least 2–3 h. The oviducts were included in the human UTx-case (Fageeh et al., 2002). It is questionable whether natural ovarian-tubal function will form between a transplanted oviduct and the native ovary. The chance for natural conception would be minimal and in that case ectopic pregnancy-risk is high. Furthermore, low grade inflammation is often temporarily present in transplanted tissue and any inflammation in a transplanted oviduct would most likely negatively influence implantation after IVF (Aboughar et al., 1998), a procedure we would recommend before UTx.

Experiments on uterus retrieval from multi-organ donors (Del Priore et al., 2007) were performed in seven females. After development of paravesical/pararectal spaces, sharp dissection freed the cervix from the bladder/rectum with the ureters transected at the bladder and retracted with the kidney. All branches from the internal iliac artery, except the uterine artery, were ligated. The uterine veins were not freed and instead a large part of the parametrium was preserved up to the internal iliac vein. Heparin was given before aortic/caval cross-clamping. Vascular pedicles, including the uterine and internal iliac vessels up to the divisions from the common iliacs, were only obtained in two of the seven donors. Thus, the technique for uterus retrieval in multi-organ donors should be further developed.

Medical criteria for uterus donor would include excellent health, previous successful pregnancy, normal cervical cytology/endometrial histology and no myomas/polyps. The selection of donors that meet these criteria is possible with living-donors but difficult with multi-organ donors. Possible living-donors would be mothers or older sisters, after their childbearing, who could even be haploidentical. Pregnancy capacity seems to be unaffected by uterine age (Navot et al., 1994).

Non-human primate

In the rhesus monkey the uterus was auto- and allo-transplanted (Scott et al., 1971) with blood flow re-established by neoangiogenesis from the omentum. Uterus retrieval did not involve dissection of vascular pedicles and lasted <20 min. In preparation for human UTx, baboons were used for auto-UTx (Fageeh et al., 2002). It is only stated that the hysterectomy preserved tissue and vascular integrity, with no further details given. In our baboon auto-UTx experiments, retrieval of the uterus with long vascular pedicles, took about 3 h (unpublished observations). The baboon was chosen as a suitable model because of the relatively large body size and since uterine anatomy is similar to the human with a straight cervical canal enabling endometrial sampling, embryo-transfer and hysteroscopy (Nyachio et al., 2007).

Dog

A technique for isolation of the bicornuate dog uterus and adnexae with blood vessels for re-anastomosis was described several decades ago (Eraslan et al., 1966). The common part of the internal iliac artery was dissected from its origin and freed caudally with ligations of all branches except the uterine and superior vesicle arteries. The uterine veins were dissected cranially from the uterus to the fusion of the internal and external iliacs. The ovarian vessels were divided, followed by clamping of the vagina. The blood flow to the specimen was then interrupted by division of the common internal iliac artery. Noteworthy is that the vaginal connection, although clamped, was intact during flushing and re-anastomosis and the uterus was never disconnected from the body. A similar dissection method was later used by another group (Truta et al., 1969) but with the difference that the vagina was at no time transected. Later experiments were proper auto-transplantations (Barzilai et al., 1973; Paldi et al., 1975) since the vagina was divided at an early stage. None of these reports describe dissection of the ureters, most likely since the arteries were dissected in a caudal direction from the common iliacs and freed only to a level before crossing the ureters. The utero-tubal-ovarian specimen could then not be removed from the body. Later, allogenic transplantations, with vascular connections were reported. The donor animals were sacrificed since the vascular pedicles included the common iliacs (Yonemoto et al., 1969; Paldi et al., 1975) or lower aorta/vena cava (Mattingly et al., 1970; Wingate et al., 1970).

One remark is the lack of data concerning durations of utero-tubal-ovarian retrieval in all these studies. It is likely that it extended over several hours. A much shorter time for graft harvesting was probably present in studies aimed to transplant the dog uterus by omental wrapping (O'Leary et al., 1969; Scott et al., 1970) since blood vessels were not dissected. However, the survival rate of these grafts was low (Barzilai et al., 1973).

Pig

In efforts to develop a suitable large animal model for UTx research we (Wranning et al., 2006) and others (Sieunarine et al., 2005a) tested the pig for auto-UTx. A supracervical hysterectomy was performed and the uterine vessels were divided above the ureters, since the deeper pelvis was inaccessible for vascular dissection. Because of poor surgical access to the pelvis and since the pig

uterus is very large, this animal was found unsuitable for uterus retrieval training. Dissection of the uterine arteries and veins, up to the level of aorta/vena cava, has been performed in pig cadavers (Sieunarine *et al.*, 2005b) and more recently in miniature breed pigs as part of allogenic UTx (Avison *et al.*, 2009).

Sheep

The advantage of the sheep in UTx research, compared with the pig, is that the body size is more equivalent to that of a young woman, the wider pelvis and that the size/anatomy of pelvic vasculature resembles the human. Previously, a technique for heterotopic auto-UTx to the neck, with vascular anastomosis to the carotid artery and jugular vein, was presented (McCracken *et al.*, 1971; Baird *et al.* 1976). Our techniques for retrieval of the uterus (with one horn removed) only (Dahm-Kähler *et al.*, 2008) or together with the ipsilateral adnexae (Wranning *et al.*, 2009) included midline incision with dissections of the uterine arteries from the anterior branch of the internal iliac artery, the utero-ovarian vein and ureters. In short-term studies, excluding the ovary, the ovarian vein was divided close to the point of fusion with the uterine vein (Dahm-Kähler *et al.*, 2008). In tests to study pregnancy after auto-UTx (Wranning *et al.*, 2009), the adnexae and ovarian artery were preserved. After vaginal division the remaining procurement steps were divisions of the anterior branch of the internal iliac artery, the utero-ovarian vein caudally of their branching from the internal iliac vessels, and in animals for long-term studies, acquisition of an aortic patch including the origin of the ovarian artery. The duration of procurement surgery was around 3 h when only the uterus was retrieved and 4 h when also the ovary was harvested.

Another less complicated method for uterus retrieval in the sheep, with uterine artery end-to-end anastomosis, did not involve ureter dissection (Ramirez *et al.*, 2008). A similar method could only be used in the small number of human cases where simultaneous recipient hysterectomy is performed.

Rabbit

Surgical isolation of the rabbit uterus for non-vascular transplantation to the surface of the broad ligament has been described (Confino *et al.*, 1986) and rabbit cadavers were used to study the feasibility to use a large vessel patch including the aorta and vena cava for UTx (Sieunarine *et al.*, 2005b).

Rat

Methods to harvest a rat utero-tubal-ovarian graft for vascular anastomosis of the aorta and vena cava of the specimen with exclusion (Jiga *et al.*, 2003) or inclusion (Lee *et al.*, 1995) of ovarian vessels were reported. Our rat model for isolation of only the uterus and vascular transplantation (Wranning *et al.*, 2008a) included a xiphopubic incision in the donor; which would not survive the surgery. The specimen included the right uterine horn, the common uterine part, the cervix and a vaginal rim. The right uterine artery and vein were dissected cranially to the common iliac vessel, with ligations of all other branches. The duration of uterus retrieval decreased from 90 to 60 min after 30 operations (Wranning *et al.*, 2008a).

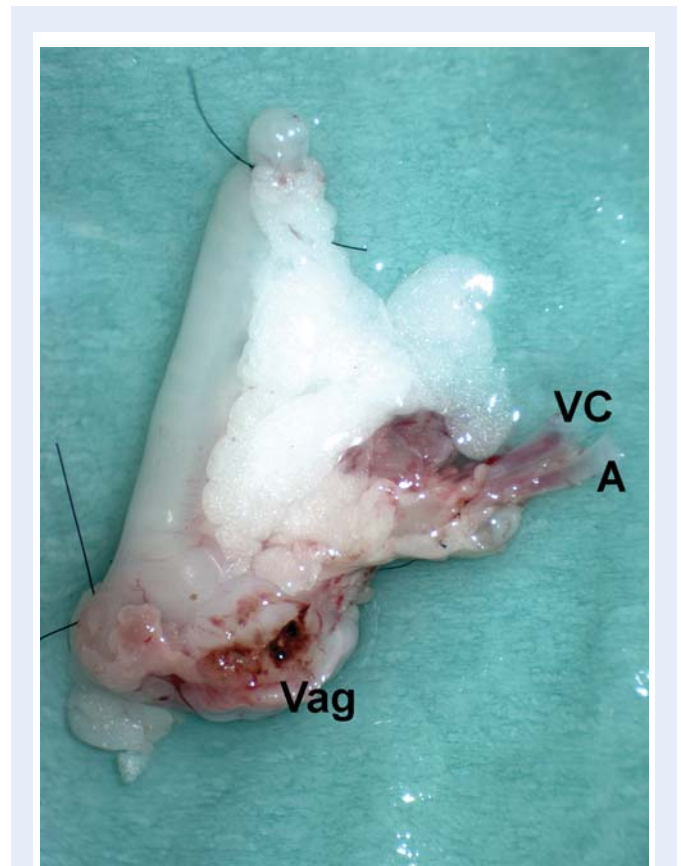


Figure 2 A mouse uterus ex vivo at backtable preparation. VC, vena cava; A, aorta; Vag, vaginal rim.

Mouse

Our initial rodent model for UTx research was the mouse (Racho El-Akouri *et al.*, 2002). The retrieval included excision of one uterine horn and both adnexae, with unilateral dissection of vasculature including the uterine vessels up to the mid-abdominal part of the aorta/vena cava (Fig. 2). The duration of uterus retrieval decreased from 60 to 45 min with increased experience (Racho El-Akouri *et al.*, 2002).

Summary: surgical technique for uterus retrieval

Techniques for uterus retrieval have been developed in several animal species and in the human UTx attempt. The procedure involves complicated retroperitoneal dissection of the pelvic vasculature and ureters. Gynaecologists, with experience in retroperitoneal surgery, should perform future human uterus retrievals, preferably together with transplant surgeons.

Ischemia-reperfusion injury

The injury of a transplant, during ischemia and reperfusion, represents a major problem. There is an initial warm ischemic period during organ retrieval, from the time of vascular clamping until cold flushing. The second warm ischemic period occurs after cold ischemia, when the

vascular anastomoses are established. The first warm ischemic period, occurring at body temperature, is more harmful than the second warm ischemic period, with a gradual increase in temperature and protection by preservation solution (Feuillu et al., 2003). The terms 'first warm ischemia (donor)' and 'second warm ischemia (recipient)' should be used for clarification (Halazun et al., 2007).

The ischemic damage to the parenchyma and the microcirculatory dysfunction (Menger et al., 1997) during reperfusion are collectively named ischemia-reperfusion injury. It is related to post-transplantation perfusion (Schramm et al. 2007), graft function (Quiroga et al., 2006) and acute (Howard et al., 1990; Totsuka et al., 2004) plus chronic (Schwarz et al., 2005) rejection. The pathophysiological mechanisms involve energy depletion (Wedenberg et al., 1995; Stoica et al., 2003), vasoconstriction (Menger and Vollmar, 2000), oxidative stress (Kayyali et al., 2001; Zhang et al., 2007), complement (Schmidt et al., 2004), cytokines (Gu et al., 2004), leukocytes (Vollmar et al., 1995) and cell death (Jaeschke and Lemasters, 2003, Kim et al., 2003). The post-ischemic inflammation induces dendritic cell maturation in the graft to initiate an adaptive immune response in the recipient (Land, 2005; Münz et al., 2005) which influences rejection progression.

Cold ischemic storage, after flushing with a cold protective buffer (Mühlbacher et al., 1999), reduces tissue-damage since metabolism declines by around 50% for every 10°C of temperature lowering (Biberthaler et al., 2001). Maximum recommended cold ischemic times are around 6 h for the heart and 36 h for the kidney.

Human

In the human trial (Fageeh et al., 2002) heparin (20 000 IU) and prednisolone were given intravenous (iv) to the uterus donor just before vascular clamping to prevent clotting and inflammation. The vagina was divided and the first warm ischemia (donor) probably extended over several minutes, until the organ was immersed *ex vivo* in cold saline and flushed with Euro-Collins solution. Experiments to minimize ischemia-reperfusion injury at human uterus retrieval from multi-organ donors (Del Priore et al., 2007) used heparin (30 000 IU) just before retrieval with flushing *in situ* with cold University of Wisconsin (UW) solution through the femoral arteries and ice slush in the pelvis. The duration of first warm ischemia (donor) was minimal. The uterus was stored in cold ischemic conditions for 12 h and morphological alterations could not be detected by light microscopy. However, sub-cellular damage of ischemia in cold-preserved human uterine tissue may only be detectable by electron microscopy (Wranning et al., 2005).

Non-human primate

The group that performed the human UTx attempt practiced on auto-UTx in baboons (Fageeh et al., 2002). The uteri were flushed with cold Euro-Collins solution with ischemic times not mentioned. Inspection of tissue texture and colour at exploration 6–12 weeks later indicated viability.

Dog

In the first publication on uterus isolation (Eraslan et al., 1966) flushing with heparinised saline through the common iliac artery of the specimen was performed with 30 min of warm ischemia. Another report

used normothermic heparinised saline until all traces of blood had washed away (Truta et al., 1969), with 45 min of warm ischemia. The early reports of allogenic utero-tubal-ovarian transplantation (Mattingly et al., 1970; Wingate et al., 1970; Paldi et al., 1975) used 20–50 ml of saline with heparin (500–1000 IU) for flushing *ex vivo* with warm ischemia around 30 min. None of the studies in the dog used cold ischemia to minimize injury.

Pig

The reports on auto-UTx in the pig assessed ischemia-reperfusion injury after cold storage *ex vivo* for 1 h in UW/Celsior (Sieunarine et al., 2005a) or Ringer Acetate (Wranning et al., 2006). Doppler and oxygen saturation measurements suggested satisfactory perfusion in one study (Sieunarine et al., 2005a). The use of Ringer Acetate for cold preservation, together with the long duration (2–3 h) of second warm ischemia during re-anastomosis may be explanations for the fact that only <20% of the uteri were adequately reperfused in our study (Wranning et al., 2006). Analysis of the venous effluents of the properly reperfused uteri showed that blood gases and lactate normalized after 60 min and that levels of thiobarbituric acid-reactive species (indicators of oxidative stress) were normal (Wranning et al., 2006), but with histology demonstrating inflammation. At heterotopic UTx in miniature breed pigs the aorta of the donor was cannulated above the level of the renal arteries for infusion of 5 l of cold UW with the uterus preserved in UW until vascular anastomosis in the recipient (Avison et al., 2009).

Sheep

In sheep auto-UTx experiments (Wranning et al., 2008b) flushing *in situ* with either Ringer Acetate or Perfadex preservation solution was followed by cold storage. The cold ischemic time was about 70 min and the second warm ischemia period, during vascular anastomosis, was about 60 min. During reperfusion (3 h), uterine vein blood samples showed minor and reversible changes in parameters related to glucose metabolism and oxidative stress. An increase in uterine neutrophil density was found and use of Perfadex was beneficial.

Rabbit

Non-vascular UTx in the rabbit involved washing *ex vivo* in 37°C lactated Ringers solution (Confino et al., 1986). Around 75% of the auto-transplanted organs were preserved.

Rat

In allogenic rat utero-tubal-ovarian transplantation flushing was done *in situ* with cold Ringer until all visible blood was flushed away, resulting in 30 min cold ischemia (Jiga et al., 2003). The second warm ischemia period lasted >60 min. Uterine blood flow was intact at 24 h but venous thromboses had formed at 72 h (Jiga et al., 2003), probably due to rejection. In syngenic utero-tubal-ovarian transplantation no details are given on ischemic conditions but all grafts showed revascularization for at least 3 months (Lee et al., 1995). In syngenic UTx (Wranning et al., 2008a) the uterus was flushed *in situ* with 2 ml of cold heparinised Ringer Acetate supplemented with xylocaine and then 1 ml of Perfadex. Cold ischemia and second warm ischemia lasted 60 and 90 min, respectively. The graft survival was 80% and only mild oedema and neutrophil influx were noted.

Mouse

In syngenic mouse UTx (Racho El-Akouri *et al.*, 2002), the uterus was flushed *in situ* with cold saline supplemented with heparin and xylocaine. The cold ischemic time was about 35 min and the second warm ischemia lasted for about 50 min. The graft survival was about 90%. To test the limits for cold ischemic preservation the uterus was later cold-stored in UW solution for 24–72 h (Racho El-Akouri *et al.*, 2003b). Uteri that had been stored *ex vivo* for 24 h regained their functionality with normal pregnancies and offspring.

Summary: ischemia-reperfusion injury in UTx

Studies of ischemia-reperfusion injury in UTx indicate that the uterus is quite resistant to ischemia. However, since there is significant impact of ischemia-reperfusion injury on transplantation outcome, any available steps to reduce the severity of this injury, should be taken.

Surgical technique for UTx

There are great changes in uterine size and blood flow during pregnancy (Mäkikallio *et al.*, 2004) and in UTx it would be important to ensure that the vascular anastomosis sites and uterine structural support are adequate. A fundamental problem in evaluating results of experimental transplantation is to separate the potentially harmful effects of ischemia-reperfusion and surgical trauma from the degenerative process of rejection. Auto- or syngenic-UTx exclude rejection effects and are commonly used, as described below.

Human

The human UTx trial (Fageeh *et al.*, 2002) ended after 99 days, when a necrotic uterus was removed because 'acute vascular occlusion appeared to be due to inadequate uterine structure support, which led to probable tension, torsion, or kinking of connected vascular grafts'. Thus, insufficiencies in both vascular anastomosis and uterine fixation may be reasons for the failure. The recipient surgery was performed through a midline incision with initial removal of the remnant cervix. The uterine arteries and veins were extended bilaterally by 6–8 cm long segments of the saphenous vein, presumably from the recipient. The cervix of the graft was sutured to the vaginal vault and the only other structural support was two sutures for 'uterosacral shortening'. The vascular anastomoses were performed bilaterally with the grafts of the three uterine veins on each side and the uterine arteries anastomosed to the external iliacs. Doppler indicated uterine perfusion for 2 months. Exogenous cyclic estrogen/gestagen induced withdrawal bleedings. It is unclear why hormonal treatment was needed since the recipient had preserved ovaries. The uterus was removed when the cervix was 'dusky-coloured' and prolapsing. The uterine arteries/veins plus vein grafts were thrombosed. It was concluded that in future attempts it would be advisable to obtain longer vascular pedicles during uterus retrieval and to increase the uterine fixation. The saphenous grafts and flushing of the vascular grafts with Euro-Collins, with its tendency to induce endothelial cell injury (Alamanni *et al.*, 2002), may be contributing factors to the thrombosis. In cases of uterus retrieval from multi-organ donors it may be possible to retrieve a vascular pedicle, including the internal

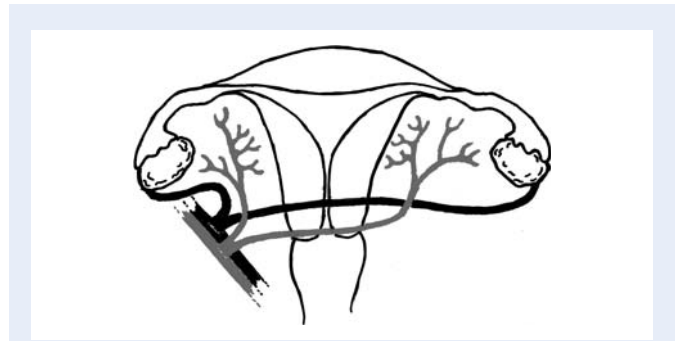


Figure 3 Schematic outline of end-to-side vascular anastomoses of the vessels of a baboon utero-tubal-ovarian graft to the external iliac vessels.

iliacs (Del Priore *et al.*, 2007) to enable direct vascular anastomosis to the external or internal iliacs.

In a future human attempt, uterine displacement would be avoided by multiple attachments such as the round ligaments to the pelvic side-walls, and reconstructions of the uterosacral ligaments and cardinal ligaments, with use of recipient tissue.

Non-human primate

The experience of UTx in non-human primates is primarily derived from auto-transplantation experiments. In preparation for the human UTx, auto-UTx in the baboon (Fageeh *et al.*, 2002) using end-to-end uterine vessel anastomosis and end-to-side anastomosis to the internal iliac vessels resulted in 75 and 10% occlusion, respectively. In our auto-UTx experiments in the baboon (unpublished observations) vascular connections were established between the anterior portion of the internal iliac artery and the ovarian veins unilaterally to the external iliac vessels (Fig. 3). The ends of the two arteries and veins of the specimen were bisected and sutured to create larger vessels for anastomosis (Fig. 4). Satisfactory reperfusion was initially seen but long-term survival of the grafts was unsatisfactory. In a human UTx situation the ovarian veins would not be used since the human uterine veins are of large diameter.

Avascular auto-UTx in the rhesus monkey by omental wrapping (Scott *et al.*, 1971) resulted in a normal-sized uterus, resumed menstruation but without pregnancy. Avascular transplantation would not be recommendable in a species with a larger uterus.

Dog

Vascular anastomosis at dog utero-tubal-ovarian transplantation mostly involved end-to-end anastomosis of the common iliac artery and end-to-side anastomosis of the internal iliac veins to the common iliacs (Eraslan *et al.*, 1966; Truta *et al.*, 1969; Yonemoto *et al.*, 1969; Mattingly *et al.*, 1970; Paldi *et al.*, 1975). In one study involving allogenic transplantation, end-to-side anastomosis of the vena cava and aorta of the graft to the same vessels of the recipient was accomplished (Wingate *et al.*, 1970). In most of these studies, the viability of the uterus after transplantation was not evaluated and the outcome cannot be determined. Some studies (O'Leary *et al.*, 1969; Scott *et al.*, 1970) examined omentopexy for vascularization with demonstration of viable uterine tissue. However, in a

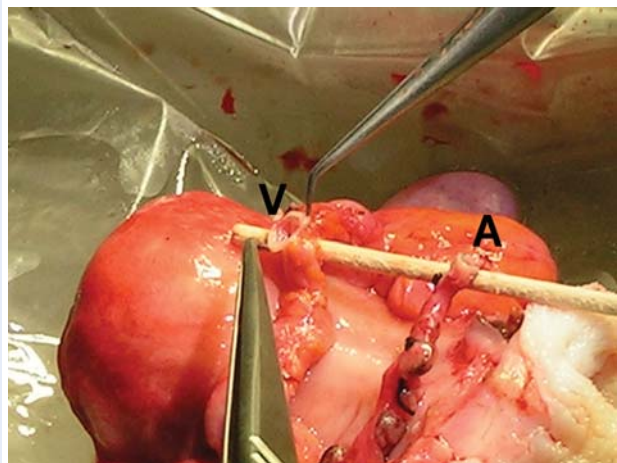


Figure 4 Baboon uterus *ex vivo* after the two ovarian arteries have been joined to create one larger vessel (A) and two ovarian veins have been joined to create a large vein (V).

comparative study all uteri in the omentopexy group were degenerated at 3 months but those transplanted by vascular anastomosis were viable (Barzilai et al., 1973).

Pig

The technique used for vascular anastomosis at auto-UTx in the pig were end-to-end anastomosis of the uterine artery and veins, well distal to their branching from the internal iliac vessels (Sieunarine et al., 2005a; Wranning et al., 2006), a technique that in human UTx only is applicable when hysterectomy is performed in the recipient so that the proximal ends of the uterine vessels are spared. Short-term function with appropriate pinkish colour of the uterus and spontaneous contractions were only seen in 20% (Wranning et al., 2006) and later thrombosis developed at the anastomosis sites (Sieunarine et al., 2005a). In a procedure of heterotopic, allogenic UTx in miniature breed pigs the lower donor aorta and vena cava of the graft were anastomosed end-to-side with the aorta and vena cava of the recipient (Avison et al., 2009).

Sheep

In sheep UTx, the anterior division of the internal iliac artery and the utero-ovarian vein were anastomosed end-to-side to the external iliacs (Dahm-Kähler et al., 2008; Fig.5). The uterus was fixed by anastomosing the vagina and suturing the uterine body to the round ligaments. The success rate, in terms of immediate reperfusion, was around 70% (Wranning et al., 2008b). In animals auto-transplanted by a similar approach, with a specimen including also the ipsilateral adnexae, pregnancies were achieved after natural mating (Wranning et al., 2009). In one pregnant ewe Caesarean section after initiation of labour revealed fetal death in a uterus which had rotated 360°. This finding further calls attention to the importance of uterine fixation and that Caesarean section should be the delivery-mode after UTx. A modified UTx procedure in the sheep with bilateral end-to-end anastomosis of the uterine vessels, showed normal uteri in 6/10 of animals 6 months later (Ramirez et al., 2008).

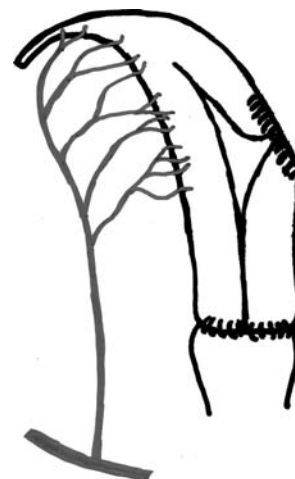

Figure 5 Schematic outline of end-to-side vascular anastomosis between the anterior branch of the left internal iliac artery of a sheep uterine graft and the external iliac vessel.

Rabbit

In the rabbit UTx report the supracervically removed uterus was fixed with sutures to the cervix and the broad ligament (Confino et al., 1986) with a 75% success rate.

Rat

The rat uterus was either isolated en-bloc together with the ovaries and oviducts (Lee et al., 1995; Jiga et al., 2003) or as a uterine graft (Wranning et al., 2008a). In utero-tubal-ovarian transplantation, the aortic and caval stumps of the graft were anastomosed either end-to-side to the aorta and vena cava (Lee et al., 1995) or end-to-end to the femoral vessels (Jiga et al., 2003), with an obvious risk of hind limb ischemia. The only other fixation was the vaginal anastomosis. The surgical outcome can only be properly evaluated in syngenic transplantations, where all animals and grafts were reported to survive (Lee et al., 1995). In our syngenic UTx experiments the right uterine horn, the common uterine cavity and the cervix was transplanted by anastomosing the right common iliac artery and vein of the graft end-to-side (Fig. 6) to the aorta and the vena cava (Wranning et al., 2008a). The native uterus was left *in situ* and the transplanted uterus was placed in a heterotopic position with the vaginal rim of the graft connected to a cutaneous stoma (Fig. 7). There was a 30% loss of transplants among the surviving animals (>95% in the last series) and the graft loss was exclusively because of thrombosis.

Mouse

In the mouse UTx-model, the graft contained one uterine horn, the common uterine cavity, the cervix and a vaginal rim (Racho El-Akouri et al., 2002). The vascular pedicles, including all vessels up to the caudal parts of the aorta and vena cava, were attached end-to-side to the aorta and vena cava although the diameters of the vessels were only 0.7 and 1.5 mm, respectively. The difficulty in these microsurgical procedures is illustrated by the fact that the survival rate was only 38% for the first 21 animals but increased to 71% (Racho

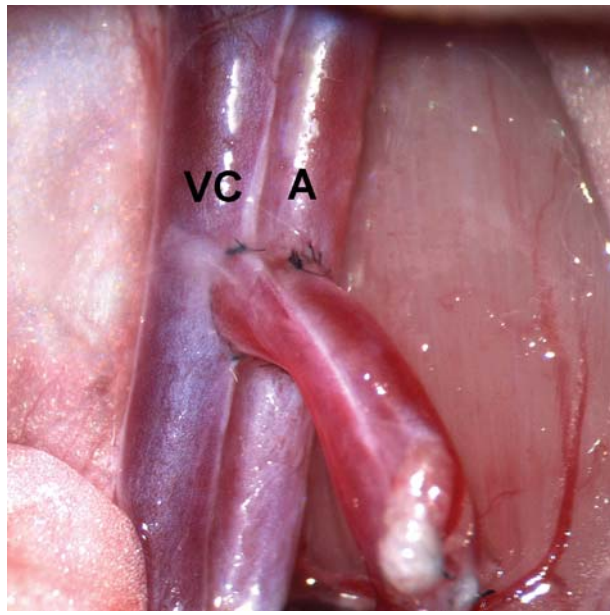


Figure 6 Close up view of end-to-side vascular anastomoses between the common iliac artery and vein of a rat uterus transplant to the vena cava (VC) and the aorta (A) of the recipient rat.

El-Akouri *et al.*, 2002) with 90% of the grafts exhibiting normal blood flow on post-operative Days 15–30.

Summary: surgical technique for UTx

There are several collective lessons learned regarding the surgical technique at UTx. Thus, neovascularization by omental wrapping does not provide the conditions needed for normal function. The surgery by itself does not seem to interfere with normal uterine function as demonstrated by achieved pregnancies in small and large animals after non-rejecting transplantation. Techniques and sites for vascular anastomosis have to be improved because of high rates of vascular thrombosis. There are still issues to be solved before a safe methodology for human use can be presented.

Rejection and immunosuppression in UTx

Rejection of a transplanted organ occurs because of orchestrated immune responses to foreign histocompatibility antigens of the graft. The rejection response to an allogenic transplanted organ varies depending on the specific organ and its setup of tissue-bound immune cells. Thus, at transplantation of tissues with high immunogenicity such as the hand (Dubernard *et al.*, 1999) and small bowel (Vianna *et al.*, 2008), there is a need for combinations of immunosuppressants including steroids but at liver transplantation steroid-free immunosuppression is used (Pirenne *et al.*, 2003; Jain *et al.*, 2005) with some patients developing tolerance (Takatsuki *et al.*, 2001).

The uterus shows variation in population/activity of immune cells during the ovarian cycle (Robertson, 2000) and pregnancy (Chaouat *et al.*, 2007) as well as tolerance of an allogenic fetus/placenta. The

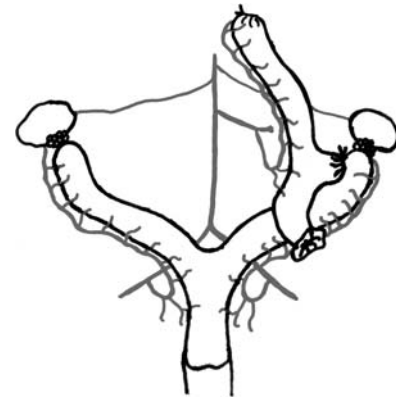


Figure 7 Schematic outline of end-to-side vascular anastomosis between the common iliac artery of a rat uterus transplant and the aorta of the recipient rat. The native uterus is left *in situ* and the cervix of heterotopically transplanted uterus is connected to a cutaneous stoma.

fetus is protected from assaults by the maternal immune system by effector T-cells, regulatory T-cells (Trowsdale and Betz, 2006) and uterine natural killer-cells (Croy *et al.*, 2003). This inherent capacity of localized tolerance during pregnancy may render an allogenic transplanted uterus to be less prone to rejection during pregnancy. Considering that human UTx would be performed in an otherwise healthy woman it is of uttermost importance that extensive research on uterine rejection, anti-rejection medication and effects of these drugs on the pregnancy/fetus is carried out before another human UTx.

According to the US Food and Drug Administration (FDA) the current pregnancy risk-categories for immunosuppressants are; category B (no evidence of risk) for corticosteroids; category C (risk cannot be ruled out) for cyclosporine A (CsA), mycophenolate mofetil, tacrolimus, rapamycin; category D (positive evidence for risk) for azathioprine. These categories cannot directly be applied to the human since they are partly based on animal data. Thus, azathioprine increases rates of fetal malformations in rodents (Githens *et al.*, 1965) but registry studies in the human do not indicate any risk (Armenti *et al.*, 1998). In most transplant programs it is recommended to avoid pregnancy during the first year since this period is needed for establishment of allograft function and for reduction of maintenance immunosuppression to moderate doses (McKay and Josephson, 2005).

The first post-transplantation pregnancy with live birth 50 years ago (Murray *et al.*, 1963) has been followed by >14 000 births (McKay and Josephson, 2006). Registry-data indicates increased risk for mild prematurity, low birthweight and hypertension/pre-eclampsia but no increased rate of structural malformations (Armenti *et al.*, 2004; McKay and Josephson, 2006). The only complete population-based study on pregnancy outcome after maternal organ transplantation (Källen *et al.*, 2005) compared pregnancies in transplanted women before and after transplantation with adjustments for age and smoking. The miscarriage-risk was increased equally before and after transplantation. There was an increased risk for preterm birth, pre-

eclampsia and small for gestational age but similar odd ratios were found in pregnancies before and after transplantation. These results strongly suggest that the major cause of pregnancy complications in transplant-patients is the underlying disease-morbidity of the mother and not the immunosuppressants, however, long-term consequences on the immune system of the offspring may exist (Scott et al., 2002).

Transplant recipients under immunosuppression are more likely to acquire some viral diseases and neoplasms with risks related to type and duration of immunosuppressants (Opelz and Döhler, 2004). A transplanted uterus would be surgically removed after the woman has given birth once or twice, and immunosuppressants are only needed during a restricted time. Moreover, strategies to induce allo-tolerance may be developed in the future (Golshayan et al., 2007).

Human

The immunosuppressants used in the human UTx case (Fageeh et al., 2002) were CsA (6 h prior to surgery) and prednisolone (at surgery-start and uterine perfusion) followed by conventional CsA, azathioprine and prednisolone. Possible rejection was monitored by CD4/CD8-ratio in blood and Doppler of uterine blood flow, but for some reason cervical/endometrial biopsies were not used. The uterus was removed at Day 99 when the uterus was 'infected' and the uterine vessels were thrombosed. Since necrosis and thrombosis are signs of full rejection, this could be the reason for the demise of the organ rather than 'torsion and kinking of the vessels secondary to inadequate structural support', as suggested. The oviducts were of normal histology, which is difficult to comprehend since these were also supplied via the uterine arteries.

In future human UTx a modern protocol for immunosuppressant medication, including tacrolimus, should be used and it may well be that the doses of immunosuppressants could be lowered during pregnancy because of induced local immunological tolerance (Trowsdale and Betz, 2006).

Non-human primate

Non-human primates have been extensively used for studies of various immunosuppressants after allotransplantation (Todo et al., 1988) but these results cannot directly be extrapolated to the human, as illustrated by that triple regimen of immunosuppressants is subtherapeutic in composite tissue allotransplantation in monkeys (Cendales et al., 2005) but therapeutic in human hand transplantation (Siemionow, 2005). Only one study (Scott et al., 1971) has examined rejection after allo-UTx in a non-human primate. Subtotal hysterectomy-grafts, with neovascularization by omental wrapping, showed presence of endometrium 1 week post-transplantation. Rejection signs then appeared initially in the endometrium and after 14 days full rejection was present.

Dog

Rejection of allogenic transplanted uterus plus adnexae was first described in the dog (Truta et al., 1969). Azathioprine and cortisone were later used (Yonemoto et al., 1969) and some therapeutic effects were indicated by variable degrees of rejection up to 49 days after surgery. Perivascular accumulation of inflammatory cells was followed by loss of endometrium. In a more detailed study of azathioprine and cortisone after utero-tubal-ovarian transplantation, oedema and

hyperemia were seen on Day 4 (Wingate et al., 1970), followed by haemorrhage, patchy necrosis and intravascular thrombosis. Similar results, with identical immunosuppressant combination, were seen after avascular UTx (Scott et al., 1970).

Pig

In heterotopic, allogenic UTx in miniature breed pigs, iv tacrolimus was administered for 12 days post-transplantation and then oral CsA was given (Avison et al., 2009) since it was difficult to achieve satisfactory blood levels of tacrolimus with oral administration. In addition, methylprednisolone was used for 3 months. The acute rejection episodes, detected by endoscopy through the stoma and endometrial biopsy, were successfully treated with increased maintenance immunosuppression and steroids. The survival of the six allogenic transplanted animals were between 0.2 and 6.7 months, but details on the grades of uterine rejection in these cases were not given.

Sheep

Sheep to be allogenic transplanted with uterine grafts were treated with CsA plus prednisone starting 2 days before surgery (Ramirez et al., 2008) and with prednisone discontinued after 2 weeks. Laparotomy 6 months after surgery showed pronounced abdominal adhesions in 7/10 animals and blood-perfused uteri in 6/10 animals. Histology revealed patchy lymphocytic infiltration. Our allo-UTx sheep experiments with CsA/tacrolimus and prednisone showed fluctuating CsA levels and stable tacrolimus levels (Wranning et al., 2008c). In both groups mild inflammation was seen.

Rabbit

In the only study of allo-UTx in the rabbit, single therapy with CsA preserved the endometrium and myometrium 1 month after avascular transplantation (Confino et al., 1986).

Rat

Allogenic rat utero-tubal-ovarian grafts were used to study the time course of uterus rejection (Jiga et al., 2003). After 72 h, the anastomosis sites were thrombosed and the uteri were necrotic. In our ongoing experiments on semiallogenic UTx in the rat we use a protocol with moderate doses of CsA/tacrolimus, which has been shown to effectively suppresses rejection after rat composite tissue transplantation (Siemionow et al., 2005).

Mouse

In a fully allogenic mouse UTx model major inflammation and reduction of blood flow was seen from Day 10 to 15 with massive necrosis Day 28 (El-Akouri et al., 2006). In a follow-up study, we found early (Day 2–5) invasion of neutrophils and macrophages followed by influx of cytotoxic T-cells (Groth et al., 2009). In semiallogenic UTx CsA delayed, but not fully suppressed, rejection (Wranning et al., 2007).

Summary: rejection and immunosuppression in UTx

A handful of studies on immunosuppression to prevent rejection after UTx have been published. However, no treatment protocol,

successful in terms of long-term survival and functionality of the graft, has been presented. It is obvious that detailed studies addressing this issue and with a high success rates are needed before another human UTx attempt.

Pregnancy and offspring in UTx

Apart from the ability to establish pregnancy after UTx, it is also important to determine that pregnancy and offspring are not negatively affected. The negative effects may not only relate to immunosuppressants but also to altered uterine blood/lymphatic flow, denervation or changed uterine fixation.

Human

In the human UTx there was no pregnancy attempt (Fageeh *et al.*, 2002). Among organ-transplanted patients pregnancy is regarded as safe after the first post-transplant year if rejection episodes have not occurred and then generally the nadir immunosuppressant doses are reached (McKay and Josephson, 2006). A prospective UTx patient should undergo IVF treatment prior to transplantation since it is essential to ensure fertilization-potential within the couple and since embryo cryopreservation would decrease embryo exposure to immunosuppressants. An IVF procedure after transplantation would be more unsafe because of altered vascular anatomy and risk of pelvic infection due to the immunosuppressed state. It would be essential to avoid severe ovarian hyperstimulation syndrome, with associated hypercoagulability (Rogolino *et al.*, 2003), and risk of thrombosis at the anastomosis sites.

Non-human primate

There is no reported pregnancy in non-human primates either after auto- or allo-UTx. After avascular auto-UTx in rhesus monkeys three animals were placed with males for 10 months but no pregnancy occurred (Scott *et al.*, 1971). It was speculated that the infertility was due to non-preserved tubal patency during the post-transplantation ischemic period of several days (Scott *et al.*, 1971). In future experiments involving UTx in non-human primates the use of IVF would be advantageous to mimic the human situation and to achieve pregnancies after non-oviductal UTx.

Dog

After auto-transplantation of utero-tubal-ovarian grafts in dogs, five pregnancies (11% pregnancy rate) with live births were seen, in the studies where pregnancy was one end-point (Eraslan *et al.*, 1966; Truta *et al.*, 1969; Barzilai *et al.*, 1973). However, these experiments involved only short ischemic periods and the uterus was never outside the abdomen.

Pig and sheep

There are no reported pregnancies after UTx in the pig. In a small series of sheep that had undergone utero-tubal-ovarian auto-transplantation by vascular anastomosis to the external iliac vessels pregnancies were achieved in three out of five animals (Wranning *et al.*, 2009). Deliveries were through Caesarean section.

Rabbit and rat

There are no reported pregnancies after UTx in the rabbit or the rat.

Mouse

Pregnancy in a strictly transplanted uterus of any species was first reported in the mouse (Racho El-Akouri *et al.*, 2002). These were syngenic transplants and pregnancies were achieved after embryo transfer. In a modified mouse UTx model, with the cervix of the transplanted uterus brought to a cutaneous stoma, the implantation and pregnancy rates of the transplanted uteri were similar to that of the native uteri (Racho El-Akouri *et al.*, 2003a). Moreover, birth-weight, growth trajectory and offspring fertility were normal.

Summary: pregnancy and offspring in UTx

Although no pregnancies have been achieved after allo-UTx, a few studies in non-rejecting settings have shown that surgery and novel vascular connections are not likely to interfere with pregnancy. It is clear that more research is needed in animal models before a new human attempt. Our opinion is that safe pregnancies and healthy offspring have to be demonstrated in allo-UTx in one animal species and that there has to be a proof of concept of surgery in a non-human primate species. This latter experiment could involve auto-UTx to a new vascular supply after cold storage.

Ethics and institutional requirements

It is important that UTx is thoroughly discussed from an ethical perspective. This discussion should be brought forward in parallel with animal research. Moreover, certain requirements should apply to a group/institution that would pursue human UTx. A surgical innovation, such as UTx, should appear in the operating theatre only after extensive laboratory work on all aspects of the procedure, in order to maximize success rate. Ethical considerations regarding UTx were recently brought forward by the FIGO Committee for the Ethical Aspects of Human Reproduction and Womens's Health (Milliez, 2009). Concerning surgical innovations, laboratory background, field strength and institutional stability should be considered from ethical standpoints (Moore, 1970, 2000).

The laboratory background of UTx should involve extensive experience of the procedure in several species and with excellent success rate, taking into account the learning curve of UTx surgery (Wranning *et al.*, 2008a). The animal models should involve non-human primates, to include experimental circumstances which would be similar to human UTx. Studies of human pelvic vascular anatomy could also be considered, if these could be carried out at elective surgery or by radiological examinations for clinical reasons.

Satisfactory field strength implies expertise and long tradition of the institution in all clinical fields that may be involved. Experienced psychologists should be involved in the screening process of potential uterus recipients and living donors. Specialists in reproductive medicine should assess the patient and her partner before transplantation to assure excellent fertility potential and to carry out IVF. Gynaecologists, trained in retroperitoneal pelvic surgery, should perform surgery in collaboration with transplant surgeons to optimize organ retrieval,

cold-ischemia preservation, backtable preparation and vascular anastomosis. Specially trained pathologists and transplant surgeons would be highly needed after transplantation for assessment of rejection and guidance of immunosuppressant therapy. It is also central that obstetricians with experiences in antenatal care of transplant patients and high-risk obstetrics are involved.

Institutional stability implies that an innovative surgical procedure, such as UTx, should only be carried out in a hospital where there is sufficient support for the experimental procedure and with team-members that have worked together for a long time. Evaluation of stability of the institution and the team should include assessment of resources and commitment to care for a living donor, the recipient and her partner as well as for the future child for many years.

The important ethical principle of a dominance of benefits over risks should thoroughly be analyzed also for UTx, where four subjects may be involved; the donor (living or deceased) with immediate family, the recipient, the partner of the recipient who is also the prospective father, and the future child.

Concerning the donor and its family, a uterus from a multi-organ donor does not involve any risks for the donor. However, the relatives may be unfamiliar with a situation where the donor have consented to donation of an organ that previously may have harboured a fetus, that today may be a family member.

We consider that the most suitable living donor would be a mother or an older sister who has decided that she has completed her child-bearing period. The likelihood of a reasonable tissue type match would be increased. The risks taken by the donor would be similar to the risks related to hysterectomy (Spilsbury et al., 2008), the most common major surgical procedure in women today. We acknowledge that the surgical procedure of uterus retrieval from a living donor is more extensive than a total abdominal hysterectomy, but balancing this is that uterus retrieval would be carried out by extremely well-trained surgeons with vast experience of the procedure in experimental animals. It is important that the donor is informed about the risk panorama and that her understanding of potential risks is evaluated during consultations before donation. Medical consultations, before and after donation, should be offered and performed by physicians/psychologists with previous experience from other living donor cases. These practitioners should be separate from those caring for the recipient in order to protect donor autonomy. The most common living organ donation is the kidney with excellent outcome after donations from close relatives (Terasaki et al., 1995). In a large transplantation unit expertise for living kidney donor care exists on all levels and this should be useful in living uterus donation.

The uterus recipient and her partner do, prior to becoming a candidate couple, have to be well informed about other alternatives than UTx to form a family. These alternatives are to accept the infertility, adoption of a child or gestational surrogacy. Genetic parenthood can be acquired through gestational surrogacy and this procedure has the benefits over UTx to exclude risks related to surgery and immunosuppressants. However, at gestational surrogacy you put the pregnancy-morbidity risk on another person, you cannot control for lifestyle factors including smoking/alcohol, and legal conflicts about the motherhood of the newborn may emerge. Psychological counselling of the future uterus recipient at many occasions before surgery should be mandatory, including evaluation of her understanding of

Table 1 Experimental animal studies which should be performed and show favourable outcome before the next human UTx is performed

Type of study	Species
Allogenic UTx under immunosuppression and fertility/offspring	Rat/mouse
Fetal immunosuppression exposure and longterm effects	Rat/mouse
Autologous UTx and fertility	Non-human primate
Long-term graft survival after allogenic UTx	Non-human primate

the procedure, risks and need for monitoring possible episodes of rejection. Also, evaluation of risk of non-adherence to immunosuppressive medication is needed since around 30% of organ transplant recipients are non-adherent during some period (Nevins and Matas, 2004). The surgical risks of the uterus recipient would be equal to any open pelvic surgery with the addition of risks related to vascular anastomosis surgery. The uterus recipient should also be informed about the risks connected to use of immunosuppressants in general with increased risks for certain viral infections and malignancies (Opelz and Döhler, 2004). These risks are connected to the type of immunosuppressants used and the duration of treatment. In human UTx, we anticipate that the transplanted organ would be removed within 3 years, thus considerably reducing these risks.

The risks for the fetus/prospective child should be assessed. There does not seem to be increased perinatal risk due maternal immunosuppression (Källen et al., 2005) but long-term effects of fetal exposure to immunosuppressants may exist (Padgett and Seelig, 2002; Scott et al., 2002). The risk assessment for the fetus has to consider that the new vascular supply or altered uterine fixation may affect the pregnancy. Many planned pregnancies today are associated with increased risks for fetal complications, such as congenital malformations in pregnancies of diabetics (Plagemann et al., 2008) but these risks are balanced against the wish of parents. In situations where unanticipated maternal health problems occur during pregnancy after UTx, the life of the mother should be the priority.

It is important that all anticipated risks of UTx are identified and defined prior to human UTx. Established exit strategies for each of the identified risks should be included in a research protocol for human UTx.

Ethical questions regarding UTx touch on fundamental issues concerning perception of procreation and parenthood as well as of medical advancements. These perceptions are not globally homogenous and the diversity in moral, religious and philosophical values in different societies will most likely render human UTx acceptable in some societies and unacceptable in others.

Conclusions

In this review on UTx research, we summarize the results of experimental studies and the first human UTx attempt. We also discuss points of concern regarding requirements that need to be fulfilled by

the institution and team pursuing future human UTx. Several appropriate animal models for experimental UTx have been developed and the surgical techniques can be modified for use in a future human case. The results indicate that the uterus is resistant to ischemia-reperfusion injury and after transplantation exhibits normal function and ability to carry pregnancies, at least in non-rejecting situations. There are some key studies which should be performed and show successful outcome before the next human UTx is performed (Table I). Considering the current state and activity of research we predict that the next human UTx will be performed within 5 years.

Funding

The Swedish Research Council, The Sahlgrenska Academy ALF, Hjalmar Svensson Research Foundation.

References

- Aboulgar MA, Mansour RT, Serour GI. Controversies in the modern management of hydrosalpinx. *Hum Reprod Update* 1998;**4**:882–890.
- Alamanni F, Parolari A, Visigalli R, Bussolati O, Rubini P, Sala R, Bonati L, Gazzola GC, Biglioli P, Dall'Asta V. Endothelial cell injury induced by preservation solutions: a confocal microscopy study. *Ann Thorac Surg* 2002;**73**:1606–1615.
- Al-Inany H. Intrauterine adhesions. An update. *Acta Obstet Gynecol Scand* 2001;**80**:986–993.
- Altchek A. Uterus transplantation. *Mount Sinai J Med* 2003;**70**:154–162.
- Andersen CY, Rosendahl M, Byskov AG, Loft A, Ottosen C, Dueholm M, Schmidt KL, Andersen AN, Ernst E. Two successful pregnancies following autotransplantation of frozen/thawed ovarian tissue. *Hum Reprod* 2008;**23**:2266–2272.
- Andrae B, Kemeti L, Sparen P, Silfverdal L, Strander B, Ryd W, Dillner J, Törnberg S. Screening-preventable cervical cancer risks: evidence from a nationwide audit in Sweden. *J Natl Cancer Inst* 2008;**100**:605–606.
- Armenti VT, Moritz MJ, Davison JM. Drug safety issues in pregnancy following transplantation and immunosuppression: effects and outcomes. *Drug Saf* 1998;**19**:219–213.
- Armenti VT, Radomski JS, Moritz MJ, Gaughan WJ, Hecker WP, Lavelant A, McCroy CH, Coscia LA. Report from the National Transplantation Registry (NTPR): outcomes of pregnancy after transplantation. *Clin Transpl* 2004;**18**:103–114.
- Asherman JG. Amenorrhoea traumatica. *J Obstet Gynaecol Br Emp* 1948;**55**:23–30.
- Avison DL, DeFaria W, Tryphonopoulos P, Tekin A, Attia GR, Takahashi H, Jin Y, Palaois N, Pararas N, Carreno MR et al. Heterotopic uterus transplantation in a swine model. *Transplantation* 2009;**88**:465–469.
- Baird DT, Land RB, Scaramuzzi RJ, Wheeler AG. Functional assessment of the autotransplanted uterus and ovary in the ewe. *Proc R Soc Lond B Biol Sci* 1976;**192**:463–474.
- Barzilai A, Paldi E, Gal D, Hampel N. Autotransplantation of the uterus and ovaries in dogs. *Israel J Med Sci* 1973;**9**:49–52.
- Bath LE, Critchley HOP, Chambers SE, Anderson RA, Kelnar CJH, Wallace WHB. Ovarian and uterine characteristics after total body irradiation in childhood and adolescence: response to sex steroid replacement. *Br J Obstet Gynecol* 1999;**106**:1265–1272.
- Biberthaler P, Luchting B, Massberg S, Teupser D, Langer S, Lederer R, Messmer K, Krombach F. The influence of organ temperature on hepatic ischemia-reperfusion injury: a systemic analysis. *Transplantation* 2001;**72**:1486–1490.
- Birchall MA, Lorenz RR, Berke GS, Genden EM, Haughey BH, Siemionow M, Strome M. Laryngeal transplantation in 2005: a review. *Am J Transplant* 2006;**6**:20–26.
- Borgfeldt C, Andolf E. Transvaginal ultrasonographic findings in the uterus and endometrium: low prevalence of leiomyoma in a random sample of women age 25–40 years. *Acta Obstet Gynecol Scand* 2000;**79**:202–207.
- Bosch FX, Burchell AN, Schiffman M, Giuliano AR, de Sanjose S, Bruni L, Tortolero-Luna G, Kjaer SK, Munoz N. Epidemiology and natural history of human papilloma infections and type-specific implications in cervical neoplasia. *Vaccine* 2008;**26**:K1–K16.
- Brännström M, Milenkovic M. Advances in fertility preservation for female cancer survivors. *Nat Med* 2008;**14**:1182–1184.
- Brännström M, Wranning CA, El-Akouri RR. Transplantation of the uterus. *Mol Cell Endocrinol* 2003;**202**:177–184.
- Brucker SY, Gegusch M, Zubke W, Rall K, Gauwerky JF, Wallwiener D. Neovagina creation in vaginal agenesis: development of a new laparoscopic Vecchiotti-based procedure and optimized instruments in a prospective comparative interventional study in 101 patients. *Fertil Steril* 2008;**90**:1940–1952.
- Bukulmez O, Yarali H, Gurgan T. Total corporal synechiae due to tuberculosis carry a very poor prognosis following hysteroscopic synechialysis. *Hum Reprod* 1999;**14**:1960–1961.
- Buttram VC. Müllerian anomalies and their management. *Fertil Steril* 1983;**40**:159–163.
- Carson SA, Simpson JL, Malinak LR, Elias S, Gerbie AB, Buttram VC, Sarto GE. Heritable aspects of uterine anomalies. II. Genetic analysis of müllerian aplasia. *Fertil Steril* 1983;**40**:86–90.
- Cendales LC, Xu H, Bacher J, Eckhaus MA, Kleiner DE, Kirk AD. Composite tissue allotransplantation: development of a preclinical model in nonhuman primates. *Transplantation* 2005;**80**:1447–1454.
- Chaouat G, Ledée-Bataille N, Dubanchet S. Immune cells in uteroplacental tissues throughout pregnancy: a brief review. *Reprod Biomed Online* 2007;**14**:256–266.
- Chen CR, Buck GM, Courey NG, Perez KM, Wactawiski-Wende J. Risk factors for uterine fibroids among women undergoing tubal sterilization. *Am J Epidemiol* 2001;**153**:20–26.
- Cicinelli E, Einer-Jensen N, Galantino P, Alfonso R, Nicoletti R. The vascular cast of the human uterus: from anatomy to physiology. *Ann NY Acad Sci* 2004;**1034**:19–26.
- Cohen BM. Vascularised transplantation of the Fallopian tube in the human female: a proposed surgical technique. *Int J Fert* 1976;**21**:33–46.
- Confino E, Vermesh M, Thomas W Jr, Gleicher N. Non-vascular transplantation of the rabbit uterus. *Int J Gynaecol Obstet* 1986;**24**:321–325.
- Connolly G, Doyle M, Barrett T, Byrne P, De Mello M, Harrison RF. Fertility after abdominal myomectomy. *J Obstet Gynaecol* 2000;**20**:418–420.
- Creasman WT, Odicino F, Maisonneuve P, Quinn MA, Beller U, Benedet JL, Heintz APM, Ngan HYS, Pecorelli S. Carcinoma of the uterine corpus uteri. FIGO 6th annual report on the results of treatment in gynaecological cancer. *Int J Gynaecol Obstet* 2006;**83**:S105–S143.
- Critchley HOD, Wallace WHB. Impact of cancer treatment on uterine function. *J Natl Cancer Inst Monogr* 2005;**34**:64–68.
- Croy BA, He H, Esadeg S, Wei Q, McCartney D, Zhang J, Borzychowski A, Ashkar AA, Black GP, Evans SS et al. Uterine natural killer cells: insights into their cellular and molecular biology from mouse modelling. *Reproduction* 2003;**126**:149–160.
- D'Argent D, Martin X, Saccheoni A, Mathevet P. Laparoscopic vaginal radical trachelectomy: a treatment to preserve the fertility of cervical carcinoma patients. *Cancer* 2000;**88**:1877–1882.

- Dahm-Kähler P, Wranning C, Lundmark C, Enskog A, Mölne J, Marcickiewicz J, El-Akouri RR, McCracken J, Brännström M. Transplantation of the uterus in the sheep: methodology and early reperfusion events. *J Obstet Gynaecol Res* 2008;**34**:784–793.
- Davies MC, Creighton SM. Vaginoplasty. *Curr Opin Urol* 2007;**17**:425–418.
- Del Priore G, Stega J, Sieunarine K, Ungar L, Smith JR. Human uterus retrieval from a multi-organ donor. *Obstet Gynecol* 2007;**107**:101–104.
- Demeestere I, Simon P, Emiliani S, Delbaere A, Englert Y. Fertility preservation: successful transplantation of cryopreserved ovarian tissue in a young patient previously treated for Hodgkin's disease. *Oncologist* 2007;**12**:1437–1442.
- Devauchelle B, Badet L, Lengele B, Morelon E, Testelin S, Michallet M, D'Hauthuille C, Dubernard JM. First human face allograft: early report. *Lancet* 2006;**368**:203–209.
- Donnez J, Dolmans MM, Demylle D, Jadoul P, Pirard C, Squifflet J, Martinez-Madrid B, van Langendonck A. Livebirth after orthotopic transplantation of cryopreserved ovarian tissue. *Lancet* 2004;**364**:1405–1410.
- Donnez J, Martinez-Madrid B, Jadouls P, van Langendonck A, Demylle D, Dolmans MM. Ovarian tissue cryopreservation and transplantation: a review. *Hum Reprod Update* 2006;**12**:519–535.
- Dubernard JM, Owen E, Herzberg G, Lanzetta M, Martin X, Kapila H, Dawahra M, Hakim NS. Human hand allograft: report on first 6 months. *Lancet* 1999;**353**:1315–1320.
- El-Akouri RR, Mölne J, Groth K, Kurlberg G, Brännström M. Rejection patterns in allogenic uterus transplantation in the mouse. *Hum Reprod* 2006;**21**:436–442.
- El-Hamamy E, B-Lynch C. A worldwide review of the uses of the uterine compression suture techniques as alternative to hysterectomy in the management of severe post-partum haemorrhage. *J Obstet Gynaecol* 2005;**24**:143–149.
- Eraslan S, Hamernik RJ, Hardy JD. Replantation of uterus and ovaries in dogs, with successful pregnancy. *Arch Surg* 1966;**92**:9–12.
- Fageeh W, Raffa H, Jabbad H, Marzouki A. Transplantation of the human uterus. *Int J Gynecol Obstet* 2002;**76**:245–251.
- Farhi J, Ashkenazi J, Feldberg D, Dicker D, Orvieto R, Ben Rafael Z. Effect of uterine leiomyomata on *in-vitro* fertilisation treatment. *Hum Reprod* 1995;**10**:2576–2578.
- Farquhar CM, Steiner CA. Hysterectomy rates in the United States 1990–1997. *Obstet Gynecol* 2002;**99**:229–234.
- Fernandez H, Sefrioui O, Virelizier C, Gervaise A, Gomel V, Frydman R. Hysteroscopic resection of submucosal myomas in patients with infertility. *Hum Reprod* 2001;**16**:1489–1492.
- Fernandez H, Al-Najjar F, Chauveud-Lambling A, Frydman R, Gervaise A. Fertility after treatment of Asherman's syndrome stage 3 and 4. *J Minim Invasive Gynecol* 2006;**13**:398–402.
- Feuillu B, Cormier L, Frimat L, Kessler M, Amrani M, Mangin P, Hubert J. Kidney warming during transplantation. *Transpl Int* 2003;**165**:307–312.
- Folch M, Pigem I, Konje JC. Müllerian agenesis: etiology, diagnosis, and management. *Obstet Gynecol Surv* 2000;**55**:644–649.
- Friedler S, Margalioth EJ, Kafka I, Yaffe H. Incidence of post-abortion intrauterine adhesions evaluated by hysteroscopy—a prospective study. *Hum Reprod* 1993;**8**:442–444.
- Githens JH, Rosenkrantz JG, Tunnock SM. Teratogenic effects of azathioprine (Imuran). *J Pediatr* 1965;**66**:959–961.
- Goldfarb JM, Austin C, Peskin B, Lisbona H, Desai N, Loret de Mola JR. Fifteen years experience with an *in-vitro* fertilization surrogate gestational pregnancy programme. *Hum Reprod* 2000;**15**:1075–1078.
- Golshayan D, Buhler L, Lechler RI, Pasqual M. From current immunosuppressive strategies to clinical tolerance of allografts. *Transpl Int* 2007;**20**:12–24.
- Griffin JE, Edwards C, Madden JD, Harrod MJ, Wilson JD. Congenital absence of the vagina. The Mayer–Rokitansky–Kuster–Hauser syndrome. *Ann Intern Med* 1976;**85**:224–236.
- Grimbizis GF, Camus M, Tarlatzis BC, Bontis JN, Devroey P. Clinical implications of uterine malformations and hysteroscopic treatment results. *Hum Reprod Update* 2001;**7**:161–174.
- Groth K, El-Akouri R, Wranning CA, Mölne J, Brännström M. Rejection of allogenic uterus transplant in the mouse – time-dependent and site-specific infiltration of leukocyte subtypes. *Hum Reprod* 2009;**24**:2746–2754.
- Gu XP, Qiu YD, Xu FT, Jiang Y, Ding YT. *In vivo* suppressive effect of nuclear factor-kappa B inhibitor on neutrophilic inflammation of grafts after orthotopic liver transplantation in rats. *World J Gastroenterol* 2004;**10**:3654–3658.
- Guerrier D, Mouchel T, Pasquier L, Pellerin I. The Mayer–Rokitansky–Küster–Hauser syndrome (congenital absence of uterus and vagina)—phenotypic manifestations and genetic approaches. *J Neg Results Biomed* 2006;**5**:1–8.
- Habek D, Becarevic R. Emergency peripartum hysterectomy in a tertiary obstetric center: 8-year evaluation. *Fetal Diagn Ther* 2007;**22**:139–142.
- Halazun KJ, Al-Mukhtar A, Aldouri A, Willis S, Ahmad N. Warm ischemia in transplantation: search for a consensus definition. *Transplant Proc* 2007;**39**:1329–1331.
- Hauser GA, Schreiner WE. Das Mayer–Rokitansky–Küster syndrome. *Schweiz Med Wochenschr* 1961;**91**:381–384.
- Heinonen PK, Saarikoski S, Pystynen P. Reproductive performance of women with uterine anomalies: an evaluation of 182 cases. *Acta Obstet Gynecol Scand* 1982;**61**:157–162.
- Hilger WS, Magrina JF, Magtibay PM. Laparoscopic management of the adnexal mass. *Clin Obstet Gynecol* 2006;**49**:535–548.
- Holm K, Nysom K, Brocks V, Hertz H, Jacobsen N, Müller J. Ultrasound B-mode changes in the uterus and ovaries and Doppler changes in the uterus after total body irradiation and allogeneic bone marrow transplantation in childhood. *Bone Marrow Transplant* 1999;**23**:259–263.
- Homer HA, Li TC, Cooke ID. The septate uterus: a review of management and reproductive outcome. *Fertil Steril* 2000;**73**:1–14.
- Howard TK, Klintmalm GB, Cofer JB, Husberg BS, Goldstein RM, Gonwa TA. The influence of preservation injury on rejection in the hepatic transplant recipient. *Transplantation* 1990;**49**:103–107.
- Jaeschke H, Lemasters JJ. Apoptosis versus oncotic necrosis in hepatic ischemia/reperfusion injury. *Gastroenterology* 2003;**125**:1246–1257.
- Jain A, Marcos A, Reyes J, Mazariagos G, Kashyap R, Eghtesad B, Marsh W, Fontas P, De Vera M, Costa G et al. Tacrolimus for primary liver transplantation: 12 to 15 years actual follow-up with safety profile. *Transplant Proc* 2005;**37**:1207–1210.
- Jiga LP, Lupu CM, Zoica BS, Ionac M. Experimental model of heterotopic uterus transplantation in the laboratory rat. *Microsurgery* 2003;**23**:246–250.
- Jones HW, Mermut S. Familial occurrence of congenital absence of the vagina. *Am J Obstet Gynecol* 1972;**114**:1100–1101.
- Källen B, Westgren M, Åberg A, Otterblad Olausson P. Pregnancy outcome after maternal organ transplantation in Sweden. *Br J Obstet Gynaecol* 2005;**112**:904–909.
- Kandela P. Uterine transplantation failure causes Saudi Arabian government clampdown. *Lancet* 2000;**356**:838.
- Kayyali US, Donaldson C, Huang H, Abdelnour R, Hassoun PM. Phosphorylation of xanthine dehydrogenase/oxidase in hypoxia. *J Biol Chem* 2001;**276**:14359–14365.
- Kim JS, Qian T, Lemasters JJ. Mitochondrial permeability transition in the switch from necrotic to apoptotic cell death in ischemic rat hepatocytes. *Gastroenterology* 2003;**124**:494–503.

- Küster H. Uterus bipartitus solidus rudimentarius cum vagina solida. *Z Geburtshilfe Gynäkol* 1910;**91**:381–384.
- Kwee A, Bots ML, Visser GH, Bruinse HW. Emergency peripartum hysterectomy: a prospective study in the Netherlands. *Eur J Obstet Gynecol Reprod Biol* 2006;**124**:187–192.
- Land WG. The role of postischemic reperfusion injury and other nonantigen-dependent inflammatory pathways in transplantation. *Transplantation* 2005;**79**:505–514.
- Larsen EC, Schmiegelow K, Rechnitzer C, Loft A, Müller J, Nyboe-Andersen A. Radiotherapy at a young age reduces uterine volume of childhood cancer survivors. *Acta Obstet Gynecol Scand* 2004;**83**:96–102.
- Lee S, Mao L, Wang Y, D'Silva M, Yoo CH, Wolf D, Chung WS, Takahashi E, Chung DY, Gittes RF. Transplantation of reproductive organs. *Microsurgery* 1995;**16**:191–198.
- Levi DM, Tzakis AG, Kato T, Madariaga J, Mittal NK, Nery J, Nishida S, Ruiz P. Transplantation of the abdominal wall. *Lancet* 2003;**361**:2173–2176.
- Lönnroth K, Raviglione M. Global epidemiology of tuberculosis: prospects for control. *Semin Respir Crit Care Med* 2008;**29**:481–491.
- Mäkikallio K, Tekay A, Jouppila P. Uteroplacental hemodynamics during early human pregnancy: a longitudinal study. *Gynecol Obstet Invest* 2004;**58**:49–54.
- Marino JL, Eskenazi B, Warner M, Samuels S, Vercellini P, Gavoni N, Olive D. Uterine leiomyoma and menstrual cycle characteristics in a population-based cohort study. *Hum Reprod* 2004;**19**:2350–2355.
- Marshall LM, Spiegelman D, Barbieri RL, Goldman MB, Manson JE, Colditz GA, Willett WC, Hunter DJ. Variation in the incidence of uterine leiomyoma among premenopausal women by age and race. *Obstet Gynecol* 1997;**90**:967–973.
- Mattingly RF, Clark DO, Lutsky II, Huang WY, Staff A, Maddison FE. Ovarian function in uteroovarian homotransplantation. *Am J Obstet Gynecol* 1970;**108**:773–794.
- Mayer CA. Über verdoppelungen des uterus und ihre arten, nebst bemerkungen über hasenscharte und wolfsrachen. *J Chir Augen* 1829;**13**:525–564.
- McCracken JA, Baird DT, Goding JR. Factors affecting the secretion of steroids from the transplanted ovary in the sheep. *Recent Progr Horm Res* 1971;**27**:537–582.
- McKay DB, Josephson MA. Reproduction and transplantation: report on the AST consensus conference on reproductive issues and transplantation. *Am J Transplant* 2005;**5**:1592–1599.
- McKay DB, Josephson MA. Pregnancy in recipients of solid organs—effects on mother and child. *N Engl J Med* 2006;**354**:1281–1293.
- Meirow D, Levron J, Eldar-Geva T, Hardan I, Fridman E, Zalel Y, Schiff E, Dor J. Pregnancy after transplantation of cryopreserved ovarian tissue in a patient with ovarian failure after chemotherapy. *N Engl J Med* 2005;**353**:318–321.
- Menger MD, Rücker M, Vollmar B. Capillary dysfunction in striated muscle ischemia/reperfusion: on the mechanisms of capillary 'no-reflow'. *Shock* 1997;**8**:2–7.
- Menger MD, Vollmar B. Role of microcirculation in transplantation. *Microcirculation* 2000;**7**:291–306.
- Merril JP, Murray JE, Harrison JH. Successful homotransplantations of the human kidney between identical twins. *J Am Med Assoc* 1956;**160**:277–282.
- Mertens AC, Yasui Y, Neglia JP, Potter JD, Nesbit ME, Ruccione K, Smithson WA, Robison LL. Late mortality experience in five-year survivors of childhood and adolescent cancer: the childhood cancer survivor study. *J Clin Oncol* 2001;**19**:3163–3172.
- Milliez J. Uterine transplantation. *Int J Gynecol Obstet* 2009;**106**:270.
- Moore FD. Therapeutic innovation: ethical boundaries in the initial clinical trials of new drugs and surgical procedures. *CA Cancer J Clin* 1970;**20**:212–227.
- Moore FD. Ethical problems special to surgery: surgical teaching, surgical innovation, and the surgeons in managed care. *Arch Surg* 2000;**135**:14–16.
- Mühlbacher F, Langer F, Mittermayer C. Preservation solutions for transplantation. *Transplant Proc* 1999;**31**:2069–2070.
- Münz C, Steinman RM, Fujii S. Dendritic cell maturation by innate lymphocytes: coordinated stimulation of innate and adaptive immunity. *J Exp Med* 2005;**202**:203–207.
- Murray JE, Merrill JP, Dammin GJ, Dealey JB, Walter CW, Brooke MS, Wilson RE. Study of transplantation immunity after total body irradiation: clinical and experimental investigation. *Surgery* 1960;**48**:272–282.
- Murray JE, Reid DE, Harrison JH, Merrill JP. Successful pregnancies after human renal transplantation. *N Engl J Med* 1963;**269**:341–343.
- Nakash H, Herdman J. Surrogacy. *J Obstet Gynaecol* 2007;**27**:246–251.
- Navot D, Drews MR, Bergh PA, Guzman I, Karstaedt A, Scott RT, Garrisi GJ, Hofmann GE. Age-related decline in female fertility is not due to diminished capacity of the uterus to sustain embryo implantation. *Fertil Steril* 1994;**61**:97–101.
- Nevins TE, Matas AJ. Medication noncompliance: another iceberg's tip. *Transplantation* 2004;**77**:776–778.
- Nyachio A, Chai DC, Deprest J, Mwenda JM, D'Hooghe TM. The baboon as a research model for the study of endometrial biology, uterine receptivity and embryo implantation. *Gynecol Obstet Invest* 2007;**64**:149–155.
- O'Leary J, Feldman M, Gaensslen DM. Uterine and tubal transplantation. *Fertil Steril* 1969;**20**:757–760.
- Oliveira FG, Abdelmassih VG, Diamond MP, Dozortsev D, Melo NR, Abdelmassih R. Impact of subserosal and intramural fibroids that do not distort the endometrial cavity on the outcome of *in vitro* fertilization—intracytoplasmic sperm injection. *Fertil Steril* 2004;**81**:582–587.
- Opelz G, Döhler B. Lymphomas after solid organ transplantation: a collaborative transplant study report. *Am J Transplant* 2004;**4**:222–230.
- Oppelt P, Renner SP, Kellermann A, Brucker S, Hauser GA, Ludwig KS, Strissel PL, Strick R, Wallwiener D, Beckmann MW. Clinical aspects of Mayer–Rokitansky–Küster–Hauser syndrome: recommendations for clinical diagnosis and staging. *Hum Reprod* 2006;**21**:792–797.
- Pabuccu R, Gomel V. Reproductive outcome after hysteroscopic metroplasty in women with septate uterus and otherwise unexplained infertility. *Fertil Steril* 2004;**81**:1675–1678.
- Padgett EL, Seelig LL Jr. Effects on T-cell maturation and proliferation induced by lactational transfer of cyclosporine to nursing pups. *Transplantation* 2002;**73**:867–874.
- Paldi E, Gal D, Barzilai A, Hampel N, Malberger E. Genital organs. Auto- and homo-transplantation in forty dogs. *Int J Fertil* 1975;**20**:5–12.
- Papp Z, Mezei G, Gavai M, Hupuczai P, Urbancsek J. Reproductive performance after transabdominal metroplasty: a review of 157 consecutive cases. *J Reprod Med* 2006;**51**:544–552.
- Petrozza JC, Gray MR, Davis AJ, Reindollar RH. Congenital absence of the uterus and vagina is not commonly transmitted as a dominant genetic trait: outcomes of surrogate pregnancies. *Fertil Steril* 1997;**67**:387–389.
- Pirenne J, Aerts R, Koshiba T, Van Gelder F, Roskams T, Schetz M, Verhaegen M, Lauwers P, Fevery J, Nevens F. Steroid-free immunosuppression during and after liver transplantation—a 3-yr follow-up report. *Clin Transplant* 2003;**17**:177–182.

- Plagemann A, Harder T, Dudenhausen JW. The diabetic pregnancy, macrosomia, and perinatal nutritional programming. *Nestle Nutr Workshop Ser Pediatr Program* 2008;**61**:91–102.
- Quinn MA, Benedet JL, Odicino F, Maisonneuve P, Beller U, Creasman WT, Heintz APM, Ngan HYS, Pecorelli S. Carcinoma of the uterine cervix. FIGO 6th annual report on the results on treatment in gynaecological cancer. *Int J Gynaecol Obstet* 2006;**95**:S43–S103.
- Quiroga I, McShane P, Koo DD, Gray D, Friend PJ, Fuggle S, darby C. Major effects of delayed graft function and cold ischaemia time on renal allograft survival. *Nephrol Dial Transplant* 2006;**21**:1689–1696.
- Racho El-Akouri R, Kurlberg G, Dindelegan G, Mölne J, Wallin A, Brännström M. Heterotopic uterine transplantation by vascular anastomosis in the mouse. *J Endocrinol* 2002;**174**:157–166.
- Racho El-Akouri R, Kurlberg G, Brännström M. Successful uterine transplantation in the mouse: pregnancy and post-natal development of offspring. *Hum Reprod* 2003a;**18**:2018–2023.
- Racho El-Akouri R, Wranning CA, Mölne J, Kurlberg G, Brännström M. Pregnancy in transplanted mouse uterus after long-term cold ischaemic preservation. *Hum Reprod* 2003b;**18**:2024–2030.
- Ramirez ER, Ramirez DK, Pillari VT, Vasquez H, Ramirez HA. Modified uterine transplant procedure in the sheep model. *J Minim Invasive Gynecol* 2008;**15**:311–314.
- Robertson SA. Control of the immunological environment of the uterus. *Rev Reprod* 2000;**5**:164–174.
- Rogolino A, Coccia ME, Fedi S, Gori AM, Cellai AP, Scarselli GF, Prisco D, Abbate R. Hypercoagulability, high tissue factor and low tissue factor pathway inhibitor levels in severe ovarian hyperstimulation syndrome: possible association with clinical outcome. *Blood Coagul Fibrinolysis* 2003;**14**:277–282.
- Rokitansky KF. Über die sogenannten verdoppelungen des uterus. *Med Jahrb Österr Staat* 1838;**26**:39–77.
- Sanders JE, Hawley J, Levy W, Gooley T, Buckner CD, Deeg HJ, Doney K, Storb R, Sullivan K, Whitterspoon R et al. Pregnancies following high-dose cyclophosphamide with or without high-dose busulfan or total-body irradiation and bone marrow transplantation. *Blood* 1996;**87**:3045–3052.
- Saravelos SH, Cocksedge KA, Li TC. Prevalence and diagnosis of congenital uterine anomalies in women with reproductive failure: a critical appraisal. *Hum Reprod Update* 2008;**14**:415–429.
- Schenker JG, Margalioth EJ. Intrauterine adhesions: an updated appraisal. *Fertil Steril* 1982;**37**:593–610.
- Schmidt A, Tomasdottir H, Bengtsson A. Influence of cold ischemia time on complement activation, neopterin, and cytokine release in liver transplantation. *Transplant Proc* 2004;**36**:2796–2798.
- Schramm R, Menger MD, Kirsch S, Langer F, Harder Y, Hamacher J, Schäfers HJ. The subepicardial microcirculation in heterotopically transplanted mouse hearts: an intravital multicolor fluorescence microscopy study. *J Thorac Cardiovasc Surg* 2007;**134**:210–217.
- Schwarz A, Mengel M, Gwinner W, Radermacher J, Hiss M, Kreipe H, Haller H. Risk factors for chronic allograft nephropathy after renal transplantation: a protocol biopsy study. *Kidney Int* 2005;**67**:341–348.
- Sciller I, Hupucz P, Papp Z. Hypogastric artery ligation for severe hemorrhage in obstetric patients. *J Perinat Med* 2007;**35**:187–192.
- Scott JR, Andersson WR, Kling TG, Yannone ME. Uterine transplantation in dogs. *Gynecol Invest* 1970;**1**:140–148.
- Scott JR, Pitkin RM, Yannone ME. Transplantation of the primate uterus. *Surg Gynecol Obstet* 1971;**133**:414–418.
- Scott JR, Hendrickson M, Lash S, Shelby J. Pregnancy after tubo-ovarian transplantation. *Obstet Gynecol* 1987;**70**:229–234.
- Scott JR, Ware BD, Holman J. Autoimmune and pregnancy complications in the daughter of a kidney transplant patient. *Transplantation* 2002;**73**:815–816.
- Shenfield F, Pennings G, Cohen J, Devroey P, de Wert G, Tarlatzis B. ESHRE task force on ethics and law 10: surrogacy. *Hum Reprod* 2005;**20**:2705–2707.
- Siemionow M. Analysis of historical outcomes of composite tissue allograft transplants in nonhuman primates. *Transplantation* 2005;**80**:1374–1375.
- Siemionow M, Demir Y, Mukherjee A, Klimczak A. Development and maintenance of donor-specific chimerism in semi-allogenic and fully major histocompatibility complex mismatched facial allograft transplants. *Transplantation* 2005;**79**:558–567.
- Sieunarine K, Zakaria FBP, Boyle DCM, Corless DJ, Noakes DE, Lindsay I, Lawson A, Ungar L, Del Priore G, Smith JR. Possibilities for fertility restoration: a new surgical technique. *Int Surg* 2005a;**90**:249–256.
- Sieunarine K, Hakim NS, Corless DJ, Noakes DE, Ungar L, Del Priore G, Smith JR. Is it feasible to use a large vessel patch with a uterine allograft en bloc for uterine transplantation? *Int Surg* 2005b;**90**:257–261.
- Silber SJ, DeRosa M, Pineda J, Lenahan K, Gorman K, Gosden RG. A series of monozygotic twins discordant for ovarian failure; ovary transplantation (cortical versus microvascular) and cryopreservation. *Hum Reprod* 2008;**23**:1531–1517.
- Sillo-Seidl G. The first transplantation of a fallopian tube of frozen material in woman. *Int J Fertil* 1975;**20**:106–108.
- Sonoda Y, Abu-Rustum NR, Gemignani ML, Chi DS, Brown CL, Poyner EA, Barakat RR. A fertility-sparing alternative to radical hysterectomy: how many patients may be eligible? *Gynecol Oncol* 2004;**95**:534–538.
- Spilsbury K, Hammond I, Bulsara M, Semmens JB. Morbidity outcomes of 78,577 hysterectomies for benign reasons over 23 years. *Br J Obstet Gynecol* 2008;**115**:1473–1483.
- Stephens PC, Edwards RG. Birth after reimplantation of a human embryo. *Lancet* 1978;**2**:366.
- Stoica SC, Satchithananda DK, Atkinson C, White PA, Redington AN, Goddard M, Kelley T, Large SR. The energy metabolism in the right and left ventricles of human donor hearts across transplantation. *Eur J Cardiothorac Surg* 2003;**23**:503–512.
- Takatsuki M, Uemoto S, Inomata Y, Egawa H, Kiuchi T, Fujita S, Hayashi M, Kanematsu T, Tanaka K. Weaning of immunosuppression in living donor liver recipients. *Transplantation* 2001;**72**:449–454.
- Taylor E, Gomel V. The uterus and fertility. *Fertil Steril* 2008;**89**:1–16.
- Terasaki PI, Cecka JM, Gjertson DW, Takemoto S. High survival rates of kidney transplants from spousal and living donors. *N Engl J Med* 1995;**333**:333–336.
- Todo S, Ueda Y, Demetris JA, Inventarza O, Nalesnik M, Venkataramanan R, Makowka L, Starzl TE. Immunosuppression of canine, monkey and baboon allografts by FK 506: with special reference to synergism with other drugs and to tolerance induction. *Surgery* 1988;**104**:239–249.
- Totsuka E, Fung JJ, Hakamada K, Ohashi M, Takahashi K, Nakai M, Morohashi S, Morohashi H, Kimura N, Nishimura A et al. Synergistic effect of cold and warm ischemia time on postoperative graft function and outcome in human liver transplantation. *Transplant Proc* 2004;**36**:1955–1958.
- Trowsdale J, Betz AG. Mother's little helpers: mechanisms of maternal-fetal tolerance. *Nat Immunol* 2006;**7**:241–246.
- Truta E, Pop I, Popa D, Ionescu M, Truta F. Experimental re- and transplantation of the internal female genital organs. *Rom Med Rev* 1969;**13**:53–58.
- Ungar L, Palfalvi L, Hogg R, Siklos P, Boyle DC, Del Priore G, Smith JR. Abdominal radical trachelectomy: a fertility-preserving option for

- women with early cervical cancer. *Br J Obstet Gynaecol* 2005; **112**:366–369.
- Vianna RM, Mangus RS, Tector AJ. Current status of small bowel and multivisceral transplantation. *Adv Surg* 2008; **42**:129–150.
- Vollmar B, Glasz J, Menger MD, Messmer K. Leukocytes contribute to hepatic ischemia/reperfusion injury via intercellular adhesion molecule-1-mediated venular adherence. *Surgery* 1995; **117**:195–200.
- Wallace WH, Thomson AB, Saran F, Kelsey TW. Predicting age of ovarian failure after radiation to a field that includes the ovary. *Int J Radiat Oncol Biol Phys* 2005; **62**:738–744.
- Wedenberg K, Rönquist G, Ulmsten U, Waldenström A. Energy economy of human uterine muscle strips under different in vitro conditions and its dependence on tissue redox potential. *Eur J Obstet Gynecol Reprod Biol* 1995; **62**:115–119.
- Wellesley DG, Slaney SF. MURCS in a male? *J Med Genet* 1995; **32**:314–315.
- Wingate MB, Karasewich E, Wingate L, Lauchian S, Ray M. Experimental uterotubovarian homotransplantation in the dog. *Am J Obstet Gynecol* 1970; **106**:1171–1176.
- Winston RM, Browne JC. Pregnancy following autograft transplantation of Fallopian tube and ovary in the rabbit. *Lancet* 1974; **2**:494–495.
- Wood C, Downing B, McKenzie I, O'Brien BM, Paterson P. Microvascular transplantation of the human fallopian tube. *Fertil Steril* 1978; **29**:607–613.
- Wranning CA, Mölne J, Racho El-Akouri R, Kurlberg G, Brännström M. Short-term ischaemic storage of human uterine myometrium—basic studies towards uterine transplantation. *Hum Reprod* 2005; **20**:2736–2744.
- Wranning CA, El-Akouri R, Lundmark C, Dahm-Kähler P, Mölne J, Enskog A, Brännström M. Autotransplantation of the uterus in the domestic pig (*sus scrofa*): surgical technique and early reperfusion events. *J Obstet Gynaecol Res* 2006; **32**:358–367.
- Wranning CA, El-Akouri RR, Groth K, Mölne J, Parra AK, Brännström M. Rejection of the transplanted uterus is suppressed by cyclosporine A in a semi-allogeneic mouse model. *Hum Reprod* 2007; **22**:372–379.
- Wranning CA, Akhi SN, Kurlberg G, Brännström M. UTx in the rat: model development, surgical learning and morphological evaluation of healing. *Acta Obstet Gynecol Scand* 2008a; **87**:1239–1247.
- Wranning CA, Dahm-Kähler P, Mölne J, Nilsson UA, Enskog A, Brännström M. Transplantation of the uterus in the sheep: oxidative stress and reperfusion injury after short-time cold storage. *Fertil Steril* 2008b; **90**:817–826.
- Wranning CA, Enskog A, Brännström M. Uterus transplantation: allo-transplantation with cyclosporin A/FK506 and pregnancies after auto-transplantation in the ewe. *1st American Conference on Reconstructive Transplant Surgery. Prospects and future of Composite Tissue Allotransplantation*, Philadelphia, PA, USA, 2008c; abstract.
- Wranning CA, Marcickiewicz J, Enskog A, Dahm-Kähler P, Brännström M. Fertility after autologous ovine-tubal-ovarian transplantation by vascular anastomosis to the external iliac vessels. *Hum Reprod* 2009; (submitted).
- Yonemoto RH, Du Sold WD, Deliman RM. Homotransplantation of uterus and ovaries in dogs. A preliminary report. *Am J Obstet Gynecol* 1969; **104**:1143–1151.
- You W, Dainty LA, Rose GS, Krivak T, McHale MT, Olsen CH, Elkas JC. Gynecologic malignancies in women aged less than 25 years. *Obstet Gynecol* 2005; **105**:1405–1409.
- Zhang W, Wang M, Xie HY, Zhou L, Meng XQ, Shi J, Zheng S. Role of reactive oxygen species in mediating hepatic ischemia-reperfusion injury and its therapeutic applications in liver transplantation. *Transplant Proc* 2007; **39**:1332–1337.

Submitted on January 30, 2009; resubmitted on October 1, 2009; accepted on October 7, 2009