

## Expression of ICAM-1 and Acute Inflammatory Cell Infiltration in the Early Phase of Radiation Colitis in Rats

YUJI IKEDA, MASAHIRO ITO\*, MUTSUMI MATSUU, KAZUKO SHICHIJO, EIICHIRO FUKUDA, TOSHIYUKI NAKAYAMA, MASAHIRO NAKASHIMA, SHINJI NAITO and ICHIRO SEKINE

Department of Molecular Pathology, Atomic Bomb Disease Institute, Nagasaki University School of Medicine, 1–12–4 Sakamoto, Nagasaki 852–8523, Japan

(Received, January 24, 2000)

(Revision received, August 8, 2000)

(Accepted, August 21, 2000)

### Radiation colitis/ICAM-1/Leukocyte/Myeloperoxidase/Rat

Inflammatory cell infiltration of the colon is observed at an early stage of radiation-induced colitis. The emigration of inflammatory cells from the circulation requires interactions between cell adhesion molecules on the vascular endothelium and molecules on the surface of leukocytes. To elucidate this process, the present work analyzes the kinetics of the expression of intercellular adhesion molecule-1 (ICAM-1) and the accumulation of inflammatory myeloperoxidase (MPO)-positive cells in relation to the appearance of acute radiation colitis prior to an overt radiation-induced ulcer. Colon tissues were obtained from Wistar Kyoto rats at various times after 22.5 Gy irradiation to the rectum. Histologically, crypt depletion and numerous inflammatory cells were observed 4 days after irradiation, and mucosal ulcer 6 days after irradiation. ICAM-1 immunopositivity was present in the endothelial cells of small vessels in the mucosa of both control and irradiated rats. ICAM-1 mRNA expression was detected in normal colon and irradiated colon by reverse transcription-PCR. In Northern blotting, ICAM-1 mRNA levels were found to increase markedly in the irradiated colon compared to the normal colon. In Western blotting, ICAM-1 protein expression also increased with a peak one day after irradiation, and remained elevated up to 6 days thereafter. The number of MPO-positive cells in lamina propria mucosa increased in a time-dependent fashion from 6 h to 6 days after irradiation. These data suggest that up-regulation of ICAM-1 in endothelial cells and accumulation of MPO positive cells play important roles in the development of radiation-induced colonic ulcer.

## INTRODUCTION

Radiation-induced colitis may be encountered as one of the most harmful side-effects of radiation therapy for pelvic malignancies<sup>1</sup>. During the treatment of these malignancies with external, intracavitary, or combined irradiation, the rectum often receives a substantial expo-

\*Corresponding author: Phone; +81–95–849–7106, FAX; +81–95–849–7108, E-mail; itohm@nmc.hosp.go.jp

sure<sup>2</sup>). Nearly all patients who undergo pelvic irradiation experience some degree of colitis. The most common acute symptoms of radiation-induced colitis are diarrhea and tenesmus, although rectal bleeding may on occasion be encountered. In a study assessing the histological changes after pelvic irradiation, 95% of patients were found to have acute intestinal radiation damage<sup>3</sup>.

Leukocyte infiltration and accumulation in irradiated pig kidney and rat rectum have been well documented<sup>4,5</sup>. However, the pathological consequences of leukocyte infiltration and accumulation in irradiated normal tissues are not fully understood. Leukocytes are believed to be one of the key participants in the development of tissue injury in a variety of acute inflammatory diseases. Leukocytes contain large amounts of myeloperoxidase (MPO) that generate toxic oxygen metabolites. Extremely powerful oxidant, HOCl (hypochlorous acid), production is regulated by a complex, multicomponent system in which a latent enzyme must be specifically activated to fuel the discharged MPO with its required H<sub>2</sub>O<sub>2</sub><sup>6</sup>. Leukocyte infiltration in irradiated tissues can cause parenchymal damage by this oxidant, and consequently can cause organ dysfunction and tissue failure<sup>7</sup>. Thus, an assessment of the MPO positive cell number could be important for evaluating radiation-induced tissue damage.

Inflammatory processes are mediated by the interaction of adhesion molecules expressed by inflammatory cells and by resident cells. Cell adhesion molecules on leukocytes and endothelial cells have been found to play a crucial role in the passage of leukocytes from blood vessels into tissues after irradiation. Four classes of adhesion molecules are known, including adhesion molecules of the immunoglobulin superfamily, selectins, integrins, and cadherins<sup>8</sup>. The immunoglobulin family includes ICAM, a vascular cell adhesion molecule, a neural cell adhesion molecule, a mucosal adhesion cellular adhesion molecule, and a platelet endothelial cell adhesion molecule. Selectins are preferentially involved in the first step of cell-cell interaction, the so-called rolling phase, whereas the vascular cell adhesion molecule and ICAM are important for later steps, the so-called sticking and transmigration phases<sup>9</sup>. ICAM-1 expression on endothelium plays an important role in migration of activated leukocytes into the sites of inflammation<sup>10</sup>. Increased expression of ICAM-1 in the colon of patients with inflammatory bowel disease (IBD) has been reported<sup>11-14</sup>. Recent studies have shown that ICAM-1 expression can be induced by ionizing radiation<sup>15,16</sup>. ICAM-1 expression regulates leukocyte migration into the tissue region of highest adhesiveness. Prophylactic treatment with anti-ICAM-1 antibodies significantly attenuated colonic damage and neutrophil infiltration of the colon in dextran sulphate sodium (DSS) colitis<sup>17</sup>. Furthermore, ICAM-1 knockout mice had no increase in inflammatory cell infiltration into the lung in response to irradiation<sup>18</sup>. In radiation-induced colitis, ICAM-1 might play an important role in causing indirect tissue damage mediated by leukocyte infiltration. However, ICAM-1 expression has not been reported in this model.

In this study, we therefore investigated the expression of ICAM-1 and infiltration of MPO positive cells in an early phase of radiation-induced colitis.

## MATERIALS AND METHODS

### *Animals*

Male Wistar Kyoto rats (10 weeks old, n=48) were provided by IZM(Shimane, Japan) and fed with food and water *ad libitum*. All experiments were performed in accordance with the guidelines for animal experimentation at the Institutional Animal Care and Use Committee of Nagasaki University School of Medicine.

### *Radiation techniques*

Before irradiation, the animals were anesthetized with an intraperitoneal injection of 40 mg/kg of sodium pentobarbital. Thereafter, the animals were placed in a supine position. After a midabdominal laparotomy, the small intestine was moved and the descending colon was pulled from the posterior abdominal wall. Two small sheets of lead (2mm thickness) were then arranged beside the descending colon. The descending colon was exposed and covered with a gauze moistened with 0.9% NaCl solution. Lead shielding (3.18mm thickness) containing a window (0.8×2cm) was used to shield the rat except for a 0.8×2cm area of the descending colon. Irradiation was accomplished using a Toshiba EXS-300 X-ray, 200KV, 15mA unit with filters of 0.5mm Cu and 0.5mm Al. The distance from tube target to the descending colon was approximately 50cm, and the dose rate was approximately 0.458Gy/min<sup>19</sup>). The total dose administered was 22.5Gy. This dose was selected because it induced severe radiation colitis effectively<sup>20</sup>). Our preliminary study showed that 22.5Gy induced 100% of macroscopical ulceration in Wistar Kyoto rats. Control animals were treated in an identical fashion without irradiation.

### *Tissue preparation*

The animals were euthanized by an intraperitoneal injection of sodium pentobarbital at 0h (control), 6h, 1 day, and 2 days, 4 days, and 6 days after irradiation. A portion of the descending colon was fixed in 10% neutral-buffered formalin and embedded in paraffin. Paraffin blocks were then sectioned (4μm thick), stained with hematoxylin and eosin, and examined immunohistochemically by light microscopy. Fresh tissues were obtained arbitrarily at 0h (control), 6h, 1day, 2 days, 4 days, and 6 days for immunohistochemistry, MPO cell counting, reverse transcription-PCR (RT-PCR), Northern blotting, and Western blotting to study early events of ICAM-1 associated inflammation.

### *Immunohistochemistry*

Paraffin embedded sections (3μm) and cryostat sections (8μm) were used for immunostaining of ICAM-1. Internal peroxidase activities were suppressed with 1% H<sub>2</sub>O<sub>2</sub> in methanol for 10 minutes. Sections were preincubated with normal bovine serum to prevent nonspecific binding, and then incubated overnight at 4°C with anti-rat ICAM-1 antibody (Seikagaku Corp., Tokyo, Japan). Secondary reagents were made by using the Vector Elite ABC kit (Vector Laboratories Inc., Burlingame, CA), and DAB was used for color develop-

ment. In addition, the catalyzed signal amplification method (CAS system, DAKO JAPAN, Tokyo, Japan) was applied to paraffin sections. Treatment of the primary antibody was omitted in the negative control samples.

#### *Myeloperoxidase staining*

Frozen tissues were embedded in OCT compound (Tissue-Tek, Sakura Fine technical Corp., Tokyo, Japan), and cryostat sections ( $8\mu\text{m}$ ) of irradiated descending colon were air-dried for 2h, fixed in acetone for 10 min at  $-20^{\circ}\text{C}$  and then used for MPO staining. MPO staining, showing the localization of inflammatory cells (leukocytes and macrophages), was performed by reaction with a peroxidase substrate solution containing 0.05% 3,3'-diaminobenzidine tetrahydrochloride (DAB) and 0.01% hydrogen peroxide in 50 mM Tris (pH 7.2) for 5 min at room temperature. The sections were counterstained with methyl green. The number of cells positive for MPO staining was counted every  $500\times 500\mu\text{m}^2$  in the irradiated descending colon (at least three fields in each rat) and the average value was used for the representative data. In this field about ten crypts were scanned microscopically. For MPO-positive cell counting, six rats were used for each data point.

#### *RT-PCR*

The total RNA was extracted with the single-step guanidinium thiocyanate-phenol-chloroform method<sup>21</sup>. The yield and purity of RNA were confirmed by measuring the ratio of the absorbencies at 260 and 280nm. To identify ICAM-1-specific cDNA, PCR was performed using ICAM-1-specific primers. Rat ICAM-1-specific primers were synthesized: sense primer, 5' TGTGCTTTGAGAACTGTGGC 3'; antisense primer, 3' GGTTCGTCCAACTTCTCAG5'. Sense and antisense primers corresponded to exon 2 and exon 4, respectively. The rat  $\beta$ -actin PCR primers were 5'-TCCTCCCTGGAGAAGACTA-3' (sense) and 5'-AGTACTTGCGCTCAGGAGGA-3' (antisense). Each primer pair was chosen to span the introns of their respective rat genes. Using the primers, it is expected that DNA fragments of 584 and 313 bp are amplified from the ICAM-1 and  $\beta$ -actin RNA, respectively.

#### *Northern blot analysis*

The expression of ICAM-1 mRNA in descending colon was examined in control ( $n=2$ ) and irradiated animals 2 days after exposure ( $n=2$ ). The total RNA ( $30\mu\text{g}$ ) was prepared by formaldehyde/1.0% agarose gel electrophoresis and transferred onto a nylon membrane (Hybond N, Amersham Life Science, Buckinghamshire, U.K.). The PCR products of ICAM-1 (584bp) were subcloned, sequenced, and used as cDNA probes. The random primer method was used to label the cDNA with [ $^{32}\text{P}$ ]dCTP (rediprime DNA labelling system, Amersham). Specific activity of the probe was about  $8\times 10^4$  cpm/mg. Hybridization was performed at  $42^{\circ}\text{C}$  in a solution containing 0.87mol/L NaCl, 50% formamide, 0.5% SDS, and 167 mg/ml salmon sperm DNA. The membrane was washed in 0.1XSSC and 0.1% SDS at  $50^{\circ}\text{C}$  and autoradiographed on Hyper film-MP (Amersham) at  $-80^{\circ}\text{C}$  for 24 hours. Assays were performed in duplicate and experiments were repeated twice.

### *Western blot analysis*

The colon tissues were frozen immediately after tissue sampling. The tissues were then suspended in RIPA buffer (50 mM Tris, 150mM NaCl, 1% NP-40, 1% sodium deoxycholate and 0.05% SDS, pH 7.4), broken into pieces on ice and subjected to three freeze-thaw cycles. The insoluble cell debris was removed by centrifugation. Supernatants were collected and the protein concentration was quantified using a protein assay reagent (Bio-Rad Laboratories, Hercules, CA). The level ICAM-1 protein in descending colon was evaluated at 0 (control), 6h, 1day, 2 days, 4 days, and 6 days after irradiation. For each data point two rats were used for assays and the assays were performed in duplicate. Proteins (30 $\mu$ g) from the irradiated descending colon were separated by polyacrylamide gel electrophoresis (PAGE) under denaturing and reducing conditions and transferred to Hybond ECL Nitrocellulose Membranes (Amersham). Membranes were rinsed in TBS, blocked with 5% low-fat dried milk in TBS containing 0.1% Tween 20 (TTBS), and then incubated for 2h at a room temperature with a 1 : 500 dilution of the anti-rat ICAM-1 antibody (Seikagaku Corp., Tokyo, Japan). After extensive washing of the membranes with TTBS, they were incubated for 1h with a 1 : 20,000 dilution of the horseradish-peroxidase-conjugated goat anti-mouse IgGs in TTBS containing 3% low-fat dried milk. The membranes were washed and developed with a horseradish peroxidase chemiluminescence detection reagent (ECL Plus system, Amersham) and were exposed to Hyperfilm ECL (Amersham).

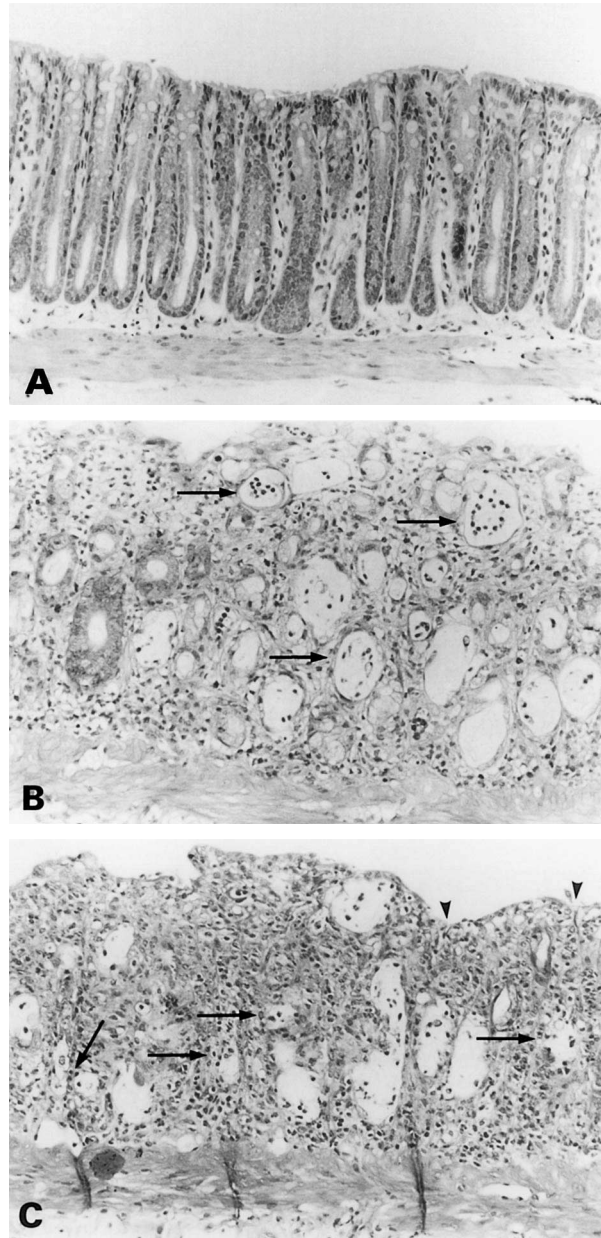
### *Statistics*

Values were expressed as the mean  $\pm$ SD. Student's t-test was used to test the significance between groups. A P value less than 0.05 denoted the presence of a statistically significant difference.

## RESULTS

### *Histopathology of radiation-induced colitis*

In control animals no lesions were observed in the intestinal mucosa. The crypts were regularly arranged and interstitial edema was not encountered (Fig. 1A). A few eosinophils were present in the basal layer of the propria mucosa. Macroscopical changes were not evident 6 h after irradiation, but an inflammatory reaction had begun. Neutrophils and eosinophils increased noticeably at day 1 after irradiation and interstitial edema was prominent by day 2. Crypt depletion progressed and robust neutrophil infiltration was observed 4 days after irradiation (Fig. 1B). Mucosal ulcer, also associated with the presence of numerous neutrophils, was observed 6 days after irradiation (Fig. 1C). Dilated crypts were filled with neutrophils, and some crypt epithelia were destroyed by these neutrophils. Lymphocyte aggregation and macrophage infiltration were also encountered in the interstitium. The regenerative mucosa and viable crypt re-appeared 10 days after irradiation (data not shown). The mucosal regeneration was complete within 16 days after irradiation (data not shown). The histological findings of 10 and 16 days after irradiation were obtained from a preliminary study, but have



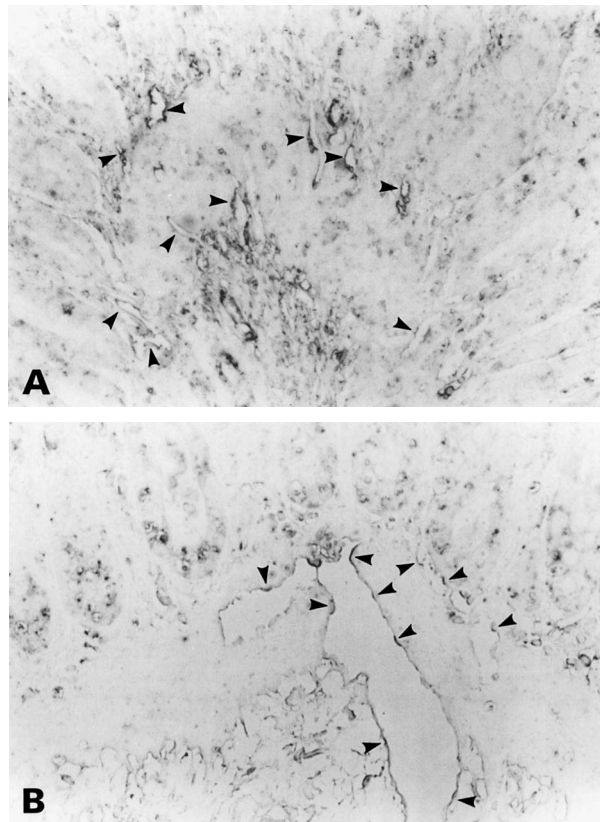
**Fig. 1.** Time-dependent histopathological changes of colonic mucosa after irradiation (22.5Gy). A: Normal colon mucosa. Crypts were arranged regularly and no significant stromal changes were observed. B: Radiation-induced colitis 4 days after irradiation (22.5Gy). Glands were distorted and dilated with mucus and neutrophils (arrows). Moderate interstitial cell infiltration was observed. C: Radiation-induced colitis 6 days after irradiation (22.5Gy). Erosive changes (arrow heads) appeared in this phase. Marked inflammatory cell infiltration occurred and most crypts were destroyed (arrows). Inflammatory cells consist mainly of neutrophils and eosinophils. (H&E,  $\times 50$ )

been repeatedly confirmed.

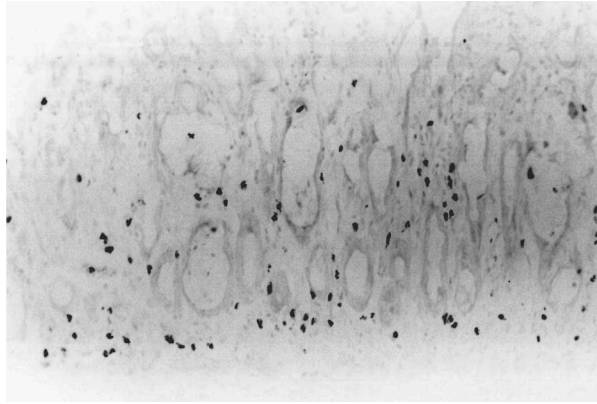
*ICAM-1 immunohistochemistry and MPO positive cells*

In normal colon, ICAM-1 immunoreactivity was observed in cryostat sections of the endothelial cells of capillary vessels in the mucosal layer (Fig.2A), but not in paraffin-embedded samples. The ICAM-1 expression on the endothelial cells of dilated venules in the submucosa was enhanced from 6h after irradiation (Fig. 2B) and lasted for 6 days (data not shown) in both cryostat and paraffin sections.

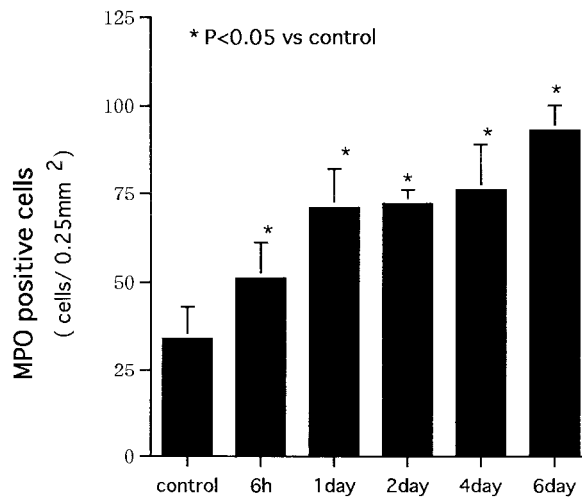
The number of the MPO-positive cells was measured by the method mentioned above (Fig. 3). As shown in Fig.4, the number of MPO-positive cells increased in a time-dependent fashion in the irradiated descending colon from 6 h after irradiation. Numerous MPO-positive cells were encountered at day 6.



**Fig. 2.** ICAM-1 immunohistochemistry. A: ICAM-1 immunopositivity was detected in endothelial cells of capillaries in the normal mucosa (arrow heads). B: ICAM-1 expression was detected in endothelial cells of vessels in the mucosa and submucosa 6h after irradiation (arrow heads: immunopositive endothelial cells). (ABC method, A: frozen section of normal control, B: paraffin section from 6h after irradiation,  $\times 100$ )



**Fig. 3.** MPO-positive cells in colonic mucosa 2 days after irradiation. Cells with internal MPO activity were detected by DAB coloration. MPO-positive cells were broadly distributed in the interstitial area of mucosa. (DAB,  $\times 100$ )

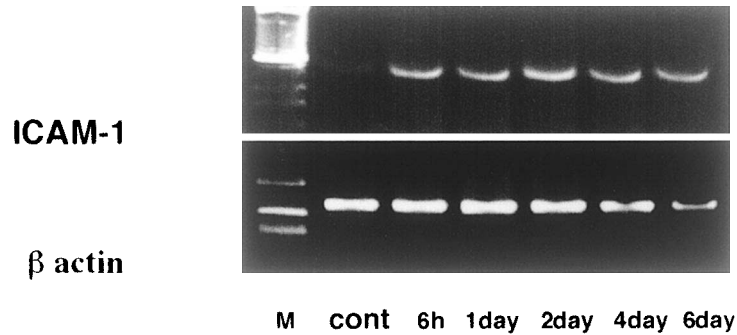


**Fig. 4.** Time course of accumulation of MPO-positive cells. The number of MPO-positive cells increased after irradiation in a time-dependent fashion. The values are mean  $\pm$  S.D. (n=6, each group). \*p<0.05 (vs. control)

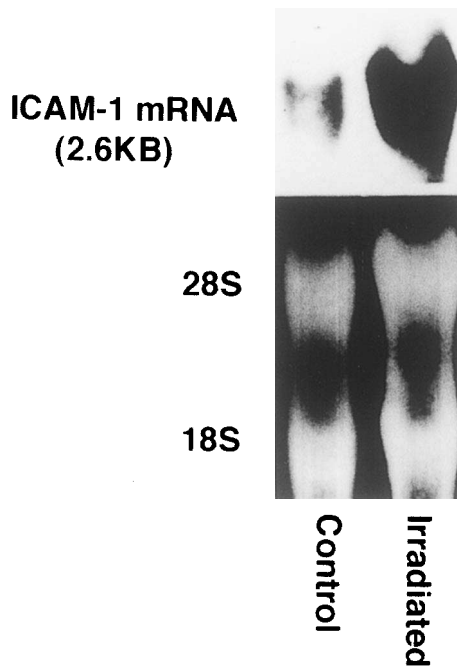
#### *RT-PCR and Northern blot analysis*

RT-PCR revealed the presence of ICAM-1 mRNA in normal and irradiated colon tissues (Fig. 5).  $\beta$ -actin mRNA was detected in all samples to demonstrate that equivalent amounts of tissue RNA were used for cDNA synthesis. By a Northern blot analysis, a major band of 2.6kb representing the rat ICAM-1 transcript was detected (Fig. 6). In the control animals, an amount of the ICAM-1-specific transcripts were faintly detected. In contrast, the ICAM-1 mRNA increased greatly in the irradiated rats.





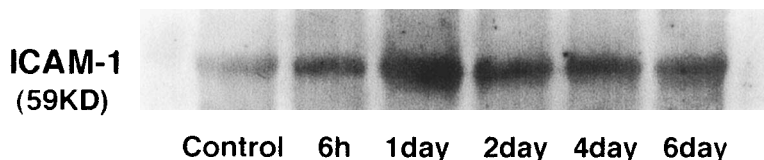
**Fig. 5.** RT-PCR revealed ICAM-1 mRNA expression in normal and irradiated colon tissues. PCR products of ICAM-1 mRNA were detected in all data points (584bp). M1: 100bp DNA ladder (Life Technologies, Rockville, MD ). PCR products of  $\beta$ -actin mRNA (313bp), as an internal control, were detected in all samples. M2: 100bp DNA ladder (Takara, Tokyo, Japan).



**Fig. 6.** Northern blotting of ICAM-1mRNA (2.6kb) in control and irradiated colon. Thirty mg of total RNA was loaded in each lane. (Upper panel) The autoradiogram was developed after 24h of exposure at  $-80^{\circ}\text{C}$ . Lane 1: control (0h); Lane2: irradiated rat (2 days). ICAM-1mRNA expression was strongly enhanced by irradiation. (Lower panel) Ethidium bromide staining of the total RNA.

*Western blot analysis*

The results of the Western blot analysis are shown in Fig. 7. A major band of 59kD representing rat ICAM-1 protein was detected. The control animals showed no increase of the



**Fig. 7.** Western blot analyses of ICAM-1 in colon after irradiation. Thirty  $\mu\text{g}$  of protein was loaded in each lane. A representative experiment is shown. ICAM-1 expression (59kD) was detected in the normal mucosa and its expression was enhanced from 6h after irradiation through the 6th day. The peak expression was observed one day after irradiation.

ICAM-1 protein, but at 6h after irradiation it increased slightly. One day after irradiation, a peak of the increase was observed and the increase remained relatively high until 6 days after irradiation.

## DISCUSSION

In this study, we demonstrated radiation-mediated induction of ICAM-1 and acute inflammation associated with MPO-positive cells in the colon. Radiation induces the expression of cytokines, such as TNF and IL-1<sup>22-24</sup>. These cytokines stimulate endothelial cells and lymphocytes, resulting in leukocyte adhesion, extravasation and macrophage activation<sup>25</sup>. The number of adherent leukocytes significantly increases several hours after irradiation *in vitro*<sup>26</sup> and *in vivo*<sup>27</sup>. Adhesion molecules must be expressed on the surface of the vascular endothelium before leukocyte. Leukocytes then migrate into the tissue region of highest adhesiveness, which is regulated mainly by ICAM-1 expression<sup>16</sup>. However, it is unclear exactly how integrin-binding mechanisms might operate to mediate leukocyte transmigration. Berman et al<sup>28</sup> speculated that CD31-mediated integrin activation might play a major role in transmigration. Even though leukocytes may have a beneficial function in this setting through phagocytosis and disposal of cellular and connective tissue debris, nonetheless they contribute to the development of radiation colitis and interstitial pulmonary fibrosis<sup>7,29</sup>.

*In vitro* studies have shown that radiation doses of 10–40 Gy induce ICAM-1 mRNA in human cell lines 3–6h after irradiation in a time- and dose-dependent manner, and this was followed by an increase at cell surface in the expression of this adhesion molecule<sup>15</sup>. In a mouse model of cerebral irradiation, ICAM-1 mRNA increased in a dose-dependent manner from 15 Gy to 40 Gy, and ICAM-1 immunopositivity was detected in endothelial cells from 4h to 7 days after irradiation<sup>30</sup>. Our results also showed that ICAM-1 expression was increased from 6h to 6 days after a dose of 22.5 Gy irradiation to the colon.

Enhancement of ICAM-1 expression has been reported in Crohn's disease<sup>11</sup>, ulcerative colitis<sup>12</sup>, DSS-induced colitis<sup>13</sup>, and trinitrobenzene sulfonic acid (TNBS)-induced colitis<sup>14</sup>. However, some other studies have shown unchanged expression in human IBD and TNBS-induced colitis<sup>31</sup>. The assessment of changes in the expression of ICAM-1 in bowel inflammation has mainly relied on immunohistochemical staining of colonic samples from patients with IBD. This approach has brought on conflicting results, probably because of technical limita-

tions in quantification of staining intensity, about molecules between high constitutive expression and low stimulated expression. Our results revealed that paraffin sections were not appropriate for the detection of ICAM-1 immunohistochemically because their sensitivity for detection of constitutive expression was especially low. The contribution of ICAM-1 to leukocyte recruitment in colonic tissues is derived from therapeutic interventions in experimental models. The treatment with anti-ICAM-1 monoclonal antibody ameliorated the inflammatory response in acetic acid-induced colitis in the rat<sup>32)</sup> and that an ICAM-1 antisense oligonucleotide prevented and reversed DSS-induced colitis in mice<sup>33)</sup>.

Leukocytes are believed to be one of the key participants in the development of tissue injury in a variety of acute inflammatory diseases. Leukocytes contain large amounts of MPO, which are one of a group of enzymes that generate toxic oxygen metabolites for antibacterial properties<sup>6)</sup>. MPO-positive cells produce a second burst of oxygen radicals which contribute to radiation-induced colonic ulceration and other radiation-induced tissue damage<sup>7)</sup>. In the present study, an increase of MPO-positive inflammatory cells was observed 6h after irradiation, followed by crypt depletion associated with numerous MPO-positive inflammatory cells in the lamina propria mucosa 4 days after irradiation. A time-dependent increase of MPO-positive cells was evident up to 6 days after irradiation. ICAM-1 was expressed at a relatively high level after irradiation, with the peak expression observed at day 1. Probably, in addition to ICAM-1, other adhesion molecules may also participate in the process of leukocyte recruitment in radiation-induced colitis one day after irradiation. Constitutive ICAM-1 expression in non-inflamed intestine implies that this adhesion molecule may play a role in physiological leukocyte traffic of the normal colon<sup>31)</sup>.

In conclusion, we found that the expression of ICAM-1 elevated in the colon after irradiation, as well as early recruitment of MPO-positive cells which are activated to produce oxygen radicals. The up-regulation of ICAM-1 and accumulation of MPO-positive cells may be key steps in the development of radiation-induced acute colitis.

## REFERENCES

1. Minami, K., Matsuzaki, S., Hayashi, K., Mokarim, A., Ito, M. and Sekine, I. (1998) Immunohistochemical study of p53 overexpression in radiation-induced colon cancers. *J. Radiat. Res.* **39**: 1–10.
2. Rubin, P and Casarett, G. W. (1968) Alimentary tract: Small and large intestines and rectum. In *Clinical Radiation Pathology*, Vol. I, pp. 193–240. Saunders, Philadelphia.
3. Gelfand, M. D., Tepper, M., Katz, L. A., Binder, H. J., Yenser, R. and Floch, M. H. (1968) Acute irradiation proctitis in man: development of eosinophilic crypt abscesses. *Gastroenterology* **54**: 401–411.
4. Robbins, M. E. C., Jaenke, R. S., Bywaters, T., Golding, S. J., Rezvana, M., Whitehouse, E. and Hopewell, J. W. (1993) Sequential evaluation of radiation-induced glomerular ultrastructural changes in the pig kidney. *Radiat. Res.* **137**: 351–364.
5. Hubmann, F. H. (1982) Proctitis cystica profunda and radiation fibrosis in the rectum of the female Wistar rat X irradiation: a histopathological study. *J. Pathol.* **138**: 193–204.
6. Weiss, S. J. (1989) Tissue destruction by neutrophils. *New Engl. J. Med.* **320**: 365–376.
7. Panés, J. and Granger, D. N. (1996) Neutrophils generate oxygen free radicals in rat mesenteric microcirculation after abdominal irradiation. *Gastroenterology* **111**: 981–989.

8. van de Stolpe, A. and van de Saag. (1996) Intercellular adhesion molecule-1. *J. Mol. Med.* **74**: 13–33.
9. Butcher, E. C. and Picker, L. J. (1996) Lymphocyte homing and homeostasis. *Science* **272**: 60–66.
10. Quarmby, S., Kumar, P. and Kumar, S. (1999) Radiation-induced normal tissue injury: Role of adhesion molecules in leukocyte-endothelial cell interactions. *Int. J. Cancer* **82**: 381–395.
11. Bernstein, C. N., Sargent, M. and Gallatin, W. M. (1998) Beta2 integrin/ICAM expression in Crohn's disease. *Clin. Immunol. Immunopathol.* **86**: 147–160.
12. Nielsen O. H., Brynskov, J. and Vainer, B. (1996) Increased mucosal concentrations of soluble intercellular adhesion molecule-1 (sICAM-1), sE-selectin, and interleukin-8 in active ulcerative colitis. *Dig. Dis. Sci.* **41**: 1780–1785.
13. Bendjelloul F., Maly, P., Mandys, V., Jikovska, M., Prokesova, L., Tuckova, L. and Tlaskalova-Hogenova, H. (2000) Intercellular adhesion molecule-1 (ICAM-1) deficiency protects mice against severe forms of experimentally induced colitis. *Clin. Exp. Immunol.* **119**: 57–63.
14. Zingarelli, B., Szabo, C and Salzman, A. L. (1999) Reduced oxidative and nitrosative damage in murine experimental colitis in the absence of inducible nitric oxide synthase. *Gut* **45**: 199–209.
15. Behrends, U., Peter, R. U., Hintermeier-Knabe, R., Eissner, G., E. Holler, E., Caughman, G. W. and Degitz, K. (1994) Ionizing radiation induces human intercellular adhesion molecule-1 in vitro. *J. Invest. Dermatol.* **103**: 726–730.
16. Hallahan, D. E., Kuchibhotla, J. and Wyble, C. (1996) Cell adhesion molecules mediate radiation-induced leukocyte adhesion to the vascular endothelium. *Cancer Res.* **56**: 5150–5155.
17. Taniguchi, T., Tsukada, H., Nakamura, H., Kodama, M., Fukuda, K., Saito, T., Miyasaka, M. and Seino, Y. (1998) Effects of the anti-ICAM-1 monoclonal antibody on dextran sodium sulphate-induced colitis in rats. *J. Gastroenterol Hepatol.* **13**: 945–949.
18. Hallahan, D. E. and Virudachalam, S. (1997) Intercellular adhesion molecule 1 knockout abrogates radiation induced pulmonary inflammation. *Proc. Natl. Acad. Sci. USA.* **94**: 6432–6437.
19. Matsuo, M., Shichijo, K., Nakamura, Y., Ikeda, Y., Naito, S., Ito, M., Okaichi, K. and Sekine, I. (2000) The role of the sympathetic nervous system in radiation-induced apoptosis in jejunal crypt cells of spontaneously hypertensive rats. *J. Radiat. Res.* **41**: 55–65.
20. Northway, M. G., Scobey, M. W. and Geisinger, K. R. (1988) Radiation proctitis in the rat. Sequential changes and effects of anti-inflammatory agents. *Cancer* **62**: 1962–1969.
21. Chomczynski, P. and Sacchi, N. (1987) Single-step method of RNA isolation by acid guanidinium thiocyanate-phenol-chloroform extraction. *Anal. Biochem.* **162**: 156–159.
22. Hallahan, D. E., Spriggs, D. R., Beckett, M. A., Kufe, D. W. and Weichselbaum, R. R. (1989) Increased tumor necrosis factor alpha mRNA after cellular exposure to ionizing radiation. *Proc. Natl. Acad. Sci. USA* **86**: 10104–10107.
23. Ishihara, H., Tsuneoka, K., Dimchev, A. B. and Shikita, M. (1993) Induction of the expression of the interleukin-1 beta gene in mouse spleen by ionizing radiation. *Radiat. Res.* **133**: 321–326.
24. Baker, W. H., Limanni, A., Chang, C. M., Jackson, W. E., Seemann, R. and Patchen, M. L. (1995) Comparison of interleukin-1 alpha gene expression and protein levels in the murine spleen after lethal and sublethal total-body irradiation. *Radiat. Res.* **143**: 320–326.
25. Ibuki, Y. and Goto, R. (1999) Contribution of inflammatory cytokine release to activation of resident peritoneal macrophages after in vivo low-dose  $\gamma$ -irradiation. *J. Radiat. Res.* **40**: 253–262.
26. Dunn, M. M., Drab, E. A. and Rubin, D. B. (1986) Effects of irradiation on endothelial cell-polymorphonuclear leukocyte interactions. *J. Appl. Physiol.* **60**: 1932–1937.
27. Panés, J., Anderson, D. C., Miyasaka, M and Granger, D. N. (1995) Role of leukocyte-endothelial cell adhesion in radiation-induced microvascular dysfunction in rats. *Gastroenterology* **108**: 1761–1769.
28. Berman, M. E., Xie, Y. and Muller, W. A. (1996) Roles of platelet/endothelial cell adhesion molecule 1 (PECAM-1, CD31) in natural killer cell transendothelial migration and integrin activation. *J. Immunol.* **156**: 1515–1524.
29. Crystal, R. G., Bitterman, P. B., Rennard, S. I., Hance, A. J. and Keogh, B. A. (1984) Interstitial lung diseases

- of unknown cause. Disorders characterized by chronic inflammation of the lower respiratory tract (first of two parts). *New Engl. J. Med.* **310**: 154–166.
30. Olschowka, J. A., Kyrkanides, S., Harvey, B. K., O'Banion, M. K., Williams, J. P., Rubin, P. and Hansen, J. T. (1997) ICAM-1 induction in the mouse CNS following irradiation. *Brain Behav. Immun.* **11**: 273–85.
  31. Sans, M., Panes, J., Ardite, E., Elizale, J. I., Arce, Y., Elena, M., Palacin, M., Fernandez-Checa, J. C., Anderson, D. C., Lobb, R. and Pique, J. M. (1999) VCAM-1 and ICAM-1 mediate leukocyte-endothelial cell adhesion in rat experimental colitis. *Gastroenterology* **116**: 874–883.
  32. Wong, P. Y., Yue, G., Yin, K., Miyasaka, M., Lane, C. L., Manning, A. M., Anderson, D. C. and Sun, F. F. (1995) Antibodies to intercellular adhesion molecule-1 ameliorate the inflammatory response in acetic acid-induced inflammatory bowel disease. *J. Pharmacol. Exp. Ther.* **274**: 475–480.
  33. Bennett, C. F., Kornbrust, D., Henry, S., Stecker, K., Howard, R., Cooper, S., Dutson, S., Hall, W. and Jacoby, H. I. (1997) An ICAM-1 antisense oligonucleotide prevents and reverses dextran sulfate sodium-induced colitis in mice. *J. Pharmacol. Exp. Ther.* **280**: 988–1000.