




Contents lists available at ScienceDirect

# The Journal of Foot & Ankle Surgery

journal homepage: [www.jfas.org](http://www.jfas.org)

## Original Research

### Extra-corporeal Pulsed-activated Therapy (“EPAT” Sound Wave) for Achilles Tendinopathy: A Prospective Study

Amol Saxena, DPM, FACFAS<sup>1</sup>, Sona Ramdath Jr., DPM<sup>2</sup>, Patrick O’Halloran, MS<sup>3</sup>,  
Ludger Gerdesmeyer, MD, PhD<sup>4</sup>, Hans Gollwitzer, MD<sup>5</sup>

<sup>1</sup> Fellowship Director, Palo Alto Medical Foundation, Palo Alto, CA

<sup>2</sup> Sports Medicine Fellow, Palo Alto Medical Foundation, Palo Alto, CA

<sup>3</sup> University of Birmingham School of Medicine, Birmingham, UK

<sup>4</sup> Universitaet Schleswig Holstein, Kiel Germany

<sup>5</sup> Technische Universitaet, Muenchen, Germany

#### ARTICLE INFO

Level of Clinical Evidence: 2

Keywords:

athlete  
EPAT  
ESWT  
heel  
injury  
Roles and Maudsley  
sound wave

#### ABSTRACT

Achilles tendinopathy is common and extracorporeal shockwaves have become a popular treatment for this condition, even though previous research has not provided conclusive results regarding its efficacy in cases of Achilles tendinopathy. Our aim was to evaluate 3 weekly shockwave treatments in patients with Achilles tendinopathy, as quantified by the Roles and Maudsley score. A total of 74 tendons in 60 patients were assessed at baseline and at least 1 year posttreatment, including 32 (43.24%) paratendinoses, 23 (31.08%) proximal tendinoses, and 19 (25.68%) insertional tendinoses. The mean age of the participants was  $48.6 \pm 12.94$  years, and patients with paratendinosis ( $41.44 \pm 14.01$  years) were statistically significantly younger than those with proximal ( $53 \pm 8.9$  years) and insertional ( $54.26 \pm 9.74$  years) tendinopathy, and these differences were statistically significant ( $P = .0012$  and  $P = .0063$ , respectively). Overall, 58 (78.38%) tendons improved by at least 1 year posttreatment, including 75% in the paratendinosis, 78.26% in the proximal tendinosis, and 84.21% in the insertional tendinosis groups, and no adverse effects were observed. The Roles and Maudsley score improved from  $3.22 \pm 0.55$  to  $1.84 \pm 1.05$  ( $P < .0001$ ) in the paratendinosis group,  $3.39 \pm 0.5$  to  $1.57 \pm 0.66$  ( $P < .0001$ ) in the proximal tendinopathy group, and  $3.32 \pm 0.58$  to  $1.47 \pm 0.7$  ( $P = .0001$ ) in the insertional tendinopathy group. Based on these results, we believe that shockwave therapy serves as a safe, viable, and effective option for the treatment of Achilles tendinopathy.

© 2011 by the American College of Foot and Ankle Surgeons. All rights reserved.

Achilles tendinopathy is a common cause of posterior heel pain. An estimated 30% to 50% of sporting injuries are tendon related, and Achilles tendinopathy specifically has a prevalence of 11% in runners and 14.5% in military recruits, whereas observational studies in elite gymnasts have demonstrated a 17.5% prevalence in women and 12.5% prevalence in men (1–3). Former distance runners are thought to have a lifetime risk of developing Achilles tendinopathy of 52% (4). The condition is frequently attributed to running and jumping activities, although the problem is not just confined to the active population but is also seen in sedentary individuals (5, 6). Symptoms may include, but are not limited to, pain, swelling, and loss of function, such that the condition may interfere with sporting activity and the activities of daily

living (5–7). Despite its prevalence, the etiology of the condition in many cases remains unclear. Proposed causal factors range from biomechanical and anthropometric abnormalities to training and equipment errors in athletes (3, 5, 7–9). More recently there has been great interest in the condition on a molecular and genetic level, although a great deal of debate exists in regard to the precise interpretation of the histology and the pathogenesis of the condition (7–11).

Potential therapeutic interventions for Achilles tendinopathy are many and varied, both conservative and surgical. Systemic nonsteroidal anti-inflammatory drugs (NSAIDs), local glucocorticosteroid injections, sclerosing injections, laser and radiofrequency therapies, massage techniques, and instillation of platelet-rich plasma have all been described as potentially useful nonoperative interventions (6, 7). Despite this breadth of options, eccentric calf exercises remain one of the cornerstones of treatment (5–7).


More recently, based on promising results observed with other similar pathologies, high- and low-energy extracorporeal shockwave therapy (ESWT) has been used for the treatment of Achilles tendinopathy (8–15). Although it is a subject of much debate, it has been

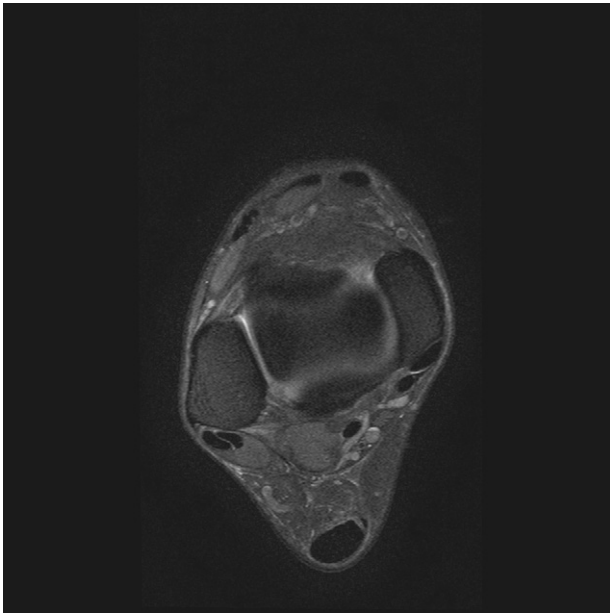
**Financial Disclosure:** None reported.

**Conflict of Interest:** None reported.

Address correspondence to: Amol Saxena, DPM, FACFAS, Department of Sports Medicine, Clark Building, Palo Alto Foundation Medical Group, 795 El Camino Real, Palo Alto, CA 94301.

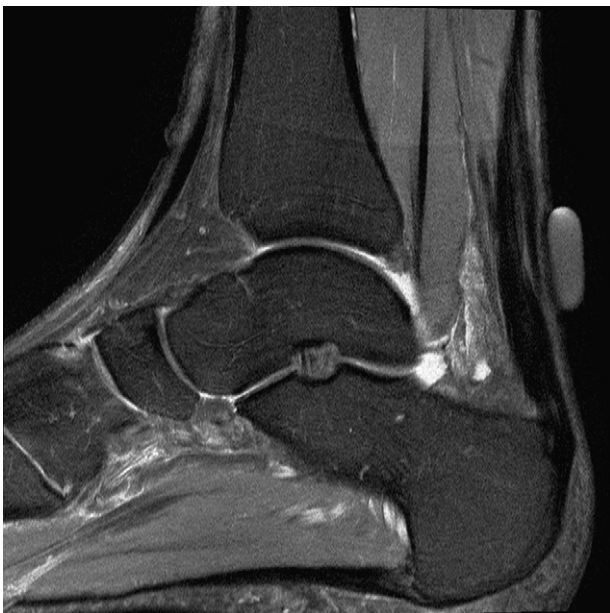
E-mail address: [heysax@aol.com](mailto:heysax@aol.com) (A. Saxena).

 Audio file online only at <http://www.jfas.org>

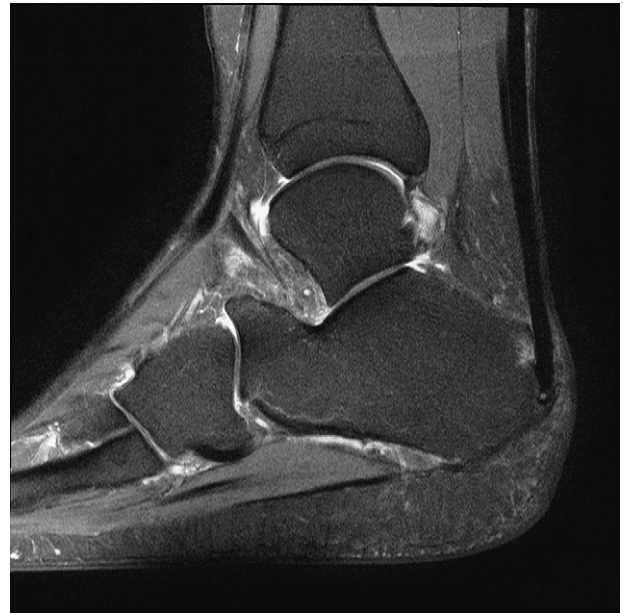

**Fig. 1.** Magnetic resonance image showing the "halo sign" with Achilles paratendinitis and normal tendon in a patient who went on to have surgery.

suggested that such treatment may result in both a short-term analgesic effect as well as a longer-term resolution of the pathology, thus enabling continuation of activity during recovery, which enhances the attractiveness of this form of treatment (8–11). With this background in mind, we undertook a prospective cohort study that focused on the effect of low-energy radial-pulsed-activated (EPAT) shockwave (sound wave) as an isolated treatment for Achilles tendinopathy. We aimed specifically to see if activity levels were improved after treatment with a radial shockwave device that had been previously approved by the United States Food and Drug Administration for this purpose.



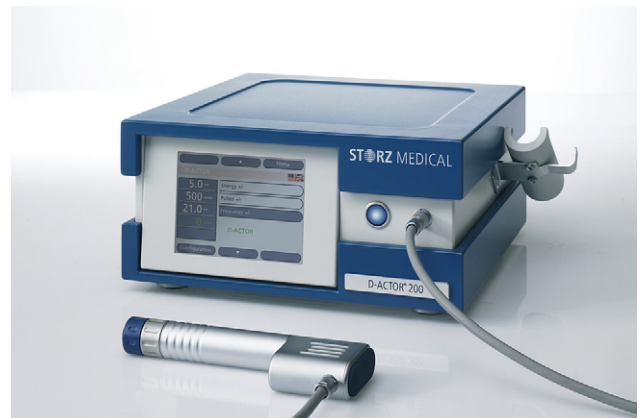**Fig. 2.** Magnetic resonance image showing mucinous degeneration of the Achilles tendon in a patient who went on to have surgery.



**Fig. 3.** Magnetic resonance image showing inflammation of the retro-calcaneal bursa and the Achilles tendon insertion in a patient who went on to have surgery.

#### Patients and Methods

Patients with Achilles tendinopathy from the senior author's practice were voluntarily enrolled in this prospective study from August 2008 through August 2009. All of the patients came from the senior author's (A.S.) clinical practice. Informed consent and institutional review board approval was granted before commencement of data acquisition. The diagnosis of Achilles tendinopathy and identification of the subcategories of tendinopathy were made by clinical examination by the senior author (A.S.) and based on the presence of pain localized to any portion of the Achilles tendon complex including the insertion. Patients were categorized as having tendon pathology localized to the paratenon, the tendon in the "watershed" region (noninsertional region, generally situated 2 to 6 cm proximal to the insertion), or the insertion. Patients diagnosed with paratendinitis involvement displayed diffuse pain along the tendon, not localized to one specific point within the body of the tendon, which typically became more symptomatic with increased activity. They may or may not have palpable crepitus about the tendon, and magnetic resonance imaging (MRI) scans, if obtained, revealed a "halo sign" around the Achilles tendon without intratendinous mucinous degeneration (Figure 1). For para- and tendinopathic patients, MRI was performed if they were unable to perform a single-leg heel raise or patients felt a "pop"; in these patients X-ray was often not performed. For insertional tendinopathic patients X-ray was performed, however, unless they noted symptoms above, MRI was not performed. Noninsertional or insertional tendinosis was diagnosed on the basis of pain localized to the tendon itself, either in the watershed region or at the insertion into the calcaneus, in conjunction with a palpable lump or induration that typically decreased with activity,



**Fig. 4.** D-Actor 200 EPAT device (Storz Medical AG, Taegerwilten, Switzerland).

**Table 1**  
Statistical description\* of the cohort (N = 74 Achilles tendons in 60 patients)

Age (years)	48.32 ± 12.94
Sex	
Female	30 (40.54)
Male	44 (59.46)
Side	
Right	32 (43.24)
Left	42 (56.76)
Bilateral	14 (23.33) <sup>†</sup>
Achilles tendinopathy	
Paratendinosis	32 (43.24)
Noninsertional <sup>‡</sup> tendinopathy	23 (31.08)
Insertional tendinopathy	19 (23.68)
Duration of follow-up (months)	Range 12–24 mos
Complications <sup>§</sup>	0
Roles and Maudsley score	
Before shockwave	3.3 ± .54
After shockwave	1.66 ± .87
Final follow-up via telephone	74 tendons

\* Results shown as mean ± standard deviation for continuous data, or count (%) for categorical data.

<sup>†</sup> Percentage of 60 patients.

<sup>‡</sup> Usually 2 to 6 cm proximal to the insertion.

<sup>§</sup> Rupture, nerve damage, phlebitis, or chronic pain syndrome.

and MRI findings indicative of intratendinous signal change and mucinous degeneration (Figure 2). Patients with insertional tendinopathy also had symptoms involving the retrocalcaneal region, and their standard radiographs may or may not have displayed a superior calcaneal prominence with or without calcific tendinopathy (1, 2, 6, 7), and MRI findings included retrocalcaneal bursal inflammation and degeneration at the Achilles insertion (Figure 3). Exclusion criteria included acute tendon rupture, recent immobilization, pregnancy, current NSAID use, current narcotic use or dependence, age <14 years, or prior surgery for the same condition within the 5 years preceding the current treatment. Also excluded were any patients with follow-up of <1 year. Although radiographs and MRI studies were often performed, they were not a requirement for inclusion. For paratendinopathic and tendinopathic patients, MRI was performed if they were unable to perform a single-leg heel raise or if they felt a “pop” in the tendon on injury. In these patients, moreover, standard radiography was usually not performed. Standard radiography was performed for patients with clinical evidence of insertional tendinopathy, but unless they were unable to perform the ipsilateral heel raise, or if they did not experience the “pop” at the time of injury, as noted above, MRI was not undertaken. Patient demographics and activity levels were abstracted from the medical records, and this information was procured by a researcher not involved in the treatment.

A standardized treatment protocol was used for each patient, specifically 3 shockwave treatments spaced 7 ± 3 days apart with a Storz D-Actor 200 (Storz Medical AG, Taegerwilten, Switzerland) device (Figure 4) to administer 2500 shocks, at 2.4 Bar ranging from 11 to 13 Hz, without anesthesia, applied directly to the affected area. Patients were restricted from ingesting NSAIDs or using additional treatment modalities for 12 weeks after the last shockwave treatment; however, NSAID use was allowed after 12 weeks on an individualized, as-needed basis. No new exercises such as eccentric strengthening were implemented during this time, so we could attempt to isolate the effect of the sound waves. Recommendations for appropriate shoe gear based on foot type, sport, and body habitus were made, but new foot orthoses were not instituted during the 12-week period. Patients were permitted to stretch the gastrocnemius with the knee straight for 15 seconds twice daily and to apply ice only after sports or strenuous activity for 15 minutes.

The Roles and Maudsley (R&M) score (16) was measured before and at least 1 year after administration of the shockwave therapy. This scoring system quantifies disability

**Table 2**  
Comparison of Roles and Maudsley scores and age by tendon condition before and at least 1 year after low-intensity extracorporeal shockwave treatment (N = 74 Achilles tendons in 60 patients)

Achilles Tendon Treatment Group	Age (years)	Roles and Maudsley Score			Improved <sup>†</sup> n (%)
		Pretreatment	Posttreatment	P Value*	
Paratendinosis (n = 32)	44.2 ± 13.3	3.22 ± 0.55	1.84 ± 1.05	< .0001	24 (75)
Noninsertional tendinopathy (n = 23) <sup>‡</sup>	53.1 ± 14.5	3.39 ± 0.5	1.57 ± 0.66	< .0001	18 (78.26)
Insertional tendinopathy (n = 19)	53.9 ± 9.9	3.32 ± 0.58	1.47 ± 0.7	.0001	16 (84.21)
P value <sup>§</sup>	0.0003				

\* Student's *t* test (probabilities were the same using the Wilcoxon signed ranks test).

<sup>†</sup> Overall, 58 (78.38%) tendons were improved by at least 1 year after treatment, and 4 (5.41%) tendons failed to satisfactorily improve and were subsequently treated surgically.

<sup>‡</sup> Usually 2 to 6 cm proximal to the insertion.

<sup>§</sup> Kruskal-Wallis test.

based on symptoms limiting daily and recreational activities, ranging from the best, which would be a score of 1 (no pain or limitations of daily and recreational activities), to the worst, which would be a score of 4 (constant pain with inability to undertake daily and recreational activities). Patients were reassessed in the clinic or via telephone interview by a clinician not involved in their treatment at ≥1 year after the shockwave treatment. Note was taken if they were able to resume their activities including sports, and if they subjectively noted “improvement” after the treatment. Even if patients did not note improvement at ≥1 year after treatment, their R&M scores were tabulated and included in the final analysis.

The data were analyzed by the senior author (A.S.) with Systat 13 (Systat Software, Inc., Chicago, IL), with attention paid to data type and distribution. Statistical significance was defined at the 5% ( $P \leq .05$ ) level, and Student's *t* tests, as well as nonparametric tests, were used to determine differences in age of the patients and pretreatment and posttreatment R&M scores.

## Results

Tables 1 through 4 depict the results obtained in this investigation. A total of 74 Achilles tendons were treated in 60 patients, including 32 (43.24%) left and 42 (56.76%) right tendons, and 14 (23.33%) patients had the treatment performed bilaterally (on both of their Achilles tendons), during the 13-month period extending from August 2008 to August 2009. The range was 12–24 months. Ten other patients (10 tendons) underwent ESWT for Achilles tendinopathy but did not respond to our request to participate in either a telephone interview or clinical follow-up examination and were therefore considered lost to follow-up for no distinctly identifiable reason, hence their data were excluded from the analyses. The overall mean patient age was 48.32 ± 12.94 years (range, 17–74 years), and 30 (40.54%) of the tendons were treated in women and 44 (59.46%) in men. There were 32 (43.24%) tendons treated for paratendinosis, 23 (31.08%) for tendinosis, and 19 (25.68%) for insertional tendinopathy, respectively. Of the patients who underwent bilateral shockwave treatment, 8 (13.33%) displayed paratendinous disease, 4 (6.67%) displayed tendinosis proximal to the insertion, and 2 (3.33%) displayed insertional tendinosis. There were no complications such as tendon rupture, nerve damage, phlebitis, or chronic pain syndrome identified and attributed to the shockwave treatments.

Table 2 depicts the comparison between the pretreatment and posttreatment R&M scores. The mean age of the patients with the 32 (43.24%) tendons that displayed paratendinosis was 44.2 ± 13.3 years, and they had a pretreatment mean R&M score of 3.22 ± 0.55, whereas their posttreatment score was 1.84 ± 1.05, and this difference was statistically significant ( $P < .0001$ ). These patients also noted that 24 (75%) of the tendons were subjectively rated as improved after the treatment. The mean age of the patients with the 23 (31.08%) tendons that displayed proximal tendinopathy was 53.1 ± 14.5 years, and they had a pretreatment mean R&M score of 3.39 ± 0.5, whereas their posttreatment score was 1.57 ± 0.66, and this difference was statistically significant ( $P < .0001$ ). These patients also noted that 18 (78.26%) of the tendons were subjectively rated as improved after the treatment. The mean age of the patients with the 19 (25.68%) tendons that displayed insertional tendinopathy was 53.9 ± 9.9 years, and they

**Table 3**

Comparison of Roles and Maudsley scores by sex, before and after shockwave therapy (N = 74 tendons in 60 patients)

Variable	Pretreatment Roles and Maudsley Score	Posttreatment Roles and Maudsley Score	P Value*
Female sex	3.3 ± .6	1.83 ± .87	< .0001
Male sex	3.3 ± .51	1.55 ± .85	< .0001
	Female sex	Male sex	
Pretreatment roles and Maudsley score	3.3 ± .6	3.3 ± .51	.8815
Posttreatment roles and Maudsley score	1.83 ± .87	1.55 ± .85	.1109

\* Wilcoxon signed ranks test for paired data, and Wilcoxon rank sum (Mann-Whitney U) test for paired data.

had a pretreatment mean R&M score of  $3.32 \pm 0.58$ , whereas their posttreatment score was  $1.47 \pm 0.7$ , and this difference was statistically significant ( $P = .0001$ ). These patients also noted that 16 (84.21%) of the tendons were subjectively rated as improved after the treatment. Overall, 58 (78.38%) of the tendons were noted by the patients to have subjectively improved after shockwave treatment, and the proportion of patients that improved after the treatment ranged from 75% to 84.21% when stratified by the location of Achilles tendinopathy. Four (5.41%) tendons in 4 (6.67%) separate patients failed to satisfactorily improve and eventually underwent surgical intervention by the senior author (A.S.). There were no statistically significant differences in the pretreatment and posttreatment scores between men and women for any of the tendon conditions (Table 3). Interestingly, the patients in the paratendinosis ( $41.44 \pm 14.01$  years) group were statistically significantly younger than those in the proximal ( $53 \pm 8.9$  years) and insertional ( $54.26 \pm 9.74$  years) tendinopathy groups, and these differences were statistically significant ( $P = .0012$  and  $P = .0063$ , respectively) (Table 4). Comparison of the mean ages of those in the noninsertional ( $53 \pm 8.9$  years) and insertional ( $54.26 \pm 9.74$  years) tendinosis groups did not reveal a statistically significant difference ( $P = .573$ ).

## Discussion

Previous research in the area of Achilles tendinopathy treated with ESWT is somewhat limited and in the past has not provided conclusive results. Although Furia has found relatively promising findings with the use of high-energy ( $> 0.5$  mJ/mm<sup>2</sup>) ESWT in the treatment of both insertional and noninsertional (usually 2 to 6 cm proximal to the tendon insertion) Achilles tendinopathy, little has been published regarding the use of low-energy ( $< 0.5$  mJ/mm<sup>2</sup>) ESWT in this pathology (9, 10). Two studies regarding low-energy ESWT are particularly noteworthy. The first, a randomized, placebo controlled trial by Costa (4) treated a heterogeneous group of Achilles tendinopathies and found no difference in pain relief between the treatment and control groups over a 1-year follow-up period. The study used a protocol of 3 treatments given at monthly intervals and used a visual analog scale to analyze pain relief. However, the sample size was limited to 49 patients overall, and some authors have since criticized the study on methodological issues (17). The second investigation,

**Table 4**

Comparison of age by location of Achilles tendinopathy (N = 74 tendons in 60 patients)

Age (years) by Location of Tendinopathy		P Value*
41.44 ± 14.01, paratendinosis (n = 32)	53 ± 8.9, noninsertional tendinopathy (n = 23) <sup>†</sup>	.0012
41.44 ± 14.01, paratendinosis (n = 32)	54.26 ± 9.74, insertional tendinopathy (n = 19)	.0063
53 ± 8.9, noninsertional tendinopathy (n = 23)	54.26 ± 9.74, insertional tendinopathy (n = 19)	.5730

\* Wilcoxon signed ranks test.

<sup>†</sup> Usually 2 to 6 cm proximal to the insertion.

also a randomized controlled trial (RCT) by Rompe et al (5), compared conservative management with eccentric strengthening and low-energy ESWT (radial waves, similar technology used in our study) protocols for the treatment of mid-portion Achilles tendinopathy only. This trial used similar sized samples and visual analog scores and Likert scales to assess pain relief. A protocol of 3 shockwave treatments with a radial device at weekly intervals was administered, and a statistically significant difference was found in terms of pain relief between the control group and the 2 treatment groups over a 4-month follow-up; however, no differences were found between the 2 active treatment groups. Approximately 60% of the patients in the shockwave and eccentric training group had significant improvement, but interestingly doing nothing (i.e., “rest” only) also resulted in improvement in 20% of patients. Neither of the aforementioned studies investigated the level of activity of their participants after treatment.

A recent systematic review on the nonoperative management of mid-portion Achilles tendinopathy concluded that further investigation was required in regard to the use of ESWT in this pathology (6). It can be seen, therefore, that based on the current biomedical literature, there is increasing knowledge regarding the efficacy of this treatment modality in patients with Achilles tendinopathy and that further investigation is necessary, particularly with regards to long-term follow-up in these patients. In addition, no previous published study has been performed with a sample size of  $N > 25$  patients administered low-intensity ESWT for the treatment of Achilles tendinopathy. Our review of the literature also highlighted the fact that little is known about the return of patients to activity, regardless of their pain score.

We realize that our investigation, like many prospective cohort studies, is likely to have been influenced by a number of methodological shortcomings. Although we did not measure pain with a visual analog scale, we feel that our use of the R&M score was even more useful, because it takes into consideration musculoskeletal functional activity. Finally, we can only speculate as to the reason why we had a high number of “drop-outs.” Many ESWT studies performed as RCTs have a stipend for participants, whereas non-RCTs often have patients paying for their treatment. In the latter scenario, patients may rate the results of their treatment more favorably. In our study, patients were not charged for the EPAT treatment, only the office visit fee. Because they were not paid for their participation, they may have been less likely to return for follow-up. Other studies based in clinical practices may be biased if patients are paying for treatment. By not charging for the EPAT treatment in our study, we feel we eliminated this bias, i.e., clinicians and patients reporting favorable results because they are either getting paid or receiving financial incentive for the treatment.

We can only speculate as to the reason why we had a high number of “drop-outs.” Many ESWT studies performed as RCTs have a stipend for participants, while non-RCTs often have patients paying for their treatment. In the latter scenario, patients may rate the results of their treatment more favorably. In our study, patients were not charged for the EPAT treatment, only the office visit fee. Because they were not paid for their participation, they may have been less likely to return for follow-up. Other studies based in clinical practices may be biased if patients are paying for treatment. By not charging for the EPAT treatment in our study, we feel we eliminated this bias (i.e., clinicians and patients reporting favorable results because they are either getting paid or receiving financial incentive for the treatment). Another scenario for lack of patient willingness for follow-up may be due to the phone call method and discourse that ensued; a standardized script may have been helpful.

Our study showed statistically and clinically significant improvements in 58 (78.38%) of 74 tendons treated with the low-energy radial shockwave device at least 1 year after treatment. We documented

improvement in activity level, which is beneficial not only for athletic individuals but also for anyone required to work on their feet. Interestingly, no adverse effects were observed, and athletic patients were able to continue their activity. Furthermore, we noted that paratendinosis occurred in patients who were statistically significantly younger than those with noninsertional and insertional tendinosis, although this did not appear to be clinically significant in regard to the proportion of patients that improved after the treatment. The low-energy radial shockwave (EPAT) was beneficial in patients with Achilles tendinopathy, and we believe that this modality should be considered as a viable nonsurgical treatment option for patients with this condition. Moreover, the results of this investigation could be useful in the development of future prospective cohort studies and randomized controlled trials that focus on the treatment of Achilles tendinopathy.

### Acknowledgment

Marshall Shieh, DPM, helped collect the data for this study.

### References

1. Jarvinen TA, Kannus P, Maffulli N, Khan KM. Achilles tendon disorders: etiology and epidemiology. *Foot Ankle Clin* 10(2):255–266, 2005.
2. Johnston E, Scranton P Jr, Pfeffer GB. Chronic disorders of the Achilles tendon: results of conservative and surgical treatments. *Foot Ankle Int* 18(9):570–574, 1997.
3. Paavola M, Orava S, Leppilahti J, Kannus P, Jarvinen M. Chronic Achilles tendon overuse injury: complications after surgical treatment. An analysis of 432 consecutive patients. *Am J Sports Med* 28(1):77–82, 2000.
4. Costa ML. Shock wave therapy for chronic Achilles tendon pain. *Clin Orthop Relat Res* 440:199–204, 2005.
5. Rompe JD, Nafe B, Furla J, Maffulli N. Eccentric loading, shock-wave treatment or a wait-and-see policy for tendinopathy of the main body of tendo-Achillis: a randomized controlled trial. *Am J Sports Med* 35:374–383, 2007.
6. Magnussen RA, Dunn WR, Thomson AB. Nonoperative treatment of mid-portion Achilles tendinopathy: a systematic review. *Clin J Sports Med* 19:54–64, 2009.
7. Krishna Sayana M, Maffulli N. Insertional Achilles tendinopathy. *Foot Ankle Clin* 10(2):309–320, 2005.
8. Furla JP. Extracorporeal shockwave therapy in the treatment of chronic insertional Achilles tendinopathy. *Orthopade* 34(6):571–578, 2005.
9. Furla JP. High-energy ESWT as a treatment for chronic insertional Achilles tendinopathy. *Am J Sports Med* 34:733–740, 2006.
10. Furla JP. High-energy ESWT as a treatment for chronic noninsertional Achilles tendinopathy. *Am J Sports Med* 36:502–508, 2008.
11. Orhan Z, Ozturan K, Guven A, Cam K. The effect of extracorporeal shock waves on a rat model of injury to tendo Achillis. A histological and biomechanical study. *J Bone Joint Surg [Br]* 86(4):613–618, 2004.
12. Costa ML, Shepstone L, Donell ST, Thomas TL. Shock wave therapy for chronic Achilles tendon pain: a randomized placebo-controlled trial. *Clin Orthop Relat Res* 440:199–204, 2005.
13. Rompe JD, Hope C, Kullmer K, Heine J, Burger R. Analgesic effect of extracorporeal shock-wave therapy on chronic tennis elbow. *J Bone Joint Surg [Br]* 78(2):233–237, 1996.
14. Weil LS Jr, Roukis TS, Weil LS, Borrelli AH. Extracorporeal shock wave therapy for the treatment of chronic plantar fasciitis: indications, protocol, intermediate results, and a comparison of results to fasciotomy. *J Foot Ankle Surg* 41(3):166–172, 2002.
15. Ogden JA, Alvarez R, Levitt R, Cross GL, Marlow M. Shock wave therapy for chronic proximal plantar fasciitis. *Clin Orthop Relat Res* 387:47–59, 2001.
16. Roles NC, Maudsley RH. Radial tunnel syndrome: resistant tennis elbow as nerve entrapment. *J Bone Joint Surg Br* 54:499–508, 1972.
17. Rompe JD. Letter to the editor: shock wave therapy for chronic Achilles tendon pain: a randomized placebo controlled trial. *Clin Orthop Relat Res* 445:276–277, 2006.