

# Extracorporeal membrane oxygenation support of donor abdominal organs in non-heart-beating donors

**Ko WJ, Chen YS, Tsai PR, Lee PH.** Extracorporeal membrane oxygenation support of donor abdominal organs in non-heart-beating donors.

Clin Transplantation 2000: 14: 152–156. © Munksgaard, 2000

**Abstract:** Both family consent and legal consent were required for organ/tissue donation from non-heart-beating donors (NHBD) in Taiwan. A district attorney had to come to the bedside to confirm the donor's asystole, confirm the family consent, and complete some legal documents before a legal consent was issued for organ donation. The resultant warm ischemic time would be unpredictably long and in fact precluded the organ donation from NHBD in Taiwan. We developed a method of using extracorporeal membrane oxygenation (ECMO) to maintain NHBD for a longer time and prevent warm ischemic injury of the donor abdominal organs. After ventilator disconnection in NHBD, phentolamine and heparin were injected and mannitol infusion was given. After the donor's asystole was confirmed by the electrocardiogram (EKG) strip recording, the ECMO support was set up through the right femoral veno-arterial route, an occlusion balloon catheter was inserted through the left femoral artery to occlude the thoracic aorta, and bilateral femoral arteries were ligated. Usually, the ECMO could begin within 10 min after the donor's asystole. The ECMO, combined with a cooler, provided cold oxygenated blood to the abdominal visceral organs, and prevented their warm ischemic injuries. Under the ECMO support (range: 45–70 min), eight renal grafts were procured from 4 NHBD. With the exception of the first two renal grafts with delayed function, all others had immediate function postoperatively and dialysis was no longer needed. In conclusion, by our ECMO technique, NHBD could be maintained for a longer time and the renal grafts had better immediate postoperative function than those reported by other methods.

**Wen-Je Ko, Yih-Shang Chen, Pi-Ru Tsai and Po-Huang Lee**

Department of Surgery, National Taiwan University Hospital, Taipei, Taiwan

Key words: extracorporeal membrane oxygenation – kidney transplantation – non-heart-beating donor

Corresponding author: Po-Huang Lee, M.D., Department of Surgery, National Taiwan University Hospital, 7 Chung-Shan S. Road, Taipei, Taiwan 100

Accepted for publication 4 October 1999

Due to the cultural background, organ donation from brain-dead donors was not common in Taiwan, and there were only 100 brain-dead donors or so each year in this island country with a population of 22 million. Non-heart-beating donors (NHBD) could be an additional source to increase donor organs (1). There were at least three situations that NHBD could be considered for organ donation in Taiwan: 1) The donor was clinically brain dead, but had pulmonary dysfunction that precluded an apnea test needed to verify the brain death. The pulmonary dysfunction could result

from pulmonary contusion, neurogenic pulmonary edema, acute respiratory distress syndrome, etc., and the apnea test could not be completed due to its resultant hypoxemia and hemodynamic instability. 2) The donor had a severe brain lesion, which was incompatible with survival but did not fulfil the brain-death criteria. 3) Owing to some cultural or religious belief, the family accepted donor organ procurement only after the donor's heart beats had stopped. However, we never tried organ procurement from NHBD before in Taiwan because of some practical difficulties. Both family consent and

legal consent were required for organ procurement from an asystolic donor. A district attorney had to come to the hospital to confirm the donor's asystole at the bedside, confirm the family consent, and complete some legal procedures before he/she gave a legal consent for organ procurement from NHBD. Only after these legal procedures, could we send the donor to the operation room for organ procurement. However, a district attorney could not always stand by in the hospital due to a busy schedule. In a word, the warm ischemic time would be unpredictably long and prohibited a successful organ transplantation. In this paper, we report a new method to maintain NHBD with extracorporeal membrane oxygenation (ECMO), and this is also the first reported NHBD of kidney in Taiwan.

### Patients and methods

When a patient was accepted as a NHBD, the family consent was first obtained after the explanation of the procedures to the family. The ECMO system (cat. no. CB2505; Medtronic Inc., Anaheim, CA, USA), including centrifugal pump and oxygenator, was primed with normal saline alone. The priming normal saline was supplemented with CaCl<sub>2</sub> up to a concentration of 1 mmol/L of calcium to prevent acute hemodilution hypocalcemia after the donor was put on the ECMO support. A temperature controller (11160 dual heater-cooler; Sarns/3M, Ann Arbor, MI, USA) was connected to the ECMO to cool down the recirculating priming solution in the ECMO circuit. The temperature set-point was 4°C.

Bilateral femoral areas were disinfected and well draped when the ECMO system was being prepared. After all were ready, we stopped all catecholamine infusion, and disconnected the ventilator. Twenty-five thousand units of heparin and 10 mg of phentolamine were injected intravenously. After the heart beats had stopped, a strip of EKG was recorded for legal document of asystole. Then the right femoral artery and vein were dissected and cannulated, and the cannulae were connected to the ECMO system. Usually, ECMO began to run within 10 min after the asystole. Initial centrifugal pump speed was 2000 rounds/min and ECMO blood flow was around 2 L/min. Sweep gas flow through the oxygenator was 2 L/min and oxygen fraction (FiO<sub>2</sub>) of the sweep gas was 0.6. Mannitol (20% in concentration) was infused into the ECMO circuit at a rate of 300 cm<sup>3</sup>/h immediately after the ECMO began to run. The left femoral artery was dissected, and an occlusion balloon catheter (OBW/40/8/2/100; Boston Scientific Ireland Ltd., Galway, Ireland) was pushed into the left

femoral artery through a guidewire until the proximal end of the balloon was above the level of xyphoid process. The balloon was inflated to a maximum diameter of 40 mm to occlude the thoracic aorta, and both femoral arteries were ligated around the ECMO arterial cannula and the balloon catheter (Fig. 1). The ECMO was a recirculating closed-circuit system, and did not need replacement and drainage of the perfusing medium. The ECMO used the patient's own blood, cooled and oxygenated, as the perfusing medium. Because of hemodilution from normal saline priming solution in the ECMO circuit, the hematocrit was usually between 25 and 30%. All ECMO blood flow was directed to perfuse the abdominal visceral organs, and the warm ischemia of them was prevented. Bilateral femoral wounds were closed primarily. A district attorney came to the bedside to make sure the asystole of the donor, interviewed with the family to confirm their consent for organ donation, and completed some legal documents. Only after all these legal procedures, a legal consent was given to us for organ procurement. Then we sent the donor to the operation room for the organ procurement.

For the convenience of transport, the temperate controller was disconnected temporarily, and a small O<sub>2</sub> cylinder was used to supply O<sub>2</sub> to the ECMO oxygenator. After the donor was sent into the operation room, the temperature controller with 4°C set-point was reconnected to the ECMO, and gas with FiO<sub>2</sub> 0.6 and gas blow 2 L/min for the ECMO oxygenator was again supplied through a gas flow meter.

Laparotomy and kidney procurement were done as usual. The occlusion balloon was deflated and pulled out through the left femoral wound, and aorta was clamped just above the diaphragm. The abdominal aorta was cannulated at its lower end, ECMO pump was stopped, and low abdominal aorta was ligated around the perfusion cannula. Cold lactated Ringer solution, followed with Euro-Collins solution, perfused the abdominal organs through the perfusion cannula. Instead of the traditional method of cutting inferior vena cava for venous drainage, we clamped arterial route of the ECMO, and released the clamp on the drain tube of the oxygenator. Then the ECMO centrifugal pump ran at a lower rate of 500 rounds/min, and venous drainage was collected through this oxygenator drain tube (Fig. 1). The abdominal operative field was kept clean and dry. After the perfusion, both kidneys were removed *en bloc* and stored in icy cold Ringer solution.

If the renal graft did not function immediately after the operation, hemodialysis was given as necessary. Initially, cyclosporine was given intravenously, but immediately shifted to oral form

when oral intake became feasible. Maintenance immunosuppression included cyclosporine, prednisolone, and mycophenolate mofetil.

### Results

In 1998, there were 46 patients undergoing renal transplantation at National Taiwan University Hospital. Two recipients received renal grafts from living-related donors, 36 from cadaver donors, and 8 (17%) from NHBD. It was 10–20 min from ventilator disconnection to the donor's asystole. Because of our experienced ECMO team, ECMO support could begin within 10 min after the donor's asystole. The duration of ECMO support for these NHBD ranged from 45 to 70 min. The demography of donors and recipients and early results of renal transplantation are shown in Table 1. Recipients 1a and 1b needed hemodialysis four and three times, respectively, after the renal transplantation due to delayed graft function. However, function of renal grafts recovered quickly, and

hemodialysis was no longer needed 12 and 6 days after the transplantation, respectively. In fact, phentolamine injection and mannitol infusion were not given in donor 1: maybe these contributed to the delayed function of renal grafts. However, in all subsequent cases, renal grafts functioned immediately after the transplantation, and had good urine output. By our method of ECMO support, most renal grafts from NHBD had immediate function postoperatively, even though the time interval from donor's asystole to renal graft harvest was around 1 h. The time delay caused by our legal requirements no longer prevented organ donation from NHBD in our hospital.

### Discussion

Renal allograft from NHBD could have a comparable long-term result as that obtained from brain-dead heart-beating donors (2, 3). However, due to high incidence of delayed graft function or primary graft non-function, we should not be too

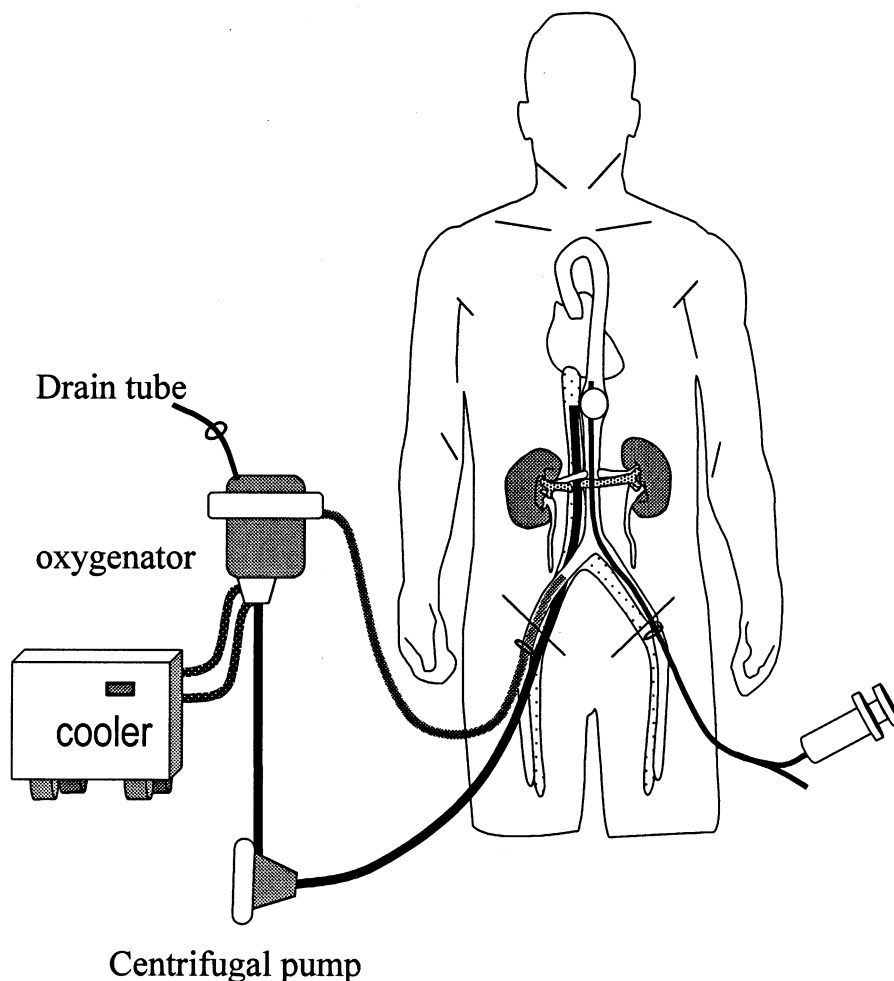


Fig. 1. The donor kidneys were supported by extracorporeal membrane oxygenation through the right femoral veno-arterial route.

Table 1. The demography of donors and recipients, and renal transplantation results

Donor no.	Sex/age	Etiology	Reason for NHBD <sup>a</sup>	ECMO (min)	Recipients no.	Sex/age	Cold storage time (h)	Immediate graft function	Cr at 1 m/o (mg/dL)
1	F/39	Stroke	I	65	1a	F/42	4.5	No	2.3
					1b	F/56	3.5	No	1.4
2	M/46	H.I.	III	45	2a	F/53	4.0	Yes	1.2
					2b	M/32	4.0	Yes	1.7
3	M/23	H.I.	II	70	3a	F/49	4.0	Yes	1.8
					3b	F/60	6.0	Yes	1.4
4	M/45	H.I.	I	45	4a	M/45	5.0	Yes	1.6
					4b	M/38	5.0	Yes	1.2

Cr, serum creatinine; ECMO, extracorporeal membrane oxygenation; H.I., head injury.

<sup>a</sup> Reason for NHBD: I, clinically brain dead, but apnea test precluded by pulmonary dysfunction; II, brain lesion incompatible with life, but not brain dead; III, family accept organ procurement only after the donor's asystole.

optimistic in organ transplantation from NHBD (4). Hoshinaga et al. reported that only 16.5% of renal grafts from NHBD functioned immediately after the transplantation (5). Acute tubular necrosis was common in renal grafts from NHBD, and the incidence of delayed renal graft function was reported to be as high as 65% (6) or 50–77% (7). Kievit et al. reported that 45–50% of renal grafts from NHBD were discarded for different reasons (7). Warm ischemic time was the most important determining factor for function of renal grafts from NHBD. When it was more than 10 min, the prognosis would be guarded (8). The allowable warm ischemic time is very limited for a successful renal transplantation from NHBD.

In Taiwan, both family consent and legal consent are required for tissue/organ procurement from an asystolic donor, and a district attorney must come to the bedside to complete some legal procedures before he/she signs the legal consent. This is why for NHBD in Taiwan only tissue donation was feasible before, because the warm ischemic time would be prohibitively long for a successful organ transplantation. Our new method to support NHBD with ECMO could solve the problem in our situation. After ECMO support for up to 70 min, renal grafts were procured as usual and they could function immediately after the transplantation.

*In situ* cooling technique had been developed to prevent warm ischemic injury in donor organs from NHBD (9). The technique included abdominal aorta cannulation with a double-balloon catheter through the femoral artery, infusion of large amount of cold lactated Ringer solution through the catheter, and blood drainage through a femoral vein cannula. In comparison to *in situ* cooling technique, our ECMO support in NHBD had several advantages. *In situ* cooling technique

needed 6 L or more of cold solution to cool down the abdominal organs of NHBD (5, 9, 10), this would require a lot of nursing work to prepare the cold solution and replace it during the perfusion; collection of a large amount of venous drainage was another problem. In comparison, our ECMO method was simple and labor saving, because no extra solution was needed to run the ECMO after its priming with normal saline. Our ECMO method could maintain a steady lower temperature in the abdominal organs of NHBD, because a temperature controller continued to cool down the ECMO recirculating blood flow. Someone irrigated the intraperitoneal cavity with cold solution to help maintain a lower intraabdominal temperature, but this increased the technique complexity (11). Due to technical error of catheter malposition, a significant proportion of donor kidneys was not well perfused and lost when *in situ* cooling technique was used for organ procurement from NHBD. Koostra et al. failed five times in 49 procurements (12), and Hassen et al. failed seven times in 32 procurements (10). Our ECMO support could provide 2 L/min of cold oxygenated blood into the right femoral artery. Because of bilateral femoral arteries ligation and thoracic aorta occlusion by a balloon catheter, all abdominal organs were well perfused. There would be less chances of technical errors to lose donor kidneys by our ECMO technique, and we believed that not only kidneys but also liver, pancreas, etc., could be well protected from warm ischemic injury.

Koyama et al. reported a special design of portable cardiopulmonary bypass for renal procurement from NHBD (13). This special design supplied oxygenated blood to the whole donor body rather than the abdominal organs alone. Due to transport difficulty, the cardiopulmonary bypass was disconnected after venous blood temperature

was decreased to about 15°C, then the donors were transferred to the operating room. In comparison, our technique used the commercial product, was easy to prepare, and perfused cold oxygenated blood only to the abdominal organs. Because of continuous cold oxygenated blood supply, our ECMO technique could maintain abdominal organs of NHBD for a longer time, and made organ procurement from NHBD less hasty a task. Due to the protection of donor kidneys by our ECMO technique, incidence of delayed graft function or primary graft non-function should decrease. By portable cardiopulmonary bypass, renal grafts from NHBD had immediate function after the transplantation in only 3 of 34 recipients (13). On the contrary, in our reported series, except the first 2 cases, all other 6 renal grafts had immediate function postoperatively. Immediate renal graft function had advantages of improving detection of acute rejection, permitting early therapeutic cyclosporine dose, simplifying fluid and electrolyte management, and decreasing cost and hazard of dialysis. Scarcity of donor organs had been the bottleneck of organ transplantation. Without this ECMO technique, renal transplantation from NHBD would be impossible in our situation. All these advantages could justify the cost of ECMO used in our situation. In a word, our ECMO technique could decrease warm ischemic injury of donor kidneys from NHBD, and improve the early results of renal transplantation from NHBD. Because of the experienced ECMO team in our hospital, we did not need additional equipment, personnel, and training to set up this ECMO-supported NHBD program. In conclusion, if ECMO is available in your hospital, we recommend using it in abdominal donor organ procurement from NHBD.

## References

- CASAVILLA A, RAMIREZ C, SHAPIRO R, NGHEIM D, MIRACLE K, BRONSTHER O, RANDHAWA P, BROZNICK B, FUNG JJ, STARZL T. Experience with liver and kidney allografts from non-heart-beating donors. *Transplantation* 1995; 59: 197.
- CHO YW, TERASAKI PI, CECKA JM, GJERTSON DW. Transplantation of kidneys from donors whose hearts have stopped beating. *N Engl J Med* 1998; 338: 221.
- WIJNEN RM, BOOSTER MH, STUBENITSKY BM, DE BOER J, HEINEMAN E, KOOSTRA G. Outcome of transplantation of non-heart-beating donor kidneys. *Lancet* 1995; 345: 1067.
- CHANG RW. Transplantation of non-heart-beating donor kidneys. *Lancet* 1995; 346: 322.
- HOSHINAGA K, FUJITA T, NAIDE Y, AKUTSU H, SASAKI H, TSUKIASHI Y, NISHIYAMA N, YANAOKA M, SHINODA M, KANNO T. Early prognosis of 263 renal allografts harvested from non-heart-beating cadavers using an *in situ* cooling technique. *Transplant Proc* 1995; 27: 703.
- CASTELAO AM, GRINO JM, GONZALEZ C, FRANCO E, GILVERNET S, ANDRES E, SERON D, TORRAS J, MORESO F, ALSINA J. Update of our experience in long-term renal function of kidneys transplanted from non-heart-beating cadaver donors. *Transplant Proc* 1993; 25: 1513.
- KIEVIT JK, OOMEN AP, DE VRIES B, HEINEMAN E, KOOSTRA G. Update on the results of non-heart-beating donor kidney transplants. *Transplant Proc* 1997; 29: 2989.
- KINUKAWA T, OHSHIMA S, FUJITA T, ONO Y. Exploration of the system for cadaver kidney transplantation with the non-heart-beating donor: efficacy of *in situ* cooling and low-dose cyclosporine. *Transplant Proc* 1993; 25: 1524.
- GUILLARD G, RAT P, HAAS O, LETOURNEAU B, ISNARDON JP, FAVRE JP. Renal harvesting after *in situ* cooling by intra-aortic double-balloon catheter. *Transplant Proc* 1993; 25: 1505.
- HASSAN TB, JOSHI M, QUINTON DN, ELWELL R, BAINES J, BELL PR. Role of the accident and emergency department in the non-heart-beating donor programme in Leicester. *J Accid Emerg Med* 1996; 13: 321.
- MATSUNO N, KOZAKI M, SAKURAI E, UCHIYAMA M, IWAHORI T, KOZAKI K, KONO K, TANAKA M, TAMAKI T, TAMAKI I. Effect of combination *in situ* cooling and machine perfusion preservation on non-heart-beating donor kidney procurement. *Transplant Proc* 1993; 25: 1516.
- KOOSTRA G, WIJNEN R, VAN HOOFF JP, VAN DER LINDEN CJ. Twenty percent more kidneys through a non-heart beating program. *Transplant Proc* 1991; 23: 910.
- KOYAMA I, SHINOZUKA N, WATANABE T, OGAWA N, NAGASHIMA N, ASAMI H, OZAKI S, ADACHI R, OMOTO R. Utilization of kidneys from non-heart-beating donors by portable cardiopulmonary bypass. *Transplant Proc* 1997; 29: 3550.