

Extracorporeal Shock Wave Therapy for the Treatment of Chronic Plantar Fasciitis: Indications, Protocol, Intermediate Results, and a Comparison of Results to Fasciotomy

Lowell Scott Weil, Jr., DPM, FACFAS,¹ Thomas S. Roukis, DPM, AACFAS,² Lowell Scott Weil, Sr., DPM, FACFAS,³ and Anthony H. Borrelli, DPM, FACFAS⁴

A review of the history, mechanism of action, and application of extracorporeal shock wave therapy for chronic plantar fasciitis is presented. The results of 40 feet treated with this modality are reviewed after a mean follow-up time of 8.4 months. All procedures were performed under intravenous sedation and local infiltrative anesthesia. An electrohydraulic shock wave with a mean of 20.6 kV combined with a mean of 2,506 pulses was used. The results of a similar demographic class of patients having undergone a percutaneous plantar fasciotomy at our institution were compared to the results of this cohort of shock wave patients. Eighty-two percent of the patients treated with extracorporeal shock wave therapy were successfully treated as compared to 83% with a percutaneous plantar fasciotomy. The mean score on the 11-point visual analog scale for satisfied patients was 7.9 preoperatively and 2.95 within 7 days postoperatively. After 3 months, the mean visual analog score was 4.2 or 50% of the preoperative value after a mean of 8.4 months following treatment. Eighty-three percent of the patients treated stated that shock wave therapy improved their symptoms. There were no complications encountered in any patient in this study. Extracorporeal shock wave therapy is an effective treatment, which significantly reduces the symptoms associated with chronic plantar fasciitis and compares favorably to the results achieved with surgical intervention in the form of a percutaneous plantar fasciotomy. (The Journal of Foot & Ankle Surgery 41(3):166 – 172, 2002)

Key words: extracorporeal shock wave therapy, heel spur syndrome, percutaneous plantar fasciotomy, plantar fasciitis, shock wave

The history of extracorporeal shock wave dates back to World War II. Submarines that were attacked with depth charges often had structural integrity, yet many members aboard the submarine were critically injured. When autopsies were subsequently performed, the sailors were found to have severe trauma to their internal organs, more specifically to their lungs. This trauma was attributed to sound waves, which penetrated the walls of

the submarine (1). In the late 1970s, this high-level energy produced by shock waves (sound waves) was harnessed and came to be known as extracorporeal shock wave therapy (ESWT). Throughout the 1980s, ESWT or lithotripsy would evolve as a revolutionary and noninvasive treatment of renal calculi. Concomitantly, it was found that ESWT could be beneficial in healing wounds and fracture nonunions, as well as aid in loosening of cement during prosthetic removal and revision replacement (1). In the early 1990s, ESWT started to be utilized for painful tendinosis, chronic proximal plantar fasciitis, and calcific tendinosis of the shoulder (1). The term "shock wave" denotes a high-energy sound wave that terminates in a bursting of energy similar to a mini-explosion. It is essentially the same as a supersonic jet breaking the sound barrier and creating an energy force strong enough to shatter windows. ESWT utilizes a high peak pressure ranging from 5 to 130 Mpa, with a most common energy of 50 Mpa and a broad frequency of 14 Hz to 20 MHz (Fig. 1). The most significant aspect

From Weil Foot & Ankle Institute, Des Plaines, IL. Address correspondence to: Lowell Scott Weil, Jr., DPM, FACFAS, Weil Foot & Ankle Institute, 1455 E. Golf Road, Suite 131, Des Plaines, IL 60016; e-mail: www.weil4feet.com. The authors have received no financial benefits from a commercial party and have no conflicts of interests regarding shock wave devices as they pertain to this article.

¹ Director, Foot and Ankle Fellowship.

² Foot and Ankle Fellow.

³ Director, Foot and Ankle Services.

⁴ Attending Staff Physician

Received for publication March 2, 2001; accepted in revised form for publication December 28, 2001.

The Journal of Foot & Ankle Surgery 1067-2516/02/4103-0166\$4.00/0

Copyright © 2002 by the American College of Foot and Ankle Surgeons

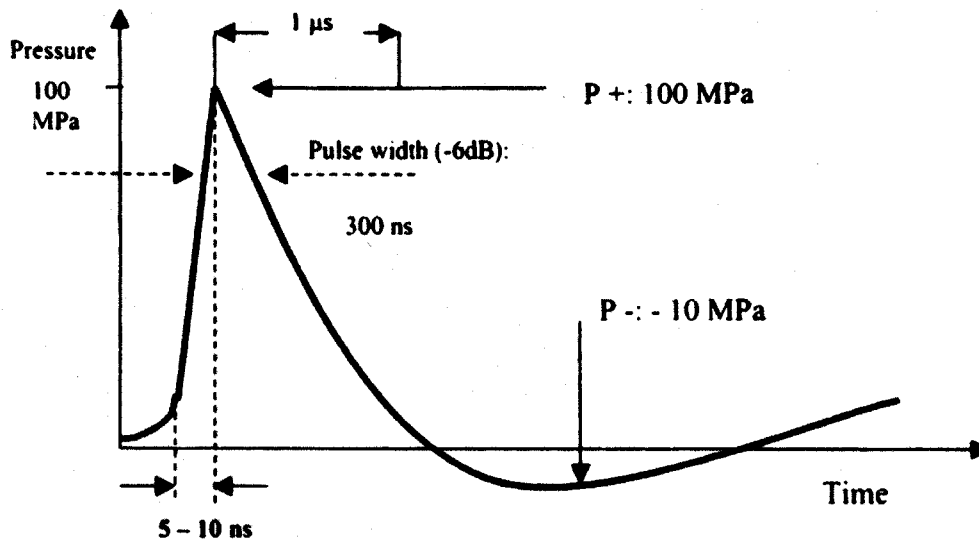


FIGURE 1 Physical properties of the extracorporeal shock wave.

of this unique form of energy is the rapid initial rise in pressure amplitude (500 bar) over a short life cycle of less than 10 ns (2). The action of ESWT is the result of a process called cavitation, which is defined as the formation and movement of bubbles in a fluid. Strong forces exerted in the region of a moving bubble cause mechanical tissue disruption (3). The repair of the mechanical tissue disruption is the theoretical basis for the neovascularization process and subsequent pain relief following ESWT (4).

In order for ESWT to be therapeutic, the energy should be focused at the point of existing pathology. Although the mechanism of ESWT disintegration of renal calculi is well understood (2), the current mechanism of ESWT in the treatment of musculoskeletal disorders is not fully appreciated. Some have used an analogy of creating microtrauma to the tissues with an effect similar to tenderizing meat. The mechanism of pain relief is attributed to a release of enzymes, which effect nociceptor, much like the action of transcutaneous electrical nerve stimulation (TENS). More importantly, studies have shown that neovascularization occurs following the application of ESWT (4 – 7).

Heel pain syndrome is a compilation of disorders affecting the inferior aspect of the heel. These may include proximal plantar fasciitis, inferior calcaneal bursitis, and local entrapment neuropathy (8). Heel pain syndrome is one of the most common complaints seen by foot and ankle specialists, with a frequency of 15% (9) of new patients seeking treatment. Although the exact mechanism responsible for the development of plantar fasciitis is not known, there is a direct relationship between heel pain syndrome and patients with high body mass index (7, 8). Females appear to be affected more frequently than males with this condition (7, 8). There is a professional consensus that 70 – 90% of

heel pain patients can be managed by nonoperative measures (10, 11). When conservative measures fail, surgical plantar fasciotomy with or without heel spur removal and neurolysis of branches of the lateral plantar nerve have been employed (11 – 16).

In a study of 35 patients (27 female, 8 male) with a mean age of 47 years (range 31 – 76) undergoing percutaneous plantar fasciotomy (PPF), Benton-Weil et al. (11) found that conservative treatment prior to surgical intervention ranged from 6 months to 8 years and 66% of the patients had visited multiple doctors in an attempt to relieve their symptoms. All procedures were performed unilaterally. Pain level prior to the PPF was 8.7 (?1.2) on an 11-point visual analog scale. The mean follow-up was 34 months (range 12 – 57). Eighty-three percent of the patients achieved satisfaction following surgical treatment with a 17% complication rate of lateral column (N = 2) and/or peroneal tendon pain (N = 1) lasting for 1 – 6 months postoperatively (11). Barrett et al. (12) and Lundeen et al. (13) achieved similar results using endoscopic plantar fasciotomy (EPF). However, complications such as lateral column pain and nerve injuries have been reported following plantar fasciotomy (11, 14).

There is a consensus that release of the plantar fascia, either percutaneously, endoscopically, or through an open procedure, is an effective treatment without the need for removal of a calcaneal spur formation, when present (15). Martin (16) concluded that subjects with insertional plantar fasciitis could obtain good results with a nonsurgical treatment program. However, he found a correlation that subjects were less likely to have a good outcome if their symptoms persisted for greater than 12 months after beginning an appropriate and comprehensive treatment program. All surgical procedures reported have had

complications including lateral column syndrome, nerve injury, and several weeks of disability. ESWT has been shown to alleviate the symptoms of proximal plantar fasciitis in several studies with minimal complications and disability (17, 18). A prospective study was undertaken to assess the demographics, results of treatments, disability, and complications following ESWT for heel pain syndrome. Furthermore, the results of the ESWT study were then compared to the results of a similar demographic group of heel pain patients.

Materials and Methods

Between February 2000 and March 2001, 94 patients were treated at the Weil Foot and Ankle Institute with a diagnosis of recalcitrant heel pain syndrome. The diagnosis of recalcitrant heel pain was made for those patients who had failed conservative treatment methods which included nonsteroidal anti-inflammatory drugs (NSAIDs), ice application, posterior calf musculature stretching exercises, shoe modifications, over-the-counter and/or custom orthoses, corticosteroid injection(s), night splints, and immobilization.

Inclusion criteria for undergoing ESWT were: 1) patients over the age of 18; 2) symptomatic heel pain of greater than 6 months' duration; and 3) unsuccessful response to conservative care utilizing four or more treatment modalities. Exclusion criteria were prior history of heel surgery and heel pain with systemic comorbidities or nerve-related symptoms (Baxter's nerve entrapment, radiculopathy, or tarsal tunnel syndrome).

Following failure, each patient was offered three options: continuation of nonoperative therapeutic measures, PPF, or ESWT. Forty-nine patients chose to continue with their conservative care, 9 patients chose to undergo PPF, and 36 patients chose to undergo ESWT. For the population undergoing ESWT, 32 patients had the procedure performed unilaterally and 4 patients had the procedure bilaterally. The study involved 36 subjects (40 feet). There were 23 female subjects (25 feet) and 13 male subjects (15 feet) with a mean age of 50.9 (range 26 – 72) years. Each of these patients had a history of heel pain for greater than 6 months with median of 21.6 months (range 6 – 120 months).

Technique of ESWT

Using a VAS (Fig. 2), patients were asked to rate the greatest intensity of heel pain during ambulation (19). Prior to the procedure, patients marked the area of most intense pain with a skin marker. All procedures were performed under intravenous sedation combined with local infiltration of 6 cc of 0.5% bupivacaine using a technique similar to that of the medial administration of a "heel spur" cortisone injection. ESWT was applied

using an electrohydraulic shock wave generator⁵. A special aiming device was used to triangulate the target area.

The head of the shock wave device was coupled to the inferior aspect of the calcaneus using ultrasonic gel as a coupling medium, and then two series of shocks were applied. The energy intensity applied ranged from 17 to 21 kV, 2 Hz, 1500 – 3000 pulses and were divided into two distinct directional applications, which were applied at 45° to the target area (Fig. 3). Following the treatment, a mixture of dexamethasone (2 mg) and triamcinalone (20 mg) was infiltrated into the target area. The patients were then discharged to the postanesthesia unit where they received post-treatment instructions. These included return to regular shoe gear, full weightbearing to tolerance, and no sports activities or excessive walking or standing for 2 weeks. All patients continued with their prior conservative care protocol including foot orthoses, posterior calf musculature stretching exercises, and NSAIDs as needed.

Two patients who were symptomatic at greater than 3 months post-treatment elected to have the procedure repeated. Patients were seen postoperatively at 7 days (?3 days), 6 weeks, and 3 months. All patients in the study completed a post-treatment questionnaire (Fig. 4). The questionnaires of the two patients who had the procedure repeated were based on the results of their second treatment. Analysis of the following was undertaken: duration of follow-up and preoperative pain; pain versus satisfaction; pre- and postoperative visual analog scale (VAS); body mass index (BMI); and effectiveness of ESWT. Using the VAS, patients were evaluated for preprocedure pain, pain at between 4 and 10 days after the procedure, and pain at greater than 3 months post procedure. BMI was evaluated to determine its role in the success of the procedure. The BMI was determined using the National Heart, Lung, and Blood Institute's Formula of weight in kilograms divided by height in meters squared (20). A normal BMI was considered to be between 21 and 24. Statistical analysis, using the Student *t*-test was applied to each parameter. A *p* value of less than .05 was considered to be significant.

Results

At a mean follow-up of 8.4 months (range 3 – 16), 82% of the patients were either very satisfied or satisfied with the results of the ESWT, with 50% of the patients demonstrating greater than 50% improvement on the VAS. The mean kilovolts used during the procedures was 20.6. The mean kilovolts used for the patients who were satisfied with their outcome was 20.6 ± 1 as compared to

⁵ Orbasone, Norland Medical Systems, White Plains, New York

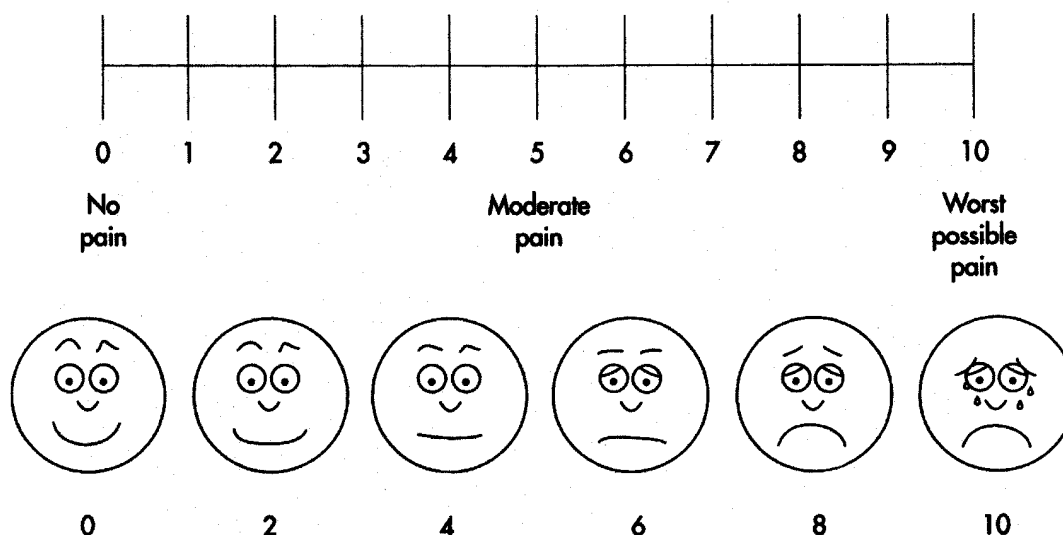


FIGURE 2 Eleven-point visual analog "faces pain rating scale" utilized (19).

20.6 ± 2 for the dissatisfied patients; this was not statistically significant ($p = .939$). The mean duration of preoperative pain was 17.2 months for the satisfied group and 32.9 months for the dissatisfied group. Although not statistically significant, patients who had pain for between 6 and 12 months prior to treatment had a 90% satisfaction rate, while those with pain for greater than 12 months had a satisfaction rate of 72%.

The mean number of pulses used in the procedures averaged 2,506 ± 726. The mean number of pulses was 2,543 ± 732 for the satisfied patients and 2,409 ± 735 for the dissatisfied patients; this was not statistically significant ($p = .613$). The mean BMI of the patients in the study was 28.0 (range 18.7 – 42.3). For the satisfied patients, the mean BMI was 28.1 and for the dissatisfied patients 28.4. This was not statistically significant ($p = .798$).

The overall mean pretreatment VAS pain score was 7.9 (range 5 – 10). The mean pretreatment VAS pain score for the satisfied group was 7.9 and 7.7 for the dissatisfied group; this was not statistically significant ($p = .13$). The mean VAS pain score at the first post-treatment visit (4 – 10 days) for the satisfied group was 2.95 (median of 3) and for the dissatisfied group, 2.8. This was not statistically significant ($p = .887$). At the 3-month follow-up questionnaire, the overall mean VAS pain score was 4.2 with 3.1 for the satisfied group and 7.1 for the dissatisfied group. This was statistically significant ($p = .000$). When asked what effect ESWT had upon their symptoms, 83% of the patients stated that ESWT improved their symptoms, 17% stated that ESWT had no effect upon their symptoms, and no patient stated that ESWT made their condition worse. Those patients whose symptoms were improved were asked to subjectively rate the percentage

of improvement. The overall mean percentage of improvement was 78.1%. The mean percentage of improvement for the satisfied group was 81.2% and 25.0% for the dissatisfied group. Each of the patients who were satisfied stated that, if necessary, they would undergo ESWT again, while none of the patients who were dissatisfied would undergo ESWT again. There was one case of a transient rash localized to the area of treatment that resolved in 6 weeks. No other complications or adverse reactions were noted. The patient's satisfaction with ESWT for chronic plantar fasciitis (82%) was compared with our success obtained following PPF (8) for chronic plantar fasciitis (83%). Both of these groups had a similar patient population and inclusion criteria.

Discussion

The authors consider heel pain syndrome a "chronic disease" rather than a simple condition. The disease requires an ongoing comprehensive program to sustain an effective result and prevent exacerbation. This program includes a serious discussion with patients regarding a weight loss program (with an appropriate referral to a weight reduction facility), posterior calf musculature stretching exercises, refraining from barefoot ambulation, and appropriate supportive footwear and/or orthoses at the first sign of new heel pain symptoms. Although the results of surgery were slightly better, the benefits of no complications, no immobilization, immediate return to work, and resumption of full activities within 2 – 3 weeks make ESWT an attractive alternative for the treatment of chronic plantar fasciitis recalcitrant to nonoperative treatments. This comparison may

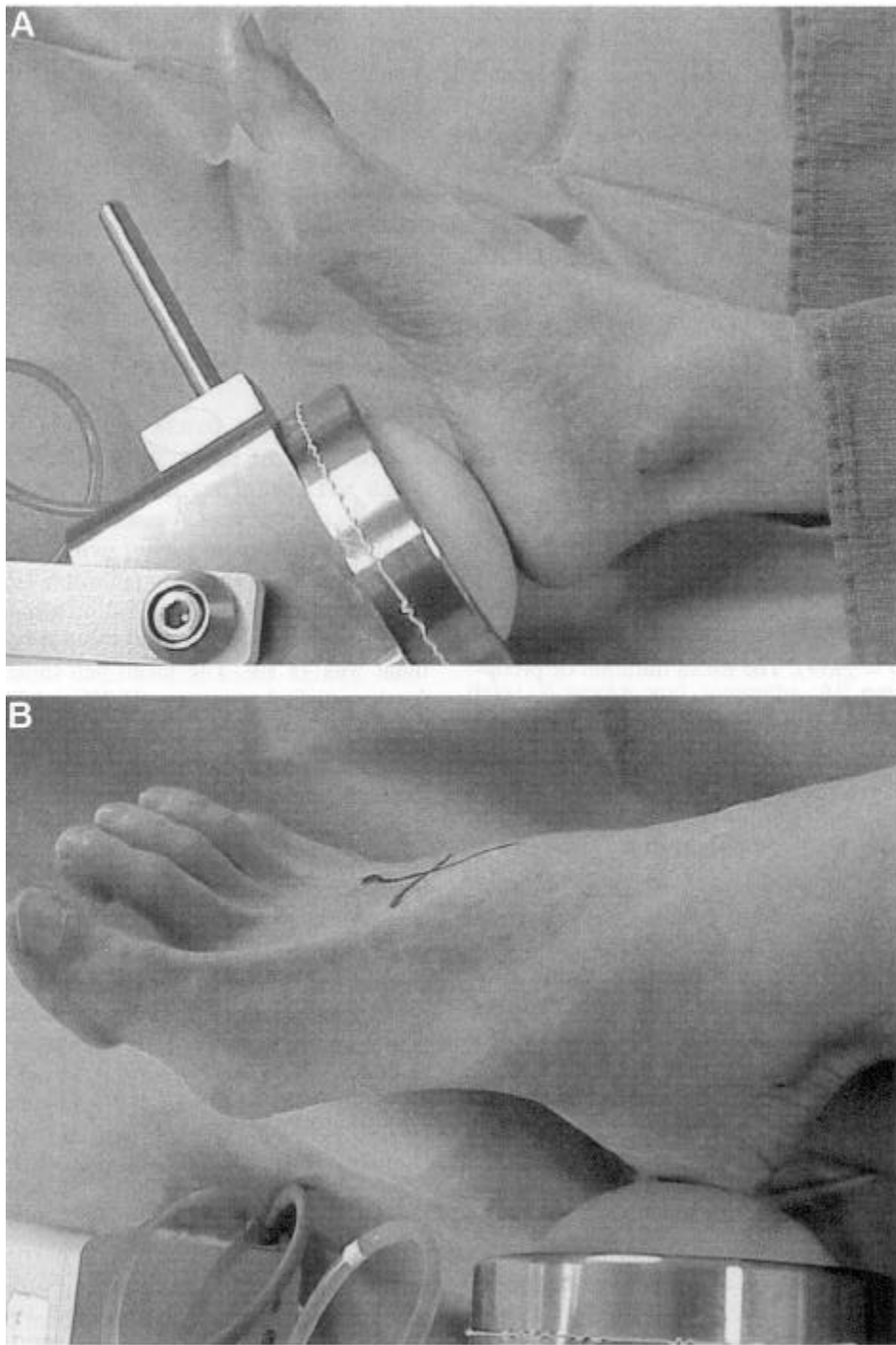


FIGURE 3 A, Position and orientation of the ESWT directly plantar and (B) at a 45 angle to the medial aspect of the heel.

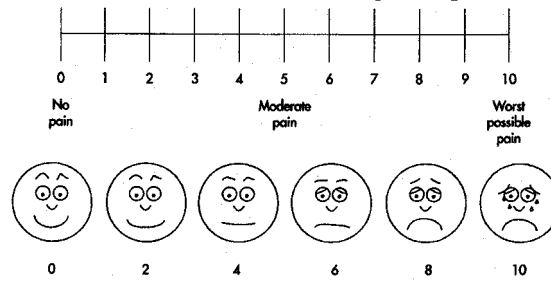
have some valid limitations in that the follow-up of PPF and ESWT was statistically different in each of our studies. Plantar fasciitis can be effectively treated in a conservative manner in a great majority of cases. Patients with recalcitrant symptoms, who have undergone a comprehensive treatment program for 6 months, or patients who have had the condition for greater than 12 months

are less likely to respond to conservative measures (10, 11).

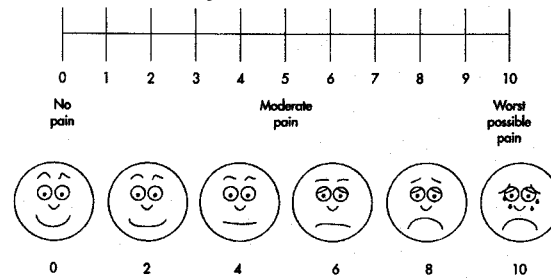
ESWT provides a safe and statistically reliable reduction of pain associated with plantar fasciitis. Conservative measures for at least 6 months should be exhausted prior to application of ESWT. Due to its high success rate and lack of risks and complications, ESWT may be employed

For each of the next three (3) questions use the "faces pain scale rating" and circle the level of pain you are experiencing today:

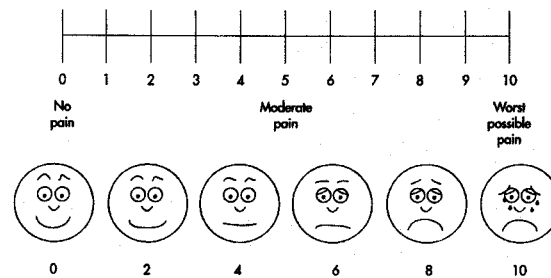
(1) What is your pain level when getting out of bed?



(2) What is your pain level after activity?



(3) What is your pain level at rest?



How did the Extracorporeal Sound-Wave Treatment affect your condition?

- (1) Made it worse
- (2) Did not affect it at all
- (3) Improved it (if yes, how much did your condition improve _____ %)

How did you feel about this treatment for your condition?

- (1) Dissatisfied
- (2) Satisfied
- (3) Very Satisfied

Knowing what you know now, would you have the treatment again? YES/NO

FIGURE 4 Post-treatment questionnaire completed by patients greater than 3 months following extracorporeal shock wave treatment.

References

in the future as an earlier line of treatment. Further studies will need to be undertaken to assess the physiologic and anatomical effects on the plantar fascia following ESWT (17, 21). A larger patient population and a 1-year or longer follow-up will be helpful to determine the "curative effects" of ESWT on chronic plantar fasciitis.

1. Coombs, Schaden, Zhou. *Musculoskeletal Shockwave Therapy*, Greenwich Medical Media, Ltd., London, 2000.
2. Toth-Kischkat, A. Physical principles of shockwave. Presented at the 3rd Congress of the International Society of Musculoskeletal Shockwave Therapy, Naples, Italy. June 2000.

3. Delius, M. Bioeffects of shockwaves in vivo and in vitro effects. Presented at the 3rd Congress of the International Society of Musculoskeletal Shockwave Therapy, Naples, Italy. June 2000.
4. Wang. Shock wave enhanced neovascularization at the tendon-bone junction: an experiment in dogs. Presented at the 3rd Congress of the International Society of Musculoskeletal Shockwave Therapy, Naples, Italy. June 2000.
5. Brendel, W., et al. Effect of shock waves on the microvasculature. *Prog. Appl. Microcirculation* 12:41 – 50, 1987.
6. Haupt, G., et al. Effect of shock waves in the treatment of partial-thickness wounds in piglets. *J. Surg. Res.* 49:45 – 48, 1990.
7. Steinbach, P., et al. In vitro investigations on cellular damage induced by high energy shock waves. *Ultrasound. Med. Biol.* 18:691-699, 1992.
8. McCarthy, D., Gorecki, G. The anatomical basis of inferior calcaneal lesions: a cryomicrotomy study. *J. Am. Podiatr. Assoc.* 69:527 – 536, 1979.
9. Tomczak, R. L., Haverstock, B. D. A retrospective comparison of endoscopic plantar fasciotomy to open plantar fasciotomy with heel spur resection for chronic plantar fasciitis/heel spur syndrome. *J. Foot Ankle Surg.* 34(3):305 – 311, 1995.
10. Weil, L. S., Gowldwing, P. B., Nutbrown, N. J. Heel spur syndrome. A retrospective study of 250 patients undergoing a standardized method of treatment. *Foot* 4:69 – 78, 1994.
11. Benton-Weil, W., Borrelli, A. H., Weil, Jr., L. S., Weil, Sr., L. S. Percutaneous plantar fasciotomy: a minimally invasive procedure for recalcitrant plantar fasciitis. *J. Foot Ankle Surg.* 37(4):269 – 272, 1998.
12. Barrett, S. L., Day, S. V., Pignetti, T. T., Robinson, L. B. Endoscopic plantar fasciotomy: a multi-surgeon prospective analysis of 652 cases. *J. Foot Ankle Surg.* 34:1 – 7, 1995.
13. Lundeen, R. O., Asia, S., Burks, J. B., Rose, J. M. Endoscopic plantar fasciotomy: a retrospective analysis of results in 53 patients. *J. Foot Ankle Surg.* 39(4):208 – 217, 2000.
14. Lombardi, C. Endoscopic plantar fasciotomy: a review of twenty-five cases. Presented at the American College of Foot and Ankle Surgeons Annual Meeting and Scientific Seminar, San Francisco, CA, 1995.
15. American College of Foot and Ankle Surgeons. The painful heel: current procedural guidelines (CPG). *J. Foot Ankle Surg.* 40:329 – 340, 2001.
16. Martin, R. Outcomes study of subjects with insertional plantar fasciitis. *Foot Ankle Int.* 19(12):803 – 811, 1998.
17. Ogden, J. A., Alvarez, R., Levitt, R., Cross, G. I., Marlow, M. Shock wave therapy for chronic proximal plantar fasciitis. *Clin. Orthop.* 387:47 – 59, 2001.
18. Chen, H.-S., Chen, L.-M., Huang, T.-W. Treatment of painful heel syndrome with shock waves. *Clin. Orthop.* 387:41 – 46, 2001.
19. Chapman, C. R., Case, K. L., Dubner, R. Pain measurement: an overview. *Pain* 22:1 – 31, 1985.
20. National Heart, Lung, and Blood Institute. Clinical Guidelines on the Identification, Evaluation, and Treatment of Overweight and Obesity in Adults: Body Mass Index Chart, June 1998.
21. Ogden, J. A., Alvarez, R. G., Levitt, R., Marlow, M. Shock wave therapy (orthotripsy) in musculoskeletal disorders. *Clin. Orthop.* 387:22-40, 2001.