

## Eye movements in response to electrical stimulation of the lateral and superior ampullary nerves

GUYOT, Jean-Philippe, *et al.*

### Abstract

Recently, we demonstrated that it was possible to elicit vertical eye movements in response to electrical stimulation of the posterior ampullary nerve. In order to develop a vestibular implant, a second site of stimulation is required to encode the horizontal movements.

GUYOT, Jean-Philippe, *et al.* Eye movements in response to electrical stimulation of the lateral and superior ampullary nerves. *The Annals of otology, rhinology & laryngology*, 2011, vol. 120, no. 2, p. 81-7

PMID : 21391418

DOI : 10.1177/000348941112000202

Available at:

<http://archive-ouverte.unige.ch/unige:25397>

Disclaimer: layout of this document may differ from the published version.



Eye Movements in Response to Electric Stimulation of the Lateral and Superior  
Ampullary Nerves

*Running title: Electric stimulations of the vestibular nerve branches*

Jean-Philippe Guyot MD<sup>1</sup>, Alain Sigrist, Ingeneer<sup>1</sup>, Marco Pelizzone PhD<sup>1</sup>,  
Georg C Feigl MD<sup>2</sup>, Maria Izabel Kos MD<sup>1</sup>

*<sup>1</sup>Service of Oto-rhino-laryngology, Head and Neck Surgery,  
Department of Clinical Neurosciences  
University Hospital, Faculty of Medicine, University of Geneva, Switzerland*

*<sup>2</sup>Institute of Anatomy,  
Medical University Graz, Graz, Austria*

*Academic degrees:* Professor: Jean-Philippe Guyot MD, Marco Pelizzone PhD  
Doctor: Georg C Feigl MD, Maria Izabel Kos MD

Reprint requests and corresponding author:

Jean-Philippe Guyot  
Service of Oto-rhino-laryngology  
Head and Neck Surgery  
University Hospital  
Rue Gabrielle Perret-Gentil 4  
1211 Geneva 14  
CH - Switzerland  
Phone +41 22 372 82 42  
Fax +41 22 372 82 40  
e-mail [jean-philippe.guyot@hcuge.ch](mailto:jean-philippe.guyot@hcuge.ch)

**ABSTRACT**

**Objectives.** Recently, we demonstrated that it was possible to elicit vertical eye movements in response to electric stimulation of the posterior ampullary nerve. In order to develop a vestibular implant, a second site of stimulation is required to encode the horizontal movements.

**Methods.** Three patients suffering from a disabling Menière's disease were included in the study. Before a labyrinthectomy via a standard transcanal approach was performed, their lateral and anterior ampullary nerves were surgically exposed under local anesthesia through a procedure we recently developed. The attic was opened, the incus and malleus head removed, and a small well drilled above the horizontal portion of the facial canal to place an electrode. This electrode was used to deliver balanced biphasic trains of electric pulses.

**Results.** Electric stimuli elicited mainly horizontal nystagmus without simultaneous stimulation of the facial nerve.

**Conclusions.** It is possible to stimulate electrically the lateral and superior ampullary nerves without simultaneous stimulation of the facial nerve. As both nerves run close to each other, electric stimulation provoked eye movements that were not purely horizontal but had also some vertical components. Nevertheless, this site can be used to encode horizontal movements because central adaptation may correct unnatural afferent vestibular cues delivered by a prosthetic sensor. The range of stimulus intensities producing a response was broad enough to envision the possibility to encode eye movements of varying speeds.

**Key Words** – vestibular, implant, prosthesis, imbalance, rehabilitation

## INTRODUCTION

Patients with bilateral loss of the vestibular function suffer from blurred vision when in movement as well as from disabling imbalance. This imbalance worsens in the dark. Such patients are unable to recognize familiar faces or to read signs while they walk. The lost vestibular function cannot be restored but a vestibular prosthesis could improve the state of such patients. Research carried out on animals led to the concept of a vestibular implant which could be compared to a cochlear implant currently used to restore hearing in patients suffering from profound deafness [1 - 9]. Before such prosthesis could be used in humans, some fundamental questions must be addressed. One is where to place the electrodes that should selectively stimulate the isolated structures of the vestibular system. Ideally, a vestibular implant would require the stimulation of 3 semicircular canals and 2 otolithic organs. However, the horizontal semicircular canals on both sides, the anterior semicircular canal on one side and the posterior semicircular canal of the opposite ear operate in synergy. Therefore, it is expected that a vestibular implant acting on two orthogonal directions of the eye movements, encoding horizontal and vertical movements, will be of help. Today, no attempt is made to stimulate the otolithic organs.

We have already demonstrated that it is possible in the human to place one electrode in the vicinity of the posterior ampullary nerve (PAN) to deliver electrical stimuli that elicits vertical eye movements [10]. In that case, the experiment was performed through the external auditory canal, under local anesthesia, using the approach to the PAN first described by Gacek for the treatment of intractable benign paroxysmal positional vertigo (BPPV) [11]. We have recently described a surgical approach to the lateral (LAN) and superior ampullary nerves (SAN) through the external auditory canal developed in an anatomical study of human heads [12].

The aim of the present study is to evaluate 1) the feasibility of this procedure in patients under local anesthesia; 2) the possibility to elicit horizontal eye movements in stimulating selectively the LAN; and 3) the possibility to stimulate the LAN without simultaneous stimulation of the facial nerve.

## **METHODS**

**Subjects.** Three male patients (68, 44, and 57 years old) were enrolled in the experiment. The procedure was approved by the ethical committee for human research of our institution, and patients gave their informed consent.

The three subjects had been suffering from definite unilateral Menière's disease for several years (7, 4, 7 years respectively) according to AAO-HNS guidelines [13]. They had recurrent spells of vertigo during the last 6 months, refractory to medical treatment. They also had useless residual hearing on the affected ear, making them eligible for a surgical labyrinthectomy. The pre-operative video-nystagmography showed a discrete vestibular hypofunction in the affected ear (discrete diminished response to bithermal caloric and pendular tests) and a normal function on the unaffected side. Brain MRIs were normal.

**Surgical procedure.** All procedures were performed by the same surgeon (MIK). Before the labyrinthectomy, under local anesthesia, the patient had his external canal anesthetized using 1% lidocaine. An ear speculum was fitted into the external canal, and a tympanomeatal flap elevated. The attic was opened to provide access to the epitympanum. The incus and malleus head were removed. To approach the LAN the bone was drilled in a spot defined by the prolongation of the vertical line of the anterior limb of the stapes to the area superior to the horizontal portion of the facial canal, ventral to the prominence of the lateral semicircular canal and inferior to the tegmen of the mastoid. The drill was directed ventrally, medially, and inferiorly (figure 1) [12]. At different steps of the drilling, attempts of electric stimulations were performed. The drilling was stopped when eye movements were elicited in response to the electric stimulation delivered via an electrode kept manually in place.

**Stimulus.** An arbitrary waveform generator (HP33120A) was preloaded to store in its memory a biphasic pulse of 400  $\mu$ s phase duration. A function generator (HP3314A) was used to trigger repeatedly the HP33120A to produce a train of 400  $\mu$ s biphasic pulses with a repetition rate of 200 Hz. This train of pulses was then modulated as 7 seconds 'on', followed by 7 seconds 'off' to facilitate the analysis of the response. The stimulus

waveform was finally converted to current using an opto-isolated converter built in the laboratory which is similar to those used for cochlear implants stimulations.

The stimulating electrode was a 125  $\mu\text{m}$  diameter 90% Platinum - 10% Iridium Teflon-coated wire (*MicroProbes for Life Science 18247-D Flower Hill Way Gaithersburg, MD 20879*). The wire was inserted into a 0.58 x 1.00 x 100 mm glass tube and flame melted at the end to form a ball of 300  $\mu\text{m}$  in diameter. The glass tube was also melted down to cover the platinum wire around the ball which was left uncoated. At its opposite end, the wire was left approximately 10 cm longer than the glass tube and the Teflon® was removed along 5 mm to allow the electrical connection with the current source [10].

**Response recording.** The horizontal and vertical eye movements were recorded using 2D binocular video oculography (Difra Instrumentation, Belgium) at 50 samples per second. The video cameras were mounted in a black plastic face mask kept in front of the subject's eyes by an elastic cloth band. Four responses were simultaneously recorded during data acquisition, two for the right and left horizontal eye movements and two for the right and left vertical eye movements. The envelope of the stimulus was also added to enable the correlation with the eye movements during the laboratory analysis. The slow component velocity (SCV) of the nystagmus was estimated using a homemade Matlab® program to measure the slope of each beat manually [10].

The presence of facial movements was inspected by a nurse. Patients were also frequently encouraged to report any sensation of vertigo or facial movements.

At the end of the experiment, general anesthesia was induced and a transcanal labyrinthectomy was performed according to the classical technique described by Schuknecht [14].

## RESULTS

*Patient 1* suffered from Menière's disease on the right ear. The first stimulation attempts were done after drilling a small well at the indicated spot (see surgical procedure). The first stimulation attempt, made at an intensity of 100  $\mu\text{A}$ , stimulated immediately the

facial nerve. Drilling continued, each time followed by new attempts of stimulation. After 3 or 4 attempts, a site was found where eye movements were elicited at intensities ranging from 240 to 400  $\mu\text{A}$ , without simultaneous stimulation of the facial nerve. Within this range, the nystagmus was mainly horizontal (figure 2). The stimulation was then kept constant for a short period and the patient described a rotational sensation. No attempt was made to obtain from the patient a precise description of the direction or the plane of the sensation. When stimulus ceased, a nystagmus in the opposite direction was observed and the patient described spontaneously a rotational sensation of opposite direction. This suggested the existence of an adaptation phenomenon. However, to avoid further discomfort for the patient and because time constraints, no attempt was made to detect additional signs of adaptation. The site of the drilling can be observed on a postoperative Ct-Scan (figure 3).

*Patient 2* suffered from Menière's disease on the left ear. After some drilling attempts, the electrical stimulation elicited eye movements at intensities ranging from 120 to 240  $\mu\text{A}$ . An increase to 250  $\mu\text{A}$  activated the facial nerve. The movements of the face were reported by the patient, observed by the nurse, and visible with the camera of the video oculography. The nystagmus was predominantly horizontal, with some vertical component (figure 4). This patient did not describe rotational sensation and did not complain of intense movements of the face during the procedure. The labyrinthectomy following the experiment was uneventful. Five days after surgery he developed a facial nerve palsy HB grade V [House-Brackmann] [15].

*Patient 3* suffered from Menière's disease on the right ear. Due to failure of one infrared camera, the eye movements were recorded unilaterally. A horizontal nystagmus was elicited with stimuli ranging from 800 to 1'000  $\mu\text{A}$  (figure 5). During stimulation, the patient reported a clear rotational sensation. In spite of higher levels of stimulation as compared to the 2 previous patients, this patient did not complain of intense movements of the face at any moment of the procedure, and indeed no movement of the face was observed.

The three patients were followed for 1 year. Patient 2 had recovered a fairly good facial function (grade II HB) 6 months after the surgery [15]. All three patients compensated

from the unilateral vestibular deafferentation, and none presented late complications secondary to the electrical stimulation.

## **DISCUSSION**

These results show that the LAN and the SAN can be successfully reached through the external auditory canal in patients under local anesthesia. This approach could be useful to denervate the LAN in the rare cases of intractable BPPV involving the lateral or the superior semicircular canals [12]. In order to safely approach the vestibular nerves underneath the prominence of the facial nerve it is necessary to make an atticotomy and to remove the malleus head and the incus. This implies that the ossicular chain must be reconstructed at the end of the procedure. In our view this is not a serious limitation since good functional results can be achieved with a type III tympanoplasty with interposition of a minor columella between the stapes head and the tympanic membrane. With this procedure one can expect to achieve air bone gaps inferior to 20 dB in more than 90% of the cases [16].

In this study this procedure was not performed to interrupt the LAN or the SAN but as an additional step towards the development of a multichannel vestibular prosthesis to restore balance. We have already demonstrated that it was possible to generate and modulate vertical oculomotor responses through an electrode placed in the vicinity of the PAN [10]. The goal of the present study was to find a second site of stimulation to encode movements in the horizontal plane. For this reason we developed a surgical approach to the LAN and SAN, at their emergence from the cupulae to enable us to place an electrode as close as possible without opening the inner ear, in a concept similar to that used for the surgical approach of the PAN. Once the surgical approach was established [12], it was still necessary to show that it was possible to generate oculomotor responses without simultaneous stimulation of the facial nerve. It was also necessary to obtain responses inside a broad range of stimulus intensities to encode movements of varying speeds, in a way similar to those of the natural system in which type I neurons have a resting discharge rate of 90 action potentials/s (AP) modulated by 0.5 PA/degree/s of rotation



[17]. The ideal location of the electrode was determined by the monitoring of the oculomotor responses to electric stimulation performed at slightly different places during the drilling process. We observed that minimal displacements of the electrode resulted in drastic changes in the amplitude of the response or in the occurrence of facial movements. Therefore it is of utmost importance that the surgery be done under local anesthesia to be able to observe precisely the oculomotor responses or the movements of the face. This is feasible using a transcanal approach which is easily tolerated by the patient under local anesthesia. With this approach the vicinity of the nerve branches emerging from the ampulla can be reached to place the electrode. If necessary, the ampulla can itself be also exposed to place the electrode. We prefer the first option as it may limit the risk of hearing loss due to the introduction of a foreign body in the perilymphatic space. This is illustrated by an increasing number of publications reporting deleterious effects of cochlear implantation on the vestibular function [18, 19] (see Krause reporting a decrease in caloric response in 8 of 16 implanted patients [19]).

During surgery, it was necessary to flush periodically the cavity with cold water to avoid overheating. This caused a few episodes of caloric stimulation. Care was taken each time to await the end of the caloric response before recording proper oculomotor electric responses. This unavoidable caloric stimulation as well as the time spent searching for the ideal site of stimulation certainly added some minutes to the procedure. The small surface of the stimulation site (approximately  $1 \text{ mm}^2$ ) may be a problem in the future. During an acute experiment, the electrode can be precisely maintained in place for a few minutes, manually. In a vestibular implant, the electrode will have to remain permanently fixed in a very discrete site.

In all 3 patients, we were able to find a suitable stimulation site provoking oculomotor responses. This was possible without simultaneous stimulation of the facial nerve in a significant range of stimulation intensities, from 240 to 400  $\mu\text{A}$  in the first patient, from 120 to 240  $\mu\text{A}$  in the second and from 800 to 1000  $\mu\text{A}$  in the third. Such ranges might be enough to encode eye movements of different velocities. Given the drastic changes observed in the amplitude of responses at minimal displacements of the electrode, we cannot certify that it was placed at the same distance from the LAP in the 3 patients. This probably explains why the stimulus thresholds were not similar.

In patient 3, the responses to the electrical stimulation were almost purely horizontal, suggesting that the LAN was selectively stimulated. In patients 1 and 2, a stronger vertical component was observed. This observation was expected because the branches of the vestibular nerve arising from the lateral and superior canals run close to each other. However, the simultaneous stimulation of these 2 nerve branches might not represent a strong limitation when encoding horizontal movements. Indeed, it has already been demonstrated in animals that central adaptation may possibly compensate for unnatural afferent vestibular cues delivered by a prosthetic sensor. Lewis and co-workers placed a stimulating electrode near the PAN and linked it to a velocity sensor parallel to the axis of the lateral canals. In one week, the axis of the VOR response in this animal had shifted towards alignment with the axis of head rotation [3].

One patient (patient 2) developed HB grade V facial nerve palsy 5 days after surgery [15]. His facial nerve was electrically stimulated briefly during the experiment. However, it is difficult to consider this as the cause of the deficit. Electrical monitoring of the facial nerve is performed routinely during removal of tumours from the parotid gland and has not been proven dangerous for the nerve [20]. There are also reports of chronic facial nerve stimulation by cochlear implants without deleterious effects on its function [21 - 23]. Facial palsy due to an inflammation of the nerve as result of surgical trauma would have occurred only a few hours after surgery and not many days later. Sporadic cases of facial nerve paresis occurring many days after uneventful middle ear surgery have been reported by several authors. Most of them consider that this results from the reactivation of neurotropic viruses [24 - 32]. This hypothesis is supported by some clinical observations of patients who presented successive otoneurological disorders affecting the same ear, such as sudden deafness, vestibular neuronitis, and facial palsy occurring in successive years [33]. It is also supported by histopathological examinations of temporal bones disclosing lesions of the neuronal bodies of the meatal ganglion of the facial nerve which are consistent with viral inclusions [34, 35]. According to Gacek, neurotropic viruses might migrate from the meatal ganglion towards neighbouring structures and lead to different clinical manifestations such as a facial nerve paralysis, a sudden hearing loss, a vestibular neuronitis or the symptoms of Menière's disease [34, 35]. We consider that

this hypothesis could explain the delayed facial nerve paralysis observed in our patient. Six months after surgery, he had recovered an almost normal function.

#### **ACKNOWLEDGEMENTS**

*We gratefully acknowledge Olga Delaspre for her help in collecting data.*

*This work was partly funded by the Seventh framework Programme, Theme 3, Information and Communication Technologies; European Community CLONS (225929) (CLOsed-loop Neural prostheses for vestibular disorderS), approved by EC on (17/10/2008).*

#### **REFERENCES**

1. Gong W, Merfeld DM. Prototype neural semicircular canal prosthesis using patterned electrical stimulation. *Ann Biomed Eng* 2000; 28:572-81.
2. Gong W, Merfeld DM. System design and performance of a unilateral horizontal semicircular canal prosthesis. *IEEE Trans Biomed Eng* 2002; 49:175-81.
3. Lewis RF, Gong W, Ramsey M, Minor L, Boyle R, Merfeld DM. Vestibular adaptation studied with a prosthetic semicircular canal. *J Vestib Res* 2002; 12: 87-94.
4. Wall C, Merfeld DM, Rauch SD, Black FO. Vestibular prostheses: the engineering and biomedical issues. *J Vestib Res* 2002; 12:95-113.
5. Merfeld DM, Gong W, Morrissey J, Saginaw M, Haburcakova C, Lewis RF. Acclimation to chronic constant-rate peripheral stimulation provided by a vestibular prosthesis. *IEEE Trans Biomed Eng* 2006; 53:2362-72.
6. Merfeld DM, Haburcakova C, Gong W, Lewis RF. Chronic vestibulo-ocular reflexes evoked by a vestibular prosthesis. *IEEE Trans Biomed Eng* 2007; 54:1005-15.

7. Gong W, Haburcakova C, Merfeld DM. Vestibulo-ocular responses evoked via bilateral electrical stimulation of the lateral semicircular canals. *IEEE Trans Biomed Eng* 2008; 55:2608-19.
8. Della Santina CC, Migliaccio AA, Patel AH. A multichannel semicircular canal neural prosthesis using electrical stimulation to restore 3-d vestibular sensation. *IEEE Trans Biomed Eng* 2007; 54:1016-30.
9. Fridman GY, Davidovics NS, Dai C, Migliaccio AA, Della Santina CC. Vestibulo-ocular reflex responses to a multichannel vestibular prosthesis incorporating a 3D coordinate transformation for correction of misalignment. *J Assoc Res Otolaryngol* 2010 Feb 23.
10. Wall C, Kos MI, Guyot JP. Eye movements in response to electric stimulation of the human posterior ampullary nerve. *Ann Otol Rhinol Laryngol* 2007;116:369-374.
11. Gacek RR. Transection of the posterior ampullary nerve for the relief of benign paroxysmal positional vertigo. *Ann Otol Rhinol Laryngol* 1974; 83:596-605.
12. Feigl GC, Fasel JH, Anderhuber F, Ulz H, Rienmüller R, Guyot JPh, Kos IM. Superior vestibular neurectomy: a novel transmeatal approach for a denervation of the superior and lateral semicircular canal. *Otol Neurotol* 2009 ; 30:586-591.
13. Committee on hearing and equilibrium guidelines for the diagnosis and evaluation of therapy in Menière's disease. *Otolaryngol Head Neck Surg* 1995; 113:181-185.
14. Schuknecht HF. Ablation therapy for the relief of Menière's disease. *Laryngoscope* 1956; 66:859-870.
15. House JW, Brackmann DE. Facial nerve grading system. *Otolaryngol Head Neck Surg* 1985; 93:146-147.
16. Zheng C, Guyot JPh, Montandon P. Ossiculoplasty by interposition of a minor columella between the tympanic membrane and stapes head. *American Journal of Otology* 1996; 17:200-202.

17. Goldberg JM, Fernandez C. Physiology of peripheral neurons innervating semicircular canals of the squirrel monkey. I. Resting discharge and response to constant angular accelerations. *J Neurophysiol* 1971; 34:635-660.
18. Wagner JH, Basta D, Wagner F, Seidl RO, Ernst A, Todt I Vestibular and taste disorders after bilateral cochlear implantation. *Eur Arch Otorhinolaryngol* 2010, Jul 6; Epub ahead of print.
19. Krause E, Louza JP, Wechtenbruch J, Gürkov R. Influence of cochlear implantation on peripheral vestibular receptor function. *Otolaryngol Head Neck Surg* 2010; 142:809-813.
20. Dulguerov P, Marchal F, Lehmann W. Postparotidectomy facial nerve paralysis: possible etiologic factors and results with routine facial nerve monitoring. *Laryngoscope* 1999; 109:754-62.
21. Muckle RP, Levine SC. Facial nerve stimulation produced by cochlear implants in patients with cochlear otosclerosis. *Am J Otol* 1994;15:394-8.
22. Kelsall DC, Shallop JK, Brammeier TG, Prenger EC. Facial nerve stimulation after Nucleus 22-channel cochlear implantation. *Am J Otol* 1997;18:336-41.
23. Bigelow DC, Kay DJ, Rafter KO, Montes M, Knox GW, Yousem DM. Facial nerve stimulation from cochlear implants. *Am J Otol* 1998; 19:163-9.
24. Bonkowsky V, Kochanowski B, Strutz J, Pere P, Hosemann W, Arnold W. Delayed facial palsy following uneventful middle ear surgery: a herpes simplex virus type 1 reactivation? *Ann Otol Rhinol Laryngol* 1998; 107:901-905.
25. Ng M, Maceri DR. Delayed facial paralysis after stapedotomy using KTP laser. *Am J Otol* 1999; 20:421-424.
26. Vrabec T. Delayed facial palsy after tympanomastoid surgery. *Am J Otol* 1999; 20:26-30.
27. Gyo K, Honda N. Delayed facial palsy after middle-ear surgery due to reactivation of varicella-zoster virus. *J Laryngol Otol* 1999; 113: 14-15.

28. Shea JJ, Ge X. Delayed facial palsy after stapedectomy. *Otol Neurotol* 2001; 22:465-470.
29. Wu W, Han D, Wang J, Yang W. The observation of delayed facial paralysis after middle ear and mastoid surgery: 10 cases analysis. *Lin Chuang Er Bi Yan Hou Ke Za Zhi* 2004; 18:200-1.
30. Kitahara T, Kubo T, Doi K, Mishiro Y, Kondoh K, Horii A, Okumura S, Miyahara H. delayed facial nerve palsy after otologic surgery. *Nippon Jibiinkoka Gakkai Kaiho* 2006; 109:600-5.
31. Safdar A, Gendy S, Hilal A, Walshe P, Burns H. Delayed facial nerve palsy following tympano-mastoid surgery: incidence, aetiology and prognosis. *J Laryngol Otol* 2006; 120:745-8.
32. De Stefano A, Neri G, Kulamarva G. Delayed facial nerve paralysis post middle ear surgery: herpes simplex virus activation. *B-ENT* 2009;5(1):47-50.
33. Guyot JPh, Crescentino V, Kos MI. A propos d'un patient ayant souffert de plusieurs affections otoneurologiques. *Médecine et Hygiène* 2002; 60:1954-1959.
34. Gacek RR. The pathology of facial and vestibular neuronitis. *Am J Otolaryngol* 1999; 20:202-10.
35. Gacek RR, Gacek MR. Meatal ganglionitis: a pathologic correlate in idiopathic facial paralysis. *Adv Otorhinolaryngol* 2002;60:32-53.

## FIGURES LEGENDS

**Figure 1:** *Drawing of the surgical access to the lateral and superior ampullary nerves, right ear.* The triangle determines the anatomic landmarks of the drilling point: the roof of the tympanic cavity superiorly, the prominence of the lateral semicircular canal posteriorly (1), and the facial nerve canal inferiorly (2) (stapes head (3); footplate (4); tendon of the stapedius muscle (5); promontory (6); tendon of the tensor tympani muscle (7). [Reproduced with permission Feigl GC, Fasel JH, Anderhuber F, Ulz H, Rienmüller R, Guyot JPh, Kos MI. *Superior vestibular neurectomy: a novel transmeatal approach for a denervation of the superior and lateral semicircular canal. Otol Neurotol* 2009 ; 30:586-591].

**Figure 2:** *Eye movements, patient 1.* Eye movements in response to electric stimulation are predominantly in the horizontal plane (2 upper tracings). There is a weak down beating nystagmus (2 lower tracings). The slow phase velocity of the horizontal nystagmus averaged  $11^{\circ}/s$  and that of the vertical component of  $4.5^{\circ}/s$ . The bottom trace shows stimulus envelope.

**Figure 3:** *Postoperative CT-Scan, patient 1.* The site of drilling (arrow) is visible immediately in front of the ampulla of the lateral semicircular canal, above the facial nerve (dotted arrow) (IAC: internal auditory canal; c: cochlea; A: horizontal view; B: vertical section).

**Figure 4:** *Eye movements, patient 2.* Electric stimulations elicited horizontal eye movements with a vertical component. In this sample, the slow phase velocity of the horizontal nystagmus averaged  $20^{\circ}/s$  and that of the vertical component of  $8^{\circ}/s$ . The bottom curve shows the envelope of the stimulus.

**Figure 5** *Eye movements, patient 3.* Eye movements were predominantly horizontal. The slow phase velocity of the horizontal nystagmus averaged  $7^{\circ}/s$  and that of the vertical component of  $1.5^{\circ}/s$ . Due to a technical problem of one infrared camera, only the tracings on the right eye were recorded. The bottom trace shows stimulus envelope.

Figure 1

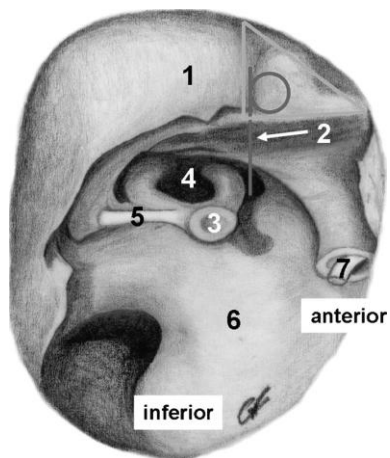




Figure 2

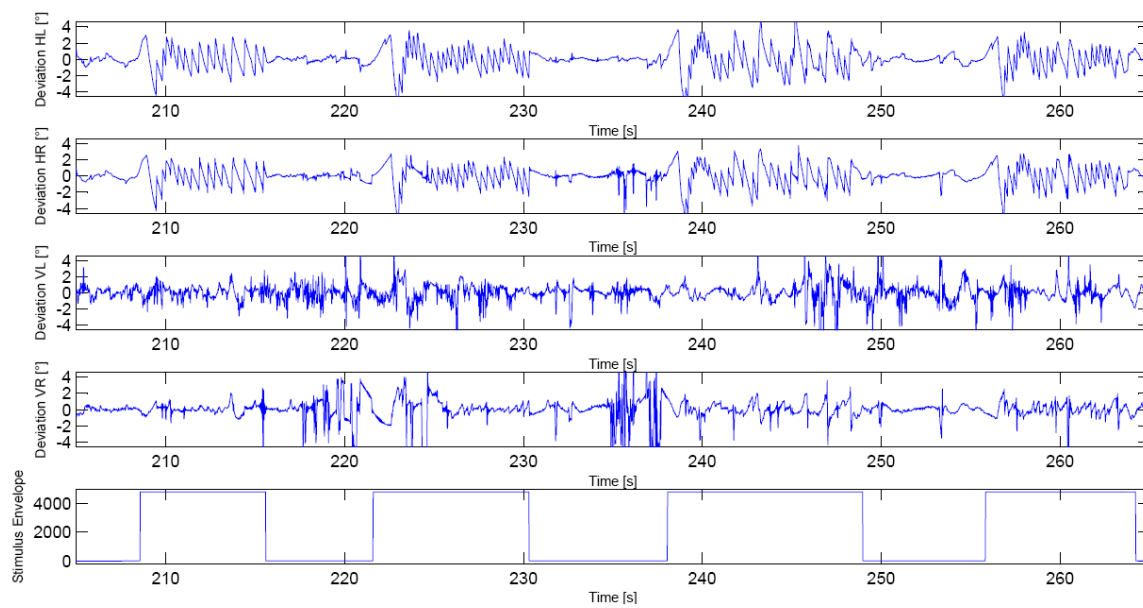
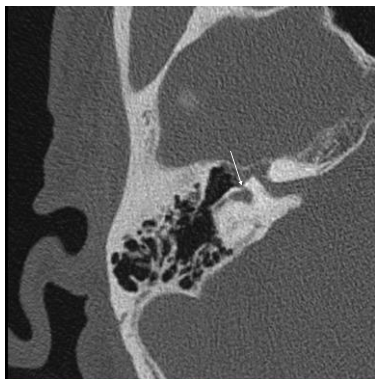
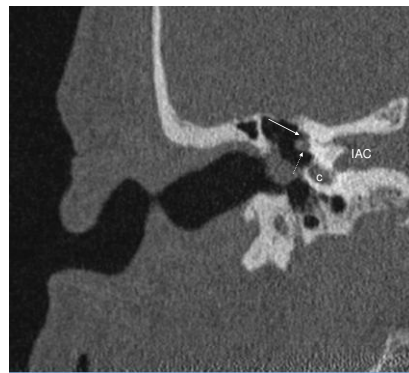

Figure 3



A



B

Figure 4

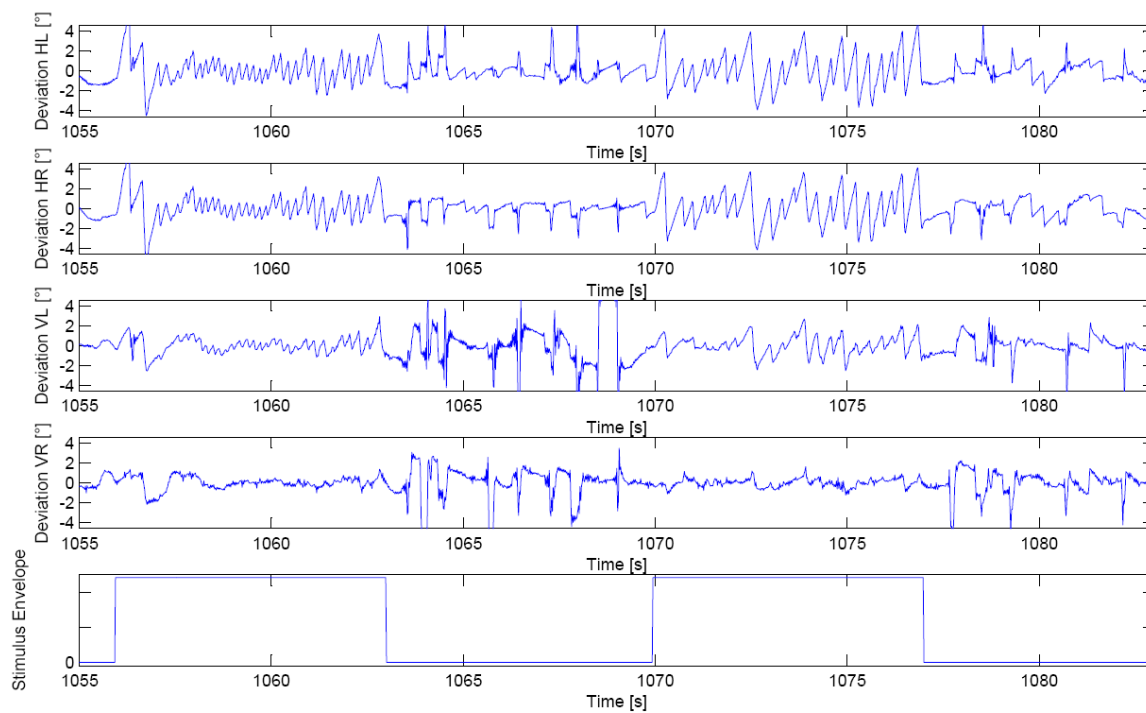


Figure 5

