

Eye-rima oris distance and its relation to the vertical dimension of occlusion measured by two methods: Anthropometric study in a sample of Yemeni dental students

Mohammed Nasser Alhaji^{1,2}, Nadia Khalifa³, Abdullah Amran⁴

¹Department of Oral Rehabilitation, Faculty of Dentistry, Khartoum University, Khartoum, Sudan,

²Department of Prosthodontics, Faculty of Dentistry, Tamar University, Dhamar, Yemen,

³Department of General and Specialist Dental Practice, College of Dental Medicine, University of Sharjah, Sharjah, UAE,

⁴Department of Periodontics, Faculty of Dentistry, Tamar University, Dhamar, Yemen

Correspondence: Dr. Mohammed Nasser Alhaji

Email: dr_alhaj@hotmail.com

ABSTRACT

Objective: This study was conducted to evaluate the relationship between the distance measured from the distal outer of the eye to the parting line of the lips and the occlusal vertical dimension (OVD) measured by two methods. **Methods:** One hundred and fourteen dental students (76 males and 38 females) were recruited for this study with mean age (22.34 ± 1.83) years. The distance from distal canthus of the eye to rima oris (eye-RO) was compared with two different measurements of the OVD (nasal [N] to gnathion [Gn], and subnasal [Sn] to menton [Me]). All distances were measured using modified digital caliper. **Results:** Pearson correlation coefficient test for correlations and paired samples *t*-test for differences were used with a significant level of ($P < 0.05$). There was a positive significant correlation between the eye-RO distance and the two measurements of the OVD. However, this correlation was stronger between eye-RO and the distance from the tip of the nose to the tip of the chin than that between eye-RO and the distance from the septum of the nose to the under of the chin ($r = 0.313$ with $P = 0.0007$, $r = 0.296$ with $P = 0.0014$), respectively. **Conclusion:** The distance from the outer canthus of the eye to the parting of the lips seems to be a reliable method in predicting the OVD and should relate to the distance from the tip of the nose to the tip of the chin.

Key words: Corner of the mouth, occlusal vertical dimension, outer canthus of the eye, rima oris

INTRODUCTION

Loss of natural dentition has many subsequent complications that can be perceived in function (mastication and swallowing), speech (phonation), esthetics, and a negative psychological as well as social effect.^[1-3] It can ultimately lead to loss of vertical dimension, shortening of the lower face height that can change one's appearance, cause an inverted smile (corners of the mouth sag), a "toothless" smile, frequent cracking or chapping at the corners of the mouth (angular cheilitis) and problems in chewing due to a decrease in bite force.^[4,5] Reestablishing a correct vertical dimension of occlusion for those who have a collapsed vertical dimension is of optimum importance

that can help in managing these deficits and, therefore, improving the quality of life.^[6,7] Although there are many advances in materials and techniques applied in prosthodontics, in particularly, for the determination

This is an open access article distributed under the terms of the Creative Commons Attribution-NonCommercial-ShareAlike 3.0 License, which allows others to remix, tweak, and build upon the work non-commercially, as long as the author is credited and the new creations are licensed under the identical terms.

For reprints contact: reprints@medknow.com

How to cite this article: Alhaji MN, Khalifa N, Amran A. Eye-rima oris distance and its relation to the vertical dimension of occlusion measured by two methods: Anthropometric study in a sample of Yemeni dental students. *Eur J Dent* 2016;10:29-33.

DOI: 10.4103/1305-7456.175689

of the occlusal vertical dimension (OVD), still there is no scientific, accurate, and accepted method of assessing this component in edentulous patients and the clinical judgment still plays an important role. In the literature, several methods and devices were used to measure the OVD.^[8-11] Measuring the distance between soft tissue landmarks on the face is one of many techniques used for predicting the vertical dimension of occlusion in complete denture construction. This method is based on the harmony of the face and facial proportions that have been advocated to be relatively constant and unchanged with age progress.^[12,13] Two different ways of facial measurements can be applied to determine the OVD in edentulous patients: (1) Measuring the resting vertical dimension between two points one on the upper jaw and the other on the lower jaw then subtract 2–4 mm which conform the freeway space. (2) To correlate a proportionate distance between two anatomical landmarks on the face.^[11,13,14] The Willis gauge is commonly used to measure the OVD measuring the distance between the septum of the nose (subnasal [Sn]) and the inferior border of the mandible (menton [Me]). Another is pleasure's method that measures the distance between the tip of the nose (nasal [N]) and the tip of the chin (gnathion [Gn]).^[9,15,16] The purpose of this study was to evaluate the relation between the distance from outer canthus of the eye to the corner of the mouth (rima oris [RO]) and OVD measured by two methods in a sample of Yemeni dental students.

METHODS

The sample frame included dental students who attended the faculty of dentistry, Thamar University, Dhamar, Yemen. One hundred and fourteen subjects (76 male and 38 female) were randomly recruited for this study, the mean age was (22.34 ± 1.83) and ranged from 19 to 28 years. Ethical approval was obtained from the ethical committee of the college of dentistry and a signed informed consent form was also obtained from each subject prior to conducting this study. Each participant, to be included, had to fulfill the inclusion criteria that are: a full dentition set (except third molars), Class I jaw relation, and a harmonious as well as symmetrical face. The exclusion criteria were missing teeth, malocclusion, Class II or III jaw relation, previous or current orthodontic treatment, previous major stomatognathic or plastic surgery, and disfigurement of the face. Each subject was asked to sit in an erect forward position with an unsupported head. For centric occlusion, the subjects were asked to bring their teeth into contact with their lips relaxed.

Two different measurements of the OVD were performed using different landmarks on the face (N, Gn, Sn, and Me). Two dots using indelible pen were placed; one on the tip of the nose (N) and the other on the tip of the chin (Gn), the distance between the dots was recorded [Figure 1]. For the second measurement, the distance between (Sn) and (Me) was also measured and recorded [Figure 2]. The parallelism between the septum of the nose and the under of the chin was achieved using a tongue blade and the subjects were asked to hold it lightly on the inferior border of the chin [Figure 3]. The study variable (eye-RO) was obtained by recording the distance from the outer canthus of the eye to the corner of the mouth [Figure 4]. A digital caliper was used to measure all variables (accurately measure within ± 0.02 mm/0.001 inch). MS. Excel 2013 was used for data entering. Statistical Package for the Social Sciences SPSS version 22.0 (IBM Corp., Released 2013. IBM SPSS Statistics for Windows, Version 22.0. Armonk, NY, USA: IBM Corp.) was used for statistical analysis. Pearson's correlation coefficient test was utilized to study the correlation between the measured parameters at significant level $P < 0.05$ and 95% confidence level. Independent *t*-test was used to find out the differences of means between males and females for the parameters of the study, as well as paired *t*-test, was performed to calculate the differences between the means for the study parameters. All measurements were made by one author.

Reliability test

Sixteen subjects were randomly selected for test-retest method of reliability. The measurements were made twice on the same participants by one author with an interval of 2 weeks in between. Data were entered and

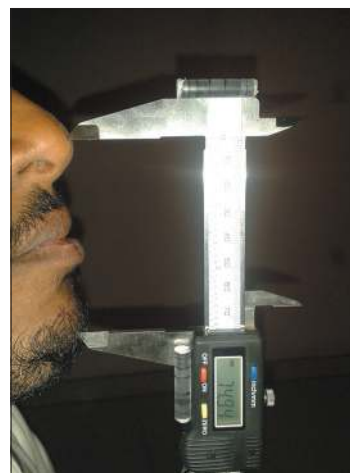

Figure 1: Measurement of the distance from tip of the nose to tip of the chin

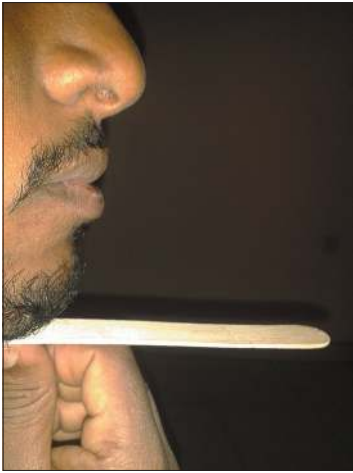

Figure 2: Parallelism for measurement

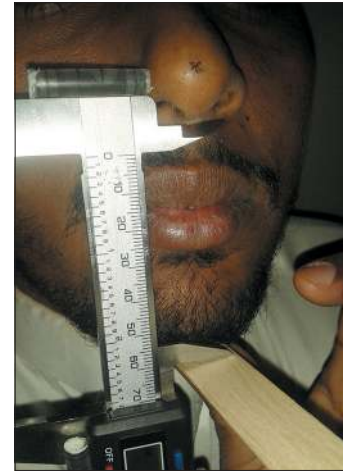


Figure 3: Measurement of the distance from septum of the nose to under of the chin

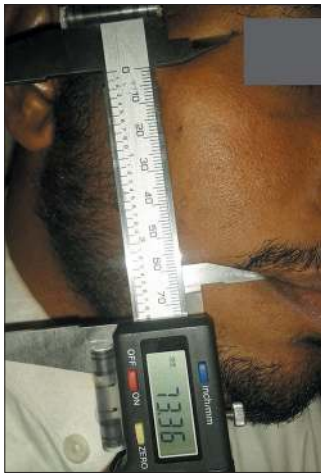

Figure 4: Measurement of the distance from outer canthus of the eye to rima oris

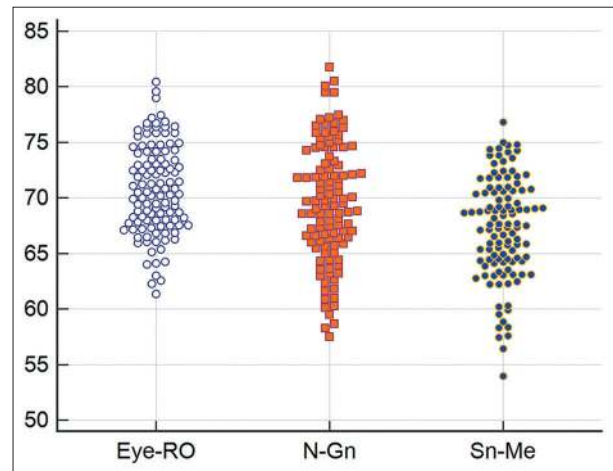


Figure 5: Dotplots graph showing all readings

analyzed using SPSS program. Intraclass correlation coefficient was performed for intra-examiner reliability. Tables 1 and 2 show the results of the agreement for all variables and between the two readings. Findings suggest that all measurements can be repeated with high significance of reliability and reproducibility ICC = 0.81 with $P = 0.0001$.

RESULTS

This study consisted of 114 dental students. According to gender, the sample size comprised of 76 males (67%) and 38 females (33%) with an age range of 19–28 years (22.34 ± 1.82). The mean of the distance (eye-RO) was (70.79 ± 4.01) mm with minimum 61.34 mm and maximum 80.47 mm, while (Sn-Me) was (67.24 ± 4.59) mm ranging from 53.97–76.81 mm and (N-Gn) was (69.60 ± 5.32) mm ranging from 57.49–81.77 mm [Table 3]. As shown in [Figure 5], the measurements recorded from

Table 1: Intraclass correlation coefficient-reliability for all subjects

Intraclass correlation	95% CI		df	Significant
	Lower bound	Upper bound		
0.810	0.618	0.924	15	0.0001

CI: Confidence interval

Table 2: Intraclass correlation coefficient-reliability for the different measurements

Readings	ICC	Significant
Eye-RO 1 and 2	0.801	0.002
Subnasal-menton 1 and 2	0.836	0.001
Nasal-gnathion 1 and 2	0.946	0.001

ICC: Intraclass correlation coefficient, RO: Rima oris

the distance (eye-RO) are closer to those recorded from (N-Gn) than those taken from (Sn-Me). To find the correlation between the distances (eye-RO and N-Gn) and (eye-RO and Sn-Me) correlation coefficient

of Pearson was initialized [Table 4]. There was a significant correlation ($r = 0.313$) with $P = 0.0007$ for the pair (eye-RO and N-Gn), while it was ($r = 0.296$) for the pair (eye-RO and Sn-Me) with $P = 0.0014$. The differences between the means were calculated for the two pairs as shown in [Table 5]. The difference between the means for the pair (eye-RO and N-Gn) was lesser than the difference between the means for the pair (eye-RO and Sn-Me). It was (1.19 ± 5.57) with $P = 0.025$ and (3.55 ± 5.12) with $P = 0.0001$ respectively. Table 6 shows the differences between males and females for the study parameters, significant differences

were found between males and females regarding the recordings measured from the outer canthus of the eye to parting of the lips (2.45 mm, $P = 0.002$). It was also significant for the readings from the tip of the nose to the tip of the chin (6.23 mm, $P = 0.001$). While there were no significant differences between the two genders regarding the distance from the septum of the nose to the under of the chin (0.30 mm, $P = 0.750$).

DISCUSSION

Reestablishing the vertical dimension of occlusion not only creates a space between the upper and lower ridges to be occupied by the artificial teeth but also improves the function of the denture prosthesis as well as the esthetic appearance of the patient. Restoring this important component should be in harmony with the facial dimensions with no facial strain or patient discomfort. The absence of any preextraction records for the OVD makes the measurement of the vertical height of the lower third of the face arbitrary. Since there is no superior method to establish the original OVD for all individuals, suggestions have been made to use the facial proportions as alternative methods to predict the missing OVD. This study was set out with the aim of assessing the relation between some distances measured from certain soft tissue landmarks on the face. In this study, the OVD measured from the tip of the nose to the tip of the chin was longer than OVD measured from the septum of the nose to the under of the chin while the distance from the outer canthus of the eye to the corner of the mouth was longer than both of them. However, the difference between the means for (eye-RO) and (Sn-Me) was higher than the one between (eye-RO) and (N-Gn). These results agree with the findings of other studies, in which they found that the distance from the septum of the nose to the under of the chin was smaller than the other distances.^[17-20] Statistically significant correlations were observed between the study variable (eye-RO) and the two readings of the OVD (N-Gn) and (Sn-Me). This correlation was higher, with higher significant level, between the pair (eye-RO) and (N-Gn) than that between (eye-RO) and (Sn-Me). Although these findings seem to be consistent with those found by Nagpal *et al.*,^[21] Delic *et al.*,^[22,23] and Basnet *et al.*,^[24] they differ from a study conducted by Tina-Olaivar *et al.*^[25] in which he found that the difference between (eye-RO) and (N-Gn) was 3 cm, this variation might be because their study was carried out on Mongoloid individuals while this study was conducted on Caucasian subjects. Differences in the distance (between the outer canthus of the eye

Table 3: Descriptive statistics of the facial measurements for total subjects

	n	Minimum	Maximum	Mean	SD
Eye-RO	114	61.34	80.47	70.79	4.01
Subnasal-menton	114	53.97	76.81	67.24	4.59
Nasal-gnathion	114	57.49	81.77	69.60	5.32

SD: Standard deviation, RO: Rima oris

Table 4: Correlation between (eye-rima oris) and other methods in all subjects

	Subnasal-menton	Nasal-gnathion
Eye-RO		
Pearson correlation	0.296**	0.313**
Significant (two-tailed)	0.0014	0.0007
n	114	114

**Correlation is significant at the 0.01 level (two-tailed). RO: Rima oris

Table 5: Differences between the means

	Paired differences				Significant (two-tailed)
	Mean	SD	95% CI of the difference		
			Lower	Upper	
Pair 1					
Eye-RO - Subnasal-menton	3.55	5.12	2.60	4.50	0.001
Pair 2					
Eye-RO - nasal-gnathion	1.19	5.57	0.15	2.22	0.025

SD: Standard deviation, CI: Confidence interval, RO: Rima oris

Table 6: Group statistics of all measurements comparing the gender

	Gender	n	Mean	SD	Differences	Significant (two-tailed)
Eye-RO	Male	76	71.61	4.01	2.45	0.002
	Female	38	69.16	3.54		
Subnasal-menton	Male	76	67.34	4.59	0.30	0.750
	Female	38	67.05	4.64		
Nasal-gnathion	Male	76	71.68	4.53	6.23	0.001
	Female	38	65.45	4.27		

SD: Standard deviation, CI: Confidence interval, RO: Rima oris

and parting of the lips) as well as (from tip of the nose to tip of the chin) between males and females were significant. Similar differences between the genders were described by Nagpal *et al.*,^[21] Delic *et al.*,^[22,23] Basent *et al.*,^[24] and Al-Hamdany.^[26] It is somewhat surprising that no significant differences were found in the current study between males and females regarding the distance from the septum of the nose to the under of the chin. A possible explanation for this result might be the lack of adequate sample of female subjects ($n = 38$) compared with the larger sample of males ($n = 76$). Another possible explanation for this is the variances in soft tissues topography that may reflect such a result. However, several limitations of this study should be noted; the subjects were limited to a single race (Yemenis), collected from convenient sample frame (dental students), and they may have been too young (22.34 years) to be used as considerable data for patients with lost OVD. Thus, further studies using larger sample size from broader age and racial groups are recommended.

CONCLUSION

Within the limitations of the present study, the following conclusion can be drawn:

- Eye-RO distance is a reliable method for predicting the OVD for the study group
- If this distance is to be used as a method to predict OVD, it should be compared with the distance from the tip of the nose to the tip of the chin rather than the distance for septum of the nose to the under of the chin.

Financial support and sponsorship

Nil.

Conflicts of interest

There are no conflicts of interest.

REFERENCES

1. Harper RP. Clinical indications for altering vertical dimension of occlusion. Functional and biologic considerations for reconstruction of the dental occlusion. *Quintessence Int* 2000;31:275-80.
2. Sowmya M, Vinaya B, Krishna P. Psychological impact of edentulousness. *JIADS* 2011;2:34-6.
3. Freeman R. Prosthetics: A study of the emotional reaction to tooth loss. *Br Dent J* 2000;188:497.
4. Khalifa N, Allen PF, Abu-bakr NH, Abdel-Rahman ME. Factors associated with tooth loss and prosthodontic status among Sudanese adults. *J Oral Sci* 2012;54:303-12.
5. Allen PF, McMillan AS. A review of the functional and psychosocial

6. outcomes of edentulousness treated with complete replacement dentures. *J Can Dent Assoc* 2003;69:662.
7. Emami E, de Souza RF, Kabawat M, Feine JS. The impact of edentulism on oral and general health. *Int J Dent* 2013;2013:498305.
8. Alhajj MN. Prosthodontic rehabilitation of severely worn dentition. *Int J Dent Clin* 2012;4:35-6.
9. Fayz F, Eslami A. Determination of occlusal vertical dimension: A literature review. *J Prosthet Dent* 1988;59:321-3.
10. Turrell AJ. Clinical assessment of vertical dimension. *J Prosthet Dent* 1972;28:238-46.
11. Sheppard IM, Sheppard SM. Vertical dimension measurements. *J Prosthet Dent* 1975;34:269-77.
12. Widen HM. Obtaining vertical dimension in edentulous cases. *J Am Dent Assoc* 1941;28:240-6.
13. Misch CE. Clinical indications for altering vertical dimension of occlusion. Objective vs subjective methods for determining vertical dimension of occlusion. *Quintessence Int* 2000;31:280-2.
14. McGee GF. Use of facial measurements in determining vertical dimension. *J Am Dent Assoc* 1947;35:342-50.
15. Niswonger ME. Obtaining the vertical relation in edentulous cases that existed prior to extraction. *J Am Dent Assoc* 1938;25:1842-7.
16. Willie RG. Trends in clinical methods of establishing an ideal interarch relationship. *J Prosthet Dent* 1958;8:243-51.
17. Geerts GA, Stuhlinger ME, Nel DG. A comparison of the accuracy of two methods used by pre-doctoral students to measure vertical dimension. *J Prosthet Dent* 2004;91:59-66.
18. Bhat V, Gopinathan M. Reliability of determining vertical dimension of occlusion in complete dentures: A clinical study. *J Indian Prosthodont Soc* 2006;6:38-42.
19. Miralles R, Dodds C, Palazzi C, Jaramillo C, Quezada V, Ormeño G, *et al.* Vertical dimension. Part 1: Comparison of clinical freeway space. *Cranio* 2001;19:230-6.
20. Sakar O, Sülün T, Kurt H, Gençel B. Reliability and comparison of two facial measurements to detect changes of occlusal vertical dimension in complete denture wearers. *Gerodontology* 2011;28:205-8.
21. Unger JW. Comparison of vertical morphologic measurements on dentulous and edentulous patients. *J Prosthet Dent* 1990;64:232-4.
22. Nagpal A, Parkash H, Bhargava A, Chittaranjan B. Reliability of different facial measurements for determination of vertical dimension of occlusion in edentulous using accepted facial dimensions recorded from dentulous subjects. *J Indian Prosthodont Soc* 2014;14:233-42.
23. Delic Z, Simunovic-Soskic M, Perinic-Grzic R, Vukovojac S, Rajic Z, Kuna T, *et al.* Evaluation of craniometric methods for determination of vertical dimension of occlusion. *Coll Antropol* 2000;24 Suppl 1:31-5.
24. Delic Z, Vukovojac S, Grzic R, Maricic D, Kovac Z, Kovacevic D. Evaluation of craniometric methods for determination of vertical dimension of occlusion - Part 2. *Coll Antropol* 2003;27 Suppl 1:191-4.
25. Basnet BB, Singh RK, Parajuli PK, Shrestha P. Correlation between facial measurements and occlusal vertical dimension: An anthropometric study in two ethnic groups of Nepal. *Int J Dent Sci Res* 2014;2:171-4.
26. Tina-Olaivar EO, Olaivar OK. A comparative study of the upper and lower vertical facial measurements of the Filipinos as it is used in the Willis method for determining the vertical dimension of occlusion. *J Philipp Dent Assoc* 1998;50:44-8.
27. Al-Hamdany AK, Kassab NH. Correlation of vertical dimensions of soft tissue facial profiles. *Al Rafidain Dent J* 2010;10:243-53.

Access this article online

Quick Response Code:



Website:
www.eurjdent.com