

EXPERT
REVIEWS

Faecal matrix metalloprotease-9 is a more sensitive marker for diagnosing pouchitis than faecal calprotectin: results from a pilot study

Expert Rev. Gastroenterol. Hepatol. Early online, 1–6 (2014)

Klaudia Farkas¹,
Anita Bálint¹,
Renáta Bor¹,
Imre Földesi¹,
Mónika Szűcs²,
Ferenc Nagy¹,
Zoltán Szepes¹,
Anita Annaházi¹,
Richárd Róka¹ and
Tamás Molnár*¹

¹First Department of Medicine,
University of Szeged H-6720, Korányi
fasor 8, Szeged, Hungary

²Department of Medical Physics and
Informatics, University of Szeged,
Szeged, Hungary

*Author for correspondence:

Tel.: +36 6254 5186

Fax: +36 6254 5185

molnar.tamas@med.u-szeged.hu

Background: Potential non-invasive markers of pouchitis would have a great deal of significance within clinical practice. **Aim:** This study is aimed at assessing the diagnostic accuracy of fecal calprotectin and matrix metalloprotease-9 as potential markers in patients both with and without pouchitis. **Patients and methods:** Stool and blood samples were collected from 33 ileal pouch-anal anastomosis patients before a follow-up pouchoscopy. Biopsy samples were taken for histological purposes. The presence of cuffitis and stenosis was evaluated with an endoscopy. **Calprotectin and matrix metalloprotease-9** were quantified with an enzyme-linked immunosorbent assay. **Results:** Pouchitis was detected in 30.3% of the patients. The levels of fecal calprotectin and matrix metalloprotease-9 increased significantly in patients with pouchitis. The sensitivity and specificity of matrix metalloprotease-9 was higher than that of fecal calprotectin. Only matrix metalloprotease-9 correlated significantly with the severity of pouchitis. **Discussion:** Faecal matrix metalloprotease-9 has a high specificity in the diagnosis of pouchitis.

KEYWORDS: fecal calprotectin • ileal pouch-anal anastomosis • matrix metalloprotease-9 • pouchitis, ulcerative colitis

Background

A severe flare-up requiring hospitalization and intravenous steroid therapy develops in approximately 15% of patients with ulcerative colitis (UC) at least once during the course of the disease. Approximately 30% of patients with relapsing, extensive UC require surgery [1]. Total proctocolectomy with ileal pouch-anal anastomosis (IPAA) has been the most common and potentially curative surgical procedure for intractable UC since 1978, although up to 50% of the patients who undergo this surgery develop pouchitis [2]. The incidence of pouchitis is high and increases over time after pouch formation. The study by Simchuk *et al.* determined the short- and long-term outcomes of patients undergoing IPAA, revealing that the incidence of pouchitis in patients who

were followed for 6 months, 1 year and 3 years was 25, 37 and 50%, respectively. The incidence of pouchitis was 94% in patients who were followed for more than 6 years [3]. However, according to other studies, the reported cumulative frequency of pouchitis 10–11 years after IPAA surgery ranges from 23 to 46% [2,4,5]. Suzuki *et al.* found the cumulative risk of pouchitis to be 10.7% at 1 year, 17.2% at 2 years, 24.0% at 5 years and 38.2% at 10 years [6].

The clinical symptoms of pouchitis include watery and/or bloody diarrhea, abdominal discomfort, urgency and incontinence, occasionally accompanied by extraintestinal manifestations [7]. If symptoms persist, the presence of cuffitis – the inflammation of the rectal cuff – should also be considered. For the standardized definition of pouchitis, Sandborn *et al.* developed the

Table 1. Scoring system of pouchitis disease activity index.

Criteria	Score
Clinical	
• Stool frequency	
– Usual postoperative stool frequency	0
– 1–2 stools/day > postoperative usual	1
– 3 or more stools/day > postoperative usual	2
• Rectal bleeding	
– None or rare	0
– Present daily	1
• Fecal urgency or abdominal cramps	
– None	0
– Occasional	1
– Usual	2
• Fever (temperature >37.8°C)	
– Absent	0
– Present	1
• Endoscopic inflammation	
– Edema	1
– Granularity	1
– Friability	1
– Loss of vascular pattern	1
– Mucous exudates	1
– Ulceration	1
• Acute histologic inflammation	
– Polymorphic nuclear leukocyte infiltration	
Mild	1
Moderate + crypt abscess	2
Severe + crypt abscess	3
• Ulceration per low-power field (mean)	
– >25%	1
– 25–50%	2
– >50%	3

pouchitis disease activity index (PDAI) in 1994, which includes clinical, endoscopic and histological criteria [8]. The current gold standard for assessing the severity of pouch inflammation is an endoscopy with biopsies. However, non-invasive methods for detecting the onset of pouch inflammation in order to differentiate between pouchitis and cuffitis, to monitor disease activity and to determine treatment efficacy during the follow-up would have a high clinical value and could help make the diagnosis without an endoscopy, which would be much more comfortable for the patients.

Fecal calprotectin (FC), a diagnostic stool marker of neutrophilic intestinal inflammation, correlates with endoscopic and histological disease activity in adults and children afflicted by inflammatory bowel disease (IBD) and also appears to be a good predictor of relapse in IBD, mainly in UC [9–11]. Matrix metalloproteinase-9 (MMP-9), one of the zinc-dependent enzymes participating in the normal mucosal defense, is also abundantly released by neutrophils in IBD. MMP-9 levels have been shown to be significantly increased in the stool of UC patients compared to healthy control patients and patients with irritable bowel syndrome, and it correlates to a high degree with the clinical and endoscopic activity of UC, as well as with

FC [12]. Only limited data are available on the diagnostic accuracy of FC in pouchitis, and this is the first study to examine the sensitivity of MMP-9 in pouch inflammation.

Aim: The aim of our prospective study is to evaluate the diagnostic accuracy of FC and MMP-9 in colectomized UC patients with and without pouchitis, assessed by clinical, endoscopic and histological scores.

Patients & study design

Study population

Overall, 33 patients (female/male ratio: 18/15; median age at UC diagnosis: 25.5 years, interquartile range (IQR): 19.5–34.3; median age at surgery: 36.5 years, IQR: 26.8–46; median time elapsed after pouch formation: 43.5 months, IQR: 21.3–72.8) undergoing proctocolectomy with IPAA at the University of Szeged were consecutively enrolled in the study between March 2012 and May 2013. IPAA was performed in two steps requiring a temporary ileostomy for an average of 6 months. The level of the IPAA was at 3 to 4 cm above the dentate line. Disease activity was evaluated by PDAI [8], which includes the clinical, endoscopic and histological assessment of the disease. Pouchitis was defined as a PDAI score of >7. The severity of the suspected pouchitis was also estimated by the physician based on the symptoms of the patients admitted to the First Department of Medicine, University of Szeged. A day before pouchoscopy, patients were asked to provide fecal samples once at the First Department of Medicine, Szeged, Hungary. Blood samples were also obtained during the outpatient visit. Before pouchoscopy, the physician assessed in each patient if pouchitis was present or not on the basis of clinical symptoms only. Scoring system of PDAI is detailed in TABLE 1.

Blood inflammatory markers, FC & MMP-9 measurements

Routine laboratory methods were used to determine C-reactive protein and serum iron levels, hematocrit, hemoglobin levels and the thrombocyte count.

Stool samples were obtained and stored at -20°C until the determination of FC and MMP-9 levels. For calprotectin measurements, fecal specimens were thawed at 4°C. Calprotectin levels were quantified with an enzyme-linked immunosorbent assay (Quantum Blue, Bühlmann Laboratories Ltd, Schönenbuch), according to the manufacturer's instructions. For MMP-9 measurements, 1 g of the fecal samples was diluted, mixed and homogenized in 4 ml of ice-cold Tris-buffer (0.15 m NaCl + 20 mm Tris-HCl, pH 8.3) and then centrifuged. MMP-9 was also measured with a quantitative enzyme-linked immunosorbent assay (R&D Systems, Abingdon, UK). Detection limit for FC and MMP-9 was 30 µg/g and 0.156 ng/ml.

Pouchoscopy, histological examination

The participants underwent pouchoscopy performed by a single, experienced endoscopist (TM) to evaluate the macroscopic inflammation of the pouch. The presence of cuffitis and possible stenosis of the lower surgical anastomosis was also evaluated

with endoscopy. Cuffitis was defined as inflammation of the rectal cuff in the area between the anastomosis and the dentate line on endoscopy and histological examination, with or without minimal inflammation of the pouch body [13].

Biopsy samples from the reservoir were taken for histological purposes. Histological variables, including the degree of polymorphonuclear leukocyte infiltration and the extent of ulceration, were scored by a single pathologist (LT).

Statistical analyses

Correlations between FC, MMP-9 and PDAI and blood test results were determined with Pearson's correlation test or Spearman's rank. Frequencies and continuous variables were compared with Fisher's exact test and the Mann-Whitney *U*-test. Predictors of pouchitis were assessed using multivariate logistic regression analysis. A *p* value of less than 0.05 was considered statistically significant. The cut-off levels, specificity and sensitivity were calculated using receiver operating characteristic analysis. The cut-off level was calculated in case the value of the area under the receiver operating characteristic curve (AUC) was above 0.89, which was determined based on the maximum value of Youden's index (sensitivity + specificity - 1).

Ethical considerations

The study protocol was approved by the Ethical Committee of the University of Szeged. All subjects provided written and informed consent to participate.

Results

Frequency of pouchitis

Pouchitis determined by PDAI was detected in 10 out of the 33 (30.3%) patients. The median PDAI was 10 in the case of pouchitis and 1 if no inflammation was observed in the pouch ($p < 0.0001$). Cuffitis occurred in 14 patients and stenosis developed in 12 patients. Of the 14 cases of cuffitis, pouchitis was also present in four patients and stenosis in five. The median endoscopic subscores of PDAI were 3.5 and 0, and the median histological subscores of PDAI were 4 and 0 in patients with and without pouchitis, respectively. According to the physicians' estimations, the presence of pouchitis was suspected in 16 patients. The diagnosis of pouchitis was confirmed in 10 patients, whereas the clinical symptoms were proved to be caused by cuffitis in the remaining six cases where pouchitis was not confirmed endoscopically. The clinical characteristics of patients enrolled in the study are detailed in TABLE 2.

FC levels in patients with and without pouchitis

Median FC concentration was significantly higher in patients with (560 $\mu\text{g/g}$) versus without (96.5 $\mu\text{g/g}$) pouchitis ($p = 0.009$) (FIGURE 1). The cut-off value for FC in the diagnosis of pouchitis was 262 $\mu\text{g/g}$ with a sensitivity of 67% and a specificity of 89% (AUC = 0.78) (FIGURE 2). Negative predictive value and positive predictive value of FC were 84 and 78%,

Table 2. Clinical characteristics of patients with and without pouchitis enrolled in the study.

	Patients with pouchitis (n = 10)	Patients without pouchitis (n = 23)
Median age at onset (years)	23	28
Median age at the time of the study (years)	30	40
Median disease duration at IPAA	4	9
Female/male ratio	5/5	13/10
Presence of cuffitis	4	10
Presence of stenosis	2	10
Median time elapsed after pouch formation (months)	38	47
Median PDAI	10	1
Subscores of PDAI (median values)		
– Stool frequency	1	0
– Rectal bleeding	0	0
– Fecal urgency	1.5	0
– Fever	0	0
– Endoscopic inflammation	3.5	0
– Histological subscore	4	0
Medication for pouchitis		
Antibiotics (ciprofloxacin and/or metronidazole)	10	–
Methylprednisolone	4	–
Infliximab	4	–
Median FC ($\mu\text{g/g}$) [†]	560	96.5
Median fecal MMP-9 (ng/ml) [†]	16.9	1.34

[†]FC was determined in 33, MMP-9 in 21 patients. FC: Fecal calprotectin; IPAA: ileal pouch-anal anastomosis; MMP: Matrix metalloprotease-9; PDAI: Pouchitis disease activity index.

respectively, in the diagnosis of pouchitis. However, no correlation was shown between FC concentration and the severity of pouchitis ($r = 0.188$; $p = 0.348$). Although, when examining the subscores of PDAI (stool frequency, rectal bleeding, fecal urgency, fever, endoscopic inflammation and histological subscores), the endoscopic and histological subscores showed significant association with FC concentration ($p = 0.0001$; $p = 0.0002$). FC was determined in every patient.

Fecal MMP-9 levels in patients with and without pouchitis

The median fecal MMP-9 level was significantly higher in patients with (16.9 ng/ml) versus without (1.34 ng/ml) pouchitis ($p = 0.004$) (FIGURE 3). For MMP-9, the cut-off value was 3.85 ng/ml with a sensitivity of 89 and a specificity of 91%

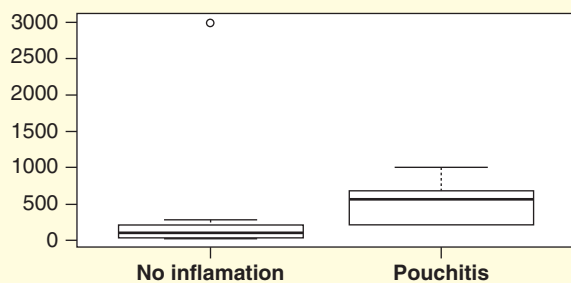


Figure 1. Median fecal calprotectin concentration was significantly higher in patients with versus without pouchitis. Y-axis shows the range of FC (range: 0–3000; minimum: 30; maximum: 3000 µg/g). FC: Fecal calprotectin.

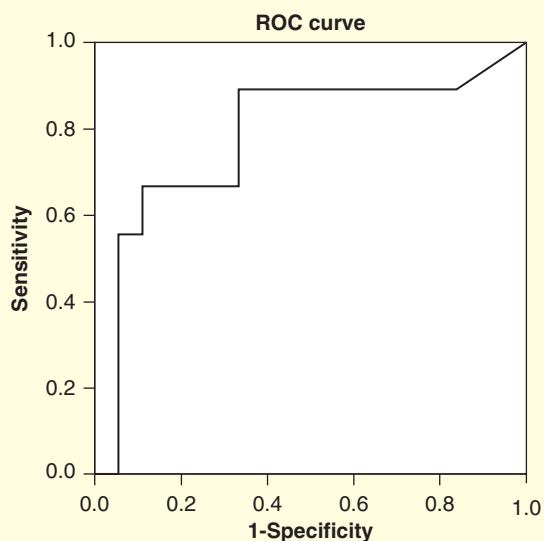


Figure 2. Receiver operating characteristic curve with AUC of 0.78 showed the cut-off value of FC of 262 µg/g with the sensitivity and specificity of 67 and 89% in the diagnosis of pouchitis. ROC: Receiver operating characteristic.

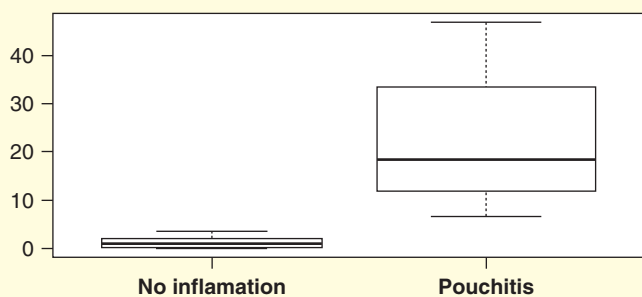


Figure 3. Median fecal MMP-9 concentration was significantly higher in patients with versus without pouchitis. Y-axis shows the range of fecal MMP-9 (range: 0–46.9; minimum: 0.05; maximum: 46.9 ng/ml).

(AUC = 0.89) (FIGURE 4). Negative Predictive Value and Positive Predictive Value of fecal MMP-9 were 90 and 89%, respectively, in the diagnosis of pouchitis. A statistically significant correlation was shown between the fecal MMP-9 concentration and the severity of pouchitis ($r = 0.526$, $p = 0.017$). As to the subscores of PDAI, the clinical, endoscopic and histological subscores were shown to have significant association with the MMP-9 concentration ($p = 0.009$, $p = 0.011$, $p = 0.002$, respectively). However, only a weak correlation was revealed between FC and MMP-9 concentrations ($r = 0.449$, $p = 0.054$) (FIGURE 5). Fecal MMP-9 was determined in 21 patients (eight patients with pouchitis and 13 patients without pouchitis).

Correlation between FC & MMP-9 concentrations & cuffitis

No association was revealed between FC and MMP-9 and the presence of cuffitis or stenosis either in patients with or without pouchitis.

Correlation between pouchitis & the inflammatory laboratory parameters

None of the laboratory markers correlated significantly with pouchitis.

Discussion

Pouchitis is an idiopathic chronic inflammatory disease that may occur in the ileal pouch after restorative proctocolectomy with IPAA and has a significant effect on the patients' quality of life. Detecting consistently available, non-invasive factors to predict, determine and follow-up pouchitis is extremely important and has a high clinical value in the selection of an appropriate treatment. In this prospective, pilot study, the median FC level was more than fivefold higher; the median MMP-9 level was almost 12 times higher in patients with versus without pouchitis, although a significant correlation was revealed only between fecal MMP-9 and the severity of pouchitis.

FC and MMP-9 are promising non-invasive diagnostic inflammatory markers not only in UC, but also in pouchitis, although only a few studies examined their diagnostic accuracy in pouchitis. In one of the first studies in this topic, Johnson *et al.* revealed the ability of FC to differentiate between inflamed and non-inflamed pouches. A close correlation was also shown between FC concentrations and acute histological and endoscopic inflammation and PDAI [14]. Although, in the study of Thomas *et al.*, FC concentration, at a cut-off of 10 mg/l, had a sensitivity of 100 and a specificity of 87% in diagnosing pouchitis, the different methodical procedure may explain the different (higher) cut-off value that was determined in our study [15]. Pakarinen *et al.* revealed a significant difference in mean FC concentration between patients with no history of pouchitis and those with recurrent pouchitis [16]. They showed that FC correlated positively with the histological neutrophil count of the distal ileum, the frequency of pouchitis and the maximum daily frequency of bowel actions.

While the diagnostic role of FC in pouchitis has previously been examined in some studies, only limited data are available on the role of MMP-9 in pouchitis, and it has never been used as a diagnostic stool marker in this disease. MMPs take part in normal mucosal defense and play a role in the development of inflammatory processes, as well as in the pathogenesis of inflammatory diseases [17]. In IBD, MMP-9 is the most abundantly expressed MMP, and it shows increased activity in inflamed UC mucosa and in pouchitis [18]. In case of pediatric-onset UC patients, most pouch samples showed an increased expression of MMP-3 and MMP-7 in pouchitis, which do not correlate with the markers of inflammation, FC, erythrocyte sedimentation rate or CRP [19].

The role of mucosal MMPs in the differentiation of pouchitis was first examined by Stallmach *et al.* [20]: they revealed that MMP-1 and MMP-2 concentrations in the mucosal biopsy samples were increased in pouchitis compared with uninfamed pouches of patients with UC or familial adenomatous polyposis. Strong MMP-9 and MMP-2 activity was detected in the inflamed pouch being reduced after antibiotic treatment in the study of Ulisse *et al.* [21]. However, MMP-9 has never been assessed in the stool of patients with IPAA. In the present study, we evaluated the diagnostic accuracy of FC and MMP-9 in pouchitis. Our results revealed that none of the routinely used laboratory activity markers correlated significantly with pouchitis, but the levels of FC and MMP-9 were significantly increased in pouchitis. Moreover, fecal MMP-9 showed a significantly stronger correlation with the severity of pouchitis than FC did, and it correlated even more significantly with the clinical, endoscopic and histological activity of pouchitis. Interestingly, histological examinations usually showed cryptitis, abnormal crypt structure or even crypt abscess and described the findings as an UC-like image, confirming a colonic-type mucosa in patients with moderate-to-severe pouchitis with higher MMP-9 levels. In case of pouchitis with only mild activity and lower MMP-9, the histological finding described the characteristic of the inflammation as an ileitis.

The authors are aware of the limitations of the study. The main restriction of the study is the low number of enrolled patients, although nearly the same or lower numbers of patients participated in the previously mentioned studies. However, it should be noted that the frequency of colectomy in UC is somewhat lower in Hungary than in the Western and Northern countries, and we enrolled almost half of the patients treated at our centre that had been operated on throughout the past 10 years. According to our previously published data, the overall colectomy rate was 24.6% at our centre during a 7-year period [22]. However, the strengths of this study are the accurately performed diagnostic and scoring procedures.

This is the first pilot study that assesses the diagnostic accuracy of FC and MMP-9 in pouchitis. Our results show that although both fecal markers are elevated in pouchitis, fecal MMP-9 has higher specificity in the detection of pouchitis. However, none of them are associated with cuffitis that presents with similar

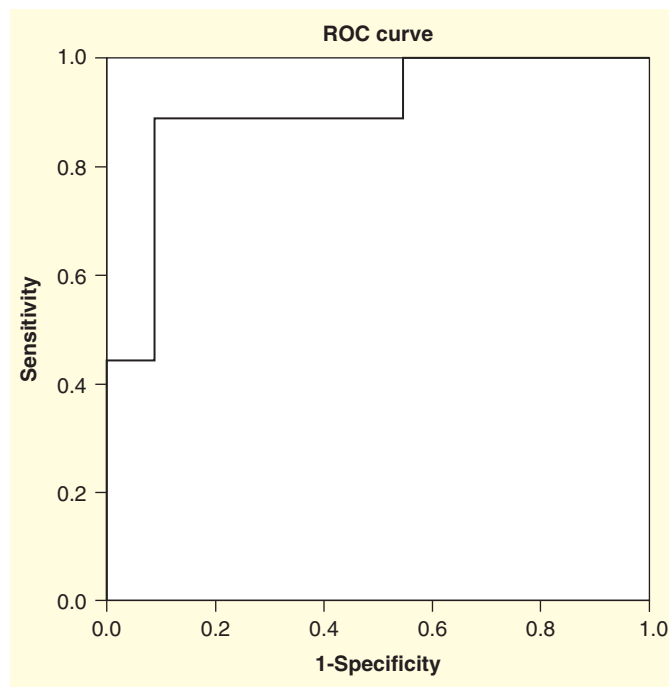


Figure 4. Receiver operating characteristic curve with AUC of 0.89 showed the cut-off value of fecal MMP-9 of 3.85 ng/ml with the sensitivity and specificity of 89 and 91% in the diagnosis of pouchitis.

ROC: Receiver operating characteristic.

symptoms as pouchitis. These non-invasive methods help assess pouch inflammation, differentiate between pouchitis and cuffitis and, therefore, optimize future management.

Financial & competing interest disclosure

This work was supported by the János Bolyai Research Scholarship of the Hungarian Academy of Sciences (BO/00632/14/5), TAMOP-4.2.2.A-11/11/KONV-2012-0035, TAMOP-4.2.2.A-11/11/KONV-2012-0052 TAMOP-

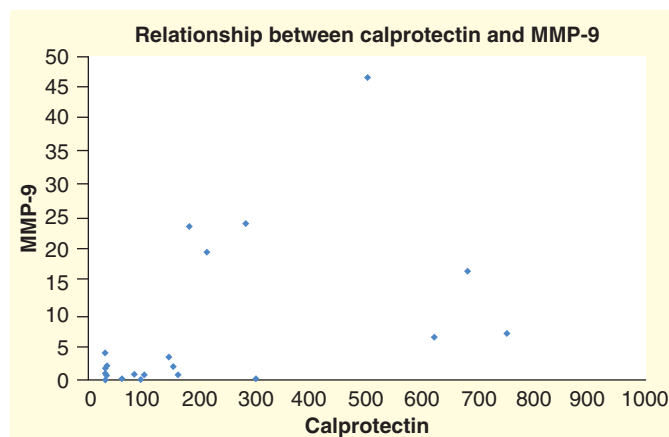


Figure 5. Correlation between fecal calprotectin and matrix metalloproteinase-9 levels. FC and fecal MMP-9 determinations were available in 21 patients. R-value = 0.549. FC: Fecal calprotectin; MMP-9: Matrix metalloproteinase-9.

4.2.2.A-11/1/KONV-2012-0073 and OTKA PD 105948 (PI: Klaudia Farkas). The authors have no other relevant affiliations or financial involvement with any organization or entity with a financial interest in or financial conflict

with the subject matter or materials discussed in the manuscript apart from those disclosed.

No writing assistance was utilized in the production of this manuscript.

Key issues

- The incidence of pouchitis after total proctocolectomy with ileal pouch-anal anastomosis is high.
- The gold standard for assessing pouchitis is endoscopy.
- Only limited data are available on the diagnostic accuracy of fecal calprotectin and in pouchitis.
- Sensitivity of fecal matrix metalloproteinase-9 (MMP-9) has never been examined in pouchitis.
- Our study revealed that both fecal calprotectin and fecal MMP-9 concentrations were significantly higher in patients with versus without pouchitis. However, a significant correlation was revealed only between fecal MMP-9 and the severity of pouchitis.
- Fecal MMP-9 seems to have higher specificity in the detection of pouchitis.

References

- Moss AC, Peppercorn MA. Steroid-refractory severe ulcerative colitis: what are the available treatment options? *Drugs* 2008;68:1157-67
- Fazio VW, Ziv Y, Church JM, et al. Ileal pouch-anal anastomosis: complications and function in 1005 patients. *Ann Surg* 1995;222:120-7
- Simchuk EJ, Thirlby RC. Risk factors and true incidence of pouchitis in patients after ileal pouch-anal anastomoses. *World J Surg* 2000;24:851-6
- Penna C, Dozois R, Tremaine W, et al. Pouchitis after ileal pouch-anal anastomosis for ulcerative colitis occurs with increased frequency in patients with associated primary sclerosing cholangitis. *Gut* 1996;38:234-9
- Ferrante M, Declerck S, De Hertogh G, et al. Outcome after proctocolectomy with ileal pouch-anal anastomosis for ulcerative colitis. *Inflamm Bowel Dis* 2008;14:20-8
- Suzuki H, Ogawa H, Shibata C. The long-term clinical course of pouchitis after total proctocolectomy and IPAA for ulcerative colitis. *Dis Colon Rectum* 2012;55:330-6
- Cheifetz A, Itzkowitz S. The diagnosis and treatment of pouchitis in inflammatory bowel disease. *J Clin Gastroenterol* 2004;38:44-50
- Sandborn WJ, Tremaine WJ, Batts KP, et al. Pouchitis after ileal pouch-anal anastomosis: a pouchitis disease activity index. *Mayo Clin Proc* 1994;69:409-15
- Roseth AG, Aadland E, Jahnsen J, Raknerud N. Assessment of disease activity in ulcerative colitis by faecal calprotectin, a novel granulocyte marker protein. *Digestion* 1997;58:176-80
- Tibble JA, Sigthorsson G, Bridger S, et al. Surrogate markers of intestinal inflammation are predictive of relapse in patients with inflammatory bowel disease. *Gastroenterology* 2000;119:15-22
- Costa F, Mumolo MG, Ceccarelli L, et al. Calprotectin is a stronger predictive marker of relapse in ulcerative colitis than in Crohn's disease. *Gut* 2005;54:364-8
- Annahazi A, Molnar T, Farkas K, et al. Fecal MMP-9: a new noninvasive differential diagnostic and activity marker in ulcerative colitis. *Inflamm Bowel Dis* 2013;19:316-20
- Wu B, Lian L, Li Y, et al. Clinical course of cuffitis in ulcerative colitis patients with restorative proctocolectomy and Ileal Pouch-Anal Anastomoses. *Inflamm Bowel Dis* 2013;19:404-10
- Johnson MW, Maestranzi S, Duffy AM, et al. Faecal calprotectin: a noninvasive diagnostic tool and marker of severity in pouchitis. *Eur J Gastroenterol Hepatol* 2008;20:174-9
- Thomas P, Rihani H, Røseth A, et al. Assessment of ileal pouch inflammation by single-stool calprotectin assay. *Dis Colon Rectum* 2000;43:214-20
- Pakarinen MP, Koivusalo A, Natunen J, et al. Fecal calprotectin mirrors inflammation of the distal ileum and bowel function after restorative proctocolectomy for pediatric-onset ulcerative colitis. *Inflamm Bowel Dis* 2010;16:482-6
- Goetzl EJ, Banda MJ, Leppert D. Matrix metalloproteinases in immunity. *J Immunol* 1996;156:1-4
- Baugh MD, Perry MJ, Hollander AP, et al. Matrix metalloproteinase levels are elevated in inflammatory bowel disease. *Gastroenterology* 1999;117:814-22
- Makitalo L, Piekkala M, Ashorn M, et al. Matrix metalloproteinases in the restorative proctocolectomy pouch of pediatric ulcerative colitis. *World J Gastroenterol* 2012;18:4028-36
- Stallmach A, Chan CC, Ecker KW, et al. Comparable expression of matrix metalloproteinases 1 and 2 in pouchitis and ulcerative colitis. *Gut* 2000;47:415-22
- Ulisse S, Gionchetti P, D'Alò S, et al. Expression of cytokines, inducible nitric oxide synthase, and matrix metalloproteinases in pouchitis: effects of probiotic treatment. *Am J Gastroenterol* 2001;96:2691-9
- Molnar T, Farkas K, Nyari T, et al. Response to first intravenous steroid therapy determines the subsequent risk of colectomy in ulcerative colitis patients. *J Gastrointest Liver Dis* 2011;20:359-63