



**Fertility Preservation: Successful Transplantation of Cryopreserved Ovarian Tissue in a Young Patient Previously Treated for Hodgkin's Disease**

Isabelle Demeestere, Philippe Simon, Serena Emiliani, Anne Delbaere and Yvon Englert

*Oncologist* 2007;12;1437-1442  
DOI: 10.1634/theoncologist.12-12-1437

**This information is current as of December 31, 2007**

The online version of this article, along with updated information and services, is located on the World Wide Web at:

<http://www.TheOncologist.com/cgi/content/full/12/12/1437>

*The Oncologist*® is devoted to medical and practice issues for medical, hematological, radiation, gynecologic, and surgical oncologists and is designed specifically for the busy practitioner entrusted with the care of adult or pediatric cancer patients.

*The Oncologist*® has been continuously published since 1995. The Journal is published 12 times annually. *The Oncologist*® is owned, published, and trademarked by AlphaMed Press, 318 Blackwell Street, Suite 260, Durham, North Carolina, 27701. © 2007 by AlphaMed Press, all rights reserved. Print ISSN: 1083-7159. Online ISSN: 1549-490X.

 **AlphaMed Press**

### Fertility Preservation: Successful Transplantation of Cryopreserved Ovarian Tissue in a Young Patient Previously Treated for Hodgkin's Disease

ISABELLE DEMEESTERE,<sup>a,b</sup> PHILIPPE SIMON,<sup>c</sup> SERENA EMILIANI,<sup>b</sup> ANNE DELBAERE,<sup>a-c</sup> YVON ENGLERT<sup>a-c</sup>

<sup>a</sup>Research Laboratory on Human Reproduction, <sup>b</sup>Fertility Clinic, and <sup>c</sup>Department of Gynaecology and Obstetrics, Université Libre de Bruxelles, Erasme Hospital, Brussels, Belgium

**Key Words.** Pregnancy • Fertility • Ovarian tissue cryopreservation • Transplantation • Cancer

**Disclosure:** No potential conflicts of interest were reported by the authors, planners, reviewers, or staff managers of this article.

#### LEARNING OBJECTIVES

After completing this course, the reader will be able to:

1. Discuss recent advances in the use of cryopreserved ovarian tissue to restore fertility.
2. Explain the main aspects of the procedure for transplantation of cryopreserved ovarian tissue.
3. Discuss the options to preserve fertility of young patients with a high risk for premature ovarian failure after cancer therapy.

CME

Access and take the CME test online and receive 1 AMA PRA Category 1 Credit™ at [CME.TheOncologist.com](http://CME.TheOncologist.com)

#### ABSTRACT

Cryopreservation of ovarian tissue is now offered as an experimental procedure to preserve the fertility of young patients with a high risk for premature ovarian failure resulting from cancer therapy. This is the only available option to preserve the fertility of prepubertal patients treated with gonadotoxic chemotherapy. At present, thousands of patients all over the world have undergone this procedure with the hope of later restoring their fertility. Although the efficiency of the transplantation of cryopreserved ovarian tissue to restore ovarian function has been established, reports of pregnancy are still very scarce. Here, we describe the second published full-term spontaneous pregnancy after an or-

thotopic and heterotopic transplantation of cryopreserved ovarian tissue in a 31-year-old woman previously treated by conditioning therapy for bone marrow transplantation for Hodgkin's disease. This birth gives compelling evidence for the graft origin of the gamete and confirms the efficacy of ovarian tissue transplantation in restoring human natural fertility after oncological treatment. This case report stresses the importance of proposing the ovarian tissue cryopreservation procedure to all young patients who require potentially sterilizing treatment, with all alternative options to preserve fertility being duly taken into consideration. *The Oncologist* 2007;12:1437-1442

## INTRODUCTION

As a result of improvements in oncological treatments, most young cancer patients achieve prolonged survival [1, 2]. For these young patients, ensuring their reproductive capacity after the oncological treatments has become a main concern, as it is directly related to their quality of life. However, premature ovarian failure is one of the most common long-term adverse effects affecting premenopausal patients treated with alkylating agents and/or radiation therapy [2–4]. The risk for premature ovarian failure depends mainly on the age of the patient, the type and dose of chemotherapy, and the irradiation field. Moreover, the resumption of cyclic menses after oncological treatment does not guarantee normal fertility. In a recent review, the chances of spontaneous pregnancy were estimated to be 28% and only 5% in women <20 years and >25 years of age, respectively, at the time of cancer treatment [5]. Conditioning therapy for bone marrow transplantation (BMT) is considered the most gonadotoxic treatment, inducing premature ovarian failure in >80% of cases, even when performed during childhood [6].

In recent years, the cryopreservation of ovarian tissue prior to gonadotoxic treatments has offered new hope for these young patients and is considered as an investigational procedure with the aim of restoring fertility [7–10]. Restoration of ovarian function after cryopreserved ovarian tissue transplantation has been described previously [11, 12]. However, data concerning fertility restoration after this procedure are still very limited. The first spontaneous full-term pregnancy after orthotopic cryopreserved ovarian tissue transplantation was reported by Donnez et al. [13] in 2004. However, the gamete's origin has been questioned in this case, and indeed spontaneous ovulation from the remaining in situ ovary could not be excluded [14]. Following cryopreserved ovarian tissue transplantation, another full-term pregnancy was reported after an in vitro fertilization (IVF) procedure and embryo transfer [15].

We report here the second spontaneous full-term pregnancy after orthotopic and heterotopic transplantation of cryopreserved ovarian tissue in a patient previously treated by BMT. The discussion addresses the indications, advantages, and limitations of this procedure considering its recent success and the other available options.

## CASE PRESENTATION

At age 24, the patient received intensive chemotherapy before autologous BMT for Hodgkin's disease, which consisted of six courses of ABVD (doxorubicin, 50 mg/m<sup>2</sup>; bleomycin, 20 mg; vincristine, 12 mg/m<sup>2</sup>; dacarbazine, 750 mg/m<sup>2</sup> per course), three courses of EVA (etoposide, 300 mg/m<sup>2</sup>; vinblastine, 6 mg/m<sup>2</sup>; doxorubicin, 50 mg/m<sup>2</sup> per

course), and a CBV conditioning regimen (cyclophosphamide, 6,400 mg/m<sup>2</sup>; carmustine, 450 mg/m<sup>2</sup>; etoposide, 1,500 mg/m<sup>2</sup>). Unilateral ovariectomy was performed after the first ABVD course, allowing the cryopreservation of 40 pieces of ovarian cortex, as previously described [16]. After BMT, the patient was considered to be disease free but never recovered spontaneous menstrual cycles. Four years later, she expressed a wish to conceive. However, amenorrhea and hormonal blood tests confirmed premature ovarian failure (follicle-stimulating hormone [FSH] of 87 mIU/ml and inhibin B <15 ng/ml). Biopsy of the remaining ovary revealed the absence of follicles.

A first orthotopic (peritoneal and ovarian sites) and heterotopic (s.c. abdominal site) transplantation of cryopreserved ovarian tissue was then performed by a two-step laparoscopy (day 0, November 2004) [16]. Before the procedure, three fragments of ovarian tissue were thawed and histologically examined for tumor cells and follicular density (12 follicles/mm<sup>2</sup>) [16].

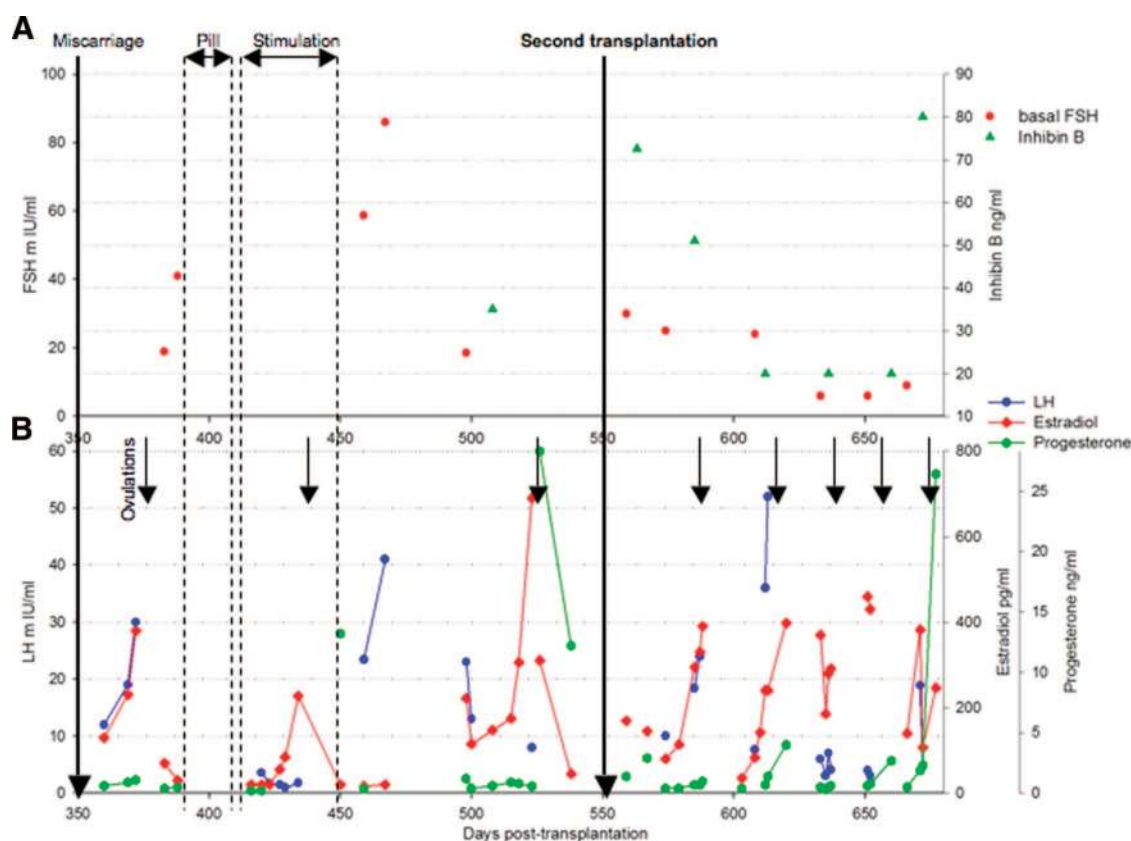
After the transplantation procedure, ovarian function was continuously monitored. Basal FSH and inhibin B (measured between day 3 and day 5 of each menstrual cycle) were used to evaluate ovarian reserve. Estradiol was regularly measured during each cycle and ovulation was determined based on the luteinizing hormone surge. Progesterone was measured during each luteal phase. Follicular development was assessed at each transplanted site by ultrasonography [16].

The ovarian tissue transplantation allowed recovery of ovarian function, and a spontaneous clinical pregnancy was obtained following the sixth cycle. Unfortunately, the patient miscarried at 7 weeks because of aneuploidy (day 310) [16].

One year after the first ovarian tissue transplantation, a progressive increase in FSH values and a decrease in inhibin B levels, both ovarian reserve markers, suggested progressive deterioration of the graft (Fig. 1A). Ovarian stimulation was attempted without success, after 21 days of contraceptive pill administration, reducing the basal FSH value.

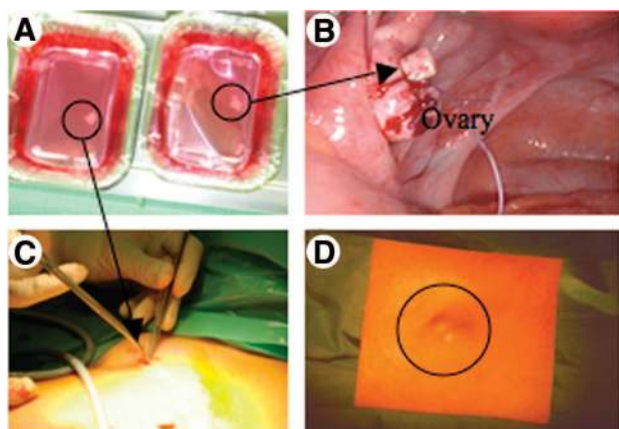
To recover a normal hormonal status and to increase, as much as possible, the chance of pregnancy, a second orthotopic and heterotopic transplantation was performed in May 2006. Four pieces of ovarian cortex were thawed as previously described [16] (Fig. 2A). By a two-step laparoscopy, two ovarian fragments were sutured on the remaining ovary (Fig. 2B). The other two fragments were divided and placed s.c. using the left abdominal incision made for the trocar (Fig. 2C). No intra- or postoperative complications were observed.

During the first 3 months, her basal FSH levels re-



**Figure 1.** Basal FSH and inhibin B values (A) and hormonal profiles (estradiol, LH, and progesterone) of the cycles (B) from the miscarriage following the first transplantation procedure (day 0).

Abbreviations: FSH, follicle-stimulating hormone; LH, luteinizing hormone.



**Figure 2.** Second transplantation procedure. (A): Thawed ovarian tissue before the transplantation procedure. Transplantation procedure at the ovarian site (B) and at the abdominal s.c. site (C). (D): Follicular development observed at the s.c. site.

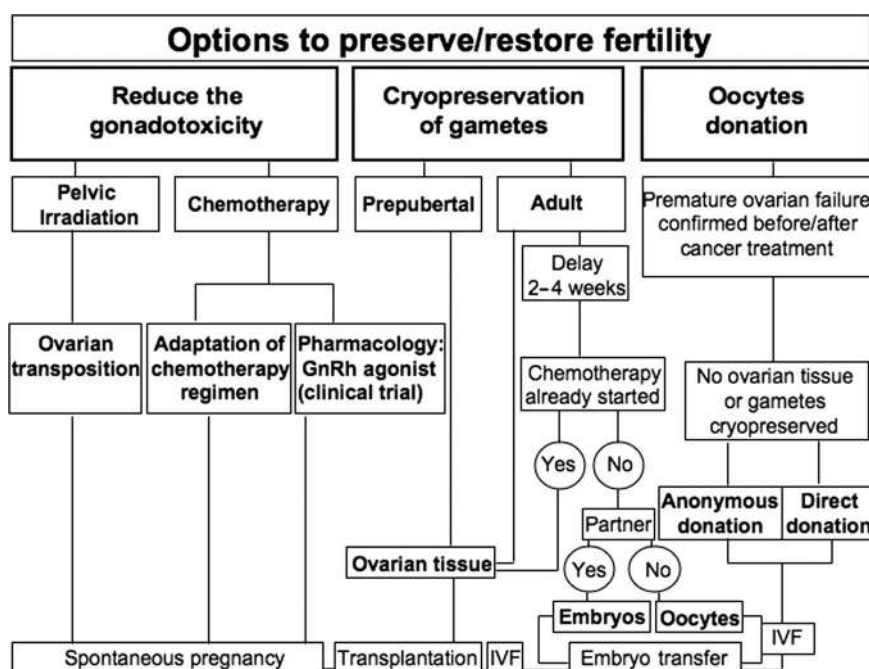
Abbreviation: s.c., subcutaneous.

mained high ( $>20$  mIU/ml), although the patient again ovulated (Fig. 1B). Follicular development was observed at both the ovarian and right s.c. sites (first s.c. transplanted site, Fig. 2D). No follicular development was observed at

the left s.c. site (second s.c. transplanted site). From the third cycle, basal FSH levels returned to normal premenopausal values ( $<10$  mIU/ml). During the fifth spontaneous cycle following the second transplantation procedure, two follicles of 15 mm diameter each were observed at the ovarian site at the time of ovulation. A positive human chorionic gonadotropin level was detected at day 14 of the luteal phase and a clinical pregnancy was later confirmed by vaginal ultrasound. The pregnancy evolved normally without any complication and the patient gave birth to a healthy girl at 41 weeks' gestation.

## DISCUSSION

Considering the impact of infertility on long-term quality of life, all young patients who potentially face premature ovarian failure should receive accurate information concerning the available options to preserve their fertility. A previous report concerning young patients affected by breast cancer showed that receiving fertility-related information was rated as significantly more important than receiving menopause-related information at the time of diagnosis [17]. In the same way, the majority of pediatric oncological patients and their parents are concerned by the fertility impact of



**Figure 3.** Options to preserve or restore fertility in cancer patients.

Abbreviations: GnRH, gonadotropin-releasing hormone; IVF, in vitro fertilization.

treatment, but only around one third of them are satisfied with the amount of information received [18]. The oncologist's initiative in starting a discussion, supported by a multidisciplinary team, is a determinant of improving access to information and proposing the optimal options to preserve fertility.

The first option is to reduce the gonadotoxicity of the cancer treatment with the intention of preserving ovarian function and future natural fertility. This includes ovarian transposition, in the case of pelvic irradiation, or adaptation of the chemotherapy regimen (Fig. 3). Based on promising results from animal studies, concomitant administration of a gonadotropin-releasing hormone (GnRH) agonist during treatment with alkylating agents has also been proposed to reduce the gonadotoxicity of the drugs [19, 20]. The efficiency of GnRH agonists in preserving human fertility was suggested by a preliminary study [21]. However, no prospective, randomized trial confirming these results has yet been reported. Thus, at present, concomitant administration of a GnRH agonist should only be proposed as part of a clinical trial.

The second option is to cryopreserve gametes in order to later restore fertility (Fig. 3). Around 15 oocytes can be harvested after FSH ovarian stimulation of young cancer patients [22]. In the case of hormone-sensitive tumors such as breast cancer, alternatives to the gonadotropin ovarian stimulation protocol can be proposed [3]. When a partner is present, oocytes can be fertilized and the resulting embryos

cryopreserved. Cryopreservation of embryos is a well-established procedure routinely performed in IVF clinics. In the absence of a partner, mature unfertilized oocytes can be cryopreserved, but the clinical pregnancy rate for thawed oocytes is still low (2%) [23]. The main limitation of the oocyte or embryo cryopreservation procedure in cancer patients is the 2- to 4-week delay needed to achieve ovarian stimulation and oocyte collection. Furthermore, this procedure cannot be proposed if the patient has already started chemotherapy treatment because of genetic risk and poor efficacy [24].

Cryopreservation of ovarian tissue has the advantage of allowing the storage of a large number of primordial follicles, it can be performed at any time in the menstrual cycle without delay, and it is available for prepubertal patients. Options to restore fertility from cryopreserved ovarian tissue include follicular in vitro culture and ovarian tissue transplantation. However, the development of in vitro culture systems supporting primordial follicular growth in humans will probably need a few more years before being available. Ovarian tissue transplantation has been performed previously with success in humans. At present, >25 cases of heterotopic and orthotopic cryopreserved ovarian tissue transplantation have been reported. However, only three births have been reported after this procedure—one baby was conceived naturally after spontaneous ovulation [13] and the others were conceived using an IVF procedure ([15]; Anderson et al.



**Table 1.** Inclusion criteria for ovarian tissue cryopreservation and transplantation procedures

Ovarian tissue cryopreservation	Ovarian tissue transplantation
Maximum age 35 years	Maximum age 40 years
Risk for premature ovarian failure	Pregnancy request
No previous high gonadotoxic treatment	Complete remission of disease
Presence of the uterus	Absence of high risk for disease transmission
No HIV or hepatitis (B,C)-positive serologies	Absence of neoplastic cells in a biopsy of the cryopreserved tissue
No surgical contraindication	Informed consent
Informed consent	

communication ESHRE 2007). Thus, the procedure should be still considered experimental with selected inclusion criteria (Table 1).

We report here the second spontaneous pregnancy following ovarian tissue transplantation and we provide strong arguments for the graft origin of the follicular development. The patient had previously received conditioning treatment for BMT, after which spontaneous recovery of ovarian function is observed in <10% of the patients [25]. Furthermore, premature ovarian failure before the first transplantation procedure was well documented by hormonal profiles as well as by biopsy of the remaining ovary, confirming the absence of follicles [16]. The evolution of the hormonal profile after the first and the second transplantations is also compatible with the graft being the origin of the follicular growth. As previously described, the time needed to restore ovarian function after the first transplantation (5 months) reflects the time necessary for folliculogenesis in humans [16]. The increase in basal FSH values 1 year after the first transplantation procedure suggests a progressive return to ovarian failure status. One of the major issues after ovarian tissue transplantation is ischemic damage during

the revascularization process, limiting the life span of the graft. According to the literature, the life span of the graft varies from a few months to >2 years, depending mainly on both the age of the patient at the time of the cryopreservation procedure and the quantity of ovarian tissue transplanted [12, 26, 27]. However, a correlation between these factors and the life span of the graft is not easy to establish.

Another limitation of the procedure is the possibility of reintroducing malignant cells. According to previous studies, there has been no evidence of disease invasion in the ovarian tissue harvested from patients with Hodgkin's lymphoma [28]. However, the safety of the procedure must be evaluated for each request, considering the type of disease and the ovarian tissue analysis. Despite reassuring data regarding the absence of relapse and the good health of babies born following this procedure, all children, and patients who conceived in this manner, should have long-term follow-up, especially when the ovarian tissue was exposed to systemic chemotherapy before cryopreservation.

Finally, if all previously described options are not feasible, alternative approaches to parenting, like oocyte donation, have to be considered (Fig. 3).

## CONCLUSION

This is the second full-term spontaneous pregnancy reported after transplantation of cryopreserved ovarian tissue. This birth represents a great hope for all patients with a high risk for premature ovarian failure after oncological treatment and provides evidence of the efficacy of the procedure in restoring natural fertility. This case report also stresses the importance of proposing ovarian tissue cryopreservation to all young patients who require potentially sterilizing treatment for cancer, especially when other procedures, such as oocyte or embryo cryopreservation, are not recommended.

## ACKNOWLEDGMENTS

This study was supported by the Belgian National Fund for Scientific Research (F.N.R.S.- grant "Télévie"). I.D. is a scientific research worker with the FNRS.

## REFERENCES

- Horwitz SM, Horning SJ. Advances in the treatment of Hodgkin's lymphoma. *Curr Opin Hematol* 2000;7:235–240.
- Brougham MF, Wallace WH. Subfertility in children and young people treated for solid and haematological malignancies. *Br J Haematol* 2005; 131:143–155.
- Sonmezer M, Oktay K. Fertility preservation in young women undergoing breast cancer therapy. *The Oncologist* 2006;11:422–434.
- Teinturier C, Hartmann O, Valteau-Couanet D et al. Ovarian function after autologous bone marrow transplantation in childhood: High-dose busulfan is a major cause of ovarian failure. *Bone Marrow Transplant* 1998;22:989–994.
- Lobo RA. Potential options for preservation of fertility in women. *N Engl J Med* 2005;353:64–73.
- Wallace WH, Anderson RA, Irvine DS. Fertility preservation for young patients with cancer: Who is at risk and what can be offered? *Lancet Oncol* 2005;6:209–218.
- Radford J, Shalet S, Lieberman B. Fertility after treatment for cancer. *Ques-*

- tions remain over ways of preserving ovarian and testicular tissue. *BMJ* 1999;319:935–936.
- 8 Demeestere I, Simon P, Englert Y et al. Preliminary experience of ovarian tissue cryopreservation procedure: Alternatives, perspectives and feasibility. *Reprod Biomed Online* 2003;7:572–579.
  - 9 Lee SJ, Schover LR, Partridge AH et al; American Society of Clinical Oncology. American Society of Clinical Oncology recommendations on fertility preservation in cancer patients. *J Clin Oncol* 2006;24:2917–2931.
  - 10 Moffa F, Biacchiardi CP, Fagioli F et al. Ovarian tissue cryostorage and grafting: An option to preserve fertility in pediatric patients with malignancies. *Pediatr Hematol Oncol* 2007;24:29–44.
  - 11 Oktay K, Karlikaya G. Ovarian function after transplantation of frozen, banked autologous ovarian tissue. *N Engl J Med* 2000;342:1919.
  - 12 Radford JA, Lieberman BA, Brison DR et al. Orthotopic reimplantation of cryopreserved ovarian cortical strips after high-dose chemotherapy for Hodgkin's lymphoma. *Lancet* 2001;357:1172–1175.
  - 13 Donnez J, Dolmans MM, Demylle D et al. Livebirth after orthotopic transplantation of cryopreserved ovarian tissue. *Lancet* 2004;364:1405–1410.
  - 14 Oktay K, Tilly J. Livebirth after cryopreserved ovarian tissue autotransplantation. *Lancet* 2004;364:2091–2092.
  - 15 Meirow D, Levron J, Eldar-Geva T et al. Pregnancy after transplantation of cryopreserved ovarian tissue in a patient with ovarian failure after chemotherapy. *N Engl J Med* 2005;353:318–321.
  - 16 Demeestere I, Simon P, Buxant F et al. Ovarian function and spontaneous pregnancy after combined heterotopic and orthotopic cryopreserved ovarian tissue transplantation in a patient previously treated with bone marrow transplantation: Case report. *Hum Reprod* 2006;21:2010–2014.
  - 17 Thewes B, Meiser B, Taylor A et al. Fertility- and menopause-related information needs of younger women with a diagnosis of early breast cancer. *J Clin Oncol* 2005;23:5155–5165.
  - 18 Oosterhuis BE, Goodwin T, Kiernan M et al. Concerns about infertility risks among pediatric oncology patients and their parents. *Pediatr Blood Cancer* 2008;50:85–89.
  - 19 Ataya KM, Palmer KC, Blacker CM et al. Inhibition of rat ovarian [<sup>3</sup>H]thymidine uptake by luteinizing hormone-releasing hormone agonists: A possible mechanism for preventing damage by cytotoxic agents. *Cancer Res* 1988;48:7252–7256.
  - 20 Ataya K, Rao LV, Lawrence E et al. Luteinizing hormone-releasing hormone agonist inhibits cyclophosphamide-induced ovarian follicular depletion in rhesus monkeys. *Biol Reprod* 1995;52:365–372.
  - 21 Blumenfeld Z, Eckman A. Preservation of fertility and ovarian function and minimization of chemotherapy-induced gonadotoxicity in young women by GnRH-a. *J Natl Cancer Inst Monogr* 2005;34:40–43.
  - 22 Porcu E, Fabbri R, Damiano G et al. Oocyte cryopreservation in oncological patients. *Eur J Obstet Gynecol Reprod Biol* 2004;113(suppl 1):S14–S16.
  - 23 Oktay K, Cil AP, Bang H. Efficiency of oocyte cryopreservation: A meta-analysis. *Fertil Steril* 2006;86:70–80.
  - 24 Dolmans MM, Demylle D, Martinez-Madrid B et al. Efficacy of in vitro fertilization after chemotherapy. *Fertil Steril* 2005;83:897–901.
  - 25 Meirow D, Nugent D. The effects of radiotherapy and chemotherapy on female reproduction. *Hum Reprod Update* 2001;7:535–543.
  - 26 Schmidt KL, Andersen CY, Loft A et al. Follow-up of ovarian function post-chemotherapy following ovarian cryopreservation and transplantation. *Hum Reprod* 2005;20:3539–3546.
  - 27 Donnez J, Martinez-Madrid B, Jadoul P et al. Ovarian tissue cryopreservation and transplantation: A review. *Hum Reprod Update* 2006;12:519–535.
  - 28 Seshadri T, Gook D, Lade S et al. Lack of evidence of disease contamination in ovarian tissue harvested for cryopreservation from patients with Hodgkin lymphoma and analysis of factors predictive of oocyte yield. *Br J Cancer* 2006;94:1007–1010.

**Fertility Preservation: Successful Transplantation of Cryopreserved Ovarian Tissue in a Young Patient Previously Treated for Hodgkin's Disease**

Isabelle Demeestere, Philippe Simon, Serena Emiliani, Anne Delbaere and Yvon Englert

*Oncologist* 2007;12;1437-1442

DOI: 10.1634/theoncologist.12-12-1437

**This information is current as of December 31, 2007**

**Updated Information  
& Services**

including high-resolution figures, can be found at:  
<http://www.TheOncologist.com/cgi/content/full/12/12/1437>