

# First Reported Case of Adrenal Neurofibroma from Iran

Siavash Falahatkar,<sup>1</sup> Ali Mohammadzadeh,<sup>2</sup> Sara Nikpour,<sup>1</sup> Hossein Khoshrang,<sup>2</sup> Korosh Askari<sup>3</sup>

Keywords: neurofibroma, adrenal tumor, pheochromocytoma, laparoscopy

Urol J. 2007;4:242-4.  
www.uj.unrc.ir

## INTRODUCTION

There is a broad spectrum of neurogenic tumors involving the abdominal organs. These tumors can be classified as those originating from the ganglion cells (ganglioneuroblastoma, ganglioneuroma, neuroblastoma), paraganglionic system (pheochromocytoma, paraganglioma), and nerve sheaths (neurilemmoma, malignant nerve sheath tumor, neurofibroma, and neurofibromatosis). Abdominal neurogenic tumors are mostly located in the retroperitoneum, especially in the paraspinal areas and adrenal glands.<sup>(1)</sup> Adrenal neurofibroma is a rare benign tumor which has not been considered in the text books of urology, yet.<sup>(2)</sup> We report a case of this tumor diagnosed in an Iranian woman

presented with discomfort in her right flank.

## CASE REPORT

Our patient was a 24-year-old woman who presented with the chief complaint of discomfort in her right flank. She did not have any history of hypertension or other specific diseases. Her blood pressure was 120/80 mmHg and the pulse rate was 80 per minute. On ultrasonography, a 5-cm mass was discovered in the retroperitoneum and near the upper pole of the right kidney which had shifted the renal vein anteriorly. Computed tomography (CT) revealed a 4.6 × 3.9-cm mass in the right adrenal gland with significant enhancement and central hypodensity (Figures 1 and 2).

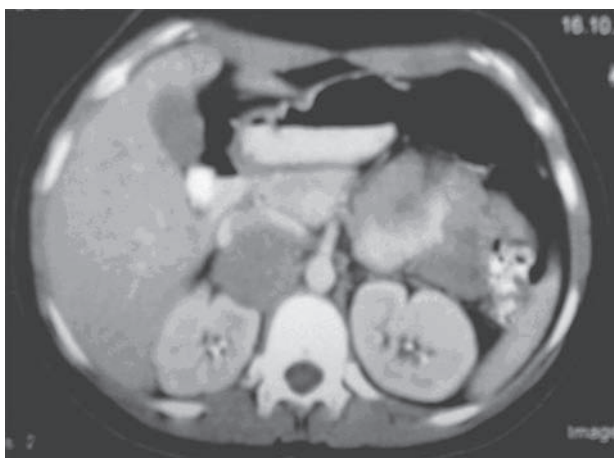
<sup>1</sup>Department of Urology, Urology Research Center, Razi Hospital, Rasht, Iran

<sup>2</sup>Department of Anesthesiology, Razi Hospital, Rasht, Iran

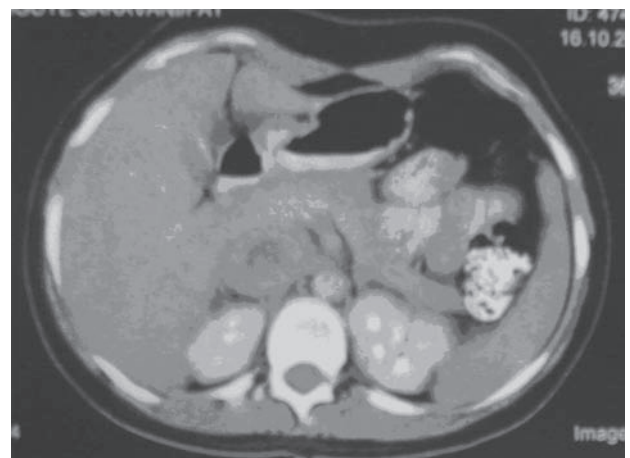<sup>3</sup>Department of Pathology, Razi Hospital, Rasht, Iran

Corresponding Author:  
Siavash Falahatkar, MD  
Department of Urology, Razi Hospital, Rasht, Iran  
Tel: +98 131 323 2050  
Fax: +98 131 323 2050  
E-mail: falahatkar\_s@yahoo.com

Received February 2007  
Accepted August 2007



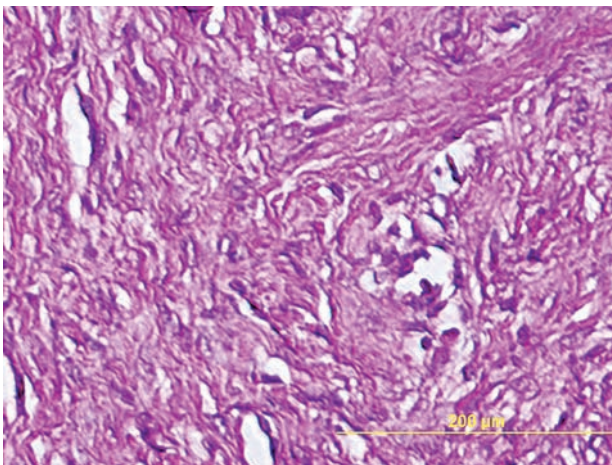
**Figure 1.** A tumor in the right adrenal gland is seen. The renal vein is shifted anteriorly.



**Figure 2.** A tumor in the right adrenal gland is detected with central hypodensity.

On laboratory examinations the mass was nonfunctional; 24-hour urine levels of vanillylmandelic acid, metanephrine, normetanephrine, and free urine cortisol were 4.3  $\mu\text{g}$  (reference range, 0.5  $\mu\text{g}$  to 12  $\mu\text{g}$ ), 91  $\mu\text{g}$  (reference range, 25  $\mu\text{g}$  to 312  $\mu\text{g}$ ), 390  $\mu\text{g}$  (reference range, 35  $\mu\text{g}$  to 445  $\mu\text{g}$ ), and 51 mg (reference range, 10 mg to 136 mg), respectively.

The patient underwent laparoscopic right adrenalectomy. After medialization of the colon, the right adrenal tumor was seen. Dissection was performed from the upper renal pole to the medial side. The tumor was adhered to the renal vein; therefore, the vein was firstly released and then, the tumor was completely removed. The patient was discharged 72 hours postoperatively without any complication and was visited 2, 4, and 12 weeks after the operation. No complication was reported during the follow-up period. Pathologic examination revealed neurofibroma (Figure 3).



**Figure 3.** The section reveals a benign neurogenic neoplasm composed of spindle-shaped cells with wavy nuclei and scanty cytoplasm among the collagen bundles (hematoxylin-eosin,  $\times 40$ ). On serial sections, no ganglion cells are detected. Staining by S100 and vimentin was positive and by neuron-specific enolase was focally positive. Specimens stained by CD34, collagen IV, desmin, Bcl 2, HMB45, and CD99 were negative.

## DISCUSSION

Neurofibromatosis is a rare systemic disease and urinary tract involvement is even more uncommon. Bladder is the organ in the urinary tract which is most frequently involved. The type of involvement is generally diffused infiltration and sometimes, it is manifested as a solitary tumor. Final diagnosis is made by pathologic and immunohistochemical

examination.<sup>(3)</sup> Abdominal neurogenic tumors are most commonly located in the retroperitoneum, especially in the paraspinal areas and adrenal glands.<sup>(1)</sup> There are few case reports of retroperitoneal neurofibroma in the literature.<sup>(4-6)</sup> Casey found a large firm painless palpable mass without neurological deficits in a 29-year-old man which was reported to be neurofibroma in pathological evaluation.<sup>(5)</sup> Also, Aoki and colleagues reported a case of solitary retroperitoneal neurofibroma in a 70-year-old woman.<sup>(6)</sup> All abdominal neurogenic tumors except neuroblastomas and ganglioneuroblastomas are seen in adult patients. Abdominal neurogenic tumors commonly manifest as well-defined and lobulated masses on radiological images.<sup>(1)</sup> Neurofibromas may show themselves as solitary tumors or a component of neurofibromatosis. Neurilemmomas and neurofibromas originate from the nerve sheaths; however, each has a special histologic appearance and may occur in different clinical settings. Malignant degeneration often happens to these tumors, particularly in the cases of neurofibromatosis.

On CT scan, these tumors have a homogeneous and smooth appearance with definite outlines. They often contain many cystic spaces with different sizes that are due to myxoid degeneration as seen in our patient (Figure 2).<sup>(7)</sup> Medullary necrosis seen on the patient's CT scan may also be due to myxoid degeneration. In addition, the well-defined neurofibromas arising from nerves traversing the mesentery or retroperitoneal space may be completely extensive. Differentiating these lesions from adenopathy may be quite difficult.<sup>(7)</sup>

Laparoscopic adrenalectomy is now the gold standard method for the treatment of adrenal tumors except for huge pheochromocytomas or invasive malignant tumors. The shorter convalescence with laparoscopic approach compared with open adrenalectomy has been accepted from the very beginning. Less blood loss, less pain, and better cosmetic results are the advantages of this method.<sup>(8)</sup> Laparoscopic resection of large adrenal tumors such as ganglioneuroma needs experience in open and advanced laparoscopic surgery. It seems that neurofibromas have not the potential for bleeding and can be dissected and separated from the surrounding tissues easily. To our best knowledge, this is the first case of adrenal neurofibroma in Iran.

## CONFLICT OF INTEREST

None declared.

## REFERENCES

1. Rha SE, Byun JY, Jung SE, Chun HJ, Lee HG, Lee JM. Neurogenic tumors in the abdomen: tumor types and imaging characteristics. *Radiographics*. 2003;23:29-43.
2. Winke JA, Lack EE. The adrenal gland. In: Silverberg SG, De Lellis RA, Frable WJ, Li Volsi VA, Wick MR, editors. *Silverberg's principles and practice of surgical pathology and cytopathology*. 4th ed. Philadelphia: Churchill Livingstone; 2005. p. 2169-209.
3. Cabrera Castillo PM, Alonso y Gregorio S, Cansino Alcaide JR, Aguilera Basan A, De La Peña Barthel JJ. [Bladder neurofibroma: case report and bibliographic review]. *Arch Esp Urol*. 2006;59:899-901. Spanish.
4. Nozomu T, Kenshi S, Kenji S, Hiroji O, Masayoshi Y. Solitary retroperitoneal neurofibroma with a cystic lesion: a case report. *Jap J of Clinical Urol*. 2001;55:567-70.
5. Casey AT. Neurological pictures. Massage of a giant retroperitoneal neurofibroma. *J Neurol Neurosurg Psychiatry*. 2006;77:814.
6. Aoki M, Nakano M, Sen S, Ohta N, Suzuki K, Fujita K. A case of solitary retroperitoneal neurofibroma. *Hinyokika Kiyo (Hinyokika Kiyo)*. 1998;44:273-6.
7. Zografos GN, Markou A, Ageli C, et al. Laparoscopic surgery for adrenal tumors. A retrospective analysis. *Hormones (Athens)*. 2006;5:52-6.
8. Nakagawa K, Murai M. Laparoscopic adrenalectomy: current status with a review of Japanese literature. *Biomed Pharmacother*. 2002;56:107s-112s.