

region. Such an extensive haematoma is very uncommon.<sup>1-4</sup> Literature review suggests that SSEDH involving more than two vertebral levels carries a worse prognosis.<sup>1,2</sup> Hence, the rapid recovery seen in our patient despite such an extensive haematoma is remarkable.

Improving clinical condition, extensive haematoma, age, and poor medical condition of the patient prompted us to pursue conservative treatment with good clinical and radiological improvement. Although emergency surgery is the treatment of choice, non-surgical therapy in the medically unfit, patients with minor deficits, and in patients with initial clinical improvement, has yielded good results, in all the aetiological groups,<sup>1,3,4</sup> which fits with our experience. Fresh frozen plasma, Vitamin K, and monitoring of INR have been the mainstay of conservative treatment in patients on anticoagulants, who need repeat MRI for follow up.<sup>3,4</sup> With the ever increasing number of patients on anticoagulant therapy for cardiovascular diseases, SSEDH is likely to become a more common problem. When to restart anticoagulant therapy and the optimal INR values to be maintained after restarting are the questions still unanswered in the literature.

In summary, SSEDH in patients taking anticoagulant drugs with initial clinical improvement may be successfully treated with regular clinical, haematological, and MRI monitoring even if they have extensive clots.

RAVI KUMAR  
CHRISTOPHER GERBER

Department of Neurosurgery, Regional Neurosciences  
Centre, Newcastle General Hospital,  
Newcastle upon Tyne, UK

Correspondence to: Mr Christopher Gerber, Department of Neurosurgery, Regional Neurosciences Centre, Newcastle General Hospital, Westgate Road, Newcastle upon Tyne NE4 6BE, UK.

- 1 Foo D, Rossier AB. Preoperative neurological status in predicting surgical outcome of spinal epidural haematomas. *Surg Neurol* 1981;15:389-401.
- 2 Lawton MW, Porter RW, Heiserman J E, et al. Surgical management of spinal epidural haematoma: relationship between surgical timing and neurological outcome. *J Neurosurg* 1995;83:1-7.
- 3 Boukobza M, Guichard JP, Boissonet M, et al. Spinal haematoma: report of 11 cases and review of literature. *Neuroradiology* 1994;36:456-9.
- 4 Holtas S, Heiling M, Lonntoft M. Spontaneous spinal epidural haematoma: findings at MR imaging and clinical correlation. *Radiology* 1996;199:409-13.
- 5 Sei A, Nakamura T, Hashimoto N, et al. Cervical spinal epidural haematoma with spontaneous remission. Case report. *J Spinal Disord* 1991;4:234-7.
- 6 Zuccarello M, Scanarini M, D'Avella, et al. Spontaneous spinal extradural haematoma during anticoagulant therapy. *Surg Neurol* 1980;14:411-3.

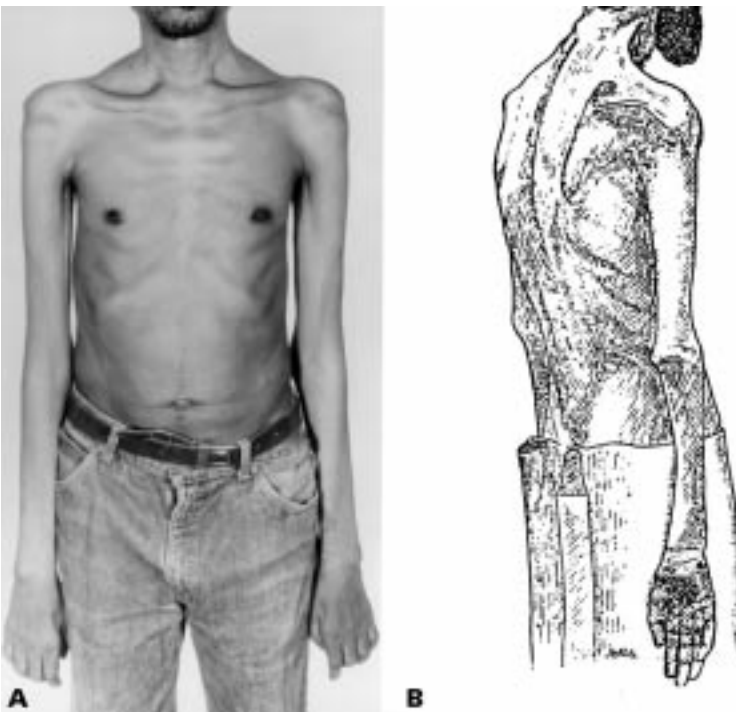
### Flail arm syndrome: a distinctive variant of amyotrophic lateral sclerosis

In a retrospective case note study of patients referred to a specialist clinic for motor neuron disorders we identified a subgroup of patients with severe wasting and weakness of the arms without significant involvement of other regions. This "flail arm syndrome" was identified in 39/395 (10%) of the subjects studied. Their clinical characteristics were compared with the amyotrophic lateral sclerosis (ALS) group as a whole. The age of onset was similar between the two groups but the male:female ratio was 9:1 in the flail arm group, compared with 1.5:1 in the ALS group ( $p=0.0015$ ). Although there was a trend

towards improved survival in the flail arm group (median survival 57 (95%CI 45-69) months) compared with the ALS group (39 (95%CI 35-43) months), this did not reach significance ( $p=0.204$ ) and was not an independent prognostic factor. As many patients with flail arm syndrome develop upper motor neuron signs in the lower limbs this syndrome probably represents a variant of ALS. It seems likely that unknown factors linked to male sex predispose a proportion of patients to develop the flail arm phenotype.

Historically, physicians have categorised illnesses according to their clinical characteristics. As a result the adult sporadic motor neuron disease syndromes have been described according to the site of lesion onset. Most patients present with both upper and lower motor neuron signs in the limbs (classic motor neuron disease or ALS). Rarer forms of predominantly upper and lower motor neuron syndromes are also recognised (primary lateral sclerosis and progressive muscular atrophy respectively). We have noted that a subgroup of patients with classic ALS present with progressive wasting and weakness of the arms, with little or no functional impairment of the bulbar muscles or legs (figure). Here we describe their clinical features and natural history in comparison to the ALS group as a whole. We have used the term "flail arm syndrome" to describe this variant of ALS.

All patients attending our specialist motor neuron disorders clinic between 1 January 1990 and 30 September 1996 were studied in a retrospective case notes study. Patients with alternative diagnoses, such as Kennedy's disease, spinal muscular atrophy, and multifocal motor neuropathy were excluded after full genetic, neurophysiological, and serological investigation, leaving 395 patients with a firm diagnosis of ALS. The censoring date for survival analysis was 31 January 1996.



(A) This 54 year old man with the flail arm syndrome has severe wasting of the arms causing profound weakness. Note the symmetric distribution and involvement of proximal musculature. Muscle bulk and strength were relatively preserved in the legs but lower limb reflexes were pathologically brisk and the plantar responses extensor. (B) Note the very similar pattern of wasting in a patient with "progressive muscular atrophy" depicted in a 1888 text of Gowers.<sup>2</sup>

Patients were classified according to the El Escorial criteria<sup>1</sup> and included in a detailed database incorporating key characteristics of the disease. Most fulfilled probable or definite ALS El Escorial categories having upper and lower motor neuron signs at first review. A minority with predominantly lower motor neuron features at presentation fulfilled suspected or possible ALS El Escorial categories. The flail arm syndrome was defined as a predominantly lower motor neuron disorder of the upper limbs without significant functional involvement of other regions at clinical presentation. Specifically, the wasting and weakness of the upper limbs had to be profound, symmetric, and involve proximal muscle groups (MRC grade  $\leq 3$ ). Those fulfilling the flail arm criteria were identified and compared with the rest of the ALS population based on the clinical assessment made at the time of the first clinic visit. Follow up was complete.

Demographic variables were compared using Student's  $t$  test. The  $\chi^2$  test and linear regression were used to test the independence of two variables. Survival of patients with ALS was estimated using the Kaplan-Meier curves and the log rank test was used to compare different categories. The Cox proportional hazards model was used to assess the simultaneous effects of several variables on survival. Results are expressed as the mean  $\pm 1$  SD and a  $p$  value of  $<0.05$  was considered significant.

Of 395 patients, 39 (10%) were identified as having the flail arm syndrome. Nine out of 39 (23%) of the patients with the syndrome had solely lower motor neuron features at the time of presentation. Upper motor neuron signs in the legs were present in most patients (77%) and although bulbar signs were present in 22 (56%) during the follow up period they were commonly asymptomatic at presentation.

The male to female ratio was strikingly different between the two groups, being 9:1 in the flail arm group and 1.5:1 in the ALS group (Student's *t* test,  $p=0.0015$ ). The mean age of symptom onset was similar (flail arm 58 (SD 13) years and ALS 55 (SD12) years) and there was no significant difference in the duration of follow up (flail arm 24 (SD 17) months and ALS 20 (SD 13) months,  $p=0.17$ ) or the proportion of familial cases (both 9%).

Using Kaplan-Meier analysis, the median survival in the flail arm group was 57 (95%CI 45–69; range 6–109) months, compared with 39 (95%CI 35–43; range 2–577) months in the ALS group, but this did not reach significance (log rank test,  $p=0.204$ ). There was no significant difference between the mean survival of flail arm and limb onset ALS groups. Using the Cox proportional hazards model, the flail arm syndrome was not identified as an independent risk factor determining survival.

The features of this distinctive ALS variant have not previously been characterised but it was probably first described by Gowers in his 1888 text *Diseases of the Nervous System*. In the chapter on the progressive muscular atrophies he noted that “when the arms are the seat of (such) atrophy as has been described, the legs, if not also wasted, may be normal, but they are often paralysed without being wasted” suggesting a pyramidal lower limb weakness.<sup>2</sup> Indeed, the illustration of a patient with primary muscular atrophy depicts the typical appearance of the patient with flail arm syndrome.

The predominant clinical feature of this syndrome is the relatively symmetric and proximal involvement of both arms, causing severe wasting and functional disability, with little or no weakness of the leg or bulbar musculature. Signs of corticospinal tract involvement are common in the legs and although denervation may be present in other regions this pattern of flail arms may persist for many years. Despite a severe loss of motor neurons in the cervical cord of patients with flail arm syndrome the higher cervical segments innervating the diaphragm seem to be spared early in the course of the disease.

What is the relation between the flail arm syndrome and other forms of ALS? The demonstration of upper motor neuron signs in most patients distinguishes this syndrome from primary muscular atrophy although there is probably an overlap. Our findings suggest that in most instances the flail arm syndrome represents a variant of classic ALS and most patients fulfil the probable or definite ALS El Escorial categories.<sup>1</sup> Although our clinic based ALS population is selected by referral it seems to be broadly representative judging by the demographic features described in other clinic and population samples.<sup>3,4</sup>

We, and others, have previously reported the influence of genotype on ALS phenotype with the apolipoprotein E  $\epsilon 4$  allele being associated with a bulbar onset of disease.<sup>5,6</sup> It is interesting to note that whereas the male:female ratio in most studies is around 1.5:1 for ALS overall, women predominate in the late onset bulbar palsy group.<sup>3,4</sup> The most striking finding of our study is the predominance of males in the flail arm group with a ratio of 9:1. It may be that factors linked to male sex predispose a proportion of patients to develop the flail arm phenotype. Curiously a male preponderance is also described in other lower motor neuron syndromes such as

multifocal motor neuropathy and monomelic amyotrophy.<sup>7,8</sup>

We suspect that survival of patients with flail arm syndrome might be better than those with other forms of ALS as the median survival in the flail arm group was 57 months, compared with 39 months in the ALS group. Although the difference was not significant, our numbers are still small and larger studies are needed. We conclude that the flail arm syndrome is a distinctive clinical variant of ALS that is strikingly more common in males and may have a better prognosis.

M T M HU  
C M ELLIS  
A AL-CHALABI  
P N LEIGH  
C E SHAW

Department of Clinical Neuroscience, Institute of Psychiatry and King's College School of Medicine and Dentistry, London, UK

Correspondence to: Dr CE Shaw, Department of Clinical Neuroscience, Institute of Psychiatry and King's College School of Medicine and Dentistry, London SE5 8AF, UK. Telephone 0044 171 346 5182; fax 0044 171 346 5181; email spgtces@iop.bpmf.ac.uk

- 1 Brooks BR. El Escorial World Federation of Neurology criteria for the diagnosis of amyotrophic lateral sclerosis. *J Neurol Sci* 1994;124:96–107.
- 2 Gowers WR. *A manual of diseases of the nervous system: spinal cord and nerves*. London: Churchill, 1888;1:356–81.
- 3 Haverkamp LJ, Appel V, Appel SH. Natural history of amyotrophic lateral sclerosis in a database population. Validation of a scoring system and a model for survival prediction. *Brain* 1995;118:707–19.
- 4 Chancellor A, Slattery J, Fraser H, et al. The prognosis of adult-onset motor neurone disease: a prospective study based on the Scottish Motor Neurone Disease Register. *J Neurol* 1993;240:339–46.
- 5 Al-Chalabi A, Enayat Z, Bakker M, et al. Association of apolipoprotein E  $\epsilon 4$  allele with bulbar-onset motor neurone disease. *Lancet* 1996;347:159–60.
- 6 Moulard B, Sefiani A, Laamri A, et al. Apolipoprotein E genotyping in sporadic amyotrophic lateral sclerosis: evidence for a major influence on the clinical presentation and prognosis. *J Neurol Sci* 1996;139(suppl):34–7.
- 7 Nobile-Orazio E. Multifocal motor neuropathy [editorial]. *J Neurol Neurosurg Psychiatry* 1996;60:599–603.
- 8 Oryema J, Ashby P, Spiegel S. Monomelic atrophy. *Can J Neurol Sci* 1990;17:124–30.

### Multifocal cortical myoclonus and cerebral amyloid $\beta$ -peptide angiopathy

The commonest clinical presentations of the sporadic cerebral amyloid angiopathies are with either recurrent lobar haemorrhages or with dementia.<sup>1</sup> In addition, transient focal neurological syndromes have occasionally been reported in association with cerebral amyloid angiopathies. These may represent transient ischaemic events or possibly focal seizures related to petechial intraparenchymal haemorrhages which are not associated with neuroimaging abnormalities; large haemorrhages may follow the onset of transient symptoms by weeks or months.<sup>2,3</sup> We report on a patient with multifocal cortical myoclonus who subsequently proved to have amyloid  $\beta$ -peptide cerebral amyloid angiopathy, an association not previously described. We consider possible pathogenetic interrelations of these findings.

A 65 year old woman presented with a 4 year history of involuntary movements. She had been noted to have abnormal jerking movements of her legs—for example, when climbing the stairs—which, on occasion had caused her to fall. Using an electric vacuum

cleaner or hearing the telephone ring had been noted to trigger these involuntary movements. There was no history of cognitive impairment. Her medical history was unremarkable aside from treated hypothyroidism. Family history was positive for sudden death, all three of her elder siblings (one sister, two brothers) dying in their mid-60s. One had previously had angina, the other two had been healthy until the time of their deaths, which were ascribed to a “heart attack” and a “clot on the brain”, respectively.

Examination of the patient disclosed a pronounced startle response, and action myoclonus in all limbs. There was no consistent stimulus sensitivity of the jerks. Otherwise, neurological examination was within normal limits.

Investigations, which proved either normal or negative, included standard tests of haematological and biochemical indices, thyroid function tests, serum vitamin B<sub>12</sub>, red cell folate, serum electrophoresis, quantitative immunoglobulins, angiotensin converting enzyme (ACE) concentrations, autoantibodies (including ANCA, anti-endothelial antibodies, and anti-GAD antibodies), and anti-neuronal antibodies (Hu, Purkinje). Blood film was negative for acanthocytes. Analysis of CSF showed a raised protein (0.82 g/l) but normal glucose concentration, cytology, and ACE; oligoclonal bands were not present. T2 weighted brain MRI showed a few small foci of high signal in the periventricular white matter, thought to represent age related small vessel disease. Carotid angiography was normal. Small bowel biopsy showed a normal mucosa with no evidence of coeliac disease. Analysis of mitochondrial DNA for common mutations (positions 3243, 3271, 8344, and 8356) proved negative. Psychometric assessment showed the patient to have a verbal IQ of 94, performance IQ of 95, indicative of functioning in the lower half of the average range but within the patient's estimated average optimal level of ability. She was noted to show signs of inefficiency and slowness, particularly in word retrieval and frontal lobe tasks, but there was no unequivocal evidence of focal deficits.

Peripheral, cervical, and cortical somatosensory evoked potentials after electrical stimulation of the median nerve at either wrist were of normal latency and morphology. However, although the amplitude of peripheral and cervical potentials was normal, the cortical responses were abnormally large, particularly from the right arm (22  $\mu$ V; left 15  $\mu$ V). Hence, on clinical and neurophysiological grounds, a diagnosis of multifocal cortical myoclonus of unknown cause was made. The patient was treated with clonazepam (0.25 mg twice daily), with marked symptomatic benefit at follow up.

Ten months after these investigations, the patient presented to an ophthalmologist with episodes of metamorphopsia for which no ocular cause was found. A further 3 months later she presented with a sudden onset of right parietal headache associated with vomiting and left sided pyramidal signs. Brain CT disclosed a large right sided parieto-occipital intracerebral haematoma with mass effect. At surgical drainage of the haematoma, a small piece of brain tissue was removed from the right parieto-occipital region. Histological examination showed small, irregular fragments of cortical grey and minimal amounts of white matter. The first included vessels, some of which were in obvious continuity with meningeal vessels. Most of them had