

9-1-2002

Flexor tendon repair and rehabilitation: State of the art in 2002

Martin I. Boyer
Washington University School of Medicine

James W. Strickland

Drew R. Engles

Kavi Sachar

Fraser J. Leversedge
Hand Surgery Associates

Follow this and additional works at: https://digitalcommons.wustl.edu/open_access_pubs



Part of the [Medicine and Health Sciences Commons](#)

Recommended Citation

Boyer, Martin I.; Strickland, James W.; Engles, Drew R.; Sachar, Kavi; and Leversedge, Fraser J., "Flexor tendon repair and rehabilitation: State of the art in 2002." *The Journal of Bone and Joint Surgery*. 84,9. 1684-1706. (2002).

https://digitalcommons.wustl.edu/open_access_pubs/957

This Open Access Publication is brought to you for free and open access by Digital Commons@Becker. It has been accepted for inclusion in Open Access Publications by an authorized administrator of Digital Commons@Becker. For more information, please contact vanam@wustl.edu.



Selected
**INSTRUCTIONAL
 COURSE
 LECTURES**

The American Academy of Orthopaedic Surgeons

Printed with permission of the American Academy of Orthopaedic Surgeons. This article, as well as other lectures presented at the Academy's Annual Meeting, will be available in March 2003 in Instructional Course Lectures, Volume 52. The complete volume can be ordered online at www.aaos.org, or by calling 800-626-6726 (8 A.M.-5 P.M., Central time).

DONALD C. FERLIC
 EDITOR, VOL. 52

COMMITTEE

DAVID L. HELFET
 CHAIRMAN

JAMES H. BEATY
DONALD C. FERLIC
TERRY R. LIGHT
VINCENT D. PELLEGRINI JR.

EX-OFFICIO

DEMPSEY S. SPRINGFIELD
 DEPUTY EDITOR OF THE JOURNAL OF BONE AND JOINT SURGERY
 FOR INSTRUCTIONAL COURSE LECTURES

JAMES D. HECKMAN
 EDITOR-IN-CHIEF,
 THE JOURNAL OF BONE AND JOINT SURGERY



Flexor Tendon Repair and Rehabilitation

STATE OF THE ART IN 2002

BY MARTIN I. BOYER, MD, FRCS(C), JAMES W. STRICKLAND, MD,
DREW R. ENGLER, MD, KAVI SACHAR, MD, AND FRASER J. LEVERSEDGE, MD

An Instructional Course Lecture, American Academy of Orthopaedic Surgeons

Major advances in the understanding of intrasynovial flexor tendon repair and rehabilitation have been made since the early 1970s^{1,2}, when reports first demonstrated that flexor tendon lacerations within the fibro-osseous digital sheath could be repaired primarily, and rehabilitation could be successful, without tendon excision and delayed grafting³. The concept of adhesion-free, or intrinsic, tendon-healing—namely, the idea that tendons could heal primarily without the ingrowth of fibrous adhesions from the surrounding sheath—has been validated both experimentally and clinically in studies over the past twenty years⁴⁻¹³. Recent attempts to understand and improve the results of intrasynovial flexor tendon repair have focused on restoration of the gliding surface^{11,14-23}, on the biomechanics at the repair site²⁴⁻³⁶, and on the molecular biology of early tendon healing³⁷⁻⁴⁷. The goals of the surgical treatment of intrasynovial flexor tendon lacerations have remained unchanged: they include achievement of a primary tendon repair of sufficient tensile strength to allow application of a postoperative passive-motion rehabilitation protocol that inhibits formation of intrasynovial adhesions, stimulates restoration of the gliding surface, and facilitates healing of the repair site⁴⁸.

Anatomy

The flexor digitorum superficialis arises from multiple origins on the volar surface of the humerus, ulna, and radius and is interconnected by a fibrous aponeurosis that overlies the median nerve and the ulnar vascular bundle in the forearm⁴⁹. In the midpart of the forearm, the superficialis muscle belly divides into four bundles, which separate into a superficial and a deep layer; the superficial layer sends tendons to the long and ring fingers, and the deep layer sends tendons to the index and small fingers. The flexor digitorum superficialis tendon to the small finger may not be present in all individuals⁴⁹. The common muscle belly of the flexor digitorum profundus originates from the anterior-medial aspect of the ulna and interosseous membrane and remains dorsal to the flexor digitorum superficialis in the volar aspect of the forearm. The four flexor digitorum profundus tendons usually arise from a common muscle belly; however, the flexor digitorum profundus to the index finger exhibits a high degree of independence, often originating from an individual muscle belly.

Kleinert and Verdan divided the flexor tendon into five anatomic zones⁵⁰. Zone V extends from the muscle-tendon junction to the entrance of the carpal

canal, and Zone IV lies deep to the transverse carpal ligament, where the flexor digitorum superficialis tendons to the long and ring fingers lie directly palmar to those of the index and small fingers and the flexor digitorum profundus tendons travel deep. As the tendons emerge from the carpal canal, the lumbrical muscles take origin from the flexor digitorum profundus tendons and travel distally to insert into the radial lateral bands of the digits. Zone III is the region from the distal edge of the transverse carpal ligament to the proximal aspect of the digital fibro-osseous sheath at the palmar crease. Zone II begins at the origin of the fibro-osseous flexor sheath in the distal aspect of the palm, and it extends to the distal aspect of the insertion of the flexor digitorum superficialis tendon. Zone I is distal to the insertion of the flexor digitorum superficialis.

At the level of the A1 pulley, the superficialis tendon flattens out and bifurcates, allowing the deeper profundus tendon to pass distal to its insertion at the base of the distal phalanx. The two limbs of the superficialis tendon rotate away from the midline and wrap around the profundus tendon, with half of the fibers crossing on the palmar surface of the phalanx to insert dorsal to the profundus tendon on the

palmar surface of the proximal half of the middle phalanx. The remaining fibers insert as radial and ulnar slips on the diaphysis of the middle phalanx.

The flexor tendons are covered by a thin visceral layer of adventitia, or paratenon. The tendons enter a synovium-lined fibro-osseous tunnel at the base of each digit that provides both a biomechanical advantage (on the basis of the pulley system) and a source of tendon nutrition (from the parietal and visceral layers of paratenon)⁵¹. Condensations of the synovial sheaths form at strategic points along the digit and work in conjunction with the palmar aponeurosis pulley⁵² and the transverse carpal ligament^{53,54} to maximize the efficiency of joint rotation and force transmission during grip. There is a predictable arrangement of five annular pulleys and three cruciform pulleys in the fingers. The A1, A3, and A5 pulleys originate from the palmar plates of the metacarpophalangeal, proximal interphalangeal, and distal interphalangeal joints, respectively. The A2 and A4 pulleys are continuous with the periosteum of the proximal aspect of the proximal phalanx and of the middle third of the middle phalanx, respectively. The cruciform pulleys are thin and compliant; they are located between the A2 and A3 pulleys (C1), between the A3 and A4 pulleys (C2), and between the A4 and A5 pulleys (C3) (Fig. 1).

Studies of the physiology of intrasynovial flexor tendons have demonstrated the importance of both intrinsic and extrinsic sources of nutrition⁵⁵⁻⁶², from local vascular networks and from the synovial fluid environment. Three primary sources of vascular supply have been described⁶³; they include longitudinally oriented vessels within the proximal paratenon, the mesotenon and its vincular arrangement, and vessels of intraosseous origin at the tendon insertion. Terminal vascular loops occur between distinct vascular regions, creating watershed areas of limited vascular supply within the tendon substance as described by Lundborg et al.⁶³. There is a single avascular zone within the intra-

synovial portion of the flexor digitorum superficialis tendon; it lies over the proximal phalanx and under the A2 pulley. There are two avascular zones within the intrasynovial portion of the flexor digitorum profundus tendon; the first lies over the proximal phalanx deep to the A2 pulley, and the second is located over the middle phalanx, typically under the A4 pulley.

Surgical Principles

Surgical exploration and repair of flexor tendon lacerations is done in an operating room under loupe magnification. An axillary block or general anesthesia is preferred, and a brachial tourniquet is used for hemostasis. As initially stressed by Lexer^{64,65} and later reemphasized by Bunnell³, tissue-handling must be meticulous: "Binding fibrosis is our arch enemy; so handling of the tissues should be reduced to a minimum, keeping the delicate histologic structure of the tendons and surrounding tissues always in mind."³ A midlateral or Bruner incision^{66,67} is used, incorporating original lacerations when feasible. Neurovascular bundles are identified and protected. Sharp dissection is carried out in the plane between the digital nerve and the fibro-osseous flexor sheath. At the level of the neck of the proximal phalanx, distal to the A2 pulley, the digital arterial ladder branch is identified and preserved. This vessel provides substantial vascular inflow to the vinculum to the superficialis tendon and also to the long vinculum to the profundus tendon. Sharp dissection is then carried out directly on the outer surface of the flexor tendon sheath, leaving both pulleys and membranous portions of the sheath intact. Thick skin flaps are raised, and devascularization of these skin flaps is avoided. The skin flaps are retracted with sutures to afford maximal exposure of the flexor sheath in the zone of injury as well as proximal and distal to the zone of injury in order to improve access through the membranous sheath for identification and retrieval of retracted tendon stumps.

The divided tendon ends are local-

ized and brought into the laceration site through windows created in the membranous portion of the flexor tendon sheath^{68,69}. A preoperative high-resolution ultrasound examination may assist in the localization of the proximal tendon stump⁷⁰ and thus aid in definitive planning of surgical incisions. Hemorrhage within the sheath often identifies the location of the retracted tendon. If the tendon is visible within the tendon sheath, it can be retrieved by proximal-to-distal "milking" of the tendon ends with the wrist and metacarpophalangeal joints both held in flexion, or by grasping the exposed interior substance of the tendon stump with fine-toothed forceps^{71,72}. Blind passage of instruments into the tendon sheath should be avoided, as direct trauma to its synovial lining can promote the formation of intrasynovial adhesions. Tendons that have retracted into the proximal aspect of the tendon sheath and are inaccessible from the wound may be retrieved by distal-to-

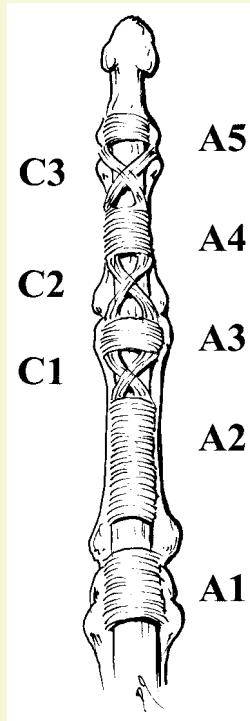


Fig. 1

The annular pulleys (A1 through A5) and cruciform pulleys (C1, C2, and C3) hold the flexor tendon within the flexor sheath and prevent bowstringing.

proximal passage of a small pediatric feeding catheter within the flexor sheath from the traumatic wound into the palm⁷³. A small, oblique, midpalmar incision is made in order to identify the proximal tendon segment and to place a suture to secure the catheter to the tendon. The catheter is pulled distally, delivering the proximal tendon stump to the repair site. The flexor tendon is thus not removed from its intrasynovial environment within the flexor sheath.

Although the checkrein effect of the vinculae^{74,75} and the lumbrical muscles typically prevents the proximal tendon stump from retracting into the palm, there are several methods for retrieval of a tendon that has retracted proximal to the A1 pulley⁷⁶⁻⁷⁹. Following delivery of the transected tendon ends into the operative site, a Keith needle or a 20-gauge needle is placed transversely through the tendon approximately 1 to 2 cm proximal and distal to the transected ends in order to stabilize the tendon ends for repair. Repairs of the flexor digitorum profundus tendon at or distal to the A4 pulley may be facilitated by placement of the core suture in the proximal tendon stump prior to passage of the tendon beneath the pulley for distal repair. In addition, the A4 pulley may be sequentially dilated by the passage of pediatric urethral dilator sounds. This allows the flexor digitorum profundus tendon to be delivered under the A4 pulley without the need for partial excision of the pulley. When a patient has a Zone-II injury involving laceration of both the flexor digitorum superficialis and the flexor digitorum profundus tendon, it is recommended that both tendons be repaired, with the flexor digitorum superficialis tendon repaired first.

Investigators have attempted to improve the time-zero early postoperative strength of the repair construct by varying the configuration of the core suture^{18,26,36,80-87}, altering the number of suture strands passing across the repair site^{31-33,35,80-83,88-98}, using core sutures of different calibers and materials^{16,99,100}, and varying the pattern and depth of placement of the circumferential epitendon suture^{95,101-103}. While clinical attempts to

augment the repair site with onlay tendon grafts, patches, or synthetic materials have been disappointing because of the increased bulk of the repair site and poor ability to restore the gliding surface, recent *ex vivo* results suggest that this technique might warrant further investigation¹⁰⁴.

Ex vivo and *in vivo* investigations employing linear, *in situ*, and other models have suggested that core-suture configurations have the greatest tensile strength when there are multiple sites of tendon-suture interaction^{25,85,105-110}. Although the Kessler and modified Kessler techniques still enjoy widespread acceptance², newer techniques, such as the Tajima^{111,112}, Strickland^{28,31,48,112}, cruciate^{81,83}, Becker^{26,28,31,108,109}, and Savage^{33,36,85,87,94,112} configurations, all offer greater suture "hold" on the tendon that is independent of the suture knot. These modern core-suture techniques have been shown to offer greater tensile strength of the repair site not only at time-zero, but also for as long as six weeks postoperatively^{25,33,110}. However, a significant relationship between the cross-sectional area of the tendon and the suture "hold" on the tendon stump has not been proven²⁴.

It is well accepted that core-suture techniques utilizing a greater number of suture strands across the repair site result in a greater tensile strength than do those utilizing a similar pattern but fewer sutures across the repair site^{27,33,93,98}. This has been found to be true in both *ex vivo* time-zero studies and *in vivo* studies for up to six weeks postoperatively. Numerous studies involving commonly used core-suture techniques have demonstrated the superiority of the four-strand core suture over the two-strand core suture as well as greater strengths achieved with both the six and the eight-strand core-suture techniques. The factor limiting more widespread use of modern multistrand suture techniques remains the surgeon's ability to perform the repair while minimizing trauma to the tendon stumps and the circumferential visceral epitendon. While several investigators have evaluated the effect of sutures with different material proper-

ties (the caliber and the composition of the core suture itself)^{16,98,100}, most surgeons use semiresorbable sutures of $\geq 4-0$ caliber.

Other variables relevant to core-suture placement that have a positive effect on the time-zero tensile strength of the repair site include a dorsovascular location of the core suture, the cross-sectional area of tendon that is grasped or locked by the redirecting loop of suture, and the number of times that the tendon is grasped by the suture. Studies of an *ex vivo* human model have shown that greater time-zero strength is achieved with a more dorsal placement of the core suture within the tendon stumps^{31,35,113}.

The effect of a more dorsal suture placement on the vascularity of the intrasynovial flexor tendon, especially in the areas where the vinculum enters the tendon, is not known. *Ex vivo* studies have suggested that both positioning the redirecting loop of the core suture to "lock" rather than "grasp" the tendon stumps and increasing the number of locks or grasps provide greater time-zero tensile strength of the repair site¹¹⁴⁻¹¹⁶. Placement of the suture knot either within or away from the repair site has not been shown conclusively to affect tensile strength^{16,117,118}. Use of a greater quantity of suture within the repair site may increase the bulk of the repair site and decrease tendon glide, whereas placement of the knot away from the repair site may also affect tendon glide detrimentally because of increased friction between the tendon and sheath proximal or distal to the repair site. Techniques that do not require the tying of intrasynovial sutures have not gained acceptance¹¹⁹.

Hand surgeons have also attempted to increase the strength of the repair site by altering the configuration of circumferential epitendinous suture. Several studies have suggested that a circumferential epitendinous suture passed multiple times across the repair site provides a significant and clinically relevant component of time-zero strength^{95,101}. However, most investigations have suggested that while the epitendinous suture does increase time-zero and early postoperative

tensile strength, it cannot be relied on to provide the majority of the strength. It has been shown that the role of the epitendinous suture, regardless of its configuration, is twofold: first, it decreases the bulk of the repair site by smoothing out the surface of the tendon stump and, second, it increases the tensile strength of the repair site. Authors of recent studies of core-suture biomechanics and in vivo clinical and experimental studies of tendon force in both canines and humans have recommended a four-strand core-suture technique supplemented by a running epitendinous suture to achieve sufficient tensile strength of the repair site that will allow postoperative passive-motion rehabilitation to proceed without substantial risk of gap formation at the repair site.

Whereas modern core and epitendinous suture techniques have achieved greater strength, the effect of small degrees of early dehiscence and gap formation at the repair site on tendon-healing and accrual of repair-site strength has been appreciated only recently²⁹. Previous investigators have posited that repair-site gaps are always accompanied by adhesions of the intrasynovial flexor tendons, decreased tendon glide, and digital stiffness^{95,120-122}. A recent in vivo canine study has refuted that assumption: it demonstrated that a repair-site gap of even greater than 3 mm is not correlated with intrasynovial adhesions or with a decreased arc of digital motion²⁹. While large gaps did not seem to affect tendon function (excursion), those that occurred during the first twenty-one days postoperatively were observed to have a significant negative effect ($p < 0.05$) on tendon structure—i.e., the accrual of tensile strength of the repair site. Tendons without a gap or with a gap of <3 mm in length had a significant increase in repair-site tensile strength between three and six weeks postoperatively, whereas those with a gap of >3 mm did not have significant accrual of repair-site strength. While the biological processes at work within larger repair-site gaps remain open to inves-

tigation, such gaps seen early in the postoperative period pose a greater risk of rupture as motion rehabilitation progresses after three weeks. Imaging modalities such as ultrasound, magnetic resonance imaging, and plain radiographs to determine the precise extent of repair-site gaps have yielded inconsistent results and thus are not yet applicable to the clinical situation⁷⁰.

Important strides have been made recently in the investigation of the biological processes taking place at the repair site during the early postoperative period. Increased synthesis of type-I-collagen mRNA and protein has been demonstrated within repair-site cells and cells within the adjacent epitenon early in the postoperative period^{38,123,124}. However, a recent study showed that neither the total amount nor the maturity of the collagen at the repair site increased significantly during the first six weeks postoperatively ($p < 0.05$)¹²⁵. The accrual of repair-site tensile strength demonstrated between three and six weeks postoperatively in tendons with a repair-site gap of <3 mm must be due to mechanisms other than increased synthesis or more rapid maturation of collagen at the repair site. Fibronectin, an abundant extracellular matrix protein involved in cell-matrix communication, as well as $\alpha_5\beta_1$ and $\alpha_3\beta_3$ integrins, cell-surface compounds involved in the binding of fibroblasts to extracellular matrix, are likewise upregulated during the early postoperative period¹²⁶⁻¹³⁰. Fibroblasts grown in culture have demonstrated responsiveness to externally applied stress at both a cellular and a molecular level⁴⁰⁻⁴³; however, the exact relationship between collagen and integrin synthesis and the accrual of tensile strength at the tendon repair site remains unknown. Upregulation of the synthesis of mRNA of angiogenic mediators has been demonstrated both within the flexor tendon repair site and in the surrounding epitenon, and it has been shown to precede temporally and to be distinct spatially from longitudinal blood-vessel growth both on the tendon surface and within the tendon substance^{38,45,47,57}. The cellular origin of these angiogenic mediators and their

role in blood-vessel ingrowth through the avascular region of the flexor tendon remain unknown. The identification of fibroblast responsiveness in culture to growth factors such as transforming growth factor-beta^{41,44,131} and insulin-like growth factor^{41,43,132-135} merits further investigation into their role in early tendon healing.

Rehabilitation

While much time, effort, and print have been devoted to the technical nuances of flexor tendon surgery, the average time spent in the operating room pales in comparison with the aggregate time spent in therapy by the typical patient. It is therefore important that attention be paid to the specifics of rehabilitation after flexor tendon surgery.

In the germinal years of hand surgery, repair of flexor tendon lacerations occurring in the intrasynovial sheath was looked upon with disdain; indeed, Bunnell had labeled this region of the hand “no-man’s land.”^{3,136} Over time, hand surgeons have learned that strong early repairs coupled with early motion therapy programs can yield not only good but often excellent results. Young and Harmon first described the concept of passive motion with use of elastic-band traction in 1960¹³⁷, but it became widespread after publication of the Louisville experience in 1977¹³⁸. Lister et al.¹³⁸ reported the results of 156 repairs of flexor tendon lacerations in sixty-eight patients. Rehabilitation was carried out with a controlled motion protocol consisting of use of an extension block splint combined with active digital extension and passive digital flexion achieved with use of rubber bands secured at the wrist and attached to the injured digit at the distal nail-plate. Eighty percent of the patients had a good or excellent result, which was a substantial improvement over previously published results. These data were among the first to demonstrate that primary repair of intrasynovial flexor tendons followed by rehabilitation could yield satisfactory functional results. The results of use of a modification of the rubber-band traction system used at the Hand Services at

Brooke Army Medical Center and Walter Reed Hospitals were presented in 1987¹³⁹. The Louisville protocol was modified further by the placement of a bar or pulley at the midpalmar level in order to improve the vector of pull; biomechanical studies at the Mayo Clinic¹⁴⁰ demonstrated that, with this change, flexion at both the distal and the proximal interphalangeal joints was greater than that achieved with the original Louisville splint and rehabilitation protocol. Further refinements over the past decade have led to the creation of a splint with a mobile joint at the wrist (a synergistic wrist splint), allowing greater intrasynovial tendon excursion to be achieved because of the tenodesis effect of wrist position on flexor tendon motion¹⁴¹⁻¹⁴³.

Duran and Houser¹⁴⁴ were early proponents of a passive-motion rehabilitation program. They determined, both by clinical observation and by experimental study, that 3 to 5 mm of excursion at the intrasynovial repair site was sufficient to prevent the development of intrasynovial adhesions. This degree of excursion was achieved postoperatively through a protocol of passive digital motion that was taught to the patients. This rehabilitation technique decreased the frequency of the flexion contractures of the proximal interphalangeal joints often seen with rubber-band protocols¹³⁸. This protocol was subsequently modified by one of us (J.W.S.), who used a dorsal blocking splint fabricated with the wrist in 20° of flexion, the metacarpophalangeal joints in 50° of flexion, and the interphalangeal joints in full extension. For the first three and one-half weeks postoperatively, the patient flexes and extends the proximal and distal interphalangeal joints and the entire digit twenty-five times daily within the confines of the dorsal blocking splint. At three and one-half weeks postoperatively, active digital flexion and extension is initiated, again within the confines of the dorsal blocking splint. Active motion exercises without the splint are initiated one week later, but the splint is worn when the patient is not exercising until five and one-half

weeks postoperatively. At that time, blocking exercises for both the proximal and the distal interphalangeal joint are initiated. While a variety of early motion protocols that advocate "place and hold," "light active," or "active" components have been described, there are conflicting reports^{145,146} regarding their success. The rates of repair-site ruptures with some early motion protocols have been reported to range between 5.7% and 46%^{145,146}.

Despite improvements in repair-site strength and in the understanding of repair-site biology, adhesions still frequently form between the tendon and the surrounding fibro-osseous sheath, resulting in digital stiffness and a decreased range of motion, following intrasynovial flexor tendon repair and rehabilitation. Recent *in vivo* studies have suggested that the formation of these restrictive intrasynovial adhesions both at the repair site and at remote sites between the tendon and sheath may be avoided by achievement of sufficient excursion of the intrasynovial tendons during passive-motion rehabilitation¹¹⁰. Recent canine studies have suggested that as little as 1.6 mm of such excursion may prevent formation of clinically relevant adhesions. Despite the experimental success of increasing excursion at the intrasynovial repair site during passive-motion rehabilitation, mechanical and pharmacological methods have been attempted in an effort to decrease the formation of intrasynovial adhesions. *In vivo* and *in vitro* studies have demonstrated beneficial effects of locally applied compounds such as a 5-fluorouracil (a mitotic inhibitor)¹⁴⁷⁻¹⁵¹ and hyaluronic acid (a lubricant)¹⁵²⁻¹⁵⁸ on tendon gliding; both compounds have been shown to increase tendon glide, decrease adhesion formation, and decrease the work of digital flexion. However, clinical application of these compounds has not been widespread because of the expense, potential side effects, and difficulty in obtaining and maintaining a high concentration of the substances. Placement of mechanical barriers between the tendon and sheath following primary repair of lacerations of intra-

synovial flexor tendons also has not gained acceptance¹⁵⁹.

In an effort to improve the strength of the repair sites of intrasynovial flexor tendons, investigators have advocated rehabilitation methods that apply increased levels of *in vivo* force across the repair. One of us (M.I.B.) and colleagues²⁵ recently performed a study in which 214 canine flexor digitorum profundus tendons were transected, repaired, and assigned to either a low-force (5-N) or a high-force (17-N) passive-motion rehabilitation regimen, as described by Lieber et al.^{141,142}. Tensile testing showed that increasing the level of applied force from 5 to 17 N did not accelerate the accrual of repair-site strength²⁵. That finding suggests that there should be a reexamination of the concept that increases in force produced by more vigorous mobilization protocols are beneficial to tendon healing.

Partial Tendon Lacerations

Multiple investigators have concluded that partial lacerations involving ≤60% of the tendon's cross-sectional area should not be repaired¹⁶⁰⁻¹⁶². That recommendation is supported by both *in vivo* and *ex vivo* biomechanical studies¹⁶⁰⁻¹⁶² that demonstrated that nonrepaired partial lacerations had a significantly higher ultimate load and stiffness than repaired tendons ($p < 0.05$). Several authors have reported an increased risk of triggering, entrapment, or rupture associated with lacerations involving >60% of the cross-sectional area of the tendon and have advocated surgical repair of those injuries^{161,163-167} even though physiologic loads may be tolerated by the tendon after laceration of ≤75%. Although it has been demonstrated that even experienced surgeons find it difficult to consistently and accurately estimate the percentage of an incomplete tendon laceration¹⁶⁸, we currently recommend tendon débridement for injuries involving ≤60% of the tendon's cross-sectional area. Injuries involving >60% of the tendon substance should be repaired with traditional core-suture methods supplemented by a running epitendinous suture.

Therapy for patients in whom an incompletely lacerated tendon has not undergone suture repair is similar to that for patients who have undergone tenolysis; studies have shown that tendons with an injury involving $\leq 70\%$ of the cross-sectional area can tolerate both passive and active range-of-motion rehabilitation programs^{163,169}. These injuries are frequently treated with a “place-and-hold” regimen or a “frayed-tendon” exercise program^{143,170-172} in order to maximize differential excursion between the flexor digitorum superficialis and flexor digitorum profundus tendons.

Repair and Reconstruction of the Flexor Sheath

The flexor sheath apparatus provides mechanical efficiency and a source of nutrition to the intrasynovial flexor tendon. Preservation of the crucial pulleys is imperative in order to minimize tendon bowstringing. Studies have demonstrated that the A2 and A4 pulleys are the most important for digital motion and the prevention of tendon bowstringing; therefore, these pulleys should be repaired or reconstructed if they are deficient^{52,173}.

Various methods of repair or reconstruction of the flexor pulleys have been described, including techniques using free tendon or retinacular grafts, the palmar plate, or the flexor digitorum superficialis tendon¹⁷⁴⁻¹⁷⁷. Bunnell¹⁷⁴ described the use of a free tendon graft for reconstruction of the A2 and A4 pulleys. For reconstruction of the A2 pulley, the graft is looped two or three times around the proximal phalanx and the flexor tendons, placed dorsal to the neurovascular bundles, and passed in the interval between the extensor tendon apparatus and the proximal phalanx. The graft is passed superficial to the extensor apparatus for reconstruction of the A4 pulley. Lister¹⁷⁶ reported a similar method of reconstruction, with use of an 8-cm section of the extensor retinaculum of the wrist. Other methods utilize free tendon grafts woven through the peripheral remnants of the flexor pulley system, the flexor digitorum superficialis tendon placed through drill holes in the proximal or

distal phalanx, or Karev's “belt-loop” reconstruction technique¹⁷⁵, which utilizes slips of the palmar plate to reconstruct the incompetent pulley or pulleys. In recent biomechanical studies, investigators have assessed the influence of donor graft and of graft tensioning on tendon gliding and functional outcomes¹⁷⁸⁻¹⁸².

While restoration of tendon sheath continuity may improve the healing environment, repair of the membranous portions of the sheath is technically difficult and may result in narrowing. This localized constriction and the increased width of the tendon repair site may impair tendon gliding and increase resistance to glide at the repair site. Investigators who have examined the influence of sheath repair have concluded that it does not substantially improve functional outcomes following repair of flexor tendon lacerations¹⁸³⁻¹⁸⁵. Studies of flexor sheath reconstruction by direct repair or by autogenous grafting at the time of primary tendon repair have demonstrated the proliferation of a new gliding surface, irrespective of reconstruction or excision of the sheath^{184,185}.

Presently available experimental and clinical data suggest that repair of an intrasynovial flexor tendon laceration should be performed within ten to fourteen days after injury and that the surgeons should use a core and epitendinous suture technique to create a repair site able to withstand gap formation of 3 mm during the first three weeks postoperatively. A passive-motion rehabilitation protocol emphasizing excursion at the intrasynovial repair site, rather than increased application of musculotendinous force across the repair site, should be utilized.

Free Tendon Grafts

When a flexor tendon divided in Zone I or Zone II has not been or cannot be directly repaired, tendon grafting must be carried out in order to restore digital flexion. Whether one uses a conventional free tendon graft or a staged reconstruction depends on several factors unique to the involved digit, including the extent and magnitude of scar for-

mation within the digital canal and the condition of the pulley system. In this section, we will consider the indications and techniques for conventional free tendon grafting.

Interruption of the Profundus and Superficialis

The first series in which free flexor tendon grafts were used in the hand was reported by Lexer in 1912^{65,186}. He used grafts to repair flexor tendons after rupture, old lacerations, infections, and “hopeless cases” of ischemic contracture¹⁸⁶. In 1916, Mayer authored three articles that have served as the basis for the present-day concepts of flexor tendon surgery¹⁸⁷⁻¹⁸⁹. He emphasized the need for an exacting operative technique, with direct juncture of the tendon to bone and use of an adequate muscle as a motor, and the necessity for peritenon around a flexor graft.

In 1918, in a classic article on tendon grafting, Bunnell stressed atraumatic technique, a bloodless field, perfect asepsis, and preservation of pulleys¹⁷⁴. He preferred the palmaris longus tendon as the donor graft and described a modified cork borer that could be used as a tendon stripper¹⁷⁴. Mason and Allen carried out experiments in 1941 that indicated that tendon grafts should not be moved for twenty-one to twenty-five days¹⁹⁰. In the first edition of his classic textbook on surgery of the hand in 1944, Bunnell³ described the pullout wire suture technique, the success of which was confirmed by Moberg¹⁹¹ in 1951.

The surgical methods and results of free flexor tendon grafting have subsequently been modified and reviewed by various leaders in the field of hand surgery, including Pulvertaft¹⁹²⁻¹⁹⁴ in England; Graham¹⁹⁵, Littler¹⁹⁶, Boyes and Stark¹⁹⁷, and White^{198,199} in the United States; and Rank and Wakefield²⁰⁰ in Australia. Important contributions have also been made by Verdan¹ in Switzerland and Tubiana^{201,202} in France. While few advances in tendon grafting have occurred in recent years, Boyes and Stark¹⁹⁷ and McClinton et al.²⁰³ presented notable reviews of large clinical series and reported that good results had been obtained by

grafting through an intact flexor digitorum superficialis for the treatment of isolated loss of the profundus.

Indications

The indications for conventional free tendon grafting have been well established. Pulvertaft¹⁹⁴ stated that results of the standard grafting method will be successful when:

- “The hand is in good overall condition. There is no extensive scarring. Passive movements are full or nearly full. The circulation is satisfactory. At least one digital nerve in the affected digit is intact.”

- “A precise and gentle surgical technique is used.”

- “The patient is cooperative. A child under 3 years of age is unlikely to assist in the aftercare and it is wise to postpone the operation until the child is older.”

Schneider and Hunter²⁰⁴ emphasized that the surgeon must decide whether a conventional free tendon graft or a staged reconstruction is more appropriate in a particular situation. In some patients in whom primary repair or previous efforts at flexor tendon reconstruction have failed, the degree of scarring within the digit may preclude the realistic possibility of achieving a good result from free grafting. In these instances, a staged reconstruction may be more appropriate. Tubiana²⁰² detailed the principles of flexor tendon grafting, stating that only one graft should be placed in one finger, an intact superficialis tendon is never sacrificed, the graft should be of small caliber, and its ends should be fixed away from the tendon sheath. Tubiana also recommended careful calculation of the tension of the graft and sparing of at least one pulley to prevent bowstringing.

Although primary or delayed primary repair has become the standard mode of treatment of acute severance of flexor tendons, free tendon grafting is applicable in patients who, for one reason or another, have not had a timely repair. In such patients, the severed tendon stumps are removed from the digital flexor sheath and replaced with a palm-to-distal phalanx graft. Almost

all tendon surgeons agree that the procedure is applicable in patients over five years of age following clean, sharp severance of the flexor tendon. The wound should be well healed with a minimum of inflammatory reaction, and the digit should be supple and free from swelling. A full range of passive motion should be achieved prior to the procedure, and at least one and preferably both digital nerves should be functional. The patient should be well motivated and informed about the rather rigorous postoperative therapy that will be necessary.

Free tendon grafting is usually not appropriate for digits with a fixed joint contracture or a severe phalangeal fracture. Crushing injuries or wounds with substantial skin loss usually result in considerable scarring in or around the flexor tendon sheath, and the results of free tendon grafting can be expected to be markedly compromised in such a situation. The procedure is contraindicated for insensate or poorly vascularized digits, for children below the age of three years, and for elderly patients²⁰⁵. In some instances, it will be difficult for the surgeon to assess the amount of fibrosis within the digit or the condition of the pulley system prior to the operative procedure. The patient should be prepared for the possibility that, should the findings at surgery mitigate against free tendon grafting, a staged flexor tendon reconstruction will be necessary.

While many surgeons, including Bunnell^{3,174}, recommended excision of the majority of the flexor tendon sheath with retention of only small sections of the annular pulleys, it is now believed that one should strive to preserve as much of the sheath system as possible. Eiken et al.²⁰⁶ even suggested transplanting synovial tissue from the toes or wrists as a sheath autograft in order to close open sections of the fibro-osseous canal. We have seen that the wholesale ablation of sections of the flexor tendon sheath may have a detrimental effect on the efficiency of flexor tendons and it is important to preserve the majority of the A2 and A4 annular pulleys. Reconstruction of pulleys at the time of free tendon grafting is rarely advisable

and, in most instances, the finding of a deficient pulley system should serve as an indication to proceed with staged reconstruction.

Donor Tendons

Although there is some disagreement about which donor tendon should be chosen for free flexor tendon grafting, the palmaris longus, when available, probably has the most advocates. This tendon is present in approximately 85% of all individuals²⁰⁷, is of sufficient length and size, and is easily procured from the ipsilateral forearm through small incisions and gentle traction or the use of a tendon stripper. The plantaris tendon may also serve as a satisfactory graft, particularly when graft length is important. It is said to be present in about 93% of all individuals²⁰⁸, although personal experience indicates that it is present less frequently. The plantaris tendon is usually 12 to 18 cm in length and may be garnered through an incision medial to the Achilles tendon and the use of a Brand tubular tendon stripper. Other tendons that may be employed as grafts include the extensor digitorum longus tendons to the second, third, and fourth toes; the extensor indicis proprius; the extensor digiti quinti proprius; and the flexor digitorum superficialis tendon to the small finger¹⁹⁹. The use of intrasynovial grafts has been advocated by Noguchi et al.²⁰⁹ and Ark et al.²¹⁰, and the science behind their recommendations is compelling. However, clinical evidence of the superiority of these grafts is still necessary before they are commonly used for these procedures.

Either the zigzag palmar incision advocated by Bruner^{66,67,211} or the midaxial approach favored by many surgeons^{3,197,200,201,204,212-216} can be used for flexor tendon grafting. The latter approach has the advantages of placing the scar away from the area of grafting and providing a healthy bed of subcutaneous tissue over the sheath and graft. Continuous digital-palmar incisions, as recommended by Tubiana²⁰¹, provide wide exposure of the flexor tendon system from the midpart of the palm to the digital tip. Attempting to work

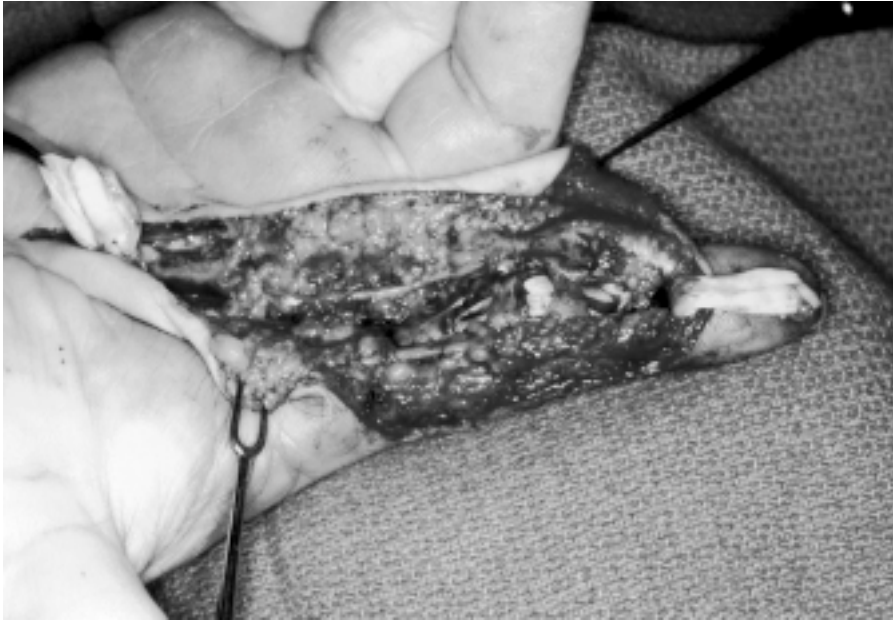

Fig. 2

Surgical approach to the index finger, involving a radial midaxial incision turned across the distal part of the palm to parallel the thenar crease. The photograph shows the appearance of the flexor tendon bed following resection of mid-digital scar tissue with reflection of the proximal and distal profundus stumps.

through small incisions with limited exposure almost always necessitates blind dissection, which may endanger neurovascular structures and increase formation of postoperative adhesions.

Surgical Technique

Some surgeons prefer the midaxial approach to the digit with use of the method of Rank and Wakefield^{215,216}, in which the neurovascular bundle is left in its dorsal position and the flap is elevated across the flexor tendon sheath. This incision, however, cannot be used if a zigzag approach had been previously employed. The neurovascular bundles must be carefully identified and protected, and dissection is carried from areas of normal anatomy toward the area of injury in order to provide the best identification of the tendon sheath with a minimum of additional injury. The annular portions of the sheath should be carefully preserved, but, if they have collapsed, they may often be expanded by the use of pediatric urethral dilator sounds (Fig. 2).

Small windows are fashioned in the cruciate-synovial areas of the sheath in order to identify the proximal and

distal tendon stumps, and the distal stump of the profundus is mobilized. One centimeter of the profundus stump is preserved and is reflected to its insertion in the distal phalanx. The profundus and superficialis stumps are withdrawn proximally if they still re-

side in the flexor sheath or they are identified in the midpart of the palm, where their ends will have enlarged. Distal traction may then be placed on the profundus tendon for several minutes to improve its excursion⁶⁸. The bulbous profundus stump is trimmed back to good tendon, and the lumbrical muscle is excised if it is scarred or adherent. The superficialis tendon is pulled forward and cut so that it will retract well away from the proximal graft juncture.

Whatever scar tissue is found at the site of the original injury is then meticulously excised. If the scar proves to be excessive or if a great deal of the pulley system has been lost, it may be better to proceed with a staged reconstruction by implanting a silicone rod and reconstructing annular pulleys. It is also recommended that the distal portion of the superficial flexor be preserved to prevent recurvatum at the proximal interphalangeal joint, particularly when it has not been badly scarred by the initial injury.

Following preparation of the nail bed, a heavy suture is placed beneath the intact portions of the sheath by using a small blunt probe, and an oblique drill hole is fashioned in the base of the distal phalanx, with the point of the drill directed from proximal-palmar to distal-

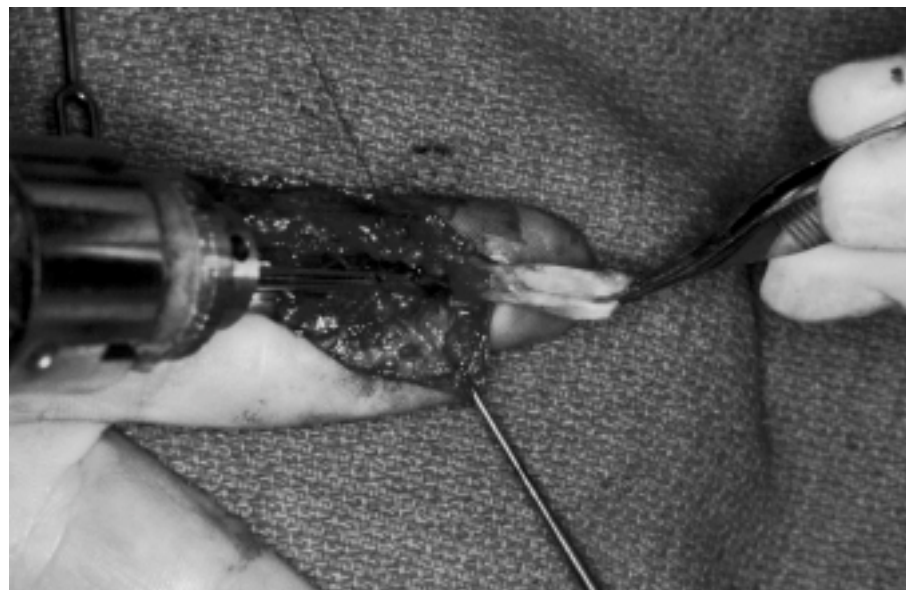

Fig. 3

A drill point passed just proximal to the insertion of the profundus tendon in the base of the distal phalanx.

dorsal (Fig. 3). The surgeon should try to minimize dorsal cortical penetration by placing a finger over the proximal nail bed during the drilling process.

When the digital bed has been prepared, the donor tendon is procured. One of us (J.W.S.) prefers to use the palmaris longus when it is present (Fig. 4). It is garnered with a transverse incision just proximal to the wrist, through which the distal part of the tendon can be easily identified. A small hemostat is placed beneath the tendon to increase its tension and to allow the tendon to be palpated in the midpart of the forearm. A short transverse incision is then made directly over the tendon, and dissection is carried down to the proximal portion of the palmaris, which is easily withdrawn after it has been divided distally and freed of its attachments.

A 4-0 monofilament suture, armed at each end with a straight needle, is passed twice through the distal end of the suspended graft, and an addi-

tional 4-0 suture is placed in the tendon prior to its release. The proximal end of the graft suture is tied to the distal end of the suture in the digital bed, and the tendon can then be easily drawn from distal to proximal beneath the intact portions of the tendon sheath. The straight needles are then passed through the distal phalangeal drill hole and will usually exit over the proximal portion of the nail. The needles are taken through a gauze pad or a Kitner sponge and through the holes of a button. Distal traction on the suture will pull the tendon graft into the osseous defect in the distal phalanx, and the suture may be tied over the button to anchor the graft. Additional sutures are used to secure the profundus stump to the graft, and proximal traction on the graft should demonstrate its excursion and produce full digital flexion (Fig. 5).

All wounds are closed, and the proximal juncture of the graft to the profundus motor tendon is completed

in the palm. A Pulvertaft^{192,193,217} tendon weave is excellent for the proximal juncture and allows careful adjustment of the tension of the graft. When the calibers of the tendons are the same, one may prefer an end-to-end suture rather than the weave technique. Most surgeons agree that the tension placed on a tendon graft should result in a resting posture of the grafted digit that is slightly more flexed than it would be under normal circumstances. This is best achieved by placing the wrist in neutral and observing the posture of the adjacent digits. In general, the posture of the grafted digit should be about the same as that of the adjacent ulnar digit. For the small finger, a position of flexion somewhat greater than that of the contralateral small finger is appropriate. At the conclusion of the proximal tendon repair, the digit is checked to be sure that it can be passively extended with the wrist in neutral.

Obviously, certain variations in this technique may be appropriate in unique circumstances. The use of a drill hole at the base of the distal phalanx is not appropriate in children with open epiphyses; in such cases, direct tendon suture to the stump of the profundus is preferable. When a palmaris longus tendon is not present, the plantaris, the superficialis tendon of the small finger, or one of the proprius tendons may be selected; the toe extensors should be reserved for rare situations in which no other donor tendons are available. In some instances, it is preferable to use the superficialis muscle as a motor for the tendon graft, particularly when it is less scarred than the profundus.

Postoperative Care

Most surgeons are much more reluctant to utilize early motion programs following grafting than they are following flexor tendon repair. It is generally believed that flexor tendon grafts should be immobilized for at least three weeks in order to avoid tension on the suture and to allow for revascularization²⁰³. Immobilization should be in a position midway between neutral and full wrist flexion, with the metacarpophalangeal joints flexed to 60° or 70° and the inter-

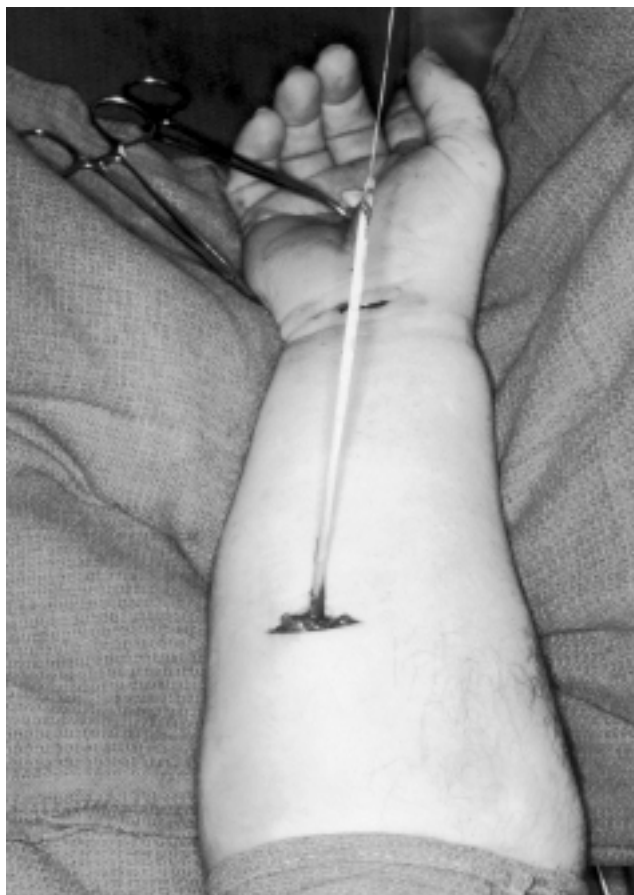

Fig. 4
The palmaris longus tendon has been withdrawn in the midpart of the forearm with use of two transverse incisions.

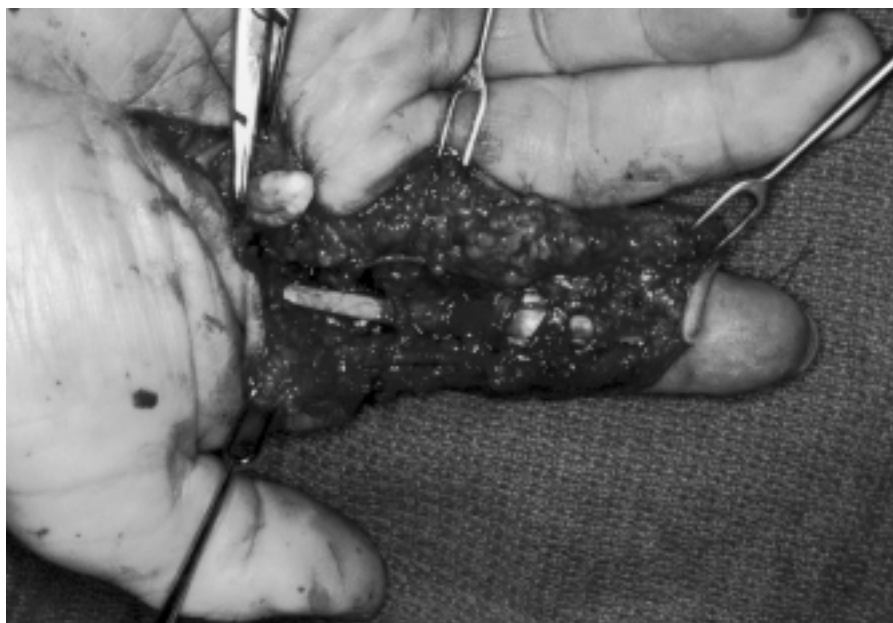

Fig. 5
The appearance of the digital bed following completion of the distal tendon-bone insertion and suturing of the distal profundus stump to the graft.

phalangeal joints held in nearly full extension. This position relieves tension on the repair site and provides the best safeguard against the development of flexion contractures of the interphalangeal joints. At three to four weeks, a gentle protected-motion program that includes passive and active digital flexion and active digital extension is initiated. Full passive extension of the digit is not permitted for several additional weeks.

Intact Superficialis

The late treatment of a division or rupture of the flexor digitorum profundus with an intact superficialis tendon is controversial. If the patient has full, strong function of the superficialis, the functional impairment of the involved digit may not be great. Since there is a risk that tendon grafting will compromise existing function, many surgeons use a conservative approach in this situation, preferring no treatment, or tenodesis or arthrodesis of the distal interphalangeal joint, to free grafting²¹⁸⁻²²⁴. Other surgeons have achieved satisfactory results with tendon grafting through an intact superficialis, with varying indications in carefully selected patients²²⁵⁻²³². Treatment of iso-

lated loss of the profundus with use of a tendon implant as a first stage and grafting as a second stage was advocated by Versaci²³² and by Wilson et al.²³³.

Although generally in favor of

free grafting for the treatment of profundus division in selected patients, Pulvertaft stated that "it should not be advised unless the patient is determined to seek perfection and the surgeon is confident of his ability to offer a reasonable expectation of success without risk of doing harm."²²⁹ He further noted that the decision regarding whether to use a graft in such circumstances depends on a number of factors, including the age, occupation, and wishes of the patient and the condition of the finger and hand. He recommended tendon grafting for the index and long fingers but thought that the procedure was appropriate in the ring and small fingers only when the patient required the action of those fingers because of a special interest or occupation, such as a musician or skilled technician.

Pulvertaft later changed his thinking and agreed that free tendon grafting is often worthwhile in the small finger, particularly when the superficialis tendon is weak, because of the improvement in grip provided by the restoration of profundus function. He favored the use of the plantaris tendon in such circumstances.²³¹

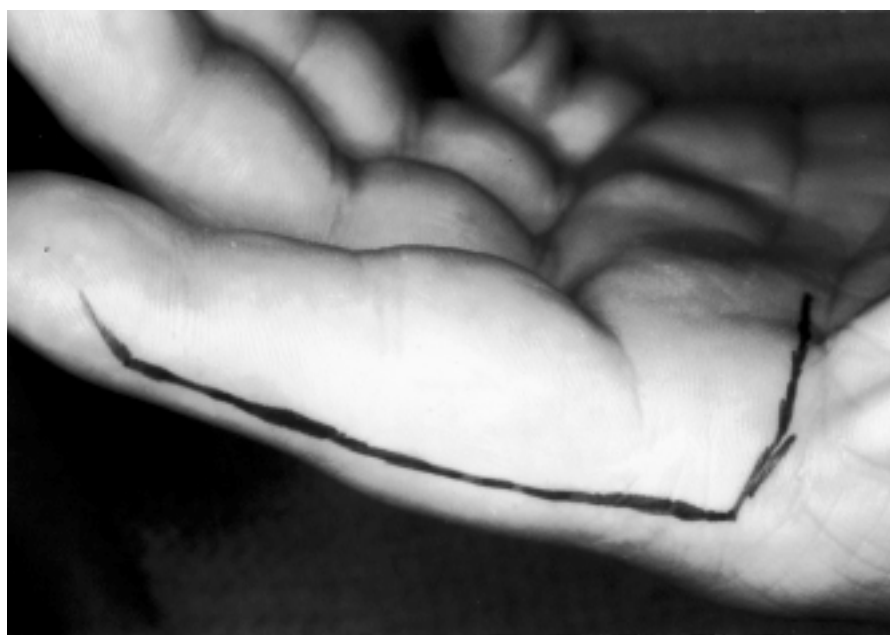

Fig. 6
A long midlateral incision on the radial aspect of the index finger. The incision continues across the palm at the level of the distal palmar crease and can be turned proximally to gain the required palmar exposure of the flexor system.

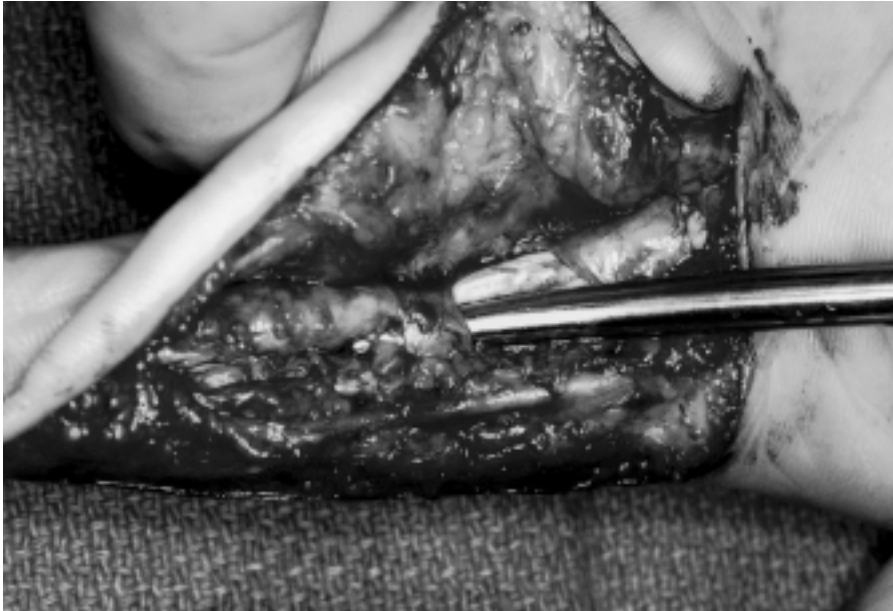

Fig. 7

The appearance of the flexor tendons following tenolysis with maintenance of three annular pulleys. (Reprinted, with permission, from: Strickland JW. Flexor tenolysis. *Hand Clin.* 1985;1:121-32.)

thought that the prerequisites for grafting in a digit with an intact superficialis tendon include a normal superficialis tendon, full passive motion, minimal soft-tissue scarring, and a patient between ten and twenty-one years of age.

The procedure should probably be reserved for the few patients who have specific functional needs or a strong desire for the restoration of profundus function. While a young age is not an absolute requirement, the majority of our patients have been less than twenty-five years old. Finally, the procedure should be carried out only after a thorough and honest discussion with the patient about the details of the procedure and its possible complications.

Surgical Technique

The technique for free flexor tendon grafting in a digit with an intact superficialis is similar to that used following the loss of both the profundus and the superficialis. Obviously, one should take great care to avoid any damage to the normal superficialis or its decussation. The palmaris and plantaris tendons are the best donor tendons for this type of grafting because of their small

size. The graft should be gently passed through the decussation of the superficialis in an effort to restore its normal anatomic position.

When the chiasm has been closed

and it is not possible to pass the graft between the superficialis slips, it may be passed around them. The distal and proximal graft junctures are the same as those described for treatment of a combined tendon loss. While some authors have suggested that motion may be commenced earlier following grafting through an intact superficialis²³⁰, our practice is to immobilize the involved hand for three and one-half weeks before permitting motion.

Flexor Tenolysis

Despite our best efforts at flexor tendon repair, free tendon grafting, or staged reconstruction, adhesion formation with restriction of tendon excursion occurs all too frequently. When satisfactory function cannot be restored, it may be necessary to proceed with tenolysis in an effort to improve tendon movement. The biological basis and clinical efficacy of this procedure have been questioned by some authors^{3,216,234,235}, whereas others have indicated that, when carried out properly, it is a worthwhile effort at restoring digital function^{77,136,204,236-241}. Tenolysis must always be approached as a major surgi-

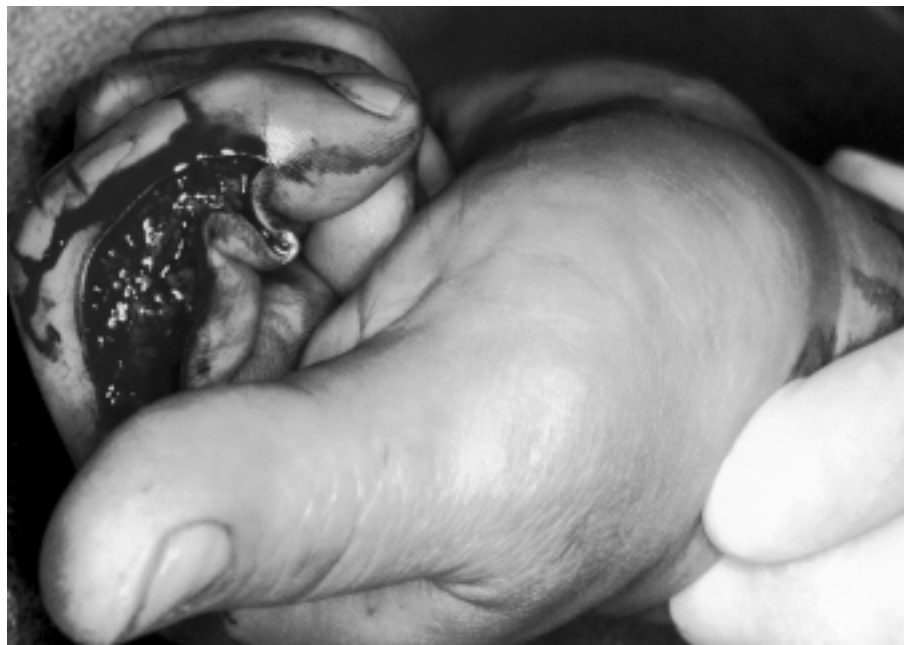

Fig. 8

At the conclusion of the procedure, complete release of all restraining adhesions is confirmed either by a proximal "traction check" through a separate wrist incision or preferably by the active participation of the patient under local anesthesia, as shown.

cal effort, with careful patient selection and great attention to the details of the operative procedure and the postoperative mobilization program. Tenolysis is probably the most demanding of all flexor tendon procedures and, in order to be successful, there must be close cooperation among the patient, the physician, and the therapist.

Preoperative Considerations

Indications

Tenolysis may be indicated following flexor tendon repair or grafting when the passive range of digital flexion substantially exceeds active flexion. The decision to carry out the procedure should be based on serial joint measurements indicating no appreciable improvement for several months despite a vigorous therapy program and conscientious efforts by the patient.

The prerequisites for tenolysis as set forth by Fetrow¹³⁶, Hunter et al.²³⁷, and Schneider and Hunter²³⁸ should be closely adhered to. All fractures should have healed, and wounds must have reached "equilibrium" with soft, pliable skin and subcutaneous tissues and minimal reaction around scars. Joint contractures must have been mobilized, and there must be a normal or nearly normal passive range of digital motion. Satisfactory sensation and muscle strength should have been regained, and the patient must be carefully informed about the objectives, surgical techniques, postoperative course, and pitfalls of the procedure. Many patients will be content with less than normal active digital motion. However, others who have regained a fairly good range may desire nearly normal function, and, in most circumstances, they should be offered the operation. When a patient elects to undergo tenolysis, he or she must understand that, if the findings at surgery preclude the possibility of regaining satisfactory function, it may be necessary to proceed with the implantation of a silicone rod as the first step of a staged flexor tendon reconstruction.

Timing

The proper timing of tenolysis following tendon repair or grafting is somewhat

controversial. Wray et al.²⁴² concluded, from an experiment on chicken tendons, that waiting twelve weeks appears to be optimum, as the tendon does not weaken in that time and the blood supply increases. Fetrow¹³⁶ and Pulvertaft²¹⁷ recommended waiting three months following primary tendon repair and six months following flexor tendon grafting before performing tenolysis. Rank et al.²¹⁶ advocated waiting six to nine months following tendon grafting for patients in whom serial examinations had revealed no substantial improvement. It is now generally accepted that tenolysis may be considered three months or more after repair or grafting, provided that the other criteria for the procedure have been satisfied and there has been no measurable improvement in active motion during the preceding four to eight weeks.

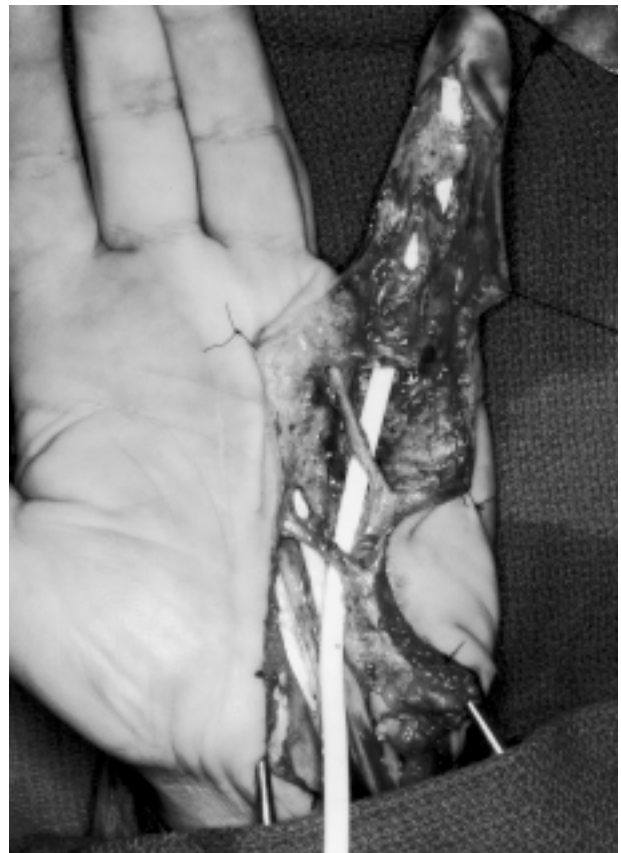Operative Considerations

Anesthesia and Tourniquet

Schneider, Hunter, and associates popularized the use of local anesthesia sup-

plemented by intravenous analgesia and tranquilizing drugs for tenolysis^{237,238,243-245}. They contended that this method best allows the patient to demonstrate the completeness of the lysis by actively flexing the involved digit during surgery. They also believed that it is important to allow the patient to observe the improved digital motion during surgery in order to provide motivation for the maintenance of that motion during the rigorous postoperative therapy program. Most surgeons now agree that the advantages of local anesthesia and active patient participation are enormous and recommend the use of this technique whenever possible²³⁹. However, this type of local and supplementary anesthesia may not be appropriate for patients who are young or uncooperative, who have a low pain threshold, or for whom extensive surgery is anticipated. It then becomes the responsibility of the surgeon to demonstrate that a thorough release of all restraining adhesions has been achieved by the tenolysis procedure.

Fig. 9
A silicone tendon implant in a small finger during stage one of a two-stage flexor tendon reconstruction for functional salvage.



It must be remembered that, while the use of local anesthesia permits immediate evaluation of the effectiveness of the tenolysis, tourniquet ischemia will result in muscle paralysis in approximately thirty minutes, and, although the active function returns after the tourniquet release, this delay is a surgical inconvenience²⁴². In addition, the tourniquet may not be well tolerated after twenty to forty minutes, depending on the effectiveness of the supplementary analgesia. Application of a sterile pediatric tourniquet to the midpart of the forearm has proved to be an effective method of dealing with the problems of muscle paralysis and tourniquet-induced pain. During the procedure, the tourniquet on the midpart of the forearm may be inflated secondarily, allowing deflation of the tourniquet on the upper arm²³⁹. Hemostasis is preserved, tourniquet-induced pain is minimized, and the function of the extrinsic forearm flexors can usually be restored following their revascularization. At the time of dressing application, the proximal tourniquet can be reinflated and the pediatric tourniquet can be removed.

The local anesthetic agent is chosen by the surgeon. Use of 1% or 2% lidocaine was advocated by Hunter et al.²³⁷ and Schneider and Hunter²³⁸; 0.5% bupivacaine (Marcaine) is also a useful agent for tenolysis because it is effective for a long duration (ten to fourteen hours), which minimizes immediate postoperative pain. Anesthesia administered by infiltration into the skin and subcutaneous tissues at the base of the finger is usually combined with a transmetacarpal digital block. The extent of the palmar dissection is anticipated at the time of injection, and when more than one finger is to undergo tenolysis or when extensive wrist-palm-digit exploration is likely, one may elect to use a wrist block. It should be remembered that this type of regional anesthetic will result in paralysis of the intrinsic muscles and, to some extent, compromise the patient's ability to demonstrate normal digital kinetics following tenolysis^{237,246,247}. Nonetheless, wrist block anesthesia still permits full function of the

extrinsic flexor system and is an excellent alternative to direct palmar injection in certain circumstances.

Although Hunter et al.^{237,246,247} stated a preference for the supplementary use of fentanyl-droperidol (Innovar) for analgesia and sedation during tenolysis, other agents such as diazepam (Valium) may be effectively substituted when the anesthesiologist is unfamiliar with or reluctant to use that drug combination^{237,239}. Whether the procedure is carried out with the patient under local, regional, or general anesthesia, it is important that the condition and comfort level of the patient be carefully monitored by an anesthesiologist throughout the procedure.

Surgical Technique

Flexor tenolysis requires wide surgical exposure. As with other digital procedures, either the midlateral or the Bruner⁶⁶ zigzag incision can be used. Hunter et al. preferred the zigzag approach, believing that it provides the best exposure of the tendon anatomy and allows lysis of the adherent structures under direct visualization^{237,246,247}. They also believed that this approach best preserves the vascular nutrition of the digits that have been injured or have had previous surgical procedures. Other surgeons prefer a midlateral incision, as described by Rank et al.²¹⁶, in which the neurovascular bundles are left dorsalward²³⁹ (Fig. 6). The advantages of this approach are that a good bed of soft tissue will usually be delivered back across the flexor tendons and sheath and less wound tension will be produced by early postoperative digital motion.

Despite Verdan's earlier recommendation that sheaths be widely excised at the time of tenolysis²⁴⁸, most surgeons now prefer to preserve as much of the pulley system as possible²³⁹. If portions of the pulley system have been damaged by injury or previous surgery, the forces acting on the smaller remaining pulleys during active flexion will be much greater, with an increase in the potential for pulley rupture. It is therefore imperative to make every effort to maintain the major portion of each of the annular pulleys.

Tenolysis is often a laborious procedure requiring meticulous division of all limiting adhesions and great care to define the borders of the flexor tendons. When possible, the profundus and superficialis tendons are separated to retain a two-tendon system. In some instances, however, this cannot be done, and a single combined tendon is created and is mobilized to its insertion. The judicious use of small knife blades and elevators may help the surgeon to extricate the tendons from their scarred beds on the floor of the fibro-osseous canal and to divide connections to the annular pulleys (Fig. 7). On occasion, small pediatric urethral dilators may be employed to gently expand annular pulleys.

When the procedure is carried out with the patient under local anesthesia, it should be possible to periodically ask the patient to actively flex the involved finger in order to determine the adequacy of the lysis. Occasionally, this motion will rupture a few remaining adhesions and permit full excursion of the lysed tendon. At approximately thirty minutes, tourniquet paralysis will preclude the ability of the patient to actively flex the digit. At this point, the sterile pediatric tourniquet applied to the midpart of the forearm can be inflated, and the tourniquet on the upper arm can be released. Voluntary muscle function will be restored, and the discomfort that had been caused by the proximal tourniquet will be relieved.

Dissection is continued until the adequacy of the release is demonstrated by the patient actively flexing the digit (Fig. 8) or by the surgeon performing a gentle proximal "traction check" in the palm. If the patient can fully flex the digit and an adequate pulley system has been preserved, the wound is closed and the dressing is applied. If annular pulleys are absent, attenuated, or inadequate, they must be rebuilt. The use of tendons passed circumferentially around the phalanges, as described by Bunnell³, is probably the most reliable method of pulley restoration during tenolysis. Pulleys may be protected by circumferential digital taping, and their restoration should not substantially alter the postoperative regimen.

Schneider and Hunter emphasized the importance of critically assessing the quality of the flexor tendons at the time of surgery²³⁸. If 30% of the tendon width has been lost or if the continuity of the tendon is through a small segment of scar tissue, it is questionable whether tenolysis should be carried out. When the quality of the tendon is seriously in doubt, it may be better to proceed with a staged reconstruction with use of an active or passive Hunter tendon implant. When the tendon quality is marginal, the final decision regarding whether to proceed with lysis is ultimately left to the discretion of the individual surgeon. Fortunately, there are methods of minimizing tensile loading of the lysed tendons while preserving their excursion during the early postoperative therapy period, as will be described in the Postoperative Considerations section. In certain circumstances, it may even be possible to combine the procedures by placing a Hunter tendon implant beneath the lysed tendon from the base of the distal phalanx to either the palm or the distal part of the forearm, as suggested by Cannon and one of us (J.W.S.)¹⁴³. The silicone rod may then serve as both an underlay for the tendon and a potential first-stage reconstruction if tendon rupture should occur.

When necessary, capsulectomy may be combined with flexor tenolysis. The capsulectomy usually involves resection of scar tissue or tightened checkrein extensions of the palmar plate at the level of the proximal interphalangeal joint. It should be emphasized, however, that every effort should be made to achieve full passive motion of the digital joint before surgery since concomitant lysis of tendons and joint release can adversely affect the final result.

Various mechanical barriers have been used to limit the reformation of peritendinous adhesions following tenolysis. There are conflicting opinions regarding the usefulness of these materials. Boyes²⁴⁹ advocated silicone inlays in certain instances, and Bunnell³, Fetrow¹³⁶, and Verdan²⁴⁸ reported satisfactory results with peritenon and fascial inlays. Bora et al.²⁵⁰ reviewed the

results of the use of fascia, vein, and cellophane around tenorrhaphy sites. They stated that these materials failed to prevent the reformation of adhesions and, in fact, acted as foreign bodies, promoting additional scarring as well as obstructing the revascularization process. At present, the most common indication for silicone interposition is a previous tenolysis when reformation of adhering scar tissue over a long distance seems to be inevitable²³⁹.

The use of steroid preparations in an effort to modify the quality and quantity of tendon adhesions following tenolysis has provoked considerable debate. Wrenn et al.²⁵¹, Rank et al.²¹⁶, Carstam²⁵², James²⁵³, and Whitaker et al.²⁴¹ indicated that locally instilled cortisone drugs may be of some value. Conversely, Fetrow¹³⁶, Brooks²³⁴, and Verdan et al.^{248,254} believed that they do not improve the results of tenolysis. The adhesion-limiting property of triamcinolone, as demonstrated by Ketchum²⁵⁵, suggests that this drug is a logical adjunct for the preservation of tendon gliding. It is probably best to reserve the use of this medication for patients who have shown a propensity for rapid and aggressive reformation of scar tissue or for those who are undergoing repeat lysis. In such instances, several milliliters of triamcinolone may be locally administered at the time of wound closure. One should be wary of the possibility of delayed wound-healing or infection when steroids are used in conjunction with this procedure.

Hunter et al.^{237,246,247} reported on the use of an indwelling polyethylene catheter to allow periodic administration of bupivacaine in an effort to provide postoperative pain relief during the first few days of post-tenolysis therapy. While this procedure is sometimes beneficial for patients with a low pain threshold or following extensive surgical procedures, it is rarely necessary for more routine procedures after which pain is not a major problem. The use of oral analgesics and a transcutaneous nerve stimulator are usually effective for controlling discomfort and obviate the need for an indwelling catheter with its attendant risk of inoculating the wound

with infectious organisms.

At the conclusion of surgery, a large compressive dressing is applied and one may elect to splint the digit in a position of flexion¹⁴³ because patients usually have much less difficulty bringing the finger from a flexed to an extended position. This motion also produces an obligatory gliding of the lysed tendon, which is more effective than that produced by passively flexing the digit.

Postoperative Considerations

Although some authors have advocated immediate motion following flexor tenolysis^{230,236,238,239,241,254}, others have recommended starting therapy as soon as soft-tissue healing permits it²⁵⁵. The rapid formation of new adhesions can probably be discouraged by methods that produce early tendon movement. Immediate motion compatible with wound-healing is desirable. It is probably best to initiate digital motion within the first twelve hours following flexor tenolysis whenever possible¹⁴³.

Before initiating a postoperative therapy program, one must carefully consider many factors pertaining to the specific clinical situation. The surgeon and therapist should have direct communication regarding the patient's history, previous surgery, and preoperative status as well as the condition of the tendon and the status of the pulley system. An appreciation of the patient's motivation and tolerance for pain will also help immeasurably. An effort should be made to identify patients who have a tendency for the development of excessive edema, those who have diminished vascularity resulting from previous injury or surgery, and those who have had a previous infection. This information is useful for establishing realistic goals and in implementing an effective treatment program.

If the lysed tendon is of poor quality or if pulleys have been reconstructed, special postoperative methods will be necessary to minimize the stress placed on the tendons or pulleys, or both. A strong, nearly normal-appearing tendon in a minimally scarred bed with an adequate pulley system is a candidate for an aggressive mobilization program.

Some aspects of the therapy will be dictated by the appearance of the involved digit and hand at the time of the removal of the surgical dressing. Excessive swelling, bleeding, infection, wound breakdown, or inordinate pain may all have an adverse effect on the initial efforts to regain motion. When possible, it is helpful for the surgeon to be in attendance during the first therapy session to carefully monitor the initial attempts to mobilize the involved digit and to allay the apprehensions of the patient. An experienced therapist can, however, effectively commence the program if he or she is familiar with all aspects of the particular patient's injury and previous surgery as well as the findings at the time of the tenolysis.

After the goals and methods of therapy have been discussed with the patient, the bulky compressive dressing is removed and a lighter dressing that is compatible with the control of edema is applied. When necessary, areas of pulley reconstruction are identified and are protected by circumferential taping or the use of a thermoplastic ring. This protection is continued for ten to twelve weeks and should reduce the possibility of pulley rupture. Finger socks or Coban wraps (3M, St. Paul, Minnesota) may be applied to control digital edema. These small dressings are aesthetically acceptable to the patient and tend to minimize the pain and bleeding that can sometimes hamper the early mobilization of a digit that has just undergone extensive surgery.

The initial rehabilitation program consists of active and passive exercises designed to move the involved digit through the full range of motion that was present passively before the operation. This session is usually not terminated until the patient can actively achieve the same amount of flexion that was demonstrated at surgery. The patient is instructed to exercise with the wrist in various positions and to place equal emphasis on both extension and flexion. At the conclusion of the first effort at postoperative mobilization, the patient is instructed to continue the exercise program for ten to fifteen minutes each waking hour. The ability to carry

out self-therapy is carefully monitored.

Postoperative splinting varies depending on the tendency toward joint stiffening in a given digit and the difficulty that the patient has with initiating motion from either a flexed or an extended position. The majority of post-tenolysis digits are managed by extension splinting between exercise sessions in order to place the digits at rest and to diminish the tendency for a flexion contracture of the proximal interphalangeal joint to develop. When passive and active flexion are difficult to initiate and when full extension is easily achieved, it may be better to splint the digit in a flexed position.

If the tenolysed tendon has diminished caliber, is badly scarred, or was judged to be of poor quality at the time of surgery, the risk of tendon rupture may be considerable. Impending rupture may also be sometimes suspected when palpable crepitation develops in the digit during the early mobilization program. In both instances, therapy should be designed to diminish the tensile strength demand on the involved tendon while preserving the excursion achieved at surgery. A "frayed-tendon program" has been suggested for such cases¹⁴³ and will hopefully reduce the rate of rupture.

The "frayed tendon program" involves passively manipulating the digit into the fully flexed position and then asking the patient to actively maintain that flexion. If the digit retains its flexed position following the removal of the manipulating finger, muscle contracture and tendon movement have been confirmed. In this manner, the tendon moves through its maximal excursion but with much less likelihood of rupture. In some instances, additional protection can be achieved by maintaining some element of wrist flexion or metacarpophalangeal joint flexion, although the full excursion of the tendon is not possible in those positions. This program is usually continued for approximately four to six weeks following tenolysis.

Although postoperative swelling of the involved digit often somewhat compromises the ability to maintain the same active joint motion that was

achieved at surgery, it is important that the therapeutic effort continue until the patient has achieved active motion that is equal to passive motion. Terminating the therapy session before that goal is accomplished can result in gradual deterioration of active motion and a less than optimal final functional result. The use of a transcutaneous nerve stimulator (TENS) has been shown to be valuable for postoperative pain reduction, and the occasional use of an indwelling catheter for periodic instillation of a long-acting anesthetic may also be of benefit when a patient has a low pain threshold or a particularly complex situation. Electrical stimulation may be beneficial when the flexor muscle of the tenolysed tendon is weakened and requires augmentation to produce full tendon excursion. For patients who protectively contract the antagonistic extensor muscle groups, the use of biofeedback may be of considerable value in overcoming this motion-defeating activity. The use of adjunctive equipment such as a continuous-passive-motion device is proving to be helpful in maintaining joint motion and tendon motion, and the development and perfection of such equipment may further assist in the sometimes difficult postoperative period.

Summary

The results of thorough tenolysis of the flexor tendons in the palm and digits in selected patients can be gratifying. Preoperative requirements include a well-motivated patient with a supple digit and a wide discrepancy between the active and passive ranges of digital motion. The surgical procedure consists of meticulous division of all restraining adhesions from one or both of the flexor tendons and careful preservation or reconstruction of annular pulleys. The adequacy of the lysis at the time of surgery must be demonstrated either by active flexion by the patient under local anesthesia or by a proximal "flexor check" by the surgeon with the patient under general anesthesia. Postoperatively, every effort must be made to achieve, as quickly as possible, active digital motion compatible with the passive motion. Maintenance of the tendon excursion and joint motion

achieved at surgery is difficult and challenging. A well-designed rehabilitation program can usually be implemented following careful consultation between the surgeon and therapist, and special efforts may be necessary to relieve pain, control edema, preserve passive motion, eliminate antagonistic muscle activity, protect pulleys, and, above all, maintain tendon excursion.

Staged Flexor Tendon Reconstruction

Restoration of the performance of the flexor tendons in badly scarred digits has historically been very difficult. Several authors have reported the use of single-stage tendon-grafting procedures in these situations^{256,257}, but functional recovery has been only modest. Tendon autografts and allografts have been used with varying degrees of clinical success^{258,259}, although a small number of composite sheath-tendon allografts have been shown to provide surprisingly good recovery²⁶⁰. Unfortunately, technical and logistic difficulties with securing, preserving, and implanting these grafts have been obstacles to their widespread use.

An ingenious staged flexor tendon repair was described by Paneva-Holevich²⁶¹. In this technique, the severed proximal ends of the flexor profundus and superficialis tendons are sutured to each other in the palm. At the second stage, the flexor superficialis is divided at the musculotendinous junction, delivered distally through the flexor sheath, and sutured to the distal phalanx as a pedicle graft. Several surgeons have combined this technique with implantation of a silicone prosthesis in the digital sheath during the first stage to prepare a bed for the subsequent distal pedicle transfer^{262,263}. The procedure can apparently provide satisfactory results under either acute or salvage conditions, although it has not been widely used in the United States.

In an effort to improve the biological bed in which tendon grafts may later be placed, materials such as celloidin²⁶⁴, glass²⁶⁵, and metal²⁶⁶ have been utilized, but these materials apparently have led to joint stiffness because their rigidity

does not allow for passive digital motion while a pseudosheath is being formed around the implant²²⁶. Bassett and Carroll²⁶⁷ began using flexible silicone rubber rods to build pseudosheaths in badly scarred fingers in the 1950s, and the method was later refined into a two-stage reconstruction of the digital flexor tendons by Hunter and Salisbury^{268,269}. The implant and method that are currently the most popular largely resulted from the work by Hunter, Schneider, and their colleagues²⁴³. LaSalle and one of us (J.W.S.)²⁷⁰ reported their results after the use of this method, and Wilson et al.²³³ reported on the use of delayed two-stage reconstruction for isolated flexor profundus injuries. Hunter et al.²⁴⁶ pursued the development and clinical use of an active tendon implant and, in some instances, the results were encouraging. Asencio et al.²⁷¹ demonstrated reasonable results from the use of human composite flexor tendon allografts for these difficult salvage situations.

Staged Flexor Tendon Reconstruction with Placement of a Silicone Implant

Staged flexor tendon reconstruction involves placement of a silicone or silicone-Dacron-reinforced gliding implant into a scarred tendon bed, resulting in the formation of a mesothelium-lined pseudosheath around the implant. Following maturation of the pseudosheath, a tendon graft is inserted to replace the implant, with the hope that a minimum number of adhesions will form around the graft. Schneider²⁴³ emphasized that patients with severe neurovascular impairment are poor candidates for staged flexor tendon reconstruction. Some surgeons prefer to carry out staged tendon reconstruction by inserting the implant from the fingertip to the forearm, whereas others believe that, when the palm has not been substantially involved by the original trauma or subsequent surgery, the procedure need go only from the fingertip to the palm.

Surgical Technique

Stage One

The flexor system is exposed by palmar incisions that may be either midaxial or

zigzag, depending on the preference of the surgeon. Previous incisions must be recognized and respected to ensure satisfactory vascularity of the skin flaps. During dissection, care must be taken to preserve as much of the annular portions of the flexor sheath as possible. All tendon remnants are excised with a 1-cm stump of the flexor profundus left attached to its insertion in the distal phalanx. When possible, long portions of the excised tendons should be preserved for use in pulley reconstruction. Joint flexion contractures are released by division of the checkrein extensions of the palmar plate and the accessory collateral ligaments. The profundus tendon is then transected in the midpart of the palm, and, through a curvilinear incision from the midpart of the forearm to the wrist, the superficialis tendon is withdrawn proximally and is divided at its musculotendinous junction.

The selection of the appropriately sized tendon implant is largely governed by the tightness of the digital pulleys and the expected size of the tendon graft to be employed at stage two. A 4-mm implant is frequently satisfactory, and it should be carefully passed through all remaining pulleys. It is important to demonstrate that the implant will glide freely in the tendon bed by pulling it back and forth and observing its movement. Distal insertion of the definitive implant is then carried out in a manner dependent on the type of implant selected. One design (Holter-Houser) has a metal end piece that may be fixed to the distal phalangeal bone beneath the profundus stump with a small Woodruff self-tapping screw. The insertion preferred by most surgeons involves trimming of the distal portion of the implant and suturing it strongly to the undersurface of the profundus stump with synthetic sutures. This implant-tendon juncture allows one to avoid both the difficulties of passing the metal plate beneath the digital pulleys and problems with accurate screw placement in the distal phalanx.

The implant may then be passed from the proximal part of the palm to the distal part of the forearm in the plane between the profundus and superficialis

tendons with use of a tendon passer. Traction is placed on the proximal end of the implant to be sure that it glides smoothly beneath the preserved or reconstructed pulleys and to check the potential range of digital motion. The adequacy of the pulley system may also be observed at this time, and additional pulleys should be reconstructed over the implant if necessary. The proximal end of the implant is then tunneled proximally to lie free over the profundus muscle in the midpart of the forearm. It may be helpful to loosely tag the future profundus motor tendon to the implant. If the tendon that will be used for graft attachment is independent and not held at length by its companion tendons (such as the common profundus to the middle, ring, and small fingers), it is probably a good idea to suture it down to the periosteum overlying the distal part of the radius so that it will not undergo myostatic contracture during the interval between implant placement and free grafting. The wound is repaired, and a compressive dressing is applied to maintain the wrist in slight flexion. Passive wrist and digital motion are begun at seven to ten days, and small immobilization splints may be utilized to prevent digital joint stiffness (Fig. 9).

At about three months or after there has been sufficient time for wound-healing, scar maturation, and formation of a pseudosheath around the implant, the second-stage, grafting procedure is done. During the period between the procedures, vigorous therapy programs are utilized in an effort to regain and maintain full passive digital motion.

Stage Two

The replacement of the silicone implant by a free tendon graft may be carried out by utilizing the terminal portions of the digital and distal forearm incisions used in stage one. Great care is taken not to open the pseudosheath proximal to the distal interphalangeal joint or to injure any of the middle phalangeal pulleys. The implant is identified and uncovered at its attachment to the stump of the flexor profundus tendon over the base of the distal phalanx, and the connecting su-

tures are divided. The implant is temporarily tagged with a hemostat, and the stump of the profundus is mobilized and is retained at its insertion for suturing to the replacement free tendon graft. The proximal end of the implant is located through the forearm-wrist incision, and any excess pseudosheath is resected to ensure free gliding of the proximal graft juncture. The appropriate motor tendon is now selected and, most frequently, the combined profundus mass is chosen for grafts to the middle, ring, and small fingers. The independent profundus to the index finger usually is the most appropriate motor for that digit. In certain circumstances, the superficialis muscle-tendons can also be utilized. Care is taken to mobilize the motor tendon unit fully, and the proximal end of the implant is tagged.

The palmaris longus is usually not of sufficient length to serve as a tendon graft for the forearm-to-digital tip technique of a staged flexor tendon reconstruction. When present, the plantaris tendon makes a better graft for this procedure because of its small size and long length. Other potential donor sources include the long extensors of the middle three toes, which are of sufficient length but are larger and more difficult to pass through the pseudosheath.

The tendon graft is attached to the distal end of the implant and is pulled proximally through the pseudosheath into the forearm incision. The implant is then removed and discarded, and the distal tendon juncture is secured in a manner identical to that described for free tendon grafting. The distal finger wound is then closed, and the proximal motor tendon-graft juncture is created in the forearm with a weave technique. Tension on the graft should be set so that the digit is flexed slightly more than its normal resting position with the wrist in neutral and all muscles relaxed. The proximal wound is then closed, and the hand is immobilized in a bulky dressing with a posterior splint that maintains the wrist in the midposition between neutral and full flexion and maintains the metacarpophalangeal joints in 70° of flexion,

with the fingers in nearly full extension.

Some surgeons think that the hand should be immobilized for three or four weeks, given the salvage nature of the procedure, whereas others now favor initiation of an early protected-motion program at about three days following the second-stage, grafting procedure. In either event, therapy proceeds carefully through passive and light active-motion stages until at least six weeks, when the tensile strength of the tendon and its junctures are sufficiently strong to tolerate a more aggressive application of motion stress.

Complications

Complications of staged tendon reconstruction include synovitis around the implant, infection or wound breakdown, and disruption of the distal implant juncture after stage one. Stage-two complications include rupture of the graft, a graft that is too loose or too tight, development of an intrinsic-plus phenomenon, and flexion deformity of the proximal or distal interphalangeal joint. Finally, adhesions of the graft may prevent a successful recovery of digital motion and may require tenolysis¹⁰. The complications of either stage of this complex reconstruction may severely compromise the end result and must be dealt with promptly and appropriately.

Summary

When digits are badly scarred as a result of injury or multiple failed efforts to restore continuity and excursion to badly damaged flexor tendons, staged reconstruction involving initial placement of a silicone implant in the tendon bed followed later by replacement of that implant with a tendon graft can offer realistic salvage possibilities when very few other options exist. The procedure must be carefully considered by both the physician and the patient, and the status of the digital tissues, including the skin, nerves, vessels, and joints, must weigh heavily in the determination of whether to proceed with such a complex and multistaged restorative effort.

Complications

The mechanism of injury has a substan-

tial effect on the outcome of surgery. Sharp injuries have tidier wound edges and require less débridement. Crush injuries, contaminated injuries, or injuries involving open fracture often require extensive débridement and may lead to volar skin deficiencies so that coverage of the repaired tendon is a problem. A wider zone of injury can also increase the number and extent of adhesions. Composite tissue injuries—those associated with fracture and/or neurovascular injury—may require more extensive exposure and alteration of postoperative therapy if the osseous fixation cannot withstand the postoperative tendon-motion rehabilitation. Also, vascular precautions combined with the need to protect extensor repairs make early mobilization of the replanted digit difficult. A delay in seeking or obtaining surgical attention for the injury also places the patient at risk for complications, and a delay of greater than three weeks might preclude primary repair. Additionally, contamination from a neglected wound may lead to infection that precludes primary repair or may result in delayed infection postoperatively.

Coexisting medical conditions such as peripheral vascular disease or diabetes mellitus can impair healing and compromise motion. In addition, preexisting musculoskeletal conditions, such as osteoarthritis, that limit digital motion compromise the results of surgical intervention. If the passive range of digital motion is limited prior to injury, excursion of the repaired tendon can likewise be limited during rehabilitation.

Wound problems should be addressed immediately so that rehabilitation can be initiated as early as possible. If the patient presents with active infection, as may happen with a neglected wound or with tendon injuries secondary to an animal or human bite, then the infectious process must be addressed first. Infected and compromised tissue must be debrided aggressively, and appropriate antimicrobial coverage must be utilized.

Poorly planned incisions or thin, devitalized flaps may result in excessive

scarring or contracture. In addition, cicatrices develop as wounds heal by secondary intention, which may hamper rehabilitation and ultimately the functional result. If the A2 or A4 pulley is substantially compromised, bowstringing typically ensues and, if left untreated, may lead to flexion deformity of the proximal or distal interphalangeal joint. Resection of large segments of pulley sheath may also increase adhesion formation.

Inadvertent neurovascular injury may result in catastrophic complications, including digital loss. If both digital arteries are transected, ischemic tissue is present even though fingertip perfusion may be judged adequate, and repair of at least one of the digital arteries is suggested. Tissue ischemia is believed to be a major contributing factor in infection and in scar formation⁶⁸.

Of all postoperative complications, the most dreaded is tendon rupture. Repair-site rupture is demonstrated by the absence of a palpable tendon within the digit during gentle attempts at digital flexion. The patient may have also felt a “pop” during rehabilitation exercise. If a rupture is noted, it should be immediately explored, and repair should be attempted if possible. If repair is not possible because of retraction of the tendon stump proximally or because of poor quality of the tendon stumps, preparations for grafting or for two-stage reconstruction should be made. Repair-site triggering during rehabilitation has also been described²⁷². It has been attributed to overly aggressive exercise on the part of the patient; typically, a mild catching sensation is noted during active flexion. Patients should be allowed to continue therapy uninterrupted with the expectation that the triggering will cease along with resolution of the digital edema.

Wounds that become infected subsequent to tendon repair must be treated with basic surgical wound care. Superficial wound infections can often be treated with elevation of the upper limb or by initiation of oral antibiotics. If purulent drainage is present, a speci-

men should be cultured so that antimicrobial therapy can be directed toward a specific pathogen, especially if there is no immediate response to intravenous antibiotics. When there is no response to antibiotics or when there is evidence of a closed-space or deep infection, surgical exploration is necessary. It should be noted that a rupture of a repaired tendon might mimic a postoperative infection. There may be a sudden increase in pain, swelling, erythema, and other signs of inflammation. Therefore, it is imperative that the function of the tendon in question be ascertained.

Contractures may also develop during the postoperative phase, either because of difficulties with the splinting or because of wound contracture. These problems are best addressed early. It is therefore of paramount importance that the patient be followed closely by both the therapist and the physician. Often, contractures can be prevented by splinting the digits in extension between exercise sessions and while the patient is sleeping. As the tendon continues to heal and strengthen, more aggressive intervention, including dynamic splinting, can be initiated. A capsular release can be contemplated for a fixed flexion contracture that remains unresponsive to therapeutic intervention. Often this is done in combination with flexor tenolysis, as adhesions and fixed flexion contractures can coexist.

Martin I. Boyer, MD, FRCS(C)
Department of Orthopaedic Surgery, Barnes-Jewish Hospital at Washington University School of Medicine, One Barnes Plaza, Suite 11300, St. Louis, MO 63110. E-mail address: boyerm@msnotes.wustl.edu

James W. Strickland, MD
755 West Carmel Drive, Suite 202, Carmel, IN 46082-3430

Drew R. Engles, MD
Summit Hand Center, 3975 Embassy Parkway, Suite 201, Akron, OH 44333

Kavi Sachar, MD
Fraser J. Leversedge, MD
Hand Surgery Associates, 2535 South Downing Street, Suite 500, Denver, CO 80210

In support of their research or preparation of this manuscript, one or more of the authors received grants or outside funding from National Institutes of Health (AR 33097). None of the authors received payments or other benefits or a commitment or agreement to provide such benefits from a commercial entity. No commercial entity

paid or directed, or agreed to pay or direct, any benefits to any research fund, foundation, educational institution, or other charitable or nonprofit organization with which the authors are affiliated or associated.

Printed with the permission of the American Academy of Orthopaedic Surgeons. This arti-

cle, as well as other lectures presented at the Academy's Annual Meeting, will be available in March 2003 in *Instructional Course Lectures*, Volume 52. The complete volume can be ordered online at www.aaos.org, or by calling 800-626-6726 (8 A.M.-5 P.M., Central time).

References

- Verdan CE. Half a century of flexor-tendon surgery. Current status and changing philosophies. *J Bone Joint Surg Am.* 1972;54:472-91.
- Kessler I, Nissim F. Primary repair without immobilization of flexor tendon division within the digital sheath. An experimental and clinical study. *Acta Orthop Scand.* 1969;40:587-601.
- Bunnell S. *Surgery of the hand.* Philadelphia: Lippincott; 1944. p 298.
- Gelberman RH, Amiel D, Gonsalves M, Woo S, Akeson WH. The influence of protected passive mobilization on the healing of flexor tendons: a biochemical and microangiographic study. *Hand.* 1981;13:120-8.
- Gelberman RH, Woo SL, Lothringer K, Akeson WH, Amiel D. Effects of early intermittent passive mobilization on healing canine flexor tendons. *J Hand Surg [Am].* 1982;7:170-5.
- Manske PR, Gelberman RH, Vande Berg JS, Lesker PA. Intrinsic flexor-tendon repair. A morphological study in vitro. *J Bone Joint Surg Am.* 1984;66:385-96.
- Gelberman RH, Manske PR, Vande Berg JS, Lesker PA, Akeson WH. Flexor tendon repair in vitro: a comparative histologic study of the rabbit, chicken, dog, and monkey. *J Orthop Res.* 1984;2:39-48.
- Manske PR, Lesker PA. Biochemical evidence of flexor tendon participation in the repair process—an in vitro study. *J Hand Surg [Br].* 1984;9:117-20.
- Manske PR, Lesker PA. Histologic evidence of intrinsic flexor tendon repair in various experimental animals. An in vitro study. *Clin Orthop.* 1984;182:297-304.
- Gelberman RH, Vandeberg JS, Manske PR, Akeson WH. The early stages of flexor tendon healing: a morphologic study of the first fourteen days. *J Hand Surg [Am].* 1985;10:776-84.
- Manske PR, Lesker PA, Gelberman RH, Rucinsky TE. Intrinsic restoration of the flexor tendon surface in the nonhuman primate. *J Hand Surg [Am].* 1985;10:632-7.
- Manske PR, Gelberman RH, Lesker PA. Flexor tendon healing. *Hand Clin.* 1985;1:25-34.
- Gelberman RH, Manske PR, Akeson WH, Woo SL, Lundborg G, Amiel D. Flexor tendon repair. *J Orthop Res.* 1986;4:119-28.
- Zhao C, Amadio PC, Zobitz ME, Momose T, Couvreur P, An KN. Gliding resistance after repair of partially lacerated human flexor digitorum profundus tendon in vitro. *Clin Biomech (Bristol, Avon).* 2001;16:696-701.
- Zhao C, Amadio PC, Zobitz ME, An KN. Gliding characteristics of tendon repair in canine flexor digitorum profundus tendons. *J Orthop Res.* 2001;19:580-6.
- Momose T, Amadio PC, Zhao C, Zobitz ME, An KN. The effect of knot location, suture mate-
- rial, and suture size on the gliding resistance of flexor tendons. *J Biomed Mater Res.* 2000;53:806-11.
- Boardman ND 3rd, Morifusa S, Saw SS, McCarthy DM, Sotereanos DG, Woo SL. Effects of tenorrhaphy on the gliding function and tensile properties of partially lacerated canine digital flexor tendons. *J Hand Surg [Am].* 1999;24:302-9.
- Aoki M, Kubota H, Pruitt DL, Manske PR. Biomechanical and histologic characteristics of canine flexor tendon repair using early post-operative mobilization. *J Hand Surg [Am].* 1997;22:107-14.
- Gelberman RH, Vande Berg JS, Lundborg GN, Akeson WH. Flexor tendon healing and restoration of the gliding surface. An ultrastructural study in dogs. *J Bone Joint Surg Am.* 1983;65:70-80.
- Nyska M, Porat S, Nyska A, Rousso M, Shoshan S. Decreased adhesion formation in flexor tendons by topical application of enriched collagen solution—a histological study. *Arch Orthop Trauma Surg.* 1987;106:192-4.
- Porat S, Rousso M, Shoshan S. Improvement of gliding function of flexor tendons by topically applied enriched collagen solution. *J Bone Joint Surg Br.* 1980;62:208-13.
- Peterson WW, Manske PR, Kain CC, Lesker PA. Effect of flexor sheath integrity on tendon gliding: a biomechanical and histologic study. *J Orthop Res.* 1986;4:458-65.
- Zhao C, Amadio PC, An KN, Zobitz ME. Gliding characteristics of tendon repair in partially lacerated canine flexor digitorum profundus tendons. *Trans Orthop Res Soc.* 1999;24:120.
- Boyer MI, Meunier MJ, Lescheid J, Burns ME, Gelberman RH, Silva MJ. The influence of cross-sectional area on the tensile properties of flexor tendons. *J Hand Surg [Am].* 2001;26:828-32.
- Boyer MI, Gelberman RH, Burns ME, Dinopoulos H, Hofem R, Silva MJ. Intrasynovial flexor tendon repair. An experimental study comparing low and high levels of in vivo force during rehabilitation in canines. *J Bone Joint Surg Am.* 2001;83:891-9.
- Miller L, Mass DP. A comparison of four repair techniques for Camper's chiasma flexor digitorum superficialis lacerations: tested in an in vitro model. *J Hand Surg [Am].* 2000;25:1122-6.
- Dinopoulos HT, Boyer MI, Burns ME, Gelberman RH, Silva MJ. The resistance of a four- and eight-strand suture technique to gap formation during tensile testing: an experimental study of repaired canine flexor tendons after 10 days of in vivo healing. *J Hand Surg [Am].* 2000;25:489-98.
- Choueka J, Heminger H, Mass DP. Cyclical testing of zone II flexor tendon repairs. *J Hand Surg [Am].* 2000;25:1127-34.
- Gelberman RH, Boyer MI, Brodt MD, Winters SC, Silva MJ. The effect of gap formation at the repair site on the strength and excursion of intrasynovial flexor tendons. An experimental study on the early stages of tendon-healing in dogs. *J Bone Joint Surg Am.* 1999;81:975-82.
- Winters SC, Gelberman RH, Woo SL, Chan SS, Grewal R, Seiler JG 3rd. The effects of multiple-strand suture methods on the strength and excursion of repaired intrasynovial flexor tendon: a biomechanical study in dogs. *J Hand Surg [Am].* 1998;23:97-104.
- Stein T, Ali A, Hamman J, Mass DP. A randomized biomechanical study of zone II human flexor tendon repairs analyzed in an in vitro model. *J Hand Surg [Am].* 1998;23:1046-51.
- Silva MJ, Hollstien SB, Fayazi AH, Adler P, Gelberman RH, Boyer MI. The effects of multiple-strand suture techniques on the tensile properties of repair of the flexor digitorum profundus tendon to bone. *J Bone Joint Surg Am.* 1998;80:1507-14.
- Winters SC, Seiler JG 3rd, Woo SL, Gelberman RH. Suture methods for flexor tendon repair. A biomechanical analysis during the first six weeks following repair. *Ann Chir Main Memb Super.* 1997;16:229-34.
- Hamman J, Ali A, Phillips C, Cunningham B, Mass DP. A biomechanical study of the flexor digitorum superficialis: effects of digital pulley excision and loss of the flexor digitorum profundus. *J Hand Surg [Am].* 1997;22:328-35.
- Komanduri M, Phillips CS, Mass DP. Tensile strength of flexor tendon repairs in a dynamic cadaver model. *J Hand Surg [Am].* 1996;21:605-11.
- Noguchi M, Seiler JG 3rd, Gelberman RH, Sofranko RA, Woo SL. In vitro biomechanical analysis of suture methods for flexor tendon repair. *J Orthop Res.* 1993;11:603-11.
- Goomer RS, Maris TM, Gelberman R, Boyer MI, Silva M, Amiel D. Nonviral in vivo gene therapy for tissue engineering of articular cartilage and tendon repair. *Clin Orthop.* 2000;379 Suppl: S189-200.
- Bidder M, Towler DA, Gelberman RH, Boyer MI. Expression of mRNA for vascular endothelial growth factor at the repair site of healing canine flexor tendon. *J Orthop Res.* 2000;18:247-52.
- Tsuzaki M, Brigman BE, Yamamoto J, Lawrence WT, Simmons JG, Mohapatra NK, Lund PK, Van Wyk J, Hannafin JA, Bhargava MM, Banes AJ. Insulin-like growth factor-I is expressed by avian flexor tendon cells. *J Orthop Res.* 2000;18:546-56.
- Banes AJ, Weinhold P, Yang X, Tsuzaki M, Bynum D, Bottlang M, Brown T. Gap junctions regulate responses of tendon cells ex vivo to mechanical loading. *Clin Orthop.* 1999;367 Suppl:S356-70.
- Banes AJ, Horesovosky G, Larson C, Tsuzaki M, Judex S, Archambault J, Zernicke R, Herzog

- W, Kelley S, Miller L. Mechanical load stimulates expression of novel genes in vivo and in vitro in avian flexor tendon cells. *Osteoarthritis Cartilage*. 1999;7:141-53.
42. McNeilly CM, Banes AJ, Benjamin M, Ralphs JR. Tendon cells in vivo form a three dimensional network of cell processes linked by gap junctions. *J Anat*. 1996;189:593-600.
43. Banes AJ, Tsuzaki M, Hu P, Brigman B, Brown T, Almekinders L, Lawrence WT, Fischer T. PDGF-BB, IGF-I and mechanical load stimulate DNA synthesis in avian tendon fibroblasts in vitro. *J Biomech*. 1995;28:1505-13.
44. Chang J, Thunder R, Most D, Longaker MT, Lineaweaver WC. Studies in flexor tendon wound healing: neutralizing antibody to TGF-beta1 increases postoperative range of motion. *Plast Reconstr Surg*. 2000;105:148-55.
45. Chang J, Most D, Thunder R, Mehrara B, Longaker MT, Lineaweaver WC. Molecular studies in flexor tendon wound healing: the role of basic fibroblast growth factor gene expression. *J Hand Surg [Am]*. 1998;23:1052-8.
46. Chang J, Most D, Stelnicki E, Siebert JW, Longaker MT, Hui K, Lineaweaver WC. Gene expression of transforming growth factor beta-1 in rabbit zone II flexor tendon wound healing: evidence for dual mechanisms of repair. *Plast Reconstr Surg*. 1997;100:937-44.
47. Boyer MI, Watson JT, Lou J, Manske PR, Gelberman RH, Cai SR. Quantitative variation in vascular endothelial growth factor mRNA expression during early flexor tendon healing: an investigation in a canine model. *J Orthop Res*. 2001;19:869-72.
48. Strickland JW. Development of flexor tendon surgery: twenty-five years of progress. *J Hand Surg [Am]*. 2000;25:214-35.
49. Idler RS. Anatomy and biomechanics of the digital flexor tendons. *Hand Clin*. 1985;1:3-11.
50. Kleinert HE, Verdan C. Report of the Committee on Tendon Injuries (International Federation of Societies for Surgery of the Hand). *J Hand Surg [Am]*. 1983;8:794-8.
51. Doyle JR, Blythe WF. Anatomy of the flexor tendon sheath and pulleys of the thumb. *J Hand Surg [Am]*. 1977;2:149-51.
52. Manske PR, Lesker PA. Palmar aponeurosis pulley. *J Hand Surg [Am]*. 1983;8:259-63.
53. Netscher D, Lee M, Thornby J, Polsen C. The effect of division of the transverse carpal ligament on flexor tendon excursion. *J Hand Surg [Am]*. 1997;22:1016-24.
54. Netscher D, Mosharrafa A, Lee M, Polsen C, Choi H, Steadman AK, Thornby J. Transverse carpal ligament: its effect on flexor tendon excursion, morphologic changes of the carpal canal, and on pinch and grip strengths after open carpal tunnel release. *Plast Reconstr Surg*. 1997;100:636-42.
55. Abrahamsson SO, Lundborg G, Lohmander LS. Tendon healing in vivo. An experimental model. *Scand J Plast Reconstr Surg Hand Surg*. 1989;23:199-205.
56. Gelberman RH. Flexor tendon physiology: tendon nutrition and cellular activity in injury and repair. *Instr Course Lect*. 1985;34:351-60.
57. Gelberman RH, Khabie V, Cahill CJ. The revascularization of healing flexor tendons in the digital sheath. A vascular injection study in dogs. *J Bone Joint Surg Am*. 1991;73:868-81.
58. Lundborg G, Rank F. Experimental intrinsic healing of flexor tendons based upon synovial fluid nutrition. *J Hand Surg [Am]*. 1978;3:21-31.
59. Manske PR, Bridwell K, Whiteside LA, Lesker PA. Nutrition of flexor tendons in monkeys. *Clin Orthop*. 1978;136:294-8.
60. Manske PR, Lesker PA, Bridwell K. Experimental studies in chickens on the initial nutrition of tendon grafts. *J Hand Surg [Am]*. 1979;4:565-75.
61. Manske PR, Lesker PA. Nutrient pathways of flexor tendons in primates. *J Hand Surg [Am]*. 1982;7:436-44.
62. Manske PR, Lesker PA. Flexor tendon nutrition. *Hand Clin*. 1985;1:13-24.
63. Lundborg G, Myrhage R, Rydevik B. The vascularization of human flexor tendons within the digital synovial sheath region—structural and functional aspects. *J Hand Surg [Am]*. 1977;2:417-27.
64. Kleinert HE, Spokevicius S, Papas NH. History of flexor tendon repair. *J Hand Surg [Am]*. 1995;20:S46-52.
65. Lexer E. Die Verwehtung der freien Schenkeltransplantation. *Arch Klinic Surg*. 1912;98:918.
66. Bruner JM. The zig-zag volar-digital incision for flexor-tendon surgery. *Plast Reconstr Surg*. 1967;40:571-4.
67. Bruner JM. Surgical exposure of flexor tendons in the hand. *Ann R Coll Surg Engl*. 1973;53:84-94.
68. Lister G. Pitfalls and complications of flexor tendon surgery. *Hand Clin*. 1985;1:133-46.
69. Lister GD. Incision and closure of the flexor sheath during primary tendon repair. *Hand*. 1983;15:123-35.
70. Teehey SA, Middleton WD, Boyer MI. Sonography of the hand and wrist. *Semin Ultrasound CT MR*. 2000;21:192-204.
71. Kleinert HE, Schepel S, Gill T. Flexor tendon injuries. *Surg Clin North Am*. 1981;61:267-86.
72. Morris RJ, Martin DL. The use of skin hooks and hypodermic needles in tendon surgery. *J Hand Surg [Br]*. 1993;18:33-4.
73. Sourmelis SG, McGrouther DA. Retrieval of the retracted flexor tendon. *J Hand Surg [Br]*. 1987;12:109-11.
74. Sasaki Y, Nomura S. An unusual role of the vinculum after complete laceration of the flexor tendons. *J Hand Surg [Br]*. 1987;12:105-8.
75. Beckham C, Greenlee TK Jr. Chick vincula: elastic structures with a check-rein mechanism. *J Anat*. 1975;119:295-308.
76. Goshgarian GG. Retrieving the proximal end of a severed flexor tendon. *Plast Reconstr Surg*. 1978;62:108.
77. Strickland JW. Management of acute flexor tendon injuries. *Orthop Clin North Am*. 1983;14:827-49.
78. Kilgore ES Jr, Adams DR, Newmeyer WL, Graham WP. Atraumatic flexor tendon retrieval. *Am J Surg*. 1971;122:430-1.
79. Titley OG. A modification of the catheter method for retrieval of divided flexor tendons. *J Hand Surg [Br]*. 1996;21:391-2.
80. Howard RF, Ondrovic L, Greenwald DP. Biomechanical analysis of four-strand extensor tendon repair techniques. *J Hand Surg [Am]*. 1997;22:838-42.
81. McLarney E, Hoffman H, Wolfe SW. Biomechanical analysis of the cruciate four-strand flexor tendon repair. *J Hand Surg [Am]*. 1999;24:295-301.
82. Labana N, Messer T, Lautenschlager E, Nagda S, Nagle D. A biomechanical analysis of the modified Tsuge suture technique for repair of flexor tendon lacerations. *J Hand Surg [Br]*. 2001;26:297-300.
83. Barrie KA, Wolfe SW, Shean C, Shenbagamurthi D, Slade JF 3rd, Panjabi MM. A biomechanical comparison of multistrand flexor tendon repairs using an in situ testing model. *J Hand Surg [Am]*. 2000;25:499-506.
84. Tang JB, Pan CZ, Xie RG, Chen F. A biomechanical study of Tang's multiple locking techniques for flexor tendon repair. *Chir Main*. 1999;18:254-60.
85. Savage R, Risitano G. Flexor tendon repair using a "six strand" method of repair and early active mobilisation. *J Hand Surg [Br]*. 1989;14:396-9.
86. Strickland JW. Flexor tendons—acute injuries. In: Green DP, Hotchkiss RN, Pederson WC. *Green's operative hand surgery*. 4th ed, volume 2. New York: Churchill Livingstone; 1999. p 1851-97.
87. Sanders DW, Bain GI, Johnson JA, Milne AD, Roth JH, King GJ. In-vitro strength of flexor-tendon repairs. *Can J Surg*. 1995;38:528-32.
88. Smith AM, Evans DM. Biomechanical assessment of a new type of flexor tendon repair. *J Hand Surg [Br]*. 2001;26:217-9.
89. Tang JB, Wang B, Chen F, Pan CZ, Xie RG. Biomechanical evaluation of flexor tendon repair techniques. *Clin Orthop*. 2001;386:252-9.
90. Barrie KA, Tomak SL, Cholewicki J, Wolfe SW. The role of multiple strands and locking sutures on gap formation of flexor tendon repairs during cyclical loading. *J Hand Surg [Am]*. 2000;25:714-20.
91. Gill RS, Lim BH, Shatford RA, Toth E, Voor MJ, Tsai TM. A comparative analysis of the six-strand double-loop flexor tendon repair and three other techniques: a human cadaveric study. *J Hand Surg [Am]*. 1999;24:1315-22.
92. Rapisio E, Cella A, Barabino P, Santi P. Two modified techniques for flexor tendon repair. *Plast Reconstr Surg*. 1999;103:1691-5.
93. Thurman RT, Trumble TE, Hanel DP, Tencer AF, Kiser PK. Two-, four-, and six-strand zone II flexor tendon repairs: an in situ biomechanical comparison using a cadaver model. *J Hand Surg [Am]*. 1998;23:261-5.
94. Shaieb MD, Singer DI. Tensile strengths of various suture techniques. *J Hand Surg [Br]*. 1997;22:764-7.
95. Lotz JC, Hariharan JS, Diao E. Analytic model to predict the strength of tendon repairs. *J Orthop Res*. 1998;16:399-405.
96. Pruitt DL, Manske PR, Fink B. Cyclic stress analysis of flexor tendon repair. *J Hand Surg [Am]*. 1991;16:701-7.
97. Bhatia D, Tanner KE, Bonfield W, Citron ND. Factors affecting the strength of flexor tendon repair. *J Hand Surg [Br]*. 1992;17:550-2.
98. Winters SC, Gelberman RH, Woo SL, Chan SS, Grewal R, Seiler JG 3rd. The effects of multiple-strand suture methods on the strength and excursion of repaired intrasynovial flexor tendons: a biomechanical study in dogs. *J Hand Surg [Am]*. 1998;23:97-104.
99. Wada A, Kubota H, Akiyama T, Hatanaka H, Miura H, Iwamoto Y. Effect of absorbable polydioxanone flexor tendon repair and restricted active mobilization in a canine model. *J Hand Surg [Am]*. 2001;26:398-406.

100. **Norris SR, Ellis FD, Chen MI, Seiler JG 3rd.** Flexor tendon suture methods: a quantitative analysis of suture material within the repair site. *Orthopedics*. 1999;22:413-6.
101. **Diao E, Hariharan JS, Soejima O, Lotz JC.** Effect of peripheral suture depth on strength of tendon repairs. *J Hand Surg [Am]*. 1995;20:234-9.
102. **Papandrea R, Seitz WH Jr, Shapiro P, Borden B.** Biomechanical and clinical evaluation of the epitenon-first technique of flexor tendon repair. *J Hand Surg [Am]*. 1995;20:261-6.
103. **Mashadi ZB, Amis AA.** Strength of the suture in the epitenon and within the tendon fibres: development of stronger peripheral suture technique. *J Hand Surg [Br]*. 1992;17:172-5.
104. **Slade JF, Bhargava M, Barrie KA, Shenbagamurthi D, Wolfe SW.** Zone II tendon repairs augmented with autogenous dorsal tendon graft: a biomechanical analysis. *J Hand Surg [Am]*. 2001;26:813-20.
105. **Tsuge K, Ikuta Y, Matsuishi Y.** Intra-tendinous tendon suture in the hand—a new technique. *Hand*. 1975;7:250-5.
106. **Tsuge K, Yoshikazu I, Matsuishi Y.** Repair of flexor tendons by intratendinous tendon suture. *J Hand Surg [Am]*. 1977;2:436-40.
107. **Ikuta Y, Tsuge K.** Postoperative results of looped nylon suture used in injuries of the digital flexor tendons. *J Hand Surg [Br]*. 1985;10:67-72.
108. **Becker H, Davidoff M.** Eliminating the gap in flexor tendon surgery. A new method of suture. *Hand*. 1977;9:306-11.
109. **Becker H.** Primary repair of flexor tendons in the hand without immobilisation—preliminary report. *Hand*. 1978;10:37-47.
110. **Silva MJ, Brodt MD, Boyer MI, Morris TS, Dinopoulos H, Amiel D, Gelberman RH.** Effects of increased in vivo excursion on digital range of motion and tendon strength following flexor tendon repair. *J Orthop Res*. 1999;17:777-83.
111. **Tajima T.** History, current status, and aspects of hand surgery in Japan. *Clin Orthop*. 1984;184:41-9.
112. **Wagner WF Jr, Carroll C 4th, Strickland JW, Heck DA, Toombs JP.** A biomechanical comparison of techniques of flexor tendon repair. *J Hand Surg [Am]*. 1994;19:979-83.
113. **Soejima O, Diao E, Lotz JC, Hariharan JS.** Comparative mechanical analysis of dorsal versus palmar placement of core suture for flexor tendon repairs. *J Hand Surg [Am]*. 1995;20:801-7.
114. **Hatanaka H, Zhang J, Manske PR.** An in vivo study of locking and grasping techniques using a passive mobilization protocol in experimental animals. *J Hand Surg [Am]*. 2000;25:260-9.
115. **Hatanaka H, Manske PR.** Effect of suture size on locking and grasping flexor tendon repair techniques. *Clin Orthop*. 2000;375:267-74.
116. **Hatanaka H, Manske PR.** Effect of the cross-sectional area of locking loops in flexor tendon repair. *J Hand Surg [Am]*. 1999;24:751-60.
117. **Pruitt DL, Aoki M, Manske PR.** Effect of suture knot location on tensile strength after flexor tendon repair. *J Hand Surg [Am]*. 1996;21:969-73.
118. **Aoki M, Pruitt DL, Kubota H, Manske PR.** Effect of suture knots on tensile strength of repaired canine flexor tendons. *J Hand Surg [Br]*. 1995;20:72-5.
119. **Seradge H, Tian W, Kashef GH, Seradge A, Owen W.** The Oklahoma repair technique: a biomechanical study of a new suture repair technique. *J Okla State Med Assoc*. 2000;93:551-6.
120. **Silfverskiold KL, May EJ.** Gap formation after flexor tendon repair in zone II. Results with a new controlled motion programme. *Scand J Plast Reconstr Surg Hand Surg*. 1993;27:263-8.
121. **Silfverskiold KL, May EJ, Tornvall AH.** Gap formation during controlled motion after flexor tendon repair in zone II: a prospective clinical study. *J Hand Surg [Am]*. 1992;17:539-46.
122. **Barmakian JT, Lin H, Green SM, Posner MA, Casar RS.** Comparison of a suture technique with the modified Kessler method: resistance to gap formation. *J Hand Surg [Am]*. 1994;19:777-81.
123. **Gelberman RH, Amiel D, Harwood F.** Genetic expression for type I procollagen in the early stages of flexor tendon healing. *J Hand Surg [Am]*. 1992;17:551-8.
124. **Garner WL, McDonald JA, Koo M, Kuhn C 3rd, Weeks PM.** Identification of the collagen-producing cells in healing flexor tendons. *Plast Reconstr Surg*. 1989;83:875-9.
125. **Goldfarb CA, Harwood F, Silva MJ, Gelberman RH, Amiel D, Boyer MI.** The effect of variations in applied rehabilitation force on collagen concentration and maturation at the intrasynovial flexor tendon repair site. *J Hand Surg [Am]*. 2001;26:841-6.
126. **Harwood FL, Goomer RS, Gelberman RH, Silva MJ, Amiel D.** Regulation of alpha(v)beta3 and alpha5beta1 integrin receptors by basic fibroblast growth factor and platelet-derived growth factor-BB in intrasynovial flexor tendon cells. *Wound Repair Regen*. 1999;7:381-8.
127. **Harwood FL, Monosov AZ, Goomer RS, Gelberman RH, Winters SC, Silva MJ, Amiel D.** Integrin expression is upregulated during early healing in a canine intrasynovial flexor tendon repair and controlled passive motion model. *Connect Tissue Res*. 1998;39:309-16.
128. **Banes AJ, Link GW, Bevin AG, Peterson HD, Gillespie Y, Bynum D, Watts S, Dahners L.** Tendon synovial cells secrete fibronectin in vivo and in vitro. *J Orthop Res*. 1988;6:73-82.
129. **Amiel D, Gelberman R, Harwood F, Siegel D.** Fibronectin in healing flexor tendons subjected to immobilization or early controlled passive motion. *Matrix*. 1991;11:184-9.
130. **Gelberman RH, Steinberg D, Amiel D, Akeson W.** Fibroblast chemotaxis after tendon repair. *J Hand Surg [Am]*. 1991;16:686-93.
131. **Robbins JR, Evanko SP, Vogel KG.** Mechanical loading and TGF-beta regulate proteoglycan synthesis in tendon. *Arch Biochem Biophys*. 1997;342:203-11.
132. **Abrahamsson SO, Lundborg G, Lohmander LS.** Long-term explant culture of rabbit flexor tendon: effects of recombinant human insulin-like growth factor-I and serum on matrix metabolism. *J Orthop Res*. 1991;9:503-15.
133. **Abrahamsson SO, Lundborg G, Lohmander LS.** Recombinant human insulin-like growth factor-I stimulates in vitro matrix synthesis and cell proliferation in rabbit flexor tendon. *J Orthop Res*. 1991;9:495-502.
134. **Abrahamsson SO.** Matrix metabolism and healing in the flexor tendon. Experimental studies on rabbit tendon. *Scand J Plast Reconstr Surg Hand Surg Suppl*. 1991;23:1-51.
135. **Linkhart TA, Mohan S, Baylink DJ.** Growth factors for bone growth and repair: IGF, TGF beta and BMP. *Bone*. 1996;19(1 Suppl):1S-12S.
136. **Fetrow KO.** Tenolysis in the hand and wrist. A clinical evaluation of two hundred and twenty flexor and extensor tenolyses. *J Bone Joint Surg Am*. 1967;49:667-85.
137. **Young RES, Harmon JM.** Repair of tendon injuries of the hand. *Ann Surg*. 1960;151:562-6.
138. **Lister D, Kleiner HE, Kutz JE, Atasoy E.** Primary flexor tendon repair followed by immediate controlled mobilization. *J Hand Surg [Am]*. 1977;2:441-51.
139. **Chow JA, Thomas LJ, Dovel S, Milnor WH, Seyfer AE, Smith AC.** A combined regimen of controlled motion following flexor tendon repair in "no man's land". *Plast Reconstr Surg*. 1987;79:447-53.
140. **Horii E, Lin GT, Cooney WP, Linscheid RL, An KN.** Comparative flexor tendon excursion after passive mobilization: an in vitro study. *J Hand Surg [Am]*. 1992;17:559-66.
141. **Lieber RL, Amiel D, Kaufman KR, Whitney J, Gelberman RH.** Relationship between joint motion and flexor tendon force in the canine forelimb. *J Hand Surg [Am]*. 1996;21:957-62.
142. **Lieber RL, Silva MJ, Amiel D, Gelberman RH.** Wrist and digital joint motion produce unique flexor tendon force and excursion in the canine forelimb. *J Biomech*. 1999;32:175-81.
143. **Cannon NM, Strickland JW.** Therapy following flexor tendon surgery. *Hand Clin*. 1985;1:147-65.
144. **Duran RE, Houser RG.** Controlled passive motion following flexor tendon repair in zones two and three. In: *The American Academy of Orthopaedic Surgeons: symposium on tendon surgery in the hand*. St. Louis: Mosby; 1975. p 105-14.
145. **Kitsis CK, Wade PJ, Krikler SJ, Parsons NK, Nicholls LK.** Controlled active motion following primary flexor tendon repair: a prospective study over 9 years. *J Hand Surg [Br]*. 1998;23:344-9.
146. **Peck FH, Bucher CA, Watson JS, Roe A.** A comparative study of two methods of controlled mobilization of flexor tendon repairs in zone 2. *J Hand Surg [Br]*. 1998;23:41-5.
147. **Khan U, Occleston NL, Khaw PT, McGrouther DA.** Single exposures to 5-fluorouracil: a possible mode of targeted therapy to reduce contractile scarring in the injured tendon. *Plast Reconstr Surg*. 1997;99:465-71.
148. **Akali A, Khan U, Khaw PT, McGrouther AD.** Decrease in adhesion formation by a single application of 5-fluorouracil after flexor tendon injury. *Plast Reconstr Surg*. 1999;103:151-8.
149. **Cerovac S, Afoke A, Akali A, McGrouther DA.** Early breaking strength of repaired flexor tendon treated with 5-fluorouracil. *J Hand Surg [Br]*. 2001;26:220-3.
150. **Moran SL, Ryan CK, Orlando GS, Pratt CE, Michalko KB.** Effects of 5-fluorouracil on flexor tendon repair. *J Hand Surg [Am]*. 2000;25:242-51.
151. **Ragoowansi R, Khan U, Brown RA, McGrouther DA.** Reduction in matrix metalloproteinase production by tendon and synovial fibroblasts after a single exposure to 5-fluorouracil. *Br J Plast Surg*. 2001;54:283-7.
152. **Wiig ME, Amiel D, VandeBerg J, Kitabayashi L, Harwood FL, Arfors KE.** The early effect of high molecular weight hyaluronan (hyaluronic acid) on anterior cruciate ligament healing: an

- experimental study in rabbits. *J Orthop Res*. 1990;8:425-34.
153. **Wiig M, Abrahamsson SO, Lundborg G.** Effects of hyaluronan on cell proliferation and collagen synthesis: a study of rabbit flexor tendons in vitro. *J Hand Surg [Am]*. 1996;21:599-604.
154. **Wiig M, Abrahamsson SO, Lundborg G.** Tendon repair—cellular activities in rabbit deep flexor tendons and surrounding synovial sheaths and the effects of hyaluronan: an experimental study in vivo and in vitro. *J Hand Surg [Am]*. 1997;22:818-25.
155. **Wiig M, Abrahamsson SO.** Hyaluronic acid modulates cell proliferation unequally in intrasynovial and extrasynovial rabbit tendons in vitro. *J Hand Surg [Br]*. 2000;25:183-7.
156. **Salti NI, Tuel RJ, Mass DP.** Effect of hyaluronic acid on rabbit profundus flexor tendon healing in vitro. *J Surg Res*. 1993;55:411-5.
157. **Miller JA, Ferguson RL, Powers DL, Burns JW, Shalaby SW.** Efficacy of hyaluronic acid/non-steroidal anti-inflammatory drug systems in preventing postsurgical tendon adhesions. *J Biomed Mater Res*. 1997;38:25-33.
158. **Amiel D, Ishizue K, Billings E Jr, Wiig M, Vande Berg J, Akeson WH, Gelberman R.** Hyaluronan in flexor tendon repair. *J Hand Surg [Am]*. 1989;14:837-43.
159. **Hanff G, Abrahamsson SO.** Matrix synthesis and cell proliferation in repaired flexor tendons within e-PTFE reconstructed flexor tendon sheaths. *J Hand Surg [Br]*. 1996;21:642-6.
160. **Chow SP, Yu OD.** An experimental study on incompletely cut chicken tendons—a comparison of two methods of management. *J Hand Surg [Br]*. 1984;9:121-5.
161. **Bishop AT, Cooney WP 3rd, Wood MB.** Treatment of partial flexor tendon lacerations: the effect of tenorrhaphy and early protected mobilization. *J Trauma*. 1986;26:301-12.
162. **McGeorge DD, Stilwell JH.** Partial flexor tendon injuries: to repair or not. *J Hand Surg [Br]*. 1992;17:176-7.
163. **McCarthy DM, Boardman ND 3rd, Tramaglino DM, Sotereanos DG, Herndon JH.** Clinical management of partially lacerated digital flexor tendons: a survey [corrected] of hand surgeons. *J Hand Surg [Am]*. 1995;20:273-5. Erratum: 1995;20:526.
164. **McCarthy DM, Tramaglino DM, Chan SS, Schmidt CC, Sotereanos DG, Herndon JH.** Effect of partial laceration on the structural properties of the canine FDP tendon: an in vitro study. *J Hand Surg [Am]*. 1995;20:795-800.
165. **Schlenker JD, Lister GD, Kleinert HE.** Three complications of untreated partial laceration of flexor tendon—entrapment, rupture, and triggering. *J Hand Surg [Am]*. 1981;6:392-8.
166. **Frewin PR, Scheker LR.** Triggering secondary to an untreated partially-cut flexor tendon. *J Hand Surg [Br]*. 1989;14:419-21.
167. **Bilos ZJ, Hui PW, Stamelos S.** Trigger finger following partial flexor tendon laceration. *Hand*. 1977;9:232-3.
168. **Grewal R, Sotereanos DG, Rao U, Herndon JH, Woo SL.** Bundle pattern of the flexor digitorum profundus tendon in zone II of the hand: a quantitative assessment of the size of a laceration. *J Hand Surg [Am]*. 1996;21:978-83.
169. **Grewal R, Saw SS, Bastidas JA, Fischer KJ, Sotereanos DG.** Passive and active rehabilitation for partial lacerations of the canine flexor digitorum profundus tendon in zone II. *J Hand Surg [Am]*. 1999;24:743-50.
170. **Strickland JW.** Flexor tendon injuries. Part 5. Flexor tenolysis, rehabilitation and results. *Orthop Rev*. 1987;16:137-53.
171. **Wehbe MA, Hunter JM.** Flexor tendon gliding in the hand. Part II. Differential gliding. *J Hand Surg [Am]*. 1985;10:575-9.
172. **Wehbe MA, Hunter JM.** Flexor tendon gliding in the hand. Part I. In vivo excursions. *J Hand Surg [Am]*. 1985;10:570-4.
173. **Lin GT, Amadio PC, An KN, Cooney WP, Chao EY.** Biomechanical analysis of finger flexor pulley reconstruction. *J Hand Surg [Br]*. 1989;14:278-82.
174. **Bunnell S.** Repair of tendons in the fingers and description of two new instruments. *Surg Gynecol Obstet*. 1918;26:103-10.
175. **Karev A.** The "belt loop" technique for the reconstruction of pulleys in the first stage of flexor tendon grafting. *J Hand Surg [Am]*. 1984;9:923-4.
176. **Lister GD.** Reconstruction of pulleys employing extensor retinaculum. *J Hand Surg [Am]*. 1979;4:461-4.
177. **Strickland JW.** Flexor tendon injuries. Part 4. Staged flexor tendon reconstruction and restoration of the flexor pulley. *Orthop Rev*. 1987;16:78-90.
178. **Coert JH, Uchiyama S, Amadio PC, Berglund LJ, An KN.** Flexor tendon-pulley interaction after tendon repair. A biomechanical study. *J Hand Surg [Br]*. 1995;20:573-7.
179. **Nishida J, Seiler JG, Amadio PC, An KN.** Flexor tendon-pulley interaction after annular pulley reconstruction: a biomechanical study in a dog model in vivo. *J Hand Surg [Am]*. 1998;23:279-84.
180. **Nishida J, Amadio PC, Bettinger PC, An KN.** Flexor tendon-pulley interaction after pulley reconstruction: a biomechanical study in a human model in vitro. *J Hand Surg [Am]*. 1998;23:665-72.
181. **Uchiyama S, Amadio PC, Coert JH, Berglund LJ, An KN.** Gliding resistance of extrasynovial and intrasynovial tendons through the A2 pulley. *J Bone Joint Surg Am*. 1997;79:219-24.
182. **Widstrom CJ, Johnson G, Doyle JR, Manske PR, Inhofe P.** A mechanical study of six digital pulley reconstruction techniques: Part I. Mechanical effectiveness. *J Hand Surg [Am]*. 1989;14:821-5.
183. **Tang JB, Ishii S, Usui M, Yamamura T.** Flexor sheath closure during delayed primary tendon repair. *J Hand Surg [Am]*. 1994;19:636-40.
184. **Tang JB, Shi D, Zhang QG.** Biomechanical and histologic evaluation of tendon sheath management. *J Hand Surg [Am]*. 1996;21:900-8.
185. **Gelberman RH, Woo SL, Amiel D, Horibe S, Lee D.** Influences of flexor sheath continuity and early motion on tendon healing in dogs. *J Hand Surg [Am]*. 1990;15:69-77.
186. **Adamson JE, Wilson JN.** The history of flexor tendon grafting. *J Bone Joint Surg Am*. 1961;43:709-16.
187. **Mayer L.** The physiological method of tendon transplantation I. Historical: anatomy and physiology of tendons. *Surg Gynecol Obstet*. 1916;22:182-97.
188. **Mayer L.** The physiological method of tendon transplantation II. Operative technique. *Surg Gynecol Obstet*. 1916;22:298-306.
189. **Mayer L.** The physiological method of tendon transplantation. III. Experimental and clinical experiences. *Surg Gynecol Obstet*. 1916;22:472-81.
190. **Mason ML, Allen HS.** The rate of healing of tendons. An experimental study of tensile strength. *Ann Surg*. 1941;113:424-59.
191. **Moberg E.** Experiences with Bunnell's pull-out wire sutures. *Br J Plast Surg*. 1951;3:249-51.
192. **Pulvertaft R.** Repair of tendon injuries in the hand. *Ann R Coll Surg Engl*. 1948;3:3-14.
193. **Pulvertaft RG.** Tendon grafts for flexor tendon injuries in the fingers and thumb. A study of technique and results. *J Bone Joint Surg Br*. 1956;38:175-94.
194. **Pulvertaft RG.** Indications for tendon grafting. In: Hunter JM, Schneider LH, editors. *The American Academy of Orthopaedic Surgeons. Symposium on tendon surgery in the hand*. St. Louis: CV Mosby; 1975. p 123-31.
195. **Graham WC.** Flexor-tendon grafts to the finger and thumb. *J Bone Joint Surg Am*. 1947;29:553-9.
196. **Littler JW.** Free tendon grafts in secondary flexor tendon repair. *Am J Surg*. 1947;74:315-21.
197. **Boyes JH, Stark HH.** Flexor-tendon grafts in the fingers and thumb. A study of factors influencing results in 1000 cases. *J Bone Joint Surg Am*. 1971;53:1332-42.
198. **White WL.** Secondary restoration of finger flexion by digital tendon grafts. An evaluation of seventy-six cases. *Am J Surg*. 1956;91:662-8.
199. **White WL.** Tendon grafts: a consideration of their source, procurement and suitability. *Surg Clin North Am*. 1960;40:403-13.
200. **Rank BK, Wakefield AR.** The repair of flexor tendons in the hand. *Br J Plast Surg*. 1952;4:244-53.
201. **Tubiana R.** Incisions and technics in tendon grafting. *Am J Surg*. 1965;109:339-45.
202. **Tubiana R.** Results and complications of flexor tendon grafting. *Orthop Clin North Am*. 1973;4:877-83.
203. **McClinton MA, Curtis RM, Wilgis EF.** One hundred tendon grafts for isolated flexor digitorum profundus injuries. *J Hand Surg [Am]*. 1982;7:224-9.
204. **Schneider L, Hunter J.** Flexor tendons; late reconstruction. In: Green D, editor. *Operative hand surgery*. 3rd ed. New York: Churchill Livingstone; 1988. p 1969-2044.
205. **Wilson RL.** Flexor tendon grafting. *Hand Clin*. 1985;1:97-107.
206. **Eiken O, Holmberg J, Ekerot L, Salgeback S.** Restoration of the digital tendon sheath. A new concept of tendon grafting. *Scand J Plast Reconstr Surg*. 1980;14:89-97.
207. **Reimann AF, Daseler EH, Anson BJ, Beaton LE.** The palmaris longus muscle and tendon. A study of 1600 extremities. *Anat Rec*. 1944;89:495-505.
208. **Daseler EH, Anson BJ.** The plantaris muscle. An anatomical study of 750 specimens. *J Bone Joint Surg*. 1943;25:822-7.
209. **Noguchi M, Seiler JG 3rd, Boardman ND 3rd, Tramaglino DM, Gelberman RH, Woo SL.** Tensile properties of canine intrasynovial and extrasynovial flexor tendon autografts. *J Hand Surg [Am]*. 1997;22:457-63.
210. **Ark JW, Gelberman RH, Abrahamsson SO,**

- Seiler JG 3rd, Amiel D. Cellular survival and proliferation in autogenous flexor tendon grafts. *J Hand Surg [Am]*. 1994;19:249-58.
211. Bruner JM. Surgical exposure of the flexor pollicis longus tendon. *Hand*. 1975;7:241-5.
212. Littler J. The digital flexor-extensor system. In: Converse JM, editor. *Reconstructive plastic surgery. Principles and procedures in correction, reconstruction, and transplantation*. 2nd ed. Volume 6, Part 3. The hand and upper extremity. Philadelphia: WB Saunders; 1977. p 3166-214.
213. Peacock EE Jr. Some technical aspects and results of flexor tendon repair. *Surgery*. 1965; 58:330-42.
214. Pulvertaft RG. Suture materials and tendon junctures. *Am J Surg*. 1965;109:346-52.
215. Rank BK, Wakefield AR. *Surgery of repair as applied to hand injuries*. 2nd ed. Baltimore: Williams and Wilkins; 1960.
216. Rank BK, Wakefield AR, Hueston JT. *Surgery of repair as applied to hand injuries*. 4th ed. Edinburgh: Churchill Livingstone; 1973.
217. Pulvertaft G. Experiences in flexor tendon grafting in the hand. Proceedings of the Hand Surgeons Club of Great Britain and Second Hand Club. *J Bone Joint Surg Br*. 1959;41:629-30.
218. Nalebuff EA. The intact sublimis. In: Verdan C, editor. *Tendon surgery of the hand*. Edinburgh: Churchill Livingstone; 1979. p 76-84.
219. Leddy JP. Avulsions of the flexor digitorum profundus. *Hand Clin*. 1985;1:77-83.
220. Carroll RE, Match RM. Avulsion of the flexor profundus tendon insertion. *J Trauma*. 1970; 10:1109-18.
221. Littler JW. The physiology and dynamic function of the hand. *Surg Clin North Am*. 1960 40. :259-66.
222. Nichols HM. The dilemma of the intact superficialis tendon. *Hand*. 1975;7:85-6.
223. Campbell Reid DA. The isolated flexor digitorum profundus lesion. *Hand*. 1969;1:115-7.
224. Wakefield AR. The management of flexor tendon injuries. *Surg Clin North Am*. 1960; 40:267-73.
225. Bora FW Jr. Profundus tendon grafting with unimpaired sublimis function in children. *Clin Orthop*. 1970;71:118-23.
226. Chang WH, Thomas OJ, White WL. Avulsion injury of the long flexor tendons. *Plast Reconstr Surg*. 1972;50:260-4.
227. Goldner JL, Coonrad RW. Tendon grafting of the flexor profundus in the presence of a completely or partially intact flexor sublimis. *J Bone Joint Surg Am*. 1969;51:527-32.
228. Jaffe S, Weckesser E. Profundus tendon grafting with the sublimis intact. An end-result study of thirty patients. *J Bone Joint Surg Am*. 1967;49:1298-308.
229. Pulvertaft RG. The treatment of profundus division by free tendon graft. *J Bone Joint Surg Am*. 1960;42:1363-71.
230. Schneider LH. *Flexor tendon injuries*. Boston: Little Brown; 1985.
231. Stark HH, Zemel NP, Boyes JH, Ashworth CR. Flexor tendon graft through intact superficialis tendon. *J Hand Surg [Am]*. 1977;2:456-61.
232. Versaci AD. Secondary tendon grafting for isolated flexor digitorum profundus injury. *Plast Reconstr Surg*. 1970;46:57-60.
233. Wilson RL, Carter MS, Holdeman VA, Lovett WL. Flexor profundus injuries treated with delayed two-staged tendon grafting. *J Hand Surg [Am]*. 1980;5:74-8.
234. Brooks DM. Problems of restoration of tendon movements after repair and grafts. *Proc R Soc Med*. 1970;63:67-8.
235. Peacock EE Jr, Van Winkle W Jr. *Surgery and biology of wound repair*. Philadelphia: Saunders; 1970. 236. James JIP. The value of tenolysis. *Hand*. 1969;1:118-9.
237. Hunter JM, Seinsheimer F 3rd, Mackin EJ. Tenolysis: pain control and rehabilitation. In: Strickland JW, Steichen JB, editors. *Difficult problems in hand surgery*. St. Louis: Mosby; 1982. p 312-8.
238. Schneider LH, Hunter JM. Flexor tenolysis. In: Hunter JM, Schneider LH, editors. *The American Academy of Orthopaedic Surgeons. Symposium on tendon surgery in the hand*. St. Louis: CV Mosby; 1975. p 157-62.
239. Strickland JW. Flexor tenolysis. *Hand Clin*. 1985;1:121-32.
240. Strickland JW, Glogovac SV. Digital function following flexor tendon repair in Zone II: A comparison of immobilization and controlled passive motion techniques. *J Hand Surg [Am]*. 1980;5:537-43.
241. Whitaker JH, Strickland JW, Ellis RK. The role of flexor tenolysis in the palm and digits. *J Hand Surg [Am]*. 1977;2:462-70.
242. Wray RC Jr, Moucharrafieh B, Weeks PM. Experimental study of the optimal time for tenolysis. *Plast Reconstr Surg*. 1978;61:184-9.
243. Schneider LH. Staged flexor tendon reconstruction using the method of Hunter. *Clin Orthop*. 1982;171:164-71.
244. Hunter JM, Schneider LH, Dumont J, Erickson JC 3rd. A dynamic approach to problems of hand function using local anesthesia supplemented by intravenous fentanyl-droperidol. *Clin Orthop*. 1974;104:112-5.
245. Strickland JW. Results of flexor tendon surgery in zone II. *Hand Clin*. 1985;1:167-79.
246. Hunter JM, Singer DI, Jaeger SH, Mackin EJ. Active tendon implants in flexor tendon reconstruction. *J Hand Surg [Am]*. 1988;13:849-59.
247. Hunter JM, Singer DI, Mackin EJ. Staged flexor tendon reconstruction using passive and active tendon implants. In: Hunter JM, Schneider LH, Mackin EJ, Callahan AD, editors. *Rehabilitation of the hand. Surgery and therapy*. 3rd ed. St. Louis: CV Mosby; 1990. p 427-57.
248. Verdan C. *Tendon surgery of the hand*. New York: Churchill Livingstone; 1979.
249. Boyes J. The great flexor tendon controversy. In: Cramer LM, Chase RA, editors. *Symposium on the hand*. Vol 3 of Proceedings of the symposium of the Educational Foundation of the American Society of Plastic and Reconstructive Surgeons. St. Louis: Mosby; 1971. p 185-191.
250. Bora FW Jr, Lane JM, Prockop DJ. Inhibitors of collagen biosynthesis as a means of controlling scar formation in tendon injury. *J Bone Joint Surg Am*. 1972;54:1501-8.
251. Wrenn RN, Goldner JL, Markee JL. An experimental study of the effect of cortisone on the healing process and tensile strength of tendons. *J Bone Joint Surg Am*. 1954;36:588-601.
252. Carstam N. The effects of cortisone on the formation of tendon adhesions and on tendon healing: An experimental investigation in the rabbit. *Acta Chir Scand Suppl*. 1953;182:1-111.
253. James JIP. The use of cortisone in tenolysis. Proceedings of the British Orthopaedic Association. *J Bone Joint Surg Br*. 1959;41:209-10.
254. Verdan C, Crawford G, Martini-Benkeddache Y. The valuable role of tenolysis in the digits. In: Cramer LM, Chase RA, editors. *Symposium on the hand*. Vol 3 of Proceedings of the symposium of the Educational Foundation of the American Society of Plastic and Reconstructive Surgeons. St. Louis: CV Mosby; 1971. p 192.
255. Ketchum LD. Effects of triamcinolone on tendon healing and function. A laboratory study. *Plast Reconstr Surg*. 1971;47:471-82.
256. Butler B Jr, Burkhalter WE, Cranston JP 3rd. Flexor-tendon grafts in the severely scarred digit. An experimental study in dogs. *J Bone Joint Surg Am*. 1968;50:452-7.
257. McCormack RM, Demuth RJ, Kindling PH. Flexor-tendon grafts in the less-than-optimal situation. *J Bone Joint Surg Am*. 1962;44:1360-4.
258. Cameron RR, Conrad RN, Latham WD. Preserved composite tendon allografts: a comparative study of changes in length, elasticity, and anastomotic and lineal tensile strength. *Surg Forum*. 1970;21:506-8.
259. Potenza AD, Melone C. Evaluation of freeze-dried flexor tendon grafts in the dog. *J Hand Surg [Am]*. 1978;3:157-62.
260. Peacock EE Jr. A review of composite tissue allografts of the digital flexor mechanism. *Transplant Proc*. 1976;8(2 Suppl 1):119-27.
261. Paneva-Holevich E. Two-stage tenoplasty in injury of the flexor tendons of the hand. *J Bone Joint Surg Am*. 1969;51:21-32.
262. Kessler FB. Use of a pedicled tendon transfer with a silicone rod in complicated secondary flexor tendon repairs. *Plast Reconstr Surg*. 1972;49:439-43.
263. Chuinard RG, Dabiezies EJ, Mathews RE. Two-stage superficialis tendon reconstruction in severely damaged fingers. *J Hand Surg [Am]*. 1980;5:135-43.
264. Mayer L. Celloidin tube reconstruction of extensor communis sheath. *Bull Hosp Joint Dis*. 1940;1:39.
265. Milgram JE. Transplantation of tendons through preformed gliding channels. *Bull Hosp Joint Dis Orthop Inst*. 1960;21:250-95.
266. Thatcher HVH. Use of stainless steel rods to canalize flexor tendon sheaths. *South Med J*. 1939;32:13-8.
267. Bassett CAL, Carroll RE. Formation of tendon sheath by silicone-rod implants. Proceedings of the American Society for Surgery of the Hand. *J Bone Joint Surg Am*. 1963;45:884-5.
268. Hunter J. Artificial tendons. Early development and application. *Am J Surg*. 1965;109:325-38.
269. Hunter JM, Salisbury RE. Flexor-tendon reconstruction in severely damaged hands. A two-stage procedure using a silicone-dacron reinforced gliding prosthesis prior to tendon grafting. *J Bone Joint Surg Am* 1971;53:829-58.
270. LaSalle WB, Strickland JW. An evaluation of the two-stage flexor tendon reconstruction technique. *J Hand Surg [Am]*. 1983;8:263-7.
271. Asencio G, Abihaidar G, Leonardi C. Human composite flexor tendon allografts. A report of two cases. *J Hand Surg [Br]*. 1996;21:84-8.
272. Strickland JW. Flexor Tendon Injuries: II. Operative Technique. *J Am Acad Orthop Surg*. 1995;3:55-62.