

# Foam and liquid sclerotherapy for varicose veins

P Coleridge Smith

Consultant Vascular Surgeon, London Vein Institute, 4 Upper Wimpole Street, London W1G 6 LF, UK

## Abstract

**Objective:** The objective of this study is to review the methods and outcome of ultrasound-guided foam sclerotherapy (UGFS) for the treatment of superficial venous incompetence.

**Method:** Medical literature databases including Medline were searched for recent literature concerning UGFS. Papers describing methods and outcome have been assessed and their main findings included in this summary. A detailed description of the methods used by the author has been included as an example of how successful the treatment may be achieved.

**Results:** A diverse range of practice is described in published literature in this field. Each group of authors used their own variation of the methods, described in the published literature, with good results. It is clear that foam sclerotherapy is far more effective than liquid sclerotherapy and that ultrasound imaging allows the treatment to be delivered accurately to affected veins. There is evidence that 3% polidocanol foam is no more effective than 1% polidocanol foam. The optimum ratio of gas to liquid is 4:1, although a range of ratios is reported in published work. There is a wide variation in the volume used as well as the method by which it is injected. The use of carbon dioxide foam reduces the systemic complications, particularly visual disturbance, when compared with air foams. Very few serious adverse events have been reported in the literature despite the widespread use of this method. Rates of recanalization of saphenous trunks following UGFS are similar to those observed after endovenous laser and endovenous radiofrequency ablation of veins, as well as the residual incompetence after surgical treatment.

**Conclusions:** UGFS is a safe and effective method of treating varicose veins. The relative advantages or disadvantages of this treatment in the longer term are yet to be published.

**Keywords:** varicose veins; telangiectases; reticular varices; ultrasound-guided foam sclerotherapy; duplex ultrasound imaging

## Introduction

Sclerotherapy gained a reputation for lack of efficacy in the latter part of the 20th century, at least in part, thanks to the work of Hobbs.<sup>1</sup> His 10-year randomized controlled study showed that the clinical recurrence of varices was common in patients with truncal saphenous reflux managed by sclerotherapy, as described by Fegan.<sup>2</sup> Hobbs found that after 10 years, 71% of patients treated surgically

for truncal saphenous incompetence had a good outcome compared with only 6% of patients treated by sclerotherapy. Recent scientific evidence has shown that liquid sclerotherapy is not very effective at eliminating truncal saphenous incompetence and failure to achieve abolition of reflux leads to early recurrence of varices.

Advances in technology led to improvements in the practice of sclerotherapy. In the 1980s ultrasound was introduced for the diagnosis of venous disease of the lower limb. In France this led Schadeck and Vin to improve the efficacy of their treatment using ultrasound imaging to guide the placement of injections into incompetent saphenous trunks.<sup>3,4</sup> However, this treatment was not as successful as had been hoped. Bishop examined a series of 55 patients in whom 89 legs had been

Correspondence: Philip Coleridge Smith DM FRCS,  
The Bridge Clinic, Bridge Road, Maidenhead SL6 8DG,  
Berks, UK.

Email: p.coleridgesmith@ucl.ac.uk

Accepted 5 January 2009

managed by ultrasound-guided liquid sclerotherapy. He found that 57% showed residual saphenofemoral reflux and 75% of patients had great saphenous vein (GSV) reflux.<sup>5</sup> The problem of recanalization of veins was encountered in up to one-quarter of patients at one year according to Kanter and Thibault.<sup>6</sup>

The next significant advancement came in 1995 when Cabrera *et al.*<sup>7</sup> suggested that foam could be created using carbon dioxide mixed with a polidocanol (POL), a detergent sclerosant. This invention built on the work of several previous authors who had experimented with various types of foam. Foote<sup>8</sup> described a method of foam sclerotherapy in 1944, which was improved by Orbach in 1950<sup>9</sup> who published a paper describing the use of a foam which he created by vigorously shaking a syringe containing air and sclerosant to produce a froth. Cabrera used sclerotherapy with foam, guiding his injections by ultrasound imaging. He called his invention 'microfoam', comprising very small bubbles in contrast to the large bubble froths that had been used previously. Cabrera *et al.*<sup>10</sup> published a further article in 1997 describing his experience in 261 legs with great saphenous varices and eight patients with vascular malformations. Some of the varicose veins reached 20 mm in diameter. He considered that foam greatly extended the range of vein sizes which could be managed by sclerotherapy. He felt that the increased efficacy of foam was attributable to it displacing blood from the treated vein and increasing the contact time between the sclerosant and the vein.

In the intervening years, several clinical series and one randomized clinical trial have confirmed that foam sclerotherapy is effective in managing truncal saphenous incompetence. No detailed follow-up beyond three years has been published.

## Commencing a practice of sclerotherapy

Sclerotherapy has not been widely taught during vascular surgical training in the UK in recent years and differs significantly in its conduct from surgery. Diagnostic ultrasonography of the venous system is largely carried out by vascular technologists in the UK (in contrast to many other European countries) and surgeons may have only passing familiarity with this technology. As a result it is common to find that surgeons are ill-equipped to undertake ultrasound-guided foam sclerotherapy.

Appropriate training is essential before commencing clinical practice. This can be broken down into

the components of sclerotherapy, ultrasound imaging and ultrasound-guided cannulation of vessels.

*Sclerotherapy.* Injecting the right volume of the right sclerosant into the right vein is essential to getting a good outcome. Complications may arise if excessive concentrations or volumes of sclerosant are used. Lack of efficacy may be encountered when not enough is given. The right 'recipe' for success seems to vary greatly between practitioners, but consensus guidelines have been published.<sup>11,12</sup> Theoretical knowledge is useful, but there is no substitute for practice! A skilled sclerotherapist will be able to put a needle into any vein visible from the surface of a limb, from the finest thread vein to large varix. This is best learnt under the supervision of an expert.

*Vascular imaging.* Diagnosis of abnormality in the venous system takes a great deal of practice and training. However, the anatomy of the superficial veins is readily assimilated and most patterns of varicose veins can be assessed by surgeons familiar with the surgical anatomy of the superficial and perforating veins. Learning the skills required with the assistance of an experienced vascular technologist or radiologist is probably the most effective strategy.

*Ultrasound guided cannulation.* This is an essential component of foam sclerotherapy and is the single most difficult aspect of the treatment for a beginner. Ultrasound phantoms are available with simulated veins to facilitate the learning process. These are not very life-like and are easy to master. The next stage involves patients and can be undertaken on suitably consented patients undergoing surgical treatment for varicose veins. The procedure of cannulating the saphenous trunk can be practised, but without injecting any foam (there is a high risk of deep vein thrombosis [DVT] in patients who have foam sclerotherapy under general anaesthesia).

Combining these skills into a complete treatment for a patient requires some further training in the best strategy to use in order to obtain good results. Again this is best done under the supervision of a skilled practitioner.

## Facilities and equipment required for sclerotherapy

In comparison with surgery and other endovenous methods of treating varicose veins, very little is required in the way of equipment and facilities to treat varicose veins by foam sclerotherapy. The room used for this purpose may be a consulting room, a clinic room or treatment room. The facilities

offered by an operating theatre are not required and may be intimidating to patients.

An adjustable and tiltable examination couch is essential for comfortable working. Most sclerotherapy is done with the patient lying recumbent, but it is useful to be able to tilt the couch during foam sclerotherapy to empty distal veins and to deal with occasional instances of syncope.

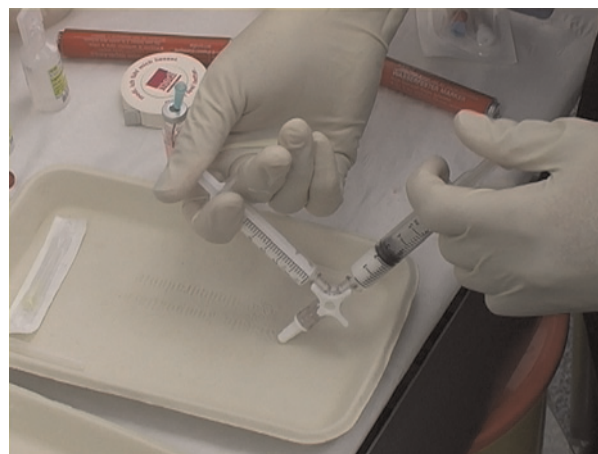
A modern ultrasound machine with imaging frequencies in the range of 5–15 MHz is required. A linear array transducer of about 40 mm length is the most appropriate for foam sclerotherapy. The better the resolution of the image, the easier it will be to see where the needle has gone. Portable machines now provide images comparable with much larger machines from a few years ago and are much easier to move from room to room.

A trolley containing needles, syringes, cannulae, bandages and all other items required to complete the treatment is useful, so that there is no need to search the cupboards for missing items. Appropriate compression stockings will also be required. In the exceptional case that a severe allergic reaction occurs following treatment, suitable drugs and equipments must be available to manage this problem.

### Preparation of sclerosant foam

Many authors have described methods of preparing foam which may be used for ultrasound-guided sclerotherapy. Monfreux<sup>13</sup> described a method necessitating a glass syringe, which produced small quantities of POL foam, which he used in a series of patients with truncal varicose veins. Sadoun and Benigni<sup>14</sup> described a method of preparing foam using a plastic syringe, avoiding the need for reusable glass syringes. Subsequently, Tessari<sup>15</sup> has described a method of preparing foam using two disposable syringes and a three-way tap. This method can be used to produce large quantities of foam suitable for treating saphenous trunks and large varices. Frullini<sup>16</sup> has added his own method of producing foam to this increasing list based on that of Flückinger.<sup>17</sup>

The most widely used method is that of Tessari, which is readily achieved using materials available in most clinics (Figure 1). Two syringes are connected using a three-way tap. A 5  $\mu$ m intravenous filter can be inserted between the syringes and this greatly improves the quality of the foam. Either 2 mL or 5 mL syringes may be used, or a combination. A mixture of sclerosant and air is drawn into one syringe at a ratio of one part



**Figure 1** Tessari method for creating sclerosant foam. Gas and sclerosant are oscillated between two syringes via a three-way tap approximately 20 times

of sclerosant to four parts of gas. The sclerosant can be sodium tetradecyl sulphate (STS) 1–3% (Fibrovein STD Pharmaceuticals, Hereford, UK) or POL 0.5–3% (Sclerovein, Resinag AG, Zurich, CH). Low concentrations of POL (0.5%) make better foam when mixed in the ratio of 1:1 with air. The mixture is oscillated vigorously between the two syringes about 10 or 20 times. The tap can be turned slightly to reduce the aperture and increase the smoothness of the foam. The foam produced in this way is stable for about two minutes so it should be injected as soon as it has been made.

The patient with stroke reported by Forlee *et al.*<sup>18</sup> highlights a potential hazard of injecting air/foam into varicose veins, although such events are rare considering the tens of millions of patients who have been treated worldwide. A recent letter to the *New England Journal of Medicine*<sup>19</sup> described how air/foam injected in the leg veins rapidly finds its way to the right side of the heart and may be a factor in producing visual disturbance. The problem may lie with the nitrogen in air which is relatively insoluble, and replacing this with carbon dioxide can limit the reported side-effects of treatment.<sup>20</sup> A mixture of 70% CO<sub>2</sub> and 30% O<sub>2</sub> can be obtained from BOC Special Gases (see [www.bocspecialgases.co.uk](http://www.bocspecialgases.co.uk)) and used to make foam. Pure CO<sub>2</sub> makes short lived, poor quality foam.

### Patient selection – indications and contraindications

Suitability of a patient for foam sclerotherapy depends on the aims of treatment as well as the

venous anatomy. Foam sclerotherapy can be carried out successfully in almost any patient with clinically significant venous disease no matter how elderly, frail, obese or ill they are. In patients with leg ulcers more aggressive treatment may be indicated or more ambitious treatment (very large varices) than in those seeking cosmetic improvement. The only absolute contraindications are severe allergy and obliterated deep veins. Table 1 lists some relative and absolute contraindications to treatment.

For those learning to use ultrasound-guided foam sclerotherapy, the easiest varices to manage are those in patients with moderate size great or small saphenous trunks (5–8 mm diameter) that have never been treated previously. In general, the saphenous trunks are straight and easy to cannulate, and the varices are not very extensive. Patients with recurrent varices following previous surgery are more difficult. Residual non-tortuous saphenous trunks are relatively easy to cannulate, but very tortuous recurrent vessels near the saphenofemoral junction (SFJ) and saphenopopliteal junction (SPJ) need significant previous experience.

## Patient consent

Patients should be fully informed of the method of treatment as well as the complications which may arise. They should be warned about the lumps

**Table 1** Some relative and absolute contraindications to treatment by foam sclerotherapy

### Adverse patient factors (relative contraindications to treatment)

Morbid obesity (BMI > 30)  
 Extreme age or frailty  
 Severe concomitant disease (malignancy, cardiovascular, respiratory)  
 Known thrombophilia or history of previous DVT  
 'Needle phobic' patients or those preferring treatment under general anaesthesia  
 Very thin patients may be left with lumps where the veins were obliterated following sclerotherapy and are less suitable for treatment

### Adverse venous anatomy (relative contraindications to treatment)

Severe post-thrombotic damage in the deep veins (little advantage of treating VVs)  
 Very large varices (more complications of skin pigmentation and lumps following treatment)  
 The lesion is an arterio-venous malformation (more difficult to treat)

### Absolute contraindications to treatment

Severe allergy to sclerosants  
 Obliteration of deep vein system (e.g. following extensive previous DVT with no recanalization of deep veins)

BMI, body mass index; DVT, deep vein thrombosis

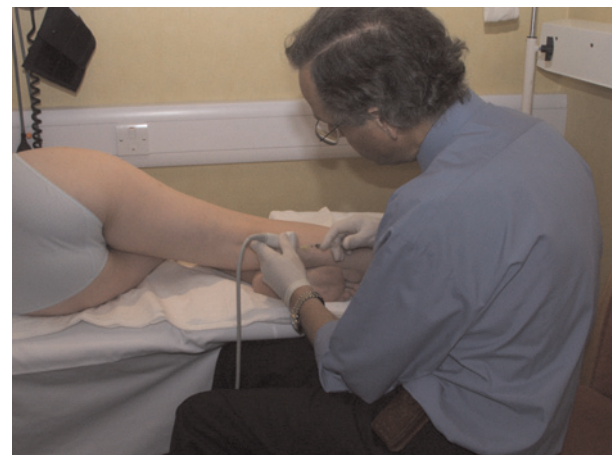caused by thrombophlebitis and skin pigmentation. Injection site ulceration is rare and need not be mentioned. Visual disturbance, chest tightness and coughing occur occasionally and are included. DVT is also mentioned as is severe allergy, although this is very uncommon. This information should be supported by written consent and an information sheet. Some clinicians may also have access to a website reference for further information.

## Position of the patient

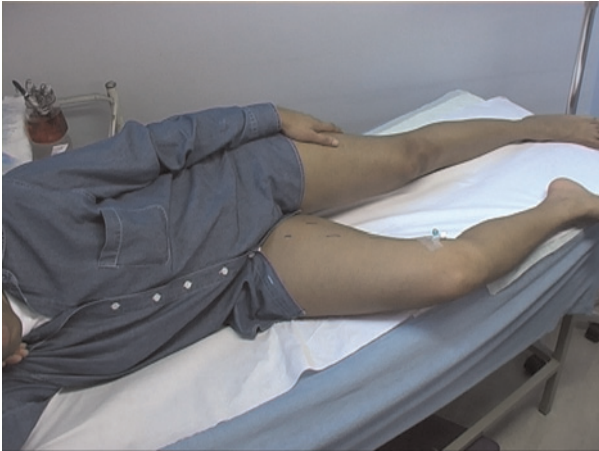The patient is positioned supine before placing any needle or cannula to minimize the risk of syncope. The small saphenous veins (SSVs) are most easily accessed with the patient lying on his left side, facing away from the surgeon. The leg to be treated is moved towards the operator as shown in Figure 2. For the left GSV, the same position works well. The left leg is drawn towards the operator giving easy access to the medial aspect of the thigh and calf. For the right GSV, the patient lies on their right side (Figure 3).

## Ultrasound-guided cannulation

Both saphenous trunks and major tributaries are treated through an intravenous cannula or Butterfly needle. All cannulae and butterflies are positioned before any foam is injected. This allows confirmation that the cannula is in the vein at all times, by flushing with saline. Once foam is injected it spreads rapidly to many superficial veins, which makes further ultrasound-guided injection more difficult. Superficial varices do not need ultrasound



**Figure 2** The patient lies in the left lateral position for treatment of the right small saphenous vein. The left small and long saphenous veins are also accessible in this position



**Figure 3** The patient lies in the right lateral position to permit cannulation of the right great saphenous vein

guidance and can be treated by direct needle injection without prejudicing safety or efficacy.

### Strategy for primary GSV varices

In those cases where the GSV lies in the saphenous compartment throughout the thigh, an 18 g cannula is placed in the GSV in the lower third of the thigh. This will treat the vein between the injection point and the SFJ. If the GSV lies more superficially in part of its track, this is strictly speaking an accessory vein and not the main saphenous trunk. It is better to inject less strong sclerosants here. Is there an 18 g cannula positioned in the saphenous trunk where it lies within the saphenous fascia? A Butterfly needle is then placed in the superficial accessory vein, usually in the distal third of the thigh. Any further accessory veins in the region of the GSV are treated by placing further Butterflies in them. These may be the source of recurrence if left untreated.

Next, any major tributaries of the GSV in the thigh are identified, especially those above the level of cannulation of the GSV. Larger tributaries (3 mm diameter and above) may supply enough venous flow to the GSV to keep it open above the level of the junction of the GSV with its tributaries. They can be managed by direct needle injection with foam.

In the calf, a 23 g Butterfly needle is used to cannulate the saphenous trunk and any varices, again inserting all cannulae and Butterflies before any treatment is commenced. In patients with primary varicose veins, between two and six cannulations are required to treat GSV reflux and associated varices.

### Primary SSV varices

SSV varices are usually much less complex to treat than GSV varices, since they have fewer tributaries and accessory veins. With the patient lying in the left lateral position the SSV is punctured in the mid-calf region using an 18 g cannula. This avoids making an injection in the popliteal fossa and inserting foam close to the popliteal vein. A 23 g Butterfly is used to treat the distal SSV. Varices can be managed using a further Butterfly or by direct needle injection; two or three cannulations are usually needed for the management of SSV varices.

### Combined GSV and SSV reflux

In patients where both the GSV and SSV are incompetent, both veins are cannulated in order to treat the two saphenous trunks in one session. More limited treatment of superficial varices may be required to minimize the number of cannulations and volume of foam injected during the first treatment session.

### Incompetent perforating veins

In the calf, most incompetent perforating veins can be managed by cannulation of a superficial vein immediately fed from the perforator. This works for ankle (Cockett's) perforators as well as more proximal paratibial perforating veins. STS 3% in liquid form is an alternative for medial calf perforators, which may help to avoid producing thrombosis in the posterior tibial veins. Foam is used for proximal calf perforating veins, popliteal fossa perforators and perforating veins in the thigh. In the popliteal fossa, the cannula is positioned within the perforator so that its tip lies at or near the fascial opening. Medial thigh perforating veins are cannulated with an 18 g cannula to ensure reliable injection of the source of varices.

### Treatment – injecting the foam

Superficial varices are injected first with 1% sclerosant foam using a syringe and 30 or 25 g needle; 1 mL is given per injection and the foam is distributed to varices near the point of injection by massaging the leg with the ultrasound probe or by hand. Next, all the previously placed Butterflies and cannulae are injected with foam, working from the calf towards the groin. The leg should be elevated well above the heart to minimize the diameter of the veins – this achieves Fegan's 'empty vein' although

it is not universally used by sclerotherapists. No more than 2 mL of foam should be injected at a time, even into the largest veins. In small veins in the calf injection of 1 mL at a time may be adequate.

After each injection of foam, the patients are asked to perform a series of ankle dorsiflexions to clear any foam which has reached the deep veins. Foam always reaches the deep veins within a few moments of injection. There is significant difference of opinion among Phlebologists over this point, some recommend that the patient lies still after injection of foam.

Further injections of 1–2 mL of foam into each needle and cannula reinforce the treatment already given. This strategy results in the veins being treated and then retreated. Retreatment has been suggested by French and Italian phlebologists as a way of achieving more effective sclerosis than a single injection. The first injection produces spasm of the treated vein and facilitates the passage of foam to more proximal veins with the subsequent injections.

The last vein to be treated is the GSV in the thigh for which 2 ml of 3% STS foam is injected, repeating this twice more making sure the patient dorsiflexes between each one. The extent of spread of the foam is monitored using duplex ultrasonography and injection is discontinued at any site where extravasation of foam is seen. Butterflies work well but sometimes cut through the side of the vein. The development of spasm in treated veins is widely regarded as a measure of success following sclerotherapy of a vein.

The total amount of foam required to treat the GSV in the thigh is usually 6 mL or 8 mL if it is a large vein. In the calf section of the GSV 2–4 mL of 1% STS foam is sufficient. In the SSV 4–6 mL of 3% STS foam is required depending on the size of the vein. Additional foam is required for accessory veins and varices. In perforating veins other than the medial ankle (Cockett's) perforators, 2–4 mL of 3% foam is used. Robust treatment of perforators is required to achieve a permanent result. For medial calf perforators connecting directly to the posterior tibial vein 1 mL of 3% liquid STS is needed.

### Compression following sclerotherapy

The treated leg is bandaged for 7–14 days using a short stretch cohesive bandage (PehaHaft, Hartmann, Germany). A compression roll is placed between the layers of the bandage to increase compression over the treated veins. Traditional crêpe

and elastocrêpe bandages are similar in price, but much thicker and the compression they apply diminishes rapidly. The bandage is secured with Medipore (3M Company, USA) 100 mm wide adhesive tape and covered with a Class 2 compression stocking. The compression regimen should be repeated after each treatment session. Using elastic compression stockings without bandaging may lead to excessive retained thrombus, thrombophlebitis and skin pigmentation over treated veins.

As with earlier practices in sclerotherapy, immediate ambulation and return to normal activity are encouraged. There is little need for time away from work. Patients are encouraged to bring a friend or relative to their treatment sessions to ensure that they can travel home safely. Provided that patients can flex their knee sufficiently, it is acceptable for them to drive since the leg is not normally painful or weak following treatment.

### Follow-up sessions

Patients should be reviewed two weeks following their first treatment, as this is the optimum time for managing any adverse consequences such as thrombophlebitis. Patients usually return having removed bandages themselves. The treated leg may be checked using duplex ultrasonography including visualization of the femoral and popliteal veins for any thrombus, although this is rarely seen. Veins and saphenous trunks containing excessive amounts of thrombus can readily be managed by aspiration. The patient is positioned supine and a 5 mL syringe and a 19 g needle (with local anaesthetic if necessary) can be inserted into saphenous trunks or varices under ultrasound guidance or by palpation. Aspiration rapidly resolves painful veins and lumps and minimizes the risk of skin pigmentation. Any residual segment of vein can be managed by further foam sclerotherapy, as described above. Re-bandaging the leg in the region of further sclerotherapy is usually appropriate.

### Management of problems following foam sclerotherapy

The most frequent problem is thrombophlebitis. This can be managed by compression and analgesia combined with aspiration of thrombus as described above.

Occasionally, STS foam is injected outside a vein due to a technical problem with a cannula. This results in an inflammatory lump at the injection

site, which resolves completely over two weeks. Injection site ulcers are rare since ultrasound monitoring of treatment allows discontinuation of injection where extravasation has occurred. POL is much safer in this respect. It causes no significant problem if injected at low concentrations and amounts outside the vein. Extravascular injection of sclerosant foam usually causes pain during injection, and treatment should then be stopped while the position of the cannula is checked.

DVT has been seen occasionally after this treatment, most frequently affecting the calf veins. This should be managed conventionally with compression and exercise or heparin/warfarin anticoagulation if it extends to major veins using local hospital protocols.

### Systemic complications

Visual disturbance occurs in about 2% of patients and is probably dose-related. This occurs following both liquid and foam sclerotherapy, but is more frequent after foam. It often occurs in patients who have a previous history of migraine, but may occur in anyone. A scotoma develops associated with other visual phenomena such as a ground glass appearance in part of the visual field and irregular coloured patterns. This resolves within 30 minutes in most patients. It is highly likely to return in subsequent sessions of treatment; it is suggested that affected patients lie supine for up to 30 minutes following injection of foam to try and prevent this problem.

Some patients may develop tightness in the chest or coughing after foam. This is probably a direct effect of the foam on the lungs and can also occur following injections of liquid sclerosant. This also resolves in about 30 minutes. Again, lying supine for some time after treatment may be useful. The incidence of visual disturbance and chest symptoms has been reported to be reduced by using CO<sub>2</sub> foams.<sup>20</sup>

Severe allergic reactions may follow injection of either of the sclerosants mentioned here. Appropriate drugs and equipment must be available to manage this problem.

### Cost of treatment

Foam sclerotherapy is relatively inexpensive. With the exception of the ultrasound machine, no complex or specialist equipment is required. The consumable items require a cost of about £30 per session and the use of expensive facilities,

such as a fully staffed operating theatre, is avoided. The staff required to complete the treatment include a surgeon or other expert practitioner and a vascular scientist or nurse assistant. These advantages are mitigated by the need for additional sessions of treatment to monitor the outcome, treat residual varices and manage retained thrombus. This is the least complex and most economical of all treatments for varicose veins.

### Sclerotherapy for superficial varices and telangiectases

Conventional liquid sclerotherapy is useful in the management of isolated small superficial varices not associated with truncal saphenous incompetence. Foam treatment has little advantage here and ultrasound guidance is unnecessary.

A frequent problem is patients who present with reticular varices and telangiectases. Reticular varices can be managed surgically, but better outcomes are usually obtained by sclerotherapy. All patients should be checked for the presence of saphenous truncal incompetence or other possible sources of varices by duplex ultrasonography. This commonly reveals an underlying problem which may lead to an unsatisfactory outcome if it is ignored. Most saphenous trunks and varices can be managed by foam sclerotherapy where they play a significant part in the development of reticular varices and telangiectases.

The detailed management of telangiectases is beyond the scope of this article. In summary, small veins are probably best managed by liquid, rather than foam sclerotherapy. Foam sclerosants tend to be very strong and can cause even more telangiectases to develop if injected over-enthusiastically. Most publications mention the injection of 0.25–0.5% POL as being the most appropriate. STS 0.2% may also be used with similar outcomes.<sup>21</sup> In Europe chromated glycerine is commonly used and a randomized trial has been published comparing this to POL and POL foam.<sup>22</sup> Allergy to metals is fairly common among adults; so methods to manage allergies should be available.

A wide range of practitioners, including surgeons, general practitioners, dentists, nurse specialists and beauticians, treat telangiectases in the UK. Very few adverse events occur. However, a good result can only be expected when the methods employed by European phlebologists are used.<sup>23</sup> The essence is to treat the 'feeding veins' as well as the telangiectases. The feeding veins comprise the reticular veins that drain the telangiectases,

plus any incompetent saphenous veins. A region of telangiectases is selected and reticular veins in this area are injected with 0.5% POL liquid, injecting 0.25–0.5 mL at each location. Sclerosant will often enter telangiectases following this, demonstrating that the valves in the reticular veins are incompetent. Then all telangiectases in the affected area should be injected with small amounts of 0.5% POL using 0.1–0.2 mL at each site. This treatment is a skill best learnt from an experienced practitioner.

If the reticular varices are not treated, a reasonable outcome will be obtained in about half of patients, but may not be sustained. The other half of patients may obtain a disappointing outcome or more telangiectases may develop.

The use of compression following sclerotherapy for small veins varies widely. A recent randomized trial shows that it is of value<sup>24</sup> and it is advised that patients wear Class 2 compression stockings for at least three days after injecting telangiectases and reticular varices.

## Outcomes

A detailed review of the outcomes of ultrasound-guided foam sclerotherapy has been published recently.<sup>25</sup> Some important publications and more recent data are discussed below.

Cabrera *et al.*<sup>26</sup> has published a clinical series of 500 legs treated by foam sclerotherapy. He reported that after three or more years 81% of treated great saphenous trunks remained occluded and 97% of superficial varices had disappeared. This required one session of sclerotherapy in 86% of patients, two in 11% and three sessions in 3% of patients. No DVT or pulmonary embolism was encountered in this series. Subsequently, a number of authors have published clinical series based on this technique including Frullini and Cavezzi,<sup>27</sup> who reported a series of 453 patients, and Barrett *et al.*,<sup>28</sup> who reported a series of 100 limbs. Cavezzi *et al.*<sup>29</sup> has subsequently published a detailed analysis of the efficacy of foam sclerotherapy in 194 patients, reporting a good outcome in 93% of patients. In fact, this technique has become widely used in southern Europe, Australia, New Zealand, South America and the USA.<sup>11</sup> However, few surgeons in the UK use this method perhaps because of limited evidence of efficacy. One series has been recently reported from the UK involving 60 patients comparing surgical treatment with foam sclerotherapy combined with saphenofemoral ligation.<sup>30</sup>

One randomized study of foam sclerotherapy in comparison with surgery has been published. This was a multicentre European study.<sup>31</sup> This randomized controlled trial included two separate studies: a surgical part undertaken by surgeons who randomized patients to saphenous stripping or ultrasound-guided foam sclerotherapy. In addition, sclerotherapists randomized patients to ultrasound-guided sclerotherapy conducted using either foam or liquid sclerosant. In all, 654 patients were treated during this study. Up to four sessions of ultrasound-guided foam sclerotherapy were allowed over three months to obliterate the saphenous trunks. After 12 months, the surgeons had eliminated truncal saphenous reflux in 130 of 176 patients (74%) by foam sclerotherapy and in 84/94 (88%) by surgery. In comparison, sclerotherapists had eliminated reflux in 239 of 254 patients (91%) by foam and 104/125 (83%) by liquid sclerotherapy. Post-treatment pain was assessed by a visual analogue scale, which showed that surgery was much more painful during the first week. Normal activities were resumed after a median of 13 days in the surgery group and two days in the foam group. DVT was seen in 10 patients treated by foam and one patient treated by liquid sclerotherapy.

A personal experience of the use of ultrasound-guided foam sclerotherapy based on an analysis of all patients treated for varicose veins between January 2002 and August 2005 has been published.<sup>32</sup> A total of 808 patients (666 women, 142 men) were managed by ultrasound-guided foam sclerotherapy for truncal saphenous incompetence. Thrombophlebitis occurred in a small number of patients (5%) and was managed by analgesia, compression and aspiration of thrombus. Calf vein thrombosis was confined to isolated gastrocnemius veins or to part of the posterior tibial vein (10 cases). All resolved with compression by stocking or bandage and exercise without use of anticoagulants. In one case, a short occlusive thrombus arose in the common femoral vein two weeks following treatment of the GSV. The mechanism appeared to be due to direct extension of thrombus from the GSV into the femoral vein. This was managed by anticoagulation using low-molecular weight heparin and warfarin continued for six months. The occluded femoral vein recanalized within four weeks and at six months follow-up no residual scarring or valve damage could be demonstrated on duplex ultrasonography. In two further cases thrombus extended from the SFJ and SPJ (one case each) into the femoral and popliteal vein. The extent of the thrombus was limited and firmly adherent to the vein wall. This was managed by compression stockings and



exercise while monitoring the extent of the thrombus by serial duplex ultrasonography.

In all, 457 legs have been reviewed at six months or more following treatment (average 11 months, range 6–46 months). This includes 367 of 886 GSV and 145 of 263 SSV which had been treated. A substantial improvement in clinical venous disease was obtained. Duplex examination of the GSV showed that occlusion had been obtained in 322 of 364 (88%). In the SSV occlusion was present in 118 of 143 (83%). The median diameter of the GSV and SSV fell from 5 mm before treatment to GSV: 2 mm and SSV: 1 mm at follow-up of six months or more.

The only residual adverse events still present at six months or more of follow-up were skin pigmentation and palpable lumps. Skin pigmentation was seen in 115 of 457 legs reviewed after six months and palpable lumps were present in 21 legs. The skin pigmentation was almost always minor and continued to fade with the passage of time. In those patients reviewed one year or more following treatment, skin pigmentation was present in 11 of 115 legs. Small palpable lumps were sometimes detectable in the calf and comprised residual elements of treated veins. These could be identified by ultrasound imaging, but were not otherwise visible. In contrast to surgery, no scars, neurological damage or lymphatic injuries were encountered.

The relative efficacy of foam and liquid sclerotherapy has been investigated in a detailed study.<sup>33</sup> Patients with truncal saphenous incompetence were injected with either 2–2.5 mL of 3% POL liquid or foam into the GSV under ultrasound guidance, on only one occasion. Obliteration of saphenous incompetence was obtained in 35% of liquid-treated patients and 85% of foam-treated patients after three weeks. At two years 53% of foam-treated and 12% of liquid-treated patients had successful obliteration of the GSV. A further study was performed to assess the relative efficacy of 1% and 3% sclerosant foam.<sup>34</sup> Patients with truncal saphenous reflux were randomized to treatment with either 1% or 3% POL foam, in a single session. An average of 4.5 mL of foam was injected in both groups. Immediate occlusion rates were 96% (3% foam) and 86% (1% foam). After two years saphenous occlusion was seen in 69% of the 3% group and 68% of the 1% group. In both of these studies, a rather small volume of foam was used compared with the maximum of 10 mL recommended in the Tegernsee document<sup>12</sup> and 20 mL that I have suggested above was used. This probably prejudiced the outcome but allowed the authors to demonstrate clearly the advantages of foam and lack of increased efficacy with 3% POL.

A number of papers have addressed particular problems in the management of varicose veins. Recurrent varices managed surgically have a poor outcome with further recurrence from neovascularization as a common feature.<sup>35</sup> The clinical series mentioned above found similar outcomes in primary and recurrent varices managed by foam sclerotherapy, with 88% of SFJs and saphenous trunks remaining obliterated at 11 months of follow-up.<sup>32</sup> Creton and Uhl<sup>36</sup> have reported a combined surgical and foam sclerotherapy technique (in one session) for patients with recurrent varices, with obliteration of 93% of varices and saphenous trunks at 40 days of follow-up. Perrin and Gillet<sup>37</sup> have reviewed the available literature on recurrent varices of the popliteal fossa and concluded that, unless a grossly incompetent SPJ stump is present, ultrasound-guided foam sclerotherapy is the most appropriate treatment. They acknowledge that this conclusion is supported by reports of clinical series and not randomized clinical trials.

A number of papers have discussed the outcome of foam sclerotherapy in patients with venous ulceration and severe venous disease. In one study, 185 limbs with venous disease (CEAP C4–6: 109 limbs, CEAP C1–3: 76 limbs).<sup>38</sup> In about three-quarters of patients in both groups, the saphenous trunk remained obliterated at six months. The authors conclude that foam sclerotherapy is equally applicable in complicated and uncomplicated venous disease. The clinical outcome of treatment has been reported in a number of papers.<sup>39–41</sup> In general, rapid healing of ulcers is reported following foam sclerotherapy confirming that this treatment can probably achieve the same outcomes that result from saphenous obliteration in leg ulcer patients.

Systemic complications of foam sclerotherapy have been examined in some detail in view of occasional visual disturbance reported by some patients following both foam and liquid sclerotherapy.<sup>42</sup> Visual disturbance has been reported following the injection of a range of liquid sclerosants although it is clear that it is far more common following foam sclerotherapy. Some serious neurological adverse events, from which recovery was eventually complete have been reported.<sup>43</sup> This has led to attention focussing on the effects of a patent foramen ovale. This was the subject of a study by Morrison, in which 20 patients with visual or respiratory symptoms following foam sclerotherapy were studied by trans-thoracic echocardiography during treatment and 65% were found to have echoes in the left atrium after injection of foam sclerosant. Five of nine patients who then underwent transcranial Doppler investigation

during foam sclerotherapy were found to have high-intensity events in the middle cerebral artery during treatment. Clearly, gas bubbles injected in the lower limb may reach the cerebral circulation, but the relationship to this phenomenon to the visual disturbance reported in some patients is yet to be established. Morrison has also reported the outcome of treating patients with foam made with carbon dioxide in comparison with air foam. This resulted in a substantial reduction in visual and other adverse events following treatment. It seems logical to consider moving to CO<sub>2</sub> foams to minimize these side-effects, even if they are usually benign and resolve swiftly. In general, the number of serious adverse events is very small compared with the number of treatments which have been done. These remind us that even minimally invasive treatments may have significant side-effects and that we shall take all reasonable precautions to prevent these.

One study has examined the relative efficacy of minimally invasive means of treating incompetent saphenous trunks in comparison with surgical management.<sup>44</sup> A meta-analysis of 119 studies including 12,320 limbs was undertaken. The main outcome measure was obliteration of the saphenous trunk as assessed by duplex ultrasonography at an average of 30 months following treatment. A small advantage in favour of endovenous laser ablation was found, but the authors concluded that surgery and endovenous laser ablation, endovenous RF ablation and ultrasound-guided foam sclerotherapy are equally effective.

## Conclusions

There is sufficient evidence to conclude that ultrasound-guided foam sclerotherapy is a safe and effective treatment for superficial truncal saphenous incompetence as well as for varices. This treatment is suitable for the management of primary uncomplicated varices, recurrent varicose veins and patients with lipodermatosclerosis. The majority of clinical series published so far have limited follow-up (3 years at most), so the five-year clinical outcome remains uncertain at present.

## Conflict of interest

The author hereby declares no conflict of interests.

## References

- 1 Hobbs JT. Surgery or sclerotherapy for varicose veins: 10-year results of a random trial. In: Tesi M, Dormandy

- JA, eds. *Superficial and Deep Venous Diseases of the Lower Limbs*. Turin, Italy: Panminerva Medica, 1984:243–8
- 2 Fegan WG. Injection with compression as a treatment for varicose veins. *Proc R Soc Med* 1965;**58**:874–6
- 3 Schadeck M, Allaert F. Echotomographie de la sclérose. *Phlébologie* 1991;**44**:111–30
- 4 Vin F. Echo-sclérothérapie de la veine saphène externe. *Phlébologie* 1991;**44**:79–84
- 5 Bishop CC, Fronek HS, Fronek A, Dilley RB, Bernstein EF. Real-time color duplex scanning after sclerotherapy of the greater saphenous vein. *J Vasc Surg* 1991;**14**:505–8
- 6 Kanter A, Thibault P. Dermatol saphenofemoral incompetence treated by ultrasound-guided sclerotherapy. *Surgery* 1996;**22**:648–52
- 7 Cabrera Garido JR, Cabrera Garcia Olmedo JR, Garcia Olmedo Dominguez. Nuevo método de esclerosis en las varices tronculares. *Patologia Vasculares* 1995;**1**:55–72
- 8 Foote RR. *Varicose Veins*. London: Butterworth & Co., 1949:1–225
- 9 Orbach EJ. The thrombogenic activity of foam of a synthetic anionic detergent (sodium tetradecyl sulfate NNR). *Angiology* 1950;**1**:237–43
- 10 Cabrera Garrido JR, Cabrera Garcia-Olmedo JR, Garcia-Olmedo Dominguez MA. Elargissement des limites de la sclérothérapie: nouveaux produits sclérosants *Phlébologie* 1997;**50**:181–8
- 11 Breu FX, Guggenbichler S, Wollmann JC. 2nd European Consensus Meeting on Foam Sclerotherapy, 2006. Tegernsee, Germany, VASA 2008;**3 Suppl 1**:1–29
- 12 Breu FX, Guggenbichler S, Wollmann JC. Second European Consensus Meeting on Foam Sclerotherapy. Duplex ultrasound and efficacy criteria in foam sclerotherapy from the Second European Consensus Meeting on Foam Sclerotherapy 2006, Tegernsee, Germany. VASA 2008;**37**:90–5
- 13 Monfreux A. Traitement sclérosant des troncs saphéniens et leurs collatérales de gros calibre par le méthode mus. *Phlébologie* 1997;**50**:351–3
- 14 Sadoun S, Benigni JP. The treatment of varicosities and telangiectases with TDS and Lauromacrogol foam. XIII World Congress of Phlebology, 1998. Conrad P, Myers K, eds. Abstract book. International Union of Phlebology, Sydney, 1998
- 15 Tessari L. Nouvelle technique d'obtention de la scléromousse. *Phlébologie* 2000;**53**:129
- 16 Frullini A. New technique in producing sclerosing foam in a disposable syringe. *Derm Surg* 2000;**26**:705–6
- 17 Flückinger P. Nicht-operative retrograde Varizenverödung mit Varsylschaum. *Schweizer Med Wochenschrift* 1956;**86**:1368–70
- 18 Forlee MV, Grouden M, Moore DJ, Shanik G. Stroke after varicose vein foam injection sclerotherapy. *J Vasc Surg* 2006;**43**:162–4
- 19 Ceulen RP, Sommer A, Vernooij K. Microembolism during foam sclerotherapy of varicose veins. *N Engl J Med* 2008;**358**:1525–6
- 20 Morrison N, Neuhardt DL, Rogers CR, et al. Comparisons of side effects using air and carbon dioxide foam for endovenous chemical ablation. *J Vasc Surg* 2008;**47**:830–6
- 21 Goldman MP. Treatment of varicose and telangiectatic leg veins: double-blind prospective comparative trial between aethoxyskerol and sotradecol. *Dermatol Surg* 2002;**28**:52–5
- 22 Kern P, Ramelet AA, Wutschert R, Bounameaux H, Hayoz D. Single-blind, randomized study comparing

- chromated glycerin, polidocanol solution, and polidocanol foam for treatment of telangiectatic leg veins. *Dermatol Surg* 2004;**30**:367–72
- 23 Guex JJ. Microsclerotherapy. *Semin Dermatol* 1993;**12**: 129–34
- 24 Kern P, Ramelet AA, Wütschert R, Hayoz D. Compression after sclerotherapy for telangiectasias and reticular leg veins: a randomized controlled study. *J Vasc Surg* 2007;**45**:1212–6
- 25 Jia X, Mowatt G, Burr JM, Cassar K, Cook J, Fraser C. Systematic review of foam sclerotherapy for varicose veins. *Br J Surg* 2007;**94**:925–36
- 26 Cabrera J, Cabrera J Jr, Garcia-Olmedo MA. Treatment of varicose long saphenous veins with sclerosant in microfoam form: long-term outcomes. *Phlebology* 2000;**15**: 19–23
- 27 Frullini A, Cavezzi A. Sclerosing foam in the treatment of varicose veins and telangiectases: history and analysis of safety and complications. *Dermatol Surg* 2002;**28**:11–15
- 28 Barrett JM, Allen B, Ockelford A, Goldman MP. Microfoam ultrasound-guided sclerotherapy of varicose veins in 100 legs. *Dermatol Surg* 2004;**30**:6–12
- 29 Cavezzi A, Frullini A, Ricci S, Tessari L. Treatment of varicose veins by foam sclerotherapy: two clinical series. *Phlebology* 2002;**17**:13–18
- 30 Bountouroglou DG, Azzam M, Kakkos SK, Pathmarajah M, Young P, Geroulakos G. Ultrasound-guided foam sclerotherapy combined with sapheno-femoral ligation compared to surgical treatment of varicose veins: early results of a randomised controlled trial. *Eur J Vasc Endovasc Surg* 2006;**31**:93–100
- 31 Wright D, Gobin JP, Bradbury AW, et al.; the Varisolve® European Phase III Investigators Group. Varisolve® polidocanol microfoam compared with surgery or sclerotherapy in the management of varicose veins in the presence of trunk vein incompetence: European randomized controlled trial. *Phlebology* 2006;**21**:180–90
- 32 Coleridge Smith P. Chronic venous disease treated by ultrasound guided foam sclerotherapy. *Eur J Vasc Endovasc Surg* 2006;**32**:577–83
- 33 Ouvry P, Allaert FA, Desnos P, Hamel-Desnos C. Efficacy of polidocanol foam versus liquid in sclerotherapy of the great saphenous vein: a multicentre randomised controlled trial with a 2-year follow-up. *Eur J Vasc Endovasc Surg* 2008;**36**:366–70
- 34 Hamel-Desnos C, Ouvry P, Benigni JP, et al. Comparison of 1% and 3% polidocanol foam in ultrasound guided sclerotherapy of the great saphenous vein: a randomised, double-blind trial with 2 year-follow-up. 'The 3/1 Study'. *Eur J Vasc Endovasc Surg* 2007;**34**:723–9
- 35 Winterborn RJ, Foy C, Heather BP, Earnshaw JJ. Randomised trial of flush saphenofemoral ligation for primary great saphenous varicose veins. *Eur J Vasc Endovasc Surg* 2008;**36**:477–84
- 36 Creton D, Uhl JF. Foam sclerotherapy combined with surgical treatment for recurrent varicose veins: short term results. *Eur J Vasc Endovasc Surg* 2007;**33**:619–24
- 37 Perrin M, Gillet JL. Management of recurrent varices at the popliteal fossa after surgical treatment. *Phlebology* 2008;**23**:64–8
- 38 O'Hare JL, Parkin D, Vandebroek CP, Earnshaw JJ. Mid term results of ultrasound guided foam sclerotherapy for complicated and uncomplicated varicose veins. *Eur J Vasc Endovasc Surg* 2008;**36**:109–13
- 39 Hertzman PA, Owens R. Rapid healing of chronic venous ulcers following ultrasound-guided foam sclerotherapy. *Phlebology* 2007;**22**:34–9
- 40 Ergan J, Pascarella L, Mekenas L. Venous disorders: treatment with sclerosant foam. *J Cardiovasc Surg (Torino)* 2006;**47**:9–18
- 41 Pascarella L, Bergan JJ, Mekenas LV. Severe chronic venous insufficiency treated by foamed sclerosant. *Ann Vasc Surg* 2006;**20**:83–91
- 42 Guex JJ, Allaert FA, Gillet JL, Chleir F. Immediate and midterm complications of sclerotherapy: report of a prospective multicenter registry of 12,173 sclerotherapy sessions. *Dermatol Surg* 2005;**31**:123–8
- 43 Bush RG, Derrick M, Manjoney D. Major neurological events following foam sclerotherapy. *Phlebology* 2008;**23**: 189–92
- 44 van den Bos R, Arends L, Kockaert M, Neumann M, Nijsten T. Endovenous therapies of lower extremity varicosities: a meta-analysis. *J Vasc Surg* 2009;**49**:230–9