

Formulation, characterization, *in vitro*, *in vivo*, and histopathological evaluation of transdermal drug delivery containing norfloxacin and *Curcuma longa*

Kamal Dua, Srikumar Chakravarthi¹, Dinesh Kumar², Ravi Sheshala, Gaurav Gupta²

Departments of Pharmaceutical Technology, ²Life Sciences, School of Pharmacy, International Medical University, Bukit Jalil, Kuala Lumpur, ¹Department of Pathology, Perdana University Graduate School of Medicine, Serdang, Selangor, Malaysia

Abstract

Objective: In an attempt for better treatment of bacterial infections and burn wounds, semisolid formulations containing norfloxacin (NF) and natural wound healing agent *Curcuma longa* were prepared. The rationale behind employing combination of NF and *Curcuma longa* is to obtain synergistic wound healing effect. The prepared formulations were compared with silver sulfadiazine cream 1%, USP. **Materials and Methods:** Various ointments containing NF and *C. longa* were prepared using standard procedures. These formulations were evaluated for antimicrobial activity against various strains of aerobic and anaerobic microorganisms. The wound healing property was evaluated by histopathological examination and by measuring the wound contraction. **Results:** The significant antimicrobial and wound healing effects were demonstrated by formulations which are comparable with silver sulfadiazine 1% cream ($P < 0.05$). Various morphological changes were observed by histopathology during the study period (days 1, 4, 8, and 12) which also supported the wound healing process. **Conclusion:** Based on the observed antimicrobial and wound healing effects, the formulations containing combination of NF and *Curcuma longa* could be employed as an alternative to commercial silver sulfadiazine 1% cream. This innovative mode of formulation can be employed for making burn wound healing process more effective.

Key words: Burns, *Curcuma longa*, silver sulfadiazine, wounds

INTRODUCTION

Microorganisms that cause burn wound infections have changed over years related to changes made in the treatment of burn patients. Infection is a major complication of burn injury and is responsible for 50-75% of hospital deaths. A moist, thermally coagulated burn wound, with its constantly replenished supply of diffusing serum nutrients and warm surface temperature, provides an environment suitable for

rapid microbial growth. As local microbial growth increases, the potential for invasion to subjacent viable tissues and penetration into circulation increases.

Topical antibiotics can play an important role in prevention and treatment of many primary cutaneous bacterial infections commonly seen in dermatological practice like localized superficial infections due to surgery, injury, and abrasion. Topical antimicrobials help in preventing entry of microorganism into wound, which lead to fast healing of wounds.^[1,2]

Norfloxacin (NF), a broad-spectrum fluoroquinolone antibacterial agent, is commonly employed in the treatment of urinary and genital tract infections. It is a hydrophilic fluoroquinolone with unique physiochemical properties such as low water solubility and partition coefficient.^[3,4] *Curcuma longa* is reported to possess antibacterial and anti-inflammatory activity, which are complimentary to wound healing process.^[5,6]

The easy availability of *C. longa*, cost-effectiveness, and reduction of microbial resistance against NF; prompted us to formulate the topical formulations containing NF in combination with *C. longa* and to evaluate burn wound healing efficacy in comparison with marketed

Address for correspondence:

Dr. Kamal Dua,
Department of Pharmaceutical Technology,
School of Pharmacy and Health Sciences,
International Medical University, No. 126, Jalan 19/155B,
Bukit Jalil - 570 00, Kuala Lumpur, Malaysia.
E-mail: kamalpharmacist@gmail.com

Access this article online

Quick Response Code: 	Website: www.jpionline.org
	DOI: 10.4103/2230-973X.121287

silver sulfadiazine 1% cream, USP. The prepared formulations also aims to evaluate whether the combination of *C. longa* and antibiotic produce any synergistic effect on wound healing. *C. longa* has been traditionally used as a wound healer in ancient days. As a result of the discovery of newer antibiotics and related chemotherapeutic agents, use of *C. longa* went into total obscurity.^[5]

Ability of microorganisms to render themselves resistant to antibiotics necessitated search for newer agents. During such efforts it was noticed that *C. longa* promotes wound healing even without the application of antibiotics and its activity is almost parallel to antibiotic. This observation leads to the logical reasoning that combination of *Curcuma longa* with an antibiotic may provide better and efficient process of wound healing.

MATERIALS AND METHODS

Materials

NF (Pfiscar India Ltd., Murthal, Haryana); All other chemicals used were of analytical grade.

Methods

Preparation of topical formulations

Various semisolid formulations containing NF and *C. longa* were prepared, with different bases using standard procedures [Table 1]. In each of the formulations, NF and *C. longa*

was incorporated at 5 and 2% w/w concentration in the base with trituration using geometric dilution procedure to get a homogeneous mass.^[7-10]

Skin irritation test

Skin irritation was tested in order to find any allergic reactions caused by the application of topical/transdermal formulations. Six rabbits of either sex weighing 1.3-1.5 kg were used in this study. The abdominal hairs were removed by shaving, selected plaster formulation containing NF were applied on to the shaved skin of each rabbit and left in contact for 23 h daily for 22 days. The skin was observed regularly for the study period for erythema (reddening of the skin), inflammation, contact dermatitis, or any change.^[9]

Microbiological studies

The antibacterial activity of various semisolid formulations containing NF and *C. longa* against various strains of aerobic and anaerobic microorganisms was evaluated by standard cup- late method.^[10,11] *Bacillus subtilis*, *Staphylococcus aureus*, *Escherichia coli*, *Pseudomonas aeruginosa* (aerobic organisms), and *Bacteriodes fragilis* (anaerobic organism) were used for testing the antibacterial activity. Nutrient agar medium was used for aerobic bacterial cultures and blood agar medium was used for *Bacteriodes fragilis*. Plates with aerobic organisms were incubated at 37 ± 0.2°C for 24 h under aerobic conditions, while *Bacteriodes fragilis* cultures were incubated

Table 1: Composition of topical formulations of norfloxacin (NF) and *Curcuma longa*

Ingredients↓	Quantity in mg								
	F ₁	F ₂	F ₃	F ₄	F ₅	F ₆	F ₇	F ₈	F ₉
Norfloxacin (NF)	5.0	5.0	5.0	5.0	5.0	5.0	5.0	5.0	5.0
<i>Curcuma longa</i>	2.0	2.0	2.0	2.0	2.0	2.0	2.0	2.0	2.0
Sodium carboxymethyl cellulose (CMC)		5.0							
Cetostearyl alcohol					15			15.0	
Yellow beeswax					2.5	5.0		1.0	1.0
Carbopol 940	2.0								
Triethanolamine	q.s.								
Tween 80					5.5				
Borax						0.2			
Methyl paraben	0.15	0.2	0.3		0.2	0.2		0.2	
Ethyl paraben	0.05	0.1	0.2		0.1	0.1	10	0.1	
Sodium metabisulphite								0.1	
Sodium lauryl sulfate (SLS)								1.0	
Hard paraffin						7.0			
Hydroxypropyl methylcellulose (HPMC)			2.0						
Polyethylene glycol (PEG) 4000				49.0					
PEG 300				44.0					
Dimethyl sulfoxide (DMSO)							9.5		
Isopropyl myristate							8.0		
Mineral oil						44.0	30		
White petrolatum						10.0	29.7		82.0
Propylene glycol								9	
Span 60					7.5				
Wool fat									10.0
Beeswax							4.8		
Glycerine		22.0	8						
Water q.s.	100	100	100		100	100	1.0	66.6	

F₁: Carbopol gel base; F₂: Sodium CMC gel; F₃: HPMC gel; F₄: Macrogol gel; F₅: Water miscible base; F₆: Cold cream; F₇: Simple ointment base; F₈: Beller's ointment base; F₉: Oleagenous base

under carbon dioxide atmosphere in an anaerobic jar at $37 \pm 0.2^\circ\text{C}$ for 48 h. Inhibition zone diameters were measured with the help of zone reader (Digital Antibiotech Zone Reader, Effem Technologies).

Burn wound healing studies

The experiments were carried out as per the guidelines and prior approval of Animal Ethics Committee (KNMIPER/140305/878). Healthy Wistar albino rats weighing between 150 and 180 g were used for burn wound healing. The animals were divided into various groups, each group containing six animals. The untreated group was taken as control. The dorsum of each rat was shaved and the burn wounds were inflicted on overnight-starved animals under pentobarbitone sodium (6 mg/100 g, intraperitoneal (i.p.)), anesthesia. A 2×2 cm metal cylinder was placed on the shaven back of the animals. Melted wax at 80°C was poured into the metal cylinder and the wax was allowed to solidify. Eight minutes after this or until the wax was completely solidified, the metal cylinder containing wax adhering to the skin was gently removed to inflict a distinctly demarcated burn wound.^[12,13] In all cases, the burns were third degree, and the percentage was in one sample unit area according to the rule of nines, that is 9% of the body surface involved.

Selected topical formulation and the marketed silver sulfadiazine 1% cream USP (500 mg) were applied to the wound inflicted areas of animals every day from day 1 until day 12. The epithelialization period was monitored by recording the number of days required for eschar to fall off from the burn wound surface without leaving a raw wound behind. The animals were observed for wound healing by measuring the wound contraction (tracing the raw wound area on a transparent polythene paper which was retraced on graph paper (to assess the area) up to 12th day post wounding. The wound contraction was calculated as percentage of original wound size for each animal of a group.

The epithelialization period and wound contraction was observed in the study. The epithelialization period was monitored by recording the number of days required for eschar to fall off from the burn wound surface without leaving a raw wound behind.

Histopathological studies

The rats were anesthetized and the burned skin tissue samples were collected from rats (day 1, 4, 8, and 12) for histopathological examinations. The samples was fixed in 10% neutral buffered

formalin, and were cut into $5 \mu\text{m}$ sections and stained with hematoxylin and eosin (H and E), and examined by light microscopy for morphological changes. A histopathologist, blinded to the study was assigned to analyze and grade the histological changes of each group.^[14-17]

Statistical analysis

Data pertaining to antimicrobial and burn wound healing activity were expressed as mean \pm standard deviation (SD) and the data was analyzed by one-way analysis of variance (ANOVA) with Tukey's test for multiple comparisons using Jandel Sigma Stat statistical software, version 2.0. In all the analysis, $P < 0.05$ was considered as statistically significant.

RESULTS

Skin irritation test

The skin irritation study indicated that neither the drug nor its components caused any edema or inflammation in or around the application area during the period of study, however reddening of the skin was observed after 7th day, at the application site of formulation F₇. However, the reddening of the skin disappeared after the discontinuation. Reddening of the skin may be due to the presence of dimethyl sulfoxide (DMSO) in the formulation.

Antimicrobial activity

In this experiment, all the formulations produced marked antimicrobial activity as compared to silver sulfadiazine 1% cream USP as indicated by the inhibition zone diameter. Importantly, the formulations F₁ exhibited a significant and potential inhibitory effect on the growth of various strains of aerobic and anaerobic microorganisms as compared to other formulations ($P < 0.05$) [Table 2].

Burn wound healing activity

Mortality was not observed in the animals during the entire study period. The mean period of epithelialization for selected NF and *Curcuma longa* semisolid formulations was found to decrease significantly when compared to the control ($P < 0.05$; 36.9 ± 1.4 days).

A statistically significant increase in the percent burn wound contraction was observed with selected semisolid formulations treated animals during the observation period (days 4, 8, and 12)

Table 2: Antimicrobial activity of various selected semisolid formulations of norfloxacin and *Curcuma longa*

Formulation	Inhibition zone diameter (mm)				
	<i>Bacillus subtilis</i>	<i>Staphylococcus aureus</i>	<i>Escherichia coli</i>	<i>Pseudomonas aeruginosa</i>	<i>Bacteroides fragilis</i>
NF-CL F ₁	51.23 ^{a, b} (0.81)	53.72 ^{a, b} (0.94)	49.92 ^{a, b} (0.71)	48.13 ^{a, b} (0.75)	52.16 ^{a, b} (0.93)
F ₄	45.92 ^{a, b} (0.81)	45.13 ^{a, b} (0.91)	44.12 ^{a, b} (0.94)	45.12 ^{a, b} (0.92)	49.15 ^b (0.90)
F ₈	38.92 [*] (0.95)	36.13 [*] (0.75)	34.16 [*] (0.95)	35.17 [*] (0.75)	38.31 [*] (0.85)
Silver sulfadiazine 1% cream, USP	45.33 (0.78)	51.22 (0.86)	48.31 (0.72)	44.72 (0.98)	50.12 (0.92)

NF: Norfloxacin, CL: *Curcuma longa*. Values in parenthesis indicates the standard deviation ($n=6$). ^{*} $P < 0.05$ vs silver sulfadiazine 1% cream, USP. ^a $P < 0.05$ vs F₄, ^b $P < 0.05$ vs F₈

as compared to control. All the formulations including the silver sulfadiazine 1% cream USP had shown wound healing activity ($P < 0.05$) in rats. Burn wound healing studies revealed a maximum percent wound healing of $85.14 \pm 0.75\%$ with F_1 and $84.34 \pm 0.49\%$ with silver sulfadiazine formulation within 12 days [Table 3].

Histopathological studies

The various histopathological changes observed during the study period (day 1, 4, 8, and 12) are tabulated in Table 4 and illustrated in Figures 1-3.

DISCUSSION

Skin irritation test

The results obtained from the skin irritation studies demonstrate the suitability of the prepared topical dosage forms.

Antimicrobial activity

Formulations containing polyethylene glycol and carbopol gel base showed better larger zones of inhibition in comparison to other dermatological base formulations, indicating the better

Table 3: Percent burn wound contraction of various selected semisolid formulations of norfloxacin and *Curcuma longa*

Formulations ↓ Days →	% Wound contraction			Period of epithelialization (days)	
	4 th day	8 th day	12 th day		
NF-CL	Control	27.61* (1.33)	53.31* (1.22)	67.03* (0.92)	36.9* (1.4)
	NF ₁	52.15 ^{a, b, c, d, e, f} (1.46)	73.12 ^{a, b, c, d, e, f} (1.91)	85.14 ^{a, b, c, d, e, f} (0.75)	23.1 ^{a, e, f} (1.4)
	NF ₁ [#]	31.03* (1.84)	58.13* (0.37)	70.10* ^f (0.92)	31.3 ^{a, f} (1.2)
	NF ₄	49.13 ^{a, c, d, e, f} (1.77)	69.12 ^{a, c, d, e, f} (0.35)	80.13 ^{a, c, d, e, f} (0.66)	26.4 ^{a, e, f} (1.5)
	NF ₄ [#]	30.02* (1.30)	56.34* (0.24)	65.31* (0.73)	33.6 ^{a, a} (1.6)
	NF ₈	46.15 ^{a, a} (1.28)	62.14* ^f (1.21)	73.12* (0.75)	29.2 ^{a, a, f} (1.2)
	NF ₈ [#]	30.10* (0.72)	48.01* (0.29)	58.03* (0.29)	35.9* (1.2)
	Silver sulfadiazine 1% cream, USP	52.00 (1.45)	71.87 (0.98)	84.34 (0.49)	25.9 (1.3)

NF; Norfloxacin; CL=*Curcuma longa*. Values in parenthesis indicates the standard deviation (n=6). #Indicates the group treated with base alone. * $P < 0.05$ vs silver sulfadiazine 1% cream, USP, ^a $P < 0.05$ vs control %, ^b $P < 0.05$ vs F_1 , ^c $P < 0.05$ vs F_4 , ^d $P < 0.05$ vs F_8 , ^e $P < 0.05$ vs F_1 , ^f $P < 0.05$ vs F_4 , ^g $P < 0.05$ vs F_8

Table 4: Comparative evaluation of histopathological observations of selected norfloxacin and *Curcuma longa* semisolid formulations with silver sulfadiazine 1% cream, USP

Day	F_1	SS
1	Extensive ulceration and burns on the skin and subcutaneous tissue, with areas of necrosis, visible both grossly and microscopically	Presence of ulcer on surface due to injury, the base of the ulcer is filled with slough and necrotic debris
4	Abundant granulation tissue, scab formation, moderate proliferation of macrophages, neutrophils, and fibroblasts seen	Scab formed, beneath which a clot composed of fibrin, red blood cells (RBCs), and platelets are formed. Inflammatory cells like macrophages and neutrophils migrate to the site
8	Fibroblasts proliferation, collagen laying down, angiogenesis, neovascularization, and wound contraction seen	Areas of fibroblast proliferation, new blood vessel formation, wound beginning to contract
12	Wound contraction is increased, scar formation occurs, composed of collagen thickening and fibrosis. Cellularity is reduced, as inflammatory cells disappear.	Collagen is laid down significantly, inflammatory cells are reduced due to the healing process and presence of fibrous scar is noticed.

SS: Silver sulfadiazine 1% cream, USP

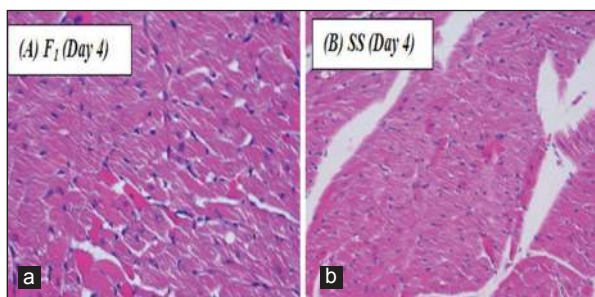


Figure 1: Microscopic appearance of burned skin on the 4th day. (a) F_1 treated (hematoxylin and eosin (H and E), 400x) area of wound showing coagulative necrosis. The cells show dense wavy cytoplasm and pyknotic cells. (b) (SS) treated (H and E, 400x) wounded area showing subcutaneous tissue and muscle showing necrotic cells with pink cytoplasm and scanty nuclei

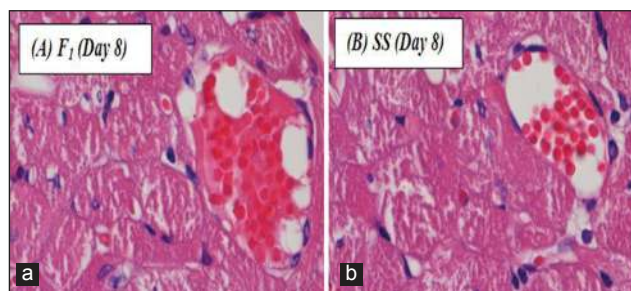


Figure 2: Microscopic appearance of burned skin on the 8th day. (a) F_1 treated (H and E, 1,000x) area of granulation tissue showing proliferating fibroblasts and new blood vessels filled with red blood cells (RBCs), amidst necrotic cells. (b) SS treated (H and E, 1,000x) area of healing showing proliferating fibroblasts and new blood vessels filled with RBCs, amidst necrotic cells

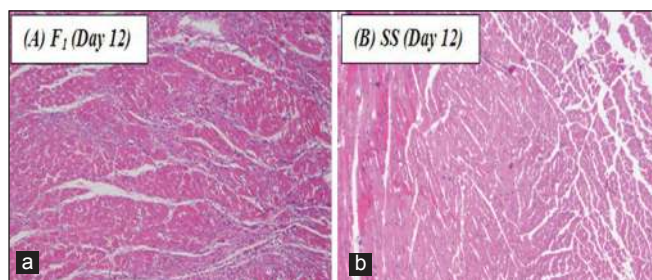


Figure 3: Microscopic appearance of burned skin on the 12th day. (a) F₁ treated (H and E, 100×) healing scar showing fibroblasts, fibrosis, macrophages amidst the scar area. (b) SS treated (H and E, 100×) area of scar formation, showing fibrous tissue due to laying down of collagen

activity of the drug. In creams, owing to their biphasic nature, partitioning of the drug occurs in two phases, resulting in slower release of drug; while in the case of gels, the drug diffusion occurred through the aqueous phase and hence they offer a greater drug diffusion and release.^[7,8]

Burn wound healing activity

In the past, many studies have been done using natural products for the treatment of burn wounds, but these were mainly aimed at controlling infections.^[14,15,17] Anti-inflammatory activity of certain natural products could also play a part in the healing of burn wounds.^[17] Although the present investigation did not explore the exact mechanism of prohealing of *C. longa*, it could be attributed to both anti-inflammatory and antiseptic properties. A clinical study showed that in the treatment of superficial and deep second-degree burns, addition of another prohealing agent like hyaluronic acid significantly overcame the disadvantages associated with silver sulphadiazine.^[16,17] Based on the above studies, we recommend that the incorporation of *C. longa* could significantly enrich the assortment of topical medications available on the market for the treatment of burn wounds and infection.

CONCLUSION

Formulations containing a combination of NF and *C. longa* were easy to prepare and prevent microorganisms recess on the wound. The antibacterial and wound healing activity of the formulations was comparable to that of the silver sulfadiazine 1% cream, USP, available in the market. Among all the semisolid formulations prepared, Carbopol gel base was found to be most suitable dermatological base in comparison with various other dermatological bases. It also has esthetic appeal, which other bases lack, an important aspect from patient compliance and consumer point of view. The therapeutic potential of such formulations may motivate researchers for its further exploitation for their commercial viability.

ACKNOWLEDGMENTS

The authors are very thankful to G.C.M. Laboratories, Chandigarh, India for their generous gift sample of norfloxacin. The authors also place on record their thanks to International Medical University, Kuala Lumpur, Malaysia.

REFERENCES

- Clewell A, Barnes M, Endres JR, Ahmed M, Ghambeer DK. Efficacy and tolerability assessment of a topical formulation containing copper sulfate and hypericum perforatum on patients with herpes skin lesions: A comparative, randomized controlled trial. *J Drugs Dermatol* 2012;11:209-15.
- Sushil S, Yogesh T, Chetan A, Lalit P, Naveen KP, Chhaya H, Gadgoli. Wound healing activity of topical application form based on herbomineral formulation. *Asian J Plant Sci Res* 2012;2:355-63.
- Reynolds JE, ed. *Martindale: The Extra Pharmacopoeia*. 29th ed. London: Pharmaceutical Press; 1989. p. 69.
- Dua K, Ramana MV, Sara UV, Himaja M, Agrawal A, Garg V, et al. Investigation of enhancement of solubility of norfloxacin beta-cyclodextrin in presence of acidic solubilizing additives. *Curr Drug Deliv* 2007;3:21-5.
- Akanksha D, Vikas G. Formulation and evaluation of neomycin sulphate ointment containing natural wound healing agent *Curcuma longa*. *Int J Pharm Sci Drug Res* 2009;1:116-8.
- Jagetia GC, Rajanikant GK. Role of curcumin, a naturally occurring phenolic compound of turmeric in accelerating the repair of excision wound, in mice whole-body exposed to various doses of gamma-radiation. *J Surg Res* 2004;120:127-38.
- Malipeddi VR, Dua K, Sara UV, Malipeddi H, Agrawal A. Comparative evaluation of transdermal formulations of norfloxacin with silver sulfadiazine cream, USP, for burn wound healing property. *J Burns Wounds* 2006;5:e4.
- Pabreja K, Dua K, Padi SS. Evaluation of extemporaneously manufactured topical gels containing aceclofenac on inflammation and hyperalgesia in rats. *Curr Drug Deliv* 2010;7:324-8.
- Dua K, Pabreja K, Ramana MV. Aceclofenac topical dosage forms: *In vitro* and *in vivo* characterization. *Acta Pharm* 2010;60:467-78.
- Anil K, Bhise SJ, Jarag RJ, Jadhav NR. Preparation of cream containing Tridax Procumbens, *Curcuma longa* and *Azadirachta Indica* and its evaluation for wound healing property. *Indian Pharm* 2005;41:107-10.
- Rodrigues KL, Caputo LR, Carvalho JC, Evangelista J, Schneedorf JM. Antimicrobial and healing activity of kefir and kefir extract. *Int J Antimicrob Agents* 2005;25:404-8.
- Srikanth D, Shenoy RR, Rao CM. The effects of topical (gel) astemizole and terfenadine on wound healing. *Indian J Pharmacol* 2008;40:170-4.
- Saraf S, Saraf S, Dixit VK. Transdermal Delivery of norfloxacin. *Ind Pharm* 2006;5:74-6.
- Muhammad HS, Muhammad S. The use of *Lawsonia inermis* Linn (heena) in the management of burn wound infections. *Afr J Biotechnol* 2005;4:934-7.
- Gregory SR, Piccolo N, Piccolo MT, Piccolo MS, Heggors JP. Comparison of propolis skin cream to silver sulfadiazine: A naturopathic alternative to antibiotics in the treatment of minor burns. *J Altern Complement Med* 2002;8:77-83.
- Koller J. Topical treatment of partial thickness by silver sulfadiazine plus hyaluronic acid compare to silver sulfadiazine alone: A double blind, clinical study. *Drugs Exp Clin Res* 2004;30:183-90.
- Srivastava P, Durgaprasad S. Burn wound healing property of *Cocos nucifera*: An appraisal. *Indian J Pharmacol* 2004;40:144-6.

How to cite this article: Dua K, Chakravarthi S, Kumar D, Sheshala R, Gupta G. Formulation, characterization, *in vitro*, *in vivo*, and histopathological evaluation of transdermal drug delivery containing norfloxacin and *Curcuma longa*. *Int J Pharma Invest* 2013;3:183-7.
Source of Support: Nil. **Conflict of Interest:** None declared.