

## Research Article

Deepika Venkataramani\*, Jeyalakshmi Veeranan, and Latha Pitchai

# Fractal analysis of retinal vasculature in relation with retinal diseases – an machine learning approach

<https://doi.org/10.1515/nleng-2022-0233>  
received April 6, 2022; accepted July 20, 2022

**Abstract:** Diabetic retinopathy (DR) is caused by diabetes mellitus. Vision loss occurs as a result of DR. The goal of this study was to use the DIARETDB-1, DIARETDB-0, STARE, MESSIDOR, E-ophtha-EX, and E-ophtha-MA databases to do Fourier fractal analysis and see how it is related to retinal illnesses. Following the extraction and inversion of colour channels, blood vessel augmentation was conducted. For the blood vessel enhanced image, the fractal dimension was determined. For DR patients and normal patients, measures such as standard deviation, mean, and significance were calculated. In the E-ophtha-EX database, significance was realized. In the DIARETDB-1, STARE, and DIARETDB-0 databases, the mean fractal value for normal patients is higher than for DR patients. The STARE database's forecast of the association between fractal dimensions and various retinal disorders and the E-ophtha-EX database's accomplishment of significance are the study's main highlights. This study also improved the robustness of the blood vessel extraction there and increased the accuracy of its diagnosis.

**Keywords:** blood vessel enhancement, Fourier fractals, diabetic retinopathy

## 1 Introduction

Many important eye diseases as well as systemic diseases manifest themselves in the retina. Diseases such as diabetic

retinopathy (DR), glaucoma, and macular degeneration are predominant. DR is caused by changes in the blood vessels of the retina and prolonged type-2 diabetes. It is common in both the genders. The indications of DR are hard and soft exudates, microaneurysms, macular edema, neovascularization, and haemorrhages. The abnormal permeability of retinal blood vessel results in formation of microaneurysm. Computer-aided diagnosis has served as a boon for early detection and diagnosis for retinal diseases. It helps the physician to enhance his diagnostic opinion on image interpretation and proceed with appropriate treatment. Retinal imaging helps to assess retinal vasculature, identify retinal lesions, and analyse the retinal morphology and shape to diagnose DR. Multifarious structure in retina is due to non-linear retinal branching pattern. Vascular changes in retina are related to DR, hypertension, and risk of macular edema [1–8]. Long-term diabetes leads to DR which in turn leads to vision loss [9,10]. Retinal images have been evaluated to spot vascular and non-vascular pathologies in retina. To inhibit vision loss, deviations in blood vessel pattern can be identified quickly [11,12].

Analysis of retinal images is very important for diagnosing the diseases related to the eye. Early recognition of these changes in the blood vessel patterns makes it possible to provide early intervention so as to prevent blindness. Diagnosing the prognosis of DR is very important for deciding the course of the treatment and the stage of DR. Early detection and monitoring the progress of the disease are crucial aspects in DR and this forms the motivation of this study. There is a lack of a suitable diagnostic method for analysing the retinal images. So, there is a dire need to examine the retinal images precisely for effective diagnosis and treatment. Diagnosis of DR requires a predictive modelling approach. Fractal dimensions play a vital role in analysing the various medical data as well as images. Its effectiveness is also good in diagnosing retinal diseases. Moreover, no trials have been carried out so far to study the behaviour of fractals in blood vessel enhanced retinal images. Hence in this study it was proposed to use fractal dimensions for analysing blood vessel enhanced retinal images.

\* **Corresponding author: Deepika Venkataramani**, Department of ECE, Anna University, Chennai, Tamil Nadu, India, e-mail: vdeepika121993@gmail.com

**Jeyalakshmi Veeranan:** Department of ECE, Anna University, Chennai, Tamil Nadu, India, e-mail: jpjeya@annauniv.edu

**Latha Pitchai:** Department of EEE, Government College of Engineering, Tirunelveli, Tamil Nadu, India, e-mail: platha@gcety.ac.in

Measurement of fractal dimension of retina can be indicated using DR [11–13]. Few studies show that fractal dimension is low for pathological images [14–16]. A fractal is a kind of geometric representation. Fractals allow the description of entities which divide frequently [17,18]. Fractal analysis is done to estimate fractal characters. Fractal dimensions are useful in analysing the structural differences and abnormalities. Fractals are of two types which include the monofractals, which are ordinary fractals, and multifractals, which are a grouping of monofractals. These multifractals give rise to an exponential value. Fractal dimension is obtained as a single value in the case of monofractals. Box counting, Hausdorff fractal dimension (HFD), Fourier fractal dimension (FFD), and modified Hausdorff fractal dimension are the frequently used fractal analysis techniques [19–22]. They are widely used in various medical applications. Box counting is used for lung cancer detection [23]. FFD is used for quantifying electroencephalograms for a group of children with problem of attention [24].

Monofractals are preferred in this study as a single value would serve as a threshold and help in differentiating between the diseased and normal images. In retinal image analysis, the blood vessels in the image have to be extracted or enhanced to aid better visualization and prediction. Existing studies focus on retinal image analysis using HFD. Application of HFD to retinal images requires the process of blood vessel extraction. But blood vessel extraction is a time-consuming process and may end up in computational complexity. Moreover, HFD may not yield better accuracy in detection for certain types of retinal images. Hence, in this study it was proposed to implement analysis of retinal images using FFD. FFD can be applied to the enhanced retinal images to aid in precise diagnosis. The present study overcomes these shortcomings. The computational time was less and better detection of minute blood vessels was achieved which in turn contributed in diagnosing the presence or absence of DR. This study also contributes to non-linearity as the presence or absence of retinal diseases vary in every individual depending on the location of abnormality/lesions in the retinal images. The distribution of data points contributing to abnormality is widely distributed over the feature space. Machine learning algorithms play a vital role in prediction of diseases. Machine learning algorithms function based on the input features. In retinal images, machine learning algorithms help to predict the retinal diseases as well. Fractal dimensions can be applied on the retinal images and the obtained fractal values can be used as input to the machine learning algorithms for better prediction of retinal diseases.

## 2 Related work

Techniques used for retinal image analysis were broadly studied. Neuro-fuzzy technique was used to detect exudates. First, the RGB image was converted to grayscale then features were extracted using the fuzzy technique. These features were given as input to layers of artificial neural network, and exudates were obtained. Accuracy of 95.4% was achieved in this method [25]. Naive Bayesian was used to detect microaneurysms. Image was pre-processed and Hessian matrix was used to segment the blood vessels. After segmentation of blood vessels, only microaneurysms were present. Features of microaneurysms were extracted using directional local contrast and the extracted features were given as input for Naive Bayesian, support vector machine (SVM), and k-NN. Naive Bayesian performed well in obtaining microaneurysms only [26].

Variational mode decomposition (VMD) and textural features to detect haemorrhages. To the input image, VMD was applied and four modes were obtained. Texture features were applied and haemorrhage features were extracted. The extracted features were given separately for classifiers like SVM, linear discriminant analysis, feedforward neural network, k-NN, and Naive Bayesian which help to obtain haemorrhages. It helped in distinguishing healthy and unhealthy retinas, achieving higher accuracy. Accuracy of 100% was achieved for k-NN, SVM, and Naive Bayes [27]. The existing studies focused on segmenting the lesions and detecting the symptoms of DR. But there is a need to detect the disease so that it could serve as an efficient preliminary diagnostic technique.

In medical image diagnostics, use of fractal analysis has greatly contributed in enhancing the accuracy of detection and classification of abnormalities. Katz method was used in fractal analysis for detecting the disorders in the brain. Electroencephalography (EEG) data were recorded. The recorded data were pre-processed using band pass filtering. Katz fractal dimension was used to compute the pre-processed EEG signal. The fractal dimension values were subjected to *T*-test and the correlation was obtained. It can be used only for signals [28]. Box counting method was used for lung cancer detection. The fractal dimension of tumour region was determined using Box counting. *U*-test was applied to the fractal features and good significance was achieved. Limited samples were used in their work [29].

Higuchi's method was used for haemodynamic activity characterization. MRI brain image was pre-processed with spatial smoothing with Gaussian Kernel. Principal component analysis was used to analyse the different

activities of the brain. Higuchi's fractal dimension was used to detect the activities which have higher frequencies. Then significance test was done for activities which correspond to higher fractal frequencies [30]. The above survey indicates that fractal analysis has aided in image interpretation, diagnosis, and decision making.

Use of fractal analysis methods in retinal images was extensively studied. Detection of the blood vessel by matched filtering and morphological opening is performed and the fractal dimension is calculated by Box counting. The value of fractal dimension is used to classify DR. The fractal dimension value was higher for retinopathy patients when compared to normal patients [31].

Computer-aided methodology and edge enhancement was used for retinal blood vessel extraction. Box counting was used for fractal dimensions. Fractal dimension was calculated in different layers like retinal nerve fibre layer, inner nuclear layer, outer plexiform layer, outer segment photoreceptors, retinal pigment epithelial layer, combined outer nuclear layer and inner segment, and ganglion cell layer and inner plexiform layer. Normal and mild DR patients were taken for analysis. Smaller fractal values were observed in all layers of mild DR retina [32].

Box counting was used for detecting DR. The comparison was done between the groups for normal images, hypertensive retinopathy, and proliferative DR. Limited sample was used for analysis in this study and correlation with demographic and diagnostic parameters was not performed [33]. The studies show that fractal analysis will be helpful in detecting the presence and absence of retinal diseases.

### 3 Research methods

The retinal input images from the databases need to be pre-processed for better visualization. So blood vessel enhancement was applied on the images and FFD was used as the testing approach to analyse the images. Statistical parameters such as significance, mean, and standard deviation

were calculated for predicting the retinal diseases. *T*-test was used to validate the significance (Figure 1).

The proposed study comprises of images from DIARETDB-1, DIARETDB0, STARE, MESSIDOR, E-ophtha-EX, and E-ophtha-MA databases. Forty five degree retinal images were used in this study. DIARETDB-1 database contains 89 colour fundus images. Among this, 84 images are DR images containing slight non-proliferative signs (microaneurysms) and the remaining five are normal images. No signs of DR is found in normal images. Image acquisition was performed with a digital fundus camera which had a 50° degree field of view (FOV) with varying image settings. The collected dataset is denoted as calibration level 1 fundus images. DIARETDB-0 database contains 130 colour fundus images of which 110 images are abnormal images with the indications of DR and the remaining 20 images are normal images. The abnormal images had the presence of hard and soft exudates, haemorrhages, microaneurysms, and neovascularization. Image acquisition was performed with a digital fundus camera which had a 50° FOV. The collected dataset is denoted as calibration level 0 fundus images.

E-ophtha-EX database comprises of 35 images without lesions and 47 images with exudates. E-ophtha-MA database comprises of 233 images without lesions and 148 images with small haemorrhages or microaneurysms. MESSIDOR database contains 1,200 images of which 13 images were duplicated. So, this study utilized 1,187 images of which 546 images were normal images, 417 images were DR images, and 224 images were DR with macular edema. STARE database includes 402 images consisting of images with background DR, proliferative DR, hypertensive retinopathy, choroidal neovascularization, and age-related macular degeneration (ARMD).

#### 3.1 Blood vessel enhancement

Contrast enhancement is very important as it helps in better visualization and enhances the clarity of the

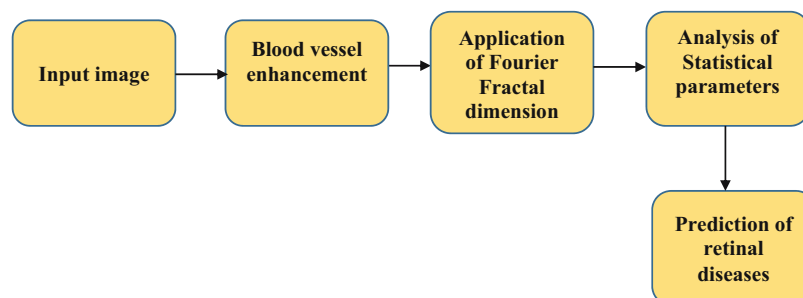


Figure 1: Flow diagram of the proposed system.

minute information available in the image. In retinal images, the blood vessels are minute structures which has to be enhanced for enabling better diagnosis and prediction of the underlying abnormalities. Adaptive histogram equalization (AHE) helps in enhancement. But on the flipside, it amplifies the noise in homogeneous regions thus creating ambiguity [34]. In retinal images, the retinal structures and minute blood vessels have to be preserved for better performance. But AHE amplifies these minute structures also resulting in overamplification. Contrast limited adaptive histogram equalization (CLAHE) resolves this problem by avoiding overamplification. Clip limit, a user defined value is used by CLAHE to constrain enhancement by clipping the histogram. CLAHE helps in enhancing blood vessels thus improving prediction and diagnosis. CLAHE is implemented in the following manner:

- a) Square neighbourhood is specified to evaluate the histogram in the neighbourhood block.
- b) A transformation function is generated with the help of histogram equalization.
- c) Mapping of gray level is carried out for every pixel individually.
- d) The histogram gets updated every time without recalculating the histogram for the entire pixels available in the new neighbourhood.
- e) Centre of the neighbourhood is moved to the nearby pixel location and the procedure is repeated.

In this study, the input image is an RGB image from which the green channel was extracted. Green channel inversion was done to enable further processing. CLAHE is applied on the inverted green channel blood vessels. Green channel was selected because blood vessels and major features of the image were highlighted in this channel very clearly. It helped in enhancing the visual aspects of the image. Blood vessel extraction is difficult for poor quality images and so blood vessel enhancement is preferred over blood vessel extraction.

## 3.2 Analysis of fractal dimensions

### 3.2.1 FFD

FFD is extensively applied in the analysis of medical images. It is less sensitive to noise and removes the necessity for image segmentation. FFD is not affected by the problems such as background noise, uneven illumination, and poor contrast. Generation of Fourier transform of a given image  $f(x, y)$  is the primary step in

computation of FFD. Fourier transform for an image of size  $(N \times N)$  is calculated as

$$F(a, b) = \frac{1}{N^2} \sum \sum f(x, y) \exp \left( -i2\pi \left( \left( \frac{ka}{N} \right) + \left( \frac{lb}{N} \right) \right) \right), \quad (1)$$

where  $F(a, b)$  indicates the Fourier transformation with  $a$  and  $b$  changing from 1 to  $N$ .

Fourier transform's magnitude is specified as

$$M(a, b) = \log(|F(a, b)|^2 + 10^{-6}). \quad (2)$$

Here  $F$  is sampled from the centre of the image. Fourier transform is calculated on a circle with radius  $\omega$  ( $\omega$  denotes overall frequency) to get the spectrum of the image. Calculation of FFD is performed by predicting the relationship between  $M$  and  $\omega$ . A logarithmic scale is used to plot this relationship which aids in the computation of FFD. FFD is correlated with the slope  $\beta$  of the plot as shown below:

$$\text{FFD} = \frac{6 + \beta}{2}. \quad (3)$$

In this study, FFD was applied for each contrast enhanced blood vessel image. FFD value was calculated for each and every image.

## 3.3 Analysis of statistical parameters

Statistical analysis was made using Statistical Package for Social Sciences. Mean, standard deviation, and significance were calculated for normal patients and DR affected patients in all the datasets. Significance, *i.e.*  $p$ -value was computed for DR patients with respect to normal patients. If the  $p$ -value is less than 0.05 and 0.001, then the significance is achieved.  $T$ -test was done to calculate significance. Mean and standard deviation [35] were used to differentiate normal and abnormal skin.  $T$ -test and significance ( $p$ -value) [36] were used to identify the factors which influenced the body mass index. In the present study mean, standard deviation, and significance were useful in differentiating normal and affected patients.

## 4 Results

The retinal images were taken individually from all the databases and were subjected to contrast enhancement

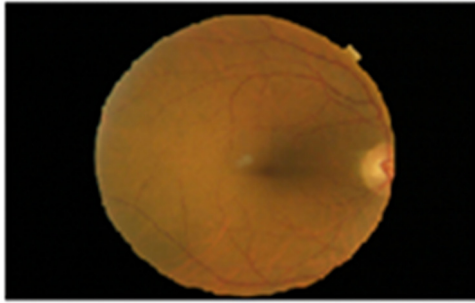


Figure 2: Input image.

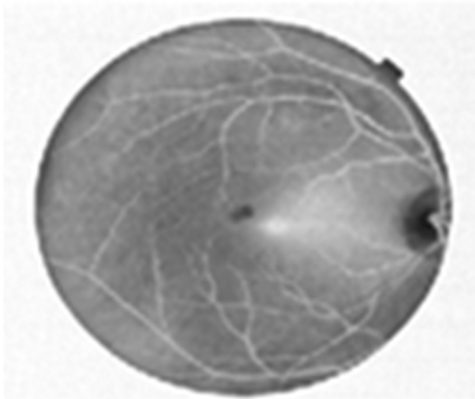


Figure 3: Blood vessel enhanced image using CLAHE.

using CLAHE. Input image is shown in Figure 2. Blood vessel enhanced image is shown in Figure 3.

FFD was applied to the blood vessel enhanced images. Table 1 shows standard deviation and mean for DR in DIARETDB-0.

From Table 1 it can be inferred that in DIARETDB-0 database normal patient had higher fractal value than DR patients. If the fractal value lies between  $-2.35$  and  $-2.41$  then the patient is affected by DR else it is normal. Table 2 represents the standard deviation and mean for DR in DIARETDB-1.

From Table 2 it can be inferred that in DIARETDB-1 database normal patient had higher fractal value than DR affected patients. If the fractal value lies between  $-2.35$  and  $-2.38$  then the patient is affected by DR else it is

Table 1: Standard deviation and mean for DR in DIARETDB-0

Statistical parameter	DR ( $p$ -value = 0.057)	
	Presence	Absence
Number	110	20
Mean $\pm$ standard deviation	$-2.41 \pm 0.139$	$-2.349 \pm 0.069$

Table 2: Standard deviation and mean for DR in DIARETDB-1

Statistical parameter	DR ( $p$ -value = 0.5816)	
	Presence	Absence
Number	84	5
Mean $\pm$ standard deviation	$-2.38 \pm 0.117$	$-2.35 \pm 0.1337$

normal. Table 3 shows standard deviation and mean for DR in E-ophtha-EX.

From Table 3 it can be inferred that in E-ophtha-EX database normal patient had lesser fractal value than patients affected with DR. Statistical significance was achieved in this database. If the fractal value lies between  $-2.39$  and  $-2.458$  then the patient is considered as normal. If the fractal value falls above  $-2.39$ , i.e. if the fractal value for an eye is  $-2.38$  it means then the patient is affected by DR. Table 4 shows standard deviation and mean for DR and normal patients in E-ophtha-MA database.

From Table 4 it can be inferred that normal patient had lesser fractal value than DR affected patients. If the fractal value lies between  $-2.45$  and  $-2.47$  then the patient is normal. If the fractal value lies above  $-2.45$ , i.e. if the fractal value for an eye is  $-2.44$  it means then the patient is affected by DR. Table 5 shows standard deviation and mean for DR and DR with macular edema in MESSIDOR database.

From Table 5 it can be inferred that mean fractal value was high for normal images and low for DR and DR with macular edema risk. If the fractal value lies between  $-2.464$  and  $-2.5$  then the patient is affected by DR and DR with macular edema. If the fractal value lies

Table 3: Standard deviation and mean for DR in E-ophtha-EX

Statistical parameter	DR ( $p$ -value = 0.0276)	
	Presence	Absence
Number	47	35
Mean $\pm$ standard deviation	$-2.39 \pm 0.137$	$-2.458 \pm 0.134$

Table 4: Standard deviation and mean for DR in E-ophtha-MA

Statistical parameter	DR ( $p$ -value = 0.1638)	
	Presence	Absence
Number	148	233
Mean $\pm$ standard deviation	$-2.45 \pm 0.137$	$-2.47 \pm 0.136$

**Table 5:** Standard deviation and mean for DR and DR with macular edema in MESSIDOR

Statistical parameter	DR	DR with macular edema		
	Presence	Absence	Presence	Absence
Number	417	546	224	546
Mean $\pm$ standard deviation	$-2.492 \pm 0.118$	$-2.464 \pm 0.126$	$-2.5 \pm 0.121$	$-2.464 \pm 0.126$

above  $-2.464$ , *i.e.* if the fractal value for an eye is  $-2.461$  it means then the patient is normal.

DIARETDB-0, DIARETDB-1, and MESSIDOR databases consist of proliferative DR images which is an advanced stage of DR. Hence normal patients had a higher fractal value than patients affected with DR in these databases. On the flip side, E-ophtha-MA and E-ophtha-EX databases do not contain proliferative DR images and so the normal patient had lesser fractal value than DR affected patients.

Figure 4 shows the graph of mean fractal value for normal and DR images in MESSIDOR, E-ophtha-EX, E-ophtha-MA, DIARETDB-1, and DIARETDB-0 databases.

The proposed study also focused on effective retinal disease prediction. Among all the retinal image databases, STARE database comprises of retinal images with various diseases apart from the normal images. Hence in this study FFD was applied to the images in STARE database in order to analyse the presence of various retinal diseases. Mean fractal value and standard deviation were calculated for retinal images with various diseases to help in disease prediction.

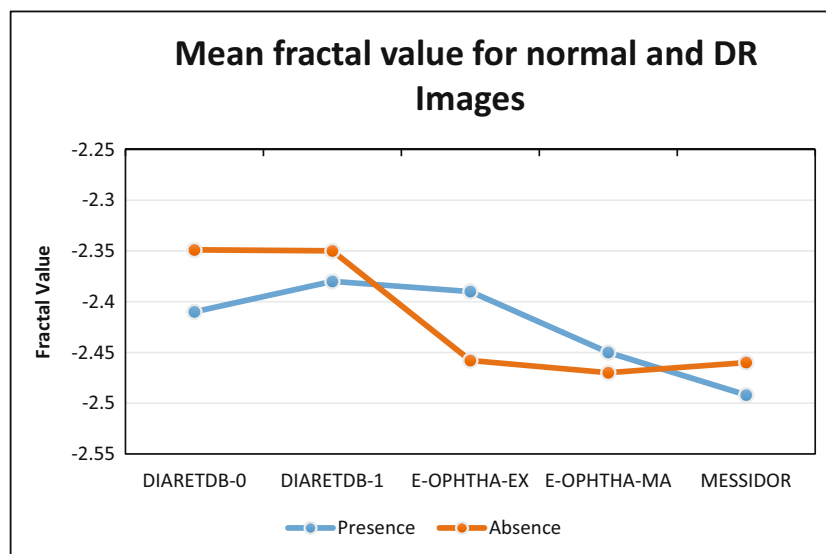
From Table 6 it can be inferred that normal retina is having high fractal value than pathological images. If fractal value is above  $-2.5 \pm 0.138$  it can be predicted

that the person is having some complications in retina. In general, demographic/diagnostic parameters can be correlated with fractals. But this study contains datasets from public databases. The public databases possess only images and it does not possess details about the demographic and diagnostic parameters. So, in this study it was not possible to correlate the obtained retinal fractals with demographic/diagnostic parameters.

## 5 Discussion

FFD [19] was focused in this work since it does not require blood vessel extraction. This is because blood vessel extraction is time consuming than blood vessel enhancement. Blood vessel extraction is prone to error because of inter-observer variation and changes due to image colour and contrast. In this study blood vessel enhancement has helped in reducing the time complexity and aiding a better prediction on combining it with FFD.

Box counting [16,21,33] method degrades the image as it has artefacts like poor contrast, uneven illumination, and background noise. FFD is more robust to noise and

**Figure 4:** Mean fractal value for normal and DR images.

**Table 6:** Standard deviation and mean fractal dimension of retinal images with various diseases

Number	Disease	Mean $\pm$ standard deviation
37	Normal	$-2.5 \pm 0.138$
53	Background DR	$-2.6 \pm 0.139$
25	Proliferative DR	$-2.627 \pm 0.163$
12	Hypertensive retinopathy	$-2.674 \pm 0.213$
36	Choroidal neovascularization and ARMD	$-2.74 \pm 0.108$
18	Retinitis	$-2.7 \pm 0.148$

performs well even with images that have poor contrast. In this study, there was a need to enhance the blood vessels. So FFD which is less sensitive to noise was used and it helped in better disease prediction.

Box counting [16,21,33] showed normal patients had a higher fractal value than patients affected with DR. In the current analysis, normal patients had higher value of fractals than DR affected patients in DiaretDB-0, DiaretDB-1, and MESSIDOR databases. HFD was used to differentiate between retinopathy and non-retinopathy patients [37].

FFD [38] showed the differentiation in MESSIDOR database between normal and affected patients. In the present study, FFD showed differentiation between normal and affected patients in DIARETDB-1, DIARETDB-0, MESSIDOR, STARE, E-ophtha-MA, and E-ophtha-EX databases.

The magnitude response spectrum of the FFD is used as a feature extraction method to classify blood vessels [39]. In the present study slope of FFD is used as a value to predict the presence and absence of disease. This has extensively contributed in reducing the noise and helped in differentiating between the normal and abnormal cases.

Blood vessel extraction approach was used to determine vascular alterations and expedite accurate identification of pathological symptoms in retinal images [40,41]. In the present study, blood vessel enhancement was used to aid better diagnosis and visualization of blood vessels to detect the underlying abnormalities using fractal techniques.

## 6 Conclusion

A broad analysis of fractal relationship with DR in various databases was analysed in this study. The study contributed significantly in differentiating the incidence and

absence of DR based on the mean fractal value. The major contribution of this work was achievement of significance for E-ophtha-EX database and prediction of retinal diseases in STARE database. Normal patient had a higher fractal value than patients affected with DR in DIARETDB-1, DIARETDB-0, and MESSIDOR databases. Normal patients had lesser fractal value in STARE, E-ophtha-MA, and E-ophtha-EX databases. This study also helped in predicting the relationship of fractal dimensions with various diseases of the retina in STARE database. If the fractal value goes beyond  $-2.5$ , it can be predicted that the patient is affected by a retinal disease. The present work reduced the effort of blood vessel extraction thereby making it more robust and enhancing its efficiency in precise diagnosis. Reduction in computational complexity and accuracy in prediction are the advantages of this study. The future study can analyse the effect of fractal dimensions in  $200^\circ$  retinal images that would aid in prediction of diseases like cataract, glaucoma, and intraocular melanoma. Deep learning techniques can be explored for detection of disease symptoms and its analysis.

**Acknowledgments:** The authors sincerely thank Mrs R. Janani Surya, Statistician, Sankara Nethralaya, Chennai for helping in statistical analysis.

**Funding information:** The authors state no funding involved.

**Author contributions:** All authors have accepted responsibility for the entire content of this manuscript and approved its submission.

**Conflict of interest:** The authors state no conflict of interest.

## References

- [1] Liew G, Wang JJ, Cheung N, Zhang YP, Hsu W, Lee ML, et al. The retinal vasculature as a fractal: methodology, reliability, and relationship to blood pressure. *Ophthalmology*. 2008;115(11):1951–6.
- [2] Klein BE, Klein R, McBride PE, Cruickshanks KJ, Palta M, Knudtson MD, et al. Cardiovascular disease, mortality, and retinal microvascular characteristics in type 1 diabetes: Wisconsin epidemiologic study of diabetic retinopathy. *Arch Intern Med*. 2004;164(17):1917–24.
- [3] Cheung N, Rogers SL, Donaghue KC, Jenkins AJ, Tikellis G, Wong TY. Retinal arteriolar dilation predicts retinopathy in

- adolescents with type 1 diabetes. *Diabetes Care*. 2008;31(9):1842–6.
- [4] Klein R, Klein BE, Moss SE, Wong TY, Hubbard L, Cruickshanks KJ, et al. The relation of retinal vessel caliber to the incidence and progression of diabetic retinopathy: XIX: the Wisconsin Epidemiologic Study of Diabetic Retinopathy. *Arch Ophthalmol*. 2004;122(1):76–83.
- [5] Alibrahim E, Donaghue KC, Rogers S, Hing S, Jenkins AJ, Chan A, et al. Retinal vascular caliber and risk of retinopathy in young patients with type 1 diabetes. *Ophthalmology*. 2006;113(9):1499–503.
- [6] Klein R, Klein BE, Moss SE, Wong TY. Retinal vessel caliber and microvascular and macrovascular disease in type 2 diabetes: XXI: the wisconsin epidemiologic study of diabetic retinopathy. *Ophthalmology*. 2007;114(10):1884–92.
- [7] Deepika V, Jeyalakshmi V, Latha P, Raman R, Srinivasalu S, Raman S, et al. Comparison of various fractal analysis methods for retinal images. *Biomed Signal Process Control*. 2021;63:102245.
- [8] Imani E, Javidi M, Pourreza HR. Improvement of retinal blood vessel detection using morphological component analysis. *Comput Methods Prog Biomed*. 2015;118(3):263–79.
- [9] Sussman EJ, Tsiaras WG, Soper KA. Diagnosis of diabetic eye disease. *JAMA*. 1982;247(23):3231–4.
- [10] Wong TY, Klein R, Sharrett AR, Schmidt MI, Pankow JS, Couper DJ, et al. Retinal arteriolar narrowing and risk of diabetes mellitus in middle-aged persons. *JAMA*. 2002;287(19):2528–33.
- [11] Lee SJ, McCarty CA, Taylor HR, Keeffe JE. Costs of mobile screening for diabetic retinopathy: a practical framework for rural populations. *Aus J Rural Health*. 2001;9(4):186–92.
- [12] Bernardes R, Serranho P, Lobo C. Digital ocular fundus imaging: a review. *Ophthalmology*. 2011;226(4):161–81.
- [13] Taylor HR, Keeffe JE. World blindness: a 21st century perspective. *Br J Ophthalmol*. 2001;85(3):261–6.
- [14] Wong TY, Klein R, Couper DJ, Cooper LS, Shahar E, Hubbard LD, et al. Retinal microvascular abnormalities and incident stroke: the atherosclerosis risk in communities study. *Lancet*. 2001;358(9288):1134–40.
- [15] Wong TY, Klein R, Sharrett AR, Duncan BB, Couper DJ, Tielsch JM, et al. Retinal arteriolar narrowing and risk of coronary heart disease in men and women: the atherosclerosis risk in communities study. *JAMA*. 2002;287(9):1153–9.
- [16] Avakian A, Kalina RE, Sage EH, Rambhia AH, Elliott KE, Chuang EL, et al. Fractal analysis of region-based vascular change in the normal and non-proliferative diabetic retina. *Curr Eye Res*. 2002;24(4):274–80.
- [17] Patton N, Aslam TM, MacGillivray T, Deary IJ, Dhillon B, Eikelboom RH, et al. Retinal image analysis: concepts, applications and potential. *Prog Retinal Eye Res*. 2005;25(1):99–127.
- [18] Masters BR. Fractal analysis of the vascular tree in the human retina. *Ann Rev Biomed Eng*. 2004;6:427–52.
- [19] Azemin MC, Kumar DK, Wong TY, Kawasaki R, Mitchell P, Wang JJ. Robust methodology for fractal analysis the retinal vasculature. *IEEE Trans Med Imaging*. 2010;30(2):243–50.
- [20] Moghaddam RF, Cheriet M. Modified Hausdorff fractal dimension (MHFD). *ArXiv*, abs/150503493
- [21] Grauslund J, Green A, Kawasaki R, Hodgson L, Sjolie AK, Wong TY. Retinal vascular fractals and microvascular and macrovascular complications in type 1 diabetes. *Ophthalmology*. 2010;117(7):1400–5.
- [22] Cheung CY, Ong S, Ikram MK, Ong YT, Chen CP, Venketasubramanian N, et al. Retinal vascular fractal dimension is associated with cognitive dysfunction. *J Stroke Cerebrovasc Dis*. 2014;23(1):43–50.
- [23] Punithavathy M, Poobal S, Ramya MM. Performance evaluation of machine learning techniques in lung cancer classification from PET/CT images. *FME Trans*. 2019;47(3):418–23.
- [24] Sebastin MV, Navascues MA. A relation between fractal dimension and fourier transform-electroencephalographic study using spectral and fractal parameters. *Int J Comput Math*. 2008;85(3):657–65.
- [25] Jeyapriya J, Umadevi KS. Detection of exudates using neuro-fuzzy technique. *Int J Electr Eng Educ*. 2020;0(0):1–10.
- [26] Long SC, Chen J, Hu A, Liu H, Chen Z, Zheng DC. Microaneurysms detection in color fundus images using machine learning based on directional local contrast. *Bio Med Eng OnLine*. 2020;19(21):1–23.
- [27] Lahmiri S, Shmuel A. Variational mode decomposition-based approach for accurate classification of color fundus images with hemorrhages. *Opt Laser Technol*. 2017;96:243–8.
- [28] Ravandi SY, Arezooji DM, Matinnia N, Shamsaei F, Ahmadpanah M, Ghaleiha A, et al. Complexity of information processing in obsessive-compulsive disorder based on fractal analysis of EEG signal. *Excli J*. 2021;20:642–54.
- [29] Al-Kadi OS. Prediction of FDG-PET stage and uptake for non-small cell lung cancer on non-contrast enhanced CT scans via fractal analysis. *Clin Imaging*. 2020;65:54–9.
- [30] Porcaro C, Mayhew SD, Marino M, Mantini D, Bagshaw AP. Characterisation of haemodynamic activity in resting state networks by fractal analysis. *Int J Neural Sys*. 2020;30(12):1–15.2050061.
- [31] Safitri DW, Juniati D. Classification of diabetic retinopathy using fractal dimension analysis of eye fundus image. *Int Conf Math Pure Appl Comput*. 2017;1867:020011.
- [32] Gao W, Debuc DC, Zakharov V, Tatrai E, Somfai G, Myakinin O, et al. Two-dimensional fractal analysis of retinal tissue of healthy and diabetic eyes with optical coherence tomography. *J Biomed Photonics Eng*. 2016;2(4):040302.
- [33] Popovic N, Radunovic M, Badnjar J, Popovic T. Fractal dimension and lacunarity analysis of retinal microvascular morphology in hypertension and diabetes. *Microvasc Res*. 2018;118:36–43.
- [34] Singala N, Singh N. Blood vessel contrast enhancement techniques for retinal images. *Int J Adv Res Comput Sci*. 2017;8(5):709–12.
- [35] Afdhal A, Zulfikar Z, Zulhelmi Z, Arif TY. Image investigation using higher moment statistics and edge detection for recognizing abnormal skin. *Bull Electr Eng Inform*. 2020;9(1):109–20.
- [36] Hoseini SH, Nakhli MP, Soltani A. Neural network model of estimation of body mass index on indirect input factors. *Bull Electr Eng Inform*. 2013;2(3):218–24.
- [37] Deepika V, Jeyalakshmi V, Latha P, Raman R, Kiruthika V, Raman S, et al. Relationship of fractal analysis in retinal microvasculature with demographic and diagnostic parameters. *Microvasc Res*. 2022;139:104237.



- [38] Relan D, Jain D, Mittal V. Robustness of fourier fractal analysis in differentiating subgroups of retinal images. *J Discrete Math Sci Cryptogr.* 2019;22(9):101–11.
- [39] Ding Y, Ward WOC, Duan J, Auer DP, Gowland P, Bai L. Retinal vasculature classification using novel multifractal features. *Phys Med Biol.* 2015;60(21):8365–79.
- [40] Bhardwaj C, Jain S, Sood M. Performance analysis of retinal features for diabetic retinopathy characterisation and diagnosis. *Int J Bus Syst Res.* 2021;15(2):253–70.
- [41] Bhardwaj C, Jain S, Sood M. Retinal blood vessel localization to expedite PDR diagnosis. *Period Eng Nat Sci.* 2020;8(3):1233–46.