

# Fractional Flow Reserve Evaluation in Patients Considered for Transfemoral Transcatheter Aortic Valve Implantation: A Case Series

Barbara E. Stähli Willibald Maier Roberto Corti Thomas F. Lüscher  
Lukas A. Altwegg

Department of Cardiology, Cardiovascular Center, University Hospital Zurich, Zurich, Switzerland

## Established Facts

- Coronary artery disease is frequently observed in patients with severe aortic stenosis.
- Fractional flow reserve is an established method in hemodynamic assessment of coronary lesions.

## Novel Insights

- Fractional flow reserve is a safe strategy to assess hemodynamic significance of coronary lesions in patients with severe aortic stenosis considered for transcatheter aortic valve implantation.

## Key Words

Aortic stenosis · Fractional flow reserve · Transcatheter aortic valve implantation

## Abstract

**Objectives:** Transcatheter aortic valve implantation (TAVI) has become an established therapy for severe aortic stenosis (AS) in high-risk elderly individuals. Concomitant coronary artery disease (CAD) is frequently encountered in this patient population and may have an impact on outcomes. Hence, in patients with both severe AS and CAD, a bespoke therapy of both AS and/or CAD appears mandatory. **Methods:** We report a series of 5 patients with severe AS and concomitant CAD considered for TAVI who underwent fractional flow

reserve (FFR) for hemodynamic assessment of coronary lesions. **Results:** In 3 patients, a 2-staged procedure was undertaken with FFR measurements at the time of invasive assessment and TAVI thereafter. In the remaining 2 patients, FFR measurements were performed immediately prior to the TAVI procedure with deferral of percutaneous coronary intervention (PCI) in one and ad hoc PCI in the other patient. All 5 patients had uneventful FFR measurements and procedural TAVI outcomes. One patient with a staged approach noted a significant improvement in symptoms already after PCI. **Conclusions:** FFR provides an effective and safe strategy to assess hemodynamic significance of coronary lesions in patients with severe AS and concomitant CAD considered for TAVI.

Copyright © 2012 S. Karger AG, Basel

## Introduction

Degenerative aortic stenosis (AS) is the most frequent valvular disease in the elderly Western population [1]. In these patients, coexisting coronary artery disease (CAD) is frequently observed. Indeed, about one third of patients with severe AS undergoing valve surgery have concomitant CAD [2].

Surgical aortic valve (AV) replacement is considered standard of care for symptomatic AS. Over the last decade, transcatheter AV implantation (TAVI) has become an alternative treatment option for selected high-risk patients with severe AS not amenable to open heart surgery [3]. Concomitant CAD may have a negative impact on post-procedural outcome [4]. In particular, rapid right ventricular pacing may be detrimental in patients with severe CAD. Yet, the necessity of coronary revascularization in the context of TAVI is not fully elucidated. Significant coexisting CAD requires preemptive percutaneous coronary intervention (PCI) in patients considered for TAVI, and among carefully selected patients, PCI proved to be safe in addition to TAVI either as a staged or a concomitant intervention [5]. Fractional flow reserve (FFR) is a well-established technique to determine the hemodynamic significance of intermediate coronary lesions for a strictly ischemia-driven revascularization [6]. A value of 0.75 or less identifies hemodynamic significant lesions with an accuracy of more than 90% and high spatial resolution [6]. Using FFR for guidance of PCI reduces major adverse cardiac events in patients with single- and multi-vessel disease as well as in unstable angina and non-ST segment elevation myocardial infarction [7]. A favorable outcome was also observed after FFR-guided surgical treatment of patients with equivocal left main coronary artery stenosis [8]. Hence, FFR-guided PCI for hemodynamic assessment of coronary lesion severity prior to TAVI might reduce major adverse cardiac events and improve procedural and long-term patient outcome. The use of intravenous adenosine to induce maximal hyperemia has been shown to be safe in patients with AS in the context of non-invasive assessments [9]. However, potential adverse effects including bradycardia or asystole as well as an adenosine-induced decrease in diastolic blood pressure compromising coronary blood flow in patients with severe AS have to be considered [10].

## Methods

Here, for the first time, we report a series of 5 patients with severe AS and concomitant CAD considered for TAVI who underwent invasive FFR measurements for coronary lesion assess-

ment. Fractional flow reserve measurements were performed applying the hyperemic pullback technique using the RadiAnalyzer™ with the PressureWire™ Certus™ or the Iliumien™ system with the Wireless PressureWire™ Aeris™ (all St. Jude Medical Inc., St. Paul, Minn., USA). Measurements were performed under hyperemia unless spontaneous values indicated ischemia. Hyperemia was induced by continuous intravenous adenosine infusion (0.14 mg/kg/min) until a steady state in hemodynamics and stable FFR values were noted. An FFR below 0.8 was considered suggestive of significant ischemia [11]. Hemodynamics at baseline and during maximal hyperemia are summarized in table 1.

## Case Series and Results

### *Case 1: FFR-Guided Multivessel Intervention and Staged TAVI*

An 88-year-old male with a previous history of diabetes and polymyalgia rheumatica with severe AS (mean systolic pressure gradient 41 mm Hg, indexed AV area 0.5 cm<sup>2</sup>/m<sup>2</sup>) presented with worsening angina and exertional dyspnea [New York Heart Association (NYHA) class II, Canadian Cardiovascular Society (CCS) class II] for 1 year. Coronary angiography showed multivessel disease including a 50% ostial stenosis of the proximal left anterior descending coronary artery (LAD), a 70–90% stenosis of the intermediate branch, a 50% stenosis of the small mid left circumflex artery (RCX), and an 80% stenosis of the right coronary artery (RCA).

On the basis of an expected high perioperative morbidity, the Heart Team opted for a transcatheter approach [PARTNER B constellation [12, 13], Society of Thoracic Surgeons (STS) risk of mortality 4.7%]. FFR was 0.63 both in the intermediate artery and in the mid RCA. PCI with drug-eluting stent deployment (Nobori® 3.0 × 14 and 3.5 × 24 mm, respectively) was performed on both lesions. FFR following PCI was 0.92 in the RCA. After PCI of the intermediate branch, the patient experienced sudden angina resulting from significant plaque shifting with subtotal occlusion of the ostial LAD. Accordingly, immediate PCI/stenting (Nobori 2.0 × 14 mm) of the ostial LAD was performed, with a good final angiographic result in the LAD and a final FFR of 0.92 in the intermediate branch. On admission for the planned TAVI procedure after 3 weeks, the patient was free of angina. TAVI was performed and a 29-mm CoreValve prosthesis was implanted. There was no relevant postprocedural pressure gradient with minimal paravalvular aortic regurgitation.

Due to 2nd-degree AV block, permanent pacemaker implantation had to be performed 2 days following the procedure. The patient had an uneventful course and was discharged 9 days after TAVI. The patient subsequently made an excellent recovery. He resumed riding his bike after 6 months and remained well at 1-year follow-up.

### *Case 2: FFR Measurement during Evaluation and Staged Intervention (PCI and TAVI)*

An 83-year-old female was admitted for decompensated AS (mean systolic pressure gradient 55 mm Hg, indexed AV area 0.2 cm<sup>2</sup>/m<sup>2</sup>) and concomitant CAD with PCI of the RCA 10 years ago.

**Table 1.** Hemodynamics at baseline and during FFR measurements

	Baseline						During maximal hyperemia			
	Ao S mm Hg	Ao D mm Hg	Ao M mm Hg	LV S mm Hg	LV EDP mm Hg	HR bpm	Ao S mm Hg	Ao D mm Hg	Ao M mm Hg	HR bpm
Case 1	129	48	78	161	43	63	117	41	68	68
Case 2	173	69	104	214	41	72	126	36	66	73
Case 3	93	54	69	145	46	72	85	45	60	62
Case 4	148	40	56	–	–	75	74	67	68	80
Case 5	128	44	73	196	18	57	100	41	58	58

Ao S = Systolic aortic pressure; Ao D = diastolic aortic pressure; Ao M = mean aortic pressure; LV S = systolic left ventricular pressure; LV EDP = left ventricular end-diastolic pressure; HR = heart rate.

Left ventricular systolic function was impaired (left ventricular ejection fraction 43%) with diffuse hypokinesia. Invasive cardiac assessment showed a porcelain aorta and severe AS with a mean systolic pressure gradient of 44 mm Hg. Coronary angiography revealed a good long-term result following PCI in the RCA. Furthermore, mild left main disease was noted, which had no hemodynamic significance as assessed by FFR (0.9). However, there was a 50–70% stenosis of the mid LAD at the bifurcation to the first diagonal branch with a clear step up in FFR from 0.76 to 0.9. In the presence of secondary pulmonary hypertension (systolic pulmonary artery pressure 82 mm Hg) and increased left ventricular end-diastolic pressure (41 mm Hg), the intervention was postponed. After complete evaluation by the Heart Team, TAVI was considered the appropriate therapy (PARTNER B constellation, STS risk of mortality 6.7%). After recompensation, TAVI (implantation of a 23-mm Edwards SAPIEN prosthesis by transfemoral access) combined with PCI including drug-eluting stent deployment (Resolute Integrity® 2.75 × 18 mm) in the mid LAD was performed. Postprocedural aortography revealed good prosthesis function with mild paravalvular aortic regurgitation. The patient had an uneventful course and was discharged after 10 days. At 1-month follow-up, the patient was free of symptoms.

#### Case 3: FFR-Guided Single-Vessel Intervention and TAVI

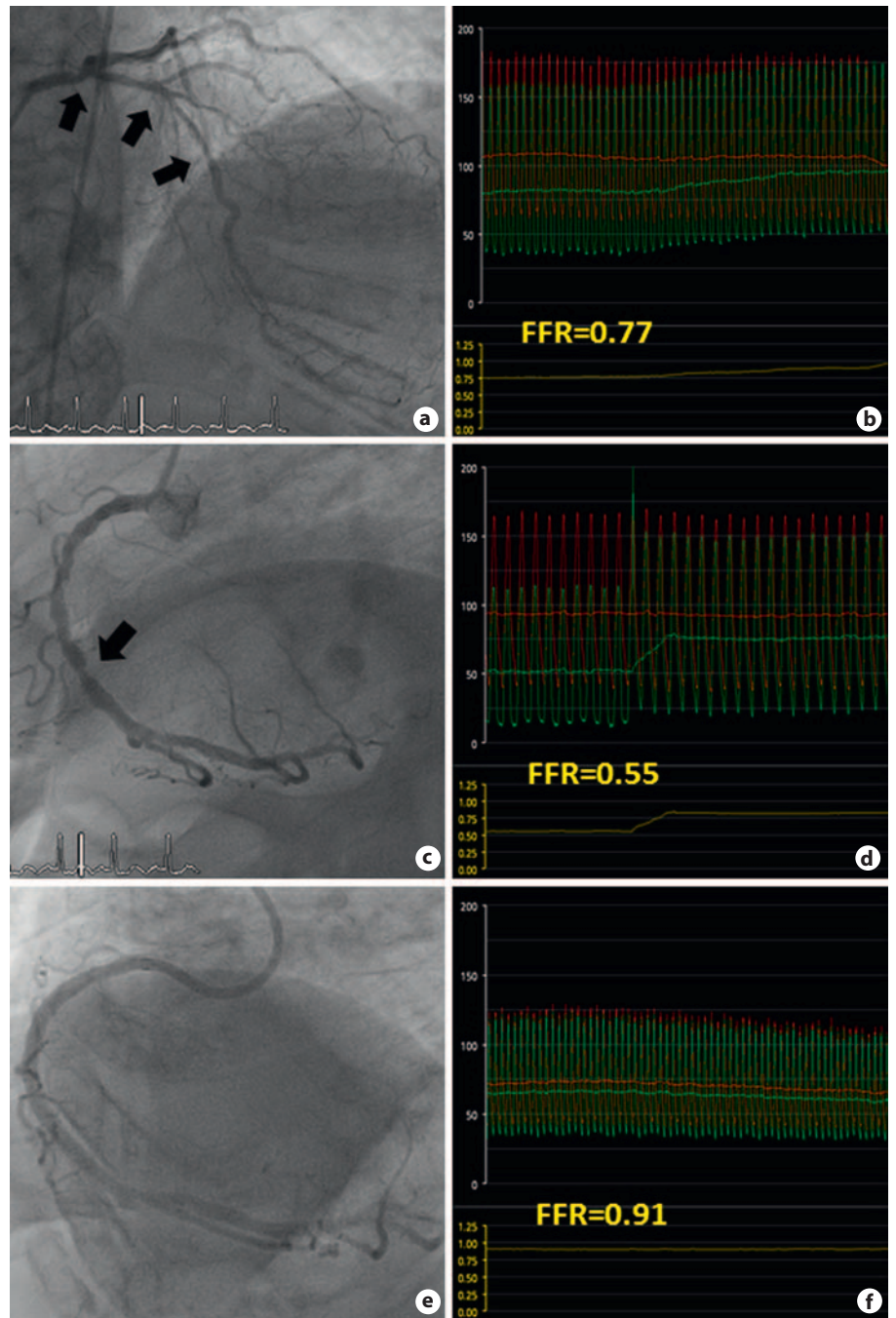
An 83-year-old patient with known AS was referred with cardiogenic shock and non-ST segment elevation myocardial infarction. The previous history included hypertension, previous surgical repair of an abdominal aortic aneurysm, and renal transplantation. Echocardiographic workup showed severe AS with a mean systolic pressure gradient of 67 mm Hg and an indexed AV area of 0.3 cm<sup>2</sup>/m<sup>2</sup>. Coronary angiography revealed diffuse multivessel disease with serial 70% stenoses of a small posterior descending artery and chronic occlusion of the small 1st diagonal branch. Foremost, a focal stenosis of borderline angiographic significance in the mid LAD was noted. In view of the critical condition, an intra-aortic balloon pump was placed and the patient transferred to the intensive care unit for hemodynamic stabilization. He was considered for TAVI by the Heart Team based on a high per se perioperative risk (PARTNER A constellation, STS risk of mortality 14.7%).

After 2 days, FFR-guided PCI of the LAD stenosis (spontaneous FFR 0.6) with implantation of a drug-eluting stent (Promus® 2.75 × 18 mm) was performed uneventfully. At the same time, successful transfemoral implantation of a 26-mm Edwards SAPIEN prosthesis was performed with only mild paravalvular regurgitation on final angiogram. The patient could be discharged after 11 days. During the further course, melena occurred and colorectal adenocarcinoma was diagnosed.

#### Case 4: Multivessel FFR and Selected PCI during Evaluation before TAVI

An 86-year-old female with squamous cell carcinoma of the tongue and otherwise unremarkable previous history was referred for a systolic murmur noted on preoperative examination. Echocardiography showed severe AS (mean systolic pressure gradient 50 mm Hg, indexed AV area 0.5 cm<sup>2</sup>/m<sup>2</sup>), and by taking a thorough medical history, shortness of breath on exertion (NYHA class II) over the last 6 months was revealed. In view of her intense pain and the inability to swallow, there was interdisciplinary consensus that she would be best served with urgent neck surgery preceded by aortic intervention, notably TAVI (PARTNER B constellation, STS risk of mortality 7.0%). Coronary angiography showed additional distal left main disease, diffuse disease of the proximal and mid LAD, and a focal borderline stenosis of the RCA. To avoid unnecessary PCI in this setting, FFR was utilized to assess both the left main coronary artery/LAD and the RCA. Interestingly, in both territories, spontaneous FFR under non-hyperemic conditions was below 0.8 already (0.77 and 0.55 in the mid LAD and mid RCA, respectively). However, on pullback, an ischemia-provoking lesion with a clear step up in FFR from 0.55 to 0.83 was only noted in the mid segment of the RCA, whereas the gradual increase in FFR from 0.77 in the mid LAD to 1.0 at the ostium of the left coronary most likely reflected the diffuse disease noted on angiogram (fig. 1). Accordingly, the left main coronary artery and the LAD were left untreated, and successful PCI of the RCA with implantation of 2 bare-metal stents (Multilink® 3.0 × 28 mm and 3.0 × 15 mm, respectively) was performed. After PCI, spontaneous FFR in the mid RCA was 1.0 with an insignificant decrease to 0.91 after continuous adenosine administration. Three days after FFR-guided PCI, transfemoral TAVI

**Fig. 1. a** Coronary angiography showing a long diseased segment (arrows) from the left main coronary artery to the mid LAD. **b** Continuous FFR tracing during pressure wire pullback from the mid LAD to the ostium of the left coronary artery under non-hyperemic, spontaneous conditions. Even though the initial value of 0.77 is below 0.8, the gradual increase in FFR to 1.0 (yellow line) suggests diffuse disease likely not profiting from PCI. **c** Coronary angiography showing a focal stenosis of borderline significance in the mid RCA (arrow). **d** Continuous FFR tracing in the RCA demonstrating a significant focal lesion in the mid segment as reflected by an initial spontaneous value of 0.55 and a clear step up to 0.83 on pullback. **e** Final angiographic result after implantation of 2 bare-metal stents from the proximal to the mid RCA. **f** Final continuous FFR tracing during hyperemic pullback confirming hemodynamic improvement without obvious residual ischemia (FFR continuously 0.91).



with implantation of a 26-mm CoreValve prosthesis was conducted with a final mean systolic pressure gradient of 8 mm Hg, a trace of paravalvular aortic regurgitation, and an uneventful short-term follow-up.

#### Case 5: FFR-Based Deferral of PCI during TAVI

An 81-year-old female with a longstanding history of disabling rheumatoid arthritis on methotrexate was admitted to our hospi-

tal with severe AS and worsening dyspnea (NYHA class IV). Transthoracic echocardiography showed a mean systolic pressure gradient of 45 mm Hg and an indexed AV area of 0.4 cm<sup>2</sup>/m<sup>2</sup>. A focal 75% stenosis in the RCX as well as irregularities of the proximal LAD and the intermediate branch were documented on coronary angiography. Peak-to-peak transvalvular aortic gradient was 68 mm Hg. After evaluation by the Heart Team, the patient was scheduled for TAVI primarily based on frailty and immobil-



ity (PARTNER B constellation, STS risk of mortality 6.4%). Prior to TAVI, the hemodynamic relevance of the RCX lesion was evaluated by FFR, which revealed a minimal value of 0.9. Therefore, no hemodynamic rationality for PCI was proven, and a 29-mm CoreValve prosthesis was implanted in the same sitting. Postprocedural aortography revealed mild paravalvular aortic regurgitation. The course was completely uneventful and the patient was discharged 8 days after the procedure. After 2 months, the patient was free of symptoms, with an increase in functional class from NYHA class IV to I.

## Discussion

This case series illustrates the safety and benefits of FFR in the assessment of hemodynamic significance of coronary lesions in patients with severe AS and concomitant CAD considered for TAVI. To the best of our knowledge, FFR measurements in patients with CAD considered for TAVI have not been reported yet.

Cardiovascular diseases, in particular degenerative AS and CAD, are increasingly prevalent in the ageing population [1]. Indeed, moderate to severe AS is present in about 2.8% of over 75-year olds [1], and in a series of patients aged 60–82 years with calcific AS, significant concomitant CAD was observed in 68% [14]. Accordingly, in patients with severe AS undergoing valve surgery, concomitant CAD was reported in about one third [2]. However, in patients with both severe AS and CAD, AS may be considered to be the leading diagnosis. Notwithstanding, symptoms in patients with severe AS may be caused by significant coronary lesions.

The optimal strategy for coronary revascularization in patients considered for TAVI remains unclear. Current guidelines recommend concomitant coronary artery bypass grafting for significant CAD in patients undergoing conventional AV replacement [15]. Transcatheter AV implantation is indicated in selected high-risk patients unsuitable to open heart surgery, as severe AS rapidly progresses once symptoms have developed, and patients usually die within 2–3 years without treatment [16, 17]. Concomitant CAD may worsen patient outcome following TAVI [4]. Treatment of severe AS may reduce ischemia despite the presence of previously significant CAD. On the other hand, PCI for significant CAD may improve symptoms. Thus, percutaneous revascularization of significant CAD before TAVI should be encouraged comparable to coronary artery bypass grafting in surgical patients. In addition, significant coronary lesions are preferably treated prior to rapid right ventricular pacing which could induce myocardial ischemia,

particularly in hypertrophic hearts. However, every additional intervention performed before or during valve implantation has to be balanced against increased periprocedural risk. Indeed, in patients with severe AS, PCI has been associated with poor outcome [18], and resuscitation outcomes are known to be poor in AS patients [19]. Furthermore, post-TAVI PCI in the presence of percutaneous prosthetic valves may be difficult. Hence, it is important to assess the hemodynamic significance of concomitant CAD.

The FAME (Fractional Flow Reserve versus Angiography for Multivessel Evaluation) study showed that FFR is a valuable tool for physiology-guided lesion assessment, and routine FFR in addition to coronary angiography has improved the outcome of PCI [11]. Deferring PCI in hemodynamically non-significant coronary lesions is safe with an annual rate of cardiac death or myocardial infarction of <1% [20]. FFR-guided PCI for hemodynamically significant coronary lesions prior to TAVI might alter the procedural strategy, improving long-term outcome and lowering costs.

In conclusion, this case series illustrates that FFR can be performed safely in different settings, either during evaluation of patients considered for TAVI or combined with PCI and TAVI in an integrated procedure. Furthermore, it can be performed to assess left main CAD in the setting of severe AS. Hence, as highlighted by this case series, FFR is easily applicable and its use might be an option in the assessment of coronary lesions in patients with severe AS and concomitant CAD considered for TAVI.

## Acknowledgements

Lukas A. Altwegg and Barbara E. Stähli have been supported by grants of the Swiss National Research Foundation (Special Program University Medicine: Grant No. 33CM30-1241112/1 and 3100-068118.02/1).

## References

- 1 Nkomo VT, Gardin JM, Skelton TN, Gottdiener JS, Scott CG, Enriquez-Sarano M: Burden of valvular heart diseases: a population-based study. *Lancet* 2006;368:1005–1011.
- 2 Shaikh AH, Hanif B, Hasan K, Adil A, Hashmani S, Raza M, Qazi HA, Mujtaba I: Coronary artery disease in patients undergoing valve replacement at a tertiary care cardiac centre. *J Pak Med Assoc* 2011;61:340–342.

- 3 Authors/Task Force Members: Vahanian A, Alfieri O, Andreotti F, Antunes MJ, Barón-Esquivias G, Baumgartner H, Borger MA, Carrel TP, De Bonis M, Evangelista A, Falk V, Jung B, Lancellotti P, Pierard L, Price S, Schäfers HJ, Schuler G, Stepinska J, Swedberg K, Takkenberg J, Von Oppell UO, Windecker S, Zamorano JL, Zembala M; ESC Committee for Practice Guidelines (CPG): Bax JJ, Baumgartner H, Ceconi C, Dean V, Deaton C, Fagard R, Funck-Brentano C, Hasdai D, Hoes A, Kirchhof P, Knuuti J, Kolh P, McDonagh T, Moulin C, Popescu BA, Reiner Z, Sechtem U, Sirnes PA, Tendera M, Torbicki A, Vahanian A, Windecker S; Document Reviewers: Popescu BA, Von Segesser L, Badano LP, Bunc M, Claeys MJ, Drinkovic N, Filippatos G, Habib G, Kappetein AP, Kassab R, Lip GYH, Moat N, Nickenig G, Otto CM, Pepper J, Piazza N, Pieper PG, Rosenhek R, Shuka N, Schwammenthal E, Schwitler J, Mas PT, Trindade PT, Walther T: Guidelines on the management of valvular heart disease (version 2012): the Joint Task Force on the Management of Valvular Heart Disease of the European Society of Cardiology (ESC) and the European Association for Cardio-Thoracic Surgery (EACTS). *Eur Heart J* 2012;33:2451–2496.
- 4 Dewey TM, Brown DL, Herbert MA, Culica D, Smith CR, Leon MB, Svensson LG, Tuzcu M, Webb JG, Cribier A, Mack MJ: Effect of concomitant coronary artery disease on procedural and late outcomes of transcatheter aortic valve implantation. *Ann Thorac Surg* 2010;89:758–767, discussion 767.
- 5 Wenaweser P, Pilgrim T, Guerios E, Stortecky S, Huber C, Khattab AA, Kadner A, Buellfeld L, Gloekler S, Meier B, Carrel T, Windecker S: Impact of coronary artery disease and percutaneous coronary intervention on outcomes in patients with severe aortic stenosis undergoing transcatheter aortic valve implantation. *EuroIntervention* 2011;7:541–548.
- 6 Pijls NH, De Bruyne B, Peels K, Van Der Voort PH, Bonnier HJ, Bartunek JKJ, Koolen JJ: Measurement of fractional flow reserve to assess the functional severity of coronary-artery stenoses. *N Engl J Med* 1996;334:1703–1708.
- 7 Sels JW, Tonino PA, Siebert U, Fearon WF, Van't Veer M, De Bruyne B, Pijls NH: Fractional flow reserve in unstable angina and non-ST-segment elevation myocardial infarction experience from the FAME (Fractional flow reserve versus Angiography for Multivessel Evaluation) study. *JACC Cardiovasc Interv* 2011;4:1183–1189.
- 8 Hamilos M, Muller O, Cuisset T, Ntalianis A, Chlouverakis G, Sarno G, Nelis O, Bartunek J, Vanderheyden M, Wyffels E, Barbato E, Heyndrickx GR, Wijns W, De Bruyne B: Long-term clinical outcome after fractional flow reserve-guided treatment in patients with angiographically equivocal left main coronary artery stenosis. *Circulation* 2009;120:1505–1512.
- 9 Burgstahler C, Kunze M, Gawaz MP, Rasche V, Wohrle J, Hombach V, Merkle N: Adenosine stress first pass perfusion for the detection of coronary artery disease in patients with aortic stenosis: a feasibility study. *Int J Cardiovasc Imaging* 2008;24:195–200.
- 10 Jeremias A, Whitbourn RJ, Filardo SD, Fitzgerald PJ, Cohen DJ, Tuzcu EM, Anderson WD, Abizaid AA, Mintz GS, Yeung AC, Kern MJ, Yock PG: Adequacy of intracoronary versus intravenous adenosine-induced maximal coronary hyperemia for fractional flow reserve measurements. *Am Heart J* 2000;140:651–657.
- 11 Tonino PA, De Bruyne B, Pijls NH, Siebert U, Ikeno F, van't Veer M, Klauss V, Manoharan G, Engstrom T, Oldroyd KG, Ver Lee PN, MacCarthy PA, Fearon WF: Fractional flow reserve versus angiography for guiding percutaneous coronary intervention. *N Engl J Med* 2009;360:213–224.
- 12 Leon MB, Smith CR, Mack M, Miller DC, Moses JW, Svensson LG, Tuzcu EM, Webb JG, Fontana GP, Makkar RR, Brown DL, Block PC, Guyton RA, Pichard AD, Bavaria JE, Herrmann HC, Douglas PS, Petersen JL, Akin JJ, Anderson WN, Wang D, Pocock S: Transcatheter aortic-valve implantation for aortic stenosis in patients who cannot undergo surgery. *N Engl J Med* 2010;363:1597–1607.
- 13 Smith CR, Leon MB, Mack MJ, Miller DC, Moses JW, Svensson LG, Tuzcu EM, Webb JG, Fontana GP, Makkar RR, Williams M, Dewey T, Kapadia S, Babaliaros V, Thourani VH, Corso P, Pichard AD, Bavaria JE, Herrmann HC, Akin JJ, Anderson WN, Wang D, Pocock SJ: Transcatheter versus surgical aortic-valve replacement in high-risk patients. *N Engl J Med* 2011;364:2187–2198.
- 14 Hancock EW: Aortic stenosis, angina pectoris, and coronary artery disease. *Am Heart J* 1977;93:382–393.
- 15 Bonow RO, Carabello BA, Chatterjee K, de Leon AC Jr, Faxon DP, Freed MD, Gaasch WH, Lytle BW, Nishimura RA, O'Gara PT, O'Rourke RA, Otto CM, Shah PM, Shanewise JS: 2008 focused update incorporated into the ACC/AHA 2006 guidelines for the management of patients with valvular heart disease: a report of the American College of Cardiology/American Heart Association Task Force on Practice Guidelines (Writing Committee to revise the 1998 guidelines for the management of patients with valvular heart disease). Endorsed by the Society of Cardiovascular Anesthesiologists, Society for Cardiovascular Angiography and Interventions, and Society of Thoracic Surgeons. *J Am Coll Cardiol* 2008;52:e1–e142.
- 16 Bach DS, Cimino N, Deeb GM: Unoperated patients with severe aortic stenosis. *J Am Coll Cardiol* 2007;50:2018–2019.
- 17 Stahli BE, Bunzli R, Grunenfelder J, Buhler I, Felix C, Bettex D, Biaggi P, Tanner FC, Nguyen-Kim DL, Plass A, Ge H, Falk V, Luscher TF, Corti R, Maier W, Altwegg LA: Transcatheter aortic valve implantation (TAVI) outcome according to standardized endpoint definitions by the Valve Academic Research Consortium (VARC). *J Invasive Cardiol* 2011;23:307–312.
- 18 Folland ED, Oprian C, Giacomini J, Schechter E, Shabetai R, Henderson WG, Hammermeister KE, Sethi G: Complications of cardiac catheterization and angiography in patients with valvular heart disease. VA Cooperative Study on Valvular Heart Disease. *Cathet Cardiovasc Diagn* 1989;17:15–21.
- 19 Pavlides GS, Cieszkowski J, Timmis GC, O'Neill W: Successful resuscitation of a patient with critical aortic stenosis and cardiac arrest by peripheral cardiopulmonary support system. *Cathet Cardiovasc Diagn* 1990;20:120–122.
- 20 Pijls NH, van Schaardenburgh P, Manoharan G, Boersma E, Bech JW, van't Veer M, Bar F, Hoorntje J, Koolen J, Wijns W, de Bruyne B: Percutaneous coronary intervention of functionally nonsignificant stenosis: 5-year follow-up of the DEFER Study. *J Am Coll Cardiol* 2007;49:2105–2111.