

## FRACTIONATED STEREOTACTIC RADIOTHERAPY TREATMENT OF CAVERNOUS SINUS MENINGIOMAS: A STUDY OF 100 CASES

CLAUDE FABIEN LITRÉ, M.D., PHILIPPE COLIN, M.D., REMY NOUDEL, M.D., PHILIPPE PERUZZI, M.D.,  
ARNAUD BAZIN, M.D., BERNARD SHERPEREEL, M.D., MARIE HELENE BERNARD, M.D.,  
AND PASCAL ROUSSEAUX, M.D.

Department of Neurosurgery, Maison Blanche Hospital, Reims, France

**Purpose:** We discuss our experiences with fractionated stereotactic radiotherapy (FSR) in the treatment of cavernous sinus meningiomas.

**Methods and Materials:** From 1995 to 2006, we monitored 100 patients diagnosed with cavernous sinus meningiomas; 84 female and 16 male patients were included. The mean patient age was 56 years. The most common symptoms were a reduction in visual acuity (57%), diplopia (50%), exophthalmia (30%), and trigeminal neuralgia (34%). Surgery was initially performed on 26 patients. All patients were treated with FSR. A total of 45 Gy was administered to the lesion, with 5 fractions of 1.8 Gy completed each week. Patient treatment was performed using a Varian Clinac linear accelerator used for cranial treatments and a micro-multileaf collimator.

**Results:** No side effects were reported. Mean follow-up period was 33 months, with 20% of patients undergoing follow-up evaluation of more than 4 years later. The tumor control rate at 3 years was 94%. Three patients required microsurgical intervention because FSR proved ineffective. In terms of functional symptoms, an 81% improvement was observed in patients suffering from exophthalmia, with 46% of these patients being restored to full health. A 52% improvement was observed in diplopia, together with a 67% improvement in visual acuity and a 50% improvement in type V neuropathy.

**Conclusions:** FSR facilitates tumor control, either as an initial treatment option or in combination with microsurgery. In addition to being a safe procedure with few side effects, FSR offers the significant benefit of superior functional outcomes. © 2009 Elsevier Inc.

Meningioma, Radiotherapy, Cavernous sinus, Cranial nerves.

### INTRODUCTION

The treatment of cavernous sinus meningiomas (CSM) has progressed over the past 20 years. This transformation has resulted in part from the contribution of anatomical imaging (MR and CT), which has facilitated early diagnostics. However, the emergence of radiosurgery, and more recently of fractionated stereotactic radiotherapy (FSR), has played the most significant role in the development of treatment therapies. These therapies have proved their worth by facilitating both good tumor control (1–4) and significant functional preservation (5–7). Surgery offers excellent tumor control; however, the benefits are limited by a considerable level of functional impairment.

FSR combines the radiobiological benefits of dose fractionation with the precision afforded by the stereotactic approach. Stereotactic localizer and repositioning allows us to use a lower margin (2 mm) and complex ballistic to obtain

a greater gradient between meningioma and normal tissues, especially for optic nerve.

This article discusses the results of our study of FSR treatment, carried out for 100 consecutive cases in which CSM tumors were clearly indicated by anatomical imaging.

### METHODS AND MATERIALS

#### Patients

From 1990 to 2006, we monitored 100 consecutive cases in which CSM tumors were clearly indicated by anatomical imaging and accompanied by corresponding symptoms. An overview is provided in Table 1. The mean patient age during treatment was 56 years (range, 30–73); 84% of the patients treated were female, which is typical for this type of pathology (1, 4, 7–9). Twenty-six percent of the patients were initially treated with what was assumed to be complete surgery. Secondary growth followed, diagnosed on the basis of worsening functional symptoms and confirmed by anatomical imaging.

Table 1. Summary of the main characteristics presented by the patients in our study

| Characteristic        | No. of patients |
|-----------------------|-----------------|
| Sex                   |                 |
| Male                  | 16%             |
| Female                | 84%             |
| Mean age, years       | 56              |
| Range                 | 30–73           |
| Initial microsurgery  | 26              |
| Cavernous sinus grade |                 |
| Grades I–II           | 46%             |
| Grades III–V          | 44%             |
| Symptoms              |                 |
| Diplopia              | 50%             |
| Headache              | 19.5%           |
| Trigeminal neuralgia  | 34%             |
| Optic nerve           | 57%             |
| Exophthalmos          | 30%             |

We used the radiological classification system proposed by Sehar (10) to perform pretreatment grading of the CSM. The results were relatively homogenous, with 8% of tumors being classified as Grade I, 38% as Grade II, 30% as Grade III, 10% as Grade IV, and 8% as Grade V.

#### Functional symptoms

The following symptoms were observed: headaches (19.5%), oculomotor dysfunction (50%), trigeminal neuralgia (34%), exophthalmos (30%), and optic nerve dysfunction, resulting in a reduction in visual acuity (57%).

These symptoms were especially prevalent in those patients who had previously been operated on, with 34% experiencing headaches, 50% showing oculomotor dysfunction, 37.5% experiencing trigeminal neuralgia, 37.5% experiencing exophthalmos, and 67% showing a reduction in visual acuity. Seven of these patients suffered complete loss of vision in one eye following surgery.

#### Radiotherapy

All patients were treated with fractionated stereotactic radiotherapy using the technique previously described (3). A total of 45 Gy was administered to the lesion across 25 fractions. Isodose coverage of 90% was achieved, with five fractions of 1.8 Gy per week. Patient positioning on the treatment table was performed using a BrainLab (BrainLab, Munich, Germany) stereotactic ring combined with a thermoplastic mask (Fig. 1). CT localization was carried out for all patients, followed by MR imaging. Image fusion and treatment planning were then performed using the BrainLab planning station (Fig. 2). Patient treatment was performed using a 8-MV Varian Clinac (Varian Medical Systems, Palo Alto, CA) linear accelerator used for cranial treatments and a BrainLab micro-multileaf collimator. Dose was delivered through 4–5 arctherapies, with dynamic collimation technique for the previous year. Planned target volume was defined as gross target volume plus a 2-mm margin. Maximal dose to normal optic nerve was 4.44 Gy (range, 0.53–4.44 Gy).

Clinical follow-up for each patient (general, ophthalmological, and paraclinical examinations with MR anatomical imaging) was performed every 6 months during the first year and once yearly thereafter. Follow-up began at the end of FSR.

#### Follow-up and statistical analysis

The mean follow-up period was 33 months, with 36% of patients undergoing follow-up evaluation more than 36 months later, 24%

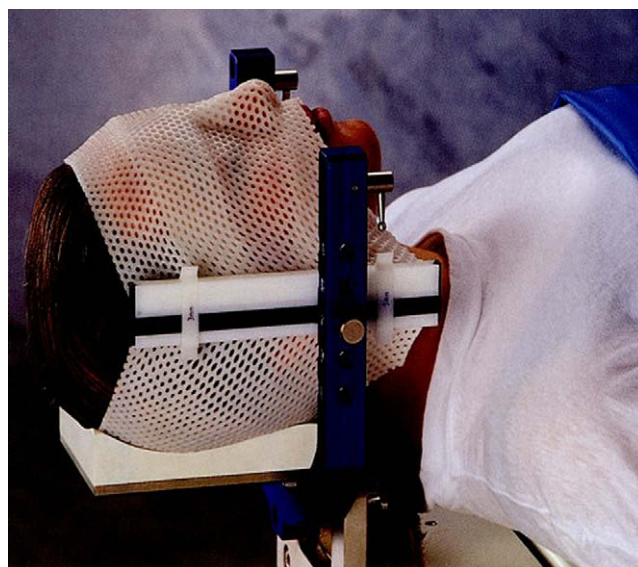


Fig. 1. Reusable BrainLab thermoplastic mask.

more than 48 months later, and 8% more than 10 years later. Follow-up evaluations performed at 48 months are significant because the risk of side effects associated with radiotherapy can be assumed to have decreased by 85% by that time (11).

## RESULTS

#### Tumor control

Following radiotherapy, 9% of the tumors had decreased in volume. The volume of 88% of the tumors was unchanged. Three percent of the tumors were found to have increased in volume at three follow-up evaluations (14, 46, and 108 months). The three patients in question required microsurgery following radiotherapy. This treatment approach was indicated on the basis of tumor growth associated with worsening symptoms. In each case, an anatomical pathology examination indicated a typical meningioma with a high proliferation index. The probability curve for tumor control showed a rate of 94% at both 3 years and 7 years (Fig. 3). These results are reasonably similar to those published for other FSR (Brell *et al.*, 93% at 4 years [1] and radiosurgery studies (Roche *et al.*, 92.8% at 5 years; [7], Pollock and Stafford, 98% at 1 year and 85% at 3 years [6], Mettelus *et al.*, 94.4% at 5 and 10 years [8]); see Table 2.

#### Functional symptoms and complications

No side effects related to FSR were reported during follow-up; in particular, there was no neuropathic toxicity.

The functional effects of FSR are summarized in Fig. 4.

Overall, improvement was seen in 67% of those patients suffering from a reduction in visual acuity, 81% of those suffering from exophthalmos, 50% of those suffering from facial neuralgia, 52% of those suffering from oculomotor dysfunction, and 44% of those suffering from headaches. In cases in whom symptoms worsened (3 patients), this was invariably associated with tumor regrowth. Following radiotherapy,

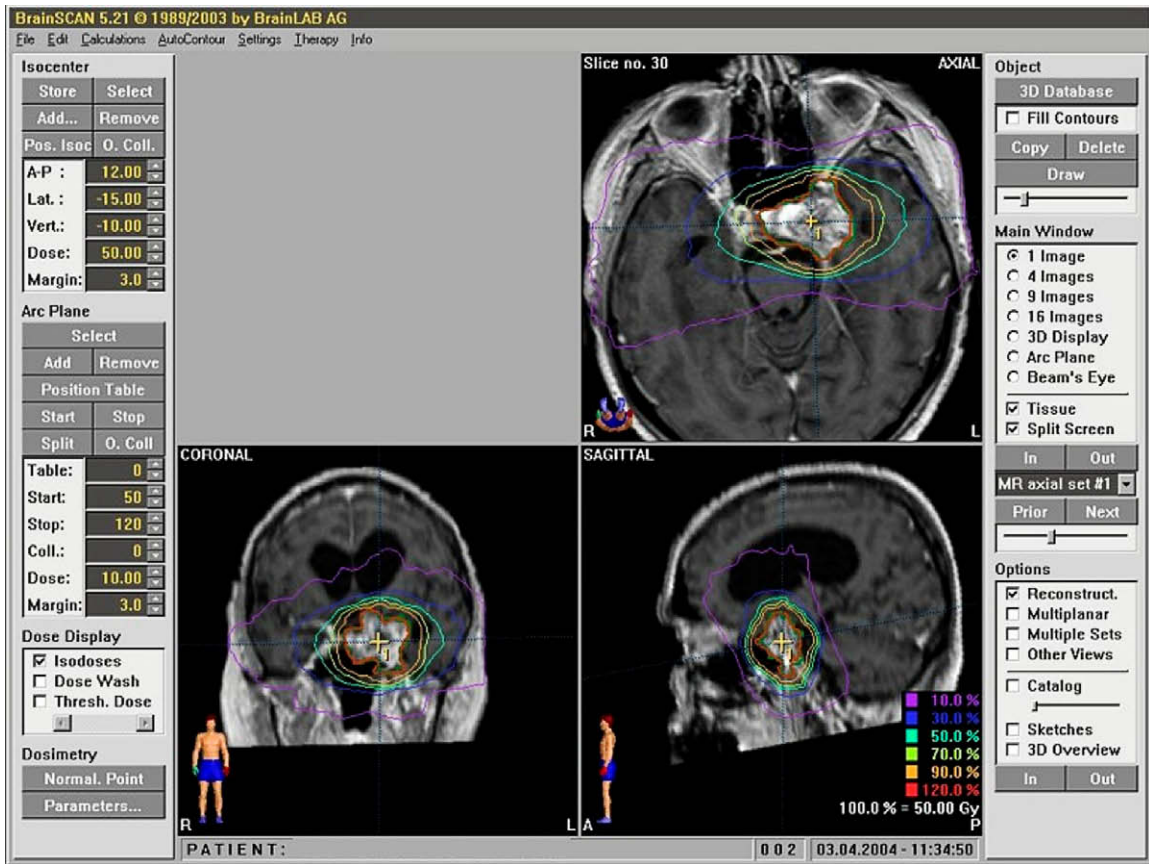


Fig. 2. Dose planning: anatomic (MR) images overlaid with dose planning data.

these patients found that their initial symptoms worsened at different intervals (14, 46, and 108 months), with changes in the tumor volume as indicated by anatomical imaging necessitating additional microsurgery.

## DISCUSSION

Over the past 20 years, the treatment of CSM has progressed steadily, both in terms of the technologies available and in terms of the achievable treatment results. Modern treatment techniques now include resection and tumor control; however, the essential focus is primarily that of functional conservation.

Although surgery generally facilitates complete tumor excision, the functional results of surgery alone are accordingly less than ideal. This can be seen in our study in which patients who were treated with what was assumed to be complete surgery experienced significantly greater functional impairment—in particular, of the optic nerve (Fig. 5).

FSR is an attractive alternative because it facilitates both appropriate tumor control (1, 3, 8, 12, 13) and a significant reduction in functional symptoms. In our study, the best results were achieved for impaired visual acuity (67% improvement). This appears to be a crucial aspect in the decision to perform microsurgery alone.

Patients who were initially treated with microsurgery showed functional improvement not significantly different from that of patients treated with FSR. The overall results

are slightly less impressive, because the functional symptoms before FSR were especially prevalent, particularly in terms of visual acuity, with seven patients suffering complete loss of vision in one eye following surgery (Fig. 5).

During patient follow-up, the majority of functional symptoms show long-term improvement without relapse. Even if symptoms either worsen only slightly or not at all, the

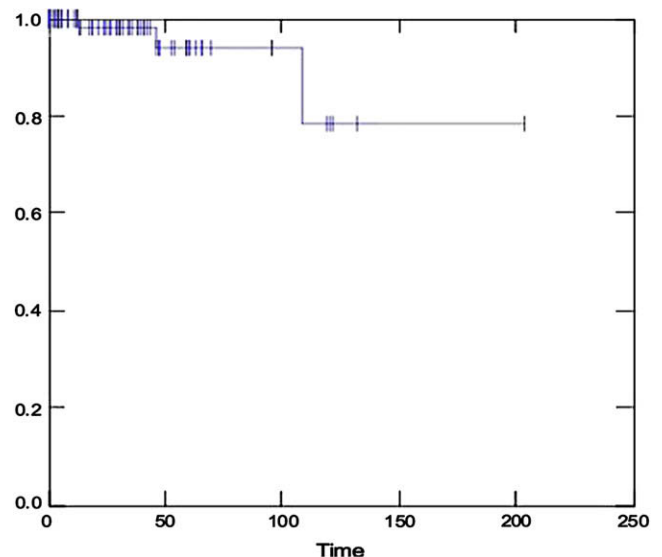


Fig. 3. Kaplan-Meier curve showing the estimated probability curve for the tumor control rate ( $n = 100$  patients).

Table 2. Summary of the main studies on radiation treatment of cavernous sinus meningiomas

|  | Type of Rx  | No. cases | Monitoring period (Months) | PFS            | Improvement: optic nerve | Improvement: OM | Improvement: trigeminal | Improvement: exophthalmos | Failure |
|--|-------------|-----------|----------------------------|----------------|--------------------------|-----------------|-------------------------|---------------------------|---------|
| Metellus <i>et al.</i> , 2005 (8)              | RT conf     | 38        | 88.6                       | 94.7% at 5 yrs | 60%                      | 47%             | 50%                     | NC                        | 2       |
| Metellus <i>et al.</i> , 2005 (8) Neurosurgery | Gamma knife | 36        | 63.6                       | 94.4% at 5 yrs | 50%                      | 50%             | 60%                     | NC                        | 2       |
| Roche <i>et al.</i> , 2000 (7)                 | Gamma knife | 80        | 30.5                       | 92.8% at 5 yrs | NC                       | 27%             | 53%                     | NC                        | 2       |
| Brell <i>et al.</i> , 2006 (1)                 | FSR         | 30        | 50                         | 93% at 4 yrs   | 0%                       | 41%             | 50%                     | 0%                        | 2       |
| Pollock <i>et al.</i> , 2004 (6)               | Gamma knife | 49        | 58                         | 85% at 3 yrs   | NC                       | 14%             | 33%                     | NC                        | 2       |
| Our study                                      | FSR         | 100       | 33                         | 98% at 3 yrs   | 67%                      | 52%             | 50%                     | 81%                       | 3       |

Abbreviations: FSR = stereotactic fractionated radiotherapy; OM = oculomotor; PFS = Progression-free survival; RT = radiation therapy; RT conf: conformal radiotherapy.

associated patient discomfort differs enormously depending on the symptom in question. Even if the majority of patients gradually become accustomed to the residual effects of diplopia or exophthalmos, or to slight headaches, trigeminal neuralgia remains a primarily functional condition. If FSR shows little or no effect, neuralgia remains a debilitating condition that generally requires treatment with strong medication, or even several percutaneous treatments. These in turn carry a not inconsiderable risk of anesthesia dolorosa.

Thanks to the fractionated dose delivery, FSR facilitates a considerable reduction in the risk of neuropathy. Symptoms of this kind were not reported in either our study or that completed by Brell *et al.* (1). It is even possible to irradiate the nerves directly while ensuring appropriate tumor control and functional control (5).

There is no set dose prescription for CSM treatments. Our team gradually reduced the total irradiation dose, moving on average from 55 to 45 Gy, with 90% isodose coverage. This reduction in dose in turn decreases the risk of toxicity, while

ensuring an appropriate tumor control rate. We based this decision on our own expertise with various kinds of irradiated intracerebral tumor (2, 3, 5, 14).

The results are encouraging compared with treatments performed using microsurgery alone. In addition to the risk associated with surgical intervention, the corresponding functional results are less convincing than those achieved with standard stereotactic radiotherapy. Our results are also encouraging compared with treatments performed using microsurgery alone. In addition to the risk associated with surgical intervention (15–17), the microsurgical results are less successful than those achieved with standard stereotactic radiotherapy.

Studies examining microsurgical resection of CSMs show a mortality rate of 1%–10%, with significant postoperative morbidity in 6%–16% of cases and worsening of functional symptoms in 16%–35% of cases (15, 16). De Jesus *et al.* (16) reported a tumor control rate following total resection of 94% at 3 years and 81% at 5 years. These statistics differ from those for the tumor control rate in the case of partial

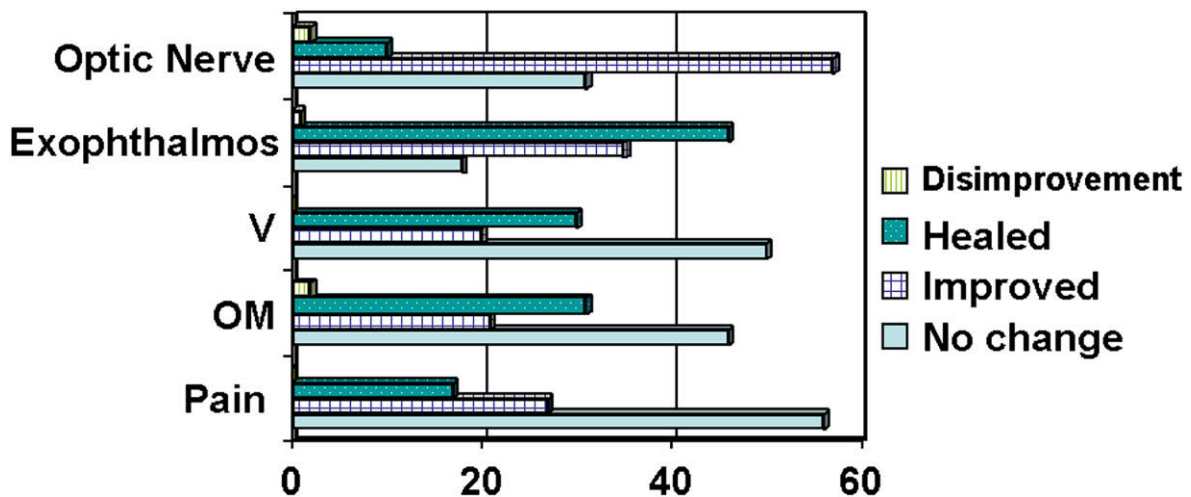


Fig. 4. Summary of the progression of the main functional symptoms in patients treated by stereotactic fractionated radiotherapy.

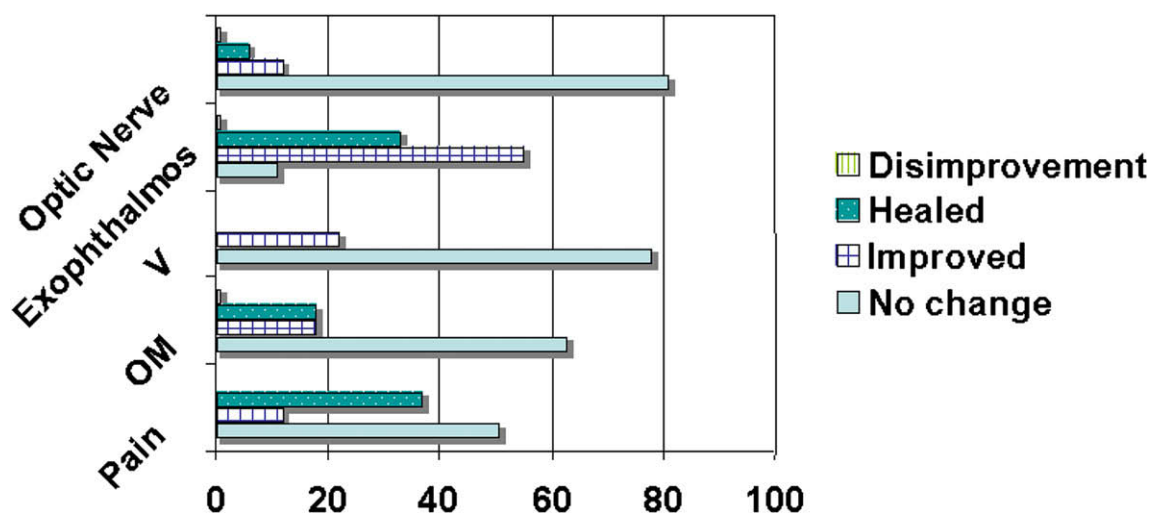


Fig. 5. Summary of the progression of the main functional symptoms in patients initially treated with microsurgery before stereotactic fractionated radiotherapy.

resection (87% at 3 years and 67% at 5 years). It is interesting to note that a study of asymptomatic CSMs that were not treated shows a median growth rate of approximately 0.24 cm per year (mean follow-up period 47 months) (18). In the study carried out by Sindou *et al.* (15) for 100 consecutive cases, 29% experienced a reduction in visual acuity, 19% oculomotor dysfunction, and 24% postoperative trigeminal neuralgia, with a long-term relapse rate of 13.3%.

Given these findings, we do not believe that partial microsurgery alone can be considered an appropriate therapy. Although the patients in question experience fewer functional complications, the tumor control rate is poor. This problem is evident in the case of large CSM that extend into extra-cavernous regions. Here a combined approach appears to be of most benefit. Partial tumor resection, preferably in extra-cavernous regions, effectively facilitates a significant reduction in functional risks while enabling subsequent irradiation of less significant volumes (19) with radiosurgery or FSR. The long-term results regarding tumor control rate and functional symptoms are better than those achieved with standard microsurgery comprising total excision (20).

Radiosurgery can also be considered an attractive alternative treatment because it facilitates treatment in a single session and also offers a tumor control rate comparable to that of other treatments (see summary of studies in Table 2). However, there are certain restrictions associated with this technique. It is not possible to treat lesions with a diameter > 3.5 cm (21, 22); in addition, treatment delivery in a single dose presents a risk of further deterioration in neuropathy (6, 7, 22–26) that can result in loss of the optic nerve. Although the functional results of the various studies published

show significant postoperative improvement, this is nevertheless not as impressive as the potential improvement offered by FSR. Pollock and Stafford (6), for example, found a 28% improvement in diplopia and 17.5% improvement in trigeminal neuralgia. Roche *et al.* (7) reported a 27% improvement in oculomotor dysfunction with a 53% improvement in trigeminal neuralgia.

FSR, like any other radiation treatment technique, requires relatively long-term follow-up. The aim is to monitor the tumor control rate but also to investigate further the complications associated with the treatment, even though the risks associated with radiation treatment decrease considerably after 4 years.

The main treatment techniques all require medium to long-term monitoring. Ten- to fifteen-year follow-up is necessary to have greater confidence in long-term tumor control with using lower doses.

## CONCLUSIONS

FSR is the treatment of choice for CSM. It has shown proven effectiveness both in tumor control and in the improvement of functional symptoms, with few side effects. Validation of results and long-term safety does appear to be necessary, however. There remain certain indications for which initial surgery is considered appropriate, for example, in the case of very large volume tumors.

To summarize, strategies in the treatment of CSMs require further study, particularly given the current dominance of surgery, the combined approach, radiosurgery, and FSR in the range of available treatment therapies.

## REFERENCES

1. Brell M, Villa S, Teixidor P, *et al.* Fractionated stereotactic radiotherapy in the treatment of exclusive cavernous sinus meningioma: Functional outcome, local control, and tolerance. *Surg Neurol* 2006;65:28–33; discussion 33–24.
2. Colin P, Jovenin N, Delemer B, *et al.* Treatment of pituitary adenomas by fractionated stereotactic radiotherapy: A prospective study of 110 patients. *Int J Radiat Oncol Biol Phys* 2005;62:333–341.

3. Colin P, Scavarda D, Delemer B, *et al.* [Fractionated stereotactic radiotherapy: results in hypophyseal adenomas, acoustic neuromas, and meningiomas of the cavernous sinus]. *Cancer Radiother* 1998;2:207–214.
4. Iwai Y, Yamanaka K, Ishiguro T. Gamma knife radiosurgery for the treatment of cavernous sinus meningiomas. *Neurosurgery* 2003;52:517–524; discussion 523–514.
5. Litre CF, Noudel R, Colin P, *et al.* [Fractionated stereotactic radiotherapy for optic nerve sheath meningioma: eight cases]. *Neurochirurgie* 2007;53:333–338.
6. Pollock BE, Stafford SL. Results of stereotactic radiosurgery for patients with imaging defined cavernous sinus meningiomas. *Int J Radiat Oncol Biol Phys* 2005;62:1427–1431.
7. Roche PH, Regis J, Dufour H, *et al.* Gamma knife radiosurgery in the management of cavernous sinus meningiomas. *J Neurosurg* 2000;93(Suppl 3):68–73.
8. Metellus P, Regis J, Muracciale X, *et al.* Evaluation of fractionated radiotherapy and gamma knife radiosurgery in cavernous sinus meningiomas: Treatment strategy. *Neurosurgery* 2005;57:873–886; discussion 873–886.
9. Ziyal IM, Ozgen T. Cavernous sinus meningioma. *J Neurosurg* 2002;96:640–641.
10. Sekhar LN, Levine ZT, Sarma S. Grading of meningiomas. *J Clin Neurosci* 2001;8(Suppl 1):1–7.
11. Debus J, Hug EB, Liebsch NJ, *et al.* Dose–volume tolerance of the brainstem after high-dose radiotherapy. *Front Radiat Ther Oncol* 1999;33:305–314.
12. Milker-Zabel S, Zabel-du Bois A, Huber P, *et al.* Fractionated stereotactic radiation therapy in the management of benign cavernous sinus meningiomas: Long-term experience and review of the literature. *Strahlenther Onkol* 2006;182:635–640.
13. Selch MT, Ahn E, Laskari A, *et al.* Stereotactic radiotherapy for treatment of cavernous sinus meningiomas. *Int J Radiat Oncol Biol Phys* 2004;59:101–111.
14. Keime-Guibert F, Chinot O, Taillandier L, *et al.* Radiotherapy for glioblastoma in the elderly. *N Engl J Med* 2007;356:1527–1535.
15. Sindou M, Wydh E, Jouanneau E, *et al.* Long-term follow-up of meningiomas of the cavernous sinus after surgical treatment alone. *J Neurosurg* 2007;107:937–944.
16. De Jesus O, Sekhar LN, Parikh HK, *et al.* Long-term follow-up of patients with meningiomas involving the cavernous sinus: Recurrence, progression, and quality of life. *Neurosurgery* 1996;39:915–919; discussion 919–920.
17. Pamir MN, Kilic T, Bayrakli F, *et al.* Changing treatment strategy of cavernous sinus meningiomas: Experience of a single institution. *Surg Neurol* 2005;64(Suppl 2):S58–66.
18. Olivero W, Lister J, Elwood P. The natural history and growth rate of asymptomatic meningiomas: A review of 60 patients. *J Neurosurg* 1995;83:222–224; comment in 84:150.
19. Maruyama K, Shin M, Kurita H, *et al.* Proposed treatment strategy for cavernous sinus meningiomas: A prospective study. *Neurosurgery* 2004;55:1068–1075.
20. Maguire P, Clough R, Friedman A. Fractionated external beam radiation therapy for meningiomas of the cavernous sinus. *Int J Radiat Oncol Biol Phys* 1999;44:75–79.
21. Alheit H, Saran F, Warrington A, *et al.* Stereotactically guided radiotherapy for meningiomas. *Radiother Oncol* 1999;50:143–144.
22. Morita A, Coffey R, Foote R, *et al.* Risk of injury to cranial nerves after gamma knife for skull base meningiomas; experience in 88 patients. *J Neurosurg* 1999;90:42–49.
23. Spiegelmann R, Nissim O, Menhel J, *et al.* Linear accelerator radiosurgery for meningiomas in and around the cavernous sinus. *Neurosurgery* 2002;51:1373–1379; discussion 1379–1380.
24. Liu AL, Wang C, Sun S, *et al.* Gamma knife radiosurgery for tumors involving the cavernous sinus. *Stereotact Funct Neurosurg* 2005;83:45–51.
25. Malik I, Rowe JG, Walton L, *et al.* The use of stereotactic radiotherapy in the management of meningiomas. *Br J Neurosurg* 2005;19:13–20.
26. Singh V, Kansai S, Vaishya S, *et al.* Early complications following gamma knife radiosurgery for intracranial meningiomas. *J Neurosurg* 2000;93:57–61.